



HAL
open science

Molecular findings and clinical data in a cohort of 150 patients with anophthalmia/microphthalmia

Nicolas Chassaing, A. Causse, A. Vigouroux, A. Delahayes, J.-L. Alessandri, O. Boespflug-Tanguy, O. Boute-Benejean, H. Dollfus, B. Duban-Bedu, B. Gilbert-Dussardier, et al.

► **To cite this version:**

Nicolas Chassaing, A. Causse, A. Vigouroux, A. Delahayes, J.-L. Alessandri, et al.. Molecular findings and clinical data in a cohort of 150 patients with anophthalmia/microphthalmia. *Clinical Genetics*, 2014, 86 (4), pp.326-334. 10.1111/cge.12275 . hal-01064928

HAL Id: hal-01064928

<https://hal.science/hal-01064928>

Submitted on 24 Feb 2022

HAL is a multi-disciplinary open access archive for the deposit and dissemination of scientific research documents, whether they are published or not. The documents may come from teaching and research institutions in France or abroad, or from public or private research centers.

L'archive ouverte pluridisciplinaire **HAL**, est destinée au dépôt et à la diffusion de documents scientifiques de niveau recherche, publiés ou non, émanant des établissements d'enseignement et de recherche français ou étrangers, des laboratoires publics ou privés.



Short Report

Molecular findings and clinical data in a cohort of 150 patients with anophthalmia/microphthalmia

Chassaing N., Causse A., Vigouroux A., Delahaye A., Alessandri J.-L., Boespflug-Tanguy O., Boute-Benejean O., Dollfus H., Duban-Bedu B., Gilbert-Dussardier B., Giuliano F., Gonzales M., Holder-Espinasse M., Isidor B., Jacquemont M.-L., Lacombe D., Martin-Coignard D., Mathieu-Dramard M., Odent S., Picone O., Pinson L., Quelin C., Sigaudy S., Toutain A., Thauvin-Robinet C., Kaplan J., Calvas P. Molecular findings and clinical data in a cohort of 150 patients with anophthalmia/microphthalmia.

Clin Genet 2014; 86: 326–334. © John Wiley & Sons A/S. Published by John Wiley & Sons Ltd, 2013

Anophthalmia and microphthalmia (AM) are the most severe malformations of the eye, corresponding respectively to reduced size or absent ocular globe. Wide genetic heterogeneity has been reported and different genes have been demonstrated to be causative of syndromic and non-syndromic forms of AM. We screened seven AM genes [*GDF6* (growth differentiation factor 6), *FOXE3* (forkhead box E3), *OTX2* (orthodenticle protein homolog 2), *PAX6* (paired box 6), *RAX* (retina and anterior neural fold homeobox), *SOX2* (SRY sex determining region Y-box 2), and *VSX2* (visual system homeobox 2 gene)] in a cohort of 150 patients with isolated or syndromic AM. The causative genetic defect was identified in 21% of the patients (32/150). Point mutations were identified by direct sequencing of these genes in 25 patients (13 in *SOX2*, 4 in *RAX*, 3 in *OTX2*, 2 in *FOXE3*, 1 in *VSX2*, 1 in *PAX6*, and 1 in *GDF6*). In addition eight gene deletions (five *SOX2*, two *OTX2* and one *RAX*) were identified using a semi-quantitative multiplex polymerase chain reaction (PCR) [quantitative multiplex PCR amplification of short fluorescent fragments (QMPSF)]. The causative genetic defect was identified in 21% of the patients. This result contributes to our knowledge of the molecular basis of AM, and will facilitate accurate genetic counselling.

Conflict of interest

None.

**N. Chassaing^{a,b}, A. Causse^{a,c},
A. Vigouroux^a, A. Delahaye^{d,e},
J.-L. Alessandri^f,
O. Boespflug-Tanguy^g,
O. Boute-Benejean^h, H.
Dollfusⁱ, B. Duban-Bedu^j,
B. Gilbert-Dussardier^k,
F. Giuliano^l, M. Gonzales^{m,n},
M. Holder-Espinasse^h,
B. Isidor^o, M.-L. Jacquemont^p,
D. Lacombe^{q,r},
D. Martin-Coignard^s,
M. Mathieu-Dramard^t, S.
Odent^u, O. Picone^v, L. Pinson^w,
C. Quelin^u, S. Sigaudy^x,
A. Toutain^y,
C. Thauvin-Robinet^{z,aa},
Josseline Kaplan^{ab,ac,ad} and
Patrick Calvas^{a,b}**

^aService de Génétique Médicale, Hôpital Purpan, CHU Toulouse, Toulouse, France, ^bUniversité Paul-Sabatier Toulouse III, Toulouse, France, ^cCHU Toulouse, Service d'Ophtalmologie, Hôpital Purpan, Toulouse, France, ^dUFR SMBH, Université Paris-Nord, Paris 13, Bobigny, France, ^eU676, Inserm, Paris, France, ^fService de Génétique, GHRS-CHU la Réunion, Hôpital Félix Guyon, Paris, France, ^gService de Neurologie Pédiatrique, AP-HP, Hôpital Robert Debré, Paris, France, ^hCHRU, Lille, Service de Génétique Clinique, Hôpital Jeanne de Flandre, CHRU, Lille, France, ⁱService de Génétique Médicale, Hôpitaux Universitaires de Strasbourg, CHU de Hautepierre, Strasbourg cedex, France, ^jGHICL, Centre de Génétique Chromosomique, Lille, France, ^kService de Génétique Médicale, CHU La Milétrie, Poitiers-Cedex, France, ^lService de Génétique Médicale, CHU Hôpital l'Archet 2, Nice, France, ^mAP-HP, Service de Génétique et d'Embryologie Médicales, Hôpital Armand Trousseau,

Paris, France, ⁿUniversité Pierre et Marie Curie-Paris 6, Paris, France, ^oService de Génétique Médicale, CHU Nantes, Nantes, France, ^pService de Génétique, Service de Néonatalogie-Pôle femme-mère-enfant, GHSR-CHU la Réunion, Saint Pierre Cedex, France, ^qService de Génétique Médicale, CHU Bordeaux, Bordeaux, France, ^rLaboratoire MRGM, Université de Bordeaux, Bordeaux, France, ^sUnité de Génétique Clinique, Centre Hospitalier du Mans, Le Mans, France, ^tUnité de génétique clinique, CHU d'Amiens, Amiens, France, ^uService de Génétique Clinique, CHU de Rennes, Rennes, France, ^vAP-HP, Service de Gynécologie-Obstétrique, Hôpital Antoine Béclère, Clamart, France, ^wService de Génétique Médicale et Chromosomique, Hôpital Arnaud de Villeneuve, CHRU Montpellier, Montpellier, France, ^xDépartement de Génétique Médicale, Hôpital Timone-Enfants, Marseille, France, ^yDépartement de Génétique, CHU de Tours, Hôpital Bretonneau, Tours, France, ^zEA 4271 GAD Génétique des Anomalies du Développement, Université de Bourgogne, Dijon, France, ^{aa}Centre de Génétique, Hôpital d'Enfants, CHU Dijon, Dijon, France, ^{ab}Génétique Ophtalmologique INSERM U781 Paris, Paris, France, ^{ac}Département de Génétique, APHP Hôpital Necker, Paris, France, and ^{ad}Université Paris Descartes-Sorbonne Paris Cité, Institut IMAGINE, Paris, France

Key words: anophthalmia – *FOXE3* – *GDF6* – microphthalmia – *OTX2* – *PAX6* – *RAX* – *SOX2* – *VSX2*

Corresponding author: Dr Nicolas Chassaing, Service de Génétique Médicale, Pavillon Lefebvre, CHU Purpan, Place du Dr Baylac, 31059 Toulouse Cedex 9, France.
Tel.: +33 5 61 77 90 55;
fax: +33 5 62 74 45 58;
e-mail: chassaing.n@chu-toulouse.fr

Received 12 July 2013, revised and accepted for publication 5 September 2013

Anophthalmia and microphthalmia (AM) are severe ocular developmental defects. Anophthalmia refers to the complete absence of ocular tissue in the orbit (true anophthalmia), or the absence of ocular tissue on clinical examination (clinical anophthalmia). Microphthalmia corresponds to a globe with a total axial length that is at least two standard deviations below the mean for age (<19 mm in a 1-year-old child, <21 mm in an adult) (1, 2). Colobomatous microphthalmia

corresponds to microphthalmia associated with failure of closure of the ectodermal optic vesicle fissure. The prevalence of AM is estimated as being between 3 and 30 per 100,000 births (1). AM can be associated with additional malformations in 33–95% of cases (3).

The aetiology of AM is diverse and includes both environmental and heritable factors. Genetic causes are thought to account for the majority of AM and the empirical recurrence risk in siblings without a

clear aetiology or family history is estimated to be 10–15% (1). The genetic basis, either monogenic or chromosomal, is identified in about 25–30% of patients (3). In order to delineate the frequency and the phenotypes associated with mutations in AM genes better, we performed molecular screening of seven of these genes [*GDF6* (growth differentiation factor 6), *FOXE3* (forkhead box E3), *OTX2* (orthodenticle protein homolog 2), *PAX6* (paired box 6), *RAX* (retina and anterior neural fold homeobox), *SOX2* (SRY sex determining region Y-box 2), and *VSX2* (visual system homeobox 2 gene)] in a cohort of 150 AM patients.

Patients and methods

Patients

One hundred and fifty samples from patients diagnosed with unilateral or bilateral AM were sent to our laboratory for molecular screening. The study respected the principles expressed in the Declaration of Helsinki. We retrospectively reviewed the clinical records and molecular results. The age of the index patients ranged from fetuses to 52-year-old adults. Among these, 41 displayed clinical anophthalmia, 53 microphthalmia, and 56 colobomatous microphthalmia. Ocular involvement was unilateral in 41 patients and bilateral in 109. It was isolated in 86 patients, and associated with other malformations in 64 patients. Most cases (122/150) were sporadic. The family history indicated dominant inheritance (one affected parent) in 13 families, recessive inheritance (one affected sibling) in 12, and was unclear in 3 families (affected cousin). 14 patients were born to consanguineous parents. Clinical data of the patients carrying mutations are described in the Appendix S1 and summarized in Table 1. Some examples of the eye phenotypes are shown in Fig. 1.

Mutation screening

DNA was extracted from blood, frozen tissue or paraffin-embedded tissue (fetuses). The number of AM genes molecularly screened in our laboratory increased progressively as new genes were identified and seven genes (*GDF6*, *FOXE3*, *OTX2*, *PAX6*, *RAX*, *SOX2*, and *VSX2*) were studied by direct sequencing. In four of these genes (*OTX2*, *RAX*, *SOX2*, and *VSX2*), quantitative multiplex polymerase chain reaction (PCR) amplification of short fluorescent fragments (QMPSF) was performed in order to detect deletions or duplications. The size of identified deletions was evaluated by 180K array-comparative genomic hybridization (CGH) in deletion carrying patients. Other AM genes which have been identified more recently were not covered in the gene tests performed in this cohort. Detailed methods are given in the Appendix S1.

Results and discussion

The causative molecular defect was identified in 32 of 150 (21%) patients. Mutations were identified in the

seven genes tested: *SOX2* ($n = 18$), *OTX2* ($n = 5$), *RAX* ($n = 4$), *FOXE3* ($n = 2$), *VSX2* ($n = 1$), *PAX6* ($n = 1$), and *GDF6* ($n = 1$). The mutation detection rate was higher in anophthalmic patients (22/41, 54%). A family history of AM only moderately increases the mutation detection rate, to 32% (9/28), when compared with sporadic cases (23/122, 19%). In addition, mutations were more frequently found in bilateral forms (28/109, 26%) than in unilateral (4/41, 10%). The presence of extra-ocular features slightly increases the mutation detection rate (16/64, 25%) compared with isolated ocular involvement (16/86, 18%).

Results from this series are described below and summarized in Table 1.

SOX2

Heterozygous *SOX2* [SRY (sex determining region Y)-box 2] mutations were identified in 18 of 150 AM patients. Sequencing identified eight small intragenic deletions/duplications, two nonsense and three missense mutations all involving conserved amino-acids located within the DNA binding domain and predicted to be probably damaging by *in silico* analyses. In addition, QMPSF analysis allowed the identification of five whole gene deletions (Fig. 2a), thus corresponding to 5 out of 18 (28%) of the *SOX2* mutations. Array-CGH of four showed that deletion sizes were highly variable between patients, ranging from 0.08 to 4.3 Mb (Fig. 2b, Table S2). In 12 of 13 cases where parents were analysed the mutation appeared *de novo*, while in the remaining case, somatic mosaicism was identified in the mother.

To date, including the 10 novel mutations reported herein, 58 different mutations have been described. Currently *SOX2*, which is mutated in about 10–15% of AM patients, represents the most frequently involved AM gene. Within this series, *SOX2* mutations were identified in 18 out of 150 (12%) of patients. The *SOX2* anophthalmia syndrome was originally described with ocular malformations (most often bilateral and severe) associated with developmental delay, seizures, mesial temporal brain malformations, growth failure, subtle facial dysmorphism and male genital tract abnormalities (4). *SOX2* mutations were also identified in the anophthalmia–esophageal–genital (AEG) syndrome (5), and various additional features were secondarily reported. The ocular phenotype has been extended to less severe malformations, and even to the absence of macroscopic or microscopic eye malformations (6). In this study, ocular involvement was often bilateral (17/18) and frequently severe with at least one absent eye (15/18). The main extra-ocular features were developmental delay, brain anomalies (mainly affecting the corpus callosum and cerebellum), hypogonadism, and short stature. Oesophageal abnormalities were present in three patients and cleft lip/palate in two.

SOX2 anophthalmia is inherited in an autosomal dominant manner, with most cases resulting from a *de novo* mutation. However, germline mosaicism leading to recurrence in siblings has been described in

Table 1. Phenotype and genotype of mutated patients^{a, b}

Patient	Age	Mutated gene	Mutation (cDNA)	Mutation (protein)	Protein domain involved	Family History	Phenotype				
							Right eye	Left eye	Brain	Intellectual disability	Other
1	32 y	SOX2	c.(?-30)_(*220_?)del	SOX2del	-	-	Ano	Ano	CCA Vermian hypoplasia	+	Short stature
2	30 wg	SOX2	c.(?-30)_(*220_?)del	SOX2del	<i>De novo</i>	-	Micro	Ano	N	-	-
3	8 y	SOX2	c.(?-30)_(*220_?)del	SOX2del	-	-	Ano	Ano	CCH Periventricular heterotopia	+	Short stature
4	5 y	SOX2	c.(?-30)_(*220_?)del	SOX2del	<i>De novo</i>	-	Ano	Ano	N	+	GH deficiency Micropenis
5	30 wg	SOX2	c.(?-30)_(*220_?)del	SOX2del	<i>De novo</i>	-	N	Micro	N	-	Oesophageal atresia
6	2 m	SOX2	c.70_86del	p.Ala29Glyfs*66	-	Germinal mosaicism with recurrence	Ano	Ano	N	-	Oesophageal atresia
7	28 wg	SOX2	c.86_95dup	p.Asn33Glyfs*66	-	<i>De novo</i>	Ano	Ano	N	-	-
8	4 y	SOX2	c.151T>C	p.Trp51Arg	HMG-box domain	-	Ano	Micro	CCH	+	Hypogonadism Micropenis
9	23 wg	SOX2	c.158_174delinsATG	p.Arg53Hisfs*37	-	<i>De novo</i>	Ano	Ano	Ventriculomegaly	-	-
10	24 wg	SOX2	c.200delA	p.His67Profs*35	-	<i>De novo</i>	Micro	Micro	N	-	-
11	37 y	SOX2	c.221G>C	p.Arg74Pro	HMG-box domain	-	Retinal dysplasia	Micro	Retinal dysplasia	+	Hypogonadism GH deficiency
12	17 y	SOX2	c.236G>C	p.Trp79Ser	HMG-box domain	<i>De novo</i>	Micro	Ano	-	+	Cleft palate
13	2 y	SOX2	c.245delT	p.Leu82Cysfs*20	-	<i>De novo</i>	Ano	Ano	N	+	Atrial septal defect Pyelic dilatation
14	8 y	SOX2	c.255_256delGGinsT	p.Thr85Thrfs*17	-	<i>De novo</i>	Ano	Ano	Left cerebellar hemisphere hypoplasia	+	Cryptorchidism
15	11 y	SOX2	c.310G>T	p.Glu104*	-	<i>De novo</i>	Ano	Micro	CCH	+	Oesophageal stenosis
16	23.5 wg	SOX2	c.476_479dup	p.Tyr160*	-	-	Ano	Ano	N	-	Micropenis
17	20 y	SOX2	c.513C>G	p.Tyr171*	-	<i>De novo</i>	Ano	Ano	CCH Vermian hypoplasia	+	Bilateral cleft L/P GH deficiency Hypogonadism
18	28 y	SOX2	c.599delA	p.Tyr200Serfs*2	-	<i>De novo</i>	Micro	Ano	N	+	GH deficiency Hypogonadism
19	33 wg	OTX2	c.(?-30)_(*220_?)del	OTX2del	-	-	Ano	Ano	Ventriculomegaly Vermian heterotopia Cortical dysplasia	-	-

Table 1. Continued

Patient	Age	Mutated gene	Mutation (cDNA)	Mutation (protein)	Protein domain involved	Family History	Phenotype				
							Right eye	Left eye	Brain	Intellectual disability	Other
20	24 y	OTX2	c.(?-30)_(*220_?)del	OTX2del		Three generations	Micro Coloboma	Micro Coloboma	N	+	-
21	23.5 wg	OTX2	c.289C>T	p.Arg97*		-	Ano	N	N	-	-
22	31 y	OTX2	c.289C>T	p.Arg97*		Four generations One son displayed otocephaly	Ano	N	N	-	-
23	22 y	OTX2	c.316delC	p.Gln106Asnfs*11		Five generations Three affected related displayed otocephaly	Ano	Ano	N	+	-
24	4 y	RAX	c.478T>C	p.Tyr160His	Homeodomain	One affected sibling	Micro	Micro	N	+	-
25	18 m	RAX	c.563G>A	p.Arg188Gln	Homeodomain	-	Ano	Ano	N	-	-
26	2 y	RAX	c.560G>A	p.Arg187Gln	Homeodomain	-	Ano	Ano	N	-	-
27	26 wg	RAX	c.560G>A c.664delT c.909C>G	p.Arg187Gln p.Ser222Argfs*62 p.Tyr303*		-	Ano	Ano	N	-	-
28	7 y	FOXE3	c.(?-30)_(*220_?)del c.685_686insTCCGGAGC c.685_686insTCCGGAGC	p.Ser222* RAXdel p.Ala230Argfs*2 p.Ala230Argfs*2		One affected cousin born to consanguineous parents	Micro Sclerocornea	Micro Sclerocornea	N	+	-
29	23 y	FOXE3	c.720C>A	p.Cys240*		One affected sibling	Micro Sclerocornea	Micro Sclerocornea	N	-	Polycystic ovarian syndrome
30	2 y	PAX6	c.720C>A c.418G>C	p.Cys240* p.Arg19Pro	Paired domain	One affected sibling	Micro Sclerocornea	Micro Sclerocornea	N	-	-
31	3 y	VSX2	c.71_72insG c.667G>A	p.Ala25Argfs*101 p.Gly223Arg	CVC domain	One affected sibling	Micro Cataract Coloboma	Micro Cataract Coloboma	N	-	-
32	4.5 y	GDF6	c.980C>A	p.Pro327His	TGF-β prodomain	Inherited from asymptomatic father	N	Micro Coloboma	N	-	-

Ano, anophthalmia; COA, corpus callosum agenesis; COH, corpus callosum hypoplasia; cDNA, complementary DNA; empty box, information unknown/micro, microphthalmia; GH, growth hormone; HMG-box, high mobility group box; m, months; N, normal; empty box: absent data; TGF, transforming growth factor; wg, weeks of gestation; y, years; -, absence; +, presence.
^aThe italicized patient numbers correspond to already reported patients (Appendix S1). Novel mutations identified in this study are indicated in bold.
^bSequence variations were numbered considering Adenine of the ATG initiation codon as the first nucleotide (GenBank accession NM_001001557.2 [GDF6], NM_012186.2 [FOXE3], NM_021728.2 [OTX2], NM_001604.4 [PAX6], NM_013435.2 [RAX], NM_003106.3 [SOX2], and NM_182894.2 [VSX2]).

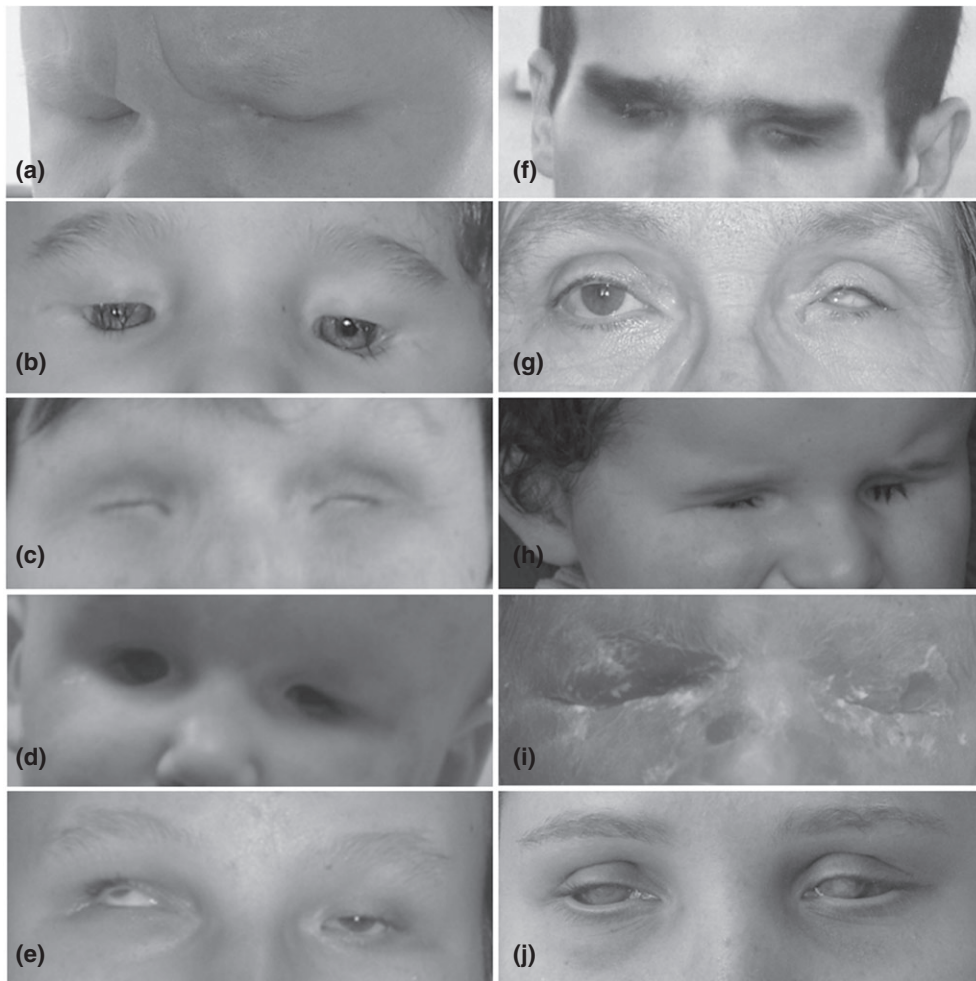


Fig. 1. Ocular involvement in patients carrying mutations. Examples of ocular involvement in patients with *SOX2* mutations ((a–e) corresponding to P1, P3, P11, P13, and P18, respectively); *OTX2* mutations ((f, g) corresponding to P23 and P23's aunt, respectively); *RAX* mutations ((h, i) corresponding to P24 and P27, respectively); and *FOXE3* mutations ((j) P29). Note unilateral (G) or bilateral anophthalmia-microphthalmia (a–f, h–j) associated with sclerocornea in P29 (j).

three families. There is no clear genotype/phenotype correlation.

OTX2

OTX2 mutations were identified in 5 of 150 (3%) AM patients including two patients with an *OTX2* gene deletion (Table S2). The *OTX2* mutation was inherited from a symptomatic parent in three families, and in two cases, no family history was mentioned but parents' samples were unavailable for analysis.

A total of 31 *OTX2* different mutations (14 frameshift, 9 nonsense, 7 missense, and whole gene deletion) have been reported. *OTX2* mutations are associated with a broad spectrum of ocular phenotypes, intellectual deficiency, seizures, brain malformations, pituitary abnormalities, and short stature (7). More recently, we described involvement of *OTX2* mutations in otocephaly-agnathia (8). In this study, clinical presentation was variable, even within families, ranging from bilateral anophthalmia to unilateral mild

microphthalmia. Otocephalic cases were reported in two families.

OTX2 anophthalmia is inherited in an autosomal dominant manner with variable expressivity and incomplete penetrance. Germline mosaicism has been described in two families.

RAX

Homozygous or compound heterozygous *RAX* mutations were identified in 4 of 150 (3%) patients, bringing the number of described *RAX* mutations to 10. Including the four patients in this report, only seven patients with *RAX* mutations have been described. The ocular phenotype associated with recessive *RAX* mutations is often bilateral and severe. Neurological involvement (intellectual deficiency, autistic features) was observed in three out of seven described patients. Apart from cerebral involvement, no other extra-ocular malformation was associated with *RAX* mutations. *RAX* anophthalmia is inherited in an autosomal recessive manner.

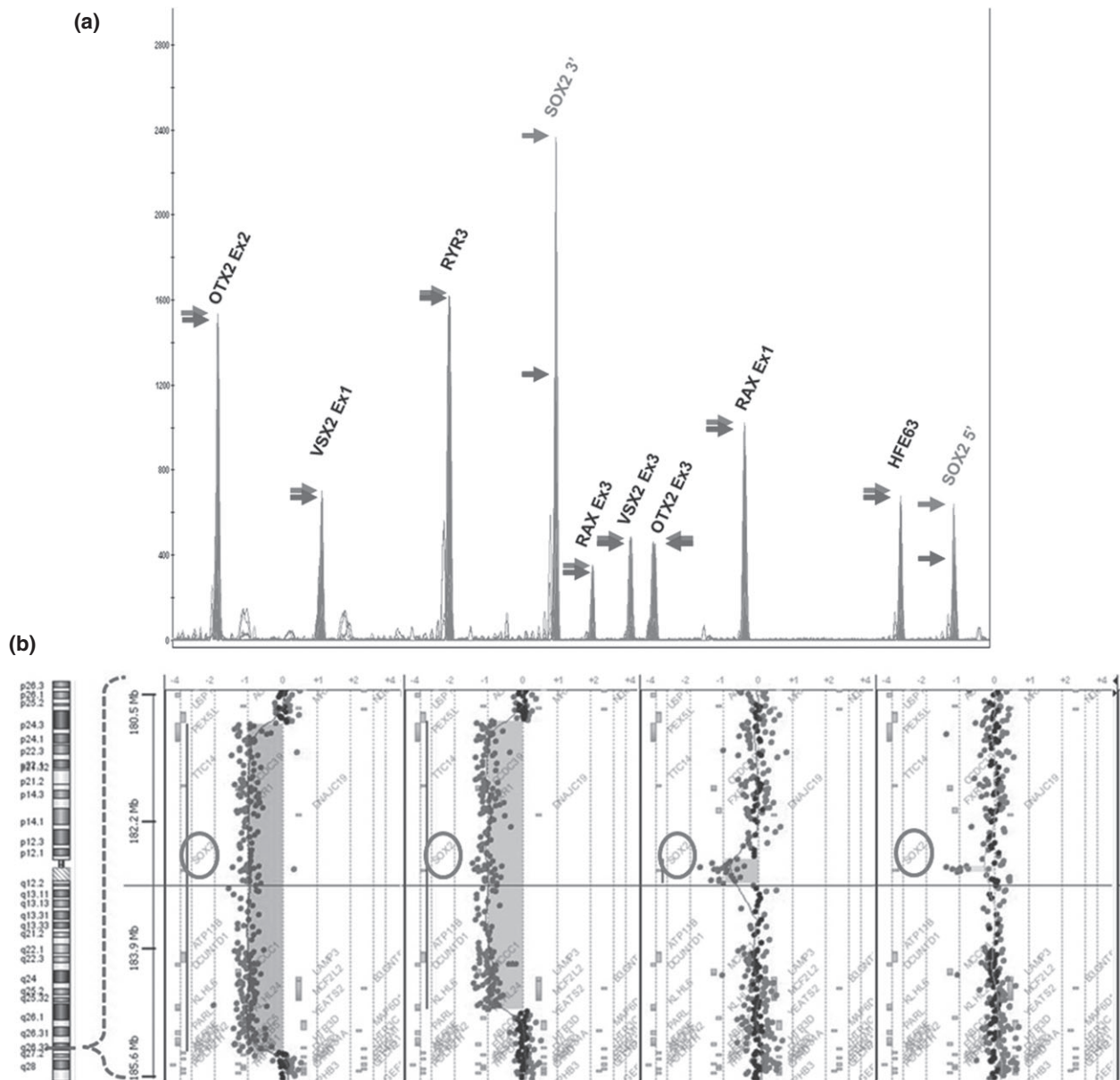


Fig. 2. Identification of *SOX2* deletion by quantitative multiplex PCR amplification of short fluorescent fragments (QMPSF) and characterization of the deletion sizes by array-comparative genomic hybridization (CGH). **(a)** Example of *SOX2* deletion revealed by QMPSF. Amplification profile of one patient sharing the deletions (in blue), and of a normal control (in red) are superimposed. Fluorescent profiles are normalized using the control amplicons *RYR3* and *HFE63*. Intensity of each peak is indicated by an arrow, blue for the patient bearing the deletion, red for the control. The twofold reduction in the intensity of *SOX2* peaks is to the result of the heterozygous deletion **(b)** Gene view of the region 3q26.33-3q27.1 (Chromosome 3: 180,556,405–185,680,405 – hg18 – view of 5.12 Mb) produced by the Agilent CGH ANALYTICS software and showing the aberrant deletions, which are highlighted in colour. The *SOX2* gene is surrounding in red. The dots correspond to the array targets, arranged on the y-axis according to their genomic position and on the x-axis according to their log₂ intensity ratio value.

FOXE3

FOXE3 mutations were identified in 2 of 150 AM patients. Both were born to consanguineous parents. One patient had a recurrent homozygous nonsense mutation (c.720C>A [p.C240*]), while the other had a novel homozygous frameshifting mutation c.685_686insTCCGGAGC. *FOXE3* mutations have previously been associated with autosomal dominant anterior segment anomalies (9), autosomal recessive

primary aphakia (10), and autosomal recessive microphthalmia (11). A total of 13 different *FOXE3* mutations have been described, 8 leading to a recessively inherited phenotype and 5 associated with dominant inheritance. Interestingly, four of the five dominant mutations correspond to non-stop mutations suggesting that the extended protein may have a dominant negative effect, while the recessive mutations would be loss of function mutations. Dominant mutations mainly cause

anterior segment dysgenesis, while recessive mutations cause a more severe ocular phenotype adding microphthalmia to the anterior segment dysgenesis. No other extra-ocular malformation has previously been associated with *FOXE3* mutations. In our cohort, one patient carrying a homozygous *FOXE3* mutation displayed intellectual deficiency and autistic features.

PAX6

A heterozygous missense mutation in the *PAX6* gene was identified in 1 of 150 AM patients. This patient has bilateral microphthalmia and sclerocornea, while her sister has a left microphthalmia and sclerocornea and right partial iris hypoplasia. Both had the same missense mutation (c.418G>C [p.Arg19Pro]). This mutation involved a conserved amino-acid in the paired domain. The change was predicted to be damaging *in silico*. Neither clinical data nor samples were available for the parents. More than 300 *PAX6* mutations have been identified (The Human *PAX6* mutation Database see <http://lsdb.hgu.mrc.ac.uk>) and are typically associated not only with autosomal dominant aniridia but also affect the cornea, lens and retina (12). Although we have identified *PAX6* mutations in patients referred for aniridia with mild microphthalmia, this is the sole example of *PAX6* involvement in our cohort of patients referred for AM.

VSX2

VSX2 compound heterozygous mutations were identified in 1 of 150 AM patients. This patient, who had bilateral colobomatous microphthalmia and cataracts, was a compound heterozygote for two novel mutations (c.71_72insG, and p.Gly223Arg), thus bringing the total of *VSX2* mutations described to 11. The p.Gly223Arg involved a conserved amino-acid located in the conserved CVC domain of the protein, and was evaluated separately by POLYPHEN-2 (damaging) and by SIFT (tolerated). It is absent in a control population (Exome Variant Server). A missense mutation involving the same amino-acid (p.Gly223Ala) had previously been reported in association with AM, suggesting that p.Gly223Arg could be deleterious. *VSX2* mutations have previously been associated with microphthalmia and coloboma and/or anterior chamber abnormalities. *VSX2* anophthalmia is inherited in an autosomal recessive manner.

GDF6

One heterozygous *GDF6* mutation was identified in 1 of 150 AM patients. He had unilateral colobomatous microphthalmia without skeletal involvement. The missense mutation (c.980C>A [p.Pro327His]) had been previously reported in association with microphthalmia (13). The variation was inherited from the asymptomatic father in our patient as in the published case. p.Pro327His is predicted to be benign *in silico*. It is, however, absent in a control population (Exome Variant Server and (13)). Functional studies are likely to

be needed to determine more conclusively whether this variant does indeed produce a deleterious effect.

GDF6 loss-of-function mutations were first associated with skeletal defects and subsequently with ocular defects (microphthalmia and coloboma) (13, 14). This oculo-skeletal syndrome is inherited in an autosomal dominant manner, with incomplete penetrance.

Conclusion

The overall mutation detection rate in this cohort is 21% (32/150) after screening the seven selected genes (*GDF6*, *FOXE3*, *OTX2*, *PAX6*, *RAX*, *SOX2*, and *VSX2*). Importantly, whole gene deletion represents a high percentage of the identified mutations, especially for *SOX2* and *OTX2*. No mutation was found in the vast majority (about 80%) of AM patients. Other genes are known to be involved. Some have been identified in syndromic and non-syndromic AM by array-CGH (e.g. *BMP4* and *TMX3*), by linkage analysis (e.g. *SMOC1* and *STRA6*) or by a candidate gene approach (e.g. *VAX1* and *BMP7*). In addition, next-generation sequencing has allowed the identification of several novel AM genes (e.g. *ALDH1A3*, *ATOH7*, *c12orf57*, *FNBP4*, *ODZ3*...). However, mutations in each of these genes explain the symptoms in only a very small percentage of AM patients, and it seems likely that only a small proportion of AM causative genes have so far been identified. While this represents a vast genetic heterogeneity, this is not entirely surprising in the developmental process of such a complex organ.

The existence of a range of modes of inheritance, germline mosaicism, and incomplete penetrance all pose particular challenges for genetic counselling. Clinical overlaps within patients and genetic heterogeneity have led to difficulties in designing an efficient screening strategy. Advances in high throughput sequencing will allow a larger set of AM genes to be screened for diagnostic purposes (15). High throughput sequencing (whole exome and whole genome) also represent to date a better method for the identification of new AM genes.

Phenotypic variability, asymmetric ocular involvement, and incomplete penetrance reflect the complexity of the developmental process, driven by interacting networks and modulated by stochastic events and environmental influences. Identifying novel genes and deciphering factors determining the clinical presentation represent further essential steps to achieve.

Supporting Information

The following Supporting information is available for this article:

Table S1. Primers used for direct sequencing and quantitative multiplex PCR amplification of short fluorescent fragments (QMPSF) analysis

Table S2. Deletions characterized using array-comparative genomic hybridization (array-CGH) Agilent 180K

Appendix S1. Clinical spectrum and molecular findings in a cohort of 150 patients with microphthalmia/anophthalmia.

Additional Supporting information may be found in the online version of this article.

Acknowledgements

The authors would like to thank the families for their participation and the following physicians and technicians for their assistance: Ludivine Pouey, Claire Scaramouche, Beaudou Joelle, Florence Nicot, Léopoldine Lequeux, Sirine Hammoud, le CPDPN de Besançon and the SOFFOET. Authors are indebted to Samantha Leonard for her help in preparing the manuscript.

This work was supported by grants from the Clinical Research Hospital Program from the French Ministry of Health (PHRC 09 109 01), and by Retina France.

References

1. Verma AS, Fitzpatrick DR. Anophthalmia and microphthalmia. *Orphanet J Rare Dis* 2007; 2: 47.
2. Weiss AH, Kousseff BG, Ross E, Longbottom J. Simple microphthalmos. *Arch Ophthalmol* 1989; 107: 1625–1630.
3. Slavotinek AM. Eye development genes and known syndromes. *Mol Genet Metab* 2011; 104: 448–456.
4. Ragge NK, Lorenz B, Schneider A et al. SOX2 anophthalmia syndrome. *Am J Med Genet A* 2005; 135: 1–7 discussion 8.
5. Williamson KA, Hever AM, Rainger J et al. Mutations in SOX2 cause anophthalmia-esophageal-genital (AEG) syndrome. *Hum Mol Genet* 2006; 15: 1413–1422.
6. Chassaing N, Gilbert-Dussardier B, Nicot F et al. Germinal mosaicism and familial recurrence of a SOX2 mutation with highly variable phenotypic expression extending from AEG syndrome to absence of ocular involvement. *Am J Med Genet A* 2007; 143: 289–291.
7. Schilter KF, Schneider A, Bardakjian T et al. OTX2 microphthalmia syndrome: four novel mutations and delineation of a phenotype. *Clin Genet* 2011; 79: 158–168.
8. Chassaing N, Sorrentino S, Davis EE et al. OTX2 mutations contribute to the otocephaly-dysgnathia complex. *J Med Genet* 2012; 49: 373–379.
9. Semina EV, Brownell I, Mintz-Hittner HA, Murray JC, Jamrich M. Mutations in the human forkhead transcription factor FOXE3 associated with anterior segment ocular dysgenesis and cataracts. *Hum Mol Genet* 2001; 10: 231–236.
10. Valleix S, Niel F, Nedelec B et al. Homozygous nonsense mutation in the FOXE3 gene as a cause of congenital primary aphakia in humans. *Am J Hum Genet* 2006; 79: 358–364.
11. Iseri SU, Osborne RJ, Farrall M et al. Seeing clearly: the dominant and recessive nature of FOXE3 in eye developmental anomalies. *Hum Mutat* 2009; 30: 1378–1386.
12. Tzoulaki I, White IM, Hanson IM. PAX6 mutations: genotype-phenotype correlations. *BMC Genet* 2005; 6: 27.
13. Asai-Coakwell M, French CR, Ye M et al. Incomplete penetrance and phenotypic variability characterize Gdf6-attributable oculo-skeletal phenotypes. *Hum Mol Genet* 2009; 18: 1110–1121.
14. Tassabehji M, Fang ZM, Hilton EN et al. Mutations in GDF6 are associated with vertebral segmentation defects in Klippel-Feil syndrome. *Hum Mutat* 2008; 29: 1017–1027.
15. Jimenez NL, Flannick J, Yahyavi M et al. Targeted 'next-generation' sequencing in anophthalmia and microphthalmia patients confirms SOX2, OTX2 and FOXE3 mutations. *BMC Med Genet* 2011; 12: 172.