



HAL
open science

Azole-resistant *Aspergillus fumigatus* isolate with the TR34/L98H mutation in both a fungicide-sprayed field and the lung of a hematopoietic stem cell transplant recipient with invasive aspergillosis.

Steffi Rocchi, Etienne Daguindau, Frédéric Grenouillet, Eric Deconinck, Anne-Pauline Bellanger, Dea Garcia-Hermoso, Stéphane Bretagne, Gabriel Reboux, Laurence Millon

► **To cite this version:**

Steffi Rocchi, Etienne Daguindau, Frédéric Grenouillet, Eric Deconinck, Anne-Pauline Bellanger, et al.. Azole-resistant *Aspergillus fumigatus* isolate with the TR34/L98H mutation in both a fungicide-sprayed field and the lung of a hematopoietic stem cell transplant recipient with invasive aspergillosis.. *Journal of Clinical Microbiology*, 2014, 52 (5), pp.1724-6. 10.1128/JCM.03182-13 . hal-01063888

HAL Id: hal-01063888

<https://hal.science/hal-01063888v1>

Submitted on 5 Sep 2024

HAL is a multi-disciplinary open access archive for the deposit and dissemination of scientific research documents, whether they are published or not. The documents may come from teaching and research institutions in France or abroad, or from public or private research centers.

L'archive ouverte pluridisciplinaire **HAL**, est destinée au dépôt et à la diffusion de documents scientifiques de niveau recherche, publiés ou non, émanant des établissements d'enseignement et de recherche français ou étrangers, des laboratoires publics ou privés.

Copyright

Azole-Resistant *Aspergillus fumigatus* Isolate with the TR34/L98H Mutation in Both a Fungicide-Sprayed Field and the Lung of a Hematopoietic Stem Cell Transplant Recipient with Invasive Aspergillosis

Steffi Rocchi,^{a,b} Etienne Daguindau,^c Frédéric Grenouillet,^{a,b} Eric Deconinck,^{c,d} Anne-Pauline Bellanger,^{a,b} Dea Garcia-Hermoso,^e Stéphane Bretagne,^e Gabriel Reboux,^{a,b} Laurence Millon^{a,b}

Chrono-Environnement UMR 6249 CNRS, Franche-Comté University, Besançon, France^a; Parasitology-Myecology Department^b and Clinical Hematology Department,^c University Hospital, Besançon, France; INSERM UMR 1098, Franche-Comté University, Besançon, France^d; Institut Pasteur, Unité de Mycologie Moléculaire, Centre National de Référence Mycologie et Antifongiques and CNRS URA3012, Paris, France^e

A French farmer developed invasive aspergillosis with azole-resistant *Aspergillus fumigatus* with the TR34/L98H mutation following a hematopoietic stem cell transplantation. He had worked in fungicide-sprayed fields where a non-genetically related *A. fumigatus* TR34/L98H isolate was collected. If azole resistance detection increases, voriconazole as first-line therapy might be questioned in agricultural areas.

Despite improvements in diagnosis and therapy, invasive aspergillosis (IA) still has a poor prognosis in hematological patients. The first-line treatment of IA is usually azole antifungals. Voriconazole yields response and survival rates 15 to 20% higher than those of nonazole regimens (1). However, in recent years, azole resistance in *Aspergillus fumigatus* has been increasingly reported in probable association with azole failure (2, 3). In the Netherlands, the main mechanism suggested in hematology is the acquisition of resistant isolates from the environment due to the increasingly extensive use of 14- α -demethylase inhibitor fungicides in agriculture (4). The presence of the TR34/L98H azole resistance mechanism has been increasingly reported in clinical and environmental *A. fumigatus* isolates throughout Europe (Netherlands, United Kingdom, Norway, Spain, Denmark, Belgium, France, Germany) and Asia (India, China, Iran) (see reference 5 and references therein). To date, only a few cases of IA due to a resistant strain of *A. fumigatus* with the TR34/L98H mutation have been described (3, 6, 7). Documenting such cases is important, since it may lead to a reappraisal of voriconazole as first-line therapy if the risk of contracting azole resistance increases.

A 63-year-old farmer in Franche-Comté, France, was diagnosed with severe aplastic anemia in 1997 and received an allogeneic hematopoietic stem cell transplant (allo-HSCT) in January 2011. The patient experienced reactivation of chronic graft-versus-host disease (GVHD) at month 4 posttransplantation (M4), which required an increase and maintenance of a continuous dose of corticoids. On 26 April 2012 (M16), he was diagnosed with probable IA according to the European Organization for Research and Treatment of Cancer/Invasive Fungal Infections Cooperative Group and the National Institute of Allergy and Infectious Diseases Mycoses Study Group (EORTC/MSG) criteria. Radiological investigation using high-resolution computed tomography (CT) showed one nodule in the left upper lobe of the lung. A positive *Aspergillus* antigen was detected in serum the same day (using an index of 0.5 as a positive threshold [Platelia *Aspergillus* sandwich enzyme-linked immunosorbent assay; Bio-Rad, Marnes la Coquette, France]). Mycological examination showed a positive culture of *A. fumigatus* from sputum. Because the patient had re-

ceived oral azole antifungal prophylaxis for 16 months (voriconazole from January to April 2011, 200 mg twice daily, and then posaconazole from May 2011, 200 mg three times daily), antifungal therapy was initiated with a combination of liposomal amphotericin B (3 mg/kg of body weight/day) and caspofungin (50 mg/day). Although a second *A. fumigatus* isolate was obtained from sputum 15 days after the first one, clinical improvement was shown. A second episode of IA was diagnosed in July 2013 (nodules on CT and positive galactomannan), but no strain was isolated. The patient died in August 2013 of multivisceral failure due to extensive chronic GVHD.

The two clinical isolates showed the same resistance pattern using the EUCAST method, i.e., resistance to itraconazole (MIC, >8 μ g/ml) and to voriconazole (MIC, 4 μ g/ml). Sequencing the complete CYP51A gene as previously described (8) revealed the presence of the 34-bp tandem repeat and the L98H mutation in both isolates.

Environmental samples were collected from inside and around the patient's home (Fig. 1). Air samples (250 liters or 500 liters) were taken from four rooms (six air samples from each room) and from six points around the house with a MAS 100 impactor. Eighteen samples of soil, leaves, moss, and twigs, three samples of hay, and one sample of straw were collected along with dust from tractor filters. All the samples were cultured on DG18 medium and on malt agar supplemented with 4 mg/liter of itraconazole medium and incubated at 30°C, 37°C, and 48°C.

A total of 145 *A. fumigatus* isolates were obtained (20 isolates from the indoor environment and 125 from the outdoor environ-

Received 12 November 2013 Returned for modification 12 December 2013

Accepted 11 February 2014

Published ahead of print 19 February 2014

Editor: S. A. Moser

Address correspondence to Laurence Millon, laurence.millon@univ-fcomte.fr.

Copyright © 2014, American Society for Microbiology. All Rights Reserved.

doi:10.1128/JCM.03182-13

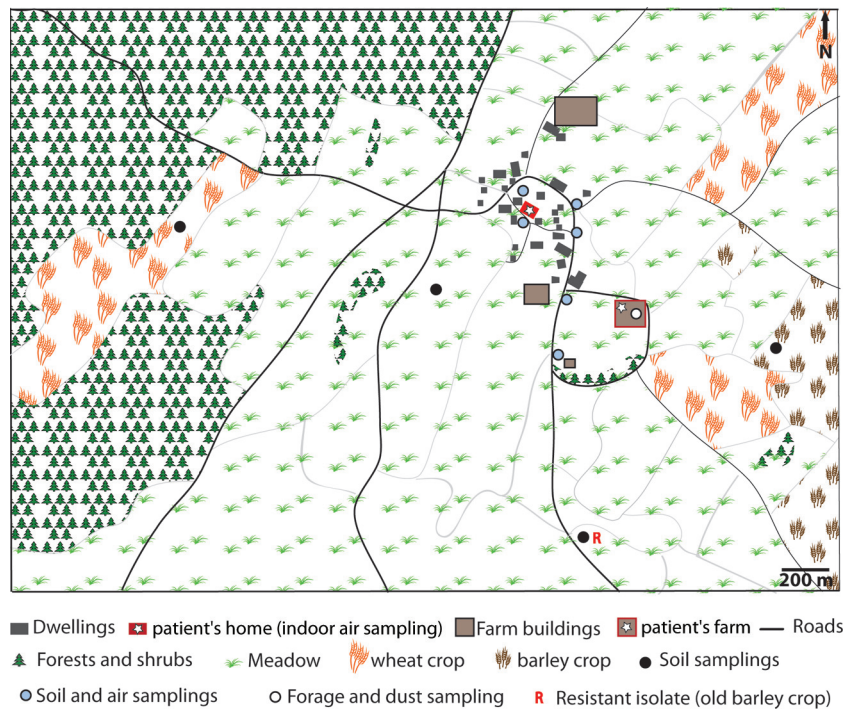


FIG 1 Locations of environmental samples.

ment). Only one isolate grew on itraconazole-malt agar. This isolate was obtained from one field previously sprayed with fungicides and where manure was applied 2 months before sampling. The patient reported use of the fungicides prothioconazole (1.25 liters/ha) and epoxiconazole (2.5 liters/ha), which he had sprayed twice a year in his wheat fields and once a year in his barley fields, as recommended by the manufacturers. The resistance pattern was similar to those of the two clinical isolates from the patient (itraconazole [MIC, >8 $\mu\text{g/ml}$] and voriconazole [MIC, 4 $\mu\text{g/ml}$]). Sequence analysis of the *CYP51A* gene showed the TR34/L98H mutation.

Genotyping was performed using microsatellite analysis as previously described (9). Microsatellite analysis of the two itraconazole-resistant isolates from the patient indicated that they were microvariants, i.e., they had differences of two repeat units at only a single locus out of the four tested (10). The environmental isolate was different for two of the four loci tested and was not genetically related to the clinical isolates. An extensive environmental analysis should be performed to determine whether this environmental azole-resistant isolate is more closely related to the clinical isolates than to other environmental ones, which would then suggest a clonal expansion of the azole-resistant isolates (11).

Only 10 reports have described azole-resistant *A. fumigatus* isolates with the TR34/L98H mutation, and these reports involved 10 IA patients with different underlying diseases: 7 hematology patients (1 with chronic myeloid leukemia, 3 with acute myeloid leukemia, 2 with non-Hodgkin lymphoma, and 1 with an other hematologic malignancy), of whom 5 underwent an allo-HSCT, and 1 patient with lung carcinoma, 1 patient with breast carcinoma, and 1 patient with liver transplantation (3, 6, 7). The French patient described here was an allo-HSCT recipient with chronic GVHD. He was an outpatient in the hematology unit and

spent most of his time in his house, which was located in a very rural area. He reported using azole fungicides to grow cereal crops for many years.

The patient had also received extensive azole therapy (for >1 year), so the question of an acquired resistance mechanism can be raised. To date, only point mutations have developed in azole-resistant isolates through patient therapy. The TR34/L98H resistance mechanism observed in our patient includes a combination of genomic changes (tandem repeat and a point mutation), which is more likely to occur in the environment (2, 3). Therefore, although an acquired resistance mechanism within his lungs cannot be formally ruled out to explain the resistance observed, the most likely explanation is the selection under azole prophylaxis of one *A. fumigatus* TR34/L98H strain among several from the environment.

Given the high genotypic diversity of *A. fumigatus* (9), the probability of recovering the same genotype from the patient and his environment was very low, and we did not succeed in doing so despite collecting 145 isolates. However, our environmental sampling confirmed the presence of the TR34/L98H mutation in agricultural areas where large amounts of triazole fungicides are widely used. The amount of the five molecules involved in TR34/L98H resistance (epoxiconazole, tebuconazole, propiconazole, difeconazole, bromuconazole) in 2012 in the Franche-Comté region was 0.62 kg/km² (Regional Forest and Agriculture Department [DRAAF-BNV-D], personal communication), which is quite similar to that used in the Netherlands (0.86 kg/km²) (12).

TR34/L98H strains were first detected in the Netherlands and then subsequently in numerous European countries and in Asia. The other recently described fungicide-driven route of the resistance mechanism TR46 Y121F/T289A, also found in hematology patients with IA, can easily spread further (13). Since more and

more immunocompromised patients are outpatients and given the growing use of the five molecules involved in such mutations, we can expect a higher risk of inhaling azole-resistant isolates and an increase in IA with azole-resistant isolates. Therefore, liposomal amphotericin B should be regarded as an alternative to voriconazole (14).

Our study shows that even in a low prevalence area (0.7% [1/145]) an immunosuppressed patient is likely to be infected with an environmental azole-resistant strain. If the number of similar observations increases in the future, the challenge will be to reconsider voriconazole as first-line therapy, especially in patients living in agricultural areas, since reducing the use of key triazole fungicides in agriculture seems unlikely.

ACKNOWLEDGMENT

We thank Pamela Albert for her editorial assistance.

REFERENCES

- Denning DW, Bowyer P. 2013. Voriconazole resistance in *Aspergillus fumigatus*: should we be concerned? *Clin. Infect. Dis.* 57:521–523. <http://dx.doi.org/10.1093/cid/cit321>.
- Howard SJ, Cerar D, Anderson MJ, Albarrag A, Fisher MC, Pasqualotto AC, Laverdiere M, Arendrup MC, Perlin DS, Denning DW. 2009. Frequency and evolution of azole resistance in *Aspergillus fumigatus* associated with treatment failure. *Emerg. Infect. Dis.* 15:1068–1076. <http://dx.doi.org/10.3201/eid1507.090043>.
- Van der Linden J, Snelders E, Kampinga GA, Rijnders BJ, Mattsson E, Debets-Ossenkopp YJ, Kuijper J, Van Tiel FH, Melchers WJ, Verweij PE. 2011. Clinical implications of azole resistance in *Aspergillus fumigatus*, the Netherlands, 2007–2009. *Emerg. Infect. Dis.* 17:1846–1854. <http://dx.doi.org/10.3201/eid1710.110226>.
- Snelders E, Camps SMT, Karawajczyk A, Schaftenaar G, Kema GHJ, van der Lee HA, Klaassen CH, Melchers WJG, Verweij PE. 2012. Triazole fungicides can induce cross-resistance to medical triazoles in *Aspergillus fumigatus*. *PLoS One* 7:e31801. <http://dx.doi.org/10.1371/journal.pone.0031801>.
- Seyedmousavi S, Hashemi SJ, Zibafar E, Zoll J, Hedayati MT, Mouton JW, Melchers WJ, Verweij PE. 2013. Azole-resistant *Aspergillus fumigatus*, Iran. *Emerg. Infect. Dis.* 19:832–834. <http://dx.doi.org/10.3201/eid1905.130075>.
- Hamprecht A, Buchheidt D, Vehreschild JJ, Cornely OA, Spiess B, Plum G, Halbsguth TV, Kutsch N, Stippel D, Kahl P, Persigehl T, Steinbach A, Bos B, Hallek M, Vehreschild MJ. 2012. Azole-resistant invasive aspergillosis in a patient with acute myeloid leukaemia in Germany. *Euro Surveill.* 17:20262. <http://www.eurosurveillance.org/ViewArticle.aspx?ArticleId=20262>.
- Mellado E, De La Camara R, Buendia B, Rodriguez-Tudela JL, Cuenca-Estrella M. 2013. Breakthrough pulmonary *Aspergillus fumigatus* infection with multiple triazole resistance in a Spanish patient with chronic myeloid leukemia. *Rev. Iberoam Micol.* 30:64–68. <http://dx.doi.org/10.1016/j.riam.2012.09.002>.
- Alanio A, Sitterle E, Liance M, Farrugia C, Foulet F, Botterel F, Hicheri Y, Cordonnier C, Costa JM, Bretagne S. 2011. Low prevalence of resistance to azoles in *Aspergillus fumigatus* in a French cohort of patients treated for haematological malignancies. *J. Antimicrob. Chemother.* 66:371–374. <http://dx.doi.org/10.1093/jac/dkq450>.
- Bart-Delabesse E, Sarfati J, Debeaupuis J-P, van Leeuwen W, van Belkum A, Bretagne S, Latge J-P. 2001. Comparison of restriction fragment length polymorphism, microsatellite length polymorphism, and random amplification of polymorphic DNA analyses for fingerprinting *Aspergillus fumigatus* isolates. *J. Clin. Microbiol.* 39:2683–2686. <http://dx.doi.org/10.1128/JCM.39.7.2683-2686.2001>.
- Balajee SA, de Valk HA, Lasker BA, Meis JF, Klaassen CH. 2008. Utility of a microsatellite assay for identifying clonally related outbreak isolates of *Aspergillus fumigatus*. *J. Microbiol. Methods* 73:252–256. <http://dx.doi.org/10.1016/j.mimet.2008.02.011>.
- Snelders E, van der Lee HAL, Kuijpers J, Rijs AJMM, Varga J, Samson RA, Mellado E, Donders ART, Melchers WJG, Verweij PE. 2008. Emergence of azole resistance in *Aspergillus fumigatus* and spread of a single resistance mechanism. *PLoS Med.* 5:e219. <http://dx.doi.org/10.1371/journal.pmed.0050219>.
- European Centre for Disease Prevention and Control. February 2013. Risk assessment on the impact of environmental usage of triazoles on the development and spread of resistance to medical triazoles in *Aspergillus* species. <http://www.ecdc.europa.eu/en/publications/publications/risk-assessment-impact-environmental-usage-of-triazoles-on-aspergillus-spp-resistance-to-medical-triazoles.pdf>.
- van der Linden JW, Camps SM, Kampinga GA, Arends JP, Debets-Ossenkopp YJ, Haas PJ, Rijnders BJ, Kuijper EJ, van Tiel FH, Varga J, Karawajczyk A, Zoll J, Melchers WJ, Verweij PE. 2013. Aspergillosis due to voriconazole highly resistant *Aspergillus fumigatus* and recovery of genetically related resistant isolates from domiciles. *Clin. Infect. Dis.* 57:513–520. <http://dx.doi.org/10.1093/cid/cit320>.
- Walsh TJ, Anaissie EJ, Denning DW, Herbrecht R, Kontoyiannis DP, Marr KA, Morrison VA, Segal BH, Steinbach WJ, Stevens DA, van Burik J-A, Wingard JR, Patterson TF. 2008. Treatment of aspergillosis: clinical practice guidelines of the Infectious Diseases Society of America. *Clin. Infect. Dis.* 46:327–360. <http://dx.doi.org/10.1086/525258>.