



HAL
open science

Toward scar-free surgery: an analysis of the increasing complexity from laparoscopic surgery to NOTES

Amine Chellali, Steven D. Schwartzberg, Daniel B. Jones, John Romanelli, Amie Miller, David Rattner, Kurt E. Roberts, Caroline G. L. Cao

► **To cite this version:**

Amine Chellali, Steven D. Schwartzberg, Daniel B. Jones, John Romanelli, Amie Miller, et al.. Toward scar-free surgery: an analysis of the increasing complexity from laparoscopic surgery to NOTES. *Surgical Endoscopy*, 2014, 28 (11), pp.3119-3133. 10.1007/s00464-014-3565-z . hal-00983294

HAL Id: hal-00983294

<https://hal.science/hal-00983294v1>

Submitted on 10 Jun 2014

HAL is a multi-disciplinary open access archive for the deposit and dissemination of scientific research documents, whether they are published or not. The documents may come from teaching and research institutions in France or abroad, or from public or private research centers.

L'archive ouverte pluridisciplinaire **HAL**, est destinée au dépôt et à la diffusion de documents scientifiques de niveau recherche, publiés ou non, émanant des établissements d'enseignement et de recherche français ou étrangers, des laboratoires publics ou privés.

Toward scar-free surgery: an analysis of the increasing complexity from laparoscopic surgery to NOTES

Amine Chellali^{1,2} PhD, Steven D. Schwaitzberg¹ MD, Daniel B. Jones³ MD, John Romanelli⁴ MD, Amie Miller⁵ MD, David Rattner⁶ MD, Kurt E. Roberts⁷ MD, Caroline G.L. Cao⁸ PhD

¹Department of Surgery, Cambridge Health Alliance, Harvard Medical School, Cambridge, MA, USA

²Department of Computer Engineering, University of Evry, Evry, France

³Department of Surgery, Beth Israel Deaconess Medical Center, Harvard Medical School, Boston, MA, USA

⁴Department of Surgery, Baystate Medical Center, Tufts University School of Medicine, Springfield, MA, USA

⁵Department of Surgery, Wright State University, Dayton, OH, USA

⁶Department of Surgery, Massachusetts General Hospital, Boston, MA, USA

⁷Department of Surgery, Yale University School of Medicine, New Haven, CT, USA

⁸Department of Biomedical, Industrial and Human Factors Engineering, Wright State University, Dayton, OH, USA

Corresponding Author:

Caroline Cao

Wright State University

207 Russ Engineering Center

3640 Colonel Glenn Hwy

Dayton, OH 45435

Email: caroline.cao@wright.edu

Phone: (937) 775-5044

Fax: (937) 775-7364

Funding information: This work was supported by NIBIB/NIH Grant #R01EB009362.

Running head: A. Chellali et al.: Towards scar-free surgery.

ABSTRACT

Background: NOTES is an emerging technique for performing surgical procedures, such as cholecystectomy. Debate about its real benefit over the traditional laparoscopic technique is on-going. There have been several clinical studies comparing NOTES to conventional laparoscopic surgery. However, no work has been done to compare these techniques from a Human Factors perspective. This study presents a systematic analysis describing and comparing different existing NOTES methods to laparoscopic cholecystectomy.

Methods: Videos of endoscopic/laparoscopic views from fifteen live cholecystectomies were analyzed to conduct a detailed task analysis of the NOTES technique. A hierarchical task analysis of laparoscopic cholecystectomy and several hybrid transvaginal NOTES cholecystectomies was performed and validated by expert surgeons. To identify similarities and differences between these techniques, their hierarchical decomposition trees were compared. Finally, a timeline analysis was conducted to compare the steps and substeps.

Results: At least three variations of the NOTES technique were used for cholecystectomy. Differences between the observed techniques at the substep level of hierarchy and on the instruments being used were found. The timeline analysis showed an increase in time to perform some surgical steps and substeps in NOTES compared to laparoscopic cholecystectomy.

Conclusion: As pure NOTES is extremely difficult given the current state of development in instrumentation design, most surgeons utilize different hybrid methods – combination of endoscopic and laparoscopic instruments/optics. Results of our hierarchical task analysis yielded an identification of three different hybrid methods to perform cholecystectomy with significant variability amongst them. The varying degrees to which laparoscopic instruments are utilized to assist in NOTES methods appear to introduce different technical issues and additional tasks leading to an increase in the surgical time. The NOTES continuum of invasiveness is proposed here as a classification scheme for these methods, which was used to construct a clear roadmap for training and technology development.

Keywords: NOTES continuum, laparoscopic surgery, cholecystectomy, hierarchical task analysis, timeline analysis, Cognitive task analysis

INTRODUCTION

NOTES (Natural orifice transluminal endoscopic surgery) is an emerging technique of minimally invasive surgery that promises to leave the patient without visible scars. The surgical site in the abdominal cavity is accessed through natural orifices, such as the mouth, the vagina, or the anus [1, 2]. This technique may offer several benefits to the patients, such as less pain as there are no incisions in the abdominal wall, faster postoperative recovery, shorter hospitalization time, no complications related to the abdominal incisions and a decreased inflammatory response after surgery [3, 4, 5]. However, it is not widely adopted by surgeons, and several questions regarding its real benefit over the traditional minimally invasive surgical techniques exist [6]. Currently, this technique is not easy to perform [7]. It is more demanding for the surgeons compared to conventional techniques, as it is more difficult to control the pressure during insufflation, and more difficult to use the unfamiliar new tools [8, 9].

NOTES has been used for a number of surgical interventions such as cholecystectomy [2, 3, 4, 10], appendectomy [11], and hernia repair [12]. Surgical practice is a constantly evolving set of techniques, and NOTES is one of them. In fact, there are currently several approaches and methods to perform a NOTES procedure, with significant variability among them. These differences include the access route (e.g., transvaginal versus transgastric), the visualization tools (e.g., rigid endoscopes versus flexible endoscopes), the surgical instruments (e.g., endoscopic instruments versus laparoscopic instruments), and the number of access points (e.g., two or more in hybrid NOTES versus one in pure NOTES). Auyang et al. [1] conducted a survey of existing NOTES approaches based on the current literature. Their analysis showed that NOTES was most commonly performed using a hybrid (90 % of cases), transvaginal approach (82 % of cases). Pure NOTES represented only 10 % of cases and the transgastric route was used only in 13% of cases. Of the cases identified by Auyang et al. [1], the most commonly performed procedure was cholecystectomy (84 % of cases), compared to appendectomy (6 % of cases).

Since the late 1980s, laparoscopic cholecystectomy has become the standard of care for symptomatic gallbladder disease including symptomatic cholelithiasis, acute cholecystitis, chronic cholecystitis, biliary dyskinesia, and gallstone pancreatitis [13]. The removal of the gallbladder during a typical laparoscopic cholecystectomy procedure consists of the following steps [13, 14]: first, the gallbladder is located visually using the laparoscope and retracted in a cephalad manner using a grasper. The tissue surrounding the cystic duct, and the cystic artery

is dissected using laparoscopic tools in order to isolate the cystic duct and cystic artery and obtain the critical view of safety [15]. Once the cystic artery and duct are isolated, they are clipped using a clip applier and divided between the clips using laparoscopic scissors. The gallbladder is then dissected from the liver bed using a laparoscopic electro-surgical tool and removed within a retrieval bag through one of the incisions.

To demonstrate the advantage of transvaginal NOTES cholecystectomy, it is necessary to compare it to the current gold standard – laparoscopic cholecystectomy. This paper presents a systematic analysis describing and comparing different existing NOTES methods to the traditional laparoscopic cholecystectomy.

Laparoscopic cholecystectomy versus transvaginal NOTES cholecystectomy

In 2005, the Society of American Gastrointestinal and Endoscopic Surgeons (SAGES) and the American Society for Gastrointestinal Endoscopy (ASGE) formed the Natural Orifice Surgery Consortium for Assessment and Research (NOSCAR) to oversee and guide research in this field. The Consortium launched the NOSCAR trial aiming to compare NOTES cholecystectomy (both transgastric and transvaginal) to the laparoscopic standard [9]. The trial was expected to be completed at the end of 2013 [16]. A similar foundation called EURO-NOTES has also been established in Europe to support the research efforts for NOTES [17]. However, to date, only a few published studies have compared the conventional laparoscopic surgery to NOTES cholecystectomy, all with a focus on the clinical outcomes of each technique [2, 8, 10, 18, 19, 6, 20, 21]. A review of these studies shows that there is currently neither an agreement regarding the feasibility and safety of NOTES in direct comparison to conventional laparoscopic surgery nor a common metric to compare the two techniques.

No systematic analysis has been conducted to describe the differences between the existing NOTES methods, and the differences between these methods and the conventional laparoscopic technique. Tessier et al. [22] compared transvaginal NOTES cholecystectomy to laparoscopic cholecystectomy from an ergonomic perspective. Their study revealed an increased complexity and inappropriateness of the tools in the NOTES technique compared with laparoscopic surgery. However, their findings were based on a case study, which limits their generalizability to other NOTES methods. An extensive analysis using a larger sample of cases is needed to capture the variants currently seen in the NOTES technique.

Task analysis methods

A human-centered analysis of complex behaviors and systems using methods from Human Factors engineering, such as hierarchical task analysis, functional analysis, cognitive task analysis, and timeline analysis can identify ergonomic and technological limitations of a complex system. Hierarchical task analysis (HTA) is a method based on the observation of the user–task–system–environment interaction in the context of actual operations [23]. It looks at the tasks performed by human operators in terms of the actions in a chronological sequence [24]. HTA has been used in previous studies for analyzing minimally invasive surgery, in order to understand the complexity of procedures, with an aim to improve training [24, 25, 26, 27]. The HTA method was used in this study to describe, classify, and compare the different existing transvaginal NOTES methods and the conventional laparoscopic technique.

METHODS AND MATERIALS

Task decomposition for cholecystectomy techniques

The task decomposition method is similar to the one used for laparoscopic cholecystectomy [27]. It is based on video analysis of actual procedures as described in [28]. From the observation of surgical events on videos, the method consists of decomposing the procedure into steps, substeps, tasks, and subtasks. The steps together achieve the big, overarching goal of the procedure. Substeps must be completed along the way in order to complete the step. Sometimes steps overlap and sometimes substeps overlap. Steps and substeps only occur once. Tasks are actions that are combined to accomplish the goal of the substep. Tasks are comprised of subtasks, more defined actions. Subtasks might occur numerous times during one task. The steps, substeps, tasks, and subtasks are hierarchical in nature. Their order and structure can be represented by tree diagrams. Hence, hierarchical decomposition trees that describe the cholecystectomy procedure at these different levels of details were generated using *FreeMind*, an Open source event mapping application.

A total of 921 min of videos from fifteen cholecystectomy cases (11 NOTES and 4 laparoscopic) were used to generate the hierarchical decomposition trees. For consistency, the videos were analyzed by the same individual following a set of operationally defined beginnings and endings of events. The video analysis was done in two phases.

Phase1: Laparoscopic cholecystectomy task decomposition

In order to easily compare the NOTES technique to the laparoscopic cholecystectomy technique, videos of the laparoscopic view from four live laparoscopic cholecystectomy cases

(n = 4) were collected and analyzed. This analysis aimed to update the laparoscopic cholecystectomy decomposition tree previously presented [27] and to describe the surgical tools currently used for each task.

Phase2: Transvaginal NOTES task decomposition

To conduct the HTA for transvaginal NOTES cholecystectomy, videos of the endoscopic view from live NOTES operations (n = 11) from three different surgeons (nine videos with internal views only and 2 videos including both internal and external views (Figure 1), were collected. The video analysis method was similar to the one described above.

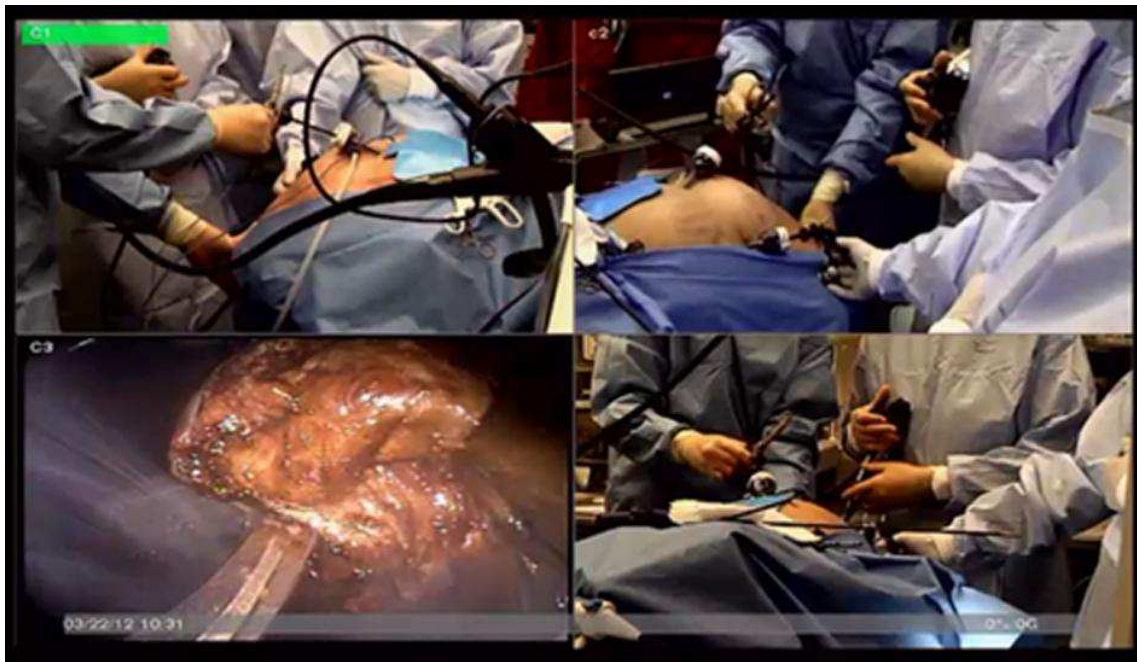

Figure 1: Screen capture of a video showing both endoscopic view (lower left corner) and three external views of a NOTES procedure

The video analysis, supplemented by the literature review, resulted in a hierarchical decomposition of the transvaginal NOTES cholecystectomy procedure with increasing level of details, from surgical steps, substeps, tasks to subtasks.

The hierarchical decomposition was then used to classify the different cholecystectomy techniques and to identify similarities and differences between them. The analysis was also used to describe the different surgical instruments used for each task.

Timeline analysis

The timeline analysis was performed to investigate whether the surgical time for each step and substep depends on the technique and/or method being used. For that purpose, the beginnings and endings of the surgical steps (see Table 1) and substeps (see Table 4 and Table 5) were defined from observable surgical events on the videos. This allowed a

systematic breakdown of the complex surgical procedures for a clear definition of the actions used, allowing easier comparison of the different existing techniques.

The average durations of the procedures, the steps and substeps were determined and compared across all the cholecystectomy techniques classified in the previous phase.

It is to be noted that given the small sample size of the collected videos, no statistical tests were conducted on the timeline analysis. Only a descriptive analysis (with the mean values and the standard deviations) is reported.

Table 1: Definition of beginnings and endings of surgical steps for cholecystectomy

| Observed surgical step | Beginning | Ending |
|-------------------------------|---|---|
| 1. Prepare patient | Moment the laparoscope enters the abdomen | Moment the first surgical instrument contacts the abdomen |
| 2. Isolate gallbladder | Moment the first surgical instrument contacts the abdomen | Moment the clip applicator contacts the abdomen |
| 3. Remove gallbladder | Moment the clip applicator contacts the abdomen | Moment gallbladder is removed from the abdomen |

Cognitive task analysis

A cognitive task analysis (CTA) was conducted for transvaginal NOTES cholecystectomy to obtain insight into the decision process that experts use to perform surgery [29]. Five surgeons with different expertise levels (1 surgical resident, 4 surgeons with more than five years of expertise in both laparoscopic cholecystectomy and transvaginal NOTES cholecystectomy) participated separately in the CTA sessions. During these sessions, a semi-structured interview was conducted to obtain a deep understanding of the issues specific to the NOTES technique. The participants were asked to review, modify and validate the tasks sequences using the generated hierarchical decomposition trees. After that, they were asked to highlight the issues they encounter when performing the procedures and the decisions they make to resolve them. The focus in this phase was on a set of tasks that illustrate variability between the different techniques (identified during the task decomposition phase). The objective was to collect information about the current issues facing the NOTES technique as compared to laparoscopic surgery, the required skills to deal with these issues, and the training methods.

RESULTS

Task decomposition trees

Laparoscopic cholecystectomy

Figure 2 shows the updated version of the laparoscopic cholecystectomy decomposition tree presented in [27].

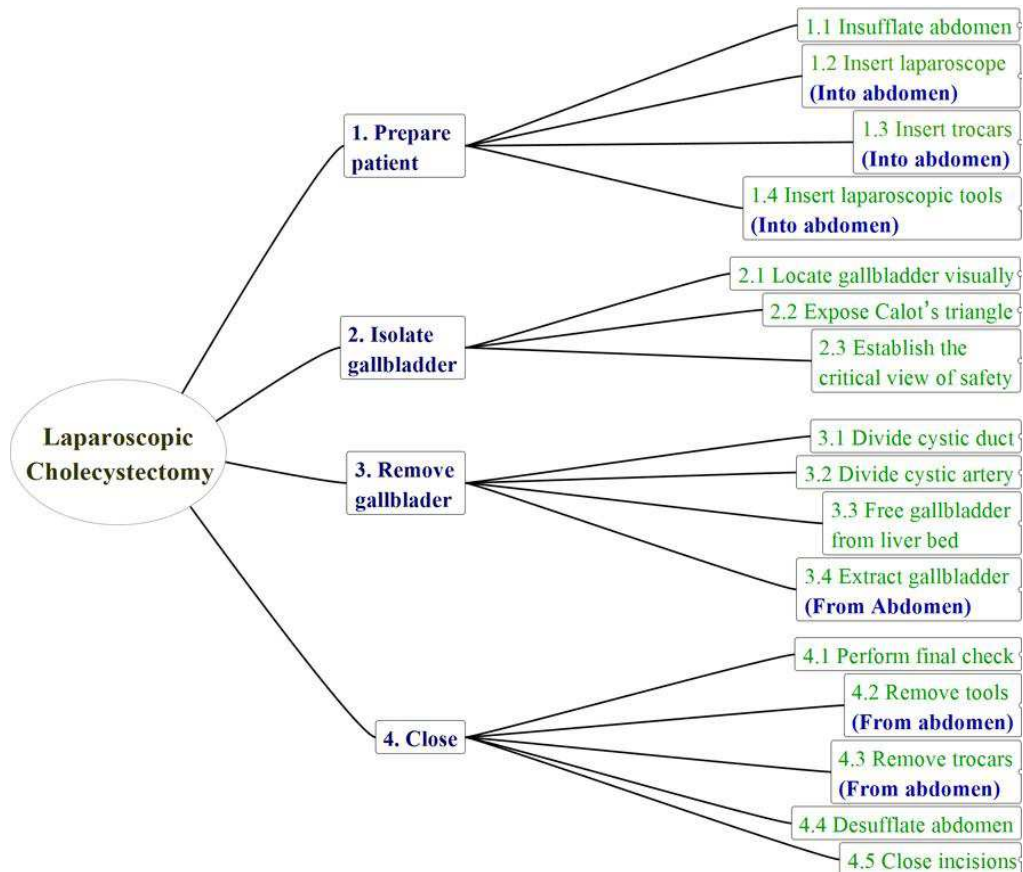


Figure 2: The updated Hierarchical task decomposition tree at the steps and substeps levels for the 4-ports laparoscopic cholecystectomy [27]

NOTES cholecystectomy

As the NOTES videos were provided by different surgeons, they were regrouped into three groups depending on their source. After that, three different HTA task trees were generated. Figure 3 shows a sample of procedural decomposition of the surgical procedure. The aim here is to illustrate the complexity of the task analysis when including all four levels of decomposition (steps, substeps, tasks and subtasks).

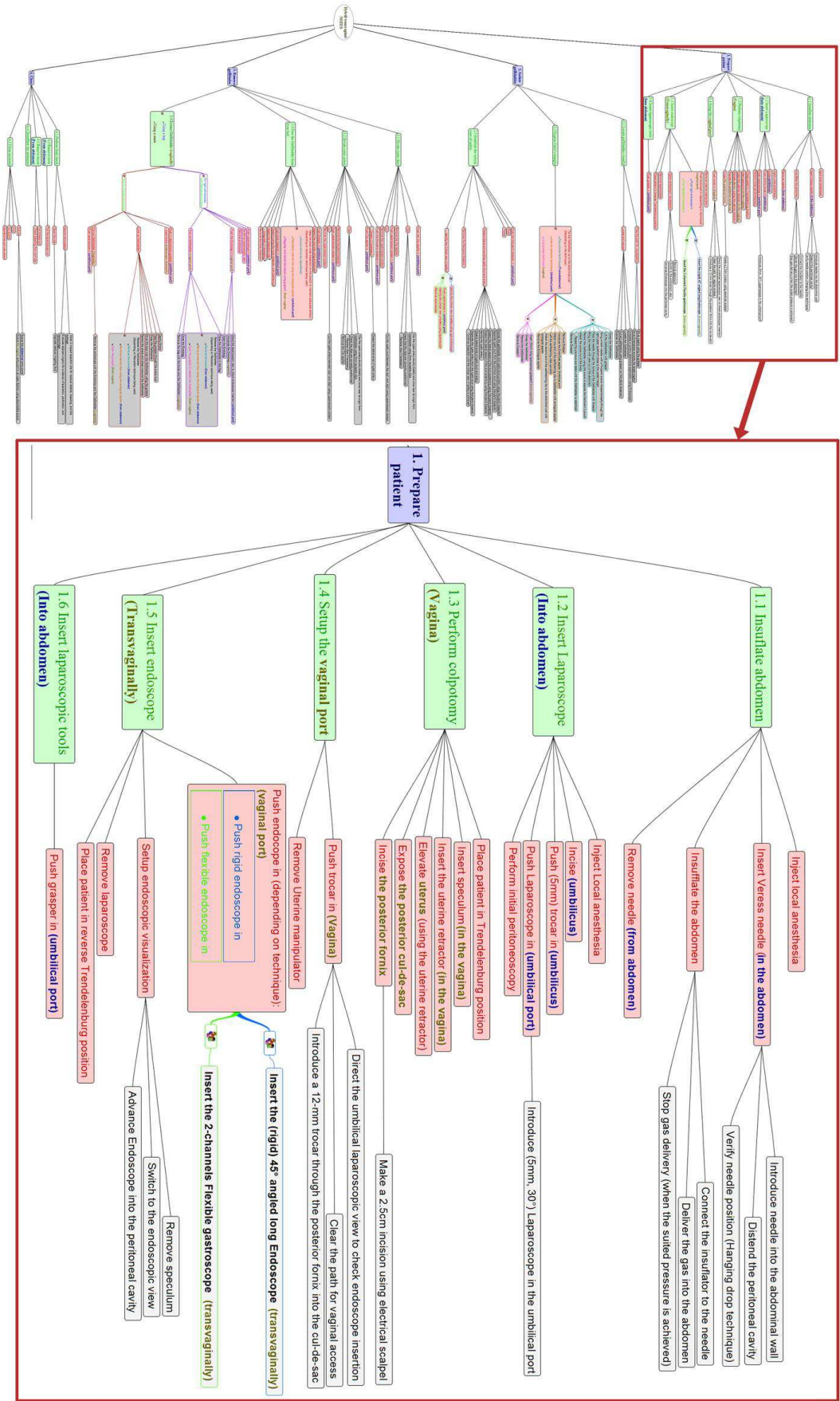


Figure 3: Sample of procedural decomposition of the surgical procedure with a focus on the first step (prepare the patient) divided into substeps (level 2), tasks (level 3) and subtasks (level 4)

A generic/typical task tree was then created by merging the three task trees. Several significant variations were noted at each level of decomposition between the different cases, requiring two distinct task trees. The main goal oriented levels of steps and substeps are layered for each tree on Figure 4 and Figure 5.

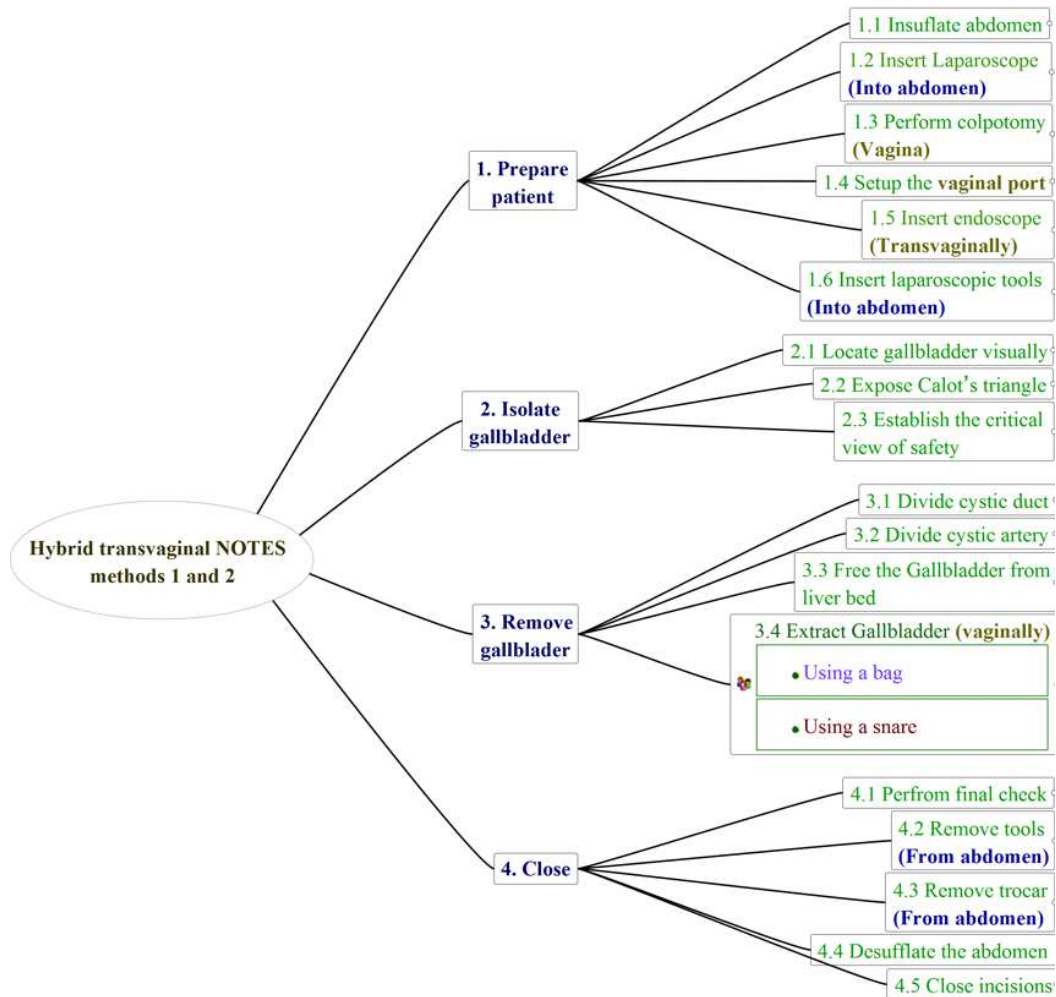


Figure 4: Hierarchical decomposition tree at the steps and substeps levels for NOTES methods 1 and 2

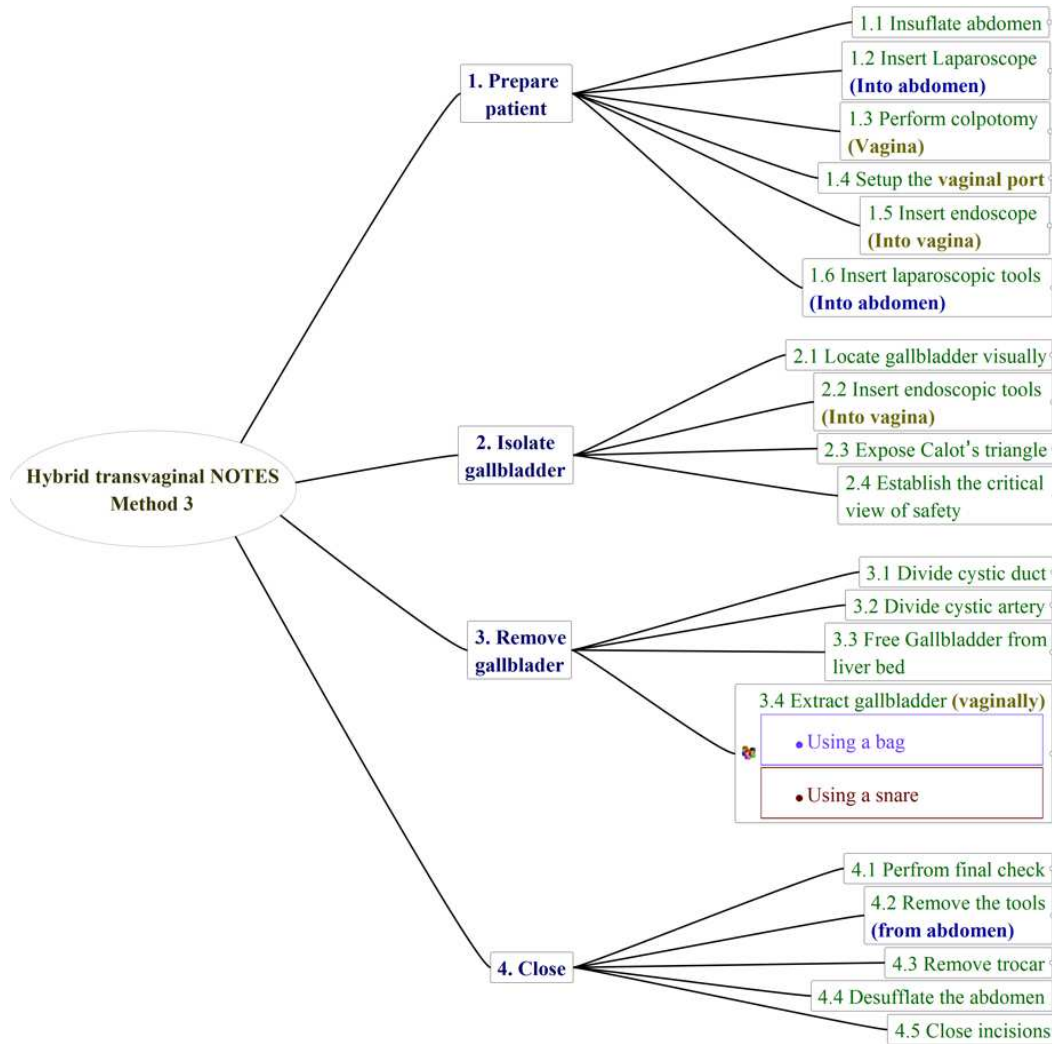


Figure 5: Hierarchical decomposition tree at the steps and substeps levels for NOTES method 3

Techniques classification and methods variations

The analysis of the decomposition trees shows that the laparoscopic cholecystectomy cases consisted of using four abdominal ports to insert a laparoscope (at the umbilicus) and a set of laparoscopic instruments (through the three remaining ports).

Furthermore, it appeared that none of the NOTES observed cases used the pure NOTES technique. Rather, they were all based on a hybrid technique [30], consisting of the use of one transvaginal port (to insert an endoscope and endoscopic instruments) and at least one abdominal port at the umbilicus (to insert a laparoscope and laparoscopic instruments) as shown on Figure 6.

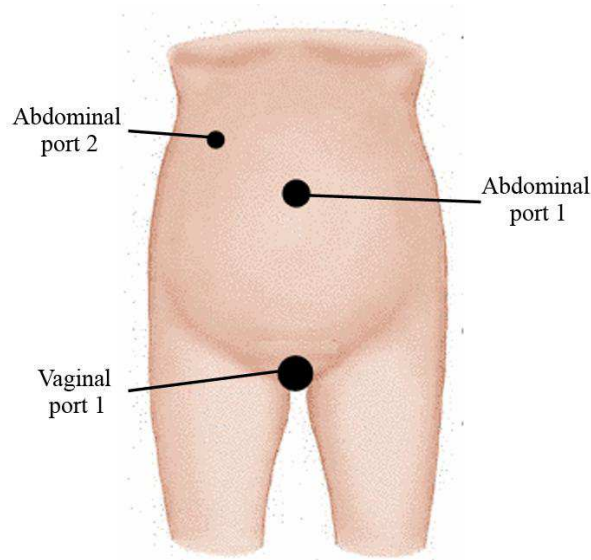


Figure 6: The entry ports for the hybrid NOTES methods

In addition, three different methods were identified within the hybrid NOTES technique:

1. **Hybrid NOTES method 1:** consisted of using a rigid endoscope and a set of laparoscopic instruments (four cases).
2. **Hybrid NOTES method 2:** consisted of using a flexible endoscope and a set of laparoscopic instruments (three cases).
3. **Hybrid NOTES method 3:** consisted of using a flexible endoscope and a combination of laparoscopic and endoscopic instruments (four cases).

Other variations were also observed either within or between the different methods.

At the steps level

The comparison between the task trees shows no variations at the steps level. Indeed, both the hybrid transvaginal NOTES technique (all methods) and the laparoscopic technique required the same three surgical steps (Figure 2, Figure 4 and Figure 5):

1. Step 1: prepare the patient.
2. Step 2: isolate the gallbladder.
3. Step 3: remove the gallbladder.

Step 4 (close the patient) is not included here as it was not observable on the collected videos.

At the substeps level

The comparison of the task trees shows that different variations between techniques/methods emerged at the substeps level and subsequently at the lower levels:

Step 1: Prepare the patient

The comparison of the task trees (Figure 2, Figure 4 and Figure 5) shows that all NOTES methods required three additional substeps compared to the conventional laparoscopic technique:

- Substep 1.3 (Figure 4 and Figure 5): perform a colpotomy.
- Substep 1.4 (Figure 4 and Figure 5): setup the vaginal port.
- Substep 1.5 (Figure 4 and Figure 5): insert the endoscope transvaginally.

While some variations described in the literature show differences on how to perform the surgical tasks resulting from these substeps, the only variation observed among the analyzed NOTES methods was the type of endoscope being introduced (rigid or flexible).

On the other hand, the conventional laparoscopic cholecystectomy required one additional substep compared to NOTES methods:

- Substep 1.3 (Figure 2): insert three additional trocars in the abdomen before the insertion of laparoscopic instruments (the umbilical port being mainly used to insert the laparoscope in this technique).

No other variations were observed between techniques at this level.

Step 2: Isolate the gallbladder

Different variations at the substeps level were identified in this step:

- Substep 2.1 (Figure 2, Figure 4 and Figure 5): locate the gallbladder visually. The only difference between the techniques was the visualization tool being used which led to different navigation tasks.
- Substep 2.2 (Figure 5): insert the endoscopic instruments. It emerged as a new substep and was observed only in the NOTES method 3.
- Substep 2.2 (Figure 2 and Figure 4)/ Substep 2.3 (Figure 5): expose the Calot's triangle. This substep shows an important variation between techniques/methods regarding the retraction technique being used. In standard laparoscopic cholecystectomy, there are two dedicated abdominal ports for retraction of the gallbladder. On the other hand, less invasive retraction techniques that aimed to reduce the number of abdominal ports were used within the observed NOTES methods.
- Substep 2.3 (Figure 2 and Figure 4)/Substep 2.4 (Figure 5): establish a critical view of safety. The use of different dissection instruments led to two variations in the way to perform this substep among the different techniques:

- Dissection using laparoscopic instruments (observed in the laparoscopic technique and NOTES methods 1 and 2).
- Dissection using endoscopic instruments (observed in NOTES method 3).

Step3: Remove the gallbladder

Different variations at the substeps level were identified in this step:

- Substep 3.1 (Figure 2, Figure 4 and Figure 5): divide the cystic duct (or artery). The same variation was observed among all NOTES methods and the laparoscopic technique with the use of laparoscopic instruments transabdominally. However, the abdominal entry port was different between the laparoscopic technique (secondary abdominal port) and the NOTES methods (umbilical port).
- Substep 3.2 (Figure 2, Figure 4 and Figure 5): divide the cystic artery (or duct). This substep is very similar to the previous one and the same variations were observed.
- Substep 3.3 (Figure 2, Figure 4 and Figure 5): free the gallbladder from the liver bed. Among the three NOTES methods, two variations in the instruments being used for dissection were observed: using laparoscopic instruments (inserted through the umbilicus) and using endoscopic instruments (inserted transvaginally). The laparoscopic technique required the use of laparoscopic instruments for dissection (inserted through a secondary abdominal port).
- Substep 3.4 (Figure 2, Figure 4 and Figure 5): extract the gallbladder. Different variations were observed for this substep. In the laparoscopic technique, the gallbladder was removed through the umbilical port within a retrieval bag. On the other hand, this was done transvaginally for the NOTES technique with two variations observed:
 - The use of retrieval bags (observed in all methods),
 - The use of endoscopic snares (observed only in methods 2 and 3 since it required the use of flexible endoscopes).

In summary, the variations described above can be categorized depending on:

1. The visualization tool being used: laparoscope (laparoscopic technique), rigid endoscope (NOTES method 1), flexible endoscope (NOTES methods 2 and 3).
2. The insertion route for surgical instruments: abdomen (laparoscopic technique, NOTES method 1), abdomen and vagina (NOTES methods 2 and 3).
3. The gallbladder retraction technique: laparoscopic grasper from abdomen (laparoscopic technique), “Stay sutures” placed through abdominal wall onto the

gallbladder (NOTES methods 1), internal retractors from abdomen, or laparoscopic grasper from vagina or from abdomen (NOTES methods 2 and 3).

4. The gallbladder extraction tool and route: Retrieval bag from abdomen (laparoscopic technique), retrieval bag from vagina (NOTES methods 1, 2 and 3), or endoscopic snare (NOTES methods 2 and 3).

Table 2: The entry ports and the tools useable in each of the NOTES methods

| Main tasks | Tools | Port # (c.f. fig. 6) | Can be used in: | Was observed in: | Additional observations |
|------------------|---------------------------------|-------------------------|-----------------|-------------------------|--|
| Visualize | Flexible endo. | Vaginal 1 | Methods 2-3 | Methods 2-3 (all cases) | The type of endoscope determines the NOTES method being used |
| | Rigid endo. | Vaginal 1 | Method 1 | Method 1 (all cases) | |
| | Rigid lap. | Abdom. 1 | All methods | All methods (all cases) | Necessary for safety issues |
| Retract | Stay sutures | None | All methods | Methods 1 (all cases) | The task requires combination of two retraction tools at the same time, Tools inserted vaginally cannot be used in method 1, Lap. grasper requires a secondary port in methods 1 and 2 because port 1 is used for other tools |
| | Long lap. grasper | Vaginal 1 | Methods 2-3 | Method 2 (all cases) | |
| | Endo. grasper | Vaginal 1 | Methods 2-3 | Method 2 (2 cases) | |
| | Internal retractor | Abdom. 1 | All methods | Methods 2-3 (all cases) | |
| | Lap. grasper | Abdom. 1 | Methods 3 | Method 3 (all cases) | |
| | Lap. grasper | Abdom. 2 | All methods | Method 2 (1 case) | |
| Dissect | Endo. dissector | Vaginal 1 | Methods 2-3 | Method 3 (all cases) | Endoscopic tools can only be used with flexible endoscopes |
| | Endo. hook electrosurgical tool | Vaginal 1 | Methods 2-3 | Method 3 (all cases) | |
| | Lap. hook electrosurgical tool | Abdom. 1 | All methods | All methods (all cases) | |
| | Lap. dissector | Abdom. 1 | All methods | All methods (all cases) | |
| Clip | Endo. clip applier | Vaginal 1 | Methods 2-3 | Not observed | Patient safety issues |
| | Lap. clip applier | Abdom. 1 | All methods | All methods (all cases) | Only safe alternative |
| Cut | Endo. scissors | Vaginal 1 | Methods 2-3 | Not observed | Patient safety issues |
| | Lap. scissors | Abdom. 1 | All methods | All methods (all cases) | Only safe alternative |
| Extract | Retrieval bag | Vaginal 1 | All methods | All methods (8 cases) | Endo. snare can only be used with flexible endoscopes |
| | Endo. snare | vaginal 1 | Methods 2-3 | Method 2 (1 case) | |

This categorization was used to describe the different tools used in each method. Table 2 summarizes the tools and entry ports that can be used in each method and the methods in which they were observed (the characteristics of the tools are described in the following section).

Tools inventory

In order to understand the variation between the different techniques, an analysis of the tools being used to perform the main surgical tasks was performed. The different tools that were used for each method and their descriptions are summarized on Table 3.

Table 3: Description of tools used during all surgical methods

| Main surgical tasks | Laparoscopic technique | NOTES method 1 | NOTES method 2 | NOTES method 3 |
|----------------------------|---|---|---|--|
| | Tools/instruments | | | |
| Visualization | Laparoscope (0°/30°) 5-10mm | Laparoscope (0° or 30°) 5mm, Rigid long angled endoscope (45°) | Laparoscope (0°/30°) 5mm, Flexible gastroscope (with one or two working channels) | Laparoscope (0°/30°) 5mm, Flexible gastroscope (with one or two working channels) |
| Retraction | Laparoscopic graspers, | Transabdominal stay sutures | Long laparoscopic graspers (introduced transvaginally), Internal retractors | Laparoscopic graspers (both mini and micro tools), Endoscopic grasper, Internal retractors |
| Dissection | Laparoscopic curved dissector, Laparoscopic electro-surgical tool | Laparoscopic curved dissector, Laparoscopic electro-surgical tool | Laparoscopic curved dissector, Laparoscopic electro-surgical tool | Endoscopic electro-surgical tool |
| Clipping | Laparoscopic clip applier | Laparoscopic clip applier | Laparoscopic clip applier | Laparoscopic clip applier |
| Cutting | Laparoscopic scissors | Laparoscopic scissors | Laparoscopic scissors | Laparoscopic scissors |
| Gallbladder Removal | Retrieval bag (transabdominally) | Retrieval bag (transvaginally) | Retrieval bag (transvaginally), Endoscopic snare | Retrieval bag (transvaginally), Endoscopic snare |

Visualization tools

All of the surgeons used conventional laparoscopes (inserted through the umbilicus) for visualization both in the conventional laparoscopic technique and the hybrid NOTES technique, with a difference in the size of the laparoscope. However, the surgeons in the conventional laparoscopic technique used the laparoscope as the main visualization instrument, while the surgeons in the hybrid NOTES technique used it only as a safety check (i.e., to ensure the endoscope and endoscopic instruments are correctly and safely inserted). The main visualization instrument used in all NOTES methods was the endoscope (inserted

transvaginally) with two variations: (single or multi channels) flexible gastroscope or rigid angled endoscope.

Operative instruments

For dissection, laparoscopic instruments were used in both laparoscopic cholecystectomy and hybrid NOTES methods 1 and 2. The differences between the NOTES methods and the laparoscopic technique were:

- The entry port (umbilicus versus a secondary abdominal port, respectively).
- The size of instruments.

On the other hand, endoscopic instruments introduced through one of the working channels of the endoscope were used in NOTES method 3 (the endoscopic hook electrosurgical tools, for instance).

For the clipping and the cutting tasks, the surgeons used similar laparoscopic clip appliers and scissors in all of the observed cases. Again, differences in the entry port and the size of instrument were observed between the NOTES technique (all methods) and the laparoscopic technique.

Retraction tools

While laparoscopic graspers in dedicated ports were used for retraction of the gallbladder in the conventional laparoscopic technique, three different tools were used in NOTES methods:

1. Transabdominal “Stay sutures”: Usually two sutures were placed through the fundus and infundibulum of the gallbladder using a straight Keith needle to allow continuous extracorporeal manipulation of the gallbladder.
2. Internal retractors (Endograb, Virtual Ports, Tel Aviv) using self-retaining clips positioned by a laparoscopic applier from the abdominal port [31].
3. Long laparoscopic graspers (50 cm), introduced transvaginally.
4. Laparoscopic graspers introduced through the secondary abdominal port.
However, this was observed only in one case (method 2) and could be replaced by one of the three previous tools to limit the number of incision.

It should be noted that the combination of two retraction tools is necessary to achieve a correct retraction of the gallbladder.

Extraction tools

Two different tools were used to remove the gallbladder from the abdomen:

1. Retrieval bags: the bags were introduced either transvaginally or transabdominally to extract the specimen.
2. Endoscopic snares: They were inserted transvaginally through one of the working channels of the flexible endoscope.

Timeline analysis

At the procedure level

Timeline analysis results showed that cholecystectomy was faster when performed using the laparoscopic technique (34 minutes) than the NOTES techniques (Figure 7). NOTES method 2 was slightly faster to perform (42 minutes) than NOTES method 1 (50 minutes). NOTES method 3 was much longer than all others (112 minutes). However, no statistical analysis was performed due to the small sample size.

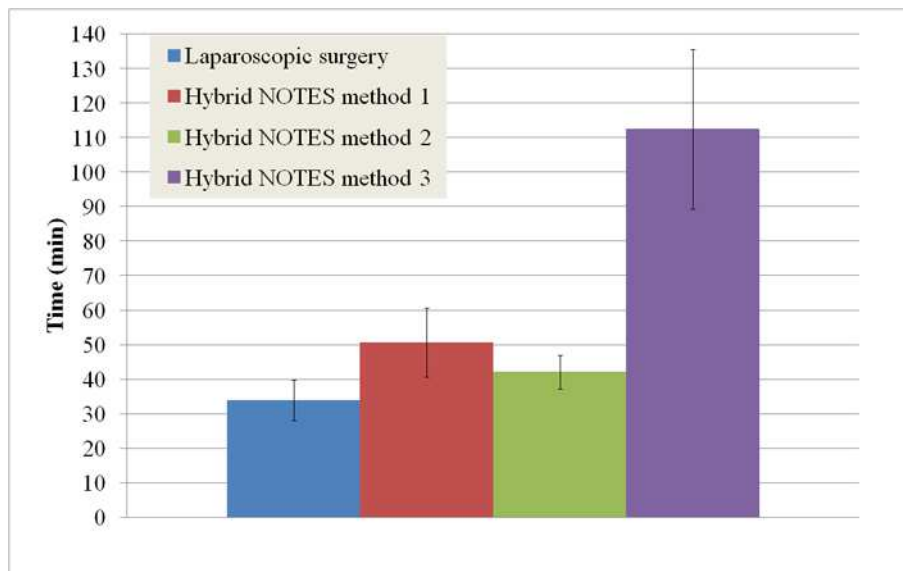


Figure 7: Total average time

At the steps level

The results (Figure 8) show that the preparation of the patient (as defined on Table 1) was faster in the laparoscopic technique than the three NOTES methods, and slightly slower in the hybrid NOTES method 1 than hybrid NOTES methods 2 and 3. In addition, the results (Figure 8) show that the isolation of the gallbladder was fastest in laparoscopic cholecystectomy, followed by the NOTES methods 2 and 1, respectively. This step was much longer in NOTES method 3. Finally, no time difference (Figure 8) was observed between the laparoscopic technique and the NOTES method 2 for the removal of the gallbladder. In addition, this step was slightly slower in NOTES method 1 while the time was highly increased in NOTES method 3.

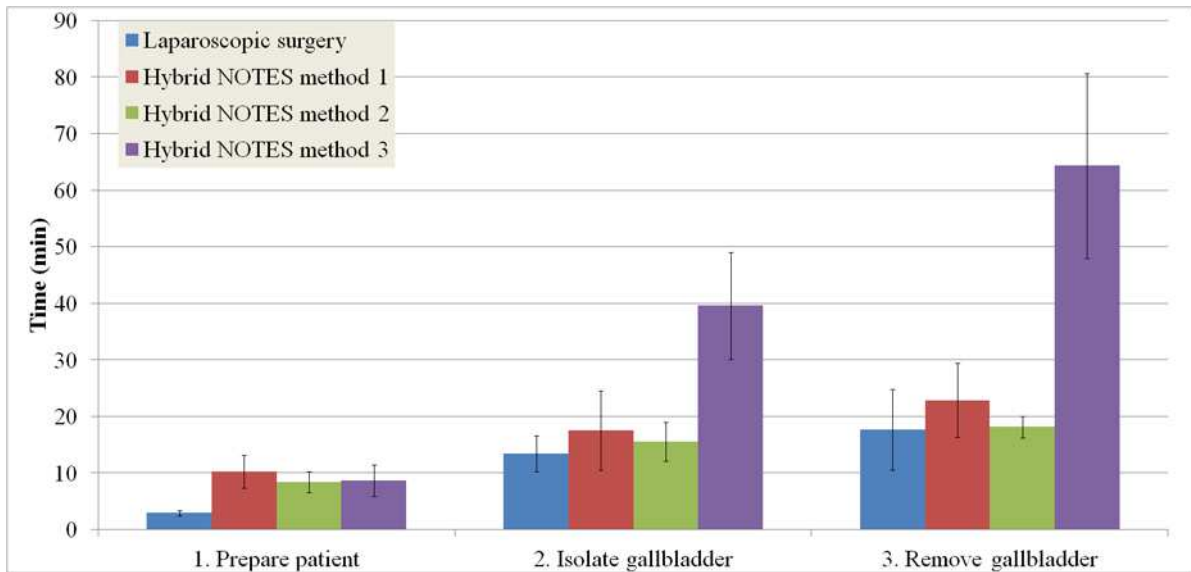


Figure 8: Timeline analysis at the steps level

At the substeps level

Step 1: Prepare the patient

As the three NOTES substeps 1.3, 1.4 and 1.5 (Figure 4 and Figure 5) were not fully captured on the videos that contained only the endoscopic views, a timeline analysis for these substeps was not performed.

Step 2: Isolate the gallbladder

Table 4: Definition of beginnings and endings of substeps for the “isolation of the gallbladder” step

| Observed surgical substeps | Beginning | Ending |
|---|---|--|
| 2.1 Locate the Gallbladder visually | Moment the first surgical instrument contacts the abdomen | Moment the Gallbladder is exposed |
| 2.2 Insert Endoscopic tools | Moment the Gallbladder is exposed | Moment the retraction tool contacts the Gallbladder |
| 2.3 (2.2) Expose Calot’s triangle | Moment the retraction tool contacts the Gallbladder | Moment the dissection tool contacts the gallbladder |
| 2.4 (2.3) Identify and isolate the cystic duct and artery | Moment the dissection tool contacts the gallbladder | Moment the dissection tool is removed from the abdomen (and replaced by clip applicator) |

The results of the timeline analysis based on the operational definitions of substeps for isolating the gallbladder (Table 4) show that (Figure 9):

- Substep 2.1: this substep was much faster to perform in the laparoscopic technique compared to the NOTES technique (all three methods).
- Substep 2.2 (Figure 5): this substep required in average 4 minutes to be performed.

- Substep 2.3 (Figure 5)/Substep 2.2 (Figure 2 and Figure 4): this substep was performed faster in the laparoscopic technique and NOTES method 2 compared to the same substep in NOTES methods 1 and 3.
- Substep 2.4 (Figure 5)/Substep 2.3 (Figure 2, Figure 4): few differences in the time to perform this substep were observed between the laparoscopic technique and NOTES methods 1 and 2, while it was highly increased in NOTES method 3.

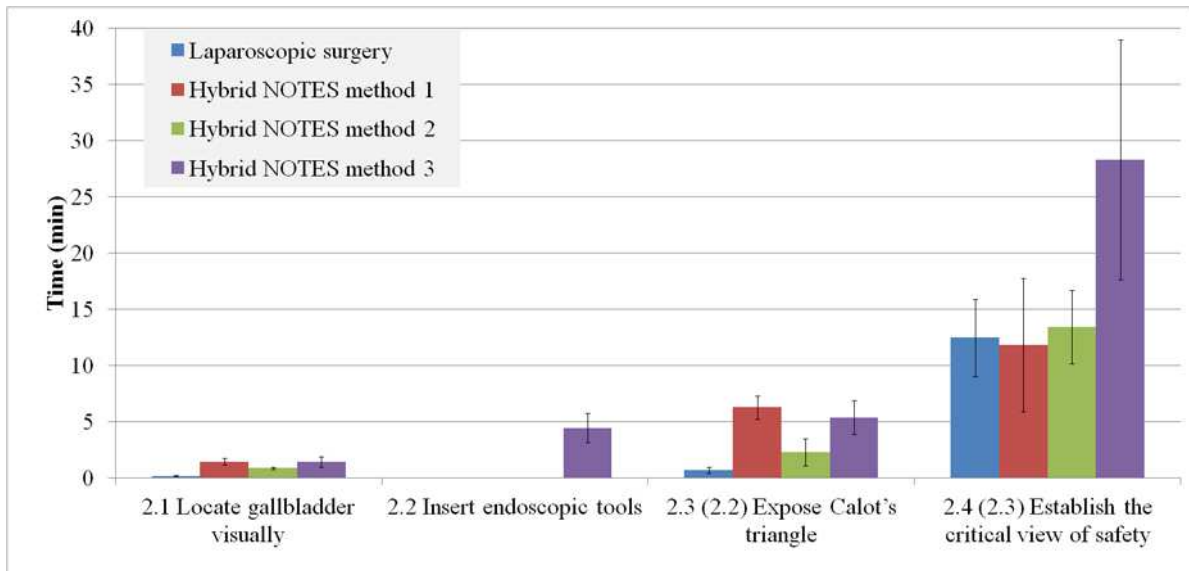


Figure 9: Timeline analysis for the “isolation of the gallbladder” step

Step3: Remove the gallbladder

Table 5: Definition of beginnings and endings of substeps for the “removal of the gallbladder” step

| Observed surgical substeps | Beginning | Ending |
|-------------------------------------|---|---|
| 3.1 Divide cystic duct | Moment clip applicator contacts the duct | Moment the cystic duct is divided |
| 3.2 Divide cystic Artery | Moment the cystic duct is divided | Moment the cystic artery is divided |
| 3.3 Free Gallbladder from liver bed | Moment the cystic artery is divided | Moment the gallbladder is detached from the liver bed |
| 3.4 Extract the gallbladder | Moment the gallbladder is detached from the liver bed | Moment gallbladder is removed from the abdomen |

Based on the operational definitions of substeps for removing the gallbladder (Table 5), results of the timeline analysis show that (Figure 10):

- Substep 3.1 (Figure 2, Figure 4 and Figure 5): this substep required similar duration in all the observed techniques/methods.
- Substep 3.2 (Figure 2, Figure 4 and Figure 5): this substep required similar duration in all the observed techniques/methods.

- Substep 3.3 (Figure 2, Figure 4 and Figure 5): this substep required similar duration in the laparoscopic technique and NOTES methods 1 and 2 while the time was highly increased in NOTES method 3.
- Substep 3.4 (Figure 2, Figure 4 and Figure 5): this substep was performed faster in the laparoscopic technique followed by NOTES methods 2 and 1 respectively, while the time was highly increased in NOTES method 3.

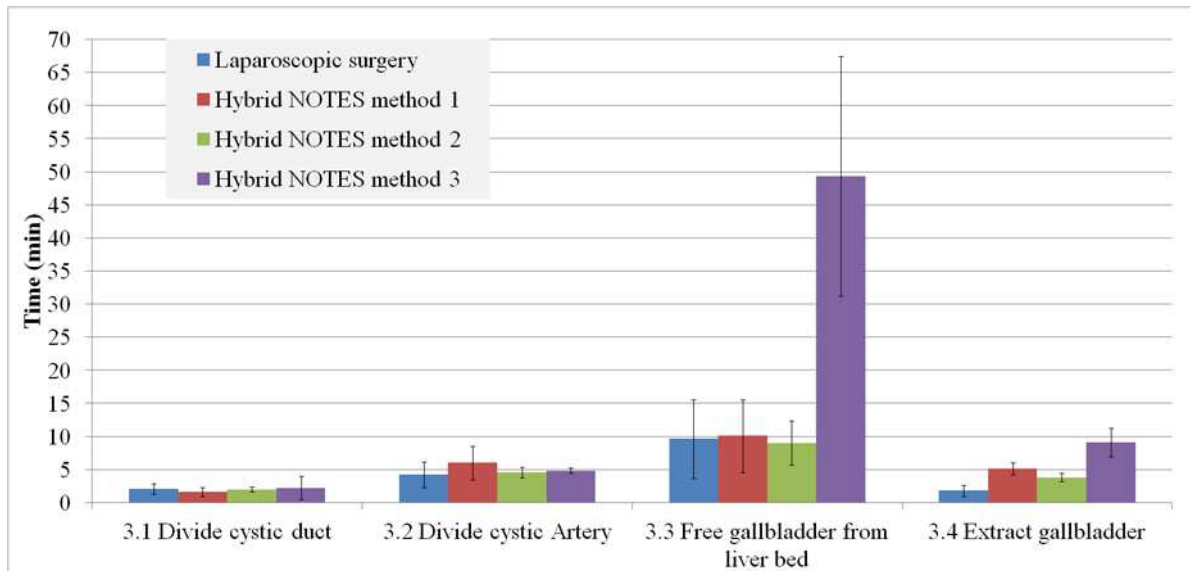


Figure 10: Timeline analysis for the “isolation of the gallbladder” step

DISCUSSION

Our analysis showed that for the most part, NOTES cholecystectomy follows the steps and substeps used in laparoscopic cholecystectomy. Variations at the substep levels can be attributed to the instrumentation and tools used, which in turn affected the time of task completion.

The HTA and the CTA permitted to raise different issues associated with the hybrid NOTES methods. These issues contributed to increase the operative time in the hybrid NOTES cases compared to the laparoscopic cases. This finding is consistent with previous research [2, 8, 10, 18, 19, 6, 20, 21]. For instance, our analysis indicates that the emergence of new substeps to setup the transvaginal access increased the surgical time suggesting the requirement of a specific training for general surgeons to improve their performance in this step.

Moreover, the introduction of the endoscopic tools for dissection in NOTES method 3 increased the time while the same tasks required similar durations when similar laparoscopic tools were used in NOTES methods 1 and 2 and laparoscopic surgery. This indicates that the current endoscopic dissection instruments are not adequate to efficiently perform these tasks.

This inadequacy of the tools can be attributed to different problems: the lack of stability of the platform, the lack of triangulation of the tools, the limited range of motion and degrees of freedom of the tools, or the lack of haptic feedback as suggested by the surgeons during the CTA. A comparison at the tasks and subtasks levels will permit to quantify the effects of these problems on the surgical performance.

Finally, the retraction of the gallbladder and the extraction of the gallbladder substeps required the use of different tools in NOTES compared to laparoscopic surgery. Our analysis indicates that these variations in tools increased the surgical time in the hybrid NOTES methods compared to laparoscopic surgery. However, a comparison at the tasks level will be necessary to give indications on the way each retraction tool and extraction tool contributes to increasing the surgical time.

The NOTES continuum

More than a decade has passed since NOTES was first described [32]. While performing a pure transvaginal NOTES cholecystectomy is commonly considered too technically complicated using existing instrumentation [7], various hybrid methods have emerged, bridging the “pure NOTES” and the laparoscopic techniques. There appears to be increasing degrees of NOTES-likeness in the three hybrid methods described in this study.

We propose a classification scheme in which the laparoscopic technique and the pure NOTES technique anchor opposite ends of a *continuum* of invasiveness, as illustrated in Figure 11. The NOTES continuum is based on the dimension of invasiveness, which is determined by the number of incisions made to introduce the necessary instruments, which in turn are constrained by their function. Our analysis showed that the number of entry ports and instruments used was similar in all NOTES methods, while the type of instruments that can be used depends on the method.

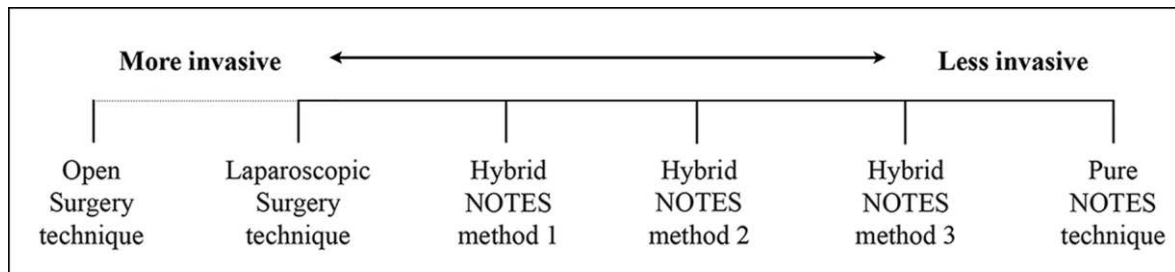


Figure 11: The NOTES cholecystectomy continuum

The case at the left of the continuum represents the current gold standard and the most invasive technique amongst the analyzed cases. The case at the far right of the continuum represents the least invasive technique: pure NOTES cholecystectomy. The hybrid methods

observed in our study can be situated anywhere between the extremes of the continuum depending on their characteristics and their possible future development toward a scar-free surgery.

From the three identified NOTES methods, the transvaginal NOTES with rigid endoscopes and laparoscopic instruments (referred to as hybrid NOTES method 1) can be considered to be the closest to the laparoscopic technique in the continuum. Indeed, it requires the use of similar tools (rigid optics and laparoscopic instruments) and can be a good starting point for novice surgeons to become familiar with the NOTES technique requirements. However, the use of the rigid endoscopes limits the type of tools that can be used in this method and thus its development toward a scar-free surgery. It requires at least one additional abdominal port to use the laparoscopic instruments necessary for some surgical tasks (e.g., dissection, clipping, cutting, etc.). While these additional ports are currently considered essential for safety, the development of new surgical instruments can replace the rigid visualization tools for the NOTES technique in the future.

In this context, the introduction of flexible endoscopes in the hybrid NOTES method 2 is a step closer toward the pure NOTES technique. Endoscopic instruments (endoscopic snares, for instance) can be introduced through working channels of the flexible scopes, providing new possibilities to the surgeons and limiting the use of the abdominal ports. The continued use of laparoscopic instruments for some tasks (dissection, clipping, and cutting) also facilitates the learning of the method and increases the safety of the patient. Our task analysis revealed that the main differences between this method and the previous one are the visualization and navigation tasks, and the use of some endoscopic instruments. This suggests that the NOTES surgeons should be trained on the manipulation of flexible endoscopes and endoscopic instruments, which is currently not fully included in the general surgeons' curriculum.

Finally, NOTES method 3 can be considered to be the closest to the pure NOTES technique with the use of more endoscopic instruments compared to the previous method. This step is necessary to eliminate the additional abdominal ports. However, the lack of surgical instruments that can be used through the endoscope (i.e., scissors and clip appliers) is currently an obstacle toward the scar free NOTES technique [7]. For instance, endoscopic clips have been shown to be inappropriate for cystic duct clipping based on animal studies [7]. In 2009, a new set of endoscopic instruments dedicated to NOTES, the generation 1 NOTES tool box (Ethicon Endo-Surgery Inc. (EES), Cincinnati, OH) was introduced. The tools were experimented in NOTES cholecystectomy procedures on porcine models [33, 34]. In spite of

the encouraging results, these studies pointed out some limitations (such as visibility of the endoscopic clip applier tool tip) that can prevent this set of tools from being used successfully for humans. Moreover, the toolbox has not been approved for clinical use by the US Food and Drug Administration.

In addition, our analysis indicates that the use of current endoscopic instruments introduces several challenges for the surgeons. First, they require performing additional surgical substeps (introduction of instruments) which contributes to increasing the surgical time. Second, they are currently inadequate to correctly perform certain tasks (such as dissection) [28], thus increasing surgical time. It is necessary to work in close collaboration with surgical device designers and manufacturers in order to design new endoscopic instruments that fit the needs of the surgeons to perform NOTES cholecystectomy procedures.

In summary, the NOTES continuum classification scheme illustrates the current state of the art of the NOTES technique. It is a framework that permits us to classify the different existing methods and to follow the evolution of the NOTES technique. Other existing NOTES methods and minimally invasive surgery techniques such as the single port minimally invasive surgery technique can be included and placed on this continuum. This can permit a systemic evaluation of the different techniques and help to design more efficient tools and more adaptive training programs.

Limitations and future work

We presented results from a systematic analysis of different existing NOTES methods and compared them to the laparoscopic cholecystectomy. As NOTES is an emerging technique, collecting video data from real human cases is challenging. Nevertheless, we have developed a classification scheme and systematic methodologies to analyze complex human work in the context of surgery. The next step will be to extend the analysis to other NOTES approaches (such as the transgastric approach) and to include a larger set of videos in order to validate the classification scheme.

Another important step will be to extend the analysis to the sub levels of the hierarchy (tasks, subtasks and motions) in order to perform a deeper comparison between the transvaginal NOTES technique and laparoscopic Cholecystectomy.

ACKNOWLEDGMENTS

The authors gratefully acknowledge the support of this study by NIH/NIBIB (Grant No. R01EB009362).

Disclosure

Dr. Schwaitzberg is Consultant for Stryker and Olympus and member of the Advisory board for NeatStitch, AcuityBio, MITI, Cambridge Endo and Surgique. Dr. Rattner has a consulting agreement for educational symposium with Olympus Corporation. Drs. Chellali, Jones, Miller, Romanelli, Roberts and Cao have no conflicts of interest or financial ties to disclose.

REFERENCES

- [1] Auyang ED, Santos BF, Enter DH, Hungness ES, Soper NJ (2011) Natural orifice transluminal endoscopic surgery (NOTES): a technical review. *Surg Endosc* 25(10): 3135–3148
- [2] Niu J, Song W, Yan M, Fan W, Niu W, Liu E, Peng C, Lin P, Li P, Khan AQ (2010) Transvaginal laparoscopically assisted endoscopic cholecystectomy: preliminary clinical results for a series of 43 cases in China. *Surg Endosc* 25(4): 1281-1286
- [3] Zorron R, Maggioni LC, Pombo L, Oliveira AL, Carvalho GL, Filgueiras M (2008) NOTES transvaginal cholecystectomy: preliminary clinical application. *Surg Endosc* 22(2): 542-547
- [4] Zornig C, Mofid H, Emmermann A, Alm M, von Waldenfels HA, Felixmüller C (2008) Scarless cholecystectomy with combined transvaginal and transumbilical approach in a series of 20 patients. *Surg Endosc* 22(6): 1427-1429
- [5] Cuadrado-Garcia A, Noguera JF, Olea-Martinez JM, Morales R, Dolz C, Lozano L, Vicens JC, Pujol JJ (2011) Hybrid natural orifice transluminal endoscopic cholecystectomy: prospective human series. *Surg Endosc* 25(1): 19-22
- [6] Noguera JF, Cuadrado A, Dolz C, Olea JM, García JC (2012) Prospective Randomized Clinical Trial Comparing Laparoscopic Cholecystectomy and Hybrid Natural Orifice Transluminal Endoscopic Surgery (NOTES). *Surg Endosc* 26(12): 3435-3441
- [7] Asakuma M, Perretta S, Allemann P, Cahil RI, Con SA, Solano C, Pasupathy S, Mutter D, Dallemagne B, Marescaux J (2009) Challenges and lessons learned from NOTES cholecystectomy initial experience: a stepwise approach from the laboratory to clinical application. *J Hepatobiliary Pancreat Surg* 16: 249–254
- [8] Vieira JP, Linhares MM, Caetano EMJ, Moura RM, Asseituno V, Fuzyi R, Girão MJ, Ruano JM, Goldenberg A, de Jesus GLF, Matos D (2012) Evaluation of the clinical and

- inflammatory responses in exclusively NOTES transvaginal cholecystectomy versus laparoscopic routes: an experimental study in swine. *Surg Endosc* 26(11): 3232-3244
- [9] Rattner D, Kalloo A (2006) ASGE/SAGES Working Group on Natural Orifice Translumenal Endoscopic Surgery. *Surg Endosc* 20(2): 329–333
- [10] Solomon D, Shariff AH, Silasi DA, Duffy AJ, Bell RL, Roberts KE (2012) Transvaginal cholecystectomy versus single-incision laparoscopic cholecystectomy versus four-port laparoscopic cholecystectomy: a prospective cohort study. *Surg Endosc* 26(10): 2823-2827
- [11] Palanivelu C, P.S. R, Rangarajan M, Parthasarathi R, Senthilnathan P, Prasad M (2008) Transvaginal endoscopic appendectomy in humans: a unique approach to NOTES—world’s first report. *Surg Endosc* 22(5): 1343-1347
- [12] Jacobsen GR, Thompson K, Spivack LAF, Wong JCB, Bosia J, Whitcomb E, Lucas E, Talamini M, Horgan S (2010) Initial experience with transvaginal incisional hernia repair. *Hernia* 14(1): 89-91
- [13] Jones DB, Maithel SK, Schneider BE (2006) *Atlas of Minimally Invasive Surgery*, 1st ed, Cine-Med, Inc., Woodbury (CT)
- [14] Navez B. (2001) Laparoscopic cholecystectomy for acute cholecystitis. Epublication: WeBSurg.com. <http://www.websurg.com/ref/doi-ot02en012.htm>. Accessed April 12, 2013.
- [15] Strasberg SM, Brunt LM (2010) Rationale and use of the critical view of safety in laparoscopic cholecystectomy. *J Am Coll Surg* 211(1): 132-138
- [16] Bingener J, Gostout CJ (2012) Update on Natural Orifice Translumenal Endoscopic Surgery. *Gastroenterol Hepatol* 8(6): 384–389
- [17] Sankaranarayanan G, Matthes K, Nemani A, Ahn W, Kato M, Jones DB, Schwaitzberg S, De S (2013) Needs analysis for developing a virtual-reality NOTES simulator. *Surg Endosc* 27(5): 1607-1616
- [18] Zornig C, Siemssen L, Emmermann A, Alm M, von Waldenfels HA, Felixmüller C, Mofid H (2011) NOTES cholecystectomy: matched-pair analysis comparing the transvaginal hybrid and conventional laparoscopic techniques in a series of 216 patients. *Surg Endosc* 25(6): 1822-1826
- [19] Santos BF, Teitelbaum EN, Arafat FO, Milad MP, Soper NJ, Hungness ES (2012) Comparison of short-term outcomes between transvaginal hybrid NOTES

- cholecystectomy and laparoscopic cholecystectomy. *Surg Endosc* 26(11): 3058-3066
- [20] Kondo W, Wood Branco A, Branco Filho AJ, Noda RW, Tessmann Zomer M, Charles L, Bourdel N (2011) Transvaginal Natural Orifice Transluminal Endoscopic Surgery (Notes): Surgical Technique and Results. In: Darwish A (ed) *Advanced Gynecologic Endoscopy*, Available from: <http://www.intechopen.com/books/advanced-gynecologic-endoscopy/transvaginal-natural-orifice-transluminal-endoscopic-surgery-notes-surgical-technique-and-results>
- [21] Bucher P, Pugin F, Ostermann S, Ris F, Chilcott M, Morel P (2011) Population perception of surgical safety and body image trauma: a plea for scarless surgery? *Surg Endosc* 25: 408–415
- [22] Tessier C, Zhang L, Cao CGL (2012) Ergonomic considerations in natural orifice transluminal endoscopic surgery (NOTES): A case study. *Work: A Journal of Prevention, Assessment and Rehabilitation*: 4683-4688
- [23] Shackel B (1991) Usability—Context; Framework; Definition; Design and Evaluation. *Human Factors for Informatics Usability*, Cambridge University Press, New York, pp 21–37
- [24] Cuschieri A (2000) Human reliability assessment in surgery—a new approach for improving surgical performance and clinical outcome. *Ann R Coll Surg Engl* 82: 83–87
- [25] MacKenzie CL, Ibbotson JA, Cao CGL, Lomax AJ (2000) Hierarchical decomposition of goal-directed activity: a valuable research and investigative tool for minimally invasive surgery. In *proceedings of the 7th World Congress of Endoscopic Surgery, Singapore*, pp 409
- [26] MacKenzie CL, Cao CGL, Ibbotson JA, Lomax AJ (2001) Hierarchical decomposition of laparoscopic surgery: A human factors approach to investigating the operating room environment. *Journal of Minimally Invasive Therapy and Allied Technologies* 10(3): 121-127
- [27] Cao CGL, MacKenzie CL, Ibbotson JA, Turner LJ, Blair NP, Nagy AG (1999) Hierarchical decomposition of laparoscopic procedures. *Stud health technol inform* 62: 83-89
- [28] Chellali A, Cao CGL (2013) The Impact of New Instruments on Surgical Performance in Natural Orifice Transluminal Endoscopic Surgery. In the *proceedings of the Human Factors and Ergonomics Society Annual Meeting HFES 2013, San Diego, CA*, pp 663-

- [29] Clark RE, Feldon D, Van Merriënboer JJG, Yates K, Early S (2008) Cognitive task analysis. In: J.M. Spector, M.D. Merrill, J.J.G. van Merriënboer, M.P. Driscoll (eds) *Handbook of research on educational communications and technology*, 3rd ed, Lawrence Erlbaum Associates, Mahwah (NJ)
- [30] Shih SP, Kantsevov SV, Kalloo AN, Magno P, Giday SA, Ko CW, Isakovich NV, Meireles O, Hanly EJ, Marohn MR (2007) Hybrid minimally invasive surgery—a bridge between laparoscopic and transluminal surgery. *Surg Endosc* 21(8): 1450–1453
- [31] Schlager A, Khalaileh A, Shussman N, et al. (2010) Providing more through less: current methods of retraction in SIMIS and NOTES cholecystectomy. *Surg Endosc* 27(4): 1542-1546
- [32] Kalloo AN, Singh VK, Jagannath SB, Niiyama H, Hill SL, Vaughn CA, Magee CA, Kantsevov SV (2004) Flexible transgastric peritoneoscopy: a novel approach to diagnostic and therapeutic interventions in the peritoneal cavity. *Gastrointest Endosc* 60: 114-117
- [33] Satgunam S, Miedema B, Whang S, Thaler K (2012) Transvaginal cholecystectomy without laparoscopic support using prototype flexible endoscopic instruments in a porcine model. *Surg Endosc* 26: 2331–2338
- [34] Whang SH, Satgunam S, Miedema BW, Thaler K (2010) Transvaginal cholecystectomy by using a prototype flexible clip applier. *J Gastrointest Endo* 72(2): 351–357