



HAL
open science

Chemotherapy-Related Gallbladder Visualization in a 99mTc-HMDP SPECT/CT Bone Scan

Juliette Bozzetto, Sophie Lancelot, Francesco Giammarile

► **To cite this version:**

Juliette Bozzetto, Sophie Lancelot, Francesco Giammarile. Chemotherapy-Related Gallbladder Visualization in a 99mTc-HMDP SPECT/CT Bone Scan. *Clinical Nuclear Medicine*, 2013, 38 (10), pp.829-831. 10.1097/RLU.0b013e31829f8e90 . hal-00948093

HAL Id: hal-00948093

<https://hal.science/hal-00948093v1>

Submitted on 23 Jan 2025

HAL is a multi-disciplinary open access archive for the deposit and dissemination of scientific research documents, whether they are published or not. The documents may come from teaching and research institutions in France or abroad, or from public or private research centers.

L'archive ouverte pluridisciplinaire **HAL**, est destinée au dépôt et à la diffusion de documents scientifiques de niveau recherche, publiés ou non, émanant des établissements d'enseignement et de recherche français ou étrangers, des laboratoires publics ou privés.

Chemotherapy-Related Gallbladder Visualization in a ^{99m}Tc -HMDP SPECT/CT Bone Scan

Juliette Bozzetto, MD,* Sophie Lancelot, PharmD, PhD,*† and Francesco Giammarile, MD, PhD*‡

Abstract: Nonosseous uptakes are occasionally found on bone scintigraphy. Most of them are easily explained by current pathophysiological mechanisms (metastatic calcifications, metabolic process, or extravascular accumulation of radiopharmaceutical) or current artifacts. Other unusual findings are still unexplained. We report 1 didactic case of incidental gallbladder uptake on bone scan. Additional single-photon emission computed tomography-computed tomography (SPECT/CT) imaging was performed to better characterize abnormal location. The significance of this serendipitous uptake is not clearly established. This finding could be due to altered distribution induced by the chemotherapy regimen and is not the result of intrinsic gallbladder disease.

Key Words: nonosseous uptake, altered distribution, gallbladder, artifacts, chemotherapy

Received for publication April 26, 2013; and revision accepted May 26, 2013.

From the *Department of Nuclear Medicine Lumen, and University Claude Bernard Lyon, Lyon; †INSERM U1028—CNRS UMR5292, Lyon; and ‡EA 3738, Faculté Charles Mérieux Lyon Sud, Lyon, France.

Conflicts of interest and sources of funding: none declared.

Institution where work was performed: Centre Lumen GCS, 15, rue Gabriel Sarrazin, 69373 Lyon Cedex 08, France.

Reprints: Juliette Bozzetto, MD, Service de Médecine nucléaire, Centre Lumen, 15, rue Gabriel Sarrazin, 69373 Lyon Cedex 08, France.
E-mail: bozzettojuliette@gmail.com.

REFERENCES

1. Bhatnagar P, Chakraborti KL, Sachdev P, et al. Serendipitous gallbladder uptake in a bone scan. *Clin Nucl Med.* 2005;30:512–513.
2. Loutfi I, Collier BD, Mohammed AM. Nonosseous abnormalities on bone scans. *J Nucl Med Technol.* 2003;31:149–153.
3. Zuckier LS, Freeman LM. Nonosseous, nonurologic uptake on bone scintigraphy: atlas and analysis. *Semin Nucl Med.* 2010;40:242–256.
4. Scheiner JD, Dupuy DE. Porcelain gallbladder detected on bone scan. *Clin Nucl Med.* 1998;23:845–846.
5. Hurwitz H, Saini S. Bevacizumab in the treatment of metastatic colorectal cancer: safety profile and management of adverse events. *Semin Oncol.* 2006;33:S26–S34.
6. Lowry PA, Carstens C. Intense gallbladder uptake associated with chemotherapy. An unusual finding in pediatric skeletal scintigraphy. *Clin Nucl Med.* 1995;20:976–978.
7. Vallabhajosula S, Killeen RP, Osborne JR. Altered biodistribution of radiopharmaceuticals: role of radiochemical/pharmaceutical purity, physiological, and pharmacologic factors. *Semin Nucl Med.* 2010;40:220–241.
8. Worsley DF, Lentle BC. Uptake of technetium-99m MDP in primary amyloidosis with a review of the mechanisms of soft tissue localization of bone seeking radiopharmaceuticals. *J Nucl Med.* 1993;34:1612–1615.

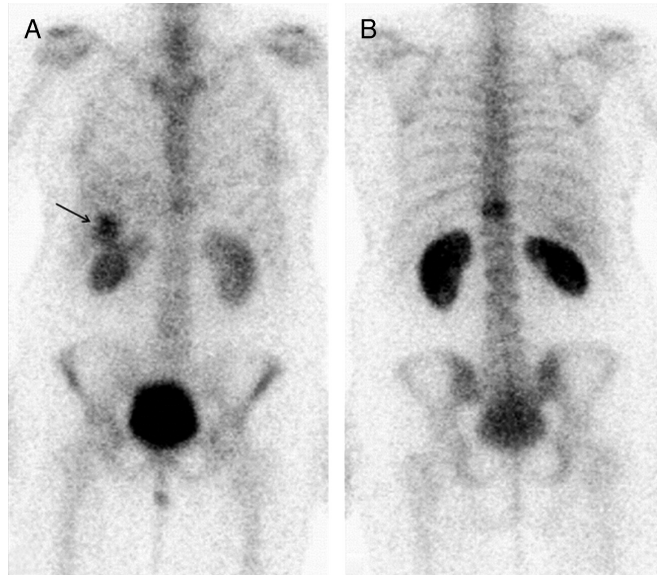


FIGURE 1. A 49-year-old woman with rectum adenocarcinoma had undergone posterior pelvicotomy resection in August 2011 followed by postoperative adjuvant chemotherapy using oxaliplatin and folic acid because of lymph node metastases. During her course of therapy, she developed liver metastases and received another chemotherapy regimen made up of folinic acid, fluorouracil, and irinotecan, plus bevacizumab in March 2012. Nine months later, she complained of her pelvis and knees. Whole-body bone scan was performed, after i.v. injection of 320 MBq (8.7 mCi) of ^{99m}Tc -hydroxymethylenediphosphonate (HMDP), to image bone abnormalities that could explain these symptoms. The patient received a course of chemotherapy 2 days before the examination. Anterior (A) and posterior (B) zoom from a whole-body bone scan showed focus of increased bony uptake within the body of 11th thoracic vertebra. The bone scan did not reveal other suspicious bone uptakes especially within the pelvis and knees. However, unexpected and unusual diffuse uptake is noted in the right upper quadrant abdominal, in the gallbladder area.¹⁻³

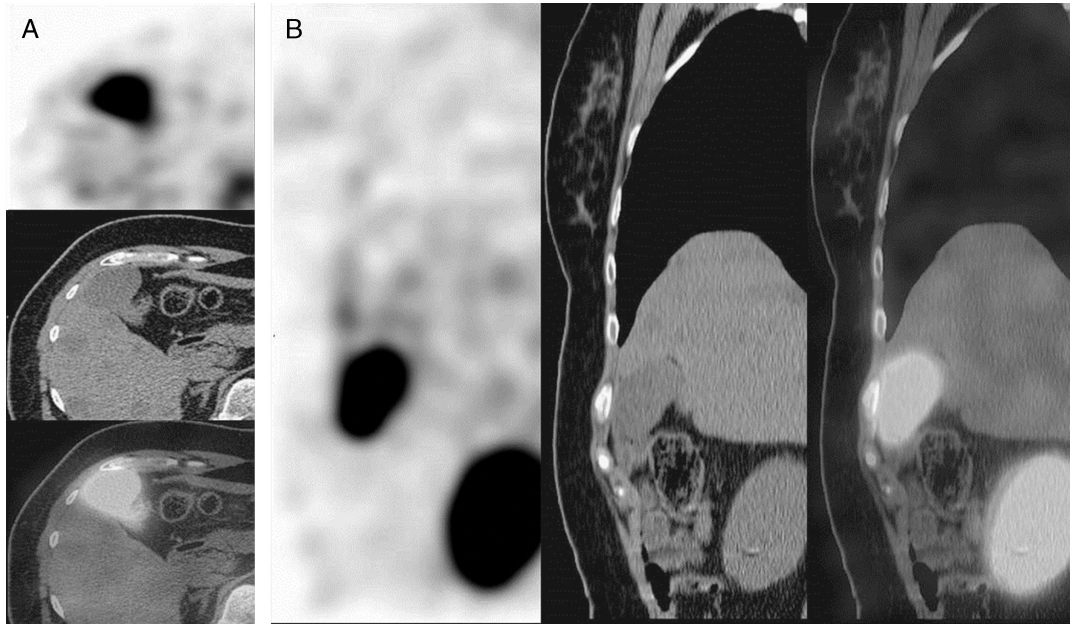


FIGURE 2. SPECT/CT imaging was performed to localize and accurately characterize planar abnormalities in 3 dimensions. Images confirmed tracer uptake in the body of the 11th thoracic vertebra and showed its heterogeneous aspect without patent morphological characteristics suspicious for metastases on CT scan. No additional foci of abnormal ^{99m}Tc -HMDP uptake were identified on the remainder of the skeleton. Otherwise, axial (A) and coronal (B) SPECT, CT, and fused SPECT/CT images depicted intense, homogenous, and diffuse uptake within the gallbladder lumen. Radiopharmaceutical (HMDP) quality control revealed no radiochemical impurities. Ten other patients received doses from the same vial on the same day with normal distribution. This incidental accumulation of ^{99m}Tc -HMDP could be readily explained by metabolic pathway such as chronic lithiasis.⁴ Furthermore, bevacizumab is known for hepatotoxicity or other digestive side effects, such as gallbladder inflammation or perforation; however, the patient presented no evidence of toxicity.⁵ However, images did not reveal calcified or inflamed gallbladder wall. Besides, abdominal CT images depicted known liver metastases. The mechanism of gallbladder excretion of derivatives of ^{99m}Tc -diphosphonates is unknown and rare.^{6,7} There are many factors that can alter the normal biodistribution of the radiopharmaceutical and lead to its extraosseous localization. Some authors have suggested a mechanism linked to increased interstitial pressure associated with liver metastases.⁸ In our case, this option seems impossible because of the low-volume metastases, and we believe that gallbladder excretion of ^{99m}Tc -HMDP could be due to an iatrogenic alteration of radiopharmaceutical by chemotherapeutic agents.