



HAL
open science

Spatial normalization of eye fundus images

Xiwei Zhang, Etienne Decencière, Guillaume Thibault, Guy Cazuguel, Gwénolé Quellec, Ronan Danno, Bruno Laÿ, Ali Erginay, Pascale Massin, Zeynep Guvenli-Victor, et al.

► **To cite this version:**

Xiwei Zhang, Etienne Decencière, Guillaume Thibault, Guy Cazuguel, Gwénolé Quellec, et al.. Spatial normalization of eye fundus images. ISBI 2012: 9th IEEE International Symposium on Biomedical Imaging, May 2012, Barcelone, Spain. IEEE, 2012. hal-00945417

HAL Id: hal-00945417

<https://hal.science/hal-00945417v1>

Submitted on 11 Oct 2022

HAL is a multi-disciplinary open access archive for the deposit and dissemination of scientific research documents, whether they are published or not. The documents may come from teaching and research institutions in France or abroad, or from public or private research centers.

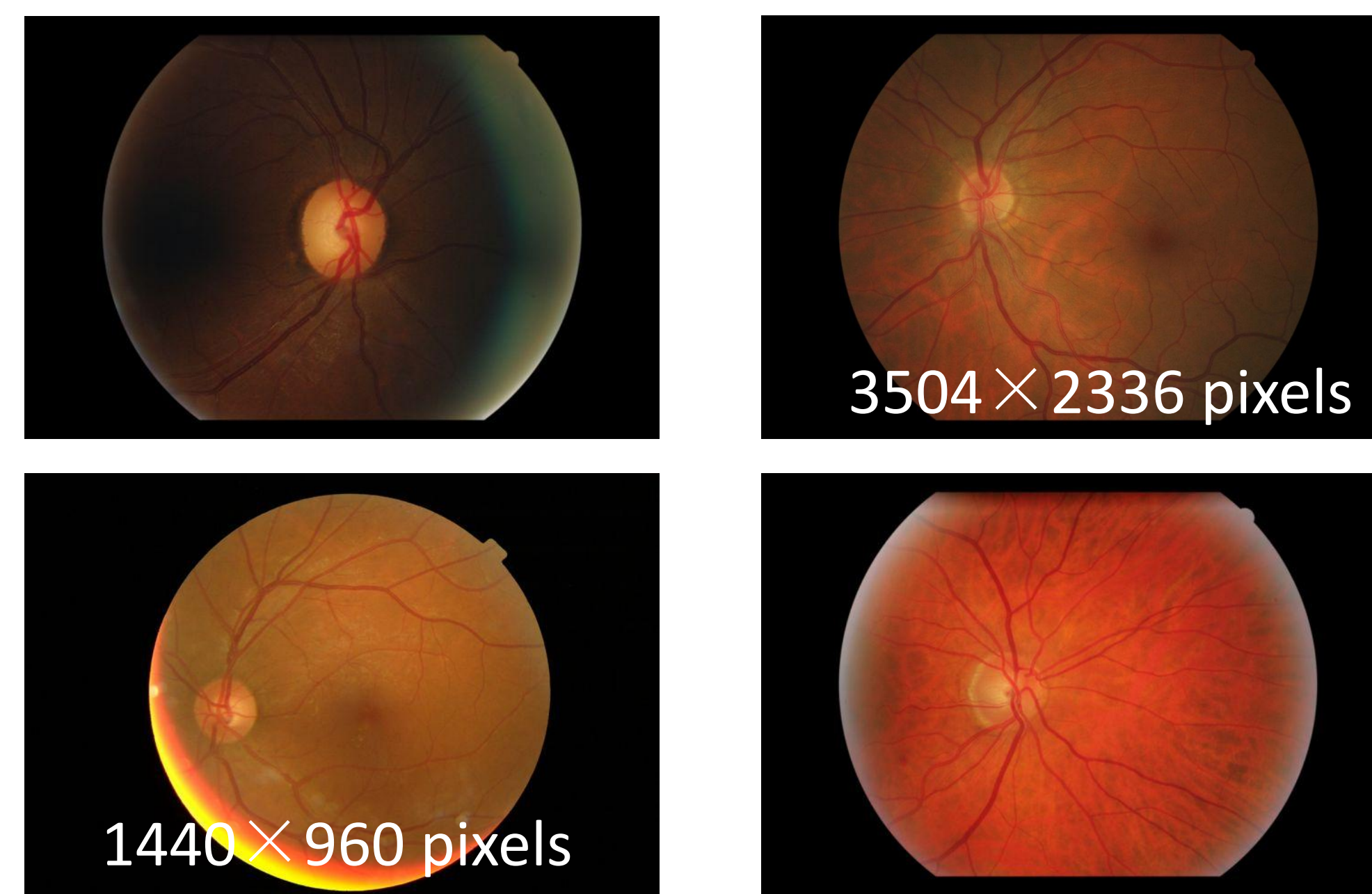
L'archive ouverte pluridisciplinaire **HAL**, est destinée au dépôt et à la diffusion de documents scientifiques de niveau recherche, publiés ou non, émanant des établissements d'enseignement et de recherche français ou étrangers, des laboratoires publics ou privés.



Distributed under a Creative Commons Attribution 4.0 International License

Introduction

- The heterogeneity of clinical retinal image databases, regarding image scale, contrast and quality, makes the design of generic image processing algorithms difficult. Different possibilities of spatial normalization of eye fundus images are analyzed, and a simple and efficient method is proposed.
- OPHDIAT** is a telemedicine network for diabetic retinopathy screening. Thousands of color eye fundus images have been collected, 70% of which have been classified as healthy by ophthalmologists. The **e-ophta** database has been built from this data. The **TeleOphta** project aims at performing a preliminary analysis of these images, in order to automatically filter out healthy images, and thus reduce the burden on specialists.



Eye fundus images from the e-ophta database. Pixel size is often either absent, or not reliable

Partners:



Authors:

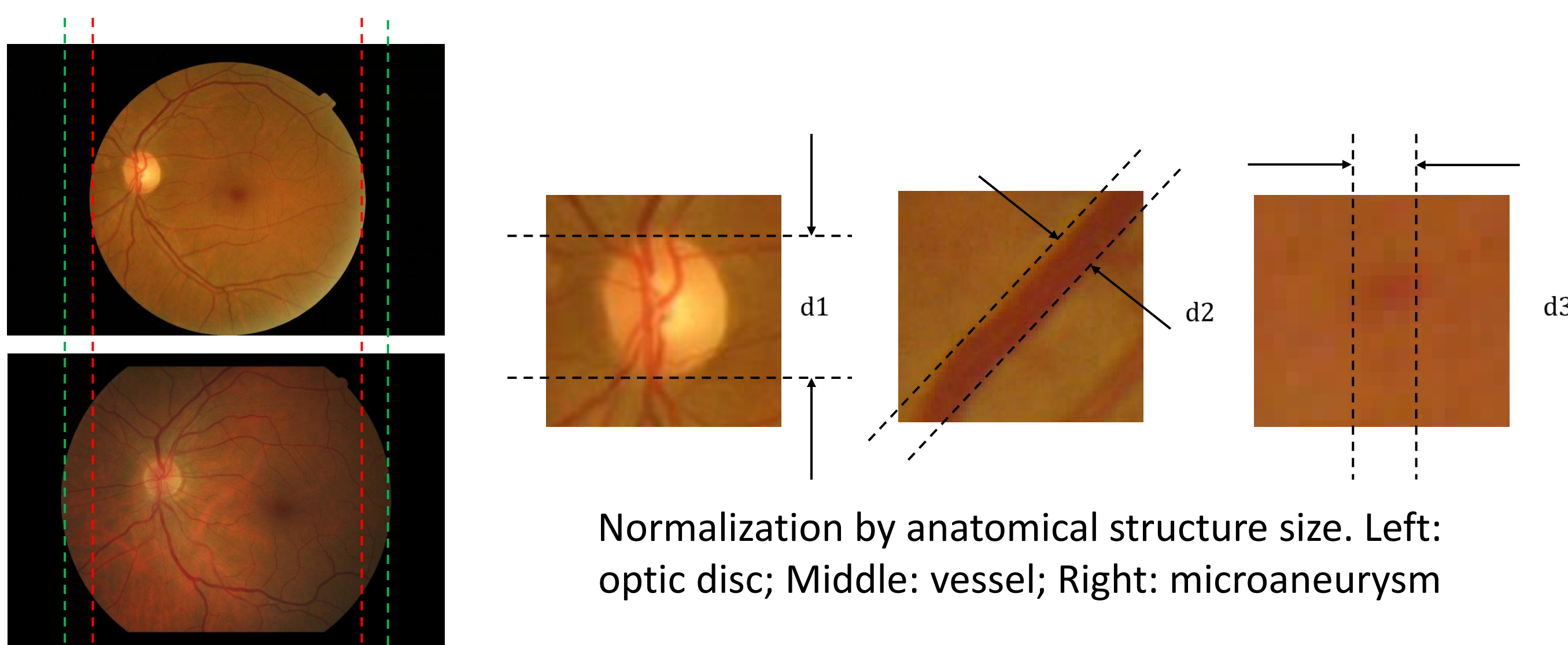
X. Zhang, E. Decencière, G. Thibault, G. Cazuguel, G. Quellec, R. Danno, B. LaÿA. Erginay, P. Massin, Z. Guvenli-Victor, A. Chabouis

Financial support:



Possible Approaches

- Using image size directly: This is the most common and the easiest method. Before any processing, all images are sampled to the same size. However, the field-of-view appears different shapes according to manufacture and date^[1]. The size of the image cannot precisely represent the pixel size.

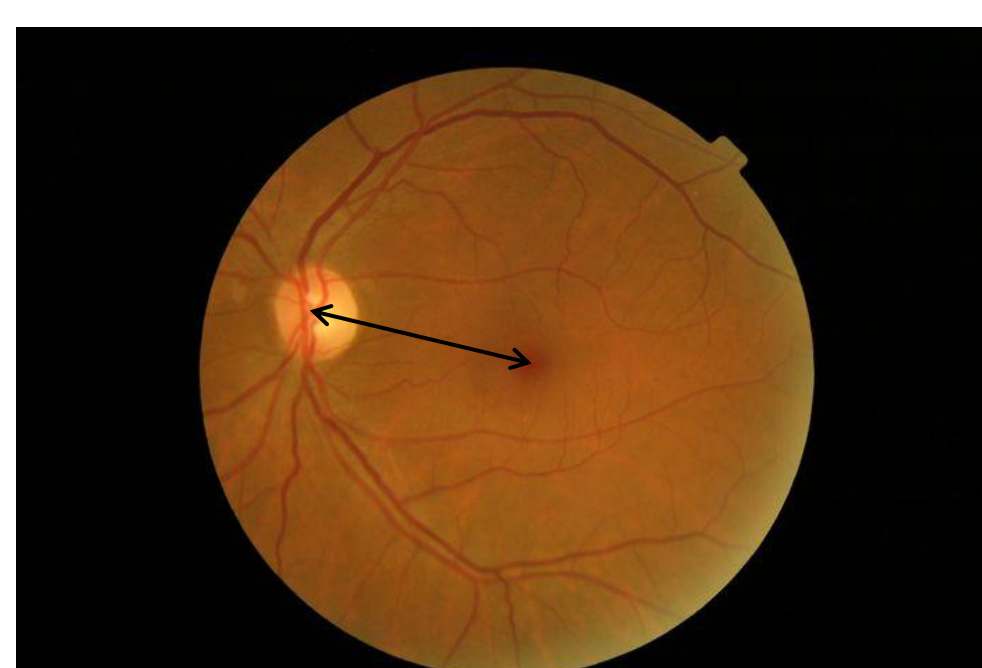


Normalization by anatomical structure size. Left: optic disc; Middle: vessel; Right: microaneurysm

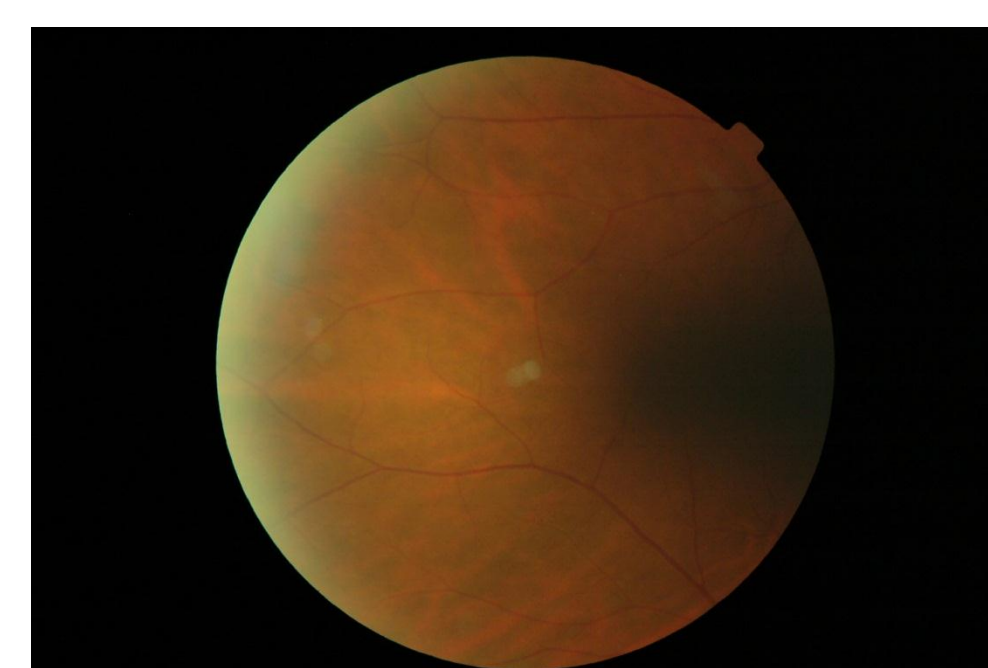
Normalization by image size, leading to different sizes of field-of-view

- Spatial normalization based on anatomic structures and lesions size, such as the diameter of the optic disc (OD) and the width of blood vessels: Difficult, given, firstly, that the anatomical size of structures varies from one person to the other (for example, the theoretical size of the OD is between 1-2 mm), and, secondly, that obtaining a precise segmentation and measurement of retinal structures, such as blood vessels, remains a problem.

- Using the distance between optic disc and fovea: the OD and fovea need to be detected, which is not easy, and moreover they may be absent from the image.



Normalization based on the distance between the optic disc and the fovea



Absence of OD

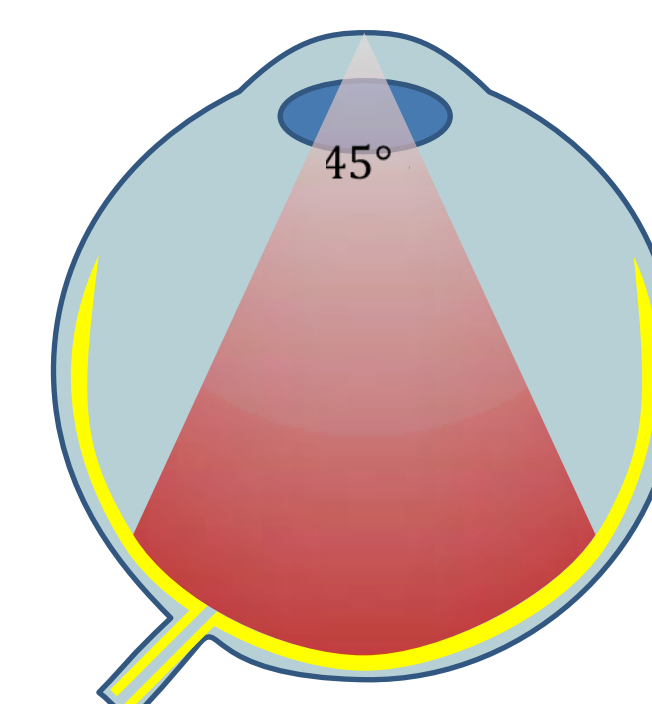
[1] P.J. Saine, 'Focusing The Fundus Camera: A Clinical Approach', Journal of Ophthalmic Photography, Vol. 14, No.1, 1992.

Validation


- The proposed method has been tested on the **e-ophta** database and compared to a manual measurement, based on the distance between the center of the Optic Disc and the fovea as the scale coefficient (see the table on the right). There are 8 different image sizes, and the first group (in red) is taken as the reference. For each group, 5 images are used to get a mean value.

Proposed Method

- The field-of-view (FOV) is easy to segment. Since all the images in the e-ophta database have been acquired with the same capture angle, the width of the FOV and the pixels size are linearly correlated.



Capture angle of a fundus camera



Normalization by the width of the FOV. Left: fundus image; Right: segmented FOV

- The width of the FOV is considered as a constant, which can then be used to compute the scale of the image.

Reference group

Field-of-view	$D_{ref} = 900$ px
Optic disc	$OD_{ref} = 160$ px
Vessel	$V_{ref} = 12$ px
Microaneurysm	$MA_{ref} = 10$ px

An unknown image → Segmentation → $D=1900$ px

I.

II. $r = \frac{D_{ref}}{D} = 0.47$

Scale coefficient	Optic disc	$OD = OD_{ref}/r = 340$ px
	Vessel	$V = V_{ref}/r = 26$ px
	Microaneurysm	$MA = MA_{ref}/r = 21$ px

- The result shows an excellent agreement between the manually measured and automatically calculated scale coefficients (blue columns). Moreover, the standard deviation of the estimated size is smaller when using the automatic method. The proposed method shows a high accuracy and stability for estimating the scale coefficients.
- The generalization to other capture angles is straightforward

Image size	Distance between OD and Fovea	Scale coefficient (manually measured)	Width of FOV	Scale coefficient (proposed method)
1440×960	349	1	910	1
1504×1000	352	0.99	923	0.99
1728×1152	512	0.68	1305	0.70
1936×1288	555	0.63	1484	0.61
2048×1360	595	0.59	1533	0.59
2544×1696	778	0.45	1924	0.47
2816×1880	817	0.43	2159	0.42
3504×2336	1044	0.33	2650	0.34

