



## Experimental infection with a low virulence isolate of *Neospora caninum* at 70 days gestation in cattle did not result in foetopathy

Silvia Rojo-Montejo, Esther Collantes-Fernández, Javier Blanco-Murcia, Antonio Rodríguez-Bertos, Veronica Risco-Castillo, Luis Miguel Ortega-Mora

### ► To cite this version:

Silvia Rojo-Montejo, Esther Collantes-Fernández, Javier Blanco-Murcia, Antonio Rodríguez-Bertos, Veronica Risco-Castillo, et al.. Experimental infection with a low virulence isolate of *Neospora caninum* at 70 days gestation in cattle did not result in foetopathy. *Veterinary Research*, 2009, 40 (5), 10.1051/vetres/2009032 . hal-00903125

**HAL Id: hal-00903125**

**<https://hal.science/hal-00903125>**

Submitted on 11 May 2020

**HAL** is a multi-disciplinary open access archive for the deposit and dissemination of scientific research documents, whether they are published or not. The documents may come from teaching and research institutions in France or abroad, or from public or private research centers.

L'archive ouverte pluridisciplinaire **HAL**, est destinée au dépôt et à la diffusion de documents scientifiques de niveau recherche, publiés ou non, émanant des établissements d'enseignement et de recherche français ou étrangers, des laboratoires publics ou privés.

## Experimental infection with a low virulence isolate of *Neospora caninum* at 70 days gestation in cattle did not result in foetopathy

Silvia ROJO-MONTEJO, Esther COLLANTES-FERNÁNDEZ, Javier BLANCO-MURCIA,  
Antonio RODRÍGUEZ-BERTOS, Verónica RISCO-CASTILLO,  
Luis Miguel ORTEGA-MORA\*

SALUVET, Animal Health Department, Faculty of Veterinary Sciences, Complutense University of Madrid,  
Ciudad Universitaria s/n, 28040 Madrid, Spain

(Received 27 February 2009; accepted 3 June 2009)

**Abstract** – The Nc-Spain 1H isolate of *Neospora caninum*, which was newly obtained from the brain of a congenitally asymptomatic infected calf, demonstrated a reduced in vitro tachyzoite yield and viability rate, as well as low virulence in mouse models. The objective of the present study was to determine the ability of this isolate to induce foetal death in a pregnant bovine model. For this purpose, 13 naïve pregnant heifers were divided into three groups and were experimentally challenged with either  $10^7$  tachyzoites of Nc-1 (group 1,  $n = 5$ ), Nc-Spain 1H (group 2,  $n = 5$ ) isolates or phosphate-buffered saline (group 3,  $n = 3$ ) intravenously at 70 days of gestation. After inoculation, pregnancy was monitored and dams were sacrificed when foetal death was detected. The remaining animals were slaughtered at 45 days post-infection. Maternal and foetal samples were collected for examination by histology and parasite DNA detection. Parasitaemia, specific anti-*N. caninum* IgG and interferon  $\gamma$  responses were also studied. At 3–4 weeks after infection, foetal death was detected in 3 out of 5 Nc-1-infected dams. However, no evidence of foetal death was observed in either Nc-Spain 1H-infected or control groups during the period studied. The most severe histopathological lesions were observed in the placenta and foetal organs from Nc-1-infected cattle that exhibited foetal death. It was in these animals that *N. caninum* DNA was more frequently detected. Parasitaemia was observed in all Nc-1-infected dams and in only 3 out of 5 Nc-Spain 1H-infected animals. The magnitude of the immune response was significantly higher in the Nc-1-inoculated group than in the group inoculated with the Nc-Spain 1H isolate. These data reveal the reduced virulence of the Nc-Spain 1H isolate in cattle.

*Neospora caninum* / low virulence isolate / cattle / foetopathy / Nc-Spain 1H

### 1. INTRODUCTION

*Neospora caninum* is a heteroxenous, cyst-forming coccidian closely related to *Toxoplasma gondii* that has been recognised as a major cause of abortion and reproductive failure in cattle worldwide [15]. Dogs and coyotes have been identified as definitive and intermediate hosts of

the parasite, whereas cattle and other mammals are natural intermediate hosts [14]. The routes of *N. caninum* transmission in cattle include transplacental infection through tachyzoites, from the dam to the foetus during gestation (vertical transmission), and infection by ingestion of sporozoite-containing oocysts shed by a definitive host (horizontal transmission). Exogenous transplacental transmission occurs following primary oocyst-derived infection of dams,

\* Corresponding author: [luis.ortega@vet.ucm.es](mailto:luis.ortega@vet.ucm.es)

while endogenous transplacental transmission occurs following recrudescence of infection in persistently infected cows during pregnancy [33].

The consequences of either primoinfection or recrudescence in a pregnant cow can be abortion, birth of a weak calf or birth of a clinically healthy but persistently infected calf [9, 19]. A key question in understanding the variation in clinical presentation and severity of disease is the influence of the isolate. Biological diversity has been reported among some isolates of *N. caninum* in experimental murine infections [2, 10, 21] and in vitro studies [29, 31]. However, nothing is known about the differences in virulence of *N. caninum* isolates in cattle and how isolates with different virulence in mice may cause different disease outcomes in cattle. Experimental infection in cattle is necessary to confirm the correlations between parasite isolates with different virulence in in vitro and murine models, and clinical signs of disease in the natural host.

Recently, a new isolate of *N. caninum*, named Nc-Spain 1H, was obtained from the brain of a congenitally infected calf. This isolate was less virulent than the Nc-1 isolate in pregnant and non-pregnant mouse models and had a decreased rate of multiplication in in vitro cell culture [30]. Previous experimental studies in cattle have demonstrated that the inoculation of Nc-Liv or Nc-1 tachyzoites at day 70 of gestation induced foetal death [22, 34]. Using this protocol, we examined the ability of Nc-Spain 1H to induce foetal death in cattle. In parallel, different clinical, pathological and parasitological parameters, as well as the immune response induced as a consequence of the infection, were also evaluated and compared to those caused by the reference isolate Nc-1.

## 2. MATERIALS AND METHODS

### 2.1. Animals and experimental design

Thirty-one Holstein Friesian female cattle, aged 16–24 months and seronegative for *N. caninum*, *Leptospira* spp., Infectious Bovine Rhinotracheitis Virus and Bovine Viral Diarrhoea Virus were

selected. These animals were oestrus synchronised using synthetic PGF<sub>2α</sub> analogue (Prosolvín, Intervet, Salamanca, Spain) at 11 days intervals and were artificially inseminated after 3 days on 2 successive days with semen from a *N. caninum*-seronegative bull. Pregnancy was confirmed by ultrasound scanning on days 35 and 57 after insemination and 13 pregnant heifers were selected for the experiment. Animals were maintained in an open housing system with a straw-bedded yard at Complutense University of Madrid, Spain. Cattle were fed concentrates and alfalfa hay twice a day and were allowed free access to fresh water.

Animals were randomly selected and allocated into three experimental groups. Groups 1 and 2 were inoculated intravenously (i.v.) with 10<sup>7</sup> tachyzoites of the Nc-1 and Nc-Spain 1H isolates, respectively, at 70 days of gestation (d.g.). Group 3 received an inoculum of phosphate-buffered saline (PBS) i.v. and was used as a negative control and a sentinel for adventitious infections.

Cattle were observed daily for 45 days post-infection (p.i.). Rectal temperatures were recorded daily from 2 days prior to challenge to 14 days p.i., then twice weekly from 14 days p.i. onward. Animals with temperatures above 39.5 °C were considered to be febrile. Transrectal ultrasonography was used to determine foetal viability. All heifers were monitored once weekly throughout the experimental period. When ultrasound examinations confirmed foetal death, dams were sacrificed by an intravenous overdose of embutramide and mebezonio ioduro (T-61, Intervet). The remaining animals were slaughtered at the end of the experimental period. This experiment was conducted in accordance with guidelines established by the current laws of animal protection in Spain.

### 2.2. Sampling

Blood samples were collected before inoculation and twice weekly thereafter until 41 days p.i. by coccygeal venipuncture in EDTA, plain evacuated and heparinised tubes for DNA extraction, serology and IFN $\gamma$  analysis, respectively. Heifers were necropsied immediately after euthanasia and tissues were recovered aseptically. Brain and placenta from dams and brain, heart and liver from foetuses were placed in 10% formol saline or stored at –80 °C until use for histopathology or PCR analysis, respectively.

### 2.3. Parasites

Tachyzoites from the Nc-1 isolate [13] were propagated under new culture conditions using

MARC-145 cells. This shift from Vero cells to a new cell line was expected to minimise the effect of prolonged maintenance in Vero cells on the biological characteristics of this isolate [5]. Prior to inoculation, Nc-1 and Nc-Spain 1H tachyzoites were propagated in MARC-145 cell monolayers using standard procedures previously described [29]. The experiment was carried out using similar parasite passage numbers in MARC-145 cells for Nc-1 (passage no. 12) and Nc-Spain 1H (passage no. 10). Parasite viability and number were determined by trypan blue exclusion, followed by counting three aliquots in a Neubauer chamber. The infection dose per animal was adjusted to  $10^7$  tachyzoites and diluted in 5 mL of PBS. Parasites were administered to heifers within 1 h of harvesting from tissue culture.

Nc-1 tachyzoites used for DNA extraction and as an antigen in specific IFN $\gamma$  detection and ELISA techniques were washed three times in sterile PBS, pH 7.4). Host cell debris was separated by passing the mixture through a 25-gauge needle, followed by passage through PD-10 columns (Amersham Biosciences, Uppsala, Sweden). Cell-free Nc-1 tachyzoites were pelleted by centrifugation ( $600\times g$ , 10 min) and frozen at  $-80^\circ\text{C}$  until use. To obtain *N. caninum* soluble protein antigen, purified tachyzoites were suspended in 1 mL of 10 mM Tris-HCl containing 2 mM phenylmethylsulfonyl fluoride (Sigma, St. Louis, MO, USA) and disrupted by sonication (Sonifier 450, Branson Ultrasonic, Danbury, CT, USA) in an ice-bath. Cell debris and unlysed cells were removed by centrifugation ( $10\,000\times g$ , 20 min,  $4^\circ\text{C}$ ). The protein concentration of the supernatant was quantified using the Micro BCA protein assay (Pierce, Rockford, IL, USA), then aliquoted and frozen at  $-80^\circ\text{C}$ .

#### 2.4. *N. caninum*-specific IgG response

Blood samples were allowed to clot before centrifugation at  $1500\times g$  for 10 min and the serum was removed, aliquoted and stored at  $-20^\circ\text{C}$  until required. Serum samples were assayed for specific IgG antibodies using an *N. caninum* soluble extract antigen-based ELISA as previously described [1]. Serum samples were diluted 1:100 for testing. The anti-bovine IgG1 and IgG2 monoclonal mAb (Laboratoire Service International, France) was diluted 1:4000. Serum samples were analysed in duplicate and the mean value of the optical density (OD) was converted into a relative index percent (RIPC) using the following formula:  $\text{RIPC} = (\text{OD}_{405} \text{ sample} - \text{OD}_{405} \text{ negative control}) / (\text{OD}_{405} \text{ positive}$

$\text{control} - \text{OD}_{405} \text{ negative control}) \times 100$ . A RIPC value  $\geq 8.2$  indicates a positive result.

#### 2.5. *N. caninum*-specific IFN $\gamma$ responses

Heparinised blood samples were maintained at room temperature and were cultured within 2 h of collection from cattle with 100  $\mu\text{L}$  of PBS (unstimulated control), concanavalin A (10  $\mu\text{g}/\text{mL}$ ; Sigma) to ensure the ability of the cells to respond to stimulation and secrete IFN- $\gamma$ , and with *N. caninum* Nc-1 isolate soluble antigen (1  $\mu\text{g}/\text{mL}$ ), as described previously [16]. In order to assess IFN $\gamma$  production, duplicate plasma samples were tested using a commercial ELISA kit (Bovigam IFN $\gamma$  kit, CSL, Australia) as recommended by the manufacturer and using positive and negative controls provided with the kit. The results are expressed as OD values.

#### 2.6. DNA extraction and PCR

Different samples from the maternal brain, placenta and foetal tissues were randomly selected and pooled. Then, 5–8 g of the pool were homogenised in sterile PBS (dilution 1:2) in a stomacher (“Masticator” IUL, Barcelona, Spain) for 2 to 5 min or minced using a sterile scalpel for placental tissue. Samples were aliquoted in different tubes and frozen at  $-80^\circ\text{C}$ . DNA was extracted using 3–5 different aliquots of 50  $\mu\text{L}$  homogenised tissues or 15 mg of placental tissue samples using Real Pure Genomic DNA Extraction Kit (Durviz, Valencia, Spain) following the manufacturer’s instructions. *N. caninum* DNA was obtained from  $10^7$  tachyzoites. DNA was extracted from 500  $\mu\text{L}$  of EDTA-blood using Real Pure DNA Extraction SSS Kit (Durviz) following the manufacturer’s recommendations. The concentration of DNA was determined by spectrophotometry and adjusted to 50 ng/ $\mu\text{L}$ . A total of 5  $\mu\text{L}$  was used for PCR amplification.

Nested PCR on the internal transcribed spacer region of *N. caninum* was carried out with four oligonucleotides as described by Buxton et al. [8]. A secondary amplification product was visualised by 1.8% agarose gel electrophoresis and ethidium bromide staining. DNA equivalent to  $10^2$  tachyzoites were used as the positive PCR control. To avoid false positive reactions, DNA extraction, PCR sample preparation and electrophoresis were performed in separate rooms employing different sets of instruments, aerosol barrier tips and disposable gloves. Moreover, negative control samples were included in each set of DNA extractions and PCR reactions.

2.7. Histopathological examination

A histopathological study was carried out on different sections from the brain and placenta from dams and brain, heart and liver from foetuses using routine histological methods. Tissues were fixed in 10% neutral buffered formalin and dehydrated through graded alcohols before being embedded in paraffin wax and stained with haematoxylin and eosin. The analysis was based on the observation of lesions according to previous descriptions [3, 28, 37], and lesions were classified as none detected/unrelated (–), consistent with (+), or characteristic of (++) bovine neosporosis.

2.8. Statistical analysis

Rectal temperatures, serology and IFN $\gamma$  data were analysed using the one-way ANOVA test. When statistically significant differences were found, a Duncan Multiple Range test was applied to examine all possible pairwise comparisons. Lesion severity was analysed by the Mann-Whitney *U*-test. A *p*-value of less than 0.05 was considered statistically significant.

3. RESULTS

3.1. Clinical observations

There was no significant increase in the mean temperatures from the different groups in the experiment. However, two animals from group 1 showed sporadic febrile responses at 2, 5, 13, 19 and 31 days p.i. The highest values were observed in one animal at 19 and 31 days p.i. (40.2 °C and 39.9 °C, respectively). In group 2, a febrile response was also observed in two heifers at 2, 5 and 26 days p.i., with 39.6 °C the highest temperature in this group.

Following infection at 70 d.g., foetal death was detected in 3 out of the 5 heifers in group 1 at 26 and 34 days p.i. The rest of the foetuses remained viable until the end of the experiment (Tab. I). Other clinical signs were not observed in any animal of the examined groups.

**Table I.** Detection of parasite DNA and histopathological changes in foetal and maternal tissues of cattle inoculated with Nc-1 (group 1) and Nc-Spain 1H (group 2) or PBS (group 3) at 70 days of gestation.

Group	Foetal death (days p.i.)	Foetal						Maternal			
		Liver		Heart		Brain		Placenta		Brain	
		HP <sup>a</sup>	DNA <sup>b</sup>	HP	DNA	HP	DNA	HP	DNA	HP	DNA
1	34*	++	3/3	++	3/3	+	3/3	++	3/3	+	–
	34*	+	1/3	++	3/3	+	3/3	++	3/3	–	–
	–	+	–	+	–	+	–	–	–	+	–
	–	+	–	+	–	+	–	+	–	–	–
	26*	++	3/3	++	3/3	+	3/3	++	3/3	+	–
2	–	–	–	+	–	+	–	–	–	–	–
	–	–	–	+	–	+	–	+	1/3	–	–
	–	–	–	+	–	+	–	–	–	–	–
	–	–	–	+	–	+	–	–	–	–	–
	–	–	–	+	–	+	–	–	–	–	–
3	–	–	–	–	–	–	–	–	–	–	–
	–	–	–	–	–	–	–	–	–	–	–
	–	–	–	–	–	–	–	–	–	–	–

\* Day p.i. when foetal death was detected by transrectal ultrasonography. The remaining foetuses lived until the end of the experiment.  
<sup>a</sup> Histopathological lesion severity: none detected (–), consistent with (+), and characteristic of (++) *N. caninum* infection.  
<sup>b</sup> Fractions represent number of samples positive by nested PCR/number of samples examined.

3.2. *N. caninum*-specific IgG response

The *N. caninum*-specific antibody response throughout the experiment is shown in Figure 1. In the Nc-1-infected group, the antibody concentration was significantly higher than in the uninfected group from 17 days p.i. onward ( $p < 0.05$ ; one-way ANOVA, Duncan Multiple Range test) and it peaked at 24 and 26 days p.i. In the Nc-Spain 1H-infected group, the antibody level increased from 17 days p.i.; the highest value was detected at 19 days p.i. and decreased afterwards. The values did not vary significantly when compared to the uninfected group ( $p > 0.05$ ; one-way ANOVA, Duncan Multiple Range test). When both infected groups were compared, group 1 had significantly higher antibody levels than group 2 on day 17 p.i. and from 24 days p.i. onward ( $p < 0.05$ ; one-way ANOVA, Duncan Multiple Range test).

3.3. *N. caninum*-specific IFN $\gamma$  response

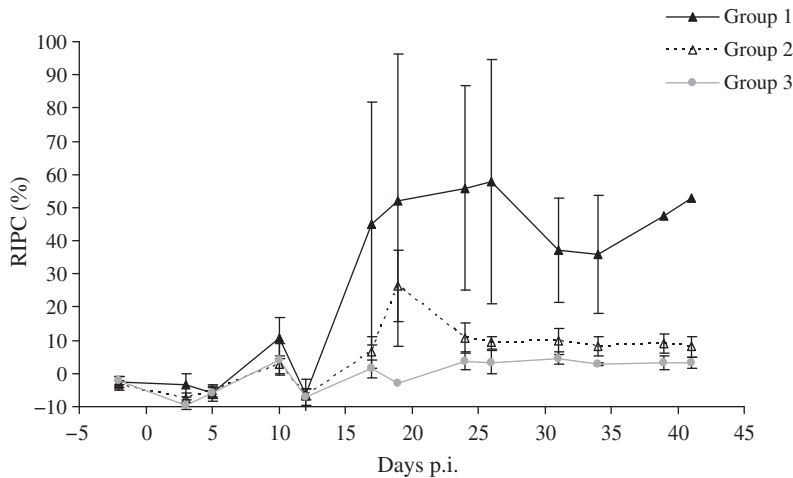
Significant higher levels of IFN $\gamma$  were detected in both infected groups from 5 to 12 days p.i. than in the uninfected group

( $p < 0.05$ ; one-way ANOVA, Duncan Multiple Range test) (Fig. 2). In the Nc-1-infected group, the IFN $\gamma$  levels remained significantly higher than in the uninfected group until the end of the study, with the highest value detected on day 24 p.i. ( $p < 0.05$ ; one-way ANOVA, Duncan Multiple Range test). In the Nc-Spain 1H-infected group, the IFN $\gamma$  values decreased to levels that were not significantly different compared to the uninfected group from day 12 p.i., excluding 19 and 34 days p.i. ( $p < 0.05$ ; Duncan Multiple Range test). When we compared both infected groups, group 1 had significantly higher IFN $\gamma$  levels than group 2 from 10 days p.i. onward ( $p < 0.05$ ; Duncan Multiple Range test), except at 26 days p.i. when these differences were not significant.

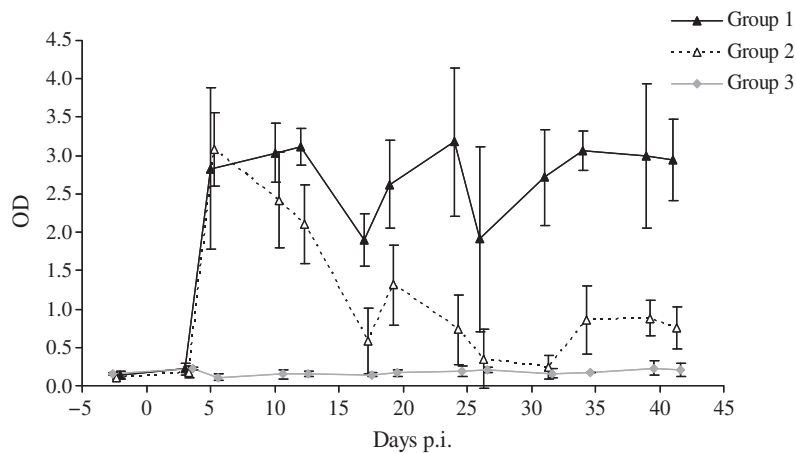
3.4. Detection of *N. caninum* DNA in blood and tissues by PCR

Parasitaemia was detected sporadically in all heifers from group 1 on days 5, 12, 19 and 24 p.i. and in 3 out of 5 heifers from group 2 on days 3, 5, 19 and 41 p.i. (Tab. II).

*N. caninum* DNA was detected in the placenta, foetal brain, heart and liver from animals



**Figure 1.** *N. caninum*-specific IgG responses in the serum of cattle inoculated at 70 days of gestation with Nc-1 (group 1), Nc-Spain 1H (group 2) or PBS (group 3). Data are expressed as mean relative index percent (RIPC) and error bars are the standard deviations for each group. Positive cut-off  $\geq 8.2$  RIPC.



**Figure 2.** *N. caninum*-specific IFN $\gamma$  response in cattle following inoculation at 70 days of gestation with Nc-1 (group 1), Nc-Spain 1H (group 2) or PBS (group 3). Data are expressed as mean optical density (OD) and error bars are the standard deviations for each group.

**Table II.** Detection of *N. caninum* DNA in the blood of animals inoculated at 70 days of gestation with Nc-1 (group 1) and Nc-Spain 1H (group 2).

Days p.i.	Group 1					Group 2				
	1 767	1 785	1 587	1 786	7 848	1 711	1 638	1 563	1 782	1 965
3	–	–	–	–	–	–	–	–	–	+
5	–	–	+	+	–	–	–	–	–	+
10	–	–	–	–	–	–	–	–	–	–
12	–	–	–	–	+	–	–	–	–	–
17	–	–	–	–	–	–	–	–	–	–
19	–	+	–	–	–	–	–	–	+	–
24	+	–	–	–	–	–	–	–	–	–
26	–	–	–	–	–	–	–	–	–	–
31	–	–	–	–	–	–	–	–	–	–
34	–	–	–	–	–	–	–	–	–	–
39	–	–	–	–	–	–	–	–	–	–
41	–	–	–	–	–	+	–	–	–	–

+ *N. caninum* DNA was detected by nested PCR.  
– *N. caninum* DNA was not detected by nested PCR.

that had presented foetal death in group 1. In group 2, parasite DNA was detected in the placenta from only one animal (Tab. I).

3.5. Histopathology

The most significant pathological changes were observed in the placentomes from cattle

in the Nc-1-infected group that presented foetal death (Tab. I). The lesions consisted of multiple foci of non-suppurative inflammatory infiltrates in both maternal and foetal mesenchyme, areas of haemorrhage and necrosis in the caruncular septa, groups of foetal villi with necrosis and cell debris and serum leakage between the maternal and foetal tissues. In contrast, mild



serum leakage in the caruncular septa was observed in only one heifer from the Nc-Spain 1H-infected group that also had detectable *N. caninum* DNA. In the brain, 3 out of 5 heifers from the Nc-1-infected group presented scarce focal perivascular mononuclear inflammatory cell cuffs in the brain. No pathological changes were seen in the tissues of the other animals. When the lesion severity was compared, our findings demonstrated that more severe lesions were observed in the brain and placenta from group 1 than in those from group 2 ( $p < 0.05$  Mann-Whitney  $U$  test).

In the dead foetuses from the Nc-1-infected group, multiple foci of hepatocellular necrosis in the liver and lymphocytic myocarditis in heart were observed (Tab. I). The remaining foetuses from both infected groups presented a mild diffuse inflammatory infiltrate of mononuclear cells in the heart. Focal lesions consisting of perivascular cuffing of mononuclear cells and glial nodules were observed in all foetal brain tissue from both infected groups. When lesion severity was compared, more severe lesions were observed in the foetal liver and heart tissues from group 1 than in those from group 2, but the differences were significant only for the liver ( $p < 0.05$  Mann-Whitney  $U$  test).

#### 4. DISCUSSION

This study highlights the relevance of the *N. caninum* isolate virulence on the outcome of infection in cattle. For the first time, inoculation of cattle with two different isolates revealed differences in clinical, immunological and pathological responses. We examined the pathogenic effects of infection with Nc-Spain 1H early in gestation, using a pregnant bovine model in which i.v. inoculation of  $10^7$  tachyzoites of Nc-Liverpool at 70 d.g. results in foetopathy between 3 and 5 weeks after infection, as previously described [17, 34–36]. Foetal mortality was also reported between 28 and 56 days p.i. in all the animals i.v. inoculated with  $5 \times 10^8$  Nc-1 tachyzoites at 70 d.g. [22]. In the present study, we observed that Nc-Spain 1H did not have the ability to induce foetal

death in pregnant cattle whereas Nc-1 caused death in 3 out of 5 foetuses between 26 and 34 days p.i.

We monitored the experiment for 45 days after infection. This time appears to be long enough to evaluate foetal mortality since foetal death occurred earlier than 6 weeks p.i. with Nc-Liverpool and Nc-1 isolates [22, 34, 35]. In fact, Macaldowie et al. [22] studied the pathogenesis of *Neospora* infection at 70 d.g. and found that at 42 and 56 days p.i. the uterus from i.v. Nc-1-inoculated dams was empty, caruncles were reduced in size and the uterine epithelium had been largely restored, suggesting that foetal death occurred earlier than 42 days p.i. In contrast to the previous results, we did not detect 100% foetal mortality in the Nc-1-infected group and a febrile response was not induced after i.v. inoculation of both *N. caninum* isolates [18, 22]. These differences could be due to the inoculum size used in our study, which was lower than in previous studies with the Nc-1 isolate ( $10^7$  instead of  $5 \times 10^8$  tachyzoites) [18, 22]. Moreover, different temperature responses have been associated with the dose of parasite inoculum [23, 24].

In a previous study, Nc-Spain 1H showed a low tachyzoite yield and viability rate in vitro. Additionally, it appeared to be a low virulence isolate in mice since it failed to induce clinical signs or mortality in a non-pregnant mouse model and led to a low transplacental transmission and neonatal mortality rate in a pregnant mouse model [30]. The low rate of multiplication of Nc-Spain 1H tachyzoites might imply a low level of parasitaemia and a low risk of placental infection. Here, parasitaemia was observed in all Nc-1- and in 3 of 5 Nc-Spain 1H-infected animals, indicating that the circulation of parasites occurred in both infected groups. The differences in the frequency of detection may be related to the isolate characteristics. However, parasitaemia was sporadically found in both groups, presumably because of small parasite numbers or short periods of detectable parasitaemia, as others have described before [22, 24, 32], making variations between groups difficult to assess.

We observed significant differences in the pathological effects of infection depending



on the isolate inoculated. The most severe lesions were observed in the placenta from Nc-1-infected animals which showed foetal death. Additionally, parasite DNA was detected in placental samples from these animals. The lesions were similar to those reported in previous experimental studies [22, 25] and may have been critical in the foetal death observed in our study. On the contrary, only one heifer from the Nc-Spain 1H-infected group presented mild lesions and a reduced *N. caninum* DNA presence, indicating that a low parasite number reached the placenta. In the foetuses, lesions were more severe in the Nc-1-infected group than in the Nc-Spain 1H-infected group, with a significant difference observed in the liver. Previous reports suggest hepatocellular necrosis would be observed when the infection occurs with a high dose of parasites, for instance in foetuses aborted during epidemic episodes of neosporosis [37]. The severe pathological changes observed in not only the liver, but also in the heart and brain from the Nc-1-infected group, simultaneously with the presence of the parasite DNA in tissues, suggest an uncontrolled spread and multiplication of the parasite that could directly lead to death. On the contrary, slight lesions and no parasite DNA were observed in the Nc-Spain 1H-infected group, which could indicate a controlled infection that did not progress to a fatal outcome.

The immunological response provides evidence of exposure to infection, since all infected animals developed *N. caninum*-specific responses after parasite inoculation. Antibody levels increased from 17 days p.i. in both infected groups, following a similar pattern to those observed in several experimental infections [4, 18, 34, 35] but the magnitude of the parasite-specific IgG response in the Nc-Spain 1H-infected group was less than the response in the Nc-1-infected group. Similarly, parasite infection induced high levels of IFN $\gamma$  production in both infected groups, suggesting that the maternal immune cell-mediated response was actively responding to the parasite. However, *N. caninum*-specific IgG and IFN $\gamma$  values in the Nc-Spain 1H-infected group declined to similar levels to those observed in the uninfected group, whereas levels in the

Nc-1-infected group remained high until the end of the experiment. This may be associated with the reduction, or absence, of a repeated antigenic stimulus and suggests a transient infection similar to experimental infections in sheep with the avirulent S48 *T. gondii* tachyzoites, in which a decline in detectable antibody from six weeks after infection suggested a short-lived infection [6]. It is unknown if the immune response developed in Nc-Spain 1H-infected animals was able to reduce parasite burden, limiting the tissue damage or if the low capacity of the isolate to multiply in host tissues may be associated with the reduction or absence of repeated antigenic stimulus. Further studies in order to comprehensively assess the variations in the immune response in cattle depending on the inoculated isolate are required.

Several recent papers have suggested that the mode of transmission (horizontal or vertical) could influence the infection [11, 12, 26]. There is evidence that variation in infection transmission exists in the field and parasite virulence could help to explain some of the epidemiological and clinical patterns of bovine neosporosis. When the parasite is transmitted from the dam to the offspring, a low virulence could be selected in order to preserve the success of transmission. Therefore, a correlation between low virulence and vertical transmission could be established. When the parasite exploits two hosts in succession in a predator-prey system, virulence may be beneficial, since the goal of the parasite is to kill the host and to increase the chances of ingestion and infection of the second host.

This study reports the characterisation of a naturally attenuated bovine *N. caninum* isolate in an experimental bovine model. The present results, together with those previously obtained in a pregnant mouse model [30], in which Nc-Spain 1H induced a low vertical transmission rate (5%) in comparison with the high transplacental transmission induced by Nc-1 isolate (92.8%), demonstrate that Nc-Spain 1H appears to be a low virulence isolate. Therefore, Nc-Spain 1H may be a suitable candidate for live vaccine development, similar to the approach that has been successful in developing a live (S48) *T. gondii* vaccine used

to prevent toxoplasmosis in farm livestock [7]. Another naturally attenuated isolate of *N. caninum*, Nc-Nowra, was previously selected as a potential vaccination candidate and was tested in an experimental mouse model [27] and pregnant bovine model [36]. Nc-Nowra induced a reduction in transplacental transmission and protected against foetal death, respectively. Furthermore, the Nc-Spain 1H isolate may be a safe candidate since its inoculation in early gestation does not produce foetal death. This information appears to be essential in the development of live parasite vaccines since a major drawback of such vaccines is safety concerns [15, 20]. In this sense, the administration prior to pregnancy, as suggest Williams et al. [36] with the Nc-Nowra isolate, and by another via administration (subcutaneous or intramuscular) could be a safe option for the Nc-Spain 1H live vaccine. Nevertheless, further studies are necessary to evaluate the protection induced by this attenuated isolate against abortion and congenital transmission of *N. caninum* infection.

**Acknowledgements.** We would like to thank Vanesa Navarro and Alberto Benito for their excellent technical assistance and Ricardo García de la Mata for statistical advice. We are grateful to Gorka Aduriz, (Instituto Vasco de Investigación y Desarrollo, NEIKER) for his collaboration in this study. This work was supported by a PETRI 95-0777.OP project from the Ministerio de Educación y Ciencia and Laboratorios Hipra S.A. and was part of the E.U. research collaboration COST-854. S. Rojo-Montejo was financed by PETRI 95-0777.OP.

## REFERENCES

- [1] Alvarez-Garcia G., Collantes-Fernandez E., Costas E., Rebordosa X., Ortega-Mora L.M., Influence of age and purpose for testing on the cut-off selection of serological methods in bovine neosporosis, *Vet. Res.* (2003) 34:341–352.
- [2] Atkinson R., Harper P.A., Ryce C., Morrison D.A., Ellis J.T., Comparison of the biological characteristics of two isolates of *Neospora caninum*, *Parasitology* (1999) 118:363–370.
- [3] Barr B.C., Conrad P.A., Dubey J.P., Anderson M.L., *Neospora*-like encephalomyelitis in a calf: pathology, ultrastructure, and immunoreactivity, *J. Vet. Diagn. Invest.* (1991) 3:39–46.
- [4] Bartley P.M., Kirvar E., Wright S., Swales C., Esteban-Redondo I., Buxton D., et al., Maternal and fetal immune responses of cattle inoculated with *Neospora caninum* at mid-gestation, *J. Comp. Pathol.* (2004) 130:81–91.
- [5] Bartley P.M., Wright S., Sales J., Chianini F., Buxton D., Innes E.A., Long-term passage of tachyzoites in tissue culture can attenuate virulence of *Neospora caninum* in vivo, *Parasitology* (2006) 133:421–432.
- [6] Buxton D., Thomson K., Maley S., Wright S., Bos H.J., Vaccination of sheep with a live incomplete strain (S48) of *Toxoplasma gondii* and their immunity to challenge when pregnant, *Vet. Rec.* (1991) 129:89–93.
- [7] Buxton D., Innes E.A., A commercial vaccine for ovine toxoplasmosis, *Parasitology* (1995) 110:S11–S16.
- [8] Buxton D., Maley S.W., Wright S., Thomson K.M., Rae A.G., Innes E.A., The pathogenesis of experimental neosporosis in pregnant sheep, *J. Comp. Pathol.* (1998) 118:267–279.
- [9] Buxton D., McAllister M.M., Dubey J.P., The comparative pathogenesis of neosporosis, *Trends Parasitol.* (2002) 18:546–552.
- [10] Collantes-Fernandez E., Lopez-Perez I., Varez-Garcia G., Ortega-Mora L.M., Temporal distribution and parasite load kinetics in blood and tissues during *Neospora caninum* infection in mice, *Infect. Immun.* (2006) 74:2491–2494.
- [11] Collantes-Fernandez E., Arnaiz-Seco I., Burgos B.M., Rodriguez-Bertos A., Aduriz G., Fernandez-Garcia A., Ortega-Mora L.M., Comparison of *Neospora caninum* distribution, parasite loads and lesions between epidemic and endemic bovine abortion cases, *Vet. Parasitol.* (2006) 142:187–191.
- [12] Dijkstra T., Lam T.J., Bartels C.J., Eysker M., Wouda W., Natural postnatal *Neospora caninum* infection in cattle can persist and lead to endogenous transplacental infection, *Vet. Parasitol.* (2008) 152:220–225.
- [13] Dubey J.P., Hattel A.L., Lindsay D.S., Topper M.J., Neonatal *Neospora caninum* infection in dogs: isolation of the causative agent and experimental transmission, *J. Am. Vet. Med. Assoc.* (1988) 193:1259–1263.
- [14] Dubey J.P., Buxton D., Wouda W., Pathogenesis of bovine neosporosis, *J. Comp. Pathol.* (2006) 134:267–289.
- [15] Dubey J.P., Schares G., Ortega-Mora L.M., Epidemiology and control of neosporosis and *Neospora caninum*, *Clin. Microbiol. Rev.* (2007) 20:323–367.
- [16] Ferre I., Aduriz G., del Pozo I., Regidor-Cerrillo J., Atxaerandio R., Collantes-Fernandez E., et al.,

Detection of *Neospora caninum* in the semen and blood of naturally infected bulls, *Theriogenology* (2005) 63:1504–1518.

[17] Gibney E.H., Kipar A., Rosbottom A., Guy C.S., Smith R.F., Hetzel U., et al., The extent of parasite-associated necrosis in the placenta and foetal tissues of cattle following *Neospora caninum* infection in early and late gestation correlates with foetal death, *Int. J. Parasitol.* (2007) 38:579–588.

[18] Innes E.A., Wright S.E., Maley S., Rae A., Schock A., Kirvar E., et al., Protection against vertical transmission in bovine neosporosis, *Int. J. Parasitol.* (2001) 31:1523–1534.

[19] Innes E.A., Andrianarivo A.G., Bjorkman C., Williams D.J., Conrad P.A., Immune responses to *Neospora caninum* and prospects for vaccination, *Trends Parasitol.* (2002) 18:497–504.

[20] Innes E.A., Vermeulen A.N., Vaccination as a control strategy against the coccidial parasites *Eimeria*, *Toxoplasma* and *Neospora*, *Parasitology* (2006) 133:S145–S168.

[21] Lindsay D.S., Lenz S.D., Cole R.A., Dubey J.P., Blagburn B.L., Mouse model for central nervous system *Neospora caninum* infections, *J. Parasitol.* (1995) 81:313–315.

[22] Macaldowie C., Maley S.W., Wright S., Bartley P., Esteban-Redondo I., Buxton D., Innes E.A., Placental pathology associated with fetal death in cattle inoculated with *Neospora caninum* by two different routes in early pregnancy, *J. Comp. Pathol.* (2004) 131:142–156.

[23] Maley S.W., Buxton D., Thomson K.M., Schrieffer C.E., Innes E.A., Serological analysis of calves experimentally infected with *Neospora caninum*: a 1-year study, *Vet. Parasitol.* (2001) 96:1–9.

[24] Maley S.W., Buxton D., Rae A.G., Wright S.E., Schock A., Bartley P.M., et al., The pathogenesis of neosporosis in pregnant cattle: inoculation at mid-gestation, *J. Comp. Pathol.* (2003) 129:186–195.

[25] Maley S.W., Buxton D., Macaldowie C.N., Anderson I.E., Wright S.E., Bartley P.M., et al., Characterization of the Immune Response in the Placenta of Cattle Experimentally Infected with *Neospora caninum* in Early Gestation, *J. Comp. Pathol.* (2006) 135:130–141.

[26] McCann C.M., McAllister M.M., Gondim L.F., Smith R.F., Cripps P.J., Kipar A., et al., *Neospora caninum* in cattle: Experimental infection with oocysts can result in exogenous transplacental infection, but not endogenous transplacental infection in the subsequent pregnancy, *Int. J. Parasitol.* (2007) 37:1631–1639.

[27] Miller C., Quinn H., Ryce C., Reichel M.P., Ellis J.T., Reduction in transplacental transmission of

*Neospora caninum* in outbred mice by vaccination, *Int. J. Parasitol.* (2005) 35:821–828.

[28] Pereira-Bueno J., Quintanilla-Gozalo A., Perez-Perez V., Espi-Felgueroso A., Alvarez-Garcia G., Collantes-Fernandez E., Ortega-Mora L.M., Evaluation by different diagnostic techniques of bovine abortion associated with *Neospora caninum* in Spain, *Vet. Parasitol.* (2003) 111:143–152.

[29] Perez-Zaballos F.J., Ortega-Mora L.M., Varez-Garcia G., Collantes-Fernandez E., Navarro-Lozano V., Garcia-Villada L., Costas E., Adaptation of *Neospora caninum* isolates to cell-culture changes: an argument in favor of its clonal population structure, *J. Parasitol.* (2005) 91:507–510.

[30] Rojo-Montejo S., Collantes-Fernandez E., Regidor-Cerrillo J., Alvarez-Garcia G., Marugan-Hernandez V., Pedraza-Diaz S., et al., Isolation and characterization of a bovine isolate of *Neospora caninum* with low virulence, *Vet. Parasitol.* (2009) 159:7–16.

[31] Schock A., Innes E.A., Yamane I., Latham S.M., Wastling J.M., Genetic and biological diversity among isolates of *Neospora caninum*, *Parasitology* (2001) 123:13–23.

[32] Serrano E., Ferre I., Osoro K., Aduriz G., Mateos-Sanz A., Martinez A., et al., Intrauterine *Neospora caninum* inoculation of heifers, *Vet. Parasitol.* (2006) 135:197–203.

[33] Trees A.J., Williams D.J.L., Endogenous and exogenous transplacental infection in *Neospora caninum* and *Toxoplasma gondii*, *Trends Parasitol.* (2005) 21:558–561.

[34] Williams D.J., Guy C.S., McGarry J.W., Guy F., Tasker L., Smith R.F., et al., *Neospora caninum*-associated abortion in cattle: the time of experimentally-induced parasitaemia during gestation determines foetal survival, *Parasitology* (2000) 121:347–358.

[35] Williams D.J., Guy C.S., Smith R.F., Guy F., McGarry J.W., McKay J.S., Trees A.J., First demonstration of protective immunity against foetopathy in cattle with latent *Neospora caninum* infection, *Int. J. Parasitol.* (2003) 33:1059–1065.

[36] Williams D.J., Guy C.S., Smith R.F., Ellis J., Bjorkman C., Reichel M.P., Trees A.J., Immunization of cattle with live tachyzoites of *Neospora caninum* confers protection against fetal death, *Infect. Immun.* (2007) 75:1343–1348.

[37] Wouda W., Moen A.R., Visser I.J., van Knapen F., Bovine fetal neosporosis: a comparison of epizootic and sporadic abortion cases and different age classes with regard to lesion severity and immunohistochemical identification of organisms in brain, heart, and liver, *J. Vet. Diagn. Invest.* (1997) 9:180–185.