



HAL
open science

Exacerbation of *Chlamydophila psittaci* pathogenicity in turkeys superinfected by *Escherichia coli*

Marnix van Loock, Karolien Loots, Marjolein van Heerden, Daisy Vanrompay,
Bruno Maria Goddeeris

► To cite this version:

Marnix van Loock, Karolien Loots, Marjolein van Heerden, Daisy Vanrompay, Bruno Maria Goddeeris. Exacerbation of *Chlamydophila psittaci* pathogenicity in turkeys superinfected by *Escherichia coli*. *Veterinary Research*, 2006, 37 (6), pp.745-755. 10.1051/vetres:2006033 . hal-00903055

HAL Id: hal-00903055

<https://hal.science/hal-00903055>

Submitted on 11 May 2020

HAL is a multi-disciplinary open access archive for the deposit and dissemination of scientific research documents, whether they are published or not. The documents may come from teaching and research institutions in France or abroad, or from public or private research centers.

L'archive ouverte pluridisciplinaire **HAL**, est destinée au dépôt et à la diffusion de documents scientifiques de niveau recherche, publiés ou non, émanant des établissements d'enseignement et de recherche français ou étrangers, des laboratoires publics ou privés.

Exacerbation of *Chlamydophila psittaci* pathogenicity in turkeys superinfected by *Escherichia coli*

Marnix VAN LOOCK^a, Karolien LOOTS^a, Marjolein VAN HEERDEN^b,
Daisy VANROMPAY^c, Bruno Maria GODDEERIS^{a,d*}

^a Department of Biosystems, Division of Gene Technology, Catholic University of Leuven, Kasteelpark Arenberg 30, 3001 Leuven, Belgium

^b Department of Pathology, Bacteriology and Poultry Disease, Ghent University, Salisburylaan 133, 9820 Merelbeke, Belgium

^c Department of Molecular Biotechnology, Ghent University, Coupure Links 653, 9000 Gent, Belgium

^d Department of Virology, Parasitology, Immunology, Salisburylaan 133, 9820 Merelbeke, Belgium

(Received 4 September 2005; accepted 10 April 2006)

Abstract – Both *Chlamydophila psittaci* and *Escherichia coli* infections are highly prevalent in Belgian turkeys and therefore they both might contribute to the respiratory disease complex observed in turkeys. *C. psittaci* can infect turkeys within the first week of age, even in the presence of maternal antibodies. However, the first *C. psittaci* outbreaks occur mostly at the age of 3 to 6 weeks, the period when also *E. coli* infections appear on the farms. Therefore, we examined in this study the pathogenicity of an *E. coli* superinfection on *C. psittaci* predisposed turkeys. Turkeys were infected with *C. psittaci*, *E. coli* or with *C. psittaci* followed by *E. coli*. Simulating the impact of an *E. coli* infection during the acute phase or the latent phase of a *C. psittaci* infection, turkeys received *E. coli* at 1 or 5 weeks post *C. psittaci* infection, respectively. *E. coli* superinfection during the acute phase of *C. psittaci* infection increased *C. psittaci* excretion and stimulated chlamydial replication in the respiratory tract resulting in exacerbated clinical disease. Interestingly, *E. coli* superinfection during the latent phase of *C. psittaci* infection induced chlamydial replication, leading to increased *C. psittaci*-specific antibody titres. In addition, chlamydial predisposition gave higher *E. coli* excretion compared with turkeys that had only been infected with *E. coli*. Overall, the present study clearly demonstrates the pathogenic interplay between *C. psittaci* and *E. coli* resulting in more severe respiratory disease.

Chlamydophila psittaci / *Escherichia coli* / turkeys

1. INTRODUCTION

Worldwide, turkey production suffers from the negative economical impact of respiratory disease. Nearly all turkey flocks experience one to multiple periods of respiratory disease leading to expensive med-

ical treatment in preventing mortality, loss of weight and carcass condemnation at slaughter [2, 6]. In Europe, influenza virus type A, avian paramyxovirus 1, 2 and 3 (PMV-1, PMV-2, PMV-3), avian pneumovirus (APV), *Ornithobacterium rhinotracheale* (ORT), *Mycoplasma* sp. and *Chlamydophila psittaci* are currently regarded as the major pathogens associated

* Corresponding author:

Bruno.Goddeeris@biw.kuleuven.be

with respiratory disease [4, 7, 8, 12, 19, 25]. At present, *C. psittaci* is commonly found in Belgian, German and probably French turkeys¹ [22, 28]. Devastating outbreaks with high mortality rates, similar to those between 1950 and 1970 in the USA occur occasionally, but respiratory signs without mortality mostly characterise present outbreaks (reviewed in [1]). Nevertheless, *C. psittaci* causes important economical losses and is a threat to public health since this zoonotic agent is able to infect poultry workers [5, 10, 15].

E. coli strains colonise the intestinal tract and protect the host against other pathogenic bacteria, but some strains induce respiratory disease in poultry [4]. The avian pathogenic *E. coli* (APEC) strains mostly isolated from broilers cause airsacculitis, pericarditis, peritonitis and necrotic foci in the liver [23]. APEC infections in broilers are mostly observed between 4 and 9 weeks of age and result in extensive economical losses [4]. In Belgium (1997–2000), APEC infections have an incidence of 17.7% in randomly selected broilers [24]. Nevertheless, APEC infections play only a complicating role, requiring predisposing environmental or host factors. Several researchers have demonstrated the exacerbation of respiratory disease in avian pneumovirus-, *Bordetella avium*- and *Mycoplasma meleagridis*-infected turkeys by an *E. coli* superinfection² [9, 14, 17, 18, 20].

C. psittaci is highly prevalent in Belgian turkeys and although the *E. coli* pres-

¹ Hafez H.M., Sting R., Jodas S. et al., *Chlamydia psittaci* infections in meat turkey: investigations on the interaction with other avian infectious agents, in: Hafez H.M., Mazaheri A. (Eds.), Proc. 1st International Symposium on Turkey Diseases, Berlin, 1998, pp. 208–217.

² Droual R., Chin R., Interaction of *Ornithobacterium rhinotracheale* and *Escherichia coli* O78 H9 when inoculated in the air sac in turkey poults, in: Proc. 46th Western Poultry Disease Conference, Sacramento, 1997, pp. 11.

ence has not been intensively examined, occasional outbreaks with mortality do occur³. Thus, *E. coli* as well as *C. psittaci* may contribute to the turkey respiratory disease complex. *C. psittaci* can infect turkeys within the first week of age, even in the presence of maternal antibodies [28]. However, the first *C. psittaci* outbreaks in turkeys mostly occur at the age of 4 to 8 weeks, a period when also *E. coli* may appear. The present study tries to contribute to the elucidation of the turkey respiratory disease complex by examining the role of *E. coli* as a possible complicating factor during the acute and latent phase of a *C. psittaci* infection in experimentally infected specific pathogen-free (SPF) turkeys.

2. MATERIALS AND METHODS

2.1. *Chlamydophila psittaci* strain 92/1293

In the present study, *C. psittaci* genotype D strain 92/1293, isolated from a pooled homogenate of the lungs, cloacae and spleen of diseased Dutch broiler turkeys was used [25].

2.2. *E. coli* strain O2:K1

E. coli strain O2:K1 was kindly provided by H. Nauwynck (Department of Virology, Parasitology and Immunology, Faculty of Veterinary Medicine, Ghent University, Belgium). The strain was isolated during a colibacillosis outbreak on a Belgian turkey farm [19].

2.3. Experimental design

The experimental design was evaluated and approved by the Ethical Commission for Animal Experiments of K.U.

³ Van de Zande S., personal communication.

Table I. Experimental design.

	Group	<i>C. psittaci</i> infection	<i>E. coli</i> infection
	1	Week 1	Week 2
Acute <i>C. psittaci</i> infection	2	/	Week 2
	3	Week 1	/
	4	/	/
	5	Week 1	Week 6
Latent <i>C. psittaci</i> infection	6	/	Week 6
	7	Week 1	/
	8	/	/

Leuven. The experimental design, simulating an *E. coli* superinfection during the acute phase (diseased turkeys, one week post infection) or latent phase (non-diseased turkeys, 5 weeks post infection) of a *C. psittaci* infection is presented in Table I. One-day-old turkeys (AFSSA, Ploufragan, France), claimed to be SPF, were divided into 8 groups of 13 turkeys. Turkeys were raised in negative pressure isolation units on wired floors (Montair, Sevenum, The Netherlands). At one week of age, groups 1, 3, 5 and 7 were aerosol-infected (Cirrus™ Nebulizer) with 10^4 tissue-culture-infective-doses₅₀ (TCID₅₀) per mL of *C. psittaci* genotype D strain 92/1293. Subsequently, groups 1 and 2 and groups 5 and 6 were oculo-nasally infected with 2.5×10^8 colony forming units (CFU) of *E. coli* strain O2:K1 at 1 and 5 weeks post *C. psittaci* infection, respectively. Groups 3 and 7 served as *C. psittaci*-infected, *E. coli* non-infected controls. Groups 2 and 6 only received *E. coli* at the ages of 2 and 6 weeks, respectively and served as *E. coli*-infected, *C. psittaci* non-infected controls. Groups 4 and 8 served as non-infected controls. In all groups, two turkeys were sacrificed at 3, 5, 7 and 10 days post *E. coli* infection. The remaining five turkeys of each group were sacrificed at 12 days post *E. coli* infection.

2.4. Samples

Turkeys were daily observed and clinical signs were scored as follows: score 0 = no clinical signs, score 1 = conjunctivitis, score 2 = score 1 + rhinitis, score 3 = score 2 + dyspnoea. Pharyngeal *C. psittaci* and *E. coli* excretion were monitored weekly and at 3, 5, 7, 10 and 12 days post *E. coli* infection. The samples were collected with cotton-tipped aluminium shafted swabs (Fiers, Kuurne, Belgium) in 2 mL complete *C. psittaci* transport medium [22]. Swabs were stored at -80°C until tested.

Blood samples were collected by venipuncture (*v. ulnaris*) for the determination of *C. psittaci* major outer membrane protein (MOMP)-specific antibody titres immediately prior to *C. psittaci* infection and subsequently on a weekly basis. *E. coli* antibodies were not monitored due to the lack of an antibody detection test specific for avian pathogenic *E. coli* (APEC). Blood samples were stored overnight at room temperature, centrifuged (325 g, 10 min, 4°C) and serum was collected and frozen at -20°C until being tested.

The turkeys were examined for macroscopic lesions at autopsy. The samples of lungs and thoracic- and abdominal airsacs were stored at -70°C for *E. coli* isolation, or fixed in 10% phosphate buffered formalin for histopathological examination, or imbedded in methocel and snap frozen in liquid nitrogen to assess the presence of *C. psittaci* by immunofluorescence staining.

2.5. *C. psittaci* isolation

Pharyngeal swabs were examined for the presence of *C. psittaci* by isolation in Buffalo Green Monkey (BGM) cells and IMAGEN™ direct immunofluorescence (DakoCytomation, Denmark), as previously described [26]. Chlamydia-positive cells were scored between 0 and

5: score 0 indicated no chlamydiae-positive cells present; score 1 was given when a mean of 1 to 5 elementary bodies was present per slide; score 2 was given when a mean of 6 to 10 elementary bodies was present; scores 3, 4 and 5 were given when a mean of 1–5, 6–10 and >10 inclusion-positive cells, respectively were present.

2.6. Indirect immunofluorescence staining of *C. psittaci* in lungs and airsacs

The lungs and thoracic airsacs were analysed for the presence of *C. psittaci* MOMP by in situ immunohistochemical staining. Cryostat sections (10 µm) were examined by indirect immunofluorescence using a monoclonal antibody (MAb) directed against a family-specific epitope of the *C. psittaci* MOMP. Briefly, all dilutions were made in PBS (pH 7.3). Acetone-fixed cryostat tissue sections were washed in PBS for 5 min. The slides were incubated with 25 µL undiluted chlamydiae-negative goat serum for 1 h at 37 °C. Subsequently, the slides were washed in PBS (2 × 5 min) and incubated for 45 min at 37 °C with 25 µL of the diluted family-specific MAb (1:200). The sections were washed in PBS (2 × 5 min) and incubated for 30 min at 37 °C with 25 µL of 1:30 diluted goat anti-mouse immunoglobulins labelled with fluorescein isothiocyanate (FITC; DakoCytomation, Denmark). Finally, the slides were washed in PBS (2 × 5 min) and in distilled water (2 × 30 s) and analysed with a fluorescence microscope (Leitz, Wetzlar, Germany). Our attention was especially focussed on the presence of inclusions demonstrating active *C. psittaci* replication versus elementary bodies in the absence of inclusions indicating that replication no longer occurred. The results were scored as mentioned for the isolation in BGM cells. Staining controls consisted of

sections from non-infected SPF turkeys as well as from *C. psittaci* positive SPF turkeys from previous experiments [30].

2.7. *C. psittaci* antibody response

The enzyme-linked immunosorbent assay (ELISA) using recombinant MOMP was performed on turkey sera as previously described [29]. Anti-MOMP immunoglobulin titres were presented as the reciprocal of the highest serum dilution that gave an optical density (OD₄₅₀) above the cut-off value. The cut-off value was the mean absorbance of three seronegative turkeys ± three times the standard deviation (SD). Negative control sera were obtained from one-week-old SPF turkeys (AFSSA, Ploufragan, France). Positive control sera originated from experimentally infected SPF turkeys of previous experiments [30].

2.8. *E. coli* isolation

Pharyngeal swabs were shaken at 4 °C for 1 h and centrifuged (10 min, 2790 g, 4 °C). Tissue suspensions of lungs and airsacs (10%, w/v) were centrifuged (200 g, 20 min) and subsequently used for bacterial quantification. The presence of *E. coli* in pharyngeal excretions or tissues was determined by incubating ten-fold serial dilutions of pharyngeal swab supernatant on MacConkey agar (OXOID, Great-Britain). Dark red/purple colonies with typical *E. coli* morphology were counted and titres were expressed as log₁₀ CFU/g mucus.

The *E. coli* O-serotype was determined by sero-agglutination. Individual colonies were inoculated in 4 mL Luria-Bertani medium and grown overnight at 37 °C in a shaking incubator. Subsequently, *E. coli* were centrifuged (5000 g, 10 min, room temperature) and re-suspended in 1 mL sterile PBS (pH 7.3). Twenty-five microlitres of this suspension were incubated

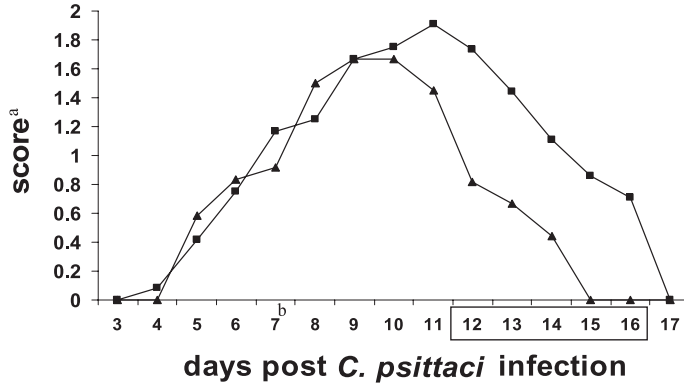


Figure 1. Mean score for clinical signs during the acute phase of a *C. psittaci* infection for the dual infected turkeys (group 1, ■) and the single *C. psittaci* infected turkeys (group 3, ▲). ^a Score 0 = no clinical signs, score 1 = conjunctivitis, score 2 = score 1 + rhinitis, score 3 = score 2 + dyspnoea. ^b Day of *E. coli* infection. Days on which clinical signs are significantly different between the two groups are boxed.

with 25 μ L of O1, O2 and O78 *E. coli* antisera in a 96 well agglutination test plate for 1 h at room temperature and subsequently for 24 to 48 h at 4 °C.

2.9. Histopathology

Formalin-fixed samples were dehydrated, embedded in paraffin and 5 μ m sections were obtained. The sections were stained with hematoxylin-eosin and Periodic Acid Schiff.

2.10. Statistics

All statistical analyses were performed using the SAS software, version 8.2 (the SAS Institute, Cary, NC, USA). Due to non-normalised distribution of chlamydial excretion scores, the Kruskal-Wallis analysis was used to determine differences. Antibody titres in the serum were analysed using Proc GLM (multiple two-tailed *t*-test). $P \leq 0.05$ was considered significant.

3. RESULTS

3.1. Clinical signs and gross lesions

Non-infected turkeys (groups 4 and 8) and *E. coli* infected, *C. psittaci* non-infected turkeys (groups 2 and 6), remained free of any clinical signs of respiratory disease throughout the experiment. Moreover, these animals were free of any gross lesion on post mortem examination performed in week 4 or 8.

First clinical signs appeared in the *C. psittaci*-infected turkeys (groups 1 and 3, as well as 5 and 7) at 4 to 5 days post-infection (Fig. 1). Eight days post-infection, all *C. psittaci*-infected animals were clinically affected, showing conjunctivitis, rhinitis and/or dyspnoea. In the absence of *E. coli* superinfection these clinical signs stabilised and disappeared by day 14 to 16 post *C. psittaci*-infection (groups 3, 5 and 7). In contrast, more severe clinical signs were observed from days 12 to 16 post *C. psittaci*-infection ($\alpha = 0.05$) in *C. psittaci* infected, *E. coli* superinfected turkeys and were completely resolved by day 17 (Fig. 1).

Table II. Pharyngeal *C. psittaci* excretion during the acute phase of *C. psittaci* infection.

dpe ^a	Mean scores of pharyngeal <i>C. psittaci</i> shedding \pm standard deviation (% positive turkeys)					
	0	3	5	7	10	12
group 1	2.4 \pm 0.89 ^c (100)	2.4 \pm 0.89 (100)	2 \pm 0.71 (100)	2 \pm 1.22 (80)	1.4 \pm 1.14 (80)	0.4 \pm 0.55 (40)
group 3 ^b	2.2 \pm 0.84 (100)	1.8 \pm 1.1 (100)	1.8 \pm 0.84 (100)	1.4 \pm 0.55 (100)	0.6 \pm 0.89 (40)	0.2 \pm 0.45 (20)

^a dpe: days post *E. coli* infection. ^b Group 3 only received *C. psittaci*. ^c Score 0: no chlamydiae present; score 1: a mean of 1–5 positive cells, containing *C. psittaci* elementary bodies, per slide; score 2: a mean of 6–10 positive cells, containing elementary bodies; scores 3, 4 and 5: a mean of 1–5, 6–10 and > 10 positive cells inclusion respectively.

During the acute phase of *C. psittaci* infection, no marked differences in macroscopic lesions could be detected between the *C. psittaci* infected turkeys (group 3) and the *E. coli* superinfected turkeys (group 1); all those turkeys, sacrificed between 3 and 10 days post *E. coli* infection, showed conjunctivitis, sinusitis, rhinitis, pneumonia, airsacculitis and/or enlargement of the spleen. Two turkeys of group 5, which had been superinfected with *E. coli* 5 weeks post-*C. psittaci* infection, showed airsacculitis and serous to fibrinous pericarditis and one turkey showed a strongly enlarged spleen. Conversely, the turkeys of the *C. psittaci* infected control group 7 showed no macroscopic lesions on post-mortem examination 7 weeks post-infection.

3.2. *C. psittaci* excretion

Pharyngeal swabs of the *C. psittaci* non-infected control groups 2, 4, 6 and 8 remained chlamydiae-negative throughout the experiment, as pharyngeal swabs of groups 1, 3, 5 and 7 prior to *C. psittaci* infection. Upon infection, overall *C. psittaci* shedding in group 1, superinfected with *E. coli*, was higher than in group 3 (only *C. psittaci* infection), although statistically not significant (Tab. II). Pharyngeal *C. psittaci* excretion in groups 1, 3, 5 and 7 lasted for about 12 days. Thereafter, excre-

tion was no longer observed, not even in the turkeys of groups 1 and 5, which had been superinfected with *E. coli*.

3.3. *C. psittaci* isolation from lungs and airsacs

In groups 1, 3, 5 and 7, replicating chlamydiae could be detected in air sacs and/or lungs until 14 days post *C. psittaci* infection (Tab. III). From that day on, air sacs and/or lungs showed a mean of 1 to 5 elementary bodies per five microscopic fields. Interestingly, the turkeys superinfected with *E. coli* during acute *C. psittaci* infection (group 1) showed chlamydial replication until the end of the experiment.

Five weeks post *C. psittaci* infection, chlamydiae could not be detected anymore in the respiratory tract of groups 5 and 7. However, superinfection with *E. coli* (group 5) reinitiated significant *C. psittaci* replication in both lungs and airsacs.

3.4. *C. psittaci* antibody response

At one week of age, all turkeys (claimed SPF) showed high antibody titres ($\log_2 7$ to $\log_2 12$) against *C. psittaci* (exemplified by turkeys of group 5 and 7 in Fig. 2). However, since no chlamydiae could be isolated and a decrease in antibody titres

Table III. Presence of *C. psittaci* in frozen tissue sections of lungs and airsacs during the acute and latent phase of *C. psittaci* infection.

dpe ^a	Score of chlamydophilae presence in the lungs and air sacs during the acute and latent phase of <i>C. psittaci</i> infection									
	3 (n ^b = 2)		5 (n = 2)		7 (n = 2)		10 (n = 2)		12 (n = 5)	
	Lung	Airsacs	Lung	Airsacs	Lung	Airsacs	Lung	Airsacs	Lung	Airsacs
1	3 ^c	2	3	3	3	3	3	3	3	3
3	3	2	3	2	2	3	1	1	0	1
5	0	1	1	2	3	3	3	3	2	2
7	0	0	0	0	0	0	0	0	0	0

^a dpe: days post *E. coli* infection. ^b n: number of turkeys. ^c Scores: score 0 indicated no chlamydophilae positive cell; score 1: mean of 1 to 5 elementary bodies in the absence of replicating reticulate bodies; score 2: mean of 6 to 10 elementary bodies in the absence of replicating reticulate bodies; scores 3, 4 and 5: mean of 1–5, 6–10 and >10 inclusion positive cells, respectively.

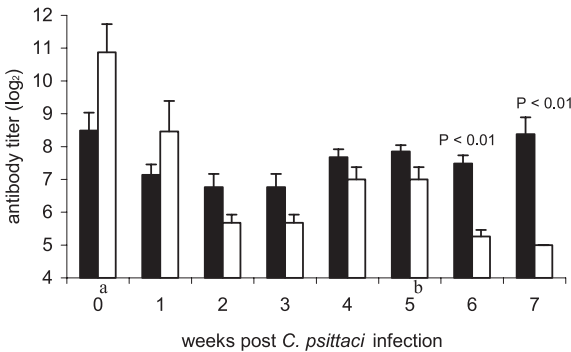


Figure 2. MOMP specific antibody responses in latently *C. psittaci* infected turkeys, superinfected with *E. coli* (groups 5 (■)) or not (group 7 (□)). ^a Day of *C. psittaci* infection, ^b day of *E. coli* infection.

in the following weeks was also observed in all the *C. psittaci* non-infected control groups 2, 4, 6 and 8, titres appeared to be maternally derived. These maternal antibodies masked the serological response against the *C. psittaci* infection during the first 3 weeks of infection (groups 1, 3, 5 and 7). However, from 4 weeks onwards the active antibody response (an increase) became visible in the *C. psittaci*-infected turkeys (Fig. 2).

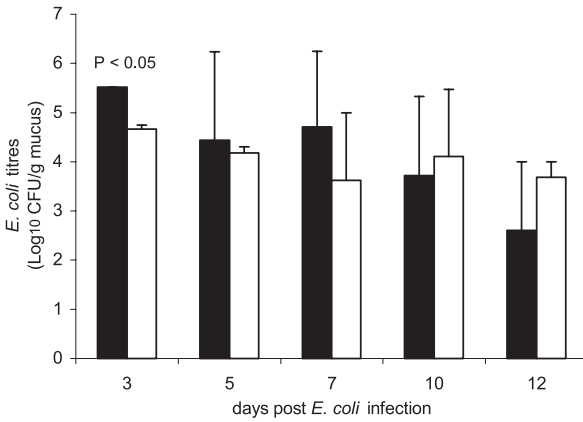
Five weeks post *C. psittaci* infection, *E. coli* superinfection (group 5) induced an increase in chlamydophilae-specific antibody titres, indicating a reactivation of the latent *C. psittaci* infection, while antibody titres decreased in group 7 (only *C. psittaci* infected turkeys). Active-infection related antibodies remained undetectable in the control groups 2, 4, 6 and 8.

3.5. *E. coli* isolation

Regardless of the time point of *E. coli* infection (2 or 6 weeks of age), the highest pharyngeal *E. coli* excretion was always observed 3 days post *E. coli* infection and at that time excretion was significantly higher in *C. psittaci* predisposed turkeys (groups 1 and 5, $P < 0.05$) than in non-predisposed turkeys (groups 2 and 6, Fig. 3). At all time points, a tendency of higher *E. coli* excretion was observed in the dual infected groups compared to the single *E. coli* infected groups. Importantly, all randomly selected *E. coli* colonies had serotype O2, identical to the serotype of the challenging strain.

E. coli was never isolated from any of the internal tissues of the *E. coli* non-infected control turkeys (groups 3, 4, 7 and

A



B

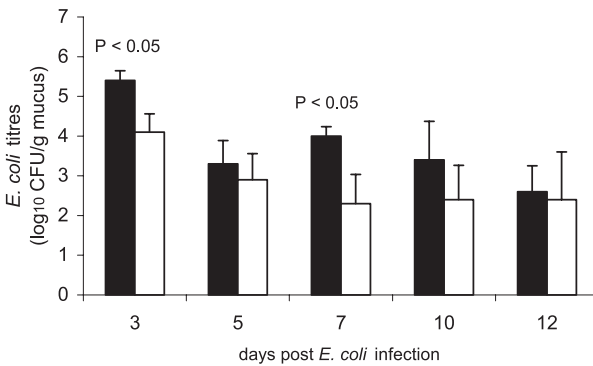


Figure 3. Pharyngeal *E. coli* excretion (\log_{10} CFU/g mucus) during the acute phase (A; groups 1 (■) and 2 (□)) and latent phase of a *C. psittaci* infection (B; groups 5 (■) and 6 (□)).

8) nor from the *E. coli*-infected turkeys which were free of *C. psittaci* (groups 2 and 6), although excretion (pharyngeal samples) in the latter groups had been observed from 3 days post *E. coli* infection until the end of the experiment. On the contrary, in *C. psittaci* predisposed turkeys (groups 1 and 5), *E. coli* was isolated from the lungs and the airsacs after *E. coli* infection.

3.6. Histopathology

The trachea, lungs and airsacs of turkeys showing gross lesions (i.e. *C. psittaci*-

infected groups 1, 3, 5 and 7) were examined. Turkeys of groups 2 and 6, which only received *E. coli*, did not develop macroscopic lesions and were therefore not examined histologically. Dual infected turkeys (group 1), showed no distinct histopathological differences with turkeys only infected with *C. psittaci* (group 3), except for lymphocyte infiltrations in the tracheal mucosae of group 3. Lungs and airsacs were comparable for both groups, showing capillary congestion and infiltration of heterophils. Histopathological lung lesions were clearly more severe in latently *C. psittaci* infected, *E. coli* superinfected turkeys (group 5),

compared to single *C. psittaci* infected turkeys (group 7). The lungs showed capillary congestion and multiple lymphoid aggregates with central necrosis and giant cells. Yet, the airsacs of groups 5 and 7 showed similar lesions: epithelial desquamation, heterophilic infiltration and multiple lymphoid aggregates.

4. DISCUSSION

The outcome of respiratory disease in turkeys receiving a superinfection with *E. coli* O2:K1 during the acute or latent phase of a *C. psittaci* infection was studied. Notwithstanding the presence of *C. psittaci*-specific maternal antibodies, the chlamydophilae infection alone caused conjunctivitis, rhinitis and dyspnoea for about 15 days resulting in pneumonia, airsacculitis, enlargement of the liver and spleen and chlamydial excretion until 12 days post infection. Thus, maternal antibodies did not block the *C. psittaci* infection and did not interfere with the experimental setup. Indeed, it has been demonstrated that one-week-old turkeys can become infected with *C. psittaci*, regardless of the presence of maternal antibodies [21, 28]. Nevertheless, we cannot rule out that the maternal antibodies might have reduced the severity of the *C. psittaci* infection, since antibodies can contribute to host protection, although CD4⁺ T helper 1 lymphocytes and interferon- γ are considered more important for protective immunity [11, 16]. Indeed, serovar-specific mucosal antibodies can impede the infection at the mucosal entrance gate, neutralizing *C. psittaci* before cellular adherence [3]. In addition, antibodies can intervene during extracellular dissemination of the bacteria.

Turkeys infected at one week of age with *C. psittaci*, received at 2 or 6 weeks of age an *E. coli* superinfection to simulate field situations [22, 25]. The *C. psittaci*-*E. coli* dual infection resulted in a respira-

tory disease with more severe clinical signs than infections with either agent alone. Severe conjunctivitis, rhinitis and dyspnoea were only observed in the dual infected groups and correlated well with the observed macroscopic lesions such as pneumonia, airsacculitis and pericarditis, and with the presence of replicating chlamydophilae in the pharyngeal swabs. Interestingly, due to the *E. coli* infection in the latently *C. psittaci* infected turkeys of group 5, anti-MOMP antibody titres increased further, whereas they decreased significantly to almost undetectable levels in the *E. coli* non-infected group 7. This indicates that reactivation of *C. psittaci* in *E. coli* superinfected turkeys took place. Indeed, *C. psittaci* replication in the lungs and air sacs was detected in the *E. coli* challenged turkeys (group 5), whereas not in the *E. coli* non-infected turkeys (group 7).

In accordance with other experimental infections in SPF or conventional turkeys [20], infection with *E. coli* alone produced no clinical signs or macroscopic lesions. In both latently or acutely *C. psittaci* infected turkeys, it was clear that a predisposing *C. psittaci* infection enhances colonisation and invasion of *E. coli* in the respiratory tract as well as pharyngeal *E. coli* excretion. The results of this study are consistent with observations in *Bordetella avium*-, avian pneumovirus-, *Ornithobacterium rhinotracheale*- or *Mycoplasma meleagridis*-infected turkeys receiving an *E. coli* superinfection [9, 14, 17, 18, 20]. However, *E. coli* excretion titres were not as high as those observed by Van de Zande et al. [20] in an APV-*E. coli* dual infection. *C. psittaci* replicates in mucosal epithelial cells and macrophages causing epithelial deciliation, desquamation and lysis. Consequently, epithelial degeneration during intracellular *C. psittaci* replication may allow extensive *E. coli* colonisation of the respiratory tract. Moreover, defence mechanisms of macrophages might have

been reduced by the *C. psittaci* infection of the macrophages themselves [13, 27].

In conclusion, the present study examined the pathogenic interplay between *C. psittaci* and *E. coli* O2:K1 in experimentally infected turkeys. A superinfection with *E. coli*, 1 or 5 weeks (acute and latent phase, respectively) after the *C. psittaci* infection, exacerbated the respiratory disease with a resurgence of *C. psittaci* replication. This study contributes to the unravelling of the multifactorial respiratory disease complex in turkeys, illustrating the pathogenic interplay between *C. psittaci* and *E. coli*.

ACKNOWLEDGEMENTS

This work was supported by the Belgian Ministry of Health (S-6037-section 2) and by Intervet International N.V. (Boxmeer, The Netherlands). We thank Carine Borgers for technical assistance. F. Vandemaele is acknowledged for his helpful statistical suggestions.

REFERENCES

- [1] Andersen A.A., Vanrompay D., Chlamydiosis, in: Saif Y.M. (Ed.), Diseases of Poultry, 11th ed., Iowa State University Press, Iowa, 2003, pp. 863–879.
- [2] Anderson D.C., Stoesz P.A., Kaufmann A.F., Psittacosis outbreak in employees of a turkey processing plant, *Am. J. Epidemiol.* 107 (1978) 140–148.
- [3] De Sa C., Souriau A., Bernard F., Salinas J., Rodolakis A., An oligomer of the major outer membrane protein of *Chlamydia psittaci* is recognised by monoclonal antibodies which protect mice from abortion, *Infect. Immun.* 63 (1995) 4912–4916.
- [4] Dho-Moulin M., Fairbrother J.M., Avian pathogenic *Escherichia coli* (APEC), *Vet. Res.* 30 (1999) 299–316.
- [5] Gosbell I.B., Ross A.D., Turner I.B., *Chlamydia psittaci* infection and reinfection in a veterinarian, *Aust. Vet. J.* 77 (1999) 511–513.
- [6] Hall C.F., Glass S.E., Grimes J.E., Moore R.W., An epidemic of ornithosis in Texas turkeys in 1974, *Southwest Vet.* 28 (1975) 19–21.
- [7] Jones R.C., Avian pneumovirus infection: questions still unanswered, *Avian Pathol.* 25 (1996) 639–648.
- [8] Macpherson I., Watt B.C., Alexander D.J., First isolation of an avian paramyxovirus other than Newcastle disease from commercial poultry in Great Britain, *Vet. Rec.* 122 (1983) 479–480.
- [9] Majo N., Gibert X., Vilafranca M., O'Loan C.J., Allan G.M., Costa L., Pages A., Ramis A., Turkey rhinotracheitis virus and *Escherichia coli* experimental infection in chickens: histopathological, immunocytochemical and microbiological study, *Vet. Microbiol.* 57 (1997) 29–40.
- [10] Moroney J.F., Guevara R., Iverson C., Chen F.M., Skelton S.K., Messmer T.O., Plikaytis B., Williams P.O., Blake P., Butler J.C., Detection of chlamydiosis in a shipment of pet birds, leading to recognition of an outbreak of clinically mild psittacosis in Humans, *Clin. Infect. Dis.* 26 (1998) 1425–1429.
- [11] Morrison S.G., Su H., Caldwell H.D., Morrison R.P., Immunity to murine *Chlamydia trachomatis* genital tract reinfection involves B cells and CD4+ T cells but not CD8+ T cells, *Infect. Immun.* 68 (2000) 6979–6987.
- [12] Redmann T., Zeydanli M.M., Herbst W., Kaleta E.F., Isolierung eines Paramyxovirus 3 aus Puten mit Atemwegserkrankung in Deutschland, *Dtsch. Tierarztl. Wochenschr.* 98 (1991) 138–141.
- [13] Rothermel C.D., Rubin B.Y., Murray H.W., Gamma-interferon is the factor in lymphokine that activates human macrophages to inhibit intracellular *Chlamydia psittaci* replication, *J. Immunol.* 131 (1983) 2542–2544.
- [14] Saif Y.M., Moorhead P.D., Bohl E.H., *Mycoplasma meleagridis* and *Escherichia coli* infections in germfree and specific pathogen free turkey poults: production of complicated airsacculitis, *Am. J. Vet. Res.* 31 (1970) 1637–1643.
- [15] Soni R., Seale J.P., Young I.H., Fulminant psittacosis requiring mechanical ventilation and demonstrating serological cross-reactivity between *Legionella longbeachae* and *Chlamydia psittaci*, *Respirology* 4 (1999) 203–205.
- [16] Stagg A.J., Tuffrey M., Woods C., Wunderink E., Knight S.C., Protection against ascending infection of the genital

- tract by *Chlamydia trachomatis* is associated with recruitment of major histocompatibility complex class II antigen-presenting cells into uterine tissue, *Infect. Immun.* 66 (1998) 3535–3544.
- [17] Turpin E.A., Perkins L.E., Swayne D.E., Experimental infection of turkeys with avian pneumovirus and either Newcastle disease virus or *Escherichia coli*, *Avian Dis.* 46 (2002) 412–422.
- [18] Van Alstine W.G., Arp L.H., Effects of *Bordetella avium* infection on the pulmonary clearance of *Escherichia coli* in turkeys, *Am. J. Vet. Res.* 48 (1987) 922–926.
- [19] Van de Zande S., Nauwynck H., Cavanagh D., Pensaert M., Infections and reinfections with avian pneumovirus subtype A and B on Belgian turkey farms and relation to respiratory problems, *J. Vet. Med. B* 45 (1998) 621–626.
- [20] Van de Zande S., Nauwynck H., Pensaert M., The clinical, pathological and microbiological outcome of an *Escherichia coli* O2:K1 infection in avian pneumovirus infected turkeys, *Vet. Microbiol.* 81 (2001) 353–365.
- [21] Van Loock M., Lambin S., Volckaert G., Goddeeris B.M., Vanrompay D., Influence of maternal antibodies on *Chlamydophila psittaci*-specific immune responses elicited by naked DNA, *Vaccine* 22 (2004) 1616–1623.
- [22] Van Loock M., Geens T., De Smit L., Nauwynck H., Van Empel P., Naylor C., Hafez H.M., Goddeeris B.M., Vanrompay D., Key role of *Chlamydophila psittaci* on Belgian turkey farms in association with other respiratory pathogens, *Vet. Microbiol.* 107 (2005) 91–101.
- [23] Vandemaele F., Assadzadeh A., Derijcke J., Vereecken M., Goddeeris B.M., Aviaire pathogene *Escherichia coli* (APEC), *Tijdschr. Diergeneesk.* 127 (2002) 582–588.
- [24] Vandemaele F., Vereecken M., Derijcke J., Goddeeris B.M., Incidence and antibiotic resistance of pathogenic *Escherichia coli* among poultry in Belgium, *Vet. Rec.* 151 (2002) 355–356.
- [25] Vanrompay D., Ducatelle R., Haesebrouck F., Hendrickx W., Primary pathogenicity of an European isolate of *Chlamydia psittaci* from turkey poults, *Vet. Microbiol.* 38 (1993) 103–113.
- [26] Vanrompay D., Ducatelle R., Haesebrouck F., Pathogenicity for turkeys of *Chlamydia psittaci* strains belonging to the avian serovars A, B and D, *Avian Pathol.* 23 (1994) 247–262.
- [27] Vanrompay D., Mast J., Ducatelle R., Haesebrouck F., Goddeeris B., *Chlamydia psittaci* in turkeys: pathogenesis of infections in avian serovars A, B and D, *Vet. Microbiol.* 47 (1995) 245–256.
- [28] Vanrompay D., Butaye P., Van Nerom A., Ducatelle R., Haesebrouck F., The prevalence of *Chlamydia psittaci* infections in Belgian commercial turkey poults, *Vet. Microbiol.* 54 (1997) 85–93.
- [29] Vanrompay D., Cox E., Mast J., Goddeeris B., Volckaert G., High-level expression of *Chlamydia psittaci* major outer membrane protein in COS cells and in skeletal muscles of turkeys, *Infect. Immun.* 66 (1998) 5494–6000.
- [30] Vanrompay D., Cox E., Volckaert G., Goddeeris B., Turkeys are protected from infection with *Chlamydia psittaci* by plasmid DNA vaccination against major outer membrane protein, *Clin. Exp. Immunol.* 118 (1999) 49–55.