



# Construction and testing of a novel host-range defective myxoma virus vaccine with the M063 gene inactivated that is non-permissive for replication in rabbit cells

Mathew Adams, Barbara van Leeuwen, Grant Mcfadden, Peter Kerr

## ► To cite this version:

Mathew Adams, Barbara van Leeuwen, Grant Mcfadden, Peter Kerr. Construction and testing of a novel host-range defective myxoma virus vaccine with the M063 gene inactivated that is non-permissive for replication in rabbit cells. *Veterinary Research*, 2008, 39 (6), pp.1. 10.1051/vetres:2008037 . hal-00902938

**HAL Id: hal-00902938**

**<https://hal.science/hal-00902938>**

Submitted on 11 May 2020

**HAL** is a multi-disciplinary open access archive for the deposit and dissemination of scientific research documents, whether they are published or not. The documents may come from teaching and research institutions in France or abroad, or from public or private research centers.

L'archive ouverte pluridisciplinaire **HAL**, est destinée au dépôt et à la diffusion de documents scientifiques de niveau recherche, publiés ou non, émanant des établissements d'enseignement et de recherche français ou étrangers, des laboratoires publics ou privés.

## Construction and testing of a novel host-range defective myxoma virus vaccine with the M063 gene inactivated that is non-permissive for replication in rabbit cells

Mathew M. ADAMS<sup>1,2</sup>, Barbara H. VAN LEEUWEN<sup>1</sup>, Grant MCFADDEN<sup>3</sup>,  
Peter J. KERR<sup>4\*</sup>

<sup>1</sup> School of Biochemistry and Molecular Biology, College of Science, The Australian National University, Canberra, ACT 0200, Australia

<sup>2</sup> Current address: Johnson and Johnson Research Pty Ltd, Level 4, 1 Central Avenue, Eveleigh, NSW 1430, Australia

<sup>3</sup> Department of Molecular Genetics and Microbiology, College of Medicine, University of Florida, 1600 SW Archer Rd, Academic Research Building, PO Box 100266, Gainesville 32610, Florida, USA

<sup>4</sup> CSIRO Entomology, GPO Box 1700, Canberra, ACT 2601, Australia

(Received 23 January 2008; accepted 4 September 2008)

**Abstract** – Deletion of the M063 gene from myxoma virus produces a virus that is unable to replicate in rabbit cells in vitro or in live rabbits but can be propagated in non-rabbit cell lines. A targeted M063 deletion mutant was constructed in the attenuated Uriarra strain of myxoma virus and the ability of this virus to act as a safe, non-transmissible vaccine against myxomatosis was tested in outbred laboratory rabbits. Immunization with the M063 deletion vaccine provided good short-term protection against lethal challenge with virulent myxoma virus. Long-term protection was similar to reported results with heterologous live virus, with some rabbits protected but others succumbing to challenge. Replication-deficient poxvirus vaccines, like the Modified Vaccinia Virus Ankara (MVA) in man and the myxoma virus vaccine described here in rabbits, are very attractive from a safety perspective. Seasonal boosting would be predicted to provide long-term protection. Targeted host-range gene deletions could have potential for rapid development of poxvirus vaccines in general.

**myxomatosis / vaccine / host-range / poxvirus / rabbits**

### 1. INTRODUCTION

Vaccination against poxvirus-induced diseases in both man and animals has traditionally used live attenuated viruses. The best example of this was the use of vaccinia virus to protect against smallpox in man. Selection of the appropriate live attenuated vaccines for specific diseases has required a trade-off between virulence of the vaccine virus and its effectiveness as a vaccine. Immunization with more virulent viruses often gives good

long-term protection but at the cost of potential disease in some vaccinated individuals, whereas immunization with highly attenuated viruses may be safer but may not provide adequate protection from challenge by the pathogen in all cases or for prolonged periods. This compromise is characteristic of the use of live vaccines to protect rabbits against myxomatosis caused by infection with the poxvirus myxoma virus.

Myxoma virus is the type species of the *Leporipoxvirus* genus. Closely related, but with different host-adapted characteristics, strains of myxoma virus have evolved in

\* Corresponding author: peter.kerr@csiro.au

two American lagomorph species: *Sylvilagus brasiliensis* in South America and *Sylvilagus bachmani* in western North America. Shope fibroma virus is another *Leporipoxvirus* closely related to myxoma virus and is found in *Sylvilagus floridanus* in eastern North America. Both types of myxoma virus and Shope fibroma virus cause localized cutaneous fibromas in their native *Sylvilagus* hosts and are spread passively on the mouthparts of biting arthropods such as mosquitoes and fleas [10].

In contrast to the relatively benign infections of *Sylvilagus* rabbits, European rabbits (*Oryctolagus cuniculus*) infected with myxoma virus develop a lethal systemic disease called myxomatosis [28]. Virulent South American strains of myxoma virus were introduced into Australia in 1950 as a biological control agent for wild European rabbits and into Europe in 1952 [11]. Vaccines to protect domestic farmed, laboratory or pet European rabbits from myxomatosis use either the heterologous Shope fibroma virus, which does not cause generalized disease in European rabbits [9], or tissue culture passage-attenuated live myxoma virus strains [13, 20, 27]. Both of these vaccines have limitations, Shope fibroma virus induces relatively short-term protection against myxomatosis [9, 14, 18] and the attenuated SG33 strain of myxoma virus has been associated with immunosuppression in young rabbits [7]. Attenuated live virus vaccines have also been investigated to protect wild rabbits in Europe [2, 27, 30].

In Australia, live virus vaccines for the protection of domestic and farmed rabbits against myxomatosis have not been used for fear that these could become established in the wild rabbit population and reduce the effectiveness of myxomatosis as a biological control. A vaccine against myxomatosis that could immunize rabbits but could not disseminate within the immunized rabbit or spread from rabbit to rabbit would have potential to be used safely both in Australia and other countries.

The myxoma virus early gene M063 is a host-range gene essential for productive replication of the virus in primary rabbit cells

and in all rabbit cell lines tested in vitro [3]. Targeted deletion of this gene by insertional inactivation produces a tropism-defective virus that can be propagated in non-rabbit cell lines but cannot complete its replication in rabbit cells in vitro or infected rabbits in vivo. The M063 deletion virus enters rabbit cells and expresses early viral genes but the infection aborts prior to the expression of late genes [3]. Protection following challenge with virulent myxoma virus has been demonstrated at 16 days after infection of laboratory rabbits with an M063 knock-out virus [3]. Thus it has the potential to be a completely safe vaccine for rabbits since it cannot complete its replication in this host and therefore cannot disseminate within an immunized rabbit or be transmitted to other rabbits.

M063 is one of a number of identified host-range genes in poxviruses including the C7L and K1L genes of vaccinia virus [3, 21, 24]. Host-range mutant viruses such as Modified Vaccinia Ankara (MVA) and NYVACC, which cannot complete their replication in human cells, are potential candidates for safe vaccines against smallpox [19]. In contrast to M063 deletion mutants however, these viruses express both early and late genes. Here we describe the evaluation of an M063 deletion mutant of myxoma virus, which expresses only early genes, as a practical vaccine against myxomatosis in European rabbits.

## 2. MATERIALS AND METHODS

### 2.1. Virus stocks and tissue culture

The Uriarra strain (Ur) of myxoma virus [22, 26] causes clinical myxomatosis in infected laboratory rabbits but death is uncommon [12]. The standard laboratory strain (SLS) of myxoma kills 100% of infected laboratory rabbits with an average survival time of < 13 days [25]. Virus stocks of Ur and SLS were prepared in RK13 cells (rabbit kidney cell line) from virus seed stocks originally obtained as testis homogenates from infected rabbits [6]. Ur-TKO (triple knock-out) is a deletion mutant of Ur with the M007, M010 and M011 open reading frames (ORF) all insertionally inactivated [1]. This virus does not cause clinical myxomatosis. Virus stocks of Ur-TKO were prepared in RK13 cells.

Titres for all virus stocks were determined by plaque assay on Vero cell (African green monkey kidney cell line) monolayers and expressed as plaque forming units (pfu)/mL.

RK13, Vero and BSC-1 (African green monkey kidney epithelial cell line) cells were maintained in minimal essential medium (MEM; Gibco, Grand Is, USA) supplemented with 10% new-born calf serum (CSL, Melbourne, Australia, 2 mM L-glutamine (Sigma, St. Louis, USA), 500 µg/mL amphotericin B (Sigma), 60 µg/mL penicillin (CSL), 100 µg/mL streptomycin (Gibco).

## 2.2. Insertional inactivation of the M063R ORF

Inactivation of the M063R ORF was achieved by homologous recombination in Ur-infected Vero cells transfected with the plasmid pKSΔM063R*gpt**gus*. This plasmid contains 349 bp homologous to the 3' end and 376 bp homologous to the 5' end of M063 between which was inserted the *gpt-gus* fusion gene under the control of a synthetic early/late poxvirus promoter [8]. Recombination between the Ur genome and the plasmid results in the insertion of the *gpt-gus* gene into the middle of the M063R ORF and the deletion of 498 bp of the ORF. Recombinant virus was selected by resistance to mycophenolic acid (Sigma) and screening for blue plaques in the presence of X-gluc (5-bromo-4-chloro-3-indolyl-β-D-glucuronic acid; Progen Industries, Ipswich, Australia). Transfection of cells and selection of recombinant viruses for resistance to mycophenolic acid (Sigma) and expression of β glucuronidase were as previously described [16, 17] respectively. Isolation of single blue-staining plaques was made in BSC-1 monolayers because plaque purification was easier from the foci of infected cells formed on these monolayers rather than the holes formed on Vero cell monolayers. Following six rounds of plaque purification, the recombinant virus was demonstrated free of parental virus by PCR analysis and failure to replicate in RK13 cells. Cloning and sequencing of the M063R ORF from this virus confirmed that the sequence was identical to the plasmid pKSΔM063R*gpt**gus* sequence. The resulting virus was termed UrΔM063. Stocks of this virus were prepared in Vero cell monolayers.

## 2.3. Vaccine trials

Vaccine trials were conducted in outbred laboratory rabbits under containment level 2 (PC2)

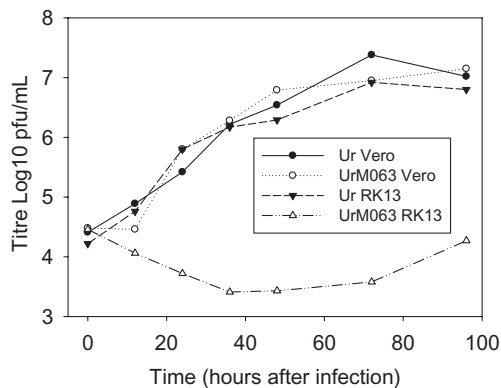
conditions as approved by the Commonwealth of Australia Office of the Gene Technology Regulator. All trials were approved by the CSIRO Sustainable Ecosystems Animal Ethics Committee. Rabbits were housed in individual cages with free access to water and commercial pelleted rabbit food under a 12 h light/dark cycle. Vaccination was by intradermal inoculation on the left thigh with 100 000 pfu of UrΔM063 in 100 µL of PBS. Boosting was with the same dose of virus inoculated on the right thigh. Boosting with Ur-TKO used 50 pfu of virus. This dose has been shown to provide protection from lethal challenge [1]. Rabbits were challenged by the inoculation of 1 000 pfu of SLS intradermally on the left thigh. Each rabbit was physically examined daily during the trials and rectal temperatures measured; a temperature of  $\geq 40^{\circ}\text{C}$  was regarded as significantly elevated.

## 2.4. Antibody assays

ELISA and plaque reduction neutralization assays were performed as previously described [15]. ELISA titrations were made using two-fold dilutions of serum from 1:100. Titres were expressed as the reciprocal of the final dilution producing an OD<sub>405</sub> 0.1 units above the negative control serum. Sera with an OD < 0.1 above the negative control at a dilution of 1:100 were recorded as a titre of 0. Plaque reduction neutralization assays used two-fold dilutions from 1:10 of heat-inactivated serum (10 min, 56°C) and constant virus concentration (~100 pfu per well). Titres were expressed as the reciprocal of the lowest dilution giving a  $\geq 50\%$  reduction in the number of plaques compared to control normal serum. Sera that did not cause at least 50% plaque reduction at 1:10 dilution were assigned a titre of 0. For both assays, a four-fold change in titre in an individual rabbit was regarded as significant.

## 2.5. Immunofluorescence staining

RK13 or Vero cell monolayers infected with Ur or UrΔM063, at a multiplicity of infection (MOI) of one, for 24 h or uninfected control monolayers, were fixed with 1:1 (v/v) methanol:acetone (Sigma) for 10 min, washed with PBS pH 7.2 and stored at  $-20^{\circ}\text{C}$  until used. The monolayers were probed with monoclonal antibody 3B6E4 [5] and binding detected with FITC-conjugated goat anti-mouse IgG (BioRad, Richmond, USA). Fluorescence was



**Figure 1.** Replication of the Ur strain of myxoma virus and UrΔM063 in Vero or RK13 cells. RK13 or Vero cell monolayers were infected with Ur or UrΔM063 at MOI 0.1 pfu. Duplicate monolayers were harvested at 0, 12, 24, 36, 48, 72 and 96 h after infection. Virus titres were determined by plaque assay on Vero cell monolayers; mean titres for duplicate monolayers are shown.

visualized using a Leitz Fluovert FS microscope and recorded with a Spot RT digital camera (Diagnostic instruments, Australia).

### 3. RESULTS

#### 3.1. Replication of Ur and UrΔM063 in Vero or RK13 cells

Both the parental Ur and UrΔM063 had similar replication kinetics in Vero cells at MOI of 0.1. However, UrΔM063 was unable to replicate in the rabbit cell line RK13 (Fig. 1). Similar results were obtained with MOI of three (data not shown). Late gene expression of myxoma virus was examined in RK13 and Vero cell monolayers infected with Ur or UrΔM063. Cell monolayers were probed with monoclonal antibody 3B6E4 [5] which binds to a 42 kDa myxoma virus core protein which is not expressed if DNA replication is inhibited with AraC (cytosine 1-β-D-arabinofuranoside). This protein is conserved in South American and North American myxoma viruses and Shope fibroma virus (data not shown). Figure 2 demonstrates that late gene expression was occurring in Vero cells infected with both Ur and UrΔM063

(panels C and E). However, in RK13 cells there was a clear difference between Ur and UrΔM063 infected cells with almost all cells infected with Ur showing strong fluorescence while those cells infected with UrΔM063 stained poorly for the viral late antigen although some cells show weak fluorescence which may be due to a small amount of protein expression or to the input virus (panels D and F).

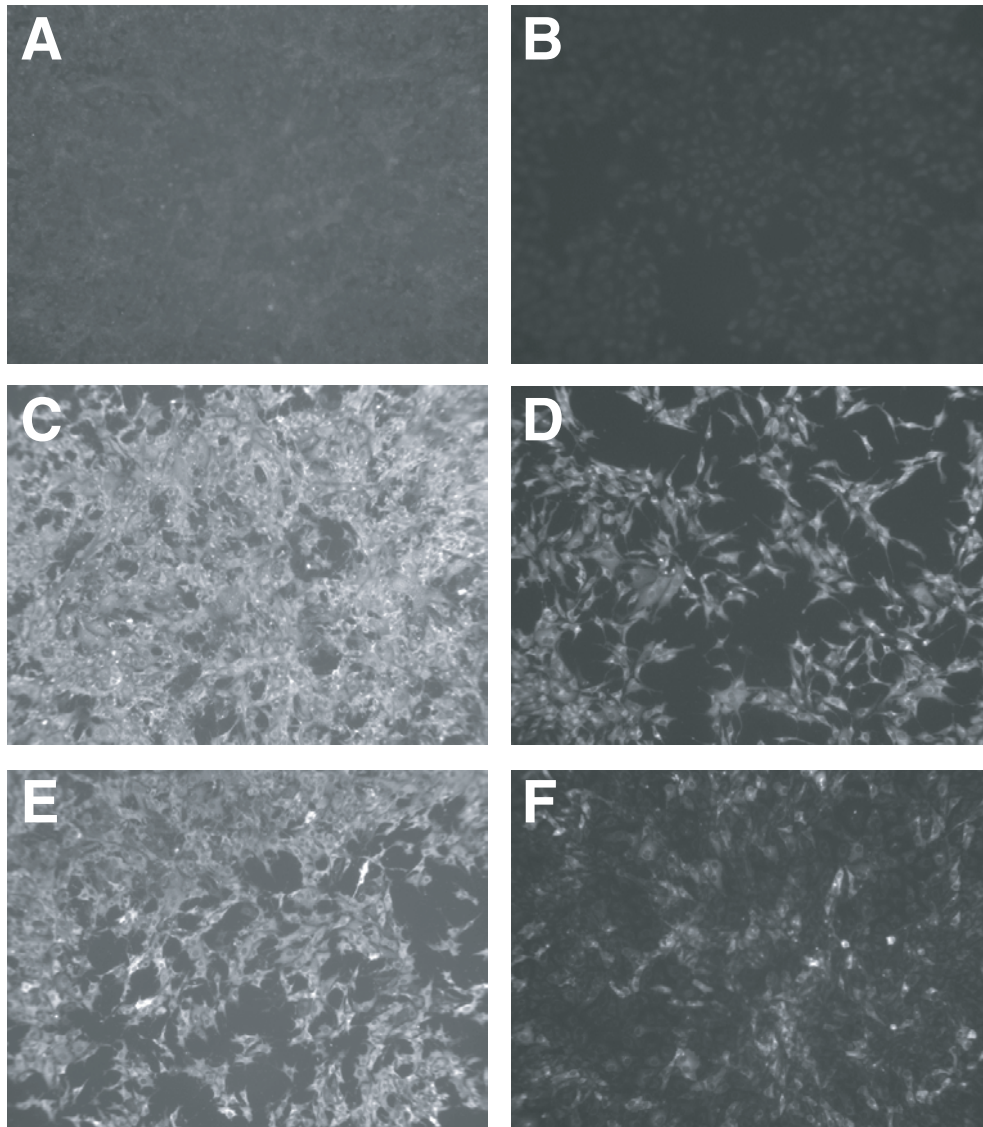
#### 3.2. Vaccination trials

##### 3.2.1. Trial 1: vaccination with UrΔM063 and SLS challenge

Six adult male rabbits were vaccinated with UrΔM063. The only clinical response to immunization was a pink lump at the inoculation site from day 5. Initially 0.3–0.5 cm in diameter, this swelling increased to as much as 1.5 cm in diameter and resolved completely by day 21. Rectal temperatures remained within normal limits during this time. Six weeks after vaccination, all six rabbits were challenged with a lethal dose of the virulent myxoma virus SLS. The clinical signs in response to challenge are summarised in Table I. All of the rabbits survived the SLS challenge. The key features were the rapid development of a cutaneous response at the inoculation site within 24 h which was quickly resolved and the presence of small, rapidly-resolved, cutaneous or mucocutaneous secondary lesions. For comparison with the clinical signs of unvaccinated control rabbits challenged with SLS, see Table II.

##### 3.2.2. Trial 2: vaccination with UrΔM063 plus boosting and SLS challenge

Six 12-week-old male rabbits were vaccinated with UrΔM063. There was no difference in the response to vaccination compared with the previous trial despite the younger age of the rabbits. These rabbits were boosted with UrΔM063 four weeks later. A 0.5–1.2 cm pink lump developed at the boost site within 24 h that increased to 0.8–1.5 cm by 3 days after boosting and had regressed by 9 days after boosting. Rectal temperatures remained in the



**Figure 2.** Immunofluorescent detection of myxoma virus antigen in infected cells. Vero cell monolayers were mock infected (A), infected with Ur (C) or Ur $\Delta$ M063 (E) at a MOI of 1. RK13 cell monolayers were mock infected (B), infected with Uriarra (D) or Ur $\Delta$ M063 (F) at a MOI of 1. After 24 h, cells were fixed and probed with the monoclonal antibody 3B6E4, specific for a late myxoma virus antigen. Original magnification 40 $\times$ .

normal range during this time. Six weeks after boosting the rabbits were challenged with SLS myxoma virus. Within 24 h, all rabbits developed a raised red lump around 1 cm in diameter at the challenge inoculation site. By 3 days

after challenge, these lesions were 1.5–3 cm in diameter and had a black centre. Secondary lesions only occurred on 2 of the 6 rabbits, at the ear margins and on the face; no more than 5 small secondary lesions were visible on

**Table I.** Clinical signs in UrΔM063 vaccinated rabbits challenged with SLS.

Day post-inoculation	Clinical signs
1	0.8–1.2 cm diameter pink lesion at inoculation site
2	All rabbits have rectal temperatures $\geq 40^{\circ}\text{C}$
3	1.5–2.5 cm red/crimson protuberant lesion at inoculation site. 5/6 rabbits have normal temperatures
5	Lesions at inoculation site are black 2–4 cm in diameter. Secondary lesions on 5/6 rabbits on eyelids, ears, face and body. All animals had rectal temperature $\geq 40^{\circ}\text{C}$
7	Lesions at inoculation site scabbed over. Secondary lesions had all turned black and were 0.5–1 cm in diameter on eyelids, ears, anus, scrotum, face, nostrils and body. 4/6 animals had a rectal temperature $\geq 40^{\circ}\text{C}$
8	2/6 rabbits had snuffly breathing with slight mucopurulent discharge from nostrils and mild anogenital swelling. 3/6 rabbits had temperatures $\geq 40^{\circ}\text{C}$
9	2/6 animals had recovered except for hard black scabs over inoculation site and over mild the secondary lesions; 3 rabbits had snuffly breathing and nasal discharge, anogenital swelling and temperatures $\geq 40^{\circ}\text{C}$ . All secondary lesions were black and regressing
13	Lesions at inoculation sites covered in hard black concave scabs. 1 rabbit still had slight nasal discharge and snuffly breathing but rapidly recovering. Anogenital swelling had regressed. Some weight loss in 2 of the rabbits that had been worst affected. All rabbits had temperatures $< 40^{\circ}\text{C}$
21	All animals recovered although some have lumpy misshapen ear margins and small black scabs on face and body

any rabbit. By 6 days after challenge, the primary lesions were covered with a black scab although some primary lesions had small secondary lesions around the periphery. By 9 days after challenge, the rabbits were completely

recovered apart from scabs on the primary and secondary lesions. Only 2 of the rabbits had rectal temperatures  $\geq 40^{\circ}\text{C}$  following challenge and all temperatures were within the normal range from day 6 after challenge.

**Table II.** Clinical signs in unvaccinated control rabbits challenged with SLS.

Day post-inoculation	Clinical signs
3	0.5 cm swelling at inoculation site in 1/3 rabbits
4	2/3 rabbits have rectal temperatures $\geq 40^{\circ}\text{C}$ ; 1/3 has 1 cm swelling at inoculation site; 2/3 have slight skin thickening at inoculation site and one has slightly swollen eyelid margins and nose
5	1–2 cm swelling at inoculation site; red eyelid margins
7	Red swollen eyelids with slight serous to mucoid discharge, slightly swollen nose and ears; mild to moderate anogenital swelling
8	Primary lesion 1.5–2.5 cm diameter; swollen eyelids – eyes half closed by swelling in one rabbit – mucopurulent conjunctival discharge, snuffling respiration and moderate to severe anogenital swelling in all 3 rabbits. Rabbits moderately to severely ill
10	One rabbit dead and one euthanized. Very swollen drooping ears, eyes completely closed by eyelid swelling, mucopurulent discharge from conjunctivae and nose, straining to breathe with head and neck extended, severely swollen anogenital region in 2/3 rabbits and severely swollen scrotums in all three rabbits. Rectal temperature of euthanized rabbit $37.5^{\circ}\text{C}$

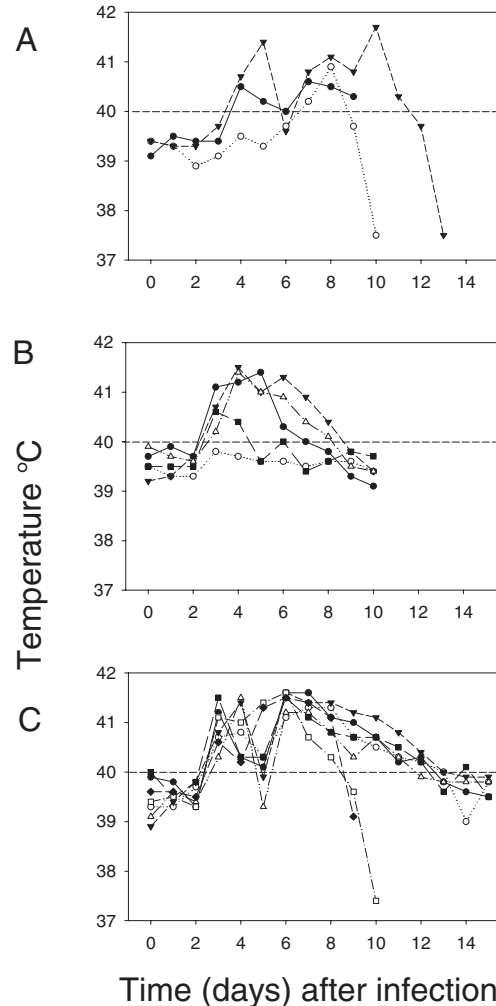


### 3.2.3. Trial 3: vaccination with Ur $\Delta$ M063 plus boost with live attenuated virus

Six 12-week-old male rabbits were vaccinated with Ur $\Delta$ M063 and 4 weeks after immunization the rabbits were boosted with 50 pfu of Ur-TKO. A small lesion developed at the boost site 3 to 4 days after boosting which, by 6 days, ranged from 0.5–1.5 cm in diameter except on one rabbit which had a  $2 \times 3$  cm lesion. These lesions scabbed and regressed over the next 5–10 days. No secondary lesions were visible and rectal temperatures remained within the normal range. Six weeks after boosting the rabbits were challenged with SLS myxoma virus. Three of the challenged rabbits had a very limited response to challenge that was characterized by a pink lesion at the challenge site within 24 h which had started to scab by 4 days after challenge. Only one of these rabbits developed a few, very small, secondary lesions on the ears and eyelids. The other 3 rabbits exhibited numerous small secondary lesions on the eyelids, anus, nose, face or ears, slightly obstructed nasal passages, mild ano-genital swelling, fever  $\geq 40^\circ\text{C}$  and some weight loss. However, at no point were these rabbits seriously debilitated.

### 3.2.4. Trial 4: vaccination with Ur $\Delta$ M063 plus boosting and long-term challenge

To determine the duration of protection, 12 male rabbits approximately four months old were vaccinated with Ur $\Delta$ M063 and boosted with the same virus 4 weeks later. Thirty-five weeks after the initial vaccination, the rabbits were challenged with SLS myxoma virus. As controls, 3 unvaccinated rabbits were challenged with SLS at the same time. Clinical signs in these control rabbits are described in Table II and the rectal temperatures are shown in Figure 3A. One control rabbit had a 0.5 cm primary lesion at the challenge site by day 3 after challenge and 2 rabbits had rectal temperatures  $\geq 40^\circ\text{C}$ . It was not until day 5 that all 3 control rabbits had distinct primary lesions at the challenge site. The control rabbits developed typical generalized severe myxomatosis and either died or were euthanized between days 10 and 13 after



**Figure 3.** Rectal temperatures of rabbits challenged with SLS myxoma virus 35 weeks after vaccination with Ur $\Delta$ M063 or unvaccinated controls. (A) Unvaccinated control rabbits. (B) Five rabbits which were resistant to challenge. (C) Seven rabbits which developed generalized myxomatosis following challenge. A temperature of  $\geq 40^\circ\text{C}$  (indicated by dashed line) was regarded as significantly elevated.

infection. In contrast to the control rabbits, the vaccinated rabbits exhibited an accelerated tissue response to challenge (Tab. III). By day 2, all 12 rabbits had an 0.5–2.5 cm swelling at the challenge site and by day 3, 11/12 rabbits had rectal temperatures  $\geq 40^\circ\text{C}$



**Table III.** Clinical signs in long-term challenged rabbits.

Day post-challenge	Clinical signs
1	4/12 rabbits had a detectable response at the challenge site ranging from slight skin thickening to a 1 cm diameter swelling
2	All rabbits had 0.5–2 cm diameter swellings at challenge site
3	11/12 rabbits had rectal temperatures $\geq 40^{\circ}\text{C}$ . 3/12 rabbits had primary lesions that were black in the centre. 3 rabbits had thickened ears
4	11/12 rabbits had rectal temperatures $\geq 40^{\circ}\text{C}$ . Primary lesions ranged from 1–6 cm diameter
5	8/12 rabbits had rectal temperatures $\geq 40^{\circ}\text{C}$ . Some secondary signs of myxomatosis such as anogenital redness and ears and eyelids slightly thickened
6	11/12 rabbits had rectal temperatures $\geq 40^{\circ}\text{C}$ . 5/12 primary lesions now black in centre. Some discrete secondary lesions are already black. Some rabbits have swollen noses, eyelids, base of ears and red slightly swollen anogenital areas. One rabbit had very rapid respiration and depressed demeanour
7	10/12 rabbits had rectal temperatures $\geq 40^{\circ}\text{C}$ . Most primary lesions black in centre and some are scabbing. Clinical signs ranged from severe anogenital swelling, swollen ears and eyelids to just a primary lesion
8	9/12 rabbits had rectal temperatures $\geq 40^{\circ}\text{C}$ . Clinical signs ranged from localized primary lesion to severe generalized myxomatosis. Clinically affected rabbits had mild to severe anogenital swelling and swollen scrotums, some conjunctival mucopurulent discharge, swollen, drooping ears, discrete secondary lesions on face and eyelids
9	5/12 rabbits were rapidly recovering and had normal temperatures; 5/12 rabbits had rectal temperatures $\geq 40^{\circ}\text{C}$ and clinical signs of myxomatosis continued to develop with snuffling, laboured respiration due to congestion of nasal passages, mucopurulent conjunctival discharge, eyelids swollen and half closed, swollen anogenital regions and scrotums and swollen drooping ears
10	5/12 rabbits were essentially completely recovered. One rabbit was found dead and one had a subnormal temperature ( $37.4^{\circ}\text{C}$ ) and was euthanized. The other 5 rabbits had temperatures $\geq 40^{\circ}\text{C}$ with clinical signs ranging from moderate to severe generalized myxomatosis. One of these rabbits was starting to recover
15	All temperatures were $< 40^{\circ}\text{C}$ . 3/5 of the severely ill rabbits were clearly recovering although 4/5 were still quite ill. Clinical signs ranged from moderate to severe generalized myxomatosis.

(Figs. 3B and 3C). Five of the vaccinated rabbits developed very mild clinical signs of myxomatosis characterized by a 1.5–2.5 cm diameter primary lesion at the challenge site, slightly swollen ears, eyelids and face with scattered small secondary lesions. These rabbits had essentially recovered by day 9 and rectal temperatures had returned to normal (Fig. 3B). The other seven vaccinated rabbits developed moderate to severe myxomatosis with prolonged fever (Fig. 3C). At day 10, one vaccinated rabbit was dead, one was euthanized, because of severe illness and a subnormal rectal temperature, and the remaining five were moderately ill. These five

rabbits became more seriously ill over the next 2 to 3 days with severely congested nasal passages causing respiratory distress. However, by day 15, 4 of the 5 were recovering and based on experience with similar clinical cases would most likely have survived. The fifth was still very ill but starting to recover. All five rabbits were euthanized at day 15 on humanitarian grounds.

### 3.3. Serum antibody titres following immunization

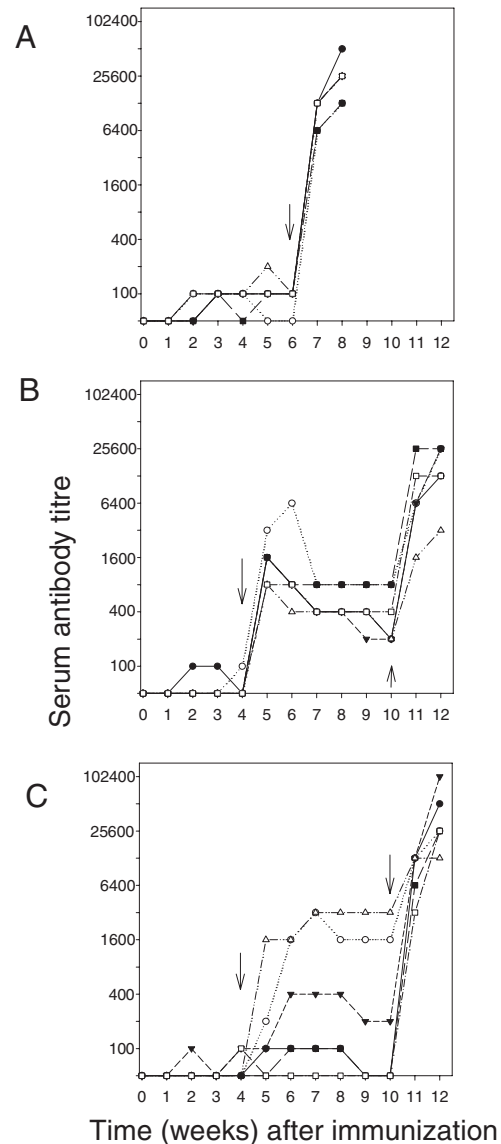
In the six weeks following immunization with UrΔM063, serum antibodies to myxoma

virus were barely detectable with ELISA titres ranging from 0 to 200 (Fig. 4A). Neutralizing antibodies were undetectable (Tab. IV A). Seven days after challenge with SLS myxoma virus, ELISA titres increased to 6 400–12 800, while at 2 weeks after challenge, neutralization titres ranged from 640 to > 20 480.

Rabbits immunized with Ur $\Delta$ M063 and then boosted with the same virus had a significant rise in ELISA titre in the week following the boost. This titre increased again following challenge (Fig. 4B). None of the rabbits had detectable neutralizing antibody prior to boosting. However, 5 of 6 rabbits developed neutralizing antibody titres ranging from 10 to 160 two weeks after boosting (Tab. IV B). On the day of challenge, six weeks after boosting, all six rabbits had neutralizing antibody titres ranging from 10–80. Two weeks after challenge these titres were 320 to 10 240.

When rabbits were boosted with Ur-TKO, 3 of 6 rabbits had a significant rise in ELISA titre with titres at two weeks after boosting of 1 600, 1 600 and 400 (Fig. 4C). These three rabbits also developed neutralizing antibody titres of 40 to 640 (Tab. IV C). The other three rabbits had no increase in antibody titre and antibody could not be detected on the day of challenge. All six rabbits had substantial rises in antibody titres following challenge. ELISA titres ranged from 3 200 to 102 400 and neutralizing titres from 640 to > 20 480. Two of the three rabbits that failed to develop neutralizing antibody titres had mild to moderate clinical signs of disease following challenge with development of numerous small secondary lesions and slight oculo-nasal discharge. However, one of the animals with neutralizing antibody titres developed similar clinical signs while the third rabbit that failed to develop neutralizing antibody had only a few secondary lesions (Tab. IV C).

In the long-term studies, only virus neutralization titres were measured because these have the potential to control virus infection.



**Figure 4.** Serum antibody titres to myxoma virus measured by ELISA. (A) Rabbits vaccinated with Ur $\Delta$ M063 and challenged at 6 weeks (arrow) with SLS. (B) Rabbits vaccinated with Ur $\Delta$ M063, boosted at 4 weeks with Ur $\Delta$ M063 (arrow) and challenged at 10 weeks (arrow) with SLS. (C) Rabbits vaccinated with Ur $\Delta$ M063, boosted at 4 weeks (arrow) with Ur-TKO and challenged at 10 weeks (arrow) with SLS.

**Table IV.** Serum neutralizing antibody titres in immunized rabbits.

A. Rabbits vaccinated with UrΔM063					
Rabbit	Titre at challenge			Titre post challenge	
184	< 10			> 20 480	
179	< 10			2 560	
183	< 10			> 20 480	
176	< 10			640	
187	< 10			5 120	
154	< 10			5 120	
B. Rabbits vaccinated with UrΔM063 and boosted with UrΔM063					
Rabbit	Titre at boost (4 weeks)	Titre at 6 weeks	Titre at challenge (10 weeks)	Titre at 12 weeks	Clinical signs at challenge
281	< 10	40	20	2 560	Primary only
278	< 10	160	80	10 240	Primary only
282	< 10	< 10	10	5 120	Few secondaries
284	< 10	80	10	320	Primary only
288	< 10	10	10	5 120	Few secondaries
287	< 10	40	20	1 280	Primary only
C. Rabbits vaccinated with UrΔM063 and boosted with attenuated live virus					
Rabbit	Titre at boost (4 weeks)	Titre at 6 weeks	Titre at challenge (10 weeks)	Titre at 12 weeks	Clinical signs at challenge
285	< 10	< 10	< 10	10 240	Mild-moderate
291	< 10	160	80	640	Primary only
289	< 10	40	10	> 20 480	Mild-moderate
290	< 10	640	320	1 280	Primary only
275	< 10	< 10	< 10	5 120	Few secondaries
293	< 10	< 10	< 10	> 20 480	Mild moderate
D. Long term trials for rabbits vaccinated with UrΔM063 and boosted with UrΔM063					
Rabbit No.	Titre post-boost	Titre at challenge	Titre 15 days post-challenge	Clinical signs at challenge	
403	10	< 10	> 640	mild	
401	20	< 10	> 640	mild	
379	40	20	> 640	mild	
405	10	< 10	80	Mild-moderate	
395	160	< 10	640	Mild to moderate	
387	80	< 10	> 640	Generalized	
385	80	< 10	> 640	Generalized	
386	40	< 10	640	Generalized	
390	80	< 10	640	Severe	
391	10	< 10	> 640	Severe	
392	80	< 10	Not tested	Fatal	
400	80	< 10	Not tested	Fatal	

All 12 rabbits had neutralizing antibody detectable at 7 days after boosting with titres ranging from 10–160 (Tab. IV D). However, on the day of challenge, 31 weeks later,

only one rabbit had neutralizing antibody detectable at a titre of 20. Following challenge, neutralization titres ranged from 80 to 640 for the 10 rabbits surviving at day 15. Blood

samples were not available for the two rabbits that died prior to day 15. Inspection of Table IV D indicates that there was no direct correlation between the titre of neutralizing antibody after boosting and the severity of clinical disease following challenge.

#### 4. DISCUSSION

Vaccination with Ur $\Delta$ M063 provided good short-term protection from lethal challenge with a dose of virus much greater than would normally be delivered by a flea or mosquito vector. Immunization was extremely safe with the only side-effect being a moderate swelling at the inoculation site from day five which resolved completely within three weeks of vaccination. This was probably due to a cell-mediated immune response to antigen produced by early gene expression in dermal cells since the virus cannot replicate in rabbit cells to induce the classic 'myxoma' at the inoculation site.

Rabbits immunized with Ur $\Delta$ M063 did not develop high titres of serum antibody to myxoma virus, measured by either ELISA or neutralization, prior to boosting. In both assays, viral proteins of the intracellular mature virus (IMV) are the predominant antigens and it is unlikely that key structural proteins that make up the outer layers of either IMV or extracellular enveloped virus (EEV) would be expressed by rabbit cells infected with Ur $\Delta$ M063 as these proteins are encoded by late genes. However, vaccination with this replication-defective virus appeared to prime both B and T cells, which responded rapidly to boosting with Ur $\Delta$ M063 and to challenge with virulent SLS myxoma virus. The T cell response was demonstrated by the rapid tissue response at the site of challenge or boosting and B cell priming by anamnestic serum antibody responses to IMV following challenge or boost. At six weeks after vaccination this provided good protection from lethal challenge with virulent myxoma virus. It seems likely that B and T cells are being primed by IMV structural proteins in the immunizing virus and stimulated to proliferate and, in the case of B cells, differentiate into

plasma cells, by the same proteins in the boosting dose of virus or in the replicating challenge virus. Comparison of Figures 4A and 4B support this model as there is a much greater response to the live virus than to the boost with Ur $\Delta$ M063. Any significant late protein synthesis or Ur $\Delta$ M063 viral replication is ruled out by the lack of antibody to IMV following the primary immunization.

Boosting with a very low dose of live attenuated virus (Ur-TKO) did not show any advantages over boosting with Ur $\Delta$ M063 and may have been less effective as only three of six rabbits had a rise in antibody titre. This was possibly because the immunized rabbits controlled replication of this very attenuated virus. Higher doses of Ur-TKO may have been more effective as a boost but when used as a primary immunization there is no difference in protection between 50 and 5000 pfu of Ur-TKO [1].

From the shorter term studies, it can be concluded that immunized and boosted rabbits have good protection from high dose lethal challenge for at least 10 weeks. However, challenge studies at 35 weeks after primary immunization showed that only 5/12 of rabbits retained good protection. Only one of the rabbits had detectable neutralizing antibody at this time which contrasts with rabbits recovered from natural infection which have neutralizing antibodies detectable for >12 months and are strongly protected from disease on challenge [15]. All of the immunized rabbits in the long-term trial developed a rapid response at the challenge site within 48 h. That this was initially largely due to an immune response rather than virus replication is seen by comparison with the control rabbits which did not develop a primary lesion at the challenge site until day three or four. Similarly 11/12 challenged rabbits developed a fever of  $\geq 40^{\circ}\text{C}$  within three days of challenge compared with 2 of 3 control rabbits at 4 days. There was no apparent correlation between the initial response to challenge and the subsequent course of the disease. Since the rabbits had very low or undetectable levels of neutralizing antibody at challenge, it seems likely that

a T cell memory response is critical to controlling initial virus replication and spread while antibody is important to limit later viral spread and to clear the virus. It is possible that the rabbits that controlled the disease had a qualitatively or quantitatively different T cell response to the severely affected rabbits.

The degree and duration of protection provided by immunization with Ur $\Delta$ M063 compared well with that provided by immunization reported with the heterologous Shope fibroma virus [9, 14]. For example, 13/20 rabbits vaccinated with Shope fibroma virus died following challenge with virulent myxoma virus seven weeks after immunization [18]. Immunization with an attenuated homologous live myxoma virus SG33 provides protection that lasts for a more prolonged period in most, but not all, immunized rabbits. In a set of 6 trials [27], 2 of 59 rabbits died following challenge 21 days after vaccination; protection waned between 6 and 8 months after vaccination and was regarded as unsatisfactory by 8 months. Vaccination with SG33 followed by a boost at 8 weeks gave reasonable protection at 8 months but by 12 months 50% of animals exhibited some degree of myxomatosis following challenge [27]. In another set of trials, rabbits vaccinated with SG33 at 4 or 6 weeks of age were regarded as insufficiently protected from challenge after approximately 10 weeks [23]. This vaccine has also been demonstrated to induce immunosuppression in vaccinated rabbits [7, 18]. Compared to these vaccines Ur $\Delta$ M063 is extremely safe, and there is no possibility of it transmitting to other rabbits. Thus it would be acceptable for use in Australia as it produces no risk to the use of myxomatosis as a biological control. It could be used strategically to provide protection from myxomatosis during the peak incidence of the disease by immunizing domestic rabbits in the spring followed by a boost. Further trials would be needed to optimize the vaccine dose and boosting regime. In addition, Ur $\Delta$ M063 could be further genetically engineered to express the Rabbit Haemorrhagic Disease Virus capsid gene under the control of an early promoter by replacing the *gpt* gene fusion gene and thus potentially provide protection against

the two major viral diseases of rabbits as has been previously described for a recombinant myxoma virus [2, 4, 29].

The research described demonstrates that deletion of host-range genes could be used to provide safe poxvirus vaccines, for diseases of livestock or humans, that could not transmit and thus potentially endanger immunoincompetent contacts and that such vaccines can protect even if only early genes are expressed. However, while very attractive from a safety perspective, the long-term trials indicate that such vaccines may require care with boosting for ongoing protection.

**Acknowledgements.** This study was funded by the Pest Animal Control Cooperative Research Centre. Grant McFadden is an International Scholar of the Howard Hughes Medical Institute.

## REFERENCES

- [1] Adams M.M., van Leeuwen B.H., Kerr P.J., Construction and evaluation of live attenuated myxoma virus vaccines with targeted virulence gene deletions, *Vaccine* (2007) doi:10.1016/j.vaccine.2008.08.036.
- [2] Bárcena J., Morales M., Vázquez B., Boga J.A., Parra F., Lucientes J., et al., Horizontal transmissible protection against myxomatosis and rabbit hemorrhagic disease by using a recombinant myxoma virus, *J. Virol.* (2000) 74:1114–1123.
- [3] Barrett J.W., Shun Chang C., Wang G., Werden S.J., Shao Z., Barrett C., et al., Myxoma virus M063R is a host range gene essential for virus replication in rabbit cells, *Virology* (2007) 361:123–132.
- [4] Bertagnoli S., Gelfi J., Le Gall G., Boilletot E., Vautherot J.F., Rasschaert D., Laurent S., et al., Protection against myxomatosis and rabbit viral hemorrhagic disease with recombinant myxoma viruses expressing rabbit hemorrhagic disease virus capsid protein, *J. Virol.* (1996) 70:5061–5066.
- [5] Best S.M., Collins S.V., Kerr P.J., Coevolution of host and virus: cellular localization of myxoma virus infection of resistant and susceptible European rabbits, *Virology* (2000) 277:76–91.
- [6] Best S.M., Kerr P.J., Coevolution of host and virus: the pathogenesis of virulent and attenuated strains of myxoma virus in resistant and susceptible European rabbits, *Virology* (2000) 267: 36–48.
- [7] Brun A., Godard A., Moreau Y., La vaccination contre la myxomatose: vaccins hétérologues et

- homologues, Bull. Soc. Vet. Med. Comp. (1981) 83:251–254.
- [8] Cao J.X., Upton C., gpt-gus fusion gene for selection and marker in recombinant poxviruses, Biotechniques (1997) 22:276–278.
- [9] Fenner F., Woodroffe G.M., Protection of laboratory rabbits against myxomatosis by vaccination with fibroma virus, Aust. J. Exp. Biol. Med. Sci. (1954) 32:653–668.
- [10] Fenner F., Ratcliffe F.N., Myxomatosis, Cambridge University Press, Cambridge, UK, 1965.
- [11] Fenner F., Fantini B., Biological control of vertebrate pests. The history of myxomatosis — an experiment in evolution, CAB International, Wallingford, UK, 1999.
- [12] Fountain S., Holland M.K., Hinds L.A., Janssens P.A., Kerr P.J., Interstitial orchitis with impaired steroidogenesis and spermatogenesis in the testes of rabbits infected with an attenuated strain of myxoma virus, J. Reprod. Fertil. (1997) 110:161–169.
- [13] Górski J., Mizak B., Chrobocińska M., Control of rabbit myxomatosis in Poland, Rev. Off. Int. Epizoot. (1994) 13:869–879.
- [14] Jerabek J., Applicability of Shope fibroma virus replicated in cell cultures for immunoprophylaxis of rabbit myxomatosis, Acta Vet. Brno (1980) 49:259–267.
- [15] Kerr P.J., An ELISA for epidemiological studies of myxomatosis: persistence of antibodies to myxoma virus in European rabbits (*Oryctolagus cuniculus*), Wildl. Res. (1997) 24:53–65.
- [16] Kerr P.J., Perkins H.D., Inglis B., Stagg R., McLaughlin E., Collins S.V., van Leeuwen B.H., Expression of rabbit IL-4 by recombinant myxoma viruses enhances virulence and overcomes genetic resistance to myxomatosis, Virology (2004) 324:117–128.
- [17] Mackenzie S.M., McLaughlin E.A., Perkins H.D., French N., Sutherland T., Jackson R.J., et al., Immuno-contraceptive effects on female rabbits infected with recombinant myxoma virus expressing rabbit ZP2 and ZP3, Biol. Reprod. (2006) 74:511–521.
- [18] Marlier D., Mainil J., Boucraut-Baralon C., Linden A., Vindevogel H., The efficacy of two vaccination schemes against experimental infection with a virulent amyomatous or a virulent nodular myxoma virus strain, J. Comp. Pathol. (2000) 122: 115–122.
- [19] McCurdy L.H., Larkin B.D., Martin J.E., Graham B.S., Modified vaccinia Ankara: potential as a smallpox vaccine, Clin. Infect. Dis. (2004) 38:1749–1753.
- [20] Mckercher D.G., Saito J.K., An attenuated live virus vaccine for myxomatosis, Nature (1964) 202:933–934.
- [21] Meng X., Chao J., Xiang Y., Identification from diverse mammalian poxviruses of host-range regulatory genes functioning equivalently to vaccinia virus C7L, Virology (2008) 372:372–383.
- [22] Myktyowycz R., An attenuated strain of the myxomatosis virus recovered from the field, Nature (1953) 172:448–449.
- [23] Picavet D.P., Lebas F., Gilbert E., Brignol E., Immunisation of rabbits against myxomatosis with an homologous vaccine, Rev. Med. Vet. (1989) 140:823–827 (in French).
- [24] Ramsey-Ewing A.L., Moss B., Complementation of a vaccinia virus host-range K1L gene deletion by the non-homologous CP77 gene, Virology (1996) 222: 75–86.
- [25] Robinson A.J., Müller W.J., Braid A.L., Kerr P.J., The effect of buprenorphine on the course of disease in laboratory rabbits infected with myxoma virus, Lab. Anim. (1999) 33:252–257.
- [26] Russell R.J., Robbins S.J., Cloning and molecular characterization of the myxoma virus genome, Virology (1989) 170:147–159.
- [27] Saurat P., Gilbert Y., Ganiere J.-P., Study on myxomatous virus modified strain, Rev. Med. Vet. (1978) 129:415–451 (in French).
- [28] Stanford M.M., Werden S.J., McFadden G., Myxoma virus in the European rabbit: interactions between the virus and its susceptible host, Vet. Res. (2007) 38:299–318.
- [29] Torres J.M., Ramírez M.A., Morales M., Bárcena J., Vázquez B., Espuña E., et al., Safety evaluation of a recombinant myxoma-RHDV virus inducing horizontal transmissible protection against myxomatosis and rabbit haemorrhagic disease, Vaccine (2000) 19:174–182.
- [30] Torres J.M., Sánchez C., Ramírez M.A., Morales M., Bárcena J., Ferrer J., et al., First field trial of a transmissible recombinant vaccine against myxomatosis and rabbit hemorrhagic disease, Vaccine (2001) 19:4536–4543.