



HAL
open science

Apoptosis of polymorphonuclear leukocytes of the juvenile bovine mammary gland during induced influx

Zbyšek Sládek, Dušan Ryšánek

► **To cite this version:**

Zbyšek Sládek, Dušan Ryšánek. Apoptosis of polymorphonuclear leukocytes of the juvenile bovine mammary gland during induced influx. *Veterinary Research*, 2000, 31 (6), pp.553-563. 10.1051/vetres:2000139 . hal-00902676

HAL Id: hal-00902676

<https://hal.science/hal-00902676>

Submitted on 11 May 2020

HAL is a multi-disciplinary open access archive for the deposit and dissemination of scientific research documents, whether they are published or not. The documents may come from teaching and research institutions in France or abroad, or from public or private research centers.

L'archive ouverte pluridisciplinaire **HAL**, est destinée au dépôt et à la diffusion de documents scientifiques de niveau recherche, publiés ou non, émanant des établissements d'enseignement et de recherche français ou étrangers, des laboratoires publics ou privés.

Apoptosis of polymorphonuclear leukocytes of the juvenile bovine mammary gland during induced influx

Zbyšek SLÁDEK^{a*}, Dušan RYŠÁNEK^b

^a Department of Morphology, Physiology and Veterinary Sciences,
Mendel University of Agriculture and Forestry, Zemědělská 1, 613 00 Brno, Czech Republic
^b Veterinary Research Institute, Hudcova 70, 621 32 Brno, Czech Republic

(Received 2 March 2000; accepted 28 June 2000)

Abstract – The dynamics of apoptosis of polymorphonuclear leukocytes (PMN) during induced influx of PMN into the cavity system of the juvenile bovine mammary gland in order to investigate the role of apoptosis of PMN in the resolution of mastitis was studied. The instillation of a synthetic analogue of muramyl dipeptide into teat sinus of the sixteen mammary glands was followed by a massive influx of PMN culminating after 24 h and resolving after 96 h. Every 24 h following the influx, apoptotic PMN were microscopically detected, based on morphological characteristics. Twenty four hours after the stimulation, apoptotic PMN were already observed, and peak counts of apoptotic PMN were reached 48 h after the stimulation. The lowest differential count of apoptotic PMN, corresponding to the pre-stimulation value, was found 96 h after the stimulation. The presence of macrophages (MAC) containing phagocytized apoptotic PMN was observed by histochemical staining for myeloperoxidase (MPO) and electron microscopy. The percentage of MPO-positive macrophages increased during the resolution phase to reach peak values 48 h after the stimulation. Apoptosis of PMN and phagocytosis by macrophages may represent a removal mechanism that is important in the resolution of the induced influx of PMN in the cavity system of juvenile bovine mammary gland.

polymorphonuclear leukocyte / macrophage / apoptosis / juvenile bovine mammary gland

Résumé – Apoptose des leucocytes polymorphonucléaires de la glande mammaire juvénile des bovins durant l'influx induit. Afin de déterminer le rôle de l'apoptose dans la résolution des mammites, la dynamique de l'apoptose des leucocytes polymorphonucléaires (PMN) durant l'influx induit dans le système des cavités de la glande mammaire juvénile des bovins a été étudiée. L'application du dérivé synthétique du muramyl dipeptide dans le sinus du trayon de la glande mammaire a été suivi de l'influx massif de PMN avec un pic à 24 h et une résolution 96 heures après la stimulation. Au cours des 24, 48, 72 et 96 h après la stimulation, les suspensions cellulaires ont été examinées

* Correspondence and reprints
Tel.: (42) 0 5 4513 3151; fax: (42) 0 5 4521128; e-mail: sladekz@seznam.cz

en microscopie optique pour détecter l'apoptose des PMN. L'identification des PMN apoptotiques a été réalisée à partir des caractéristiques morphologiques. Les PMN apoptotiques ont été observés dès 24 h après la stimulation et ont atteint un pic à 48 h. La proportion la plus faible de PMN apoptotiques a été observée au bout de 96 h après la stimulation, ce qui correspondait aux valeurs obtenues avant stimulation. La présence des macrophages contenant des PMN phagocytés apoptotiques a été révélée par coloration histochemique à la myéloperoxydase (MPO) et par microscopie électronique. Durant la phase de résolution les macrophages MPO positifs ont atteint un pic 48 h après la stimulation. L'apoptose des PMN et la phagocytose par les macrophages semble représenter un mécanisme de débâlement important dans la résolution de l'influx induit des PMN dans le système des cavités de la glande mammaire juvénile.

leucocyte polymorphonucléaire / macrophage / apoptose / glande mammaire juvénile des bovins

1. INTRODUCTION

One of the significant defense factors of the mammary gland is polymorphonuclear leukocytes (PMN). Chemotactic agents induce their migration from the blood circulation through tissues into the cavity system of the mammary gland where they act as phagocytes [27].

The life span of PMN migrating in tissues is only 1 to 2 days [37]. Thereafter, they undergo either apoptosis [30], or necrosis as an alternative form of cell death [12].

Apoptosis [16] is an active process involving gene transcription and protein synthesis which trigger a sequence of events resulting in typical morphological and biochemical changes including nuclear chromatin condensation (karyopyknosis), cell shrinking, blebbing of the cytoplasmic membrane (zeiosis), break-up of DNA into 180- to 200-base fragments, and the final cell fragmentation into apoptotic bodies [43, 44]. Apoptosis of PMN differs from necrosis. During the onset of apoptosis, the organelles and the cytoplasmic membrane remain intact and the histotoxic content of granules is not released into the extracellular compartment [6, 9, 33]. Moreover, apoptotic PMN are promptly removed by the macrophages (MAC) before they can support the development of cellular damage [33].

Necrosis of PMN is induced if the cells are affected by apoptosis-blocking signals.

It results in a release of the histotoxic content of granules and subsequent damage to the surrounding tissue [42]. Necrotic PMN are not quickly removed by MAC.

The role of apoptosis in the fate of PMN *in vivo* has been described in human [8, 31, 33] and in laboratory animals [7, 11, 13, 14, 22, 45], but no data on the role of *in vivo* apoptosis in the fate of PMN in the juvenile bovine mammary gland were found in the available literature. Hence, necrosis has been the only process of PMN death in the cavity system of the mammary gland described so far [19, 24–26].

In addition to degeneration and necrosis, apoptosis of PMN was observed as another process of cell death in our earlier experiments [36]. This finding indicates that two forms of extinction of PMN from the cavity system of the juvenile bovine mammary gland exist.

The fate of PMN in the juvenile bovine mammary gland can be studied if influx of the cells into the cavity system of the mammary gland is induced. Wardley et al. [40] were the first to use the method of induced influx into the juvenile bovine mammary gland to obtain cells for *in vitro* studies. However, their paper does not describe the mechanism of influx of PMN and its biological significance. The role of apoptosis of PMN in the dynamics of cell influx was defined later, after its mechanism in cells of the myeloid series had been recognized

and is described in human patients suffering from acute arthritis [33].

The objective of this paper was to define the role of apoptosis of PMN and its dynamics during the induced influx of PMN into the cavity system of the juvenile bovine mammary gland and thus to provide a basis for subsequent studies on the role of apoptosis of PMN in the resolution of mastitis.

2. MATERIALS AND METHODS

2.1. Animals

The dynamics of apoptosis of PMN were studied in 16 mammary glands of clinically normal unbred Holstein × Bohemian Red Pied heifers aged 16 to 18 months.

2.2. Induced influx model

Modified ureteral catheters (AC53061H06, Porges S.A., France) were inserted into the teat canal after thorough disinfection of the teat orifice with petrolalcohol and the mammary gland was rinsed with 20 mL of sterile buffered 0.01 M saline (PBS), pH 7.4. The rinsing was followed by intramammary instillation of 500 µg of a synthetic muramyl dipeptide analogue (nor MurANc-L-Abu-D-IzoGln, supplied by the Institute of Organic Chemistry and Biochemistry, the Academy of Sciences of the Czech Republic, Praha) dissolved in 10 mL PBS. After 24 to 96 h (see the next paragraph) the mammary glands were rinsed again with 20 mL of PBS heated to 37 °C.

2.3. Experimental design

All four mammary glands of each heifer were rinsed and the cell suspensions obtained were used as the controls. Thereafter, the mammary glands were stimulated

to induce cell influx. The first cell sample was obtained by lavage of the left fore-quarter 24 h after the stimulation. The remaining quarters were rinsed stepwise at 24 h intervals in the following order: left rear → right front → right rear. The resulting mammary lavages (ML) were designated in terms of the before and post-stimulation intervals as control (pre-stimulatory), ML24, ML48, ML72, and ML96. From control samples and samples taken every 24 h following stimulation of the mammary gland, bacteriological tests, cell viability tests and determination of absolute cell counts were done. Cell suspensions were prepared for the detection of apoptosis by light microscopy and for histochemical examination.

Samples of all the ML were inoculated on blood agar containing 5% washed ram erythrocytes and incubated anaerobically at 37 °C for 24 h [29]. No bacteria were detected in any of the tested ML. Absolute cell counts were determined using the conventional haemocytometer. Cell viability, assessed by the trypan blue exclusion test, exceeded 97% in all the ML. The suspensions were centrifuged at 200 × *g* and 4 °C for 10 min. The uppermost 1 mL portion of the supernatant was separated and used for resuspension of the sediment after removing the rest of the supernatant.

2.4. Light microscopy

Two smears of each cell suspension were stained panoptically by the Pappenheim method [2]. Differential leukocyte counts were assessed by enumeration of 200 cells in each smear. PMN apoptosis was assessed at oil-immersion microscopy (magnification factor of objective ×100) by identifying nuclear changes, including condensation of chromatin and simplification nuclear structure, and furthermore cell vacuolisation and shrinking, characteristic of apoptosis [36].

2.5. Histochemistry

The interaction of MAC with apoptotic PMN was assessed by staining for myeloperoxidase (MPO). Briefly, two smears of ML of each mammary gland were prepared, dried, fixed for 5 min in 2% glutaraldehyde dissolved in PBS, and stained with dimethoxybenzidine (O-dianisidine HCl, Sigma Chemical Co., Praha, Czech Republic) and hydrogen peroxide [10] and subsequently with diluted Giemsa-Romanowski stain using our own modification [36].

After enumeration of 200 MAC in each slide, the interaction of MAC with apoptotic PMN was quantified calculating the percentage of MPO-positive MAC out of the total MAC number. Moreover, percentages of MAC containing distinguishable recently phagocytized apoptotic PMN and MAC with indistinguishable phagocytized apoptotic PMN showing a granular distribution of the MPO-positive material in the cytoplasm were calculated.

2.6. Transmission electron microscopy

For transmission electron microscopy the ML cells were prepared according to the procedure we described previously [35].

2.7. Statistics

Basic statistics, Student's t-test and correlation analysis are performed on software

STATPLUS (Veterinary Research Institute, Brno, Czech Republic).

3. RESULTS

3.1. Dynamics of cell counts and percentages during induced influx

The instillation of the synthetic muramyl dipeptide analogue into the cavity system of the juvenile bovine mammary gland induced a prompt and massive influx of leukocytes which culminated after 24 h when it rose from the initial absolute cell count $1.4 \pm 0.25 \times 10^6$ per mL in control to $51.4 \pm 3.25 \times 10^6$ per mL in ML24. The subsequent stepwise resolution of the influx was characterised by a decrease in absolute cell counts in ML48–ML96. An almost tenfold decrease between ML24 to ML96 is shown in Figure 1. As identified by light and electron microscopy, the cell populations consisted of PMN, MAC and other cells (OC) including lymphocytes, epithelial and unidentifiable cells.

A dominating percentage of MAC (70.3%) and a rather low percentage of PMN (2.5%) were characteristic of the control cell population. On the contrary, PMN highly predominated the cell population of ML24 (91.6% for PMN vs. 6.1% for MAC). The PMN:MAC ratio was almost inverse at that time. A stepwise decrease in the percentage of PMN (66.9% to 32.2%) and increase in the percentage of MAC (26.4% to 54.7%) was observed in the cell popula-

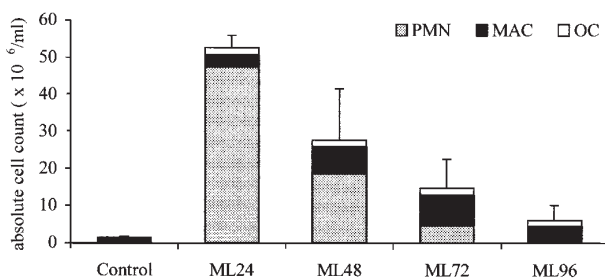


Figure 1. Cell counts in mammary lavages (ML) obtained from control and stimulated quarters 24 h (ML24), 48 h (ML48), 72 h (ML72) and 96 h (ML96) after stimulation with muramyl dipeptide (500 µg per intramammary instillation). Results represent the mean \pm SD for four heifers/time point.

tions of ML48–ML72. Moreover, the decrease in the percentage of PMN coincided with the decrease in absolute cell counts (Fig. 1). The differential cell count in ML96 was characterised by a marked predominance of MAC (71.3%) over PMN (5.4%). The MAC:PMN ratio approached its initial value of control.

3.2. Dynamics of PMN apoptosis during induced influx

No apoptotic cells were found in the PMN population in the control. PMN showing morphological features of apoptosis appeared in the cell population of ML24, i.e. at the time of PMN influx culmination. At 24 h after stimulation, MAC containing the phagocytized apoptotic PMN in their cytoplasm were observed (see below). The proportion of apoptotic PMN was maximal in ML48. The lowest percentage of apoptotic PMN was found in ML96 (72 h after the influx culmination) when the resolution of the PMN influx approached its end. Data on dynamics of apoptosis in the control through ML96 are given in Figure 2. Necrotic PMN were observed too. However, the proportion of necrotic PMN was less than 3% every time after stimulation.

3.3. Phagocytosis of apoptotic PMN during induced influx

As mentioned above, no apoptotic PMN and no signs of their phagocytosis by MAC

were observed in the cell population of the control. All the MAC were MPO-negative. On the contrary, approximately 10% of MAC were MPO-positive in ML24. The distribution pattern of the MPO-positive material showed that less than 50% of them contained recently phagocytized PMN with pyknotic nuclei.

The highest percentage of all MPO-positive MAC ($38.6 \pm 5.9\%$) was found in the cell population of ML48. Thereafter, this percentage decreased (Fig. 3).

Irrespective of the lavage time, the percentage of all MPO-positive MAC (MPO-positive MAC containing distinguishable phagocytized apoptotic PMN and MPO-positive MAC with granular distribution of the MPO-positive material in their cytoplasm) correlated significantly with the percentage of apoptotic PMN ($r = 0.76$; $P = 0.01$; $n = 16$). Like total MPO-positive MAC, the highest percentage of the MPO-positive MAC containing phagocytized PMN and MPO-positive MAC with granular distribution of the MPO-positive material in their cytoplasm coincided with the peak of apoptotic PMN, at 48 h after the stimulation (see Figs. 2 and 3).

Most of the phagocytising MAC contained more than one apoptotic PMN (Fig. 4) and major parts of apoptotic PMN were present inside the MAC. Most of the engulfed PMN showed karyopyknosis as an early morphological sign of apoptosis. However, solitary phagocytized PMN with segmented nuclei and lacking morphological features of apoptosis were observed too.

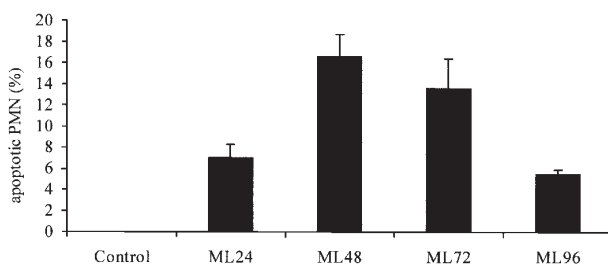


Figure 2. The relative proportion of apoptotic PMN from total PMN in mammary lavages obtained from control and various time points between 24 h (ML24) and 96 h (ML96) after stimulation with muramyl dipeptide (500 μg per intramammary instillation). Data show mean \pm SD for four heifers/time point.

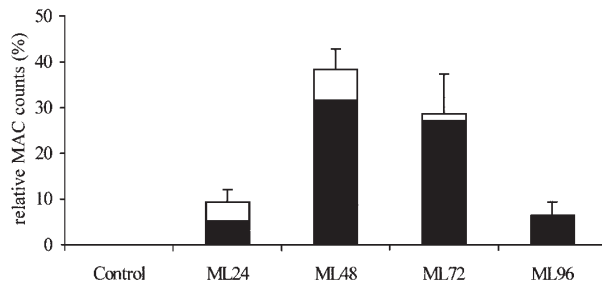


Figure 3. The relative proportion of MPO-positive MAC with granular distribution of the MPO-positive material in their cytoplasm (filled ■) and MPO positive MAC containing distinguishable phagocytized apoptotic PMN (open □) from total MAC count in mammary gland lavages obtained from control and various time points between 24 h (ML24) and 96 h (ML96) after stimulation with muramyl dipeptide (500 µg per intramammary instillation). Data are presented as mean ± SD for four heifers/time point.

3.4. Transmission electron microscopy of phagocytosis of apoptotic PMN

The presence and degradation of apoptotic PMN in the cytoplasm of MAC were confirmed by transmission electron microscopy. The apoptotic PMN present in phagosomes and phagolysosomes of MAC showed various stages of degradation of their nuclear and cytoplasmic components, and of morphological signs of apoptosis (Fig. 4).

4. DISCUSSION

This paper defines the role of apoptosis of PMN and describes its dynamics during the induced influx of leukocytes into the cavity system of the juvenile bovine mammary gland. No data on the quantitative aspects of PMN apoptosis during the induced influx of PMN into the bovine mammary gland were found in the available literature.

Stimulation of the mammary gland by instillation of a synthetic muramyl dipeptide analogue induced a massive influx of leukocytes among which PMN predominated. Fading of the effect of this chemoattractant was accompanied by a marked

decrease of both absolute and relative PMN counts, and MAC predominated again in the cell population 96 h after the stimulation. Our data fully agreed with the findings of Wardley et al. [40]. However, Wardley et al. [40] did not discuss a possible explanation for the resolution of the induced influx.

The instillation of the chemoattractant initiates migration and subsequently a massive accumulation of PMN in the cavity system of the mammary gland. Since the life span of these leukocytes is rather short, approximately one to two days [37], it can be assumed that PMN showing morphological signs of apoptosis will appear in the cavity system. Moreover, this cell type is predestined for apoptosis after leaving the blood stream [30].

In this study, PMN with structural and ultrastructural changes typical of apoptosis already appeared 24 h after the stimulation. The signs included particularly chromatin condensation (karyopyknosis), cytoplasm condensation, zeiosis, intact organelles and fragmentation into apoptotic bodies. Identical signs of *in vivo* apoptosis of PMN were described in human patients suffering from acute arthritis [33], in lungs of newborn babies [8], in rat lungs [7, 13, 14] and

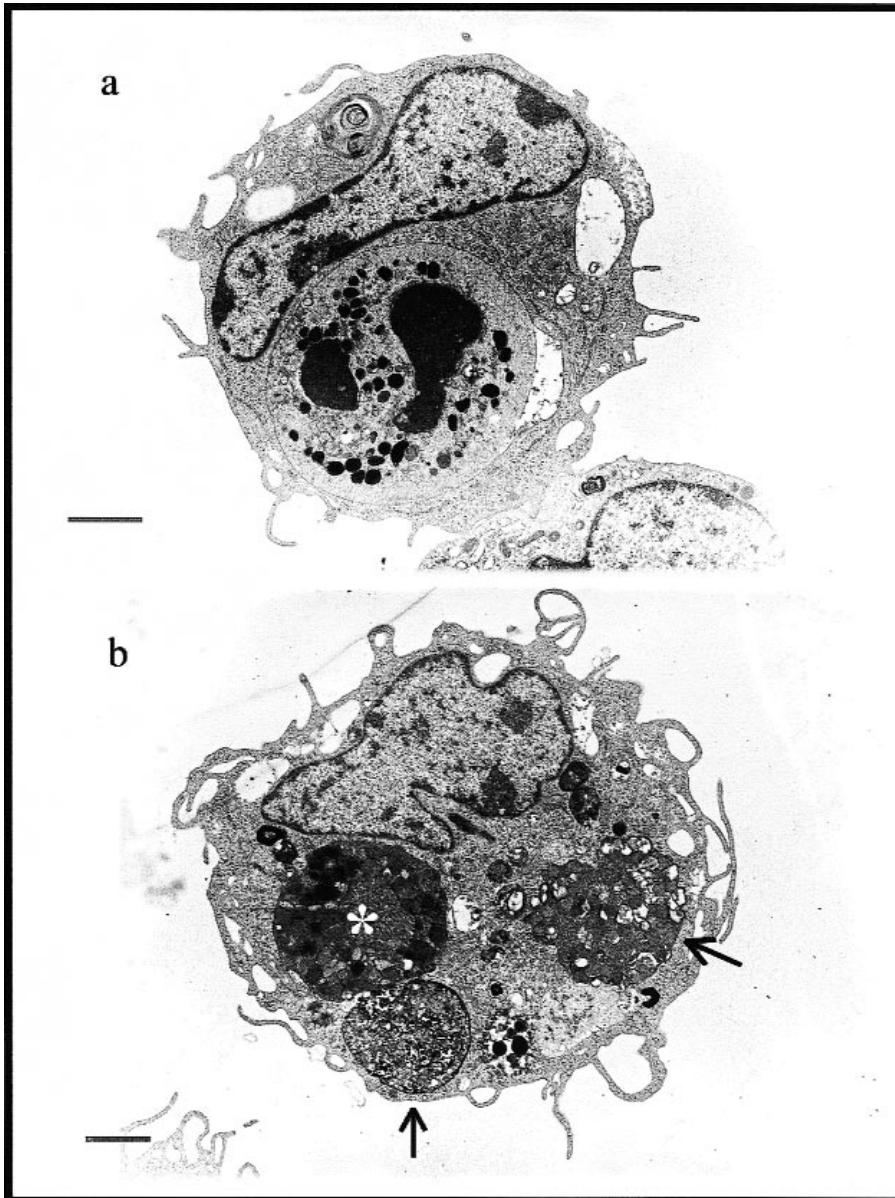


Figure 4. Electron micrograph of mammary gland lavage MAC obtained 48 h (ML48) after stimulation with muramyl dipeptide (500 μg per intramammary instillation). Panel (a) shows MAC containing a phagocytized PMN with ultrastructural characteristics typical of apoptosis, including chromatin and cytoplasm condensation and intact granules and cytoplasmic membrane. Most probably, the picture shows a recently phagocytized PMN still lacking signs of degradation. Panel (b) shows MAC containing three phagocytized PMN at various stages of degradation: an apoptotic PMN with distinguishable intact granules in condensed cytoplasm and an already degenerated nucleus (asterisk) and two apoptotic PMN in an advanced stage of destruction reflecting the active processing by MAC (arrows). Bar = 2 μm .

kidneys [11, 34], in the peritoneal cavity of guinea pigs [45], and in a rat model of experimental wound [22]. Our observations demonstrate that apoptosis of PMN also occurs during induced influx of leukocytes into the cavity system of juvenile bovine mammary glands.

While the influx culminated 24 h after the stimulation, the percentage of apoptotic PMN reached its maximum 24 h later. This delay probably coincides with the general idea that viable PMN are recruited from the blood stream into the cavity system of the mammary gland at various stages of their life cycle. When leaving the blood stream, PMN also lose their energy sources and, after a certain time, undergo apoptosis. The timing of apoptosis of bovine mammary PMN *in vivo* can be estimated from known detailed data on human blood PMN [28, 33] or bovine blood PMN [38] *in vitro*. The first signs of *in vitro* apoptosis of human PMN already appear after 3 to 4 h, and 40 to 60% of apoptotic cells were observed after 24 h of culture [28, 33].

In contrast to *in vitro* conditions, the *in vivo* survival of PMN in the cavity system of the mammary gland will probably also be influenced by other factors than the transendothelial migration [41] and exposure to cytokines [3, 5], or chemokines [17]. It is therefore very probable that the finding of the relatively low percentage of apoptotic PMN in ML was due to biochemical factors of the microenvironment in the cavity system of the juvenile bovine mammary gland, which delay PMN apoptosis.

The relatively low percentage of apoptotic PMN in ML24–ML96 also resulted from the fact that they were promptly recognised and phagocytized by local MAC. This assumption was confirmed by electron microscopy. The potential of a rapid and intensive phagocytosis of apoptotic PMN and their subsequent degradation were quantified by staining for MPO. The distribution pattern of MPO in the phagocytising MAC markedly resembles the *in vitro* engulfing

and degradation of apoptotic PMN in MAC. *In vitro* studies by Newman et al. [23] and Savill et al. [33] have confirmed that, compared with the relatively slow development of morphological signs of apoptosis, the processes of recognition, engulfing and degradation in phagolysosomes of MAC are relatively rapid. As reported by Savill et al. [33], apoptotic PMN are engulfed by MAC within the first 15 min after contact and degraded in phagolysosomes within another 30 min. In a subsequent study [32], this author demonstrated that PMN can be phagocytized by MAC during the early stage of apoptosis when the cytoplasmic membrane is still intact. This fact was also confirmed in juvenile mammary glands. A modification of the staining method for MPO and electron microscopy allowed us to observe non-degraded PMN with pyknotic nuclei in the cytoplasm of recently phagocytized MAC. This finding demonstrates that many of the cells undergoing apoptosis are already engulfed and degraded in MAC (see also [33]). Therefore, most of the MPO positive MAC showed a granular pattern of MPO distribution. However, solitary phagocytized PMN with segmented nuclei and lacking morphological features of apoptosis were observed too. This finding indicates that, in some PMN, the phagocytosis and the subsequent elimination of PMN was a rapid process, finishing before the morphological features of PMN apoptosis had fully developed.

We assessed the relatively low counts of apoptotic PMN in all the ML. It should be kept in mind that both the phagocytosis of apoptotic PMN and apoptosis itself are very rapid processes that led to a steep decrease in absolute PMN counts. The decrease is linear and we assumed that is caused by apoptosis only. Hypothetical calculation leads us to the number of 16 000 PMN per mL undergoing apoptosis each minute. Compared with the data published by other authors [20, 22], this value is acceptable.

The minor role of necrosis in the removal of PMN during the resolution of PMN influx

into the juvenile bovine mammary gland is evident from the smaller proportion of necrotic PMN and the significant correlation between the percentages of apoptotic PMN and MPO-positive MAC. Anyhow, the fact that a part of the PMN population in the juvenile bovine mammary gland underwent necrosis indicates firstly the existence of factors that modulate the apoptotic programme and shorten the life span of PMN, and secondly, that apoptotic PMN will undergo secondary necrosis if not enough MAC are available to phagocytose them (for example in ML24: 3×10^6 apoptotic PMN versus 0.3×10^6 MPO-positive MAC). Hypothetically, the higher proportion of necrotic PMN may have prolonged the resolution period. Necrotic PMN release the histotoxic content of PMN granules [42] which is a strong chemotactic agent enhancing the migration of more PMN from the blood into the cavity system of the mammary gland [15]. Capuco et al. [4] demonstrated that lysosomal release from PMN is damaging to bovine mammary parenchymal tissue. Moreover, enzymes present in the content degrade proteins to chemotactic intermediates enhancing the influx of further migrating cells which potentiate the inflammatory reaction [39].

Savill et al. [33] demonstrated that an increase in the percentage of apoptotic PMN is paralleled by an increase in the percentage of phagocytosing MAC. The rate of PMN apoptosis is controlled by the amount of PMN accessible to recognition and phagocytosis by MAC [31]. This observation was confirmed by our findings in ML24–ML96 where the increase in the apoptotic PMN percentage was accompanied by an increase in the percentage of MPO-positive MAC. The presence of MPO-positive MAC in ML24 indicates that the clearing of apoptotic cells began before the first lavage done 24 h after the stimulation. The percentage of MPO-positive MAC increased and reached its maximum in ML48. This peak coincided with the culmination of PMN clearance. This finding shifted the onset of

resolution of the PMN influx, indicated by the presence of apoptotic cells and their clearing from the cavity system of the juvenile mammary gland by phagocytosing MAC.

The marked decrease in the percentage of MPO-positive MAC and the coincident increase in the total number of MAC in ML96 when compared with ML72 are worth mentioning. We assume that this was a sign of finishing clearance of apoptotic PMN, migration of fresh MAC from the surrounding tissues into the cavity system of the mammary gland, and emigration of MPO-positive MAC into regional lymph nodes of the mammary gland. This hypothesis is based on the assumption that, during their life time, MAC undergo a two-step migration process necessary for completing their function in tissues. First, MAC migrate from blood to tissues to phagocytize alien materials and then emigrate into the regional lymph nodes where they present the potential antigen. This process subsequently influences the initiation and enhancement of immune response to potential antigens in tissues [1]. Our hypothesis is supported by the fact that migration of MAC from blood into the cavity system of the mammary gland and their subsequent emigration into regional lymph nodes of the udder have already been described in cows at the stage of mammary gland involution [18].

It can be concluded that induced influx of leukocytes into the cavity system of the mammary gland results in an accumulation of a large amount of PMN. Due to their short life span and inability to re-emigrate into the blood stream [11], PMN undergo apoptosis and are promptly phagocytized by MAC. This event results in a decrease in absolute count and percentage of apoptotic PMN, or, in other words, in resolution of the influx. No histotoxic content of granules is released into surrounding tissues from apoptotic PMN [32] and the subsequent phagocytosis does not initiate a release of pro-inflammatory mediators from MAC [21]. Therefore apoptosis and the

subsequent phagocytosis of apoptotic PMN by MAC represent a non-inflammatory mechanism of resolution of induced PMN influx into the cavity system of the juvenile bovine mammary gland.

The question remains whether apoptosis of PMN and the subsequent elimination by MAC from the cavity system of the juvenile bovine mammary gland are specific responses to the chemoattractant used in our experiment, or whether they can be interpreted as a general response to other forms of damage to this organ.

ACKNOWLEDGEMENTS

The authors gratefully appreciate Dr. A. Meszaros' valuable comments on the manuscript and her methodological assistance. The authors also wish to thank the staff of the Institute of Histology and Embryology of the Faculty of Medicine, Masaryk University, Brno, for the processing of samples and preparation of objects for transmission electron microscopy.

REFERENCES

- [1] Bellingan G.J., Caldwell H., Howie S.E.M., Dransfield I., Haslett C.H., In vivo fate of the inflammatory macrophage during the resolution of inflammation. Inflammatory macrophages do not die locally, but emigrate to the draining lymph nodes, *J. Immunol.* 157 (1996) 2577-2585.
- [2] Bessis M., Living blood cells and their ultrastructure, Springer-Verlag, New York, 1973.
- [3] Biffl W.L., Moore E.E., Moore F.A., Barnet C.C. Jr., Interleukin-6 suppression of neutrophil apoptosis concentration dependent, *J. Leukocyte Biol.* 58 (1995) 582-584.
- [4] Capuco A.V., Paape M.J., Nickerson S.C., In vitro study of polymorphonuclear leukocyte damage to mammary tissue of lactating cows, *Am. J. Vet. Res.* 47 (1986) 663-669.
- [5] Colotta F., Re F., Polentarutti N., Sozzani S., Mantovani A., Modulation of granulocyte survival and programmed cell death by cytokines and bacterial products, *Blood* 80 (1992) 2012-2020.
- [6] Cooter T.G., Fernandes R.S., Verhaegen S., McCarthy J.V., Cell death in the myeloid lineage, *Immunol. Rev.* 142 (1994) 93-112.
- [7] Cox G., Crossley J., Xing Z., Macrophage engulfment of apoptotic neutrophils contributes to the resolution of acute pulmonary inflammation in vivo, *Am. J. Respir. Cell Mol. Biol.* 12 (1995) 232-237.
- [8] Grigg J.M., Savill J.S., Sarraf C., Haslett C.H., Silverman M., Neutrophil apoptosis and clearance from neonatal lungs, *Lancet* 338 (1991) 720-722.
- [9] Haanen C., Vermes I., Apoptosis and inflammation, *Mediators Inflamm.* 4 (1995) 5-15.
- [10] Henson P.M., Zanolari B., Schwartzman N.A., Hong S.R., Intracellular control of human neutrophil secretion. I. C5a-induced stimulus-specific desensitisation and effect of cytochalasin B, *J. Immunol.* 121 (1978) 851-855.
- [11] Hughes J., Johnson R., Mooney A., Hugo C., Gordon K., Savill J., Neutrophil fate in experimental glomerular capillary injury in the rat, *Am. J. Pathol.* 150 (1997) 223-234.
- [12] Hurley J.V., Termination of acute inflammation: resolution, in: Hurley J.V. (Ed.), *Acute inflammation*, Churchill Livingstone, London, 1983, pp. 109-117.
- [13] Hussain N., Wu F., Zhu L., Thrall R.S., Kresch M.J., Neutrophil apoptosis during the development and resolution of oleic acid-induced acute lung injury in the rat, *Am. J. Respir. Cell Mol. Biol.* 19 (1998) 867-874.
- [14] Ishii Y., Hashimoto K., Nomura A., Sakamoto T., Uchida Y., Ohtsuka M., Hasegawa S., Sagai M., Elimination of neutrophils by apoptosis during the resolution of acute pulmonary inflammation in rats, *Lung* 176 (1998) 89-98.
- [15] Jain N.C., Lasmanis L., Phagocytosis of serum-resistant coliform bacteria (*Klebsiella*) by bovine neutrophils from blood and mastitic milk, *Am. J. Vet. Res.* 39 (1978) 425-427.
- [16] Kerr J.F.R., Wyllie A.H., Currie A.R., Apoptosis: a basic biological phenomenon with wide-ranging implications in tissue kinetics, *Br. J. Cancer* 68 (1972) 239-257.
- [17] Kettritz R., Gaido M.L., Haller H., Luft F.C., Jannette C.J., Falk R.J., Interleukin-8 delays spontaneous and tumor necrosis factor- α mediated apoptosis of human neutrophils, *Kidney Int.* 53 (1998) 84-91.
- [18] Lee C.S., McDowell G.H., Lascelles A.K., The importance of macrophages in the removal of fat from the involuting mammary gland, *Res. Vet. Sci.* 10 (1969) 34-38.
- [19] Lintner T.J., Eberhart R.J., Effects of antibiotics on phagocyte recruitment, function, and morphology in the bovine mammary gland during the early nonlactating period, *Am. J. Vet. Res.* 51 (1990) 533-542.
- [20] Majno G., Joris I., Apoptosis, oncosis, and necrosis: an overview of cell death, *Am. J. Pathol.* 146 (1995) 3-15.
- [21] Meagher L.C., Savill J., Baker A., Fuller R.W., Haslett C.H., Phagocytosis of apoptotic neutrophils does not induce macrophage release of

- thromboxan B₂, *J. Leukocyte Biol.* 52 (1992) 269-273.
- [22] Meszaros A.J., Reichner J.S., Albina J.E., Macrophage phagocytosis of wound neutrophils, *J. Leukocyte Biol.* 65 (1999) 35-42.
- [23] Newman S.L., Henson J.E., Henson P.M., Phagocytosis of senescent neutrophils by human monocyte-derived macrophages and rabbit inflammatory macrophages, *J. Exp. Med.* 156 (1982) 430-442.
- [24] Nickerson S.C., Paape M.J., Dulin A.M., Effect of antibiotics and vehicles on bovine mammary polymorphonuclear leukocyte morphologic features, viability, and phagocytic activity in vitro, *Am. J. Vet. Res.* 46 (1985) 2259-2265.
- [25] Nickerson S.C., Paape M.J., Harmon R.J., Ziv G., Mammary leukocyte response to drug therapy, *J. Dairy Sci.* 69 (1986) 1733-1742.
- [26] Paape M.J., Nickerson S.C., Ziv G., In vivo effect of chloramphenicol, tetracycline, and gentamicin on bovine neutrophil function and morphologic features, *Am. J. Vet. Res.* 51 (1990) 1055-1061.
- [27] Paape M.J., Guidry A.J., Jain N.C., Miller R.H., Leukocytic defense mechanisms in the udder, *Flemish Vet. J.* 62 (1991) 95-109.
- [28] Payne C.L., Glasser L., Tischler M.E., Wyckoff D., Cromey D., Fiederlein R., Bohnert O., Programmed cell death of the normal human neutrophil: An in vitro model of senescence, *Microsc. Res. Tech.* 28 (1994) 327-344.
- [29] Quinn P.J., Carter M.E., Markey M., Carter G.R., *Clinical veterinary microbiology*, MOSBY, London, 1994.
- [30] Raff M.C., Social controls on cell survival and cell death, *Nature* 356 (1992) 397-400.
- [31] Savill J., Macrophage recognition of senescent neutrophils, *Clin. Sci.* 83 (1992) 649-655.
- [32] Savill J., Apoptosis in disease, *Eur. J. Clin. Invest.* 24 (1994) 715-723.
- [33] Savill J., Wyllie A.H., Henson J.E., Walport M.J., Henson P.M., Haslett C.H., Macrophage phagocytosis of aging neutrophils in inflammation. Programmed cell death in the neutrophil leads to its recognition by macrophages, *J. Clin. Invest.* 83 (1989) 865-867.
- [34] Savill J., Smith J., Sarraf C., Ren Y., Abbott F., Rees A., Glomerular mesangial cells and inflammatory macrophages ingest neutrophils undergoing apoptosis, *Kidney Int.* 42 (1992) 924-936.
- [35] Sládek Z., Ryšánek D., Ultrastructure of phagocytes from mammary glands of non-pregnant heifers, *Anat. Histol. Embryol.* 28 (1999) 291-298.
- [36] Sládek Z., Ryšánek D., Morphology of apoptosis of polymorphonuclear leukocytes isolated from mammary glands of unbred heifers, *Vet. Med. Czech. J.* 3 (2000) 71-81.
- [37] Squier M.T., Sehnert A.J., Sellins K.S., Malkinson A.M., Takano E., Cohen J.J., Calpain and calpastain regulate neutrophil apoptosis, *J. Cell Physiol.* 178 (1999) 311-319.
- [38] van Oostveldt K., Dosogne H., Burvenich C., Paape M.J., Brochez V., van den Eeckhout E., Flow cytometric procedure to detect apoptosis of bovine polymorphonuclear leukocytes in blood, *Vet. Immunol. Immunopathol.* 70 (1999) 125-133.
- [39] Vartio T., Seppä H., Vaheri A., Susceptibility of soluble and matrix fibronectin to degradation by tissue proteinases, mast cell chymase and cathepsin G, *J. Biol. Chem.* 256 (1981) 440-442.
- [40] Wardley R.C., Rouse B.T., Babiuk L.A., The mammary gland of the ox: a convenient source for the repeated collection of neutrophils and macrophages, *J. Reticuloendothel. Soc.* 19 (1976) 29-36.
- [41] Watson R.W.G., Rotstein O.D., Nathens A.B., Parodo J., Marshall J.C., Neutrophil apoptosis is modulated by endothelial transmigration and adhesion molecule engagement, *J. Immunol.* 158 (1997) 945-953.
- [42] Weiss S.J., Tissue destruction by neutrophils, *New Engl. Med. J.* 320 (1989) 365-376.
- [43] Wyllie A.H., Kerr J.F.K., Currie A.R., Cell death: the significance of apoptosis, *Int. Rev. Cytol.* 68 (1980) 251-306.
- [44] Wyllie A.H., Morris R.G., Smith A.L., Dunlop D., Chromatin cleavage in apoptosis: association with condensed chromatin morphology and dependence on macromolecular synthesis, *J. Pathol.* 142 (1984) 67-77.
- [45] Yamamoto C.H., Yoshida S.I., Taniguchi H., Qin M.H., Maymoto H., Mizuguchi Y., Lipopolysaccharide and granulocyte colony-stimulating factor delay neutrophil apoptosis and ingestion by guinea pig macrophages, *Infect. Immun.* 61 (1993) 1972-1979.