



HAL
open science

Hyperimmune bovine colostrum treatment of moribund Leopard geckos (*Eublepharis macularius*) infected with *Cryptosporidium* sp

Thaddeus K. Graczyk, Michael R. Cranfield, Eileen F. Bostwick

► To cite this version:

Thaddeus K. Graczyk, Michael R. Cranfield, Eileen F. Bostwick. Hyperimmune bovine colostrum treatment of moribund Leopard geckos (*Eublepharis macularius*) infected with *Cryptosporidium* sp. *Veterinary Research*, 1999, 30 (4), pp.377-382. <hal-00902577>

HAL Id: hal-00902577

<https://hal.science/hal-00902577v1>

Submitted on 11 May 2020

HAL is a multi-disciplinary open access archive for the deposit and dissemination of scientific research documents, whether they are published or not. The documents may come from teaching and research institutions in France or abroad, or from public or private research centers.

L'archive ouverte pluridisciplinaire **HAL**, est destinée au dépôt et à la diffusion de documents scientifiques de niveau recherche, publiés ou non, émanant des établissements d'enseignement et de recherche français ou étrangers, des laboratoires publics ou privés.



HAL Authorization

Hyperimmune bovine colostrum treatment of moribund Leopard geckos (*Eublepharis macularius*) infected with *Cryptosporidium* sp.

Thaddeus K. Graczyk^{a,b,c,*}, Michael R. Cranfield^{b,d},
Eileen F. Bostwick^e

^a Department of Molecular Microbiology and Immunology, School of Hygiene and Public Health, Johns Hopkins University, 615 North Wolfe Street, Baltimore, MD 21205, USA

^b Medical Department, The Baltimore Zoo, Druid Hill Park, Baltimore, MD 21217, USA

^c Department of Environmental Health Sciences, School of Hygiene and Public Health, Johns Hopkins University, 615 North Wolfe Street, Baltimore, MD 21205, USA

^d Division of Comparative Medicine, School of Medicine, Johns Hopkins University, Baltimore, MD 21205, USA

^e GalaGen Inc., Arden Hills, MN 55126, USA

(Received 14 October 1998; accepted 9 February 1999)

Abstract – Therapy based on the protective passive immunity of hyperimmune bovine colostrum (HBC) was applied to 12 moribund Leopard geckos (*Eublepharis macularius*) infected with *Cryptosporidium* sp. The geckos were lethargic and moderately to severely emaciated, weighing on average 36 % of the baseline body weight value. Seven gastric HBC treatments at 1-week intervals each decreased the relative output of *Cryptosporidium* sp. oocysts and the prevalence of oocyst-positive fecal specimens. Histologically, after 8 weeks of therapy, seven out of 12 geckos had only single developmental stages of *Cryptosporidium* sp. in the intestinal epithelium, and three, one and one geckos had low, moderate and high numbers, respectively, of the pathogen developmental stages. The HBC therapy was efficacious in decreasing the parasite load in moribund geckos. Morphometric and immunologic analysis of *Cryptosporidium* sp. oocyst isolates originating from Leopard geckos (*E. macularius*) demonstrated differences between gecko-derived oocyst isolates and isolates of *C. serpentis* recovered from snakes. © Inra/Elsevier, Paris.

Cryptosporidium sp. / cryptosporidiosis / oocyst / hyperimmune bovine colostrum / gecko

Résumé – Traitement par du colostrum hyperimmun bovin de geckos léopards (*Eublepharis macularius*) moribonds, infectés par *Cryptosporidium* sp. Une thérapie basée sur le transfert d'immunité passive protectrice de colostrum hyperimmun bovin (CHB) a été appliquée à

* Correspondence and reprints

Tel.: (1) 410 614 4984; fax: (1) 410 955 0105; e-mail: tgraczyk@jhsph.edu

12 geckos léopards (*Eublepharis macularius*) moribonds, infectés par *Cryptosporidium* sp. Les geckos étaient léthargiques et modérément à sévèrement maigres, ne pesant en moyenne que 36 % de leur poids normal. Sept traitements gastriques de CHB, à une semaine d'intervalle chacun, ont fait baisser le taux d'excrétion d'ocystes de *Cryptosporidium* et la présence d'ocystes dans les selles. Histologiquement, après huit semaines de thérapie, sept des 12 geckos n'avaient qu'un stage de développement du *Cryptosporidium* dans leur épithélium intestinal, et trois, un et un geckos avaient respectivement des taux bas, modérés et élevés des stades de développement du pathogène. La thérapie CHB a été efficace pour rabaisser le taux de parasites chez les geckos moribonds. Des analyses morphométrique et immunologique des oocystes de *Cryptosporidium* provenant de geckos léopards (*E. macularius*) ont présenté des différences par rapport aux oocystes provenant de serpents (*C. serpentis*). © Inra/Elsevier, Paris.

Cryptosporidium sp. / cryptosporidiose / oocyste / colostrum hyperimmun bovin / gecko

1. INTRODUCTION

The high morbidity and frequent mortality caused by *Cryptosporidium* infections in snakes is due to the lack of safe and efficacious anticryptosporidial drugs [3, 4]. Protective passive immunity based on oral administration of hyperimmune bovine colostrum (HBC) was safe and efficacious in murine [1], ovine [15] and porcine [16] cryptosporidiosis. Heterologous protection of HBC has been demonstrated against *C. wrairi* infections in guinea pigs [14] and *C. serpentis* infections in snakes [13].

Although the reports on gekkonid cryptosporidiosis are scant, they always relate to high mortality. *Cryptosporidium* sp. oocysts were observed in squash preparations of the cloacae of moribund Madagascar giant day geckos (*Phelsuma madagascariensis grandis*) [18]. *Cryptosporidium* spp. oocysts have been recovered from the feces of moribund Sand geckos (*Chondrodactylus angulifer*) and Mediterranean geckos (*Hemidactylus turcicus turcicus*) [19]. *Cryptosporidium serpentis* infections have been histologically documented in the anterior of both stomach and small intestine of Leopard geckos (*Eublepharis macularius*) in a colony experiencing epizootic-type mortality [2].

Leopard geckos are enjoying explosive popularity as lizard-pets because of their small size, unlimited color patterns and appropriate temperament [2]. As the HBC

was safe and efficacious in clinical and sub-clinical cryptosporidiosis in snakes [13], we applied this treatment to *Cryptosporidium* sp.-infected moribund *E. macularius* to determine if the HBC therapy would decrease the output of *Cryptosporidium* sp. oocysts and rescue the moribund geckos from unavoidable death.

2. MATERIALS AND METHODS

Thirteen *E. macularius* originating from a private collection and infected with *Cryptosporidium* sp. were transported to the Baltimore Zoo (Baltimore, MD). All geckos were anorectic and moderately to severely emaciated; most of them were lethargic and all had their tails severely deficient of fat. All geckos had a history of persistent voiding of high numbers of *Cryptosporidium* sp. oocysts as determined by the acid-fast stain (AFS). Upon arrival, the geckos were classified into three categories depending on their body weight: $23 \pm \text{g}$ (moderate), $10 \pm \text{g}$ (poor) and $8 \pm \text{g}$ (very poor). Fecal specimens were collected at defecation from all geckos and examined for *Cryptosporidium* sp. oocysts by AFS and immunofluorescent antibody (IFA) of MERIFLUOR™ *Cryptosporidium*/*Giardia* test kit [9]. Twelve geckos were randomly, evenly divided into four treatment groups; the 13th gecko served as a control. The number of controls was minimized because the HBC treatment was aimed at rescuing geckos from death. Geckos were weighed and kept as described previously [2].

Liquid HBC was prepared as described previously [13]. The IgG content of the liquid colostrum was 58 mg/mL [13]. One half of the

liquid colostrum was lyophilized [6] resulting in powdered colostrum and both the liquid and the powder were stored for 3 week at -20°C until use.

Colostrum was administered to geckos by gastric intubation seven times at weekly intervals (figure 1). Geckos of groups I and II were administered liquid HBC at a volume of 1 and 3 % of their body weight (g to mL), respectively. Geckos of groups III and IV were administered the same relative volume as groups I and II, respectively, of powdered HBC reconstituted (16 %) in distilled water. The control gecko was administered saline at a volume of 3 % of his body weight in a similar manner as the HBC-treated animals. Fecal specimens were collected at defecation, refrigerated at 4°C and tested for *Cryptosporidium* sp. oocysts by the AFS. The number of oocysts was counted for 10 min under $40\times$ objective magnification, and 30 randomly selected oocysts from each gecko were measured and their shape index (length/width) was determined [19]. The relative oocyst output was measured by mean number of oocysts per fecal specimen per animal (figure 1).

A week after the last administration of HBC, all geckos were euthanized and necropsied [8]. The entire gastrointestinal track was collected, opened, fixed in buffered formalin, and embedded in paraffin. Five-micrometre-thick sections stained with hematoxylin and eosin were examined under light microscopy for developmental stages of *Cryptosporidium* sp. This procedure was also applied for all geckos that died before termination of the experiment (figure 1). The severity of *Cryptosporidium* sp. infection was scored [5] and classified into class 1, 2, 3 or 4. Class 1 included the cases that yielded only single developmental stages of *Cryptosporidium* sp. ($<0.5\%$ of intestinal epithelial cells infected). Class 4 included the most severe cases with multiple developmental stages of *Cryptosporidium* sp. (approximately 65 % of the intestinal epithelial cells infected). Classes 2 and 3 included cases in which approximately 5 and 25 %, respectively,

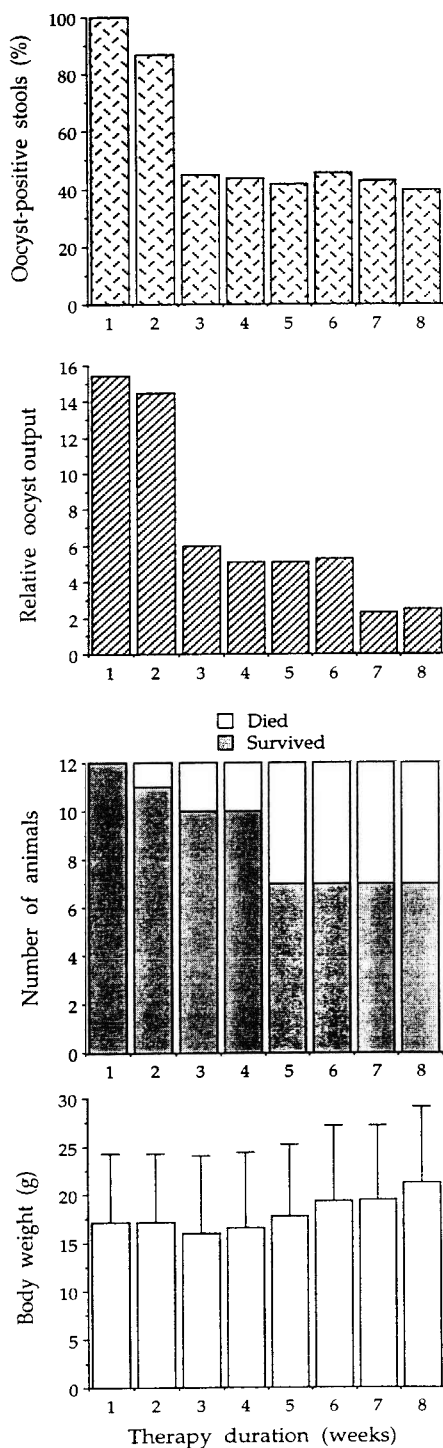


Figure 1. Results of hyperimmune bovine colostrum therapy applied to moribund Leopard geckos (*Eublepharis macularius*) infected with *Cryptosporidium* sp. Hyperimmune bovine colostrum administered gastrically seven times at weekly intervals.

of the intestinal epithelial cells harbored developmental stages of *Cryptosporidium* sp.

Statistical analysis was carried out with Statistix 4.1 (Analytical Software, St. Paul, MN, USA). The variables were examined by Runs test to determine if their distribution conformed to a normal distribution, and if not, the nonparametric test, Kruskal-Wallis analysis of variance (ANOVA), was used to determine the significance of differences between variables.

3. RESULTS

No significant differences were observed in intensity of *Cryptosporidium* sp. infections, decrease of oocyst output or prevalence of oocyst-positive fecal specimens among the four HBC treatment groups (Kruskal-Wallis ANOVA).

Five out of 12 (42 %) HBC-treated geckos died before termination of the therapy (figure 1), and the control gecko died during the first week. No mortality was observed among geckos of moderate body conditions.

All geckos were positive for developmental stages of *Cryptosporidium* sp. which occurred exclusively in the small intestine. No *Cryptosporidium* sp. developmental stages were present in the stomach or cloaca of any gecko. The severity of *Cryptosporidium* sp. infection was not related to the body weight of geckos.

No significant differences were detected in the length, width or shape index among oocyst isolates originating from 13 geckos (ANOVA). The overall oocyst length varied from 6.2 to 7.8, $x = 6.8 \pm 0.5 \mu\text{m}$, width ranged from 5.7 to 6.1, $x = 5.9 \pm 0.3 \mu\text{m}$, and the shape index varied from 1.00 to 1.29, $x = 1.15 \pm 0.01 \mu\text{m}$. The intensity of fluorescence of all *Cryptosporidium* sp. oocysts isolates obtained with the MERIFLUOR™ test was consistently very low.

The mean values of relative oocyst output progressively decreased during the HBC therapy (figure 1). Also, the prevalence of oocyst-positive fecal specimens decreased during the HBC therapy (figure 1). Neither

Eimeria sp. nor *Isospora* sp. oocysts were detected in the fecal specimens. The mean body weight of geckos increased during the 8-week HBC therapy; however, this increase was due to the survival of geckos from moderate body conditions.

Considering the severity of *Cryptosporidium* sp. infection, overall, only one gecko was in class 4; the animal had disorganized architecture of the intestinal mucosa and thinned epithelium. Seven of 12 geckos had only single developmental stages of *Cryptosporidium* sp. (class 1) in the intestinal epithelium which had normal architecture. Three other geckos had a low number of developmental stages of *Cryptosporidium* sp. on the surface of intestinal epithelium (class 2) and one gecko had a slightly higher number of the parasite's developmental stages (class 3).

4. DISCUSSION

Although three published reports on *Cryptosporidium* infections in geckos describe near 100 % epizootic-type mortality [2, 18, 19], the clinical importance of cryptosporidiosis in gekkonids remains unclear. Two reports indicate *Eimeria brygooi* and *Isospora gekkonis*, documented in *Cryptosporidium*-infected geckos, and potential (but not documented) bacterial or viral infections [17–19]. Another report suggests *Escherichia coli* as a major etiologic agent killing Leopard geckos, whereas detected *Isospora* spp. infections have not been considered as a factor significantly contributing to their death [2].

It has been demonstrated that *Cryptosporidium*-infected Leopard geckos that lost approximately 50 % of the body weight (baseline value of 38 g) died shortly thereafter [2]. In the present study, the majority of Leopard geckos weighed approximately only 25 % of the baseline value (average 36 %); yet, the mortality rate was 42 %. It is believed that the discrepancy between expected (100 %) and observed (42 %) mor-

tality rates was due to the HBC therapy applied to the moribund geckos.

Histological sections of *Cryptosporidium*-infected Leopard geckos that died during the epizootic [2] revealed moderate numbers of *Cryptosporidium* developmental stages in the anterior stomach and anterior intestine [2]. Because geckos in the present study were much more emaciated than those described previously [2], we expected to find developmental stages of *Cryptosporidium* in the gastric region of geckos in the present study. However, none of 12 Leopard geckos, including five animals that died during therapy duration, had developmental stages of *Cryptosporidium* sp. in the gastric region. We conclude that the lack of *Cryptosporidium* sp. developmental stages in the gastric region of Leopard geckos was due to HBC therapy.

Cryptosporidium sp. oocysts originating from Leopard geckos in the present study and in the previous study [2] differ from the oocysts of *C. serpentis*. Gecko-derived oocysts produced consistently a very weak immunofluorescent antibody (IFA) reaction with the MERIFLUOR™ test. A weak IFA reaction with the MERIFLUOR™ test conforms to the previous results [2]. Up to date, all snake-derived *C. serpentis* oocyst isolates, and some *Cryptosporidium* sp. oocysts isolates from lizards, turtles and tortoises, have produced strong IFA reactions [7–13]. *Cryptosporidium* sp. oocysts from Leopard geckos in the present study were bigger than *C. serpentis* oocysts that were measured previously under the same microscope [8–10]. In addition, gecko-derived oocysts in the present study had values of morphometrical parameters similar to those obtained from oocysts originating from other species of geckos [18, 19]. Also, all 13 *Cryptosporidium* sp. oocyst isolates originating from 13 Leopard geckos in the present study were uniform with regards their size and morphology. Cross-transmission experiments determining the host-species specificity of gecko-derived *Cryptosporidium* sp. oocysts should address the question as to whether

these oocysts represent different parasite species.

Based on the decreased output of oocysts and lowered prevalence of oocyst-containing stools, absence of the parasite in the gastric region, and much lower than expected mortality rate of moribund *Cryptosporidium* sp.-infected Leopard geckos, we conclude that the HBC therapy was heterologously efficacious in decreasing the load of the parasite that may represent species different from *C. serpentis*. However, the efficacy of HBC was lower in geckos than observed previously in *C. serpentis*-infected snakes [13]; which may be due to the intestinal location of *Cryptosporidium* sp. infection in these geckos. Besides the anticryptosporidial activity of immunoglobulins present in the HBC, the colostrum itself is rich in easy-digestible proteins which when delivered orally may be beneficial for geckos with significant weight lost.

ACKNOWLEDGMENTS

We thank J.D. Strandberg (Johns Hopkins University) for facilitating this study, B. Hainie, L. Campbell and S. Davis, for technical assistance, and L. Kreitmann for his assistance with the French text. The study was supported by the Morris Animal Foundation, Englewood, Colorado, grant 98ZO-28.

REFERENCES

- [1] Arrowood M.J., Mead J.R., Mahrt J.L., Sterling C.R.. Effects of immune colostrum and oral administered antiparasitic monoclonal antibodies on the outcome of *Cryptosporidium parvum* infections in neonatal mice. *Infect. Immun.* 57 (1989) 2283–2288.
- [2] Coke R.L., Tristan T.E.. *Cryptosporidium* infection in a colony of Leopard geckos. *Eublepharis macularius*, in: Frahm M.W., Boyer L.C. (Eds.), Proceedings of the 5th Annual Conference of the Association of Reptilian and Amphibian Veterinarians. Kansas City, Missouri, 1998, pp. 157–163.

- [3] Cranfield M.R., Graczyk T.K., Cryptosporidiosis, in: Mader D.R. (Ed.), *Manual of Reptile Medicine and Surgery*, W.B. Saunders Company, Philadelphia, Pennsylvania, 1996, pp. 359–363.
- [4] Cranfield M.R., Graczyk T.K., Cryptosporidia in reptiles, in: Anderson N., Meloni D., Bonagura J.D. (Eds.), *Current Veterinary Therapy*, W.B. Saunders Company, Philadelphia, Pennsylvania 1999, in press.
- [5] Fayer R., Effect of high temperature on infectivity of *Cryptosporidium parvum* oocysts in water, *Appl. Environ. Microbiol.* 60 (1994) 2732–2735.
- [6] Fayer R., Guidry A., Blagburn B.L., Immunotherapeutic efficacy of bovine colostrum immunoglobulins from a hyperimmunized cow against cryptosporidiosis in neonatal mice, *Infect. Immun.* 58 (1990) 2962–2965.
- [7] Graczyk T.K., Cranfield M.R., Assessment of the conventional detection of fecal *Cryptosporidium serpentis* oocysts of subclinically infected captive snakes, *Vet. Res.* 27 (1996) 185–192.
- [8] Graczyk T.K., Cranfield M.R., Experimental transmission of *Cryptosporidium* oocysts isolates from mammals, birds, and reptiles to captive snakes, *Vet. Res.* 29 (1998) 187–195.
- [9] Graczyk T.K., Cranfield M.R., Fayer R., A comparative assessment of direct fluorescence antibody, modified acid fast stain, and sucrose flotation techniques for detection of *Cryptosporidium serpentis* oocysts in snake fecal specimens, *J. Zoo Wildl. Med.* 26 (1995) 396–402.
- [10] Graczyk T.K., Owens R., Cranfield M.R., Diagnosis of subclinical cryptosporidiosis in captive snakes based on stomach lavage and cloacal sampling, *Vet. Parasitol.* 67 (1996) 143–151.
- [11] Graczyk T.K., Cranfield M.R., Fayer R., Evaluation of commercial enzyme immunoassay (EIA) and immunofluorescent antibody (IFA) tests kits for detection of *Cryptosporidium* oocysts other than *Cryptosporidium parvum*, *Am. J. Trop. Med. Hyg.* 53 (1996) 274–279.
- [12] Graczyk T.K., Cranfield M.R., Mann J., Strandberg J.D., Intestinal *Cryptosporidium* sp. infection in Egyptian tortoise (*Testudo kleinmanni*). *Int. J. Parasitol.* 28 (1998) 1885–1888.
- [13] Graczyk T.K., Cranfield M.R., Helmer P., Fayer R., Bostwick E.F., Therapeutic efficacy of hyperimmune bovine colostrum treatment against clinical and subclinical *Cryptosporidium serpentis* infections in captive snakes, *Vet. Parasitol.* 74 (1998) 123–132.
- [14] Hoskins D., Chrisp C.E., Suckow M.A., Fayer R., Effect of hyperimmune bovine colostrum raised against *Cryptosporidium parvum* on infection of guinea pigs by *Cryptosporidium wairi*, *J. Protozool.* 38 (1991) 185S–186S.
- [15] Naciri M., Mancassola R., Reperant J.M., Canivez O., Yvore Q.B., Treatment of experimental ovine cryptosporidiosis with ovine or bovine hyperimmune colostrum, *Vet. Parasitol.* 53 (1994) 173–190.
- [16] Tzipori S., Rand W., Griffiths J., Widmer G., Crabb J., Evaluation of an animal model system for cryptosporidiosis: therapeutic efficacy of paromomycin and hyperimmune bovine colostrum-immunoglobulins, *Clin. Diag. Lab. Immunol.* 1 (1994) 450–463.
- [17] Upton S.J., *Cryptosporidium* spp. in lower vertebrates, in: Dubey J.P., Speer C.A., Fayer R. (Eds.), *Cryptosporidiosis in Man and Animals*, CRC Press, Boca Raton, Florida, 1990, pp. 147–156.
- [18] Upton S.J., Barnard S.M., Two new species of Coccidia (Apicomplexa: Eimeriidae) from Madagascar gekkonids, *J. Protozool.* 34 (1987) 452–454.
- [19] Upton S.J., McAllister C.T., Freed P.S., Barnard S.M., *Cryptosporidium* spp. in wild and captive reptiles, *J. Wildl. Dis.* 25 (1989) 20–30.