



HAL
open science

**Protozoan infections (*Toxoplasma gondii*, *Neospora caninum* and *Sarcocystis* spp.) in sheep and goats:
recent advances**

David Buxton

► **To cite this version:**

David Buxton. Protozoan infections (*Toxoplasma gondii*, *Neospora caninum* and *Sarcocystis* spp.) in sheep and goats: recent advances. *Veterinary Research*, 1998, 29 (3-4), pp.289-310. hal-00902530

HAL Id: hal-00902530

<https://hal.science/hal-00902530>

Submitted on 11 May 2020

HAL is a multi-disciplinary open access archive for the deposit and dissemination of scientific research documents, whether they are published or not. The documents may come from teaching and research institutions in France or abroad, or from public or private research centers.

L'archive ouverte pluridisciplinaire **HAL**, est destinée au dépôt et à la diffusion de documents scientifiques de niveau recherche, publiés ou non, émanant des établissements d'enseignement et de recherche français ou étrangers, des laboratoires publics ou privés.

Review article

Protozoan infections (*Toxoplasma gondii*, *Neospora caninum* and *Sarcocystis* spp.) in sheep and goats: recent advances

David Buxton

Division of Virology, Moredun Research Institute, International Research Centre,
Pentlands Science Park, Bush Loan, Penicuik, Midlothian EH26 0PZ, Scotland, UK

(Received 14 October 1997; accepted 18 December 1997)

Abstract – The protozoan parasite *Toxoplasma gondii* is a serious cause of fetal mortality in sheep and goats. Oocysts, the parasite stage responsible for initiating infection, are produced following a primary infection in cats. A primary infection in pregnant sheep and goats can establish a placental and fetal infection which may result in fetal death and resorption, abortion or stillbirth. Diagnosis is aided by the clinical picture, the presence of characteristic small white necrotic foci in placental cotyledons, the possible presence of a mummified fetus and on fetal serology and histopathology. Development of the polymerase chain reaction (PCR) specific for *T. gondii* may also provide a valuable diagnostic tool. Measures to control abortion include improved management of farm cats, fodder and water. Vaccination of sheep with the live vaccine is an effective preventive measure and the use of decoquinate in feed may be useful in some situations. *Neospora caninum* is related to *T. gondii* and while its asexual life cycle is similar to that of the latter it is currently not known whether it has a similar sexual life cycle in a definitive host. *Neospora* is an important cause of fetal loss in cattle and parallels that of *T. gondii* infection in sheep and goats. While it does not appear to cause frequent losses in these latter animals, experimental infection is readily induced in them and if initiated during pregnancy provides a very good model of the bovine infection. Furthermore clinical signs and pathological lesions in sheep and goats are similar to those induced in them by *T. gondii*, although there are subtle histopathological differences. These changes will aid possible diagnosis as will specific serological tests such as the indirect immunofluorescent antibody test and the enzyme linked immunosorbent assay and the PCR. *Sarcocystis*, which exists as numerous species, undergoes a coccidian-like life cycle with each having a distinctive definitive (usually carnivore) host which excretes sporocysts into the environment. Clinical sarcocystiosis is much less commonly diagnosed than toxoplasmosis and neither is it normally associated with fetal infection or abortion in either sheep or goats. However, infection is extremely common throughout the world and follows ingestion of food or water contaminated with sporocysts. Clinical signs, when seen, include fever, anaemia, inappetance and weight loss or reduced weight gain. Central nervous signs (hind limb weakness, ataxia, paresis), acute myopathy and death may occur. Diagnosis is difficult as infection is

so common and clinical signs absent, mild or non-specific. Serology may be useful in some situations and histopathology/immunohistochemistry is valuable for confirming the cause of death. Control relies on preventing contamination of pasture and water with faeces of dogs, foxes and cats or by controlling access of young susceptible stock to contaminated land. Relatively little is known of the immunity induced by infection with *Sarcocystis* spp. but research indicates that protective immunity does develop and that cell-mediated mechanisms are probably important. It is likely that sarcocystiosis is underdiagnosed as a problem and that better diagnostic methods are needed to show the true extent of the losses caused. Neosporosis on the other hand would appear not to be so common in sheep and goats. The value of experimental infections in these animals may be to provide a comparative model of the infection in cattle in the same way that our understanding of toxoplasmosis in sheep provides a superior model of human toxoplasmosis. © Inra/Elsevier, Paris

Toxoplasma / *Neospora* / *Sarcocystis* / sheep / goats

Résumé – Protozooses (*Toxoplasma gondii*, *Neospora caninum* et *Sarcocystis* spp.) chez le mouton et la chèvre : avancées récentes. Le parasite protozoaire *Toxoplasma gondii* est une cause sérieuse de mortalité fœtale chez le mouton et la chèvre. Les oocystes, stade du parasite responsable de l'initiation de l'infection, sont produits après une primo-infection chez le chat. Une primo-infection chez la brebis ou la chèvre gestante peut provoquer une infection placentaire et fœtale pouvant résulter en une mort et résorption fœtale, un avortement, ou une mortalité. Le diagnostic se fait à l'aide de la description clinique, de la présence de petits foyers nécrotiques blancs caractéristiques dans les cotylédons placentaires, de la présence éventuelle d'un fœtus momifié, et de la sérologie et de l'histopathologie fœtale. Une technique d'amplification en chaîne par polymérase (PCR) spécifique de *T. gondii*, qui tend à se développer, est également un outil de diagnostic précieux. Les mesures visant à contrôler les avortements incluent une amélioration, dans les fermes, de la gestion des chats, des fourrages, et de l'eau. La vaccination des moutons avec le vaccin vivant est une mesure de prévention efficace, et l'utilisation de décoquinate dans la nourriture peut être utile dans certaines situations. *Neospora caninum* est apparenté à *T. gondii*, mais bien que son cycle asexué soit similaire à celui de ce dernier, on ne sait toujours pas s'il possède également un cycle sexué similaire dans l'hôte définitif. *Neospora* est une cause importante de perte de fœtus chez les bovins, et est analogue à l'infection par *T. gondii* chez le mouton et la chèvre. Alors que *Neospora* ne paraît pas causer de pertes fréquentes chez ces derniers, l'infection expérimentale est facilement induite chez eux, et si elle est initiée durant la gestation, elle produit un très bon modèle de l'infection bovine. De plus, signes cliniques et lésions pathologiques chez la chèvre et la brebis sont similaires à ceux induits chez eux par *T. gondii*, bien qu'il existe de subtiles différences histopathologiques. Ces différences peuvent aider à faire un diagnostic précis, de même que des tests sérologiques spécifiques tels que la détection d'anticorps par immuno-fluorescence indirecte, l'Elisa, ou la réaction en chaîne par polymérase. *Sarcocystis*, qui existe sous la forme de nombreuses espèces, a un cycle de développement semblable à celui des coccidies, chaque espèce ayant un hôte définitif particulier (généralement carnivore) qui excrète des sporocystes dans l'environnement. La sarcocystose clinique est diagnostiquée bien moins couramment que la toxoplasmose, et n'est normalement pas non plus associée à une infection fœtale ou à un avortement chez la brebis ou la chèvre. Toutefois, l'infection est très fréquente dans le monde entier, et se produit après l'ingestion de nourriture ou d'eau contaminée par des sporocystes. Les signes cliniques, lorsqu'ils sont visibles, incluent de la fièvre, une anémie, un manque d'appétit et une perte de poids ou une diminution de la prise de poids. Des symptômes liés à l'atteinte du système nerveux central (faiblesse des pattes arrière, ataxie, parésie), myopathie aiguë et mort peuvent se produire. Le diagnostic est difficile car l'infection est très fréquente, et les signes cliniques absents, légers ou non spécifiques. La sérologie pourrait être utile dans certaines situations, et l'histopathologie/l'immunohistochimie est précieuse pour confirmer la cause de la mort. Le contrôle de la maladie repose sur la prévention de la contamination des pâturages et de l'eau par les chiens, les renards et les chats, ou sur le contrôle de l'accès des cheptels jeunes et sensibles aux terres contaminées. On connaît peu de choses sur l'immunité induite par l'infection par *Sarcocystis* spp., mais des études indiquent qu'une immunité protectrice se développe,

et que les mécanismes cellulaires sont probablement importants. Il est probable que la sarcocystose soit un problème sous-estimé, et que de meilleures méthodes de diagnostic soient nécessaires pour montrer l'étendue réelle des pertes subies. La néosporose, en revanche, apparaîtrait comme n'étant pas si fréquente chez les moutons et les chèvres, et l'intérêt des infections expérimentales chez ces animaux est de fournir un modèle de l'infection chez les bovins, de la même manière que la compréhension de la toxoplasmose chez le mouton a permis de développer des mesures de contrôle utiles de cette infection importante, et de fournir un modèle de la toxoplasmose humaine. © Inra/Elsevier, Paris

Toxoplasma / *Neospora* / *Sarcocystis* / mouton / chèvre

Plan

1. Introduction	291
2. Toxoplasmosis	292
2.1. Life cycle	292
2.2. Clinical disease	293
2.3. Diagnosis	294
2.3.1. Pathological changes	294
2.3.2. Detection of <i>Toxoplasma gondii</i>	294
2.3.3. Serology	295
2.4. Control	295
2.4.1. Cats as a source of infection	295
2.4.2. General management	296
2.4.3. Vaccination	296
2.4.4. Pharmaceuticals	298
3. Neosporosis	298
3.1. Life cycle	298
3.2. Clinical disease	298
3.3. Experimental neosporosis	299
3.4. Diagnosis	300
3.5. Treatment	301
4. Sarcocystiosis	301
4.1. Life cycle	301
4.2. Clinical disease	302
4.3. Diagnosis	302
4.4. Control	303
4.4.1. Immunity	303
4.4.2. Pharmaceuticals	304
5. Current and future research	304

1. INTRODUCTION

Toxoplasma gondii, *Neospora caninum* and *Sarcocystis* spp. are all apicomplexan protozoan parasites in the family Sarcocystidae. While the former two are considered to exist as single species, *Sarcocystis* occurs as many species. All three organisms have been recorded as causing clinical disease and mortality in sheep and goats.

cystidae. While the former two are considered to exist as single species, *Sarcocystis* occurs as many species. All three organisms have been recorded as causing clinical disease and mortality in sheep and goats.

2. TOXOPLASMOSIS

Toxoplasma gondii, first described in 1908, has a worldwide distribution and is capable of infecting all warm-blooded animals, in which it has a simple two-stage asexual life-cycle. Clinical toxoplasmosis occurs in sheep and goats when they suffer a primary infection while pregnant (Dubey and Beattie, 1988).

2.1. Life cycle

The life cycle of *Toxoplasma* can be divided into two parts; an asexual cycle with little host specificity and a sexual cycle, confined to the enteroepithelial cells of cats, which results in the production of oocysts (Dubey and Beattie, 1988) (figure 1). In the asexual cycle two developmental stages are involved, the tachyzoite and the bradyzoite. Each crescent-shaped tachyzoite (about 5 µm by 1.5 µm) can actively penetrate a host cell, where it becomes surrounded by a parasitophorous vacuole in which it multiplies by endodyogeny (two daughter cells form within the mother cell). Multiplication continues until the host cell ruptures when the organisms are released to parasitize further cells. This process continues until the host dies, or

more usually, develops immunity to the parasite. In the latter case a persistent infection is established, extracellular organisms are thus eliminated, intracellular multiplication slows and tissue cysts develop. A small cyst contains only a few bradyzoites (the second stage of the asexual cycle) but a large one may contain thousands. Cysts are found most frequently in brain and skeletal muscle and represent the quiescent stage of the parasite within the host. When a cyst ruptures the bradyzoites are released and, transformed into tachyzoites, enter other cells to complete the asexual cycle (Dubey and Beattie, 1988).

Initiation of the sexual cycle occurs when a non-immune cat ingests food contaminated by oocysts or containing tachyzoites or tissue cysts. In the case of the latter the cyst wall is dissolved by proteolytic enzymes in the stomach and small intestine and the released bradyzoites penetrate the epithelial cells of the small intestine. While the parasite spreads to brain and muscles where tissue cysts will develop (asexual cycle), simultaneously toxoplasms also undergo gametogony (sexual cycle) in enteroepithelial cells. Here, in the small intestine (most commonly the ileum) gametocytes develop, over 3–15 days after infection. Microg-

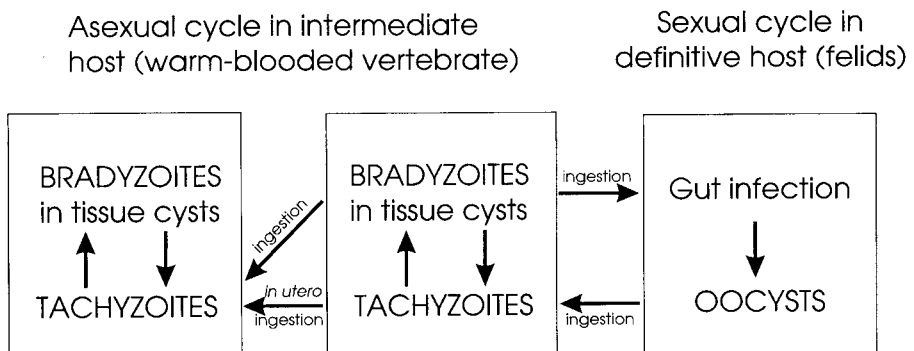


Figure 1. Life cycle of *Toxoplasma gondii*.

metes form and are released to penetrate mature macrogametes triggering the formation of an oocyst wall around each fertilized gamete. The oocysts ($10 \times 12 \mu\text{m}$ in diameter), each almost filled by the sporont, are then discharged into the intestinal lumen to pass out in the faeces. Sporulation occurs within 1–5 days (depending on aeration and temperature) to produce two ellipsoidal sporocysts, each containing four sporozoites within each oocyst (Dubey and Beattie, 1988).

Thus, during the 4–12 days after ingesting tissue cysts the cat is capable of shedding millions of oocysts in its faeces, after which it will not normally excrete the parasite again, although stress can trigger the recrudescence of infection (Dubey and Frenkel, 1974). Unrelated illness may therefore lead to the excretion of oocysts in smaller numbers and for a shorter time than in a primary infection. Cats may also become infected by ingesting oocysts or tachyzoites but in this case they tend to produce oocysts after 19 or 20 days, for only a day or two and in relatively small numbers and even then about half of these animals will not excrete oocysts (Dubey and Beattie, 1988).

2.2. Clinical disease

Sporulated oocysts ingested by a susceptible pregnant sheep excyst in the small intestines, each able to release the eight sporozoites. Four days later tachyzoites can be found in the mesenteric lymph nodes, where they multiply (Dubey, 1984), and they in turn are released into the blood to cause a parasitaemia, which may last from the 5th until the 12th day after infection (Dubey and Sharma, 1980a; Reid et al., 1982; Wastling et al., 1993), disseminating infection to many tissues. The cessation of the parasitaemia coincides with the onset of a protective immune response and infection then persists as bradyzoites

within tissue cysts. However, in the pregnant ewe infection may establish in the gravid uterus where maternal immunological responses may be altered and the ability of the fetus, with its placenta, to recognize and respond to the parasite is negligible in the early stages of gestation but develops progressively with time so that lambs are born immunocompetent (Salami et al., 1985). Toxoplasms initially parasitise the caruncular septa, the maternal tissues of the placentome, before invading the adjacent trophoblast cells of the fetal villi and from there the rest of the fetus (Buxton and Finlayson, 1986). Thus, the outcome of infection early in gestation can result in fetal death and resorption/abortion while infection in the latter part of gestation, when fetal immunity is relatively well developed, may have no clinical effect, the offspring being born normal but infected and immune. In sheep typical clinical signs of toxoplasma abortion usually result following infection in mid gestation, with ewes producing still-born and/or weakly lambs often accompanied by a small, mummified fetus. Cotyledons on the accompanying placenta(s) will also show lesions visible to the naked eye (Buxton, 1991). Abortion and neonatal mortality in goats is essentially similar to that seen in sheep whether occurring naturally (Munday and Mason, 1979; Chhabra and Gautam, 1984; Dubey, 1981a; Dubey et al., 1981; Nurse and Lenghaus, 1986) or produced experimentally (Dubey et al., 1980; Dubey, 1988). During an acute infection in goats toxoplasms may be excreted in the milk (Dubey, 1980; Skinner et al., 1990) and be a possible source of human infection if drunk unpasteurised (Skinner et al., 1990). Also, experimentally at least, toxoplasms may be present in goat semen for a variable time after infection (Dubey and Sharma, 1980b) but the epidemiological significance of this, as in sheep (Blewett et al., 1982), may be very slight.

2.3. Diagnosis

2.3.1. Pathological changes

Characteristically the placental cotyledons appear bright to dark red and speckled with white foci of necrosis 2–3 mm in diameter which may be sparse or so numerous that they can become confluent, while the intercotyledonary allanto-chorion appears normal (Hartley and Kater, 1963; Beverley et al., 1971b). Visible changes in lambs and kids vary, the most obvious being the mummified fetus, a small chocolate brown miniature of a lamb/kid, often with its own small grey–brown placenta. Fetuses dying later in gestation are born in various stages of decomposition often with clear to bloody subcutaneous oedema and a variable amount of clear to bloodstained fluid in body cavities (Hartley and Kater, 1963). However, while these latter changes indicate an intrauterine infection they are not specific to infection with *Toxoplasma*.

The most obvious histopathological changes are the necrotic foci, visible macroscopically in the cotyledons. Microscopically they appear as large foci of coagulative necrosis, remarkably free of inflammatory cells, which may become mineralised with time. Sometimes small numbers of intracellular and extracellular toxoplasms are visible, usually on the periphery of the necrotic lesions or in a villus which is in the early stages of infection (Buxton and Finlayson, 1986). In the fetal brain both primary and secondary lesions develop. Glial foci, typically surrounding a necrotic and sometimes mineralised centre, often associated with a mild lymphoid meningitis, represent a fetal immune response following direct damage by local parasite multiplication. Toxoplasms are only rarely found, usually at the periphery of the lesions. Focal leukomalacia, seen most commonly in cerebral white matter cores, is also common and

is probably due to fetal anoxia in late gestation caused by advanced necrosis in the placentome preventing sufficient oxygen transfer from mother to fetus (Buxton et al., 1982).

2.3.2. Detection of *Toxoplasma gondii*

While the most direct and established method of demonstrating *Toxoplasma* infection in cases of abortion is to transmit the parasite from aborted material (fetal brain and placental cotyledons) to laboratory mice (Fleck and Kwantes, 1980) it is slow and expensive. *Toxoplasma* may also be grown in tissue culture in virtually any mammalian cell line and while more rapid than mouse inoculation it is rarely used for routine diagnosis as it is expensive and test samples may frequently be heavily contaminated. A more rapid but less sensitive method of isolation is the direct demonstration of *T. gondii* tissue cysts by centrifugation of lamb brain homogenate on a discontinuous density gradient of 30 and 90 % colloidal silica solution (Blewett et al., 1983).

Immunohistochemical techniques allowing visualisation of both intact *T. gondii* and antigenic debris in tissue sections of aborted materials are convenient and sensitive methods and have the advantage, when compared with attempts at isolation, of detecting toxoplasma antigen even in decomposed tissues. The ABC indirect immunoperoxidase method (Vector Laboratories, USA) and the peroxidase anti-peroxidase (PAP) technique (Uggla et al., 1987) are equally good.

Both viable and non-viable toxoplasms may be identified in tissues with the polymerase chain reaction (PCR). Both the P30 and the B1 gene of *T. gondii* have been used as PCR targets for the detection of *Toxoplasma* in various clinical specimens collected from infected humans. Limited studies have also been carried out using ovine samples such as aborted placental

material, brain and peritoneal fluid from aborted fetuses and lymph, blood and lymph nodes from artificially infected ewes (Wastling et al., 1993). Detection of *T. gondii* by amplification of the B1 gene would seem to be more sensitive than by the P30 gene due to the repetitive nature of the B1 gene of which 25–50 copies are present in the genome of *T. gondii* compared with only a single copy of the longer P30 gene. Currently the technique is not used in routine diagnosis but the potential of the PCR to identify DNA in paraffin sections from histopathological tissue blocks may broaden its applicability (Ellis, 1997).

2.3.3. Serology

This is an important tool in the diagnosis of ovine and caprine toxoplasma abortion. The presence of specific antibodies in serum or tissue fluid from still-born lambs or kids or in precolostral serum from live offspring indicates uterine infection. However, high toxoplasma antibody titres in sera taken from ewes and nannies within a few weeks of abortion or production of stillborn lambs or kids can only suggest toxoplasmosis as titres remain relatively high for long periods after initial infection. Serology will also indicate the degree of exposure to infection in a group of animals. The first method to be developed was the dye test (DT) of Sabin and Feldman (1948) but it is expensive, time consuming and not without hazard as it requires live tachyzoites as antigen. The indirect immunofluorescent antibody test (IFAT) gives titres comparable with the DT but is safer as it uses killed tachyzoites (Maley et al., 1997) and the latex agglutination test (LAT) also performs well (Trees et al., 1989; Maley et al., 1997). The modified agglutination test (MAT) (Desmonts and Remington, 1980) has been shown to perform particularly well with goat sera (Dubey et al., 1985) although for epidemiological studies the indirect haemagglutination test (IHA) (Pat-

ton et al., 1990), IFAT and LAT (Opel et al., 1991) are adequate. Both the IHA and LAT are easy to perform and the latter is available in kit form (Eiken Chemical Co., Japan) and neither test requires species-specific antisera or conjugates.

The enzyme linked immunosorbent assay (ELISA) for *T. gondii* antibodies has been adapted for use in most domestic animals including sheep (Buxton et al., 1988) and goats and can be made to distinguish IgM and IgG antibodies and, as it is readily automated, it is suitable for handling large numbers of test sera.

2.4. Control

2.4.1. Cats as a source of infection

Sheep are frequently maintained in an environment significantly contaminated with oocysts and infection follows ingestion of contaminated food or water (Blewett, 1983; Blewett and Watson, 1983), with pasture perhaps being the most common source of infection, although water can be a real threat not only to animals but also to people (Bowie et al., 1997). Certainly, fields treated with manure and bedding from farm buildings where cats live can cause infection (Faull et al., 1986) and cats defaecating in farm feeds, such as hay and stored grain, will pose a risk (Plant et al., 1974).

Thus in the hypothetical situation in which a cat, actively shedding oocysts in its faeces, defaecates in 10 tonnes of grain stored on a farm, then the potential for the parasite being spread to livestock could be considerable. A single defaecation may contain as many as 10 000 000 oocysts. If further processing of the feed dispersed these oocysts evenly throughout the grain then each kilogram would contain between five and 25 sheep infective doses (McColgan et al., 1988). In this way cat faeces can create a large, potent, long-lasting source of infec-

tion for sheep. Thus, oocyst contamination of farm feeds and bedding, as well as pasture, is a threat to susceptible, pregnant sheep and goats and is closely related to the number and distribution of cats.

Cats are born free of toxoplasma infection and excretion of oocysts by them follows establishment of a primary infection. Although it has been calculated that less than 1 % of all cats are shedding oocysts at any one time (Dubey and Beattie, 1988) this figure is probably higher for young cats. Female feral cats can produce two to three litters a year, each of up to eight kittens, and may rear their young communally (Macdonald, 1980). Numbers of young cats are also dependent upon the density of breeding adults. In rural areas male cats may have territories of 60–80 hectares (250–200 acres) while females usually only occupy a tenth of this area (Macdonald, 1980). In an urban environment these territories are considerably smaller (Tabor, 1980). The area occupied by feral cats is influenced by the supply of food, which includes mice, voles, shrews, rats, rabbits and small birds (Macdonald, 1980). Such animals persistently infected with *T. gondii* are an important source of infection for cats (Jackson and Hutchison, 1989; Peach et al., 1989). In addition mice (Eichenwald, 1948; Beverley, 1959; De Roever-Bonnet, 1969), but probably not rats (Dubey et al., 1997) are particularly important because they can pass the parasite in utero without causing overt clinical disease or fetopathy. In this way a reservoir of *T. gondii* tissue cyst infection for cats can exist in a particular population of mice for a long time.

2.4.2. General management

During pregnancy a flock/herd, in which the majority are seronegative to *T. gondii*, could be at risk if it was allowed access to an environment contaminated by cat faeces and so all food and water

should be kept free from soiling as far as practically possible. Other measures to reduce environmental contamination by oocysts should be aimed at reducing the number of cats capable of shedding oocysts. These would include selective culling of aged and diseased cats and attempts to control future breeding. If male cats are caught, neutered and returned to their colonies the stability of the colony is maintained; fertile male cats do not challenge the neutered males (Tabor, 1980) and breeding is controlled. Thus the maintenance of a small healthy population of mature cats will reduce oocyst excretion as well as help control rodents.

It is likely that a flock/herd, in which seroconversion to *T. gondii* can be demonstrated in a majority of animals, is being maintained in an environment significantly contaminated with *T. gondii* oocysts. As young, seronegative, replacement stock will be at risk, there is a case to be made for attempting to expose them to a contaminated environment before mating. Identification of such an environment is difficult but is likely to be an area in or around farm buildings where cats live, as well as pasture spread with manure from such buildings. While the foregoing is useful practical advice it does not guarantee success and there is a clear need for more precise methods of control.

2.4.3. Vaccination

Natural infection with *T. gondii* stimulates protective immunity in both sheep and goats (McColgan et al., 1988) but inactivated toxoplasma tachyzoites, either alone (Beverley et al., 1971a) or in Freund's incomplete adjuvant (Wilkins et al., 1987) do not protect pregnant sheep against experimental challenge with the parasite. Similarly a preparation consisting of surface antigens of *T. gondii* combined with Quil A provided little protection against experimental challenge (Buxton et al., 1989).

The failure of these killed preparations in sheep may be partly because, in natural infections, persistence of the parasite in tissues continually stimulates immunity, as suggested in human toxoplasmosis (McHugh et al., 1997). However experiments in which mice and hamsters were infected with a live temperature-sensitive mutant of *T. gondii*, which does not persist in the host, as it cannot form bradyzoites and cannot therefore form tissue cysts did induce protective immunity (Waldeland and Frenkel, 1983; McLeod et al., 1988; Suzuki and Remington, 1990).

In 1988 the Ministry of Agriculture and Food (New Zealand) launched a live toxoplasma vaccine for the control of ovine toxoplasmosis (O'Connell et al., 1988; Wilkins et al., 1988) and in 1992, after further study (Buxton et al., 1991), it was marketed in the UK and Eire (Toxovax, Intervet UK) as a tissue-culture-grown vaccine. The vaccine consists of live S48 tachyzoites which were originally isolated by mouse injection from a case of ovine abortion in New Zealand. After around 3 000 passes twice weekly, in laboratory mice it was shown to have lost its ability to develop bradyzoites in tissue cysts and unpublished data indicate that neither can the tachyzoites initiate the sexual life cycle of the parasite in cats (Bos, pers. comm.).

Studies at the Moredun Research Institute (Edinburgh, UK) showed that when susceptible pregnant sheep were each orally dosed with 2 000 sporulated *T. gondii* oocysts, a relatively severe challenge, less than 18 % of lambs were born live and viable, whereas with vaccinated ewes similarly challenged 75 % of lambs were born live and viable. The placental lesions in vaccinated ewes, following challenge, were much less frequent and/or severe than in unvaccinated, challenged ewes and the viable lambs born to the former had significantly higher birth weights than those born to the unvaccinated ewes, thus enhancing their chances of survival

(Buxton et al., 1991, 1993a). Protection afforded by one injection of the vaccine was just as good after 18 months as it was after 6 months. Antibody may impede cell invasion by tachyzoites and, with complement, limit phagocytosis by macrophages but protective immunity in sheep given the live vaccine is largely cell mediated (reviewed by Innes and Wastling, 1995) with CD4+ and CD8+ T cells (Innes et al., 1995a) and interferon gamma (Oura et al., 1993; Innes et al., 1995b) playing an important role in suppressing *T. gondii* parasitaemia in sheep (Buxton et al., 1994) thereby protecting the developing fetus from a maternal infection.

In field studies around half of 11 000 1-year-old female sheep in 101 flocks were vaccinated. Subsequently 20 flocks were exposed to significant natural challenge from the parasite and in vaccinated animals abortions were reduced and lambing percentages significantly improved when compared with unvaccinated sheep in the same flocks (Spence et al., 1992) thus confirming the findings of field trials carried out in New Zealand.

The manufacturers recommend that in the first instance the whole flock is vaccinated at least 3 weeks before mating and in subsequent years newcomers to the flock, usually young replacement stock, are vaccinated. Only one injection is required in the life of the sheep. The vaccine has a shelf life of 7–10 days and is capable of infecting people so it must be handled with care strictly according to the manufacturers' recommendations.

As with sheep, the majority of goats previously exposed to infection with *T. gondii* develop a protective immunity to the parasite so that they are protected against subsequent challenge during pregnancy (Obendorf et al., 1990), although repeat abortions have been recorded (Dubey, 1982). Toxovax is not licensed for use in goats. Immunity induced in goats by experimental infection with the

related coccidian parasite *Hammondia hammondi* has been shown to offer some cross-protection against challenge with *T. gondii* both in non-pregnant (Dubey, 1981b) and pregnant animals (Dubey, 1981c; Munday and Dubey, 1988) but this avenue of research has not been pursued.

2.4.4. Pharmaceuticals

Even though a live vaccine for toxoplasmosis is available for use in sheep there will always be a need for other methods of preventing infection becoming established in unprotected ewes/nannies and for treating infection once it is found in animals still to give birth. Chemoprophylaxis with monensin given in the feed at the rate of 15 mg/animal/day during pregnancy, can significantly suppress a toxoplasma infection in sheep (Buxton et al., 1988) but it is not licensed for this purpose. However the anticoccidial drug decoquinate fed daily at 2 mg/kg body weight, can also significantly reduce the effect of *T. gondii* oocysts ingested by pregnant sheep (Buxton et al., 1996) and is licensed for this use in sheep.

Both monensin and decoquinate work best if they are already being fed to susceptible ewes at the time they encounter infection rather than after infection is established. However, it has been shown that a combination of pyrimethamine and sulphamezathine, a well tried treatment in human medicine, which is effective because it blocks folate synthesis, is effective in the treatment of infected sheep (Buxton et al., 1993b). The drug combination, baquiloprim and sulphadimidine (Zaquilan®, Schering-Plough Animal Health, UK) also blocks folate synthesis and has given promising results in a controlled pilot study in non-pregnant sheep (Buxton, unpublished data).

The control of toxoplasmosis in sheep (and goats) is now easier than before. Our knowledge of its epidemiology permits

sensible management procedures to be followed to minimise the weight of infection in the environment, pharmaceutical preparations have been identified which may be used to curb disease and there is an effective vaccine for use in sheep.

3. NEOSPOROSIS

Neospora caninum has been recognised only since the 1980s and while it appears to be a major cause of fetal loss in cattle (Dubey and Lindsay, 1996) it also may cause clinical loss in sheep and goats.

3.1. Life cycle

Neospora caninum naturally infects a wide range of hosts including dogs, cattle, horses, deer (Dubey and Lindsay, 1996) and foxes (Buxton et al., 1997a), as well as sheep and goats (see below). An asexual life cycle involving bradyzoites, in tissue cysts, and tachyzoites are the only life cycle stages recognised at the time of writing (figure 2), although a sexual life cycle in a definitive carnivore host, which produces oocysts in a similar way to that in which cats produce *T. gondii* oocysts, has been predicted (Dubey and Lindsay, 1993). The tachyzoites, which divide by endodyogeny, may be either crescent shaped or ovoid 3–7 µm long by 1–5 µm wide depending on their stage of division. The tissue cysts range from 20–100 µm in diameter and typically have a clearly discernible cyst wall 1–2 µm thick (Dubey and Lindsay, 1996).

3.2. Clinical disease

Clinical neosporosis is most important in cattle in which it is now recognised to be a serious cause of abortion in many countries around the world (Dubey and Lindsay, 1996). Vertical transmission from

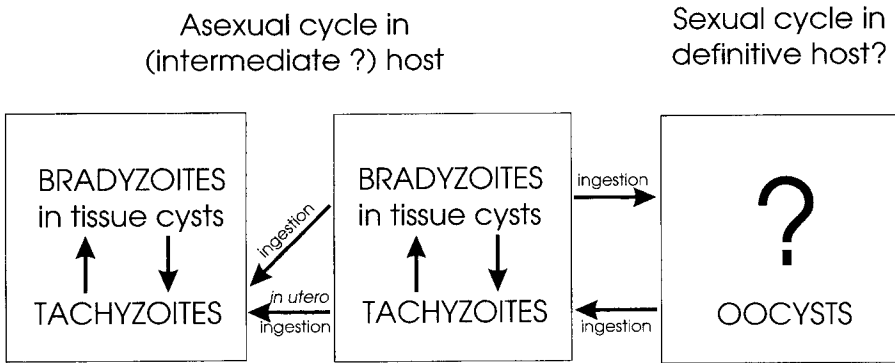


Figure 2. Life cycle of *Neospora caninum*.

cow to developing fetus is likely to be important in the epidemiology of bovine disease and is currently the only route of transmission to have been demonstrated. It is presumed that recrudescence of a persistent cyst infection in the mother occurs during pregnancy permitting a tachyzoite parasitaemia which allows the parasite to invade the gravid uterus, the placenta and then the fetus. Infection early in gestation, when the fetal immune system is little developed can be fatal with fetal resorption or abortion. Exposure of an older fetus, with its better developed immune system may result in the birth of a clinically normal but congenitally infected calf (Dubey and Lindsay, 1996).

While pregnant sheep have been shown to be very susceptible to experimental infection with *N. caninum* (Dubey and Lindsay, 1990; McAllister et al., 1996; Buxton et al., 1997b) to date there is little evidence of it being a significant field problem (Otter et al., 1997) with only one reported case of natural, congenital neosporosis in a weak, ataxic lamb which died when 1 week old (Hartley and Bridge, 1975; Dubey et al., 1990). It is, however, noteworthy that the spinal lesions in this animal were similar to those seen in calves congenitally infected with *N. caninum*. *Neospora* has also been associated with

abortion in goats in the USA (Barr et al., 1992; Dubey et al., 1992) and Costa Rica (Dubey et al., 1996) but while only a few fetuses were lost there was evidence of seroconversion to *N. caninum* in other animals in the Costa Rican herd.

3.3. Experimental neosporosis

Dubey and Lindsay (1990) showed in an uncontrolled pilot study with two ewes the susceptibility of the ovine fetus to *Neospora* and McAllister et al. (1996) and Buxton et al. (1997b) confirmed this in larger controlled studies. As with bovine neosporosis and ovine toxoplasmosis the younger fetuses were shown to be more susceptible than those challenged later in gestation (McAllister et al., 1996). Fetal lesions were most commonly manifest as a meningoencephalitis with characteristic foci of inflammation showing signs of organisation, typically with a necrotic centre surrounded by microglial and lymphoid cells. Light lymphoid vascular cuffs and meningeal infiltrates and focal microgliosis were also present. Milder lesions occurred less consistently in other tissues such as the heart and lungs (McAllister et al., 1996; Buxton et al., 1997b). Serial sampling of fetuses from experimentally infected ewes showed a progressive maturation of lymph

node structure with time and this correlated with the early production of IgM antibody followed by an IgG response to *Neospora* (Buxton et al., 1997b).

In the placenta there were scattered foci of necrosis involving fetal villous tissue and adjacent caruncular septa with accumulations of necrotic debris apparently of maternal and chorionic epithelial origin. Typically a non-suppurative inflammatory infiltrate was present in surrounding maternal and fetal tissue as well as chorio-allantoic membrane (McAllister et al., 1996; Buxton et al., 1997b). In one study neospora organisms were readily detectable (McAllister et al., 1996) while in the other they were much less frequent (Buxton et al., 1997b). While the first study used a mixture of the Nc-Liverpool and NC-2 isolates the latter study used only the Nc-Liverpool isolate and so it is possible that strain virulence is also important. Subsequent studies with the NC-1 isolate in pregnant sheep (Buxton et al., 1998) have shown it to be more virulent than Nc-Liverpool and to produce greater inflammation and more severe and frequent focal necrosis, sometimes associated with vasculitis and thrombosis.

The focal necrosis visible macroscopically as white spots scattered throughout the cotyledons and indistinguishable from ovine toxoplasmosis does differ microscopically from the latter. In toxoplasmosis the chorio-allantois is not involved, focal necrosis in placental cotyledons is remarkable for its relative lack of inflammation, and vasculitis and thrombosis do not feature. Pathological changes in fetal and placental tissues from naturally occurring and experimentally produced neosporosis in goats would appear to be similar to those seen in natural and experimental infections in sheep (Barr et al., 1992; Dubey et al., 1992, 1996; Lindsay et al., 1995). Vertical transmission to kids did not occur in a subsequent pregnancy (Lindsay et al., 1995).

In a preliminary report experimental infection with *N. caninum* before mating partially protected ewes and their developing fetuses against a second challenge with the parasite during pregnancy. Vaccination against toxoplasmosis (Toxovax, Intervet UK) however did not protect against challenge with *Neospora* (Buxton et al., 1997c). Thus it may be more difficult to induce solid immunity in sheep to *N. caninum* than to *T. gondii* although protection against both parasites probably results from stimulation of cell mediated immune mechanisms as in vitro studies have shown that recombinant ovine interferon gamma (IFN-gamma) can significantly inhibit multiplication of *N. caninum* in ovine fibroblast cell cultures (Innes et al., 1995c) as is the case with *T. gondii* (Oura et al., 1993). Studies with mice have underlined the importance of IFN-gamma in neosporosis and shown that interleukin-12 also has a role to play (Khan et al., 1997).

3.4. Diagnosis

Serology in sheep and goats has largely been carried out with the IFAT to detect IgM and IgG (Lindsay et al., 1995; Buxton et al., 1997b), IgG alone (Dubey et al., 1996; McAllister et al., 1996) or undefined immunoglobulin (Otter et al., 1997). ELISA have been developed for use in cattle using soluble extracts of sonicated neospora tachyzoites (Paré et al., 1995; Osawa et al., 1998), recombinant antigens (Lally et al., 1996a), extracted tachyzoite antigen incorporated into an immunostimulating compound (ISCOM) (Bjorkman et al., 1997) or whole organisms (Williams et al., 1997). One of these assays has been adapted successfully for use with sheep and goat sera (Osawa et al., 1998).

The PCR has been used both to make comparisons between *N. caninum* and *T. gondii* (Ellis et al., 1994; Holmdahl et al.,

1994) and as a potentially powerful diagnostic tool elegantly specific for *N. caninum* (Holmdahl and Mattsson, 1996; Kaufmann et al., 1996; Lally et al., 1996b; Muller et al., 1996; Payne and Ellis, 1996; Yamage et al., 1996). Their use in the field still remains to be demonstrated but their application to sections cut from wax embedded pathological samples could prove very valuable (Ellis, 1997).

3.5. Treatment

Dubey and Lindsay (1996) report that clindamycin, sulphonamides and/or pyrimethamine and trimethoprim with sulphadiazine have been used by various authors, often to good effect, in the treatment of clinical canine neosporosis. Their use at the appropriate dose rate could well be beneficial in the event of a diagnosis of clinical neosporosis being made in either a sheep or goat considered suitable and worthy of treatment.

4. SARCOCYSTIOSIS

Sarcocystis (synonyms; sarcosporidia, Meischer's tubules) exists as numerous species (Ugla and Buxton, 1990). In 1972 Rommel and colleagues reported that *Sarcocystis* underwent a coccidian-like life

cycle with each species having a distinct definitive host(s) (usually a carnivore) and an intermediate host (Rommel et al., 1979). Infections are recognised to occur in all parts of the world and farm animals are intermediate (tangential) hosts for a number of species (figure 3). Sheep are the intermediate host for four species, two microcyst species (*S. tenella* [syn. *S. ovi-canis*] and *S. arieticanis*) and two macrocyst species (*S. gigantea* [syn. *S. ovifelis*] and *S. medusififormis*) while goats are the intermediate host to *S. capracanis*, *S. hircicanis* and *S. moulei*.

4.1. Life cycle

Farm animals become infected following ingestion of sporocysts released by the definitive host. Following excystation in the intestinal lumen sporozoites penetrate the gut wall and multiply asexually by two schizogonous cycles in endothelial cells of small blood vessels (first and second generation merogony), with an associated parasitaemia. The merozoites released after second generation merogony penetrate muscle cells and form characteristic sarcocysts filled with bradyzoites, although they may also invade the central nervous system (Rommel, 1985). Ingestion of infected muscle by the definitive host triggers a sexual life cycle in the intestinal

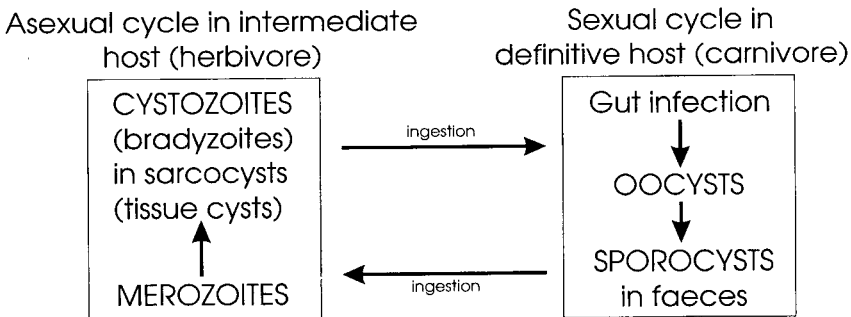


Figure 3. Life cycle of *Sarcocystis* species.

lining with the formation of macro- and microgamonts leading to the development of oocysts and then sporocysts which are excreted in the faeces.

4.2. Clinical disease

The parasite is ubiquitous and infections, which are extremely common, occur following ingestion of food or water contaminated with sporocysts. While most species appear to be non-pathogenic, a few, particularly those with a canine definitive host, may cause clinical illness (Uggla and Buxton, 1990). Symptoms include fever, anaemia and inappetence and an associated reduction in productivity. Fayer and Elsasser (1991) have suggested that the fever results from the release of interleukin-1 (IL-1) and prostaglandin E₂ while infection of macrophages by *Sarcocystis* causes release of tumour necrosis factor-alpha which i) causes inappetence, ii) together with IL-1 causes anaemia, iii) suppresses release of pituitary growth hormone, with resultant weight loss. It has also been suggested that retardation of growth in pigs infected with *S. meischeriana* is due to the parasite influencing an insulin-like growth factor (IGF) and an IGF binding protein (Prickett et al., 1992).

In some instances abortion and stillbirths (Uggla and Buxton, 1990; Mackie et al., 1992) or central nervous signs, including hind limb weakness, ataxia, paresis and death (Jeffrey et al., 1988; Dubey et al., 1989; Hamir et al., 1993; O'Toole et al., 1993) have been associated with sarcocystiosis. Hind limb weakness, quadriplegia and death have also been recorded in sheep suffering from acute myopathy associated with a sarcocystis infection (Jeffrey et al., 1988) and in cattle eosinophilic myositis is recognised (Granstrom et al., 1989; Saito et al., 1993). In experimentally induced disease the severity of clinical

symptoms is dose dependant (Rommel, 1985). Thus O'Donoghue and Wilkinson (1988) gave lambs 10⁴ *S. tenella* sporocysts but recorded no clinical signs while Munday (1981) showed that pregnant sheep experimentally infected with 6 × 10⁴ *S. tenella* sporocysts developed a mild fever followed by anaemia and gave birth early to small, weak lambs. After parturition the ewes developed myositis, myocarditis and encephalitis and died.

4.3. Diagnosis

As infection is extremely common it is very difficult to attribute the presence of sarcocysts to a disease process. Clinical symptoms are not commonly useful as a means of diagnosis as the vast majority of natural sarcocystis infections are sub-clinical and symptoms, when present, may be vague and non-specific. In cases of fatal acute sarcocystiosis tissues, such as the tongue, may appear mottled due to capillary haemorrhages (Uggla and Buxton, 1990). Histopathology is invaluable but only evidence of an active infection permits the possibility of a diagnosis of acute sarcocystiosis. Inflammatory changes may be confined to the central nervous system (CNS), often with the more prominent lesions in the spinal cord. Characteristically a non-suppurative meningo-encephalitis, associated with sarcocyst-like merozoites and meronts, gliosis and associated oedematous changes, is present (Jeffrey et al., 1988; Dubey et al., 1989; O'Toole et al., 1993). Mackie et al. (1992) also report a stillborn goat kid with a multifocal, necrotising, non-suppurative encephalitis with associated vascular endothelial cells containing sarcocyst-like meronts containing merozoites. Outwith the CNS the heart, tongue and liver may show marked mononuclear cell inflammation while tissues such as skeletal muscle, lung and kidney are usually less affected (Uggla and Buxton, 1990),

although in a spontaneous outbreak of acute myopathy in sheep, linked with a sarcocystis infection, histopathological lesions were confined largely to skeletal muscles and consisted of a non-suppurative myositis associated with mature, immature and degenerate sarcocysts (Jeffrey et al., 1989). As with toxoplasmosis and neosporosis, immunohistochemistry may be valuable (Jeffrey et al., 1988; O'Toole et al., 1993).

Serological methods most commonly used are the IFAT (Tadros and Laarman, 1982; Tenter, 1988; Uggla et al., 1987) and ELISA (Tadros and Laarman, 1982; Weiland et al., 1982; Gasbarre et al., 1984; O'Donoghue and Weyreter, 1984; Smith and Herbert, 1986; Tenter 1988). During the first merogonous stage of a *Sarcocystis* infection it may be difficult to detect an antibody response. This may be because the serological test uses an antigen preparation derived from cystozoites which may be antigenically distinct from the first generation merozoites (Uggla and Buxton, 1990). In this respect good sensitivity was reported for an ELISA using merozoite antigen, developed by Savini et al. (1994). The detection of an IgM response will suggest an acute or recent infection while an IgG response, in the absence of IgM antibodies, indicates a longer standing persistent infection (Uggla and Buxton, 1990). More recently PCR methods have been reported for a number of *Sarcocystis* spp. (MacPherson and Gajadhar, 1994; Tenter et al., 1994; Guo and Johnson, 1995; Joachim et al., 1996; Marsh et al., 1996) and they will prove valuable in establishing more accurate diagnostic procedures.

4.4. Control

Control is difficult but when a problem is perceived to occur attempts should be made to prevent contamination of animal pasture and other feed by faeces from

dogs, foxes, cats and other possible definitive hosts, or prevent access of young susceptible animals to such locations where contamination cannot be prevented.

4.4.1. Immunity

It seems likely that *Sarcocystis* spp. stimulate immune mechanisms similar to those induced by *T. gondii* and *N. caninum*. While little is known of the specific events which occur, in broad terms experimentally induced infection with a 'low' dose stimulates protective immunity to a secondary, homologous, 'high' (fatal) challenge dose (see below).

Goats experimentally infected with *S. capracanis* sporocysts resisted an otherwise fatal homologous challenge as early as 14 days later (Dubey, 1981d). However immunity to one species does not appear to trigger protective immunity to another species. Thus Fayer and Dubey (1984) showed that calves given 1×10^5 *S. cruzi* sporocysts developed non-fatal clinical sarcocystiosis and, when challenged 91 days later with 5×10^5 *S. cruzi* sporocysts, they again showed clinical signs of fever and anaemia but survived. Four control calves given only the second challenge died 27 ($n = 2$) and 28 ($n = 2$) days later and a further group of four given an initial infection of 1×10^5 *S. hirsuta* sporocysts and challenged 91 days later with 5×10^5 *S. cruzi* sporocysts also died 27 ($n = 2$) and 28 ($n = 2$) days after the second challenge. However Savini et al. (1996) showed that cows, considered to have been naturally infected with *Sarcocystis*, were not protected against a subsequent challenge with sporocysts or merozoites of *S. cruzi* during pregnancy. The former treatment caused stillbirths while the cows challenged with the latter produced live calves which were significantly lighter than control calves. These workers concluded that protective immunity from natural infection was transient.

Lambs experimentally infected with *S. tenella* sporocysts developed specific IgM and IgG to the parasite but neither following this primary challenge nor after a greater secondary challenge with the same parasite did they respond in a lymphocyte stimulation assay (LSA) to *S. tenella* antigen (either bradyzoite or sporozoite) (O'Donoghue and Wilkinson, 1988). This is in contrast to work by Gasbarre et al. (1984) who demonstrated with a LSA a blastogenic response in sheep to *S. tenella* antigen between 24 and 52 days after experimental infection (dpi) with *S. tenella* sporocysts. The authors also showed that calves infected with *S. cruzi* developed an earlier and shorter (15–21 dpi) blastogenic response to *S. cruzi* antigen in a similar LSA. Granstrom et al. (1989) suggested that this latter brief response may have occurred in the presence of continued antigenic stimulation and thus been associated with some form of parasite induced immunosuppression. Experiments in mice with *S. muris* have shown that the parasite causes both cell-mediated and humoral immunosuppression and that induction of immune memory appears to be affected while expression of immune memory remains unaffected (Gill et al., 1988a). These workers also showed that *S. muris* infection of mice causes splenomegaly with increased numbers of B-cells and, to a lesser extent, T-cells (Gill et al., 1988b). Whether this is linked to the observation that a *Sarcocystis* lectin (from *S. gigantea*) has both mitogenic properties as well as being a B cell activator (Tietz et al., 1990) remains to be seen.

Eosinophilic myositis (muscular sarcocystiosis) may be observed in cattle at slaughter. On inspection affected animals have yellow–green rice-grain sized nodules throughout their muscles. Microscopic examination has shown that each lesion represents a focus of necrosis infiltrated by eosinophils as well as lymphocytes and multinucleate giant cells (Saito et al.,

1993). Both sarcocystis antigen, IgG and IgE have been demonstrated within such lesions and specific IgE antibody has been demonstrated in the serum of affected cattle. It has been suggested that type-1 hypersensitivity is involved in the pathogenesis (Granstrom et al. 1989, 1990).

4.4.2. Pharmaceuticals

Treatment of clinical cases may be attempted and good results are recorded by Moore et al. (1997) who used trimethoprim-sulphamethoxazole and pyrimethamine and vitamin E for the treatment of horses clinically affected with *S. neurona*.

5. CURRENT AND FUTURE RESEARCH

Sarcocystis spp. are capable of causing both clinical and subclinical illness in sheep, goats and other animals and sarcocystiosis is probably underdiagnosed as a cause of production loss. It must be a priority to establish and deploy better diagnostic procedures so as to accurately define the true cost of these losses. Immunity develops following infection and it would seem to be both long lasting and to be associated with persistence of a viable 'quiet' infection. Whether this quiet infection repeatedly stimulates the immune system so maintaining an effective degree of immunity in the host is not known and neither is it clear to what extent recurrent exposure to infection is important. These apparently simple questions need to be addressed together with the more detailed mechanisms of host immunity and their role in protecting the host, as well as perhaps causing pathological change and clinical illness, in this very common infection.

Neosporosis in sheep and goats, however, would not appear to be as common a field infection as in cattle, even though

they often share a common environment, possibly because vertical transmission occurs much more readily in the latter. However, experimental ovine and caprine neosporosis is readily reproduced, offers a good model of the bovine infection and permits a more detailed analysis of certain aspects of the host/parasite interaction than could be achieved with cattle. At the same time any discrepancies between the 'model infection' and bovine neosporosis, such as vertical transmission, could point out the crucial differences in the respective host immune responses that could be exploited in the development of control measures for neospora abortion in cattle.

Toxoplasmosis in sheep and goats is important in its own right but is also a good model for studies of human toxoplasmosis as the latter more closely resembles the infection in sheep than it does the more extensively researched infection in mice (Innes and Wastling, 1995). The very success of *Toxoplasma* as an intracellular parasite is that it would appear able to infect any nucleated cell-type in any warm-blooded vertebrate. This very ubiquity and the relative ease with which a live infection (and hence live vaccine) induces immunity is in indirect proportion to the difficulty scientists have had in developing a non-viable vaccine. Success will require a detailed knowledge both of the parasite and the host response to it, including how tachyzoites bind to and subsequently invade cells (Joiner and Dubremetz, 1993; Kasper and Mineo, 1994) and the role of the secretory organelles (rhoptries, micronemes and dense granules) in establishing the tachyzoite in its parasitophorous vacuole in the cell (Joiner and Dubremetz, 1993; Cesbron-Delauw, 1994) where it multiplies. Equally it has been suggested that as *Toxoplasma* naturally infects animals orally, research should not ignore the potential role of mucosal immunity. In support of this experiments have shown that the purified major surface

tachyzoite protein SAG1 (30kDa/P30 antigen) in association with 'cholera toxin' presented to mice by the nasal route can very substantially reduce subsequent development of *T. gondii* tissue cysts in brain (Debard et al., 1996). Eventual success with these and other avenues of research will lead eventually to a cheap vaccine to prevent human and animal toxoplasmosis (Araujo, 1994) but also the knowledge gained will provide valuable insights into how to stimulate protective immunity to other apicomplexan protozoa such as *Neospora* and *Sarcocystis* spp.

REFERENCES

- Araujo F.G., Immunization against *Toxoplasma gondii*, Parasitol. Today 10 (1994) 358-360.
- Barr B.C., Anderson M.L., Woods L.W., Dubey J.P., Conrad P.A., *Neospora*-like protozoal infections associated with abortion in goats, J. Vet. Diagn. Invest. 4 (1992) 365-367.
- Beverley J.K.A., Congenital transmission of toxoplasmosis through successive generations of mice, Nature 183 (1959) 1348-1349.
- Beverley J.K., Archer J.F., Watson W.A., Fawcett A.R., Trial of a killed vaccine in the prevention of ovine abortion due to toxoplasmosis, Br. Vet. J. 127 (1971a) 529-535.
- Beverley J.K., Watson W.A., Payne J.M., The pathology of the placenta in ovine abortion due to toxoplasmosis, Vet. Rec. 88 (1971b) 124-128.
- Bjorkman C., Holmdahl O.J.M., Uggla A., An indirect enzyme-linked immunoassay (ELISA) for demonstration of antibodies to *Neospora caninum* in serum and milk of cattle, Vet. Parasitol. 68 (1997) 251-260.
- Blewett D.A., The epidemiology of ovine toxoplasmosis. I. The interpretation of data for the prevalence of antibody in sheep and other host species, Br. Vet. J. 139 (1983) 537-545.
- Blewett D.A., Watson W.A., The epidemiology of ovine toxoplasmosis. II. Possible sources of infection in outbreaks of clinical infection, Br. Vet. J. 139 (1983) 546-555.
- Blewett D.A., Teale A.J., Miller J.K., Scott G.R., Buxton D., Toxoplasmosis in rams: possible significance of venereal transmission, Vet. Rec. 111 (1982) 73-75.
- Blewett D.A., Miller J.K., Harding J., Simple technique for the direct isolation of toxoplasma tissue cysts from foetal ovine brain, Vet. Rec. 112 (1983) 98-100.

- Bowie W.R., King A.S., Werker D.H., Isaac-Renton J.L., Bell A., Eng S.B., Marion S.A. Outbreak of toxoplasmosis associated with municipal drinking water, *Lancet* 350 (1997) 173–177.
- Buxton D., Toxoplasmosis, in: Martin W.B., Aitken I.D. (Eds.), *Diseases of Sheep*, 2nd edn, Blackwell Scientific Publications, Oxford, 1991, pp. 49–58.
- Buxton D., Finlayson J., Experimental infection of pregnant sheep with *Toxoplasma gondii*: pathological and immunological observations on the placenta and foetus, *J. Comp. Pathol.* 96 (1986) 319–333.
- Buxton D., Gilmour J.S., Angus K.W., Blewett D.A., Miller J.K., Perinatal changes in toxoplasma infected lambs, *Res. Vet. Sci.* 32 (1982) 170–176.
- Buxton D., Blewett D.A., Trees A.J., McColgan C., Finlayson J., Further studies in the use of monensin in the control of experimental ovine toxoplasmosis, *J. Comp. Pathol.* 98 (1988) 225–236.
- Buxton D., Uggla A., Lövgren K., Thomson K., Lundén A., Morein B., Blewett D.A., Trial of a novel experimental *Toxoplasma* iscom vaccine in pregnant sheep, *Br. Vet. J.* 145 (1989) 451–457.
- Buxton D., Thomson K.M., Maley S., Wright S., Bos H.J., Vaccination of sheep with a live incomplete strain (S48) of *Toxoplasma gondii* and their immunity to challenge when pregnant, *Vet. Rec.* 129 (1991) 89–93.
- Buxton D., Thomson K.M., Maley S., Wright S., Bos H.J., Experimental challenge of sheep 18 months after vaccination with a live (S48) *Toxoplasma gondii* vaccine, *Vet. Rec.* 133 (1993a) 310–312.
- Buxton D., Thomson K.M., Maley S., Treatment of ovine toxoplasmosis with a combination of sulphamezathine and pyrimethamine, *Vet. Rec.* 132 (1993b) 409–411.
- Buxton D., Thomson K.M., Maley S., Wastling J.M., Innes E.A., Panton W.R.M., Nicoll S., Primary and secondary responses of the ovine lymph node to *Toxoplasma gondii*: cell output in efferent lymph and parasite detection, *J. Comp. Pathol.* 111 (1994) 231–241.
- Buxton D., Brebner J., Wright S., Maley S.W., Thomson K.M., Millard K., Decoquinat and the control of experimental ovine toxoplasmosis, *Vet. Rec.* 138 (1996) 434–436.
- Buxton D., Maley S.W., Pastoret P.-P., Brochier B., Innes E.A., Examination of red foxes (*Vulpes vulpes*) from Belgium for antibody to *Neospora caninum* and *Toxoplasma gondii*, *Vet. Rec.* 141 (1997a) 308–309.
- Buxton D., Maley S.W., Thomson K.M., Trees A.J., Innes E.A., Experimental infection of non-pregnant and pregnant sheep with *Neospora caninum*, *J. Comp. Pathol.* 117 (1997b) 1–16.
- Buxton D., Wright S., Maley S.W., Lunden A., Vermeulen A.N., Innes E.A., Protective immunity to *Neospora caninum*, in: Control of Coccidiosis into the Next Millenium, Proceedings of the VII International Coccidiosis Conference and European Union COST 820 Workshop, 1–5 September, 1997c, p. 86.
- Buxton D., Maley S.W., Wright S., Thomson K.M., Rae A.G., Innes E.A., The pathogenesis of experimental neosporosis in pregnant sheep, *J. Comp. Pathol.* 118 (1998) 267–279.
- Cesbron-Delauw M.-F., Dense-granule organelles of *Toxoplasma gondii*: their role in the host-parasite relationship, *Parasitol. Today* 10 (1994) 293–296.
- Chhabra M.B., Gautam O.P., Caprine abortion and neonatal mortality associated with toxoplasmosis in India, in: Les maladies de la chèvre, Niort (France) Les Colloques de l'Inra, No. 28, 1984, pp. 719–726.
- De Roever-Bonnet H., Congenital *Toxoplasma* infections in mice and hamsters infected with avirulent and virulent strains. *Trop. Geogr. Med.* 21 (1969) 443–450.
- Debard N., Buzoni-Gatel D., Bout D., Intranasal immunization with SAG1 protein of *Toxoplasma gondii* in association with cholera toxin dramatically reduces development of cerebral cysts after oral infection, *Infect. Immun.* 64 (1996) 2158–2166.
- Desmonts G., Remington J.S., Direct agglutination test for diagnosis of *Toxoplasma* infection: method for increasing sensitivity and specificity, *J. Clin. Microbiol.* 11 (1980) 562–568.
- Dubey J.P., Persistence of encysted *Toxoplasma gondii* in caprine livers and public health significance of toxoplasmosis in goats, *J. Am. Vet. Med. Assoc.* 177 (1980) 1203–1207.
- Dubey J.P., Epizootic toxoplasmosis associated with abortion in dairy goats in Montana, *J. Am. Vet. Med. Assoc.* 178 (1981a) 661–670.
- Dubey J.P., Protective immunity against clinical toxoplasmosis in dairy goats vaccinated with *Hammondia hammondi* and *Hammondia heydorni*, *Am. J. Vet. Res.* 42 (1981b) 2068–2070.
- Dubey J.P., Prevention of abortion and neonatal death due to toxoplasmosis by vaccination of goats with the nonpathogenic Coccidium *Hammondia hammondi*, *Am. J. Vet. Res.* 42 (1981c) 2155–2157.
- Dubey J.P., Development of immunity to sarcocystosis in dairy goats, *Am. J. Vet. Res.* 42 (1981d) 800–804.
- Dubey J.P., Repeat transplacental transfer of *Toxoplasma gondii* in goats, *J. Am. Vet. Med. Assoc.* 180 (1982) 1220–1221.

- Dubey J.P., Experimental toxoplasmosis in sheep fed *Toxoplasma gondii* oocysts. *Int. Goat Sheep Res.* 2 (1984) 93–104.
- Dubey J.P., Lesions in transplacentally induced toxoplasmosis in goats. *Am. J. Vet. Res.* 49 (1988) 905–909.
- Dubey J.P., Frenkel J.K., Immunity to feline toxoplasmosis: modification by administration of corticosteroids. *Vet. Pathol.* 11 (1974) 350–379.
- Dubey J.P., Sharma S.P., Parasitaemia and tissue infection in sheep fed *Toxoplasma gondii* oocysts. *J. Parasitol.* 66 (1980a) 111–114.
- Dubey J.P., Sharma S.P., Prolonged excretion of *Toxoplasma gondii* in semen of goats. *Am. J. Vet. Res.* 41 (1980b) 794–795.
- Dubey J.P., Beattie C.P., *Toxoplasmosis of Man and Animals*, CRC Press, Boca Raton, 1988.
- Dubey J.P., Lindsay D.S., *Neospora caninum* induced abortion in sheep. *J. Vet. Diagn. Invest.* 2 (1990) 230–233.
- Dubey J.P., Lindsay D.S., Neosporosis. *Parasitol. Today* 9 (1993) 452–458.
- Dubey J.P., Lindsay D.S., A review of *Neospora caninum* and neosporosis. *Vet. Parasitol.* 67 (1996) 1–59.
- Dubey J.P., Sharma S.P., Lopes C.W.G., Williams J.F., Williams C.S.F., Weisbrode S.E., Caprine toxoplasmosis: abortion, clinical signs and distribution of *Toxoplasma* in tissues of goats fed *Toxoplasma gondii* oocysts. *Am. J. Vet. Res.* 41 (1980) 1072–1076.
- Dubey J.P., Sundberg J.P., Matiuck S.W., Toxoplasmosis associated with abortion in goats and sheep in Connecticut. *Am. J. Vet. Res.* 42 (1981) 1624–1626.
- Dubey J.P., Desmonts G., Antunes F., McDonald C., Serologic diagnosis of toxoplasmosis in experimentally infected pregnant goats and transplacentally infected kids. *Am. J. Vet. Res.* 46 (1985) 1137–1140.
- Dubey J.P., Speer C.A., Munday B.L., Lipscomb T.P., Ovine sporozoan encephalomyelitis linked to *Sarcocystis* infection. *Vet. Parasitol.* 34 (1989) 159–163.
- Dubey J.P., Hartley W.J., Lindsay D.S., Topper M.J., Fatal congenital *Neospora caninum* infection in a lamb. *J. Parasitol.* 76 (1990) 127–130.
- Dubey J.P., Acland H.M., Hamir A.N., *Neospora caninum* (Apicomplexa) in a stillborn goat. *J. Parasitol.* 78 (1992) 532–534.
- Dubey J.P., Morales J.A., Villabos P., Lindsay D.S., Blagburn B.L., Topper M.J., Neosporosis-associated abortion in a dairy goat. *JAVMA* 208 (1996) 263–265.
- Dubey J.P., Shen S.K., Kwok O.C.H., Thulliez P., Toxoplasmosis in rats (*Rattus norvegicus*): congenital transmission to first and second generation offspring and isolation of *Toxoplasma gondii* from seronegative rats. *Parasitology* 115 (1997) 9–14.
- Eichenwald H., Experimental toxoplasmosis. I. Transmission of the infection in utero and through the milk of lactating female mice. *Am. J. Dis. Child.* 76 (1948) 307–315.
- Ellis J.T., *Neospora caninum*: prospects for diagnosis and control using molecular methods, in: *Control of Coccidiosis into the Next Millennium*, Proceedings of the VII International Coccidiosis Conference and European Union COST 820 Workshop, 1–5 September, Oxford, 1997, pp. 80–81.
- Ellis J., Luton K., Baverstock P.R., Brindley P.J., Nimmo K.A., Johnson A.M., The phylogeny of *Neospora caninum*. *Mol. Biochem. Parasitol.* 64 (1994) 303–311.
- Fayer R., Dubey J.P., Protective immunity against sarcocystosis in cattle. *Vet. Parasitol.* 15 (1984) 187–201.
- Fayer R., Elsasser T.H., Bovine sarcocystosis: how parasites negatively affect growth. *Parasitol. Today* 7 (1991) 250–255.
- Faulk W.B., Clarkson M.J., Winter A.C., Toxoplasmosis in a flock of sheep: some investigations into its source and control. *Vet. Rec.* 119 (1986) 491–493.
- Fleck D.G., Kwantes W., *The Laboratory Diagnosis of Toxoplasmosis*, Public Health Laboratory Service, London Monograph series 13, 1980.
- Gasbarre L.C., Suter P., Fayer R., Humoral and cellular immune responses in cattle and sheep inoculated with *Sarcocystis*. *Am. J. Vet. Res.* 8 (1984) 1592–1596.
- Gill H.S., Charleston W.A.G., Moriarty K.M., Immunosuppression in *Sarcocystis muris*-infected mice: evidence for suppression of antibody and cell-mediated responses to a heterologous antigen. *Immunol. Cell Biol.* 66 (1988a) 209–214.
- Gill H.S., Charleston W.A.G., Moriarty K.M., Cellular changes in the spleens of mice infected with *Sarcocystis muris*. *Immunol. Cell Biol.* 66 (1988b) 337–343.
- Granstrom D.E., Ridley R.K., Baoan Y., Gershwin L.J., Nesbitt P.M., Wempe L.A., Type-1 hypersensitivity as a component of eosinophilic myositis (muscular sarcocystosis) in cattle. *Am. J. Vet. Res.* 50 (1989) 571–574.
- Granstrom D.E., Ridley R.K., Baoan Y., Gershwin L.J., Briggs D.J., Immunofluorescent localization of *Sarcocystis cruzi* antigens. IgG and IgE, in lesions of eosinophilic myositis in cattle. *J. Vet. Diagn. Invest.* 2 (1990) 147–149.
- Guo Z.G., Johnson A.M., Genetic comparison of *Neospora caninum* with *Toxoplasma gondii* and *Sarcocystis* by random amplified polymorphic DNA-polymerase chain reaction. *Parasitol. Res.* 81 (1995) 365–370.

- Hamir A.N., Moser G., Galligan D.T., Davis S.W., Granstrom D.E., Dubey J.P., Immunohistochemical study to demonstrate *Sarcocystis neurona* in equine protozoal myeloencephalitis, *J. Vet. Diagn. Invest.* 5 (1993) 418–422.
- Hartley W.J., Kater J.C., The pathology of *Toxoplasma* infection in the pregnant ewe, *Res. Vet. Sci.* 4 (1963) 326–332.
- Hartley W.J., Bridge P.S., A case of suspected congenital *Toxoplasma* encephalomyelitis in a lamb associated with a spinal cord anomaly, *Br. Vet. J.* 131 (1975) 380–384.
- Holmdahl O.J.M., Mattsson J.G., Rapid and sensitive identification of *Neospora caninum* by *in vitro* amplification of the internal transcribed spacer 1, *Parasitology* 112 (1996) 177–182.
- Holmdahl O.J.M., Mattsson J.G., Uggla A., Johansson K.-E., The phylogeny of *Neospora caninum* and *Toxoplasma gondii* based on ribosomal sequences, *FEMS Microbiol. Lett.* 119 (1994) 187–192.
- Innes E.A., Wastling J.M., Analysis of *in vivo* immune responses during *Toxoplasma gondii* infection using the technique of lymphatic cannulation, *Parasitol. Today* 11 (1995) 268–271.
- Innes E.A., Panton W.R.M., Sanderson A., Thomson K.M., Wastling J.M., Maley S., Buxton D., Induction of CD4+ and CD8+ T cell responses in efferent lymph responding to *Toxoplasma gondii* infection: analysis of phenotype and function, *Parasite Immunol.* 17 (1995a) 151–160.
- Innes E.A., Panton W.R.M., Thomson K.M., Maley S., Buxton D., Kinetics of interferon gamma production *in vivo* during infection with the S48 vaccine strain of *Toxoplasma gondii*, *J. Comp. Pathol.* 113 (1995b) 89–94.
- Innes E.A., Panton W.R.M., Marks J., Trees A.J., Holmdahl J., Buxton D., Interferon gamma inhibits the intracellular multiplication of *Neospora caninum*, as shown by incorporation of 3H uracil, *J. Comp. Pathol.* 113 (1995c) 95–100.
- Jackson M.H., Hutchison W.M., The prevalence and source of *Toxoplasma* infection in the environment, in: Baker J.R., Muller R. (Eds.), *Advances in Parasitology*, vol. 28, Academic Press, London, 1989, pp. 55–105.
- Jeffrey M., O'Toole D., Smith T., Bridges A.W., Immunocytochemistry of ovine sporozoan encephalitis and encephalomyelitis, *J. Comp. Pathol.* 98 (1988) 213–224.
- Jeffrey M., Low J.C., Uggla A., A myopathy of sheep associated with sarcocystis infection and monensin administration, *Vet. Rec.* 124 (1989) 422–426.
- Joachim A., Tenter A.M., Jeffries A.C., Johnson A.M., A RAPD-PCR derived marker can differentiate between pathogenic and non-pathogenic *Sarcocystis* species of sheep, *Mol. Cell Probes* 20 (1996) 165–172.
- Joiner K.A., Dubremetz J.F., *Toxoplasma gondii*: a protozoan for the nineties, *Infect. Immun.* 61 (1993) 1169–1172.
- Kasper L.H., Mineo J.R., Attachment and invasion of host cells by *Toxoplasma gondii*, *Parasitol. Today* 10 (1994) 184–188.
- Kaufmann H., Yamage M., Roditi I., Dobbelaere D., Dubey J.P., Holmdahl O.J.M., Trees A.J., Gottstein B., Discrimination of *Neospora caninum* from *Toxoplasma gondii* and other apicomplexan parasites by hybridization and PCR, *Mol. Cell Probes* 10 (1996) 289–297.
- Khan I.A., Schwartzman J.D., Fonseka S., Kasper L.H., *Neospora caninum*: role for immune cytokines in host immunity, *Exp. Parasitol.* 85 (1997) 24–34.
- Lally N.C., Jenkins M.C., Dubey J.P., Evaluation of two *Neospora caninum* recombinant antigens for use in an enzyme-linked immunosorbent assay for the diagnosis of bovine neosporosis, *Clin. Diagn. Lab. Immunol.* 3 (1996a) 275–279.
- Lally N.C., Jenkins M.C., Dubey J.P., Development of a polymerase chain reaction assay for the diagnosis of neosporosis using *Neospora caninum* 14-3-3 gene, *Mol. Biochem. Parasitol.* 75 (1996b) 169–178.
- Lindsay D.S., Rippey N.S., Powe T.A., Sartin E.A., Dubey J.P., Blagburn B.L., Abortions, fetal death, and stillbirths in pregnant pygmy goats inoculated with tachyzoites of *Neospora caninum*, *Am. J. Vet. Res.* 56 (1995) 1176–1180.
- McAllister M.M., McGuire A.M., Jolley W.R., Lindsay D.S., Trees A.J., Stobart R.H., Experimentally induced neosporosis in pregnant ewes and their offspring, *Vet. Pathol.* 33 (1996) 647–655.
- McColgan C., Buxton D., Blewett D.A., Titration of *Toxoplasma gondii* oocysts in non-pregnant sheep and the effects of subsequent challenge during pregnancy, *Vet. Rec.* 123 (1988) 467–470.
- Macdonald D., The behaviour and ecology of farm cats, in: *The Ecology and Control of Feral Cats*, Herts. University Federation for Animal Welfare, Potters Bar, 1980, pp. 23–29.
- McHugh T.D., Bathgate T., Mangan J., Johnson J.D., Holliman R.E., Butcher P.D., Recognition of tissue cyst-specific antigens in reactivating toxoplasmosis, *J. Med. Microbiol.* 46 (1997) 587–595.
- Mackie J.T., Rahaley R.S., Nugent R., Suspected *Sarcocystis* encephalitis in a stillborn kid, *Aust. Vet. J.* 69 (1992) 114–115.
- McLeod R., Frenkel J.K., Estes R.G., Mack D.G., Eisenhauer P.B., Gibori G., Subcutaneous and intestinal vaccination with tachyzoites of

- Toxoplasma gondii* and acquisition of immunity to peroral and congenital *Toxoplasma* challenge, *J. Immunol.* 140 (1988) 1632–1637.
- MacPherson J.M., Gajadhar A.A., Specific amplification of *Sarcocystis cruzi* DNA using a randomly primed polymerase chain reaction assay, *Vet. Parasitol.* 55 (1994) 267–277.
- Maley S.W., Thomson K.M., Bos H.J., Buxton D., Serological diagnosis of toxoplasmosis in sheep following vaccination and challenge, *Vet. Rec.* 140 (1997) 558–559.
- Marsh A.E., Barr B.C., Madigan J., Lakritz J., Conrad P.A., Sequence analysis and polymerase chain reaction amplification of small subunit ribosomal DNA from *Sarcocystis neurona*, *Am. J. Vet. Res.* 57 (1996) 975–981.
- Moore L.A., Johnson P.J., Messer N.T., Kline K.L., Crump L.M., Knibb J.R., Management of headshaking in three horses by treatment for protozoal myeloencephalitis, *Vet. Rec.* 141 (1997) 264–267.
- Muller N., Zimmermann V., Hentrich B., Gottstein B., Diagnosis of *Neospora caninum* and *Toxoplasma gondii* infection by PCR and DNA hybridization immunoassay, *J. Clin. Microbiol.* 34 (1996) 2850–2852.
- Munday B.L., Premature parturition in ewes inoculated with *Sarcocystis ovis*, *Vet. Parasitol.* 9 (1981) 17–26.
- Munday B.L., Mason R.W., Toxoplasmosis as a cause of perinatal mortality in goats, *Aust. Vet. J.* 55 (1979) 485–487.
- Munday B.L., Dubey J.P., Prevention of *Toxoplasma gondii* abortion in goats by vaccination with oocysts of *Hammondia hammondi*, *Aust. Vet. J.* 65 (1988) 150–153.
- Nurse G.H., Lenghaus C., An outbreak of *Toxoplasma gondii* abortion, mummification and perinatal death in goats, *Aust. Vet. J.* 63 (1986) 27–29.
- O'Connell E., Wilkins M.F., Te Punga W.A., Toxoplasmosis in sheep. II. The ability of a live vaccine to prevent lamb losses after an intravenous challenge with *Toxoplasma gondii*, *New Zeal. Vet. J.* 36 (1988) 1–4.
- O'Donoghue P.J., Weyreter H., Examinations on the serodiagnosis of *Sarcocystis* infections II. Class-specific immunoglobulin responses in mice, pigs and sheep, *Zentralbl. Bakt. Microbiol. Hyg. Ser. A* 257 (1984) 168–184.
- O'Donoghue P.J., Wilkinson R.G., Antibody development and cellular immune responses in sheep immunized and challenged with *Sarcocystis tenella* sporocysts, *Vet. Parasitol.* 27 (1988) 251–265.
- O'Toole D., Jeffrey M., Challoner D., Maybey R., Welch V., Ovine myeloencephalitis-leukomalacia associated with a *Sarcocystis*-like protozoan, *J. Vet. Diagn.* 5 (1993) 212–225.
- Obendorf D.L., Statham P., Munday B.L., Resistance to *Toxoplasma* abortion in female goats previously exposed to *Toxoplasma* infection, *Aust. Vet. J.* 67 (1990) 233–234.
- Opel U., Charleston W.A.G., Pomroy W.E., Rommel M., A survey of the prevalence of *Toxoplasma* infection in goats in New Zealand and a comparison of the latex agglutination and indirect fluorescence tests, *Vet. Parasitol.* 40 (1991) 181–186.
- Osawa T., Wastling J., Maley S., Buxton D., Innes E.A., A multiple antigen ELISA to detect *Neospora*-specific antibodies in bovine sera, bovine foetal fluids, ovine and caprine sera, *Vet. Parasitol.* (1998) in press.
- Otter A., Wilson B.W., Scholes S.F.E., Jeffrey M., Trees A.J., Results of a survey to determine whether *Neospora* is a significant cause of ovine abortion in England and Wales, *Vet. Rec.* 140 (1997) 175–177.
- Oura C.A.L., Innes E.A., Wastling J.M., Entrican G., Panton W.R.M., The inhibitory effect of ovine recombinant interferon-gamma on intracellular replication of *Toxoplasma gondii*, *Parasite Immunol.* 15 (1993) 535–538.
- Paré J., Hietal S.K., Thurmond M.C., An enzyme-linked immunosorbent assay (ELISA) for serological diagnosis of *Neospora* sp. infection in cattle, *J. Vet. Diagn. Invest.* 7 (1995) 352–359.
- Patton S., Johnson S.S., Puckett K., Prevalence of *Toxoplasma gondii* antibodies in nine populations of dairy goats: compared titers using modified direct agglutination and indirect hemagglutination, *J. Parasitol.* 76 (1990) 74–77.
- Payne S., Ellis J., Detection of *Neospora caninum* DNA by the polymerase chain reaction, *Int. J. Parasitol.* 26 (1996) 347–351.
- Peach W., Fowler J., Hay J., Incidence of *Toxoplasma* infection in a population of European starlings *Sternus vulgaris* from central England, *Ann. Trop. Med. Parasitol.* 83 (1989) 173–177.
- Plant J.W., Richardson N., Moyle A.G., *Toxoplasma* infection and abortion in sheep associated with feeding of grain contaminated with cat faeces, *Aust. Vet. J.* 50 (1974) 19–20.
- Prickett M.D., Latimer A.M., McCusker R.H., Hausman G.J., Prestwood A.K., Alterations of serum insulin-like growth factor-1 (IGF-1) and IGF-binding proteins in swine infected with the protozoan parasite *Sarcocystis meischeriana*, *Dom. Anim. Endocrinol.* 9 (1992) 285–296.
- Reid H.W., Buxton D., Gardiner A.C., Pow I., Finlayson J., Maclean M.J., Immunosuppression in toxoplasmosis: studies of lambs

- and sheep infected with louping-ill virus, *J. Comp. Pathol.* 92 (1982) 181–190.
- Rommel M., Sarcocystosis of domestic animals and humans, In *Practice* 7 (1985) 158–160.
- Rommel M., Heydorn A.O., Erber M., Die Sarkosporidiose der Haustiere und des Menschen, *Berl. Muench. Tierärztl. Wochenschr.* 92 (1979) 457–464.
- Sabin A.B., Feldman H.A., Dyes as micro-chemical indicators of a new immunity phenomenon affecting a protozoan parasite (*Toxoplasma*), *Science* 108 (1948) 660–663.
- Saito M., Mizusawa K., Itagaki H., Chronic *Sarcocystis* infections in slaughtered cattle, *J. Vet. Med.* 55 (1993) 757–761.
- Salami M. Al., Simpson-Morgan M.W., Morris B., Haemopoiesis and the development of immunological reactivity in the sheep foetus, in: Morris B., Miyasaka M. (Eds.), *Immunology of Shecp*, Editiones (Roche), Basle, 1985, pp. 19–36.
- Savini G., Dunsmore J.D., Robertson I.D., Evaluation of a serological test system for the diagnosis of *Sarcocystis cruzi* infection in cattle using *S. cruzi* merozoite antigen, *Vet. Parasitol.* 51 (1994) 181–189.
- Savini G., Dunsmore J.D., Robertson I.D., Studies on pathogenesis, tissue infection and congenital transmission in cows experimentally infected with *Sarcocystis cruzi*, *Vet. Parasitol.* 64 (1996) 319–327.
- Skinner L.J., Timperley A.C., Wightman D., Chatterton J.M.W., Ho-Yen D.O., Simultaneous diagnosis of toxoplasmosis in goats and goat owner's family, *Scand. J. Infect Dis* 22 (1990) 359–361.
- Smith T.S., Herbert I.V., Experimental microcyst *Sarcocystis* infection in lambs: serology and immunohistochemistry, *Vet. Rec.* 119 (1986) 547–550.
- Spence J.A., Mitchell G.B.B., McNally J.M., Blewett D.A., Wright F., The vaccinal efficacy of the S48 strain "Toxovax" of *Toxoplasma gondii* against natural field outbreaks of ovine toxoplasmosis, Abstracts of the VIth European Multicolloquium of Parasitology, The Hague, 1992, p. 103.
- Suzuki Y., Remington J.S., The effect of anti-IFN- γ antibody on the protective effect of Iy2+ immune T cells against toxoplasmosis in mice, *J. Immunol.* 144 (1990) 1954–1956.
- Tabor R., General biology of feral cats, in: *The Ecology and Control of Feral Cats*, Hertis. University Federation for Animal Welfare, Potters Bar, 1980, pp. 5–11.
- Tadros W., Laarman J.J., Current concepts on the biology, evolution and taxonomy of tissue cyst forming Eimeriid coccidia, *Adv. Parasitol.* 20 (1982) 293–468.
- Tenter A.M., Comparison of Dot-ELISA, ELISA and IFAT for the detection of IgG antibodies to *Sarcocystis muris* in experimentally infected and immunized mice, *Vet. Parasitol.* 29 (1988) 89–104.
- Tenter A.M., Luton K., Johnson A.M., Species-specific identification of *Sarcocystis* and *Toxoplasma* by PCR amplification of small subunit ribosomal RNA gene fragments, *Appl. Parasitol.* 35 (1994) 173–188.
- Tietz H.J., Montag T., Brose E., Widera P., Kiessig S.T., Mann W., Hiepe T., *Sarcocystis gigantea* lectin - mitogen and polyclonal B-cell activator, *Parasitol. Res.* 76 (1990) 332–335.
- Trees A.J., Crozier S.J., Buxton D., Blewett D.A., Serodiagnosis of ovine toxoplasmosis: an assessment of the latex agglutination test and the value of IgM specific titres after experimental oocyst-induced infection, *Res. Vet. Sci.* 46 (1989) 67–72.
- Uggla A., Buxton D., Immune responses against *Toxoplasma* and *Sarcocystis* infections in ruminants: diagnosis and prospects for vaccination, *Rev. Sci. Tech. Off. Int. Epiz.* 9 (1990) 441–462.
- Uggla A., Sjöland L., Dubey J.P., Immunohistochemical demonstration of toxoplasmosis in fetuses and fetal membranes of sheep, *Am. J. Vet. Res.* 48 (1987) 348–351.
- Waldeland H., Frenkel J.K., Live and killed vaccines against toxoplasmosis in mice, *J. Parasitol.* 69 (1983) 60–65.
- Wastling J.M., Nicoll S., Buxton D., Comparison of two gene amplification methods for the detection of *Toxoplasma gondii* in experimentally infected sheep, *J. Med. Microbiol.* 38 (1993) 360–365.
- Weiland G., Reiter I., Boch J., Möglichkeiten und Grenzen des serologischen Nachweises von Sarkosporidieninfektionen, *Berl. Muench Tierärztl. Wochenschr.* 95 (1982) 387–392.
- Wilkins M.F., O'Connell E., Te Punga W.A., Toxoplasmosis in sheep. I. Effect of a killed vaccine on lamb losses caused by experimental challenge with *Toxoplasma gondii*, *New Zeal. Vet. J.* 35 (1987) 31–34.
- Wilkins M.F., O'Connell E., Te Punga W.A., Toxoplasmosis in sheep. III. Further evaluation of the ability of a live *Toxoplasma gondii* vaccine to prevent lamb losses and reduce congenital infection following experimental oral challenge, *New Zeal. Vet. J.* 36 (1988) 86–89.
- Williams D.T.L., McGarry J., Guy F., Barber J., Trees A.J., Novel ELISA for detection of *Neospora*-specific antibodies in cattle, *Vet. Rec.* 140 (1997) 328–331.
- Yamage M., Fletcher O., Gottstein B., *Neospora caninum*: specific oligonucleotide primers for the detection of brain "cyst" DNA of experimentally infected nude mice by the polymerase chain reaction, *J. Parasitol.* 82 (1996) 272–279.