



**HAL**  
open science

## Virus association with lymphocytes in acute African swine fever

L Carrasco, F Chacón-M de Lara, J Martín de Las Mulas, Jc Gómez-Villamandos, J Hervás, Pj Wilkinson, Ma Sierra

► **To cite this version:**

L Carrasco, F Chacón-M de Lara, J Martín de Las Mulas, Jc Gómez-Villamandos, J Hervás, et al..  
Virus association with lymphocytes in acute African swine fever. *Veterinary Research*, 1996, 27 (3),  
pp.305-312. hal-00902424

**HAL Id: hal-00902424**

**<https://hal.science/hal-00902424v1>**

Submitted on 11 May 2020

**HAL** is a multi-disciplinary open access archive for the deposit and dissemination of scientific research documents, whether they are published or not. The documents may come from teaching and research institutions in France or abroad, or from public or private research centers.

L'archive ouverte pluridisciplinaire **HAL**, est destinée au dépôt et à la diffusion de documents scientifiques de niveau recherche, publiés ou non, émanant des établissements d'enseignement et de recherche français ou étrangers, des laboratoires publics ou privés.

## Virus association with lymphocytes in acute African swine fever

L Carrasco <sup>1\*</sup>, F Chacón-M de Lara <sup>1</sup>, J Martín de las Mulas <sup>1</sup>,  
JC Gómez-Villamandos <sup>1</sup>, J Hervás <sup>1</sup>, PJ Wilkinson <sup>2</sup>, MA Sierra <sup>1</sup>

<sup>1</sup> Departamento de Anatomía y Anatomía Patológica Comparadas, Facultad de Veterinaria,  
Universidad de Córdoba, Avda Medina Azahara 7, 14005 Córdoba, Spain;

<sup>2</sup> Institute for Animal Health, Pirbright Laboratory, Pirbright, UK

(Received 5 January 1996; accepted 22 February 1996)

**Summary** — This paper reports the presence of mature viral particles within the lymphocytes of samples taken from pigs inoculated with a highly virulent African swine fever (ASF) virus isolate (Malawi '83), and the adhesion of the lymphocytes to macrophages containing the virus replication sites. Virus replication in lymph-node medullar tissue macrophages was observed from 3 days post inoculation (pi). At 3 days pi, transmission electron microscopy revealed hemadsorption in some infected macrophages. At 5 and 7 days pi, a number of macrophages with virus replication were surrounded by a ring of lymphocytes. In such cases, mature viral particles were observed in membrane evaginations of the infected cell that corresponded to invaginations of the lymphocyte membrane. Also at 5 and 7 days pi, mature virions were observed within the cytoplasm of some lymphocytes. However, incomplete virions and African swine fever virus replication sites were not observed within the lymphocytes.

**pig / virus / African swine fever / lymphocyte**

**Résumé** — **Association entre virus et lymphocytes au cours d'un épisode aigu de peste porcine africaine.** Cette étude décrit la présence de particules virales mûres dans des lymphocytes provenant de porcs inoculés avec une souche fortement virulente du virus de la peste porcine africaine (Malawi '83), et l'adhérence de lymphocytes à des macrophages qui contenaient des centres de réplication virale. La réplication du virus dans les macrophages du tissu médullaire des nodules lymphatiques a été observée à partir du 3<sup>e</sup> jour postinoculation (pi). De même au 3<sup>e</sup> jour pi, l'analyse au microscope électronique à transmission a révélé la présence de phénomènes d'hémadsorption dans quelques-uns de ces macrophages infectés. Aux 5<sup>e</sup> et 7<sup>e</sup> jours pi, quelques macrophages contenant des centres de répli-

\* Correspondence and reprints

*cation virale se sont trouvés entourés d'un cercle de lymphocytes; dans ces cas-là, on a observé des particules virales mûres dans les évaginations membranaires de la cellule infectée qui correspondaient à des invaginations des lymphocytes. En outre, au 5<sup>e</sup> et 7<sup>e</sup> jours pi on a observé des particules virales dans le cytoplasme de certains lymphocytes. Cependant, dans aucun cas on n'a observé de particules virales incomplètes ou de centres de réplication virale de la peste porcine africaine dans les lymphocytes.*

**porc / virus / peste porcine africaine / lymphocyte**

## INTRODUCTION

African swine fever (ASF) is a pig disease caused by an as yet unclassified icosahedral virus (Madeley, 1990). ASF virus replicates primarily in mononuclear phagocyte system cells (Mebus, 1987, 1988; Sierra et al, 1991). Replication has, however, also been reported in other cell types, including endothelial cells (Sierra et al, 1989; Gómez-Villamandos et al, 1995a,b,c), hepatocytes (Sierra et al, 1987; Gómez-Villamandos et al, 1995d), renal tubular epithelial cells (Gómez-Villamandos et al, 1995a), fibroblasts and smooth muscle cells (Gómez-Villamandos et al, 1995c) and neutrophils (Carrasco et al, 1996). In all cell types, ASF virus replication sites are described as a rounded area of organelle-free cytoplasm containing membranous structures and icosahedral virus particles with electron-dense nucleoids (mature) or without nucleoids (immature) (Sierra et al, 1987, 1989; Gómez-Villamandos et al, 1995a, b, c, d; Carrasco et al, 1996).

ASF is characterized by lymphopenia and a state of immunodeficiency (Sánchez-Vizcaino et al, 1981). Whole blood cell counts in swine with acutely fatal ASF are reduced, with a marked decrease in lymphocyte percentages (Wardley and Wilkinson, 1977a, b; Genovesi et al, 1988). This decrease has been attributed to lymphocyte necrosis in the course of acute forms of the disease; some authors suggest that necrosis results from the cytolytic infection of lymphocytes (Wardley and Wilkinson,

1977b). The possible replication of ASF virus in lymphocytes, however, has given rise to a certain amount of controversy. The argument advanced by Wardley and Wilkinson (1977b), that virus replication does in fact take place in these cells, is supported by immunohistochemical studies demonstrating the presence of viral antigen in lymphocytes (Colgrove, 1966; Colgrove et al, 1969), as well as by *in vitro* (Wardley and Wilkinson, 1977b) and titration studies highlighting the association of the virus with erythrocytes and lymphocytes (Wardley and Wilkinson, 1977a; Genovesi et al, 1988); as the latter authors suggest, however, this association cannot be considered proof that lymphocytes are susceptible to ASF virus infection (Genovesi et al, 1988). Other authors (Casal et al, 1984; Pan, 1987) argue that lymphocytes are resistant to ASF virus infection, a hypothesis equally supported by immunohistochemical studies to detect viral antigens (Mínguez et al, 1988; Pan, 1987; Fernández et al, 1992; Pérez et al, 1994) and *in vitro* studies by Casal et al (1984) showing that while the virus replicates in macrophages and neutrophils, B and T lymphocytes, either resting or stimulated with mitogens, are resistant to ASF virus infection. Moreover, a recent study of apoptosis of lymphocytes in acute ASF revealed no evidence of virus replication in these cells (Gómez-Villamandos et al, 1995c).

This paper describes the incidental finding of rings of lymphocytes adhering to macrophages containing virus replication sites, the presence of viral particles within lymphocytes and the absence of virus repli-

cation sites in those virus-bearing lymphocytes.

## MATERIALS AND METHODS

Nine Large White x Landrace cross-bred pigs of both sexes were used for this study. The pigs weighed roughly 30 kg at the beginning of the experiment and were free from infectious and parasitic diseases; they were fed with Prime Grover (Sctas Ltd, Winchester, UK) and housed in an environmentally-controlled isolation room. One pig was used as uninfected control, and the remainder were inoculated im with  $10^5$  50% hemadsorbing doses (HAD<sub>50</sub>) of the Malawi '83 ASF virus isolate (Harespane, 1984). The animals exhibited no behavioral changes due to experimental conditions and developed clinical signs characteristic of ASF (Hess, 1971). Animals were slaughtered in pairs at 1, 3, 5 and 7 days post inoculation (pi). The experiment was performed at the Institute of Animal Health, Pirbright (UK), in accordance with the Code of Practice for the Housing and Care of Animals used in Scientific Procedures.

Tissues were fixed by vascular perfusion using 2.5% glutaraldehyde in 0.1 M phosphate buffer (pH 7.4), at a pressure of 120 mmHg. Prior to perfusion, animals were sedated with azaperone (Stresnil, Janssen Animal Health, Belgium) and anesthetized with thiopental-sodium (Thiovet, Vet Limited, UK). Samples from retropharyngeal, mediastinic, gastro-hepatic and renal lymph nodes were embedded in paraffin and Epon 812 (Fluka, Buchs, Switzerland). For ultrastructural analysis, lymph-node sections 50 nm thick were contrasted with uranyl acetate and lead citrate and viewed through a Philips CM-10 transmission electron microscope.

Twelve blocks from each lymph node were studied per animal, and a cell count was made over forty 90 x 90  $\mu$ m fields of each lymph node per animal.

## RESULTS

From 3 days pi onwards, numerous macrophages and monocytes, present mainly in the medullar tissue of all lymph nodes, showed virus replication sites visi-

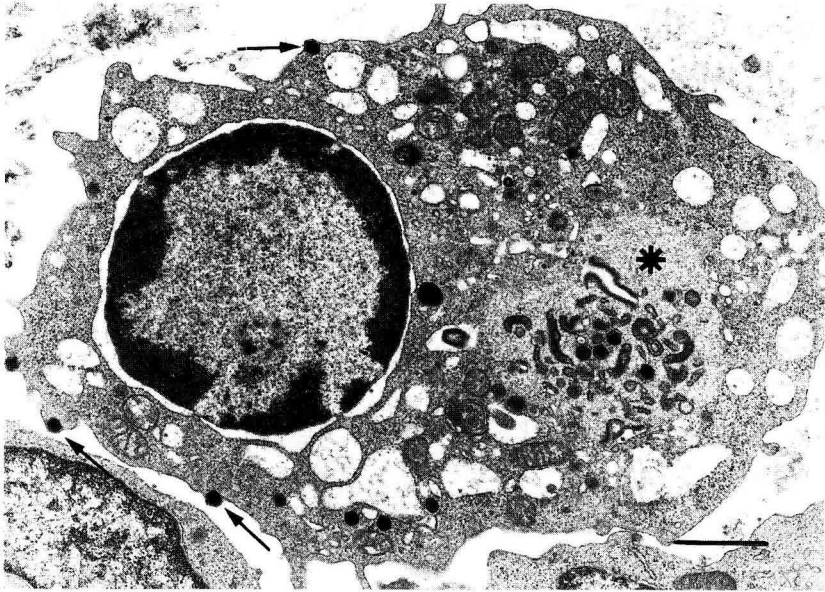
ble as rounded areas of organelle-free cytoplasm containing membranous structures and icosahedral virus particles (with or without electron-dense nucleoids), budding virus particles and marked cytopathic effect characterized by dilatation of the vacuolar system and peripheral margination of nuclear chromatin (fig 1). In some cases, hemadsorption was evident in the form of a ring of erythrocytes around cells containing virus replication (fig 2). Enveloped mature virions were also found within membrane indentations of some erythrocytes (fig 2).

From 5 days pi, roughly 10% of the macrophages with virus replication observed within the medulla of all lymph nodes were surrounded by a ring of lymphocytes (figs 3, 4). The membrane of infected macrophages showed areas of condensation (fig 3), and mature viral particles were observed in membrane evaginations corresponding to invaginations of the lymphocyte membrane (fig 4). Numerous viral particles were also found in the cytoplasm of macrophages adjacent to the membrane (fig 4).

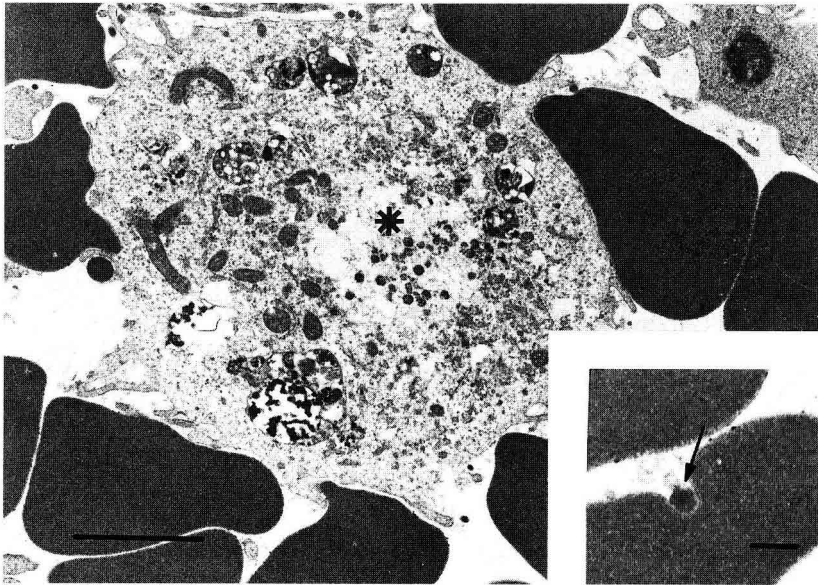
At 5 and 7 days pi, a number of lymphocytes in the medulla (roughly 5 and 10% respectively), contained intracytoplasmic mature virions (fig 5). In some cases, these cells also showed peripheral margination of nuclear chromatin (fig 5). However, none of the lymphocytes observed in the medulla, in the diffuse lymphoid tissue or in lymphoid follicles contained virus replication sites or immature / incomplete virions.

## DISCUSSION

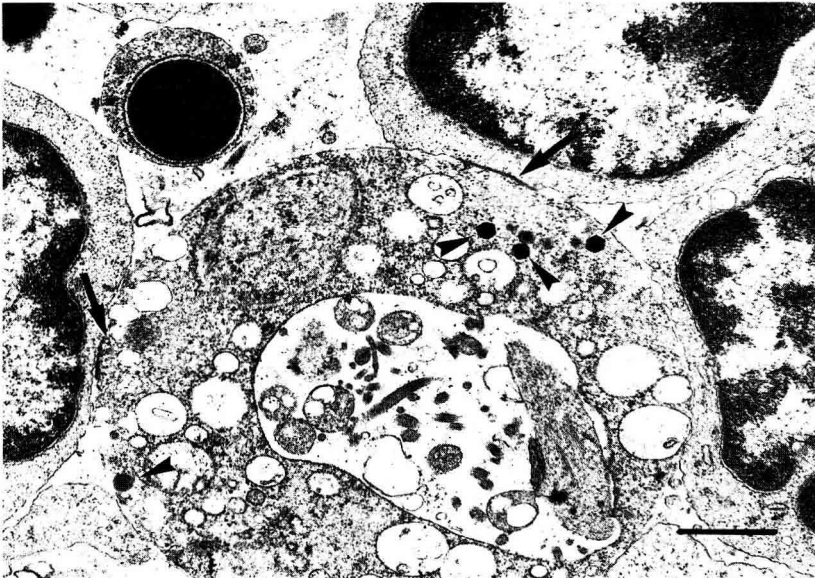
From 5 days after inoculation of the Malawi '83 isolate, a ring of lymphocytes was observed adhering to macrophages containing viral replication sites. Some lymphocytes contained intracytoplasmic mature virions, although no virus replication sites were visible in these cells.



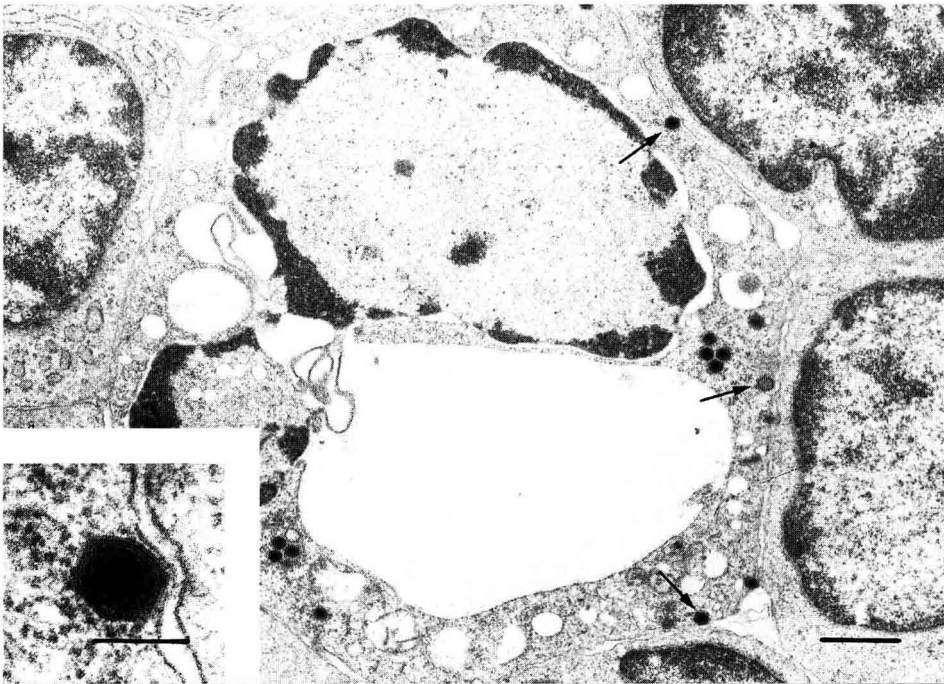
**Fig 1.** Mediastinal lymph node 5 days pi. Macrophage of the medullar tissue with a virus replication site (asterisk), budding virus (arrows) and marked cytopathic effect. Bar 1  $\mu\text{m}$ .



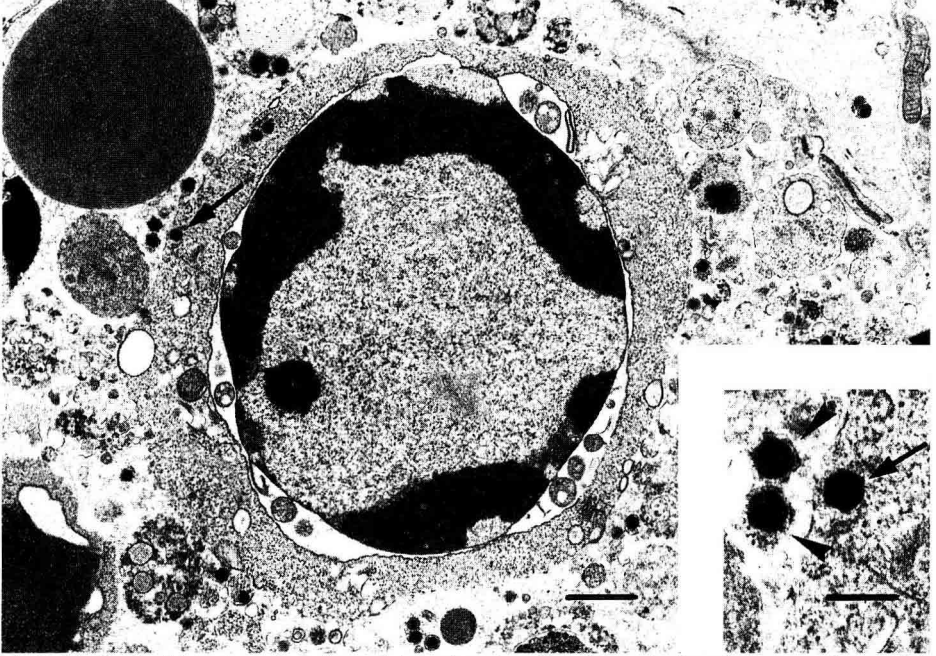
**Fig 2.** Renal lymph node 5 days pi. Macrophage with virus replication center (asterisk) and hemadsorption. Bar 6  $\mu\text{m}$ . Insert: viral particle (arrow) associated to the membrane indentations of an erythrocyte. Bar 0.5  $\mu\text{m}$ .



**Fig 3.** Retropharyngeal lymph node 7 days pi. Macrophage with numerous viral particles (arrowheads) surrounded by a ring of lymphocytes. Areas of condensation (arrows) can be observed in the cell membrane. Bar 1  $\mu$ m.



**Fig 4.** Mediastinal lymph node 5 days pi. Macrophage with virus replication surrounded by a ring of lymphocytes. Mature viral particles are present in membrane evaginations corresponding to invaginations of lymphocyte membrane (arrows). Bar 1  $\mu$ m. Insert: detail of the viral particles in the evaginations. Bar 0.5  $\mu$ m.



**Fig 5.** Mediastinal lymph node 7 days pi. Lymphocyte with a intracytoplasmic mature viral particle (arrow). Bar 1  $\mu$ m. Insert: detail of the intracytoplasmic virus (arrow) and extracytoplasmic viral particles (arrowheads). Bar 200 nm.

Most macrophages/monocytes containing ASF virus replication sites were observed in the medulla of lymph nodes. Immunohistochemical studies also indicate that most viral antigen is located in this area, while lymphoid tissue remains virtually free of viral antigens (Mínguez et al, 1988; Fernández et al, 1992; Pérez et al, 1994).

The formation of a lymphocyte ring around macrophages bearing virus replication sites could be the expression of cytotoxic T lymphocyte activity against the infected cells with ASF virus. Although this type of activity has been demonstrated *in vitro* against macrophages infected with ASF virus isolates of different virulence (Martins et al, 1993), effector T cytotoxic lymphocytes have been only observed in pigs infected with an ASF virus isolate with low virulence and no haemadsorbency (Martins et al, 1993); this activity has been consid-

ered as responsible for the recovery of swine infected with isolates of low virulence (Martins et al, 1993). This possibility was ruled out because of both the lack of necrotic macrophages and the proximity of mature virus particles to adherent lymphocytes. However, the macrophage expression of swine leukocyte antigens class 1 could be involved in the lymphocyte adhesion like it is in the cytotoxic T lymphocyte activity (Martins et al, 1993).

The adhesion of lymphocytes to macrophages containing virus replication was morphologically similar to the hemadsorption phenomenon observed both in this study and elsewhere (Sierra et al, 1991; Gómez-Villamandos et al, 1995d). Isolated adhesion of lymphocytes to cells containing virus replication has been reported in conjunction with hemadsorption in hepatic Kupffer cells (Gómez-Villamandos et al,

1995d), although there have been no reports of formation of a ring of lymphocytes around infected cells. As is the case with hemadsorption (Sierra et al, 1991; Gómez-Villamandos et al, 1995d), not all cells containing virus replication sites showed evidence of lymphocyte adhesion. The latter phenomenon may result from the expression of viral proteins or viral antigens in the membrane, as is the case with hemadsorption (Sierra et al, 1991), or infected cells may behave as antigen-presenting cells. Adhesion of lymphocytes to infected macrophages would not only allow transfer of viral particles from macrophages, but would also facilitate passage of the virus into lymphocytes; this hypothesis is borne out by the finding of viral particles in lymphocytes only in those areas where lymphocytes were observed adhering to macrophages, rather than in lymphoid tissue, where the phenomenon was not observed.

The existence of mature virions in lymphocyte cytoplasm may be responsible for the presence of ASF virus antigens observed mainly in the sinus stroma rather than lymphoid tissue following inoculation with virulent strains (Colgrove, 1966; Colgrove et al, 1969), and also for the association of ASF virus with this cell population (Wardley and Wilkinson, 1977a,b; Genovesi et al, 1988). The adhesion of lymphocytes however, differs from that reported for erythrocytes, from which virus replication is also absent, since in the latter case virions attach to the surface of the cell membrane, but do not penetrate the cytoplasm (Quintero et al, 1986; Sierra et al, 1991).

Although mature virions were observed within lymphocyte cytoplasm, the apparent absence of immature virions and virus replication sites in these cells suggests, as indeed do the results of *in vitro* studies reported by Casal et al (1984), that lymphocytes are resistant to ASF virus infection, and that there is no cytolitic infection of

these cells, of the sort proposed by Wardley and Wilkinson (1977b). Necrosis and falling numbers of lymphocytes may thus be due to other phenomena, such as lymphocyte apoptosis unrelated to virus replication (Gómez-Villamandos et al, 1995c). Moreover, the observation of mature virions but not of virus replication sites in these cells may account for the different results obtained in immunohistochemical studies.

The role of this association between ASF virus and lymphocytes may be similar to that described to erythrocytes (Quintero et al, 1986; Sierra et al, 1991), ie, passive transport contributing to dissemination of the virus. However, the contribution of lymphocytes to virus dissemination is likely to be much less significant than that of neutrophils, since although their involvement is similar, neutrophils provide active transport by harboring virus replication (Carrasco et al, 1996), so that each cell may thus transport a potentially larger number of viral particles.

This paper supports the view that lymphocytes are resistant to ASF virus infection, although intracytoplasmic virions may be observed as a result of adhesion of lymphocytes to infected macrophages.

## ACKNOWLEDGMENTS

We wish to thank A Jover for his support in this experiment, SM Williams and GH Hutchings for technical assistance in the laboratory, T Kinsella and L Fitzpatrick for assistance in the animal unit, and veterinary student B Pulido for her enthusiastic laboratory work. This work was supported by grants from CAICYT and Junta de Andalucía (Spain) and the Ministry of Agriculture, Fisheries and Food (UK).

## REFERENCES

- Carrasco L, Gómez-Villamandos JC, Bautista MJ, et al (1996) *In vivo* replication of the African swine fever virus (Malawi'83) in neutrophils. *Vet Res* 27, 55-62



- Casal I, Enjuanes L, Viñuela E (1984) Porcine leukocyte cellular subsets sensitive to African swine fever virus in vitro. *J Virol* 52, 37-46
- Colgrove GS (1966) Immunofluorescence and inclusion bodies in circulating leukocytes of pigs infected with African swine fever virus. *Bull Epizoot Dis Afr* 16, 341-343
- Colgrove GS, Haelterman EO, Coggins L (1969) Pathogenesis of African swine fever in young pigs. *Am J Vet Res* 30, 1343-1359
- Fernández A, Pérez J, Carrasco L, Bautista MJ, Sánchez-Vizcaino JM, Sierra MA (1992) Distribution of ASFV antigen in pig tissues experimentally infected with two different Spanish virus isolates. *J Vet Med B* 39, 393-402
- Genovesi EV, Knudsen RC, Whyard TC, Mebus CA (1988) Moderately virulent African swine fever virus infection: blood cell changes and infective virus distribution among blood components. *Am J Vet Res* 49, 338-344
- Gómez-Villamandos JC, Hervás J, Méndez A et al (1995a) Ultrastructural study of the renal tubular system in acute experimental African swine fever: virus replication in glomerular mesangial cells and in the collecting ducts. *Arch Virol* 140, 581-589
- Gómez-Villamandos JC, Hervás J, Méndez A et al (1995b) Pathological changes in the renal interstitial capillaries of pigs inoculated with two different strains of African swine fever virus. *J Comp Pathol* 112, 283-289
- Gómez-Villamandos JC, Hervás J, Méndez A et al (1995c) Experimental African swine fever: apoptosis of lymphocytes and virus replication in other cells. *J Gen Virol* 76, 2399-2405
- Gómez-Villamandos JC, Hervás J, Méndez A et al (1995d) A pathological study of the perisplenic unit of the liver in acute ASF. *Res Vet Sci* 59, 146-151
- Harespane JM (1984) African swine fever in Malawi. *Trop Anim Health Prod* 16, 123-125
- Hess WR (1971) African Swine Fever. In: *Virology Monograph*. Springer-Verlag, New York, 1-33
- Madeley CR (1990) The morphology and structure of virus. In: *Principles of Bacteriology, Virology and Immunology* (LH Collier, MC Timbory, eds), Butter & Tauner, London, 11-49
- Martins CLV, Lawman MJP, Scholl T, Mebus CA, Lunney JK (1993) African swine fever virus specific porcine cytotoxic T cell activity. *Arch Virol* 129, 211-225
- Mebus CA (1987) Pathobiology and pathogenesis. In: *African Swine Fever* (Y Becker, ed), Martinus Nijhoff Publishing, Boston, 21-29
- Mebus CA (1988) African swine fever. *Adv Virus Res* 35, 251-269
- Minguez I, Rueda A, Dominguez J, Sánchez-Vizcaino JM (1988) Double labeling immunohistological study of African swine fever virus-infected spleen and lymph nodes. *Vet Pathol* 25, 193-198
- Pan IC (1987) Spontaneously susceptible cells and cell culture methodologies for African swine fever virus. In: *African Swine Fever* (Y Becker, ed), Martinus Nijhoff Publishing, Boston, 81-126
- Pérez J, Rodríguez F, Fernández A, Martín de las Mulas J, Gómez-Villamandos JC, Sierra MA (1994) Detection of African swine fever virus protein VP73 in tissues of experimentally and naturally infected pigs. *J Vet Diagn Invest* 6, 360-365
- Quintero JC, Wesley RD, Whyard TC, Gregg D, Mebus CA (1986) In vitro and in vivo association of African swine fever with swine erythrocytes. *Am J Vet Res* 47, 1125-1131
- Sánchez-Vizcaino JM, Slauson DO, Ruiz-Gonzalvo, Valero F (1981) Lymphocyte function and cell-mediated immunity in pigs with experimental induced African swine fever. *Am J Vet Res* 42, 1335-1341
- Sierra MA, Bernabé A, Mozos E, Méndez A, Jover A (1987) Ultrastructure of the liver in pigs with experimental African swine fever. *Vet Pathol* 24, 460-462
- Sierra MA, Quezada M, Fernández A, et al (1989) Experimental African swine fever: evidences of the virus in interstitial tissues of the kidney. *Vet Pathol* 26, 173-176
- Sierra MA, Gómez-Villamandos JC, Carrasco L, Fernández A, Mozos E, Jover A (1991) In vivo study of hemadsorption in African swine fever virus infected cells. *Vet Pathol* 28, 178-181
- Wardley RC, Wilkinson PJ (1977a) The association of African swine fever virus with blood components of infected pigs. *Arch Virol* 55, 327-334.
- Wardley RC, Wilkinson PJ (1977b) African swine fever replication in porcine lymphocytes. *J Gen Virol* 37, 425-427