



HAL
open science

Current status of the diagnosis and control of African horse sickness

M Rodriguez, H Hooghuis, M Castaño

► **To cite this version:**

M Rodriguez, H Hooghuis, M Castaño. Current status of the diagnosis and control of African horse sickness. *Veterinary Research*, 1993, 24 (2), pp.189-197. <hal-00902117>

HAL Id: hal-00902117

<https://hal.science/hal-00902117v1>

Submitted on 11 May 2020

HAL is a multi-disciplinary open access archive for the deposit and dissemination of scientific research documents, whether they are published or not. The documents may come from teaching and research institutions in France or abroad, or from public or private research centers.

L'archive ouverte pluridisciplinaire **HAL**, est destinée au dépôt et à la diffusion de documents scientifiques de niveau recherche, publiés ou non, émanant des établissements d'enseignement et de recherche français ou étrangers, des laboratoires publics ou privés.



HAL Authorization

Current status of the diagnosis and control of African horse sickness

M Rodriguez ^{1*}, H Hooghuis ², M Castaño ¹

¹ Departamento de Patología Animal II, Facultad de Veterinaria, UCM, Madrid;

² Laboratorio de Sanidad y Producción Animal, Ministerio de Agricultura,
Pesca y Alimentación, Algete, Madrid, Spain

(Received 12 May 1992; accepted 20 August 1992)

Summary — African horse sickness (AHS) is an infectious, non-contagious, highly fatal viral disease of Equidae, transmitted by arthropod vectors of the genus *Culicoides*, and endemic in Africa south and east of the Sahara. The disease is caused by a virus of the Reoviridae family, genus *Orbivirus*, and 9 serotypes have been recognized. Recent outbreaks of AHS in the Iberian peninsula and Northern Africa emphasize the need for accurate diagnosis and rapid implementation of control measures. In this paper, the epizootiological factors, clinical signs and necropsy findings of AHS are discussed, and an updated review of diagnostic laboratory methods together with a description of the main control measures is given.

African horse sickness / diagnosis / control

Résumé — *Situation actuelle du diagnostic et du contrôle de la peste équine.* La peste équine est une maladie virale des équidés non contagieuse conduisant à la mort dans la plupart des cas. Elle est transmise par des arthropodes vecteurs du genre *Culicoides* et se trouve à l'état endémique en Afrique au Sud et à l'Est du Sahara. La maladie est causée par un virus de la famille des Reoviridae du genre *Orbivirus* et 9 sérotypes ont été identifiés. De récents foyers de peste équine apparus dans la péninsule ibérique et en Afrique du Nord ont fait apparaître le besoin d'un diagnostic précis et la mise en œuvre rapide de mesures de contrôle. Dans cet article, les facteurs épizootologiques, les signes cliniques, les résultats d'autopsies sont discutés et une revue des méthodes actuelles de diagnostic de laboratoire ainsi qu'une description des principales mesures de contrôle sont présentées.

peste équine / diagnostic / contrôle

* Correspondence and reprints

INTRODUCTION

African horse sickness (AHS) is a non-contagious highly fatal acute or sub-acute infectious disease of Equidae characterized by clinical signs due to respiratory and circulatory impairment. AHS is transmitted by arthropod vectors of the genus *Culicoides* and has a seasonal incidence (Chalmers, 1968). The disease is caused by a viscerotropic double-stranded RNA virus of the Reoviridae family, genus *Orbivirus*. Nine antigenically different serotypes have been recognized, which nevertheless present common group-specific proteins (Buxton and Fraser, 1977; Mohanty and Dutta, 1981).

AHS is enzootic throughout Africa, south and east of the Sahara. It has only occurred outside Africa occasionally, but recently the disease has been diagnosed in Spain (1987–1990), Portugal (1989) and Morocco (1989–1991) (Rodriguez *et al*, 1992a).

Due to the major sanitary and economic repercussions caused by the occurrence of AHS in non-enzootic countries, quick diagnosis and enforcement of control measures is essential.

DIAGNOSIS OF AHS

The efficacy of the emergency control measures applied in case of an outbreak of AHS in a non-enzootic area is increased with their rapid implementation. A delay even of a presumptive clinical diagnosis can result in the spread of the disease at large distances. According to the experience gained in outbreak situations, when early recognition of clinical cases of AHS occurred, the spread of the disease was notably curbed in comparison with cases in which diagnosis was delayed for several days.

In an outbreak situation, the clinical and epizootiological data, together with the pathology findings, make a tentative diagnosis possible, which by itself can justify the application of urgent control measures, even though further laboratory confirmation is necessary.

During the 1987 AHS outbreak in the Madrid area, only time-consuming virus isolation and identification methods were available for laboratory diagnosis. Due to this, the clinical, epizootiological and pathological findings were crucial for the control of the disease. Although a rapid laboratory diagnostic method is currently available, namely an indirect sandwich ELISA which detects AHS virus (AHSV) in field samples (Hamblin *et al*, 1991), the role of the equine practitioner should be considered essential for the early recognition of the disease.

Epizootiological data relevant for AHS diagnosis

The presence of the arthropod vectors has a determinant effect on the appearance and spread of AHS, and the mortality rate relates with the vector population present. AHS has a seasonal incidence, preferably occurring towards the end of the summer, in warm, low-lying and humid areas in which the breeding conditions of the midges are optimal (Dardiri, 1986). In those seasons during which the vector activity is lower due to unfavourable climatic conditions, in case the disease appears it does so only sporadically.

AHS occurs frequently among susceptible Equidae held near humid areas, such as rivers or marshes, where the number of adequate arthropod vector breeding sites is high. The spread of AHS usually takes place following river basins, as occurred during the 1987 AHS outbreak near Ma-

drid, when the disease was found throughout the Alberche and Perales river basins, affecting a stretch of land 100 km long and 50 km wide (Rodriguez *et al*, 1989). The simultaneous occurrence of cases of AHS at considerable distances can usually be traced to the movement of infected animals.

AHS only affects members of the Equidae family, with the highest mortality rate occurring in horses. Mules and donkeys are less susceptible (Fenner *et al*, 1987). During the first recent outbreak in Spain in the Madrid area, 29 horses out of 30 died in the original holding, whilst all the donkeys, namely 7, survived the disease (Rodriguez *et al*, 1987). AHS may appear in one or in a small number of animals of an equine holding simultaneously. After the first deaths, the disease is not detected again until approximately 2 wk afterwards, when a larger number of animals may show clinical signs and the disease may be found in other nearby holdings. This apparent interruption may be due to the time lapse necessary for the following sequence of chained events: feeding of an arthropod vector on a viraemic Equidae, viral replication inside the vector, bite of a susceptible host animal by the infected vector and incubation period before appearance of the first clinical signs in the infected animal. If no control measures are taken, the disease continues to spread in a similar way, depending on the prevalence of the vector population and the number of susceptible Equidae present in the area.

The vector midges of the genus *Culicoides* are exophilic and tend to bite at night, mostly during the evening and before dawn (Erasmus, personal communication, 1988). These facts must be taken into account for the control of the disease, as could be seen in those holdings in which the horses were stabled overnight during the 1987 Madrid AHS outbreak, where mortality rates were found to be much low-

er than in those in which the animals were not stabled (Rodriguez *et al*, 1987).

Clinical diagnosis

To establish a presumptive clinical diagnosis of AHS, the different forms of the disease must be taken into account. The clinical picture depends on the pathogenicity of the viral serotype involved and the individual resistance of the infected animals (Chalmers, 1968). Three main forms of the disease have been described: the acute or pulmonary form, the sub-acute or cardiac form and the mixed form. A febrile form is also recognized, known as "horse sickness fever", which is only found in enzootic areas (French and Geering, 1978). In most outbreaks in non-enzootic areas, mixed clinical signs are found, with prevalence of pulmonary or cardiac impairment in a varying degree.

The pulmonary form is characterized by a sudden onset, with high temperature and signs associated with acute pulmonary edema. The main clinical signs are dyspnea, paroxysms of coughing and discharge of frothy fluid from the nostrils. Edema of the head and neck can be seen, with bulging of the supra-orbital fossae, but less frequently than in the cardiac form. The pulmonary form has a short course with a high mortality rate, with terminal hypothermia and death occurring in 24–48 h after the onset of the first clinical signs. It was the clinical form found most frequently in the 1987 Madrid AHS outbreak (Rodriguez *et al*, 1989).

The cardiac form of AHS prevailed during the 1988 outbreak in Andalusia, although mixed clinical signs were present in many cases also during 1989 and 1990 (Rodriguez *et al*, 1992a). The incubation period and the course of this form of the disease is longer than for the acute pulmo-

nary form, and the mortality rate is lower (Dardiri, 1984). The onset of the disease is characterized by fever and the appearance of generalized signs of edema. In the early stages, a prominent bulging of the supra-orbital fossae is observed, together with a progressively increasing edema of the eyelids, lips, cervical and sternal regions and ventral abdomen. At this stage, large accumulations of fluid also occur in the thorax, abdomen and pericardial sac, producing a decompensated congestive cardiac failure (Rodriguez *et al*, 1992a). The longer course of the sub-acute forms allows for the stated edematous swellings and accumulations of fluid, although no edema of the limbs is found. Affected animals may show clinical signs during 5–7 d before death, which may occur in some cases even 15 d after the onset of the disease.

Necropsy and histopathology findings relevant for diagnosis

As stated earlier, mixed forms of the disease are the ones most frequently found, with cardiac or pulmonary functional impairment predominating in a varying degree depending on the virulence of the AHS strain involved and the resistance of the infected host animal (Chalmers, 1968).

On external inspection, the main findings were edema of the head, specifically of the supra-orbital fossae, lips and tongue, together with edemas of the neck and sternal region. Often a frothy whitish or reddish fluid could be seen oozing from the nostrils, a reflection of the pulmonary edema (Rodriguez *et al*, 1992b).

Upon opening the linea alba, a marked yellowish and gelatinous edema of the subcutaneous connective tissue was found, which could be 6–7 cm thick, together with interfascial edema of the ab-

dominal muscles. Ascites was frequently seen, with accumulation of large quantities of fluid. Focal subcapsular splenic petechiae were present, without variation of the size of the spleen. Edema of the intestinal walls was observed, with subserous petechiae appearing mostly in the small bowel. A constant finding was a marked submucosal congestion of the fundus of the stomach, accompanied in some cases by congestive, hemorrhagic and hypertrophic Peyer's patches. The mesenteric lymph nodes were reddish and moist on opening, and slightly hypertrophic. In most cases, both the liver and the kidneys presented a variable degree of congestion, but showed no other lesions. No other organs of the abdominal or pelvic cavities displayed any notable additional gross lesions.

In the mixed form of AHS hydrothorax is also frequently present, with the appearance of 500–1 000 ml of a clear, yellowish fluid in the pleural cavity. The lungs are one of the main target organs, also in the acute pulmonary form. They appear grossly distended, with marked interstitial and alveolar edema. When the lungs are cut, a clear whitish or reddish frothy fluid oozes out. The trachea contains a large amount of a whitish or pinkish frothy fluid, and subserous and submucous edema is found. Occasionally petechiae can be observed coinciding with the edematous areas, but showing a focal distribution.

The heart is the target organ presenting the most characteristic and constant lesions. It shows an increase of size, and when the pericardial sac is opened, hydropericardium is a constant finding. The amount of accumulated yellowish fluid can reach a volume of 500–2 000 ml. The mediastinal lymph nodes are hypertrophic, reddish and moist on opening.

Subcutaneous and interfascial edema of the neck is also a common necropsy finding.

The remaining organs of the thoracic cavity and the neck did not present any other notable gross lesions.

The histopathological changes observed confirm the macroscopic observations, with all the organs and tissues studied showing edema, congestion and occasionally microhemorrhages. The lymph nodes, Peyer's patches and splenic tissue are reactive, with a large number of blastic cells undergoing mitosis, indicating the development of a positive immune response during the course of the disease.

The lungs show congestion and pulmonary, alveolar and interstitial edema (fig 1). The bronchial and bronchiolar epithelial cells suffer depolarization, and appear mixed with lymphocytes, plasmacytes and histiocytes, although no intra-luminal cellular desquamation can be observed at this level, nor in the alveoli.

The blood vessels of all the organs and tissues studied contained a large or very

large number of cellular elements of the white series, mostly immature forms. The endothelial cells, mainly those located in the paracortical blood vessels of lymph nodes, which under normal circumstances show a considerable size, were very large and had undergone vacuolization.

In conclusion, the histopathology findings demonstrate the presence of an acute pathologic process, accompanied by a limited inflammatory response.

Laboratory diagnosis

The clinical signs, the necropsy findings and the epizootic nature of AHS allow an early tentative diagnosis of the disease, although the symptoms and lesions are not pathognomonic (Dardiri, 1984, 1986). Nevertheless, laboratory confirmation remains necessary not only to identify the serotype of African horse sickness virus (AHSV) re-

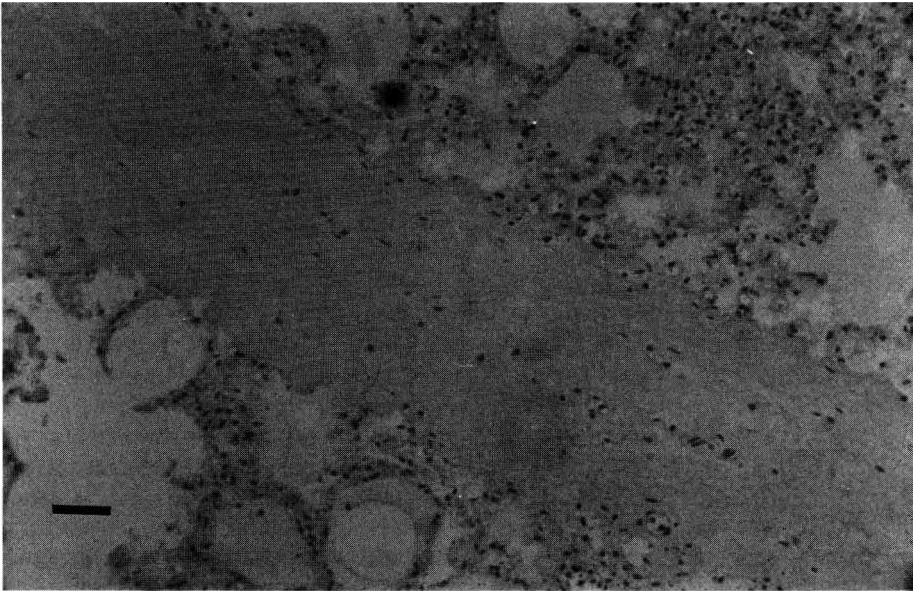


Fig 1. Alveolar and interstitial edema. Haematoxylin-eosin 25 x; bar = 100 μ m.

sponsible for the outbreak, but also to rule out diseases such as equine viral arteritis, equine infectious anemia, anthrax, the ingestion of poisonous plants such as *Crotalaria* spp, *Purpura hemorrhagica* and babesiosis, among others (Lubroth, 1988).

The laboratory confirmation of a presumptive outbreak of AHS must not be based on serological results, because it is probable that infected animals will die before showing a measurable immune response, which appears at ≈ 10 –14 d post-infection (Erasmus, personal communication, 1988). Due to this, the diagnosis of an outbreak of the disease must be based on laboratory methods which detect the virus in blood samples obtained from viraemic Equidae or in spleen samples taken from dead or euthanatized animals.

The virus isolation and identification methods most frequently used are inoculation in suckling mouse-brain to observe possible nervous clinical signs, and inoculation in cell cultures, in order to assess cytopathic effect (CPE). Several passages may be necessary before sufficient replication occurs to produce visible CPE (Anonymous, 1991). Other biological host systems may be used such as inoculation in embryonated chicken eggs or even inoculation of suspected field samples in susceptible horses (French and Geering, 1978).

After isolation, the virus involved must be identified. This can be achieved using group-specific serological assays such as the complement fixation test (CFT), considering the isolated virus as unknown antigen, or immunofluorescence, or using type-specific assays such as the virus-neutralization test (VNT), including mono-specific antisera for the 9 AHSV serotypes.

To enable a quick identification of the viral serotype involved in an outbreak, a blind VNT can be carried out, using the

supernatant of an initial passage in cell culture in which CPE has not yet been observed as unknown antigen. This procedure was applied in the Spanish reference laboratory (Laboratorio de Sanidad y Producción Animal, Ministerio de Agricultura, Pesca y Alimentación, Algete, Madrid) for identification of the AHSV serotype during the recent Spanish outbreaks, shortening the time necessary for serotyping to 8 d from the arrival of the samples to the laboratory. Recently, a very useful highly sensitive group-specific indirect sandwich ELISA has been developed for the rapid detection of AHSV directly in field samples (Hamblin *et al*, 1991). This assay is currently available, and permits to confirm the appearance of the disease in < 4 h after receipt of the sample. Nevertheless, in case a suspected outbreak of AHS takes place outside enzootic areas, the results obtained using this test should be confirmed by means of virus isolation and identification methods, which are also necessary to establish the causal serotype.

Research on similar ELISA tests using type-specific monoclonal antibodies is being carried out, which will make the immediate identification of the AHSV serotype possible, without using time-consuming procedures.

It can be expected that in the future quick and reliable AHSV detection methods will become available, based on recombinant DNA technology or on the polymerase chain reaction.

In case of AHS, since most horses die before a measurable immune response takes place, the serological assays for the detection of specific antibodies against the virus has limited use for an initial laboratory diagnosis. A systematic search for specific antibodies against the virus could only be significant, from a diagnostic point of view, in non-enzootic regions, in those species of Equidae less susceptible to the

disease, namely mules and donkeys. In enzootic regions, the use of paired serum samples would be necessary. Nevertheless, in general terms, the testing for specific antibodies against AHSV is limited to trade purposes, and consequently is applied to evaluate the immune status of individual animals.

Several serological tests are used for the detection of AHSV antibodies, including both group-specific assays such a CFT and agar gel immuno-diffusion, or type-specific ones such as VNT or hemagglutination inhibition (Anonymous, 1991).

The CFT is the assay recommended by the Office International des Epizooties (OIE) for international trade purposes, and is also recognized as such in the Directive 90/426/EEC which lays down the sanitary conditions governing intra-Community trade and importation from third countries of Equidae. The VNT is type specific and, accordingly, if the AHSV virus serotype involved is unknown, it must include the 9 known viral serotypes plus the corresponding positive type-specific antisera. This assay is highly sensitive and specific, but results can only be read after 4 or 5 d. A competitive ELISA is currently available for the rapid detection of specific antibodies against AHSV (Hamblin *et al*, 1990). This assay shows good sensitivity and specificity, and in contrast to CFT and VNT, is suitable for screening large numbers of sera.

Vaccination of susceptible horses with an attenuated AHS vaccine has been shown to induce an early rise of CF titres. VN and ELISA titres rises later, but have a longer duration (Hooghuis *et al*, 1992). Similar results were also found after experimental infection of susceptible horses (Williams, 1987). Accordingly, CFT would be the most adequate assay for the serological testing of Equidae in quarantine, since it would permit the earliest detection of the initial stages of an infection.

CONTROL AND ERADICATION MEASURES

The recent outbreaks of AHS in the Iberian peninsula and in north-west Africa is a reminder that exotic diseases of animals represent a real threat and that efficient diagnostic and control strategies must be foreseen for rapid eradication.

In those areas in which the disease is enzootic, control measures mainly include overnight stabling of animals at risk and systematic immunization of the equine population with homologous vaccine, to limit the extent of the disease.

In non-enzootic regions, in order to effectively stop the spread of AHS, a wide emergency buffer-zone surrounding the outbreak area should be established, in which the following sanitary measures must be implemented:

- slaughter or immediate isolation in vector-proof stables of infected animals, which represent a source of virulent AHSV. Early recognition and diagnosis of the disease has a major role in the general efficacy of this measure, and regular sanitary surveillance of the animals at risk is also necessary;
- vaccination of all susceptible Equidae in the infected area, and in an adequate surrounding protection zone, with permanent identification of all vaccinated animals, preferably by means of branding;
- integrated arthropod vector control, including overnight stabling of Equidae in the areas at risk, elimination of possible *Culicoides* breedings sites, use of insecticides in strategic points of the holdings, topical administration of insect repellents, etc. Insecticides of the pyrethrin group have showed adequate efficacy against AHSV vectors (Erasmus, 1989, personal communication).

Equidae which survive the disease probably present life-long immunity against

the serotype of AHSV involved (Erasmus, 1989, personal communication), but remain susceptible to heterologous AHSV serotypes. The foals from immune mares present a passive immunity which offers initial protection against the disease, but which may interfere with vaccination (Dardiri, 1984).

Monovalent vaccine including the homologous serotype which caused the outbreak is the vaccine of choice, but it may be necessary to use polyvalent vaccine until typing is completed (Erasmus, 1988). Live attenuated AHSV vaccines are currently available (Veterinary Research Institute, Onderstepoort, South Africa), using neurotropic strains modified by serial intracerebral passages in mice, and further passaged in cell line cultures. These poly- or monovalent vaccines are obtained in tissue culture. Vaccination with homologous monovalent vaccine produces a practically life-long immunity (Anonymous, 1991). Recently, an inactivated monovalent vaccine containing type 4 AHSV has been tested with favourable results (Equipest, Rhône Mérieux, Lyon, France).

CONCLUSION

The major sanitary and economic repercussions caused by an outbreak of AHS outside enzootic areas makes a rapid diagnosis and implementation of control measures essential.

The clinical signs, pathological findings and epizootiological data permit a presumptive diagnosis of the disease, stressing the crucial role of the equine practitioner. Nevertheless, laboratory confirmation is needed for differential diagnosis and to identify the viral serotype involved in the outbreak. Currently, a sandwich ELISA is available for the quick detection of AHS virus directly in field samples (Hamblin *et al*,

1991), although in case of an initial outbreak in previously non-infected areas virus isolation and identification methods should be used for confirmation.

Effective control measures must be quickly implemented during the early stages of an AHS in a non-enzootic area to permit eradication. Together with the immediate ban on movements or trade of Equidae and on the celebration of equine events, fairs or markets, the main control measures are vaccination of the susceptible animals, preferably with homologous monovalent vaccine, integrated arthropod vector control and slaughter or isolation in vector-proof facilities of Equidae showing clinical signs.

Only the comprehension of the basic facts referring to the epizootiology, diagnosis and control of the disease which have been discussed renders the control and subsequent eradication of AHS possible.

REFERENCES

- Anonymous (1991) African horse sickness. In: *Manual of Recommended Diagnostic Techniques and Requirements for Biological Products*. Office International des Epizooties, Paris, divider 3, vol 3
- Buxton A, Fraser G (1977) *Animal Microbiology*. Blackwell Scientific Publ Ltd, Oxford, vol 2, 632-635
- Chalmers AW (1968) African horse sickness. *Equine Vet J* 1, 1-4
- Dardiri AH (1984) African horse sickness. In: *Foreign Animal Diseases. Reference Manual*. USDA, APHIS, NVSL, Ames, IA, vol 1, 10-19
- Dardiri AH (1986) Peste equina Africana. In: *Enfermedades Exóticas de los Animales. Su Prevención, Diagnóstico y Control*. Comité de enfermedades exóticas de la Asociación de Sanidad Animal de los Estados Unidos; Comisión Mexico-Americana para la prevención de la fiebre aftosa. Mexico DF, 302-311
- Erasmus BJ (1988) *Epidemiology of African Horse Sickness*. Rep Meeting African horse

- Sickness, General Subdirectorato de Animal Health, Ministry of Agriculture, Fisheries and Food, Jan 13-14, Madrid
- Fenner F, Bachmann PA, Gibbs EPJ, Murphy FA, Studdert MJ, White DO (1987) *Veterinary Virology*. Academic Press, Orlando, FL, 587-590
- French A, Geering WA (1978) *Exotic Diseases of Animals. A Manual for Diagnosis*. Australian Govt Publ Serv, Canberra, 41-45
- Hamblin C, Graham SP, Anderson EC, Crowther JR (1990) A competitive ELISA for the detection of group-specific antibodies to African horse sickness virus. *Epidemiol Infect* 104, 303-312
- Hamblin C, Mertens PPC, Mellor PS, Burroughs JN, Crowther JR (1991) A serogroup specific enzyme-linked immunosorbent assay for the detection and identification of African horse sickness viruses. *J Virol Methods* 31, 285-292
- Hooghuis H, Rubio C, Cubillo MA, Anadon E (1992) Antibody titers in horses after vaccination with African horse sickness virus serotype 4. In: *Proc 2nd Inter Symp Bluetongue, African Horse Sickness and Related Orbiviruses*. CRC Press Inc, Boca Raton, FL
- Lubroth J (1988) African horse sickness and the epizootic in Spain 1987. *Equine Pract* 10, 26-33
- Mohanty SB, Dutta SK (1981) *Veterinary Virology*. Lea and Febiger, Philadelphia, PA, 172-174
- Rodríguez M, Castaño M, Escolar E, Flores JM, Toni P, Gonzalez M, Jimenez F, Gonzalez JL, Montoya A (1987) Peste equina africana: descripción del brote en España, 1987. *Med Vet* 4, 537-557
- Rodríguez M, Castaño M, García I (1989) Peste equina africana en España. Focos de 1987, 1988 y 1989. In: *Proc III Jornadas Técnicas sobre el Caballo*. Expoaviga 89, 25-30
- Rodríguez M, Hooghuis H, Castaño M (1992a) African horse sickness in Spain. *Vet Microbiol* (in press)
- Rodríguez M, Ladero JL, Castaño M, Hooghuis H (1992b) African horse sickness in Spain: epizootiological and regulatory considerations. *J Equine Vet Sci* (in press)
- Williams R (1987) A single dilution enzyme-linked immunosorbent assay for the quantitative detection of antibodies to African horse sickness virus. *Onderstepoort J Vet Res* 54, 67-70