



HAL
open science

NATURALLY-OCCURRING TYZZER'S DISEASE (BACILLUS PILIFORMIS INFECTION) IN COMMERCIAL RABBITS: A CLINICAL AND PATHOLOGICAL STUDY

J.E. Peeters, G. Charlier, P. Halen, Rita Geeroms, Ria Raeymaekers

► **To cite this version:**

J.E. Peeters, G. Charlier, P. Halen, Rita Geeroms, Ria Raeymaekers. NATURALLY-OCCURRING TYZZER'S DISEASE (BACILLUS PILIFORMIS INFECTION) IN COMMERCIAL RABBITS: A CLINICAL AND PATHOLOGICAL STUDY. *Annales de Recherches Vétérinaires*, 1985, 16 (1), pp.69-79. hal-00901552

HAL Id: hal-00901552

<https://hal.science/hal-00901552v1>

Submitted on 11 May 2020

HAL is a multi-disciplinary open access archive for the deposit and dissemination of scientific research documents, whether they are published or not. The documents may come from teaching and research institutions in France or abroad, or from public or private research centers.

L'archive ouverte pluridisciplinaire **HAL**, est destinée au dépôt et à la diffusion de documents scientifiques de niveau recherche, publiés ou non, émanant des établissements d'enseignement et de recherche français ou étrangers, des laboratoires publics ou privés.

NATURALLY-OCCURRING TYZZER'S DISEASE (*BACILLUS PILIFORMIS* INFECTION) IN COMMERCIAL RABBITS: A CLINICAL AND PATHOLOGICAL STUDY

J.E. PEETERS, G. CHARLIER, P. HALEN, Rita GEEROMS and Ria RAEYMAEKERS

National Institute of Veterinary Research, Groeselenberg 99, 1180 Brussels, Belgium

Résumé

LA MALADIE DE TYZZER (*BACILLUS PILIFORMIS*) DANS L'ÉLEVAGE CUNICOLE INTENSIF: UNE ÉTUDE CLINIQUE ET PATHOLOGIQUE. — La maladie de Tyzzer a été diagnostiquée dans neuf différents élevages intensifs de lapins. Au stade aigu de la maladie une diarrhée aqueuse abondante a été trouvée chez des lapereaux récemment sevrés. Pendant les trois premières semaines de la maladie, la mortalité était de 14,2 à 41,2 %. Les lapereaux survivants ont montré une évolution chronique avec dépression, anorexie, perte de poids et parfois cachexie prononcée. Les reproducteurs étaient atteints dans une moindre mesure. A l'autopsie les lésions les plus frappantes consistaient en nécrose hépatique multifocale, nécrose focale du myocarde, foyers nécrotiques dans la muqueuse de l'iléon, du caecum, du colon et de l'œdème caecal prononcé. Dans les coupes histologiques du foie des faisceaux de bâtonnets légèrement gram-négatifs et Giemsa-, PAS- et argent-positifs ont été trouvés dans des hépatocytes apparemment normaux au bord des foyers nécrotiques. Ils ont également été trouvés dans les myocytes autour des foyers nécrotiques du cœur et dans les entérocytes et les cellules musculaires lisses (*muscularis mucosae*) de la muqueuse intestinale. En microscopie électronique à transmission ces organismes avaient une ultrastructure similaire à *Bacillus piliformis*. La plupart des antibiotiques utilisés étaient inefficaces. Seule l'oxytetracycline se révélait active.

Tyzzer's disease was first described as an infectious disease causing overwhelming diarrhoea and high mortality in Japanese waltzing mice by Tyzzer (1917). Later the disease was found to occur enzootically and epizootically in numerous colonies of common laboratory mice all over the world (Gowen and Schott, 1933; Rights *et al.*, 1947; Kaneko *et al.*, 1960; Peace and Soave, 1969; Fries, 1977a). In 1965 the disease was also detected in another species, the rabbit (Allen *et al.*, 1965). Since then the range of susceptible animals has been extended to the guinea pig (Sparrow and Naylor, 1978), hamster (Takasaki *et al.*, 1974), mongolian gerbil (White and Waldron, 1969), monkey (Niven, 1968), rat (Jonas *et al.*,

1970), cat (Kubokawa *et al.*, 1973), dog (Qureshi *et al.*, 1976), horse (Pulley and Shively, 1974), cottontail rabbit (Ganaway *et al.*, 1976), coyote (Marler and Cook, 1976), fox (Stanley *et al.*, 1978) and muskrat (Karstad *et al.*, 1971).

Most cases of Tyzzer's disease in rabbits described in literature occurred in laboratory units (Allen *et al.*, 1965; Cutlip *et al.*, 1971; Ganaway *et al.*, 1971a; Savage and Sheldon, 1973; Zentralinstitut, 1975; Fries, 1977a) or in wild cottontail rabbits (Ganaway *et al.*, 1976). Only a few reports deal with outbreaks in commercial rabbitries (Van Kruiningen and Blodgett, 1971; Prescott, 1977; Ononiwu and Julian, 1978; Vetesi, 1982). The purpose of this paper is to describe outbreaks of

Tyzzler's disease in nine unrelated commercial rabbitries and the related clinical signs, pathology and electron microscopy.

Materials and Methods

A total of 57 live diarrhoeic rabbits were collected in nine commercial rabbitries with between 30 and 400 does. In the rabbitries New Zealand or Dendermonde White rabbits were housed in wire cages, most of which had droppings pits underneath, and were fed *ad libitum* with a commercial pelleted ration containing 66 ppm robenidine as anticoccidial drug. Rabbits were weaned between four and five weeks of age.

Within 20 minutes after the killing of the animals, segments of duodenum, midjejunum, ileum, caecum, colon ascendens, mesenteric lymph nodes, heart, liver and kidney were fixed in 10% (v/v) formaline in phosphate buffered saline for paraffin sections. They were embedded in paraplast-plus according to standard techniques and cut at 5 μ m. Sections were stained with haematoxylin and eosin (HE). Sections showing histopathological lesions were also stained with Warthin-Starry silver stain, Giemsa and Gram stain according to Lee and Luna (1960) and with periodic acid-Schiff (PAS) reagents according to Culling (1974). Some formaline-fixed samples were washed overnight in distilled water and fixed in 2.5% (w/v) cacodylate buffered glutaraldehyde (pH 7.6), postfixed with 1% (w/v) osmium tetroxide and block-stained with 2% uranyl acetate (w/v). Blocks were embedded in epon 812. Ultra-thin sections obtained with a Reichert ultracut microtome were examined with a Philips 201 transmission electron microscope.

Presence of facultative aerobic bacteria in duodenum, jejunum, ileum, caecum, liver and heart blood and of anaerobes in the caecum were evaluated according to standard procedures. The presence of *Clostridium spiroforme* was researched according to the technique of Borriello and Carman (1983). Samples of caecal content were taken for parasitology and virology. Native preparations were made for semi-quantitative evaluation of numbers of flagellates and of *Saccharomycopsis guttulatus* by phase-contrast microscopy. Smears were made for Gram's stain and May-Grünwald-Giemsa stain and other smears were stained with carbol-fuchsin for demonstration of cryptosporidia (Heine, 1981).

Caecal content was examined using the salt-flotation-concentration technique for demonstration of coccidia and helminths. Numbers of parasites were counted by the McMaster egg counting technique (MAFF, 1977). Samples with coccidia were made up in 2% (w/v) potassium bichromate and allowed to sporulate at 27 °C for subsequent differentiation of species. Samples of caecal content were clarified by low speed centrifugation (8000 \times g). The supernatants were treated for negative staining with 2% (w/v) uranyl acetate in bidistilled water and examined for the presence of viral particles by transmission electron microscopy.

Results

1. Case history and clinical findings

Outbreaks of diarrhoea from nine unrelated

rabbitries were reported to our Institute. Most outbreaks occurred in autumn and the beginning of the winter season. In six of the rabbitries, the condition existed for about ten days, whereas in three other rabbitries the problem had become enzootic. At the beginning of the outbreak some recently weaned rabbits showed profuse watery diarrhoea. They died within 24 to 72 hours. Then more and more animals became affected, culminating in 5 to 15% mortality in the second week. From the third week, diarrhoea became less evident in animals which survived the acute stage and the disease took a more chronic aspect. Animals were depressed and showed a ruffled coat, anorexia and loss of weight. Reproduction stock was affected to a much smaller degree or was not affected at all. Diseased does showed anorexia, intermittent diarrhoea, infertility, abortion and stillbirth. They died in extreme cachexia. So did a buck in two rabbitries.

Total mortality was high in slaughter rabbits and amounted to between 14.2 and 41.2% during the first three weeks of the disease. Afterwards effective treatment was established in most cases. In one rabbitry, in which the disease was enzootic, weekly mortality figures were available from 71 foregoing weeks. They were calculated on a mean of 700 weaned rabbits present. A normal weekly mortality rate was between 0.2 and 1.4%. About every 8 to 10 weeks there was an increase of this figure to 3.2-4.2%. At that moment 5-week old rabbits received tetracycline treatment for two weeks. During the 71 weeks of observation two outbreaks occurred with a peak of 10.4 and 14.4% mortality respectively in one week. The mortality mostly referred to animals of four to eight weeks of age.

Different treatments had been attempted by the local veterinarians: sulphadimidine, sulphaquinoxaline/pyrimethamine, chloramphenicol, furaltodone, flumequine and colistine had little or no effect. Only treatment with oxytetracycline resulted in a marked improvement within two to three days. Mortality ceased almost immediately. Some of the chronically diseased animals, however, remained in a cachectic state. As mentioned above, treatment during the first two weeks after weaning was not sufficient to fight the disease completely. Better results were obtained by treating the whole rabbit stock, both slaughter and reproduction animals with oxytetracyclin in the feed during eight weeks. The rabbitry followed during 71 weeks was treated in this way after the last outbreak. No new outbreaks have occurred for three years.

In most cases the source of the infection remained obscure. Three outbreaks occurred in newly started rabbitries about three months after the arrival of reproduction animals and 10 to

15 days after weaning and transfer of the first young rabbits to the fattening compartments. In two rabbitries infection could be assigned to the purchase of an infected rabbit. In most rabbitries the presence of rats or mice could be excluded. In seven rabbitries the climate (temperature, humidity, air velocity and ammonia) was good. In two cases however, high ammonia levels were associated with a high incidence of respiratory disease. In one rabbitry, problems started seven days after a change of food.

2. Gross pathology

Marked caecal oedema, multifocal hepatic necrosis and focal myocardial necrosis were the main findings at necropsy. Caecal oedema up to 5 mm in diameter was a consistent feature in animals killed during the acute and chronic phase of the disease (fig. 3). It was less pronounced or even absent when the disease became enzootic. In the case of severe caecal oedema, the mesenteric attachment of caecum, distal ileum and proximal colon was also oedematous. In some animals white spots of 1 to 5 mm were visible through the oedematous caecal wall. In some animals (9/57) haemorrhages were present on the caecal and proximal colonic serosa. There were areas of yellow-greyish necrosis and petechiae on the tips of the caecal folds in 23 of 57 animals necropsied.

Intestinal lesions were also found in the distal ileum and the proximal colon. In severe cases, areas of yellow-greyish necrosis were present in the mucosa of ileum and colon. In the ileum, they sometimes caused partial stenosis. In two animals, opaque white lines partially encircling the wall of the terminal ileum were established. In another animal, jejuno-ileal invagination was present. In animals without necrotic ileitis, the ileal wall seemed enlarged. Peyer's patches were markedly swollen and so were the mesenteric lymph nodes. They were sometimes hemorrhagic. The stomach mostly contained a watery food bolus. The spleen appeared normal, whereas kidneys were pale in 17/57 animals.

Few to numerous pale foci, usually 2 mm or less in diameter, were scattered throughout the livers of 24 out of 33 rabbits killed during the acute stage of the disease and in only 8 out of 24 animals during the enzootic stage (fig. 1). In 5 out of 57 animals, one or more circumscribed grey areas of 0.5 to 4 mm in diameter were observed in the myocardium, usually near the apex of the heart.

3. Microbiological and parasitological findings

Coccidia were detected in 18 animals from four rabbitries. In rabbits coming from three of them, fewer than 100 coccidia were counted per gramme of caecal contents (o p g). In the fourth one, however, between 3×10^4 and 1.2×10^6 o p

g have been found. Five species were established: *Eimeria flavescens* (1/18), *E. intestinalis* (6/18), *E. magna* (11/18), *E. media* (6/18) and *E. perforans* (5/18). In the rabbitry where severe coccidiosis occurred, all samples were dominated by *E. intestinalis*. In the same rabbitry and in one other, pneumonia associated with *Pasteurella multocida* was observed. A significant proliferation of flagellates and increase of numbers of blastospores of *Saccharomyces guttulatus* were present in only a few samples. Neither cryptosporidia nor helminths were observed. Rotavirus particles have been established in only 2 out of 24 preparations examined.

Caecal proliferation of *Escherichia coli* as shown by semiquantitative evaluation on selective media was present in 16 out of 57 animals. Proliferation of *E. coli* in both caecum and ileum and occasionally higher was found in another 8 animals. Culture of the liver remained negative in 42 out of 57 animals sampled and showed the presence of some *E. coli* in the other samples. *Clostridium spiroforme*-like organisms were found in five rabbitries sampled. Anaerobic culture of caecal contents revealed the presence of *Cl. perfringens* in 5 out of 19 samples.

4. Histopathology

Multiple foci of necrosis were found in the liver. Most, but not all of them, were located at the periphery of the lobuli near the portal vessels. There was usually a sharp line of demarcation between the necrotic hepatocytes and the adjacent normal tissue. The areas of necrosis consisted of eosinophilic homogeneous to granular material containing cellular debris and remnants of polymorphonuclear leucocytes (PMNL) (fig. 2). Around the lesions there was only little tissue reaction. In the hepatic sinusoids increased numbers of PMNL were present.

At the border of the necrotic foci, bundles of long, slender rod-shaped organisms were found in the cytoplasm of apparently viable hepatocytes in a random criss-cross distribution (fig. 5). They were rarely found in the necrotic areas. The bacilli were faintly visible as basophilic rods in HE-stained sections. With the Warthin-Starry silver impregnation technique they were much easier to distinguish and were faintly banded in slightly impregnated tissues. The rods were weakly Gram-negative and contained PAS-positive structures. With Giemsa they mostly stained uniformly blue. Sometimes transverse banding of the organisms was observed, mainly in the thicker rods. Most organisms were long and slender and measured $7.6 \pm 2.5 \mu\text{m}$ ($\bar{X} \pm s$). Sometimes short, thicker forms were present, measuring $4.8 \pm 0.9 \mu\text{m}$. They regularly showed an enlargement at one end. Filamentous forms with bulbar or fusiform enlargements were rarely found. Bacilli were not present

around all lesions: they disappeared around reparative hepatic lesions and when the disease became chronic or enzootic. Necrotic foci have also been established in the myocard. At their border some bundles of organisms were observed parallel to the myofibrils. Around these lesions, there was moderate mononuclear and PMNL infiltration.

Intestinal lesions were found in all rabbits examined. Changes in duodenum and jejunum

were usually minimal and consisted of a moderate increase in mononuclear cells in the lamina propria. In some rabbits however there was villous atrophy and necrosis of the jejunal epithelium. Some crypts contained leucocytes and cellular debris. In terminal ileum, caecum and proximal colon necrosis of all the layers of the mucosa,

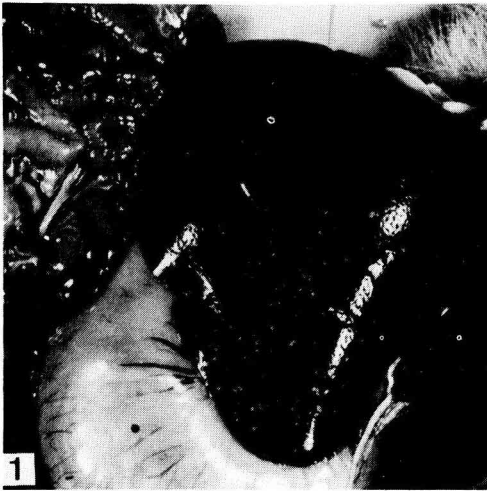

Fig. 1. — Numerous foci of miliary necrosis in the liver.

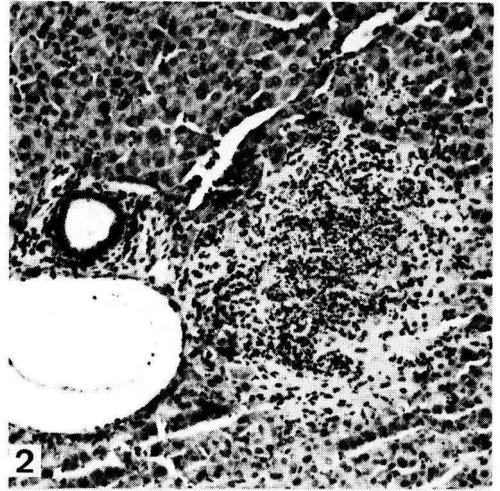


Fig. 2. — Liver: focus of coagulation necrosis containing cellular debris near portal vessels, HE \times 104.

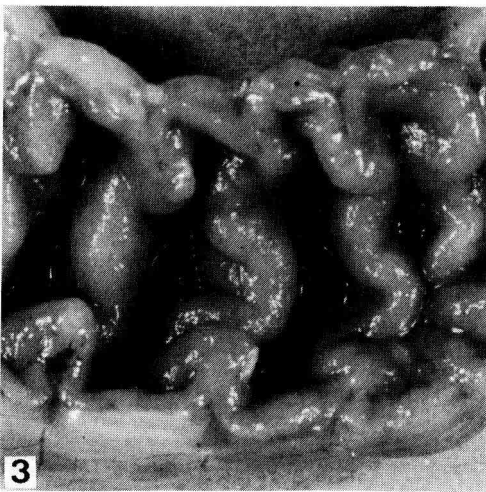


Fig. 3. — Extensive oedema of the caecal wall.

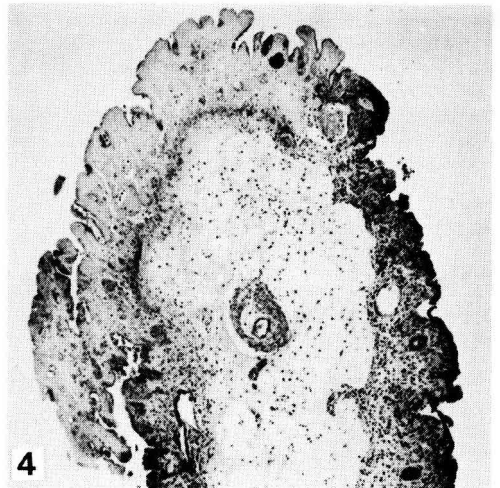


Fig. 4. — Caecal fold: area of mucosal necrosis (muscularis mucosae included); the intact epithelium is cuboidal and there is extensive oedema of the submucosa with infiltration of mononuclear cells and polymorphonuclear leucocytes. Note dilatation of vessels. HE \times 40.

portions of the muscularis mucosae included, was often observed (fig. 4). Necrotic areas were patchy in distribution. The lymphoid tissue of the Peyer's patches was hyperplastic. Between areas of necrosis the lamina propria was oedematous and infiltrated with mononuclear cells and with moderate numbers of PMNL. Bundles of filamentous rods with the same staining characteristics as those found in the liver were observed in the

epithelium (fig. 6) and muscularis mucosae (fig. 7) of jejunum, ileum, caecum and colon. They were also shown in Giemsa stained scrapings of the ileal mucosa (fig. 8). In the muscularis mucosae, where the organisms were consistently present, the bacilli were somewhat longer than in hepatocytes or enterocytes: $10.6 \pm 2.6 \mu\text{m}$.

There was extensive oedema of the submucosa with infiltration of mononuclear cells and moder-

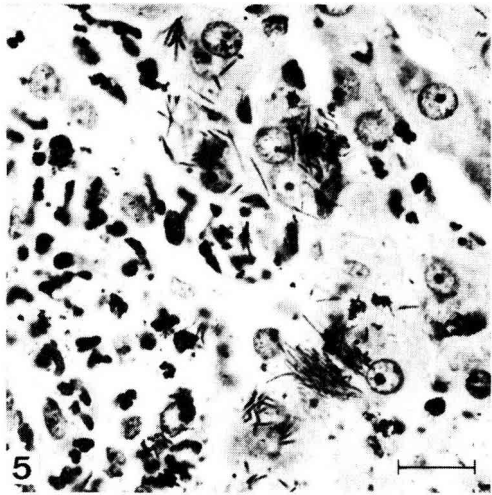


Fig. 5. — Liver: *Bacillus piliformis* in hepatocytes bordering a focus of necrosis. HE / Warthin-Starry silver stain. $\times 520$ (Bar: $20 \mu\text{m}$).

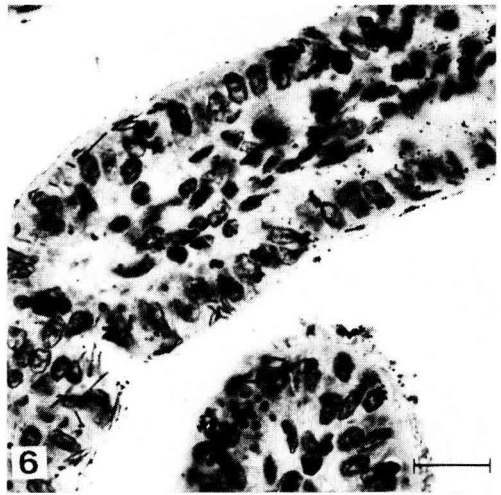


Fig. 6. — *Bacillus piliformis* in epithelial cells lining the ileal mucosa. HE / Warthin-Starry silver stain $\times 520$ (Bar: $20 \mu\text{m}$).

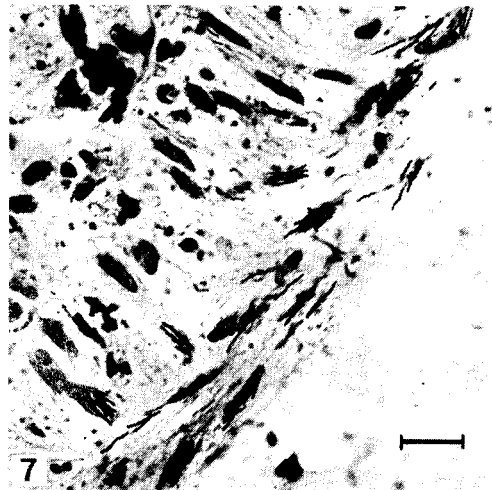


Fig. 7. — *Bacillus piliformis* in smooth muscle cells of the caecal muscularis mucosae. HE / Warthin-Starry silver stain $\times 420$ (Bar: $20 \mu\text{m}$).

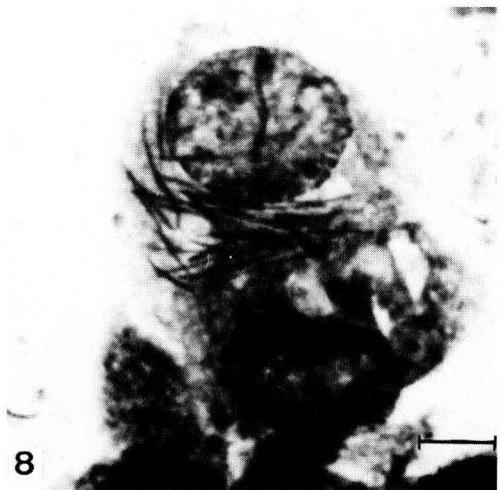

Fig. 8. — Scraping of ileal mucosa: *Bacillus piliformis* in an enterocyte. May-Grünwald-Giemsa $\times 1040$ (Bar: $10 \mu\text{m}$).

ate numbers of PMNL (fig. 4). Also, the serosa was regularly oedematous. Intestinal vessels were dilated and often contained necrotic debris. Sometimes also the muscular layer of the vessels was

necrotic. Smooth muscle cells of the circular layer of the muscularis were necrotic around such vessels. Sometimes areas of necrosis were also found in the longitudinal layer of the muscularis. In

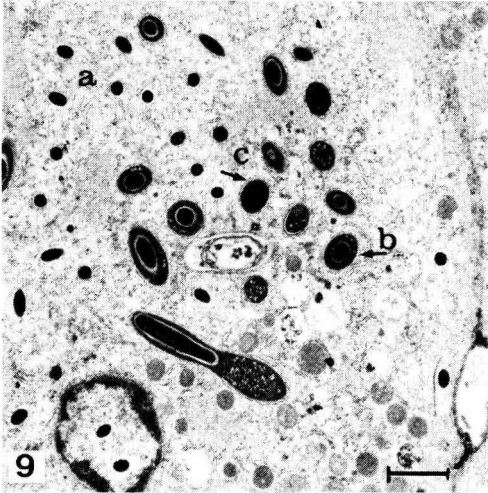


Fig. 9. — Cross and longitudinal sections of the three forms of *Bacillus piliformis* in the cytoplasm of an hepatocyte near a necrotic lesion: filamentous form (a) and thick short rod form with (b) and without (c) an inclusion body. One thick short rod shows an enlargement at one end, containing an inclusion body. Note the presence of two filamentous forms in the nucleus. TEM $\times 4100$ (Bar: 2 μm).

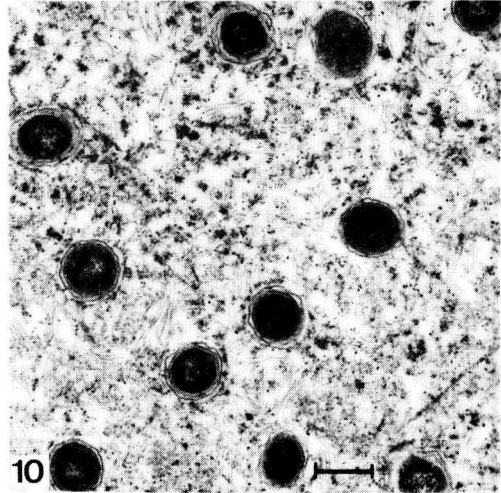


Fig. 10. — Cross sections of the filamentous form of *Bacillus piliformis* surrounded by numerous flagelliform appendages in the cytoplasm of an hepatocyte near a necrotic lesion. TEM $\times 15\,000$ (Bar: 500 nm).

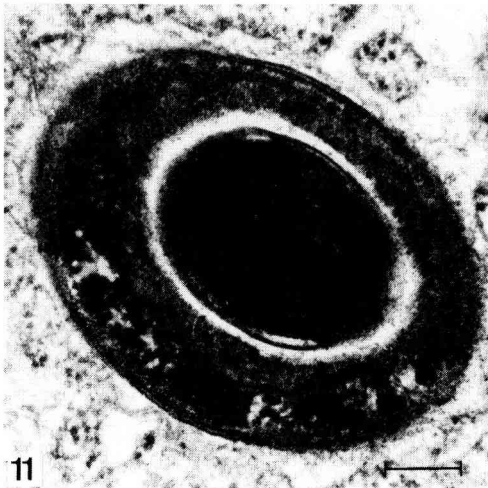


Fig. 11. — High magnification of a cross section of a thick rod form of *Bacillus piliformis*: note the similar structure of the cell wall of the thick short rod and its inclusion body. TEM $\times 52\,000$ (Bar: 200 nm).

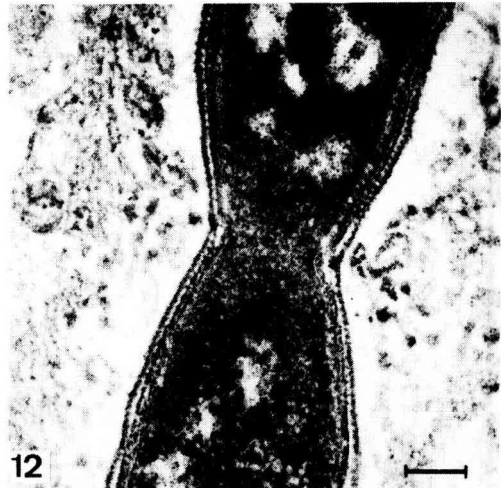


Fig. 12. — High magnification of a filamentous form of *Bacillus piliformis* with a constriction of the cell wall. The cell wall is composed out of two electron-dense layers separated by an electron-lucent zone. Between outermost and innermost layers there is a periodical pattern of electron dense bridges. TEM $\times 83\,000$ (Bar: 100 nm).

two animals, muscular necrosis coincided with the opaque white lines seen at necropsy. In the submucosal and muscular layers, bacilli have not been identified histologically. They were hardly present in the mucosa of rabbits medicated with oxytetracyclin. The sinusoids of the mesenteric lymph nodes contained varying amounts of cellular debris.

5. Electron microscopy

In infected hepatocytes at the border of necrosis, three forms of electron-dense organisms could be distinguished: filamentous forms, thick short rods and spores or inclusion bodies (fig. 9).

The filamentous forms had a mean diameter of 410 ± 70 nm and were located within the ground substance of the cytoplasm (fig. 10). In some hepatocytes with abundant presence of organisms, a few bacilli were located in the electron-lucent area of the nucleus (fig. 9). The rods contained tightly packed, densely staining, fine, granular material. The cell border of the filamentous form consisted of a cytoplasmic membrane, an intermediate layer and a characteristic cell wall of about 20 to 30 nm. This cell wall was composed out of two electron-dense layers of about 3 to 4 nm thick separated by an electron-lucent area. The innermost layer of the cell wall was most electron-dense (fig. 10 and 12). Some parts of the cell wall showed a periodical pattern of electron-dense bridges between the outermost and innermost layers at constant intervals (fig. 12). Some filamentous forms showed constrictions of the cell wall. The organisms were surrounded by numerous flagelliform appendages with a diameter of about 12 nm (fig. 10). The cytoplasm of the host cell showed vesiculation of the granular endoplasmic reticulum and mitochondria. In severely damaged hepatocytes no organisms were observed.

The thick short rods had a mean diameter of 870 ± 120 nm. The cells contained, besides a dense plasma, many electron-lucent areas of about 70 to 80 nm of diameter (fig. 9). Some of the thick rods contained inclusion bodies. They had a mean diameter of 530 ± 90 nm and a cell content of high density (fig. 11). They were only found in thick rods, never free in the cytoplasm of the host cell. The cell border of the thick rods and of the inclusion bodies was similar to that of the filamentous forms. Flagelliform appendages were never observed around thick rods.

Discussion

Tyzzler's disease is caused by a rod-shaped, motile, pleomorphic, obligate, intra-cellular organism, *Bacillus piliformis*. The diagnosis of the

disease is based upon the demonstration of bundles of Gram-negative and Giemsa-, PAS- and silver-positive, rod-shaped bacilli in the cytoplasm and rarely in the nucleus (Kurashina and Fujiwara, 1972; Pulley and Shively, 1974) of apparently viable hepatocytes or heart muscle cells at the border of foci of coagulation necrosis or in enterocytes or smooth muscle cells of the muscularis mucosae of the gut (Ganaway *et al.*, 1971b; Bernirschke *et al.*, 1978; Fujiwara, 1978). Three forms of *B. piliformis* can be distinguished by the use of electronmicroscope: thin filaments, thick short rods and inclusion bodies (Grund and Thunert, 1983). All three forms have a similar cell wall composed out of two electron-dense layers of 4 nm separated by an electron-lucent zone of varying thickness (Port *et al.*, 1971; Kurashina and Fujiwara, 1972; Goto *et al.*, 1974; Pulley and Shively, 1974; Grund and Thunert, 1983) and connected by a periodical pattern of electron dense bridges at some places (Goto *et al.*, 1974; Pulley and Shively, 1974). The filamentous form is surrounded by numerous flagelliform appendages (Fujiwara *et al.*, 1968; Jonas *et al.*, 1970; Kurashina and Fujiwara, 1972; Goto *et al.*, 1974; Pulley and Shively, 1974; Grund and Thunert, 1983). *Bacillus piliformis* does not grow on artificial media (Allen *et al.*, 1965; Craigie, 1966; Ganaway *et al.*, 1971a; Fujiwara, 1978).

The staining characteristics and the morphological data of the organisms found in liver, heart and intestine in this study correspond well with the characteristics of *B. piliformis* as discussed above. From this, it may be assumed that the described outbreaks of diarrhoea were caused by *B. piliformis*. There was a good correlation between clinical signs and the degree of mucosal damage observed. Examination of faecal samples, gut contents and histological sections failed to reveal other known pathogens capable of causing similar lesions. In one rabbitry severe *E. intestinalis* infection was observed. *E. intestinalis* is known to cause cerebriform swelling of the ileum associated with liquid caecal contents (Peeters *et al.*, 1984a). However, the parasite never induces patchy necrosis of all mucosal layers of ileum, caecum and colon, nor multifocal hepatic necrosis. In 24 out of the 57 rabbits, there was caecal proliferation of *E. coli*. In histological sections, no Gram-negative bacteria with the dimensions of *E. coli* have been found to attach to the luminal border of ileum, caecum or colon as has been observed for some strains of enteropathogenic *E. coli* in rabbits, causing caecal oedema and epithelial desquamation (Cantey and Blake, 1977; Peeters *et al.*, 1984b). Therefore, the observed proliferation of *E. coli* in the gut may be considered as a secondary reaction. Secondary *E. coli* dysbacteriosis occurs also in other intestinal disorders such as coccidiosis (Licois and Guillot, 1980; Peeters

et al., 1984a), misuse of some antibiotics (Milhaud *et al.*, 1976) and increased caecal pH (Prohaszka and Baron, 1981). The intestinal proliferation of flagellates and *Saccharomyces guttulatus* may also be considered as secondary. Rotaviruses were found too rarely to account for the outbreaks of diarrhoea.

The observed clinical signs and lesions correspond well with the descriptions from literature (Allen *et al.*, 1965; Cutlip *et al.*, 1971; Van Kruiningen and Blodgett, 1971; Savage and Sheldon, 1973; Prescott, 1977; Ononiwu and Julian, 1978; Vetesi, 1982). In most cases, the source of the infection remained obscure. In at least two cases, the infection was introduced by newly purchased animals. In the other ones, infection could have been introduced by rodents or was already present as latent infection. Indeed, it is known that Tyzzer's disease can be reactivated by stress (Ganaway *et al.*, 1971b; Fujiwara, 1978) or by immunosuppression (Yamada *et al.*, 1960; Marler and Cook, 1976; Fries, 1977b). In the new rabbitries, we suspect transplacental or faecal transmission of the bacillus to the offspring of sub-clinically infected does. Transportation of the reproduction animals before arrival at the rabbitry might have acted as the stress factor necessary for the reactivation of the disease, possibly followed by transplacental transmission of the bacillus. In literature there are many reports of outbreaks of Tyzzer's disease shortly after transport of sub-clinical infected cats (Kovatch and Zebarth, 1973), gerbils (Port *et al.*, 1970), guinea pigs (McLeod *et al.*, 1977), hamsters (Nakayama *et al.*, 1976), mice (Peace and Soave, 1969), muskrats (Chalmers and MacNeill, 1977) and rats (Stedham and Bucci, 1970). Transplacental transmission of *B. piliformis* has already been shown in mice (Fries, 1978) and rats (Fries, 1979). The fact that maternal antibodies can be passed to the offspring (Fries, 1979), can explain why clinical signs first developed after weaning. Although the hypothesis of transplacental transmission of *B. piliformis* seems logical, this has not yet been shown experimentally in rabbits. Other possible stress factors which might have contributed to the outbreaks were change of food, coccidiosis, pasteurellosis and possibly atmospheric changes.

Effective treatment of Tyzzer's disease requires diagnosis at an early stage, immediate elimination of sick animals, medication of the remaining ones over a period of one to two months and a proper disinfection programme.

Very few antibiotics are active against *B. piliformis*. Treatment of experimentally infected mice (Takagaki *et al.*, 1964; Thunert, 1982) and rabbits (Thunert, 1982) as well as experiments with infected embryonated eggs (Ganaway *et al.*, 1971a) showed that penicillin G, streptomycin,

neomycin, polymyxin B, chloramphenicol, sulfadimidine and sulfadimethoxin are useless. Only tetracycline and oxytetracycline in the drinking water or by the intramuscular route were sufficiently active. Thunert (1982) also obtained good results with high doses of erythromycin (100 mg/kg) i.m. Our excellent results with oxytetracycline in the field, where other antibiotics failed, confirm these data. Nevertheless, it has to be stressed that not only rabbits of four to six weeks of age have to be medicated, but the whole rabbit stock, reproduction stock included and this for at least one month. Otherwise the risks of an enzootic evolution are too high.

Another important item is hygiene measures. As about 50 % of surviving rabbits develop partial stenosis of the terminal ileum as a result of the healing process (Cutlip *et al.*, 1971) and become cachectic, it seems wise to eliminate such animals. Since Tyzzer's disease occurs as a sub-clinical or latent condition in recovered animals and since *B. piliformis* is transmitted through the placenta in some species, recovered animals should not be selected for breeding purposes. Rodents are often infected with *B. piliformis* (Tuffery, 1956; Fries and Svendsen, 1978). They are among other sources of infection strongly suspected of transmitting the disease to foals (Hall and Van Kruiningen, 1974; Swerczek, 1977). Therefore, elimination of rodents is also indicated.

Most authors agree that the main route of infection is the oral one (Tyzzer, 1917; Gard, 1944; Rights *et al.*, 1947; Nakayama *et al.*, 1976). Although the vegetative form *B. piliformis* is very labile (Craigie, 1966; Ganaway *et al.*, 1971b; Fujiwara, 1978) the spores may remain infective for at least one year in infected cages and dried litter (Tyzzer, 1917; Ganaway *et al.*, 1971a). So proper cleaning and disinfection after an outbreak of Tyzzer's disease is quite important. Ganaway (1980) examined the effect of different disinfection programmes on the viability of spores of *B. piliformis*: 0.3 % sodium hypochlorite and 2 % glacial acetic acid with 0.025 % sodium alkylarylsulfonate killed 100 % of the spores after five minutes of contact. Less active were 8 % formaldehyde or 1 % iodophores. Spores lost their infectivity also after 15 minutes at 80 °C.

Diagnosis of Tyzzer's disease in rabbits is rather difficult. Necrotic hepatic lesions are not always present and are not always surrounded by *B. piliformis* either. A few hours after death, histological demonstration of the bacilli becomes difficult. In enzootic cases intestinal lesions are relatively mild. Thus it is not excluded that Tyzzer's disease is more common in commercial rabbitries than the

few reports in literature suggest. This makes the study of the epidemiology of Tyzzer's disease in commercial rabbitries and the prevention and

treatment of the disease of special interest.
 Received 21st February, 1984.
 Accepted 4th June, 1984.

Summary

Tyzzer's disease has been detected in nine unrelated, commercial rabbitries. During the acute stage of the disease, recently weaned rabbits showed profuse watery diarrhoea. Mortality was between 14.2 and 41.2 % during the first three weeks of the outbreaks. In surviving animals, there was a chronic evolution with depression, anorexia, loss of weight and sometimes extreme cachexia. Reproduction animals were less badly affected. Multifocal hepatic necrosis, focal myocardial necrosis, patches of mucosal necrosis in ileum, caecum and colon and marked caecal oedema were most prominent at autopsy. In histological sections of the liver, bundles of slightly Gram-negative and Giemsa-, PAS- and silver-positive rod-shaped bacilli were established in apparently viable hepatocytes bordering foci of necrosis. They were also present in myocytes around necrotic foci in the heart and in enterocytes and smooth muscle cells of the muscularis mucosae of the intestinal mucosa. Transmission electron microscopy showed that these organisms had a similar ultrastructure as *Bacillus piliformis*. Most antibiotics used failed to combat the disease. Only oxytetracycline was active.

References

- ALLEN A.M., GANAWAY J.R., MOORE T.D., KINARD R.F., 1965. Tyzzer's disease syndrome in laboratory rabbits. *Am. J. Pathol.*, **46**, 859-882.
- BERNIRSCHKE F.M., GARNER K., JONES T.C., 1978. *Pathology of laboratory animals*, 2171 pp., Springer Verlag, New York.
- BORRIELLO S.P., CARMAN R.J., 1983. Association of iota-like toxin and *Clostridium spiroforme* with both spontaneous and antibiotic associated diarrhoea and colitis in rabbits. *J. Clin. Microbiol.*, **17**, 414-418.
- CANTEY J.R., BLAKE R.K., 1977. Diarrhoea due to *Escherichia coli* in the rabbit: a novel mechanism. *J. Infect. Dis.*, **135**, 454-462.
- CHALMERS G.A., MacNEILL A.C., 1977. Tyzzer's disease in wild-trapped muskrats in British Columbia. *J. Wildl. Dis.*, **13**, 114-116.
- CRAIGIE J., 1966. *Bacillus piliformis* (Tyzzer) and Tyzzer's disease of the laboratory mouse. I. Propagation of the organism in embryonated eggs. *Proc. Roy. Soc. London*, **166B**, 35-60.
- CULLING C.F.A., 1974. *Handbook of histopathological and histochemical techniques*. Butterworths, London.
- CUTLIP R.C., AMTOWER W.C., BEALL C.W., MATTHEWS P.J., 1971. An epizootic of Tyzzer's disease in rabbits. *Lab. Anim. Sci.*, **21**, 356-361.
- FRIES A.S., 1977a. Studies on Tyzzer's disease: application of immunofluorescence for detection of *Bacillus piliformis* and for demonstration and determination of antibodies to it in sera from mice and rabbits. *Lab. Anim.*, **11**, 69-73.
- FRIES A.S., 1977b. Studies on Tyzzer's disease: isolation and propagation of *Bacillus piliformis*. *Lab. Anim.*, **11**, 75-78.
- FRIES A.S., 1978. Demonstration of antibodies to *Bacillus piliformis* in SPF colonies and experimental transplacental infection by *Bacillus piliformis* in mice. *Lab. Anim.*, **12**, 23-26.
- FRIES A.S., 1979. Studies on Tyzzer's disease: transplacental transmission of *Bacillus piliformis* in rats. *Lab. Anim.*, **13**, 43-46.
- FRIES A.S., SVENDSEN O., 1978. Studies on Tyzzer's disease in rats. *Lab. Anim.*, **12**, 1-4.
- FUJIWARA K., 1978. Tyzzer's disease. *Jap. J. Exp. Med.*, **48**, 467-480.
- FUJIWARA K., KURASHINA H., MATSUNUMA N., TAKAHASHI R., 1968. Demonstration of peritrichous flagella of Tyzzer's disease organism. *Jap. J. Microbiol.*, **12**, 361-363.
- GANAWAY J.R., 1980. Effect of heat and selected chemical disinfectants upon infectivity of spores of *Bacillus piliformis* (Tyzzer's disease). *Lab. Anim. Sci.*, **30**, 192-196.
- GANAWAY J.R., ALLEN A.M., MOORE T.D., 1971a. Tyzzer's disease of rabbits: isolation and propagation of *Bacillus piliformis* (Tyzzer) in embryonated eggs. *Infect. Immun.*, **3**, 429-437.
- GANAWAY J.R., ALLEN A.M., MOORE T.D., 1971b. Tyzzer's disease. *Am. J. Pathol.*, **64**, 717-730.
- GANAWAY J.R., McREYNOLDS R.S., ALLEN A.M., 1976. Tyzzer's disease in free-living cottontail rabbits (*Sylvilagus floridanus*) in Maryland. *J. Wildl. Dis.*, **12**, 545-549.
- GARD S., 1944. *Bacillus piliformis* infection in mice and its prevention. *Acta Pathol. Microbiol. Scand.*, **54**, suppl., 123-134.

- GOTO N., OGHISO Y., LEE Y.S., TAKAHASHI R., FUJIWARA K., 1974. Fine structure of the Tyzzer's organism in the feline liver. *Jap. J. Exp. Med.*, **44**, 373-378.
- GOWEN J.W., SCHOTT R.G., 1933. Genetic predisposition to *Bacillus piliformis* infection among mice. *J. Hyg.*, **33**, 370-378.
- GRUND S., THUNERT A., 1983. Electron microscopic studies of three forms of *Bacillus piliformis*. *Zentralbl. Veterinaermed.*, B, **30**, 117-130.
- HALL W.C., VAN KRUNINGEN H.J., 1974. Tyzzer's disease in a horse. *J. Am. Vet. Med. Assoc.*, **164**, 1187-1189.
- HEINE J., 1981. Eine einfache Nachweismethode für Kryptosporidien im Kot. *Zentralbl. Veterinaermed.*, B, **29**, 324-327.
- JONAS A.M., PERCY D.H., CRAFT J., 1970. Tyzzer's disease in the rat. *Arch. Pathol.*, **90**, 516-528.
- KANEKO J., FUJITA H., MATSUYAMA S., KOJIMA H., ASAKURA H., NAKAMURA Y., KODAMA T., 1960. (An outbreak of Tyzzer's disease in colonies of mice) (In Japanese). *Jikken Dobutsu Iho*, **9**, 148-156.
- KARSTAD L., LUSIS P., WRIGHT D., 1971. Tyzzer's disease in muskrats. *J. Wildl. Dis.*, **7**, 96-99.
- KOVATCH R.M., ZEBARTH G., 1973. Naturally occurring Tyzzer's disease in a cat. *J. Am. Vet. Med. Assoc.*, **162**, 136-138.
- KUBOKAWA K., KUBO M., TAKASAKI Y., OGHISO Y., SATO K., LEE Y.S., GOTO N., TAKAHASHI R., FUJIWARA K., 1973. Two cases of feline Tyzzer's disease. *Jap. J. Exp. Med.*, **43**, 413-421.
- KURASHINA H., FUJIWARA K., 1972. Fine structure of the mouse liver infected with the Tyzzer's organism. *Jap. J. Exp. Med.*, **42**, 139-154.
- LEE G., LUNA H.T., 1960. *Manual of histologic staining methods of the Armed Forces Institute of Pathology*. 3rd ed., 258 pp. McGraw-Hill Book Company, New York.
- LICOIS D., GUILLOT J.F., 1980. Évolution du nombre de colibacilles chez des lapereaux atteints de coccidiose intestinale. *Recl Méd. Vét.*, **156**, 555-560.
- MAFF, 1977. *Technical bulletin n° 18. Manual of veterinary parasitological laboratory techniques*. 129 pp, Ministry of Agriculture, Fisheries and Food, London.
- MARLER R.J., COOK J.E., 1976. Tyzzer's disease in two coyotes. *J. Am. Vet. Med. Assoc.*, **169**, 940-941.
- MC LEOD C.G., STOOKEY J.L., HARRINGTON D., WHITE J.D., 1977. Intestinal Tyzzer's disease and spirochetosis in a guinea pig. *Vet. Pathol.*, **14**, 229-235.
- MILHAUD G., RENAULT L., VAISSAIRE J., MAIRE Cl., 1976. Sensibilité du lapin à l'ampicilline. *Recl Méd. Vét.*, **152**, 843-847.
- NAKAYAMA M., MACHII K., GOTO Y., FUJIWARA K., 1976. Typhlohepatitis in hamsters infected perorally with the Tyzzer's organism. *Jap. J. Exp. Med.*, **46**, 309-324.
- NIVEN J.S.F., 1968. Tyzzer's disease in laboratory animals. *Z. Versuchstierk.*, **10**, 168-174.
- ONONIWU J.C., JULIAN R.J., 1978. An outbreak of Tyzzer's disease in an Ontario rabbitry. *Can. Vet. J.*, **19**, 107-109.
- PEACE A.B., SOAVE B.C., 1969. Tyzzer's disease in a group of newly purchased mice. *Lab. Anim. Digest.*, **5**, 202-204.
- PEETERS J.E., CHARLIER G., ANTOINE O., MAMMERICKX M., 1984a. Clinical and pathological changes after *Eimeria intestinalis* infection in rabbits. *Zentralbl. Veterinaermed.*, B, **31**, 9-24.
- PEETERS J.E., GEEROMS R., GLORIEUX B., 1984b. Experimental *Escherichia coli* enteropathy in weanling rabbits: clinical manifestations and pathological findings. *J. Comp. Pathol.*, **94**, 521-528.
- PORT C.D., RICHTER W.R., MOISE S.M., 1970. Tyzzer's disease in the gerbil (*Meriones unguiculatus*). *Lab. Anim. Care*, **20**, 109-111.
- PORT C.D., RICHTER W.R., MOISE S.M., 1971. An ultrastructural study of Tyzzer's disease in the mongolian gerbil (*Meriones unguiculatus*). *Lab. Invest.*, **2**, 81-87.
- PRESCOTT J.F., 1977. Tyzzer's disease in rabbits in Britain. *Vet. Rec.*, **100**, 285-286.
- PROHASZKA L., BARON F., 1981. Studies on *E. coli*-enteropathy in weanling rabbits. *Zentralbl. Veterinaermed.*, B, **28**, 102-110.
- PULLEY L.T., SHIVELY J.N., 1974. Tyzzer's disease in a foal. *Vet. Pathol.*, **11**, 203-211.
- QURESHI S.R., CARLTON W.W., OLANDER H.J., 1976. Tyzzer's disease in a dog. *J. Am. Vet. Med. Assoc.*, **168**, 602-604.
- RIGHTS F.L., JACKSON E.B., SMADEL J.E., 1947. Observations on Tyzzer's disease in mice. *Am. J. Pathol.*, **23**, 627-635.
- SAVAGE N.L., SHELDON W.G., 1973. An epizootic of diarrhoea in a rabbit colony. Pathology and bacteriology. *Can. J. Comp. Med.*, **37**, 313-319.
- SPARROW S., NAYLOR P., 1978. Naturally occurring Tyzzer's disease in guinea pigs. *Vet. Rec.*, **102**, 288.
- STANLEY S.M., FLATT R.E., DANIELS G.N., 1978. Naturally occurring Tyzzer's disease in the gray fox. *J. Am. Vet. Med. Assoc.*, **173**, 1173-1174.
- STEDHAM M.A., BUCCI T.J., 1970. Spontaneous Tyzzer's disease in a rat. *Lab. Anim. Care*, **20**, 743-746.

- SWERCZEK T.W., 1977. Multi-focal hepatic necrosis and hepatitis in foals caused by *Bacillus piliformis* (Tyzzer's disease). *Vet. Annu.*, **17**, 131-132.
- TAKAGAKI Y., ITO M., FUJIWARA K., MAEJIMA M., NAIKI M., TAJIMA Y., 1964. Effets d'antibiotiques et de sulfamides sur la maladie de Tyzzer chez la souris expérimentalement infectée. *C.R. Soc. Biol.*, **158**, 414-418.
- TAKASAKI Y., OGHISO Y., SATO K., FUJIWARA K., 1974. Tyzzer's disease in hamsters. *Jap. J. Exp. Med.*, **44**, 267-270.
- THUNERT A., 1982. Therapy and prophylaxis of Tyzzer's disease (*In vivo* antibiogram of three strains of *B. piliformis*). *Z. Versuchstierk.*, **24**, 206-213.
- TUFFERY A.A., 1956. The laboratory mouse in Great Britain. IV. Intercurrent infection (Tyzzer's disease). *Vet. Rec.*, **68**, 511-515.
- TYZZER E.E., 1917. A fatal disease of the Japanese waltzing mouse caused by a spore-bearing bacillus (*B. piliformis*, n.sp.). *J. Med. Res.*, **37**, 307-338.
- VAN KRUININGEN H.J., BLODGETT S.B., 1971. Tyzzer's disease in a Connecticut rabbitry. *J. Am. Vet. Med. Assoc.*, **158**, 1205-1212.
- VETESI F., 1982. (Occurrence of Tyzzer's disease in Hungarian rabbit farms) (In Hungarian). *Mag. All. Lapja*, **37**, 519-524.
- WHITE D.J., WALDRON M.M., 1969. Naturally-occurring Tyzzer's disease in the gerbil. *Vet. Rec.*, **85**, 111-114.
- YAMADA A., OSADA Y., TAKAYAMA S., AKIMOTO T., OGAWA H., OSHIMA Y., FUJIWARA K., 1960. Tyzzer's disease syndrome in laboratory rats treated with adrenocorticotrophic hormone. *Jap. J. Exp. Med.*, **39**, 505-518.
- ZENTRALINSTITUT FÜR VERSUCHSTIERE, 1975. *Annual report*. Lettow-Vorbeck Allee, 57, 3000 Hannover.