



**HAL**  
open science

## MUCIN LAYER IN THE LARGE INTESTINE

T. Sakata, W.V. Engelhardt

► **To cite this version:**

T. Sakata, W.V. Engelhardt. MUCIN LAYER IN THE LARGE INTESTINE. *Annales de Recherches Vétérinaires*, 1979, 10 (2-3), pp.485-487. <hal-00901222>

**HAL Id: hal-00901222**

**<https://hal.science/hal-00901222v1>**

Submitted on 11 May 2020

**HAL** is a multi-disciplinary open access archive for the deposit and dissemination of scientific research documents, whether they are published or not. The documents may come from teaching and research institutions in France or abroad, or from public or private research centers.

L'archive ouverte pluridisciplinaire **HAL**, est destinée au dépôt et à la diffusion de documents scientifiques de niveau recherche, publiés ou non, émanant des établissements d'enseignement et de recherche français ou étrangers, des laboratoires publics ou privés.



HAL Authorization

## MUCIN LAYER IN THE LARGE INTESTINE

T. SAKATA and W.v. ENGELHARDT

*University of Stuttgart-Hohenheim, Institute of Zoophysiology, D700 Stuttgart 70, West Germany*

Savage *et al.* (1968) described microorganisms in the mucin layer at the surface of the mucosa of the large intestine as well as the stomach of mice. This luminal mucin layer (LML) is assumed to be a special microclimate for bacteria. In most histological and physiological studies on the large intestine this LML has not been taken into account, and the intestinal lumen has generally been considered a homogeneous compartment. We suppose that the thickness and the composition of the LML can create a specific microclimate at the mucosal surface of the large intestine. Thereby absorption of solutes may be influenced considerably. Our studies demonstrate differences in the thickness, compactness and histochemical nature of the luminal mucin layer.

### Material and Methods

Adult rats and guinea pigs fed commercial laboratory diets were used. Small sections of the intestine were ligated and taken from caecum, proximal and distal colon of anaesthetized animals. Samples were frozen in isopentane cooled with liquid nitrogen. Cross sections cut with a cryostat to a thickness of 15  $\mu\text{m}$  were mounted on albuminated glass slides with cold (-20°C to -30 °C) acetone for the substitution with water (Pearse, 1968). The sections were fixed with formaline vapor (40 °C, 15 h) (Pearse, 1968), and stained with alcian

blue (pH 2.5 or pH 1.0) and PAS to show the acid (sialo- and sulpho-) mucin and neutral mucin respectively, and with improved Gram's stain to show the Gram (+) and Gram (-) bacteria. Hematoxylin and eosin staining indicated the general histological structure of the section.

### Results

Our findings are shown in a schematic drawing in Figure 1. A luminal mucin layer was present at the surface of the mucosa in all sections of the large intestine. In the distal colon the LML was rather thin (table 1), on average 28  $\mu\text{m}$  in rats and 15  $\mu\text{m}$  in guinea pigs (table 1). The layer in the distal colon was more compact and more homogeneous than that in the other regions; only a small number of bacteria was present. In the caecum as well as in the proximal colon LML was irregular, and the thickness varied considerably (table 1). Especially in guinea pigs the epithelial surface frequently appeared as being covered with isolated mucin patches. The mean thickness of the LML of the caecum was 50  $\mu\text{m}$  in the guinea pig, and in the proximal colon it was 45  $\mu\text{m}$  in the rat and 47  $\mu\text{m}$  in the guinea pig.

The histochemical nature of the luminal mucin layer resembled that of the goblet cells of the epithelium in the various sections. In the caecum and in the taenia region of the proxi-

mal colon of the guinea pig, the mucin of the LML and of goblet cells was mostly neutral mucin. Layers of the remaining part of proximal colon in guinea pig and of the entire proximal colon of rat were mainly formed from neutral mucin ; a smaller amount of acid (sialo- and sulpho-) mucin was visible especially toward the digesta side in the proximal colon of rats. Rat LML as well as goblet cell mucin in the proximal colon contained more acid mucin than those of guinea pigs. In the distal colon, the LML as well as the goblet cells were rich in acid (sialo- and sulpho-) mucin ; usually sloughed fragments of LML were found in the peripheral digesta, and the formed contents were covered with a mucin coat.

Many partly degraded epithelial cells were seen in the LML in all the sections of the large intestine. The LML in the caecum and the proximal colon of guinea pig occasionally contained small protozoa.

Table 1. — Range of the Thickness of the Luminal Mucin Layer of the Large Intestine in Rat and Guinea Pig.

| Species    | Caecum<br>( $\mu\text{m}$ ) | Proximal<br>Colon<br>( $\mu\text{m}$ ) | Distal Colon<br>( $\mu\text{m}$ ) |
|------------|-----------------------------|--|-----------------------------------|
| Rat        |                             | 20 - 170                               | 10 - 40                           |
| Guinea Pig | 0 - 120                     | 20 - 120                               | 10 - 60                           |

**Discussion and Conclusion**

Along the large intestine a luminal mucin layer exists between the digesta and the surface of the epithelial cells. This layer is formed from the mucus secreted by the goblet cells. The LML in the caecum and the proximal colon seems to be more easily disintegrated by microbes. The smaller number of microbes in the dense LML of the distal colon as well as the thin acid Mucin found at the digesta side

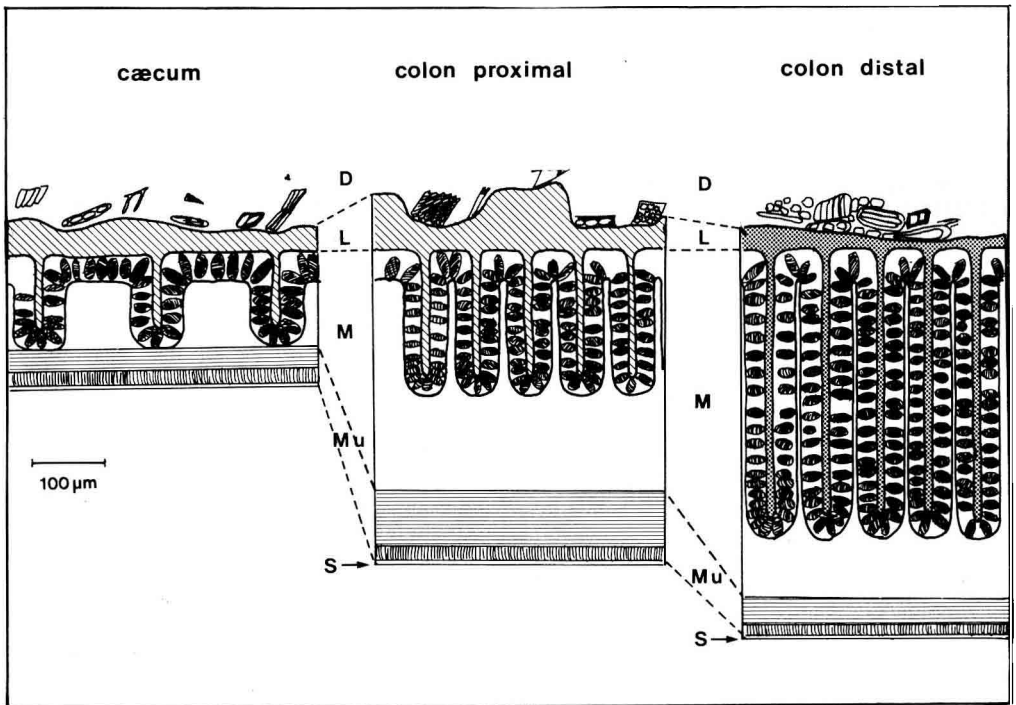


Fig. 1. — Schematic drawing of large intestine of guinea pig showing digesta (D) (shaded region), luminal mucin layer (L) hatched region indicating neutral-rich mucin and dotted region indicating acid-rich mucin, mucosa (M), muscle layers (Mu), and serosa (S).

of the LML in the proximal colon of rat may reflect a greater resistance of acid mucin against bacterial attack.

The mucin layer may have various important functions in the large intestine. The LML, especially the compact and dense mucin layer in the distal colon, is essential for lubrication and for protection of mucosal surface. It seems to be a suitable medium for microorganisms in the caecum and in the proximal colon. The microorganisms may contribute to the formation of the characteristic microclimate at the epithelial surface. The sloughed epithelial cells seem to be retained in this layer ; they seem to get gradually degraded.

Rechkemmer (1979) recently observed a stable neutral pH at the surface of the intestinal mucosa that was rather independent of the pH

of the luminal contents. We assume that the LML assists in maintaining an unstirred water layer at the surface of the epithelium. Such an unstirred layer with its microclimate may greatly influence the absorption of solutes and especially of weak acids and bases.

Studies with ligated rat colon segments (Sakata, 1979) indicate that various stimuli (volatile fatty acids and osmolarity of contents, distension of intestinal segments) can alter the release of mucin from the goblet cells ; thereby the thickness of the LML can be influenced. Findings also indicate regional differences in the release of mucus from goblet cells. The significance of differences in the histochemical nature of the LML in proximal and distal colon for absorptive processes in the large intestine is not so far understood.

#### References

- PEARSE A.G.E., 1968. *Histochemistry Theoretical and Applied* 3rd Ed., Churchill Livingstone, Edinburgh.
- RECHKEMMER G., 1979, personal communication.
- SAKATA T., 1979, unpublished data.
- SAVAGE D.C., DUBOS R., SCHAEDLER R.W., 1968. The Gastrointestinal Epithelium and its Autochthonous Bacterial Flora. *J. Exp. Med.*, **127**, 67-76.