



**HAL**  
open science

# The development of the gonadal and immune systems in the Atlantic salmon (*Salmo salar* L.) and a consideration of the possibility of inducing autoimmune destruction of the testis

Lindsay M. Laird, A. E. Ellis, A. R. Wilson, F. G. T. Holliday

## ► To cite this version:

Lindsay M. Laird, A. E. Ellis, A. R. Wilson, F. G. T. Holliday. The development of the gonadal and immune systems in the Atlantic salmon (*Salmo salar* L.) and a consideration of the possibility of inducing autoimmune destruction of the testis. *Annales de biologie animale, biochimie, biophysique*, 1978, 18 (4), pp.1101-1106. hal-00897394

**HAL Id: hal-00897394**

**<https://hal.science/hal-00897394>**

Submitted on 11 May 2020

**HAL** is a multi-disciplinary open access archive for the deposit and dissemination of scientific research documents, whether they are published or not. The documents may come from teaching and research institutions in France or abroad, or from public or private research centers.

L'archive ouverte pluridisciplinaire **HAL**, est destinée au dépôt et à la diffusion de documents scientifiques de niveau recherche, publiés ou non, émanant des établissements d'enseignement et de recherche français ou étrangers, des laboratoires publics ou privés.

## **The development of the gonadal and immune systems in the Atlantic salmon (*Salmo salar* L.) and a consideration of the possibility of inducing autoimmune destruction of the testis**

par Lindsay M. LAIRD, A. E. ELLIS \*, A. R. WILSON, F. G. T. HOLLIDAY

*Department of Zoology, University of Aberdeen,  
Tillydrone Avenue, Aberdeen AB9 2TN, U. K.*

*\* Department of Agriculture and Fisheries for Scotland,  
Marine Laboratory, Aberdeen.*

---

**Summary.** Gonad development was studied histologically and morphologically in eggs and fry of *Salmo salar* L. First signs of gonad tissue were found 6 days prior to hatching. Sex differentiation of the gonads appeared to be complete by about 60 days post-hatch. The development of the lymphoid system was also studied. The thymus is the first organ to become lymphoid (22 days post-hatch). Membrane bound immunoglobulin M (mlgM) and Mixed Lymphocyte Reactivity (MLR) appeared simultaneously about 45 days post-hatching, coincident with the start of feeding.

Experiments using testicular extracts injected into salmon parr have indicated that it is possible to induce autoimmune gonad destruction.

---

### **Introduction.**

The efficiency of salmonid farming would be greatly increased if gonad maturation could be stopped. Food would be converted to somatic tissue more efficiently and problems associated with precocious maturation, such as disease, eliminated. In several species of mammals experimental autoimmune rejection of testis germinal epithelium and autoimmune orchitis has been achieved using isogenic or allogenic tissue as antigen in Complete Freund's Adjuvant (CFA) (reviewed by Rumke and Hekman, 1975). The antigens producing the lesions are associated with mature and maturing germ cells and are of a polysaccharide-polypeptide complex of low molecular weight (Bishop et Carlson, 1971) or the enzyme sorbitol dehydrogenase (Mancini and Andrada 1971).

This paper presents the results of preliminary investigations into the ability of injected testis homogenate to produce auto-immune destruction of gonad tissue in salmon and to determine the earliest stage of development when stimulation of the

immune system could bring about such a lesion. The differentiation of the gonads, and the immune system with respect to both humoral and cell-mediated immunity is described.

### Materials and methods.

Salmon eggs and fry were kept in running water at 10 °C, hatching occurred 45 days post-fertilization : these were used for the study of gonad development. A separate batch of eggs was kept in running water at 4 °C rising 7 °C, hatching 111 days post-fertilization for the study of the development of the immune system. For the experimental work year old salmon parr and smolts, mean length 10 cms, were kept in aquarium tanks. Some of these fish were likely to mature in the next two months. Testes were extracted from a freshly killed maturing male parr. The whole testes were ground up and washed in phosphate buffered saline (PBS). 3 ml of this suspension were mixed with CFA using an ultrasonic probe. This was injected intraperitoneally into 5 parr in October 1976. A follow-up injection of sperm in PBS (0.2 ml/fish) was given 4 weeks later. A second set of 5 parr received no treatment and were held in similar conditions. Two fish from each group died, the remainder were killed in May 1977. For all the histology carried out, tissues were fixed in 10 p. 100 buffered formal-saline and paraffin embedded sections cut at 5  $\mu$ . Routine staining was in haematoxylin and eosin, and Mallory's trichrome, in addition Unna Pappenheim and fluorescent

---

#### PLATE 1

*Differentiating gonad ventral to kidney, 6 days prior to hatching. k, kidney tubule ; i, intestine ; g, gonad.  $\times$  350.*

#### PLATE 2

*Gonad containing large cells at time of hatching. g, gonad.  $\times$  220.*

#### PLATE 3

*Female gonad containing oogonia and primary oocytes 60 days post-hatching.  $\times$  110.*

#### PLATE 4

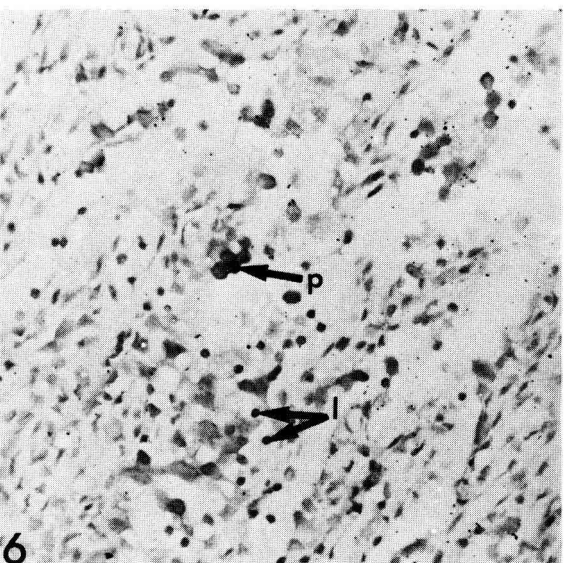
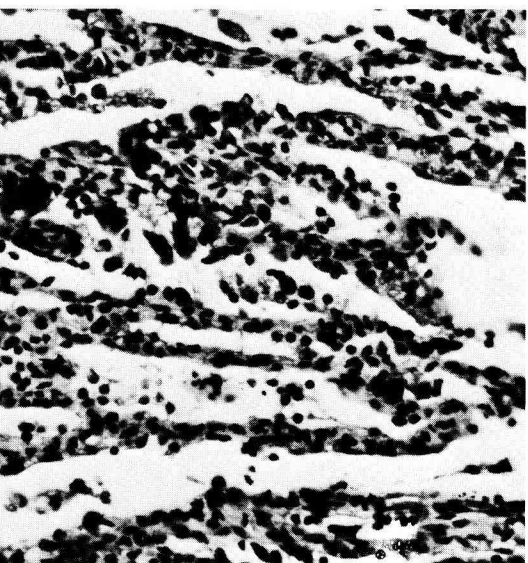
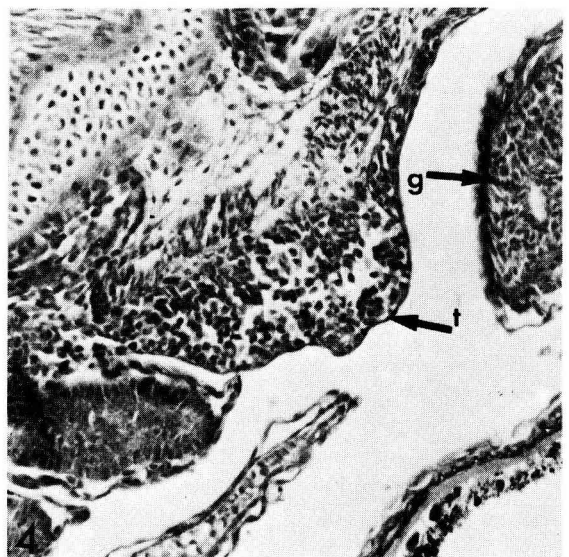
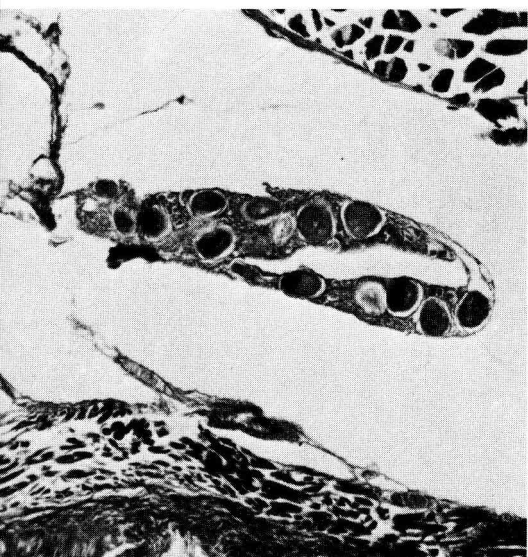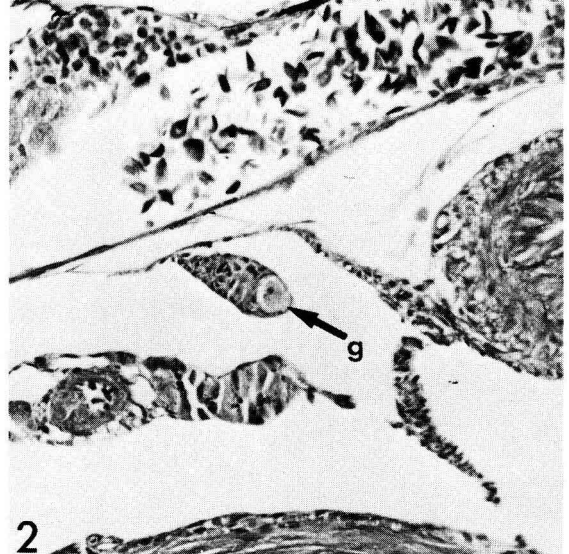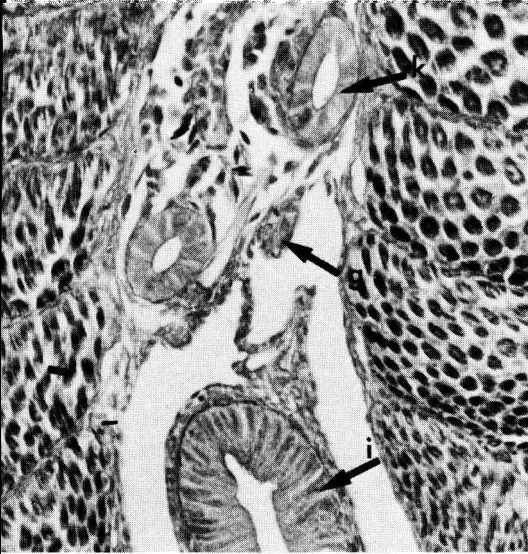
*Thymus containing small thymocytes, 12 days prior to hatching. t, thymus ; g, gill bar.  $\times$  110.*

#### PLATE 5

*Autoimmune lesion in testis showing absence of gametes and extensive lymphocyte infiltration within the gonad tissue. Haematoxylin and eosin.  $\times$  160.*

#### PLATE 6

*Autoimmune lesion in testis showing infiltration by plasma cells and small lymphocytes. p, plasma cells ; l, lymphocytes. Stained with Unna-Pappenheim.  $\times$  250.*



antibody techniques were performed. Methods for the immunofluorescent assay for mIgM and MLR have been reported in detail elsewhere (Waith and Hirschhorn, 1973 ; Ellis, 1977).

For sections of fish embryos, the shell was removed and the yolk sac cut off before sectioning.

## Results.

A. *Development of the gonad system.* — Gonads first appeared 6 days prior to hatching and were visible as ridges in the peritoneum at the base of the kidney (plate 1). The gonad ridge extended from a point above the anterior end of the stomach to a point above the anus. Germ cells appeared to be formed in the endoderm surrounding the gut as suggested for amphibia, birds and mammals (Berrill and Karp 1976), and to migrate through the dorsal mesentry to the gonad primordia. The gonads increased in size and became separated from the base of the kidney, although still attached to the dorsal mesentry. At the time of hatching, larger cells (14-16  $\mu$  diameter) were visible in the gonad (plate 2). The sexes were distinguishable by 60 days after hatching. The female gonad had increased in size, oogonia and primary oocytes are developing (plate 3). The male gonad increased in size more slowly, spermatogonia appearing after the oogonia in the female.

B. *Histological and functional development of the lymphoid system.* — The thymus was the first organ in which lymphoid differentiation took place. Development occurred within three separate pockets located over the first three gill arches, within the pharyngeal epithelium (plate 4). The anlage differentiated 22 days post-hatch and subsequently coalesced (table 1). The kidney contained haemopoietic stem cells prior to 23 days pre-hatch, but lymphoid cells were not apparent prior to 14 days pre-hatch. The spleen differentiated late in ontogeny, at 42 days post-hatch. This organ is never prominently lymphoid. Circulating lymphocytes were first observed in sections of blood vasculature 14 days pre-hatch.

TABLE 1

*Histological and functional development of the lymphoid system in Salmo salar kept at 4 °C rising to 7 °C at hatch*

Events	Days pre-hatch
Spawning .....	111
Lymphoid cells present in embryo homogenates .....	22
Thymocytes differentiated .....	22
Circulating lymphocytes .....	14
Kidney lymphocytes .....	14
	Days post-hatch
Feeding behaviour .....	41
Spleen differentiated .....	42
mIgM present on lymphocytes .....	42
MLR positive .....	45

Prior to feeding (41 days post-hatch) the lymphoid cells were negative for mlgM. In succeeding days the proportion of lymphocytes bearing mlgM increased and by day 48 post-hatch 80 p. 100 of lymphocytes were positive. Results for the mixed lymphocyte reaction are shown in table 2.

TABLE 2

*MLR using homogenates of whole larvae. Disintegrations per minute (DPM) are averages of assays done in triplicate for 3 individual larvae*

Days post-hatch .....	38	45	60	85	90
Control DPM (av) .....	3 400	2 700	8 000	3 000	12 000
MLR DPM (av).....	3 300	3 800	18 000	11 000	35 000
Ratio MLR/Control .....	1	1.4	2.2	3.6	3

*C. Auto-immune destruction of testicular tissue.* — The three surviving control fish developed gonads in the same way as the wild smolts. Three treated fish also survived and smolted.

*Fish 1.* This was a male fish and both superficial examination and subsequent histology indicated that it had certainly been maturing at the time of injection. The testes showed signs of degeneration and adhered to the body wall in some places. Histological examination showed that extensive degeneration of the testes had taken place, together with oedema and proliferation of fibrous tissue (plate 5). Neighbouring muscle tissue was not damaged. Staining with Unna Pappenheim showed pyroninophilic cells which are plasma cells associated with antibody production in immune reactions (plate 6). Fluorescent antibody tests (Sainte-Marie, 1962) also showed antibody-producing cells. No germ cells could be seen in section.

*Fish 2.* Gross examination suggested that this male fish had not matured, the gonads were two long, thin strands. Histological examination showed that the testes had responded to the injection. Compared with a normal testis from a smolt which had not previously matured there was an increase in fibrous tissue, antibody producing cells were present and germ cells were absent. Histological examination of kidney, liver and spleen from this fish showed no abnormalities, suggesting that the reaction produced in the testes was not merely the result of the adjuvant. This is supported by results from other experiments where Freund's Complete Adjuvant has been used.

*Fish 3.* Gross and histological examination showed this fish to be a normally developing female except for a small area of fibrous tissue in the region of the injection. Growth and external appearance of the treated fish seemed to be normal.

## Discussion and conclusions.

These preliminary experiments indicate that it is possible to alter gonad development by stimulating auto-immune rejection. It appears that this rejection is both sex- and organ-specific. More extensive studies are being carried out to investigate the

nature of the reaction and its long term effects. In order for the method to be used commercially, Complete Freund's Adjuvant would need to be replaced by a less toxic adjuvant and it would also be preferable to isolate soluble antigens, possibly administering them osmotically (Amend and Antipa, 1976) at the earliest possible stage of the fishes development. It appears from these results that the immune system reaches a competent stage of development to be stimulated at the time of first feeding.

*Symposium sur la Reproduction des Poissons  
Paimpont, France, 19-21 septembre 1977.*

*Acknowledgement.* — This work was carried out as part of a study financed by the Nuffield Foundation.

**Résumé.** Le développement des gonades a été étudié histologiquement et morphologiquement sur des embryons et alevins de *Salmo salar* L. Les premiers signes de formation des gonades apparaissent 6 jours avant l'éclosion. La différenciation sexuelle des gonades apparaît achevée environ 60 jours après l'éclosion. Le développement du système lymphoïde a aussi été étudié. Le thymus est le premier organe qui devient lymphoïde (22 jours après l'éclosion). Des immunoglobulines M liées aux membranes (mlgM) et une immuno-réactivité mixte des lymphocytes (MLR) apparaissent simultanément environ 45 jours après l'éclosion et coïncident avec la première prise de nourriture.

Des expériences utilisant des extraits testiculaires injectés à des parrs indiquent qu'il est possible d'induire une destruction auto-immune des gonades.

## References

- AMEND D., ANTIPA D., 1976. Uptake of bovine serum albumin by rainbow trout from hyperosmotic solutions : a model for vaccinating fish. *Science*, **192**, 732-794.
- BERRILL N. J., KARP G., 1976. *Development*. McGraw-Hill, New York.
- BISHOP D. W., CARLSON G. C., 1971. Immunologically induced aspermatogenesis in guinea pigs. *Ann. N. Y. Acad. Sci.*, **124**, 247-266.
- ELLIS A. E., 1977. Ontogeny of the immune response in *Salmo salar*. Histogenesis of the lymphoid organs and appearance of membrane. Immunoglobulin and mixed leucocyte reactivity (in press).
- MANCINI R. E., ANDRADA J. A., 1971. Immunological factors in human male and female infertility, 1240-1256. SAMTER M., *Immunological diseases*. Little, Brown and Co. Boston U. S.
- RUMKE Ph., HEKMAN A., 1975. Bibliography (with review) on autoimmunity to spermatozoa. *Bibliogr. Reprod.*, **25**, 1-8, 113-117.
- SAINTE-MARIE G., 1972. A paraffin embedding technique for studies employing immunofluorescence. *J. Histochem. Cytochem.*, **10**, 250-256.
- WAITE W. I., HIRSCHHORN K., 1973. The lymphocyte response to activators, Ch. **25**, 1-10. WEIR D. M., *Handbook of experimental immunology*. Blackwell Sci. Pub., Oxford.