



HAL
open science

Sexual differentiation of the external genital organs of the Macaca fascicularis fetus

D. C. Dang

► **To cite this version:**

D. C. Dang. Sexual differentiation of the external genital organs of the *Macaca fascicularis* fetus. *Annales de Biologie Animale, Biochimie, Biophysique*, 1978, 18 (3), pp.681-687. <hal-00897334>

HAL Id: hal-00897334

<https://hal.science/hal-00897334v1>

Submitted on 11 May 2020

HAL is a multi-disciplinary open access archive for the deposit and dissemination of scientific research documents, whether they are published or not. The documents may come from teaching and research institutions in France or abroad, or from public or private research centers.

L'archive ouverte pluridisciplinaire **HAL**, est destinée au dépôt et à la diffusion de documents scientifiques de niveau recherche, publiés ou non, émanant des établissements d'enseignement et de recherche français ou étrangers, des laboratoires publics ou privés.



HAL Authorization

Sexual differentiation of the external genital organs of the *Macaca fascicularis* fetus

par D. C. DANG

Laboratoire d'Anatomie, U. E. R. Biomédicale,
45, rue des Saints-Pères 75006 Paris, and
Laboratoire de Physiologie de la Reproduction, Université Paris VI,
I. N. R. A., 78350 Jouy en Josas, France.

Summary. The external genital organs of 34 male and female fetuses of *Macaca fascicularis* were obtained by cesarian between days 41 and 85 of pregnancy and studied. Differentiation was visible in the external genital organs of the male at 57 days : penis present, uro-genital groove closing, the two halves of the scrotum separated and lengthening of the ano-genital distance. At 75 days, these organs resembled those of the newborn (plate I). The differentiation of the external genital organs in the female only occurred at 85 days : vaginal opening and clitoris present, edged with small lips, but no large lips around the vulva. The latter were replaced by two swellings of « sexual skin » on the supero-internal surface of the thigh (plate II). The chronology of external genital apparatus differentiation in the crab-eating macaque resembled that of man.

Introduction.

The male and female genital organs of mammals mainly develop during fetal life after a so-called undifferentiated phase (Raynaud, 1969). While the fetal female ovary has no effect on the morphological development of the external genitals, the mechanism of which is still unknown, the fetal testis does secrete androgens which form and model the external genital organs (Raynaud and Frilley, 1947 ; Jost, 1947, 1969, 1970 ; Marois, 1968 ; Raynaud, 1969 ; Stoll and Maraud, 1974 ; Price *et al.*, 1975). By treating non-human primate mothers with androgens during pregnancy, genetically female fetuses have been changed into newborns presenting pseudohermaphroditic or external male genital organs (Wells and Van Wagenen, 1949 ; Dantchakoff, 1947, 1950 ; Wharton, 1966 ; Goy and Resko, 1972).

The normal development of external genital organs in the macaque has not been given much attention. In this report we compare the morphological evolution of the male and female external genital apparatus at a given age in the crab-eating macaque *Macaca fascicularis* beginning at the undifferentiated stage.

Material and methods.

Thirty-four fetuses 41 to 85 days old were used (table 1). They were obtained by cesarian according to a technique already described (Dang, 1977). Fetus age was counted from the first day the males were put with the females, i. e. between days 13 to 15 of the menstrual cycle for 24 or 48 hrs.

TABLE 1

Sex, age, body weight and length of fetuses obtained by cesarian

Males			Females		
Age (days)	Weight (mg)	Length (vertex-coccyx)	Age (days)	Weight (mg)	Length (vertex-coccyx)
41	70	18	—	—	—
42	76	19	—	—	—
43	—	—	—	—	—
—	—	—	44	128	—
45	140	23,5	45	110	22
46 (2)	95-110	22-21	—	—	—
—	—	—	47	94	19,5
48	220	23	—	—	—
50	—	—	—	—	—
51	385	40,5	—	—	—
53	290	35	—	—	—
—	—	—	54	423	40
57	700	48	—	—	—
—	—	—	58	780	49
59	690	48	—	—	—
—	—	—	60	850	51
62	1 150	57	—	—	—
—	—	—	63 (2)	1 310- 960	63-57
64	850	49	—	—	—
66	1 690	66	—	—	—
—	—	—	68	1 930	65
—	—	—	69	1 920	67
70	1 930	66	—	—	—
71	2 860	77	—	—	—
75	—	—	75	2 000	70
78	—	—	—	—	—
82	3 700	81	—	—	—
83	5 160	91	—	—	—
—	—	—	84 (2)	4 820-4 350	91-86
—	—	—	85	4 860	85

The sex of fetuses younger than 75 days was determined by histological examination of the gonads. In *Macaca fascicularis* the testis of the 41-day old fetus already has an albuginea distinguishing it from the ovary. This has also been shown in *Macaca mulatta* (Van Wageningen and Simpson, 1965).

The fetuses were weighed, measured and photographed after fixation in Bouin-Hollande with mercuric chloride.

Results.

Before 57 days, the external genital organs show no sexual differentiation. When the undifferentiated genital tubercle in the male or female assumes a postero-dorsal direction, it is above the uro-genital meatus, between two distinct swellings on the supero-internal surface of the thigh ; the ano-genital distance is about the same in both sexes.

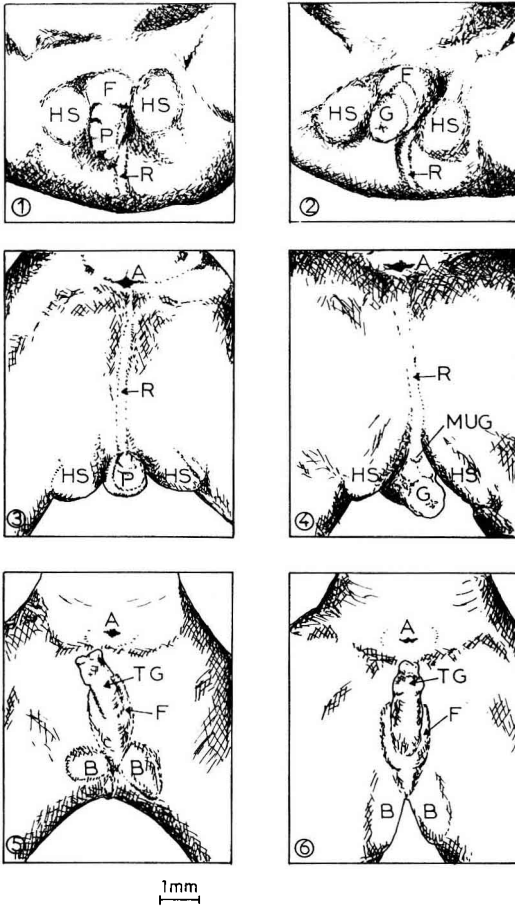


PLATE I. — *Morphology of the external genital apparatus at sexual differentiation.*

Drawings are done from photographs.

1. — 57-day fetus : anterior view.
2. — 62-day male fetus : anterior view.
3. — 57-day male fetus : posterior view.
4. — 62-day male fetus : posterior view.
5. — 58-day female fetus : posterior view
6. — 63-day female fetus : posterior view.

A : anus ; B : swelling ; F : sheath ; G : penile gland ; HS : hemiscrotum ; MUG : meatus urogenital ; P : penis ; R : ano-scrotal raphe ; TG : genital tubercle.

At 57 to 58 days there is a marked change in the male fetus ; the penis with its gland and basal « sheath » differentiates from the genital tubercle. It is located between two swellings which assume the ovoid shape of the hemiscrotum, and it tends to be directed forward. The ano-genital distance is greater than in the female ; it is indicated by a visible line prolonging the scrotal raphe. The thigh swellings in the female are elongated but not prominent, and remain under the genital tubercle which also has a basal « sheath ». The future clitoris retains its original postero-dorsal position. This morphology remains unchanged until 75 days (plate I).

Between 69 to 70 and 83 to 85 days of pregnancy, the following changes are observed in the male : fusion of the thigh swelling to form the scrotum which increases in volume ; complete closing of the uro-genital groove and formation of the prepuce. In the female, the vaginal opening is visible at 85 days, surrounded by the small lips from the « sheath » of the genital tubercle. Contrary to the human fetus, there are no large lips ; the thigh swellings visible at the previous stage remain in their original position and become the « sexual skin » in the adult female (plate II).

Discussion.

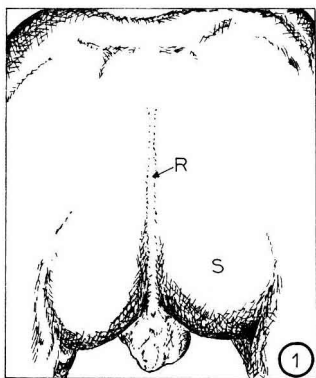
This study shows that the effect of fetal testis androgens on the developmental morphology of the external male genital apparatus appears at 57 days. In *Macaca fascicularis* an electron microscope study of the Leydig cells has shown that the interstitial cells have « steroidogenic » cell characteristics at 52 to 53 days, i. e. smooth endoplasmic reticulum and mitochondria with tubular cristae associated in operational areas, but that they only attain full maturity at 57 days (Fouquet, Dang and Meusy-Dessolle, 1978). Radioimmunological assay of plasma testosterone in the umbilical artery has also demonstrated a high level of this hormone at 57 days, the age of the youngest fetus from which umbilical arterial blood could be sampled (Dang and Meusy-Dessolle, unpublished results ; Resko *et al.*, 1973 in *Macaca mulatta*) ; it may be present earlier. We do not know the time lapse or the amount of this hormone necessary to induce morphological differentiation of the external male genital organs of the macaque. As recognized by the external morphology, this formation extends from day 57 to day 70 of pregnancy.

A comparison of the morphology of the external genital apparatus of the normal macaque fetus in this study with that of the female fetus of a mother treated with injected androgens (Van Wagenen and Hamilton, 1943 ; Wharton, 1966) indicates that at an undifferentiated stage, the genital tubercle, its basal « sheath », the thigh swellings

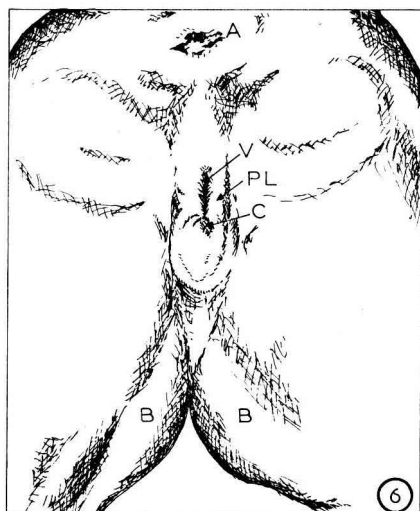
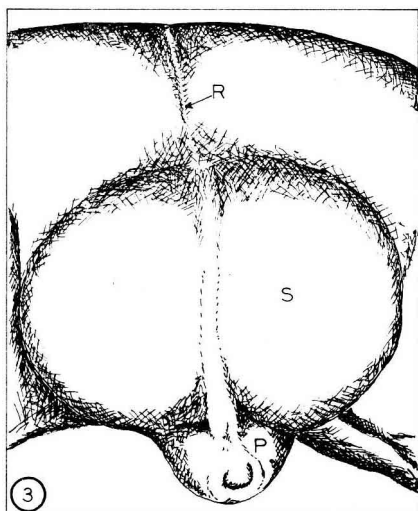
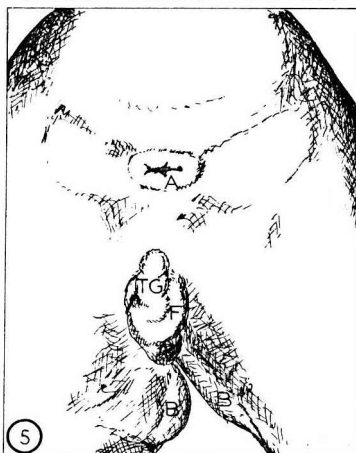
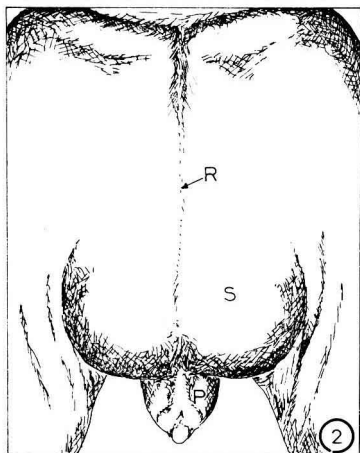
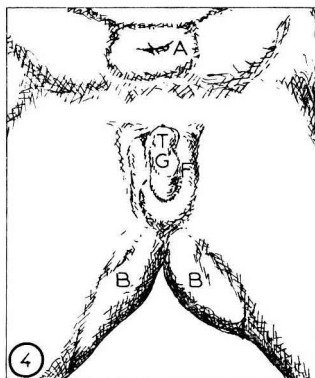
PLATE II. — *Posterior views of the genital region of fetuses between 69 to 70 and 83 to 85 days old.*

- | | |
|-------------------------|---------------------------|
| 1. — 70-day male fetus. | 4. — 69-day female fetus. |
| 2. — 75-day male fetus. | 5. — 75-day female fetus. |
| 3. — 83-day male fetus. | 6. — 85-day female fetus. |

A : anus ; B : swelling ; C : clitoris ; F : sheath ; P : penis ; PL : small lips ; R : ano-scrotal raphe ; S : scrotum ; TG : genital tubercle ; V : vaginal opening.



1mm



and the ano-genital distance are androgen-dependent structures, while androgens inhibit the formation of the vaginal opening. The morphology of the external genital organs of the fetus or newborn of genetic female sex may be more or less modified towards the male aspect, depending on exogenous androgen concentration and age at which the fetus is treated with these hormones. Dantchakoff (1950) injecting testosterone directly into the amniotic sac from days 20 to 30 of pregnancy, obtained genetically female fetuses at 3 1/2 months with fused scrotal sacs and a penis identical to that of a normal male with no vaginal opening.

In the normal female fetus, differentiation of the external genital organs occurs at about 85 days, and thus later than in the male fetus. The mechanism of female differentiation is still not understood.

In man, fetal formation of the external male genital apparatus is visible at 8 weeks of pregnancy and is finished at about week 10, while in the female fetus it is terminated at about 12 weeks (Tourneux, 1921). The chronology of the differentiation of external genital organs thus seems to be the same in macaque and man.

Reçu en octobre 1977.

Accepté en janvier 1978.

Acknowledgments. — This work was supported by the CNRS (LA 220) and the DGRST (contract N° 77-7-0671). We wish to thank Professors A. Delmas and C. Thibault for advice during this study. We also wish to thank Mr. M. Soudière for help with the photography.

Résumé. Les organes génitaux externes de 34 fœtus mâles et femelles de *Macaca fascicularis*, obtenus par césarienne et âgés exactement de 41 à 85 jours, ont été examinés. La différenciation de l'appareil génital externe mâle devient visible à 57 jours. A ce stade on peut voir le gland pénien, la gouttière uro-génitale en train de se fermer, les deux moitiés du scrotum séparées et l'allongement de la distance ano-génitale. A 75 jours, il a acquis une configuration rappelant celle du nouveau-né (planche I). Chez la femelle, ce n'est que vers 85 jours que la différenciation des organes génitaux externes est réalisée avec la présence de l'ouverture du vagin et du clitoris bordés des petites lèvres mais la vulve ne présente pas les grandes lèvres qui sont remplacées par les deux bourrelets de la « peau sexuelle » au niveau de la face supéro-interne des cuisses (planche II). La chronologie de la différenciation de l'appareil génital externe du macaque Crabier est très proche de celle de l'Homme.

References

- DANG D. C., 1977. Resumption of menstruation and fertility after cesarian in *Macaca fascicularis*. *Ann. Biol. anim. Bioch. Biophys.*, **17**, 325-329.
- DANTCHAKOFF V., 1947. La testostérone dans l'histogenèse sexuelle du Singe (*Macacus rhesus* Audeb.) : organes génitaux externes. *C. R. Acad. Sci. Paris*, **224**, 217-219.
- DANTCHAKOFF V., 1950. Sur les mécanismes différentiels dans la réalisation des sexes chez les vertébrés supérieurs (Singe, *Macacus rhesus*). *Bull. Biol.*, **84**, 311-340.
- FOUQUET J.-P., DANG D. C., MEUSY N., 1978. Differentiation of Leydig cells in the testis of the fetal monkey (*Macaca fascicularis*) (submitted to publication).
- GOY R. W., RESKO J. A., 1972. Gonadal hormones and behavior of normal and pseudohermaphroditic non-human female primates. *Recent Progr. Horm. Res.*, **28**, 707-733.

- JOST A., 1947. Recherches sur la différenciation sexuelle de l'embryon de Lapin. III : Rôle des gonades fœtales dans la différenciation somatique. *Arch. Anat. micr. Morphol. expér.*, **36**, 271-316.
- JOST A., 1969. Modalities in the action of androgens on the foetus. *Res. Steroids*, **3**, 207-220.
- JOST A., 1970. Hormonal factors in the development of the male genital system, 11-18. In ROSENBERG E., PAULSEN C. A., *The human testis*. Plenum Press, N. Y.
- MAROIS G., 1968. Action de la progestérone, de la testostérone et de l'œstradiol sur la distance anogénitale et sur la différenciation sexuelle somatique du rat. *Biol. Méd.*, **57**, 44-90.
- PRICE D., ZAAIZER J. J. P., ORTIZ E., BRINKMANN A. O., 1975. Current views on embryonic sex differentiation in reptiles, birds and mammals. *Amer. Zool.*, **15**, (suppl. 1), 173-195.
- RAYNAUD A., 1969. Les organes génitaux des mammifères, 149-636. In GRASSÉ P. P., *Traité de zoologie*, t. **16**, fasc. VI, Masson and Cie, Paris.
- RAYNAUD A., FRILLEY M., 1947. Effets sur le développement du tractus génital des embryons de souris, de la destruction des ébauches de leurs glandes génitales par irradiation au moyen des rayons X, à l'âge de 13 jours. *C. R. Soc. Biol.*, **141**, 1134.
- RESKO J. A., MALLEY A., BEGLEY D., HESS D. L., 1973. Radioimmunoassay of testosterone during fetal development of the Rhesus monkey. *Endocrinology*, **93**, 156-161.
- STOLL R., MARAUD R., 1974. Le rôle du testicule dans la différenciation sexuelle des gonoductes chez l'embryon des vertébrés amniotes. *Bull. Ass. Anat.*, **58**, 699-764.
- TOURNEUX, 1921. *Précis d'embryologie humaine*. 3^e éd., Doin G., Paris.
- VAN WAGENEN G., SIMPSON M. E., 1965. *Embryology of the ovary and testis*, Homo sapiens and *Macaca mulatta*. Yale Univ. Press, New-Haven and London.
- WELLS L. J., VAN WAGENEN G., 1949. Observations on the reproductive organs of monkeys with induced female pseudohermaphroditism. *Anat. Rec.*, **103**, 587.
- WHARTON L. R., 1966. The effect of sex steroids on the development of the reproductive tract of *Macaca mulatta*. *Excerpta med. int. Congr. Ser.* N° 3, 178.
- VAN WAGENEN G., HAMILTON J. B., 1943. The experimental production of pseudohermaphroditism in the monkey, 581-607. COWLES T., In *Essays in biology, in honor of Herbert M. EVANS*. Berkeley, Los Angeles.
-