



HAL
open science

Survival of honey bee (*Apis mellifera*) pupae after trypan blue staining of wounds caused by *Varroa destructor* mites or artificial perforation

Matthias Herrmann, Ghazwan Kanbar, Wolf Engels

► To cite this version:

Matthias Herrmann, Ghazwan Kanbar, Wolf Engels. Survival of honey bee (*Apis mellifera*) pupae after trypan blue staining of wounds caused by *Varroa destructor* mites or artificial perforation. *Apidologie*, 2005, 36 (1), pp.107-111. hal-00892121

HAL Id: hal-00892121

<https://hal.science/hal-00892121>

Submitted on 11 May 2020

HAL is a multi-disciplinary open access archive for the deposit and dissemination of scientific research documents, whether they are published or not. The documents may come from teaching and research institutions in France or abroad, or from public or private research centers.

L'archive ouverte pluridisciplinaire **HAL**, est destinée au dépôt et à la diffusion de documents scientifiques de niveau recherche, publiés ou non, émanant des établissements d'enseignement et de recherche français ou étrangers, des laboratoires publics ou privés.

Survival of honey bee (*Apis mellifera*) pupae after trypan blue staining of wounds caused by *Varroa destructor* mites or artificial perforation¹

Matthias HERRMANN*, Ghazwan KANBAR, Wolf ENGELS

Zoologisches Institut der Universität Tübingen, Auf der Morgenstelle 28, 72076 Tübingen, Germany

Received 8 December 2003 – Revised 30 June 2004 – Accepted 9 September 2004

Published online 16 March 2005

Abstract – The recently described technique of vital staining with trypan blue to visualise pupal wounds of honey bees, originating from punctures made by *Varroa destructor* mites, was applied to artificial perforations performed with a fine needle. The stained pupae were subsequently reared in vitro until eclosion of the adult bees. Their mortality was recorded daily. The survival of the treated pupae was only moderately affected by the staining procedure. No obvious toxic effects caused by the compound trypan blue were observed. The process of wound healing was normal. Pupae with previously trypan blue stained integumental wounds can therefore be used for long lasting experiments. This is of particular interest for future studies on the assumed vector function of *Varroa* mites in the transfer of bacterial and viral pathogens in honey bee diseases.

Apis mellifera / *Varroa destructor* / pupal wounds / vital staining / trypan blue / survival

1. INTRODUCTION

The only diet of the parasitic mite *Varroa destructor* Anderson & Trueman is haemolymph of its host, the honey bee. During reproduction in capped bee brood cells (Ifantidis and Rosenkranz, 1988), female mites perforate the integument of the late larval and pupal host for blood sucking (Donzé and Guerin, 1994). The wounds are used repeatedly as feeding sites by the mother mite and her progeny (Donzé and Guerin, 1997). The resulting hazard to the bee through loss of haemolymph is related to the level of infestation of the brood cell (Schatton-Gadelmaier and Engels, 1988; Duay et al., 2003). In the original host, the Asian species *Apis cerana* Fabr., this will not cause colony damage (Rath, 1999), but in the new host, the western honey bee, *Apis mellifera*

L., the colony will finally collapse (Matheson, 1993). The rapid breakdown of the colony is often accompanied by bacterial and viral diseases (Martin, 2001). *Varroa* mites are assumed to act as vectors in the transfer of the respective micropathogens. Hygienic behaviour of the colony is regarded as an important factor in the tolerance of bees to the mites (Spivak and Gilliam, 1998).

To analyse problems of pathogen transmission, the puncture wounds by the female mites into the integument of the host bee have to be studied. In such openings of the protecting cuticle, cultures of bacteria may be found (Kanbar and Engels, 2003). Because the tiny perforations of the body wall are not easy to detect on a bee pupa, we developed a technique of vital staining with trypan blue by

* Corresponding author: matthias.herrmann@tuebingen.mpg.de

¹ Manuscript editor: Stefan Fuchs

which the wounds can be visualised (Kanbar and Engels, 2004a). In subsequent observations of the infested pupae, any influence of the vital staining on the vitality of the pupa has to be considered. Furthermore, trypan blue as a toxic compound (Falbe and Regitz, 1995) could affect the survival of the bee. Since integumental perforations normally scar towards the end of the pupal phase (Kanbar and Engels, 2003), we also wanted to know whether this healing process is influenced by a preceding staining procedure.

To study sufficient numbers of bees under standard conditions, we made artificial wounds by perforating the pupal integument with a fine needle. In comparison, pupae with wounds caused by *Varroa* mites were studied. We analysed the effect of staining with trypan blue by cultivating the treated pupae in vitro until eclosion of the adult bee.

2. MATERIALS AND METHODS

Brood combs were removed from colonies of *Apis mellifera* in the apiary of the University of Tübingen. Capped worker and drone brood cells were inspected and pupae with white, red and brown eyes were used for the experiments. The pupae from cells infested with *Varroa* mites were separated from uninfested brood. The uninfested brood was used for experimental perforation and as controls. Artificial punctures were performed 0.3 mm deep with sterilised minute needles ϕ 50 μ m. The pupae were perforated at sites also punctured by female mites, the thorax and in particular the 2nd abdominal sternite (Kanbar and Engels, 2004b). Vital staining with 0.01% trypan blue solution in insect ringer (5.0 g NaCl, 0.42 g KCl, 0.25 g CaCl₂ in 1 L of distilled water adjusted to pH 6.8 with 0.1 molar KOH) was performed for 30 min at 35 °C, followed by rinsing the pupae in ringer (modified after Kanbar and Engels, 2004a). Parasitised pupae with *Varroa*-made perforations as well as uninfested and non-punctured pupae also were stained. Controls were subjected to the same treatment but without the vital staining. The whole procedure was performed in microtiter trays. Subsequently the pupae were kept in petri dishes and incubated in the lab at 35.5 °C and 80% humidity until adult eclosion. Mortality was recorded daily. The mean rates of survival in stained and unstained pupae were compared using the Levine test (Excel Statistics, 2004). Because the trypan blue staining influenced the survival of the pupae only slightly, we used pooled data of several experiments for the figures. Photomicrographs were taken with a scanning

electron microscope (Cambridge Instruments Stereoscan 250 Mk.II) using standard protocols (Kanbar and Engels, 2003).

3. RESULTS

3.1. Effect of puncturing and vital staining on survival of pupae in vitro

Untreated pupae reared in vitro all survived until adult eclosion (Fig. 1A). Artificial puncturing led to an average mortality of slightly over 15%, which was significantly different than the controls ($P = 0.027$). After trypan blue vital staining these rates did not increase significantly ($P = 0.36$).

The rate of pupal mortality depended on the pupal age at the experimental puncturing. In unstained controls the mortality of white-eyed pupae was two times higher than that of brown-eyed individuals. The younger pupae were significantly more injured by the puncture ($P = 0.021$). In brown eyed pupae, trypan blue staining increased the mortality only insignificantly by about 5% (Fig. 1B).

Mortality was only insignificantly increased in the males compared to workers ($P = 0.14$), in stained as well as in unstained individuals (Fig. 1C).

The site of puncturing also affected the rate of survival. Perforations of the thorax were less hazardous than of the abdomen ($P = 0.09$). In both locations the vital staining increased the mortality only slightly (Fig. 1D).

Therefore, in all these experiments with artificial perforations no statistically significant differences in mortality were observed between trypan blue vital stained and unstained pupae ($P = 0.36 - 0.16$).

3.2. Comparison of natural and artificial perforations

Wounds originating from *Varroa* females in naturally infested brood cells caused only insignificantly higher mortality than artificial punctures ($P = 0.44$). Trypan blue vital staining increased both rates by about 6% (Fig. 1E).

The healing of integumental wounds also occurred by an apparently identical process in artificially set punctures as in perforations

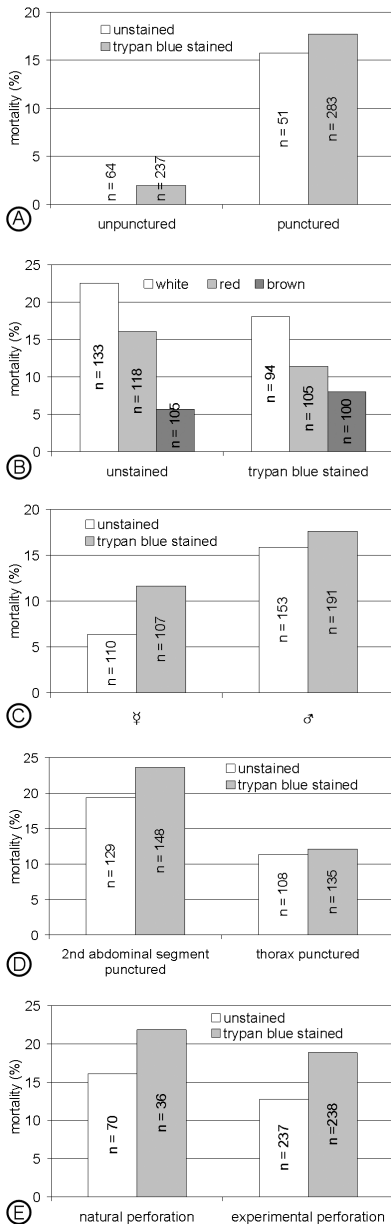


Figure 1. Effect of vital staining with trypan blue on survival of honey bee pupae. After visualisation of the artificially punctured wounds by this procedure, the pupae were reared in vitro until adult eclosion. The total mortality until eclosion was calculated. A data of worker and drone pupa of all stages combined. B different eye colour stages. C worker and drone pupae. D pupae artificially punctured at different sites, corresponding to *Varroa*-made perforations. E worker pupae with wounds on the 2nd abdominal sternite, caused by *Varroa* females, in comparison to artificially made punctures.

made by *Varroa* mites. The vital staining of such wounds with trypan blue did not have a negative influence on the formation of scar tissue, as seen in SEM micrographs (Fig. 2).

4. DISCUSSION

4.1. Factors affecting pupal survival in vitro

To evaluate the effect of trypan blue vital staining on vitality of honey bee pupae, the influence of other factors, including the in vitro culture conditions, has to be analysed. The duration of the experimental handling of the pupae outside the hive is evidently not a critical factor but has to be considered. We observed a somewhat higher mortality if young white eyed pupae were removed from the capped brood cells. The slightly increased susceptibility of drones in comparison to workers might also be caused by the longer duration of the pupal phase in males.

The artificial puncturing of the pupal integument induced some mortality regardless the stage of development and the type of the pupae. However, the position of the experimental perforation had an additional effect. Wounding of the thorax was less hazardous than piercing the ventral side of the abdomen. Perhaps the thoracic muscles were not as much harmed as the internal organs of the abdomen, because a large haemocoel is located under the first sternites. Of note is that *Varroa* mites puncture the bee pupae preferentially on the 2nd abdominal sternite (Kanbar and Engels, 2004b).

4.2. *Varroa*-made versus needle punctured wounds

To our surprise, the rate of survival of wounded pupae was higher in the experimentally perforated specimens than in those infested by female mites. Several reasons might be responsible for this result. First of all, we used sterilised steel needles to puncture the pupae. This was done to prevent any microbial infection. In fact we never observed the development of bacterial colonies in the artificially produced pupal wounds, a common aspect in *Varroa*-caused perforations (Kanbar and Engels, 2003). Furthermore, the experimentally made wounds were allowed to subsequently heal,

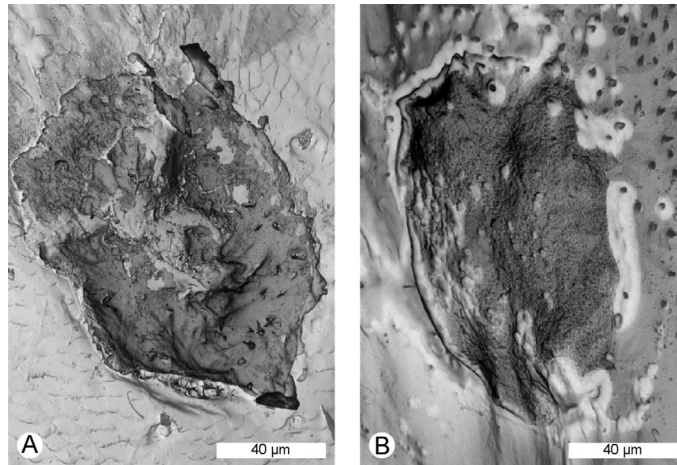


Figure 2. SEM micrographs of integumental wounds on the 2nd abdominal sternite of drone pupae. The perforations were made in recently moulted white pupae which subsequently were vital stained with trypan blue. When 20–21 days old, the wounds are closed with dark scars. A = punctured by a female *Varroa* mite, B = artificial puncture with a fine needle. There is no difference visible in the wound healing process.

whereas at least under natural conditions in the sealed brood cell, the perforations are used repeatedly by the mites for sucking of haemolymph (Donzé and Guerin, 1994) by which the scar forming process is delayed until prior to the adult eclosion of the host bee (Kanbar and Engels, 2003). This situation presumably allows the transfer of pathogens from the mite to the pupal bee (Kanbar and Engels, 2004b).

4.3. Low impact of trypan blue vital staining on pupal vitality

The overall reduction in vitality recorded after trypan blue staining of honey bee pupae was age dependent. The increase in mortality of about 5% or less was observed in specimens with any type of perforation and also in the controls without integumental lesions. At least the application of trypan blue in 0.01% solution according to the vital staining protocol (Kanbar and Engels, 2004a) apparently has no severe toxic effect (Falbe and Regitz, 1995). As shown by our SEM micrographs, the stained wounds scarred normally. In contrast to this low impact of the staining procedure, pupal wounds significantly increased mortality. Artificial puncturing of unstained controls increased mortality by 15%.

Trypan blue vital staining to visualise integumental wounds in pupal honey bees can

therefore be recommended also for use in subsequent investigations. As most of the stained pupae will survive, studies with *Varroa*-punctured individuals, and with immatures who received injections for any purpose, can be carried out. One possible application is the administration of hormones in the analysis of caste and sex development during bee metamorphosis (Hartfelder and Engels, 1998). These circumstances will likewise be of practical importance in studies on the role of *Varroa* mites as vectors for bacterial and especially for viral diseases of the honey bee which are actually spreading world wide (Brødsgaard et al., 2000) and have become a new threat to bee-keeping (Ball, 1997).

ACKNOWLEDGEMENTS

We like to thank Imkermeister Andreas Oelkrup for keeping of the bee colonies and Wolfram Engels for help with the experiments, in the data analyses and for preparation of the figures.

Résumé – Taux de survie des nymphes d’abeilles domestiques (*Apis mellifera*) après coloration vitale au bleu de trypane des blessures occasionnées par des piqûres d’acariens (*Varroa destructor*) ou des piqûres artificielles. La méthode brièvement décrite, qui consiste à rendre visibles les blessures dues aux piqûres faites par *Varroa destructor* par une coloration vitale au bleu de trypane, a été

appliquée pour colorer des piqûres faites avec une fine aiguille. Les nymphes ainsi colorées ont été élevées *in vitro* jusqu'à la mue imaginale. La mortalité a été enregistrée quotidiennement. La survie des nymphes ainsi traitées n'a été que peu influencée par la coloration. Tous les essais qui ont porté sur divers stades de développement des nymphes d'ouvrières ou de mâles ont donné le même résultat (Figs. 1A–4D). Le bleu de trypane n'a provoqué tout au plus que de légers effets toxiques. Les blessures de piqûres artificielles ont entraîné une mortalité plus faible que les lésions causées par les piqûres d'acariens (Fig. 1E). Le processus de guérison de la blessure s'est déroulé normalement (Fig. 2). Les nymphes avec les blessures colorées au bleu de trypane ont donc pu être utilisées pour des expériences de plus longue durée. Ceci est intéressant pour de futures études sur les fonctions de vecteur de *V. destructor* lors de la transmission de maladies bactériennes ou virales, étant donnée l'augmentation de la fréquence de ces maladies à l'échelle mondiale.

***Apis mellifera* / *Varroa destructor* / coloration vitale / bleu de trypane / blessure / taux de survie / nymphe**

Zusammenfassung – Überlebensrate von Puppen der Honigbiene (*Apis mellifera*) nach Vitalfärbung mit Trypanblau von Wunden, die von Milben (*Varroa destructor*) oder künstlichem Anstechen herrühren. Die kürzlich beschriebene Methode, von *Varroa destructor* herrührende Stichwunden mit einer Trypanblau-Vitalfärbung sichtbar zu machen, wurde hier angewendet, um künstlich mit einer feinen Nadel gesetzte Perforierungen anzufärben. Anschließend wurden die so angefärbten Puppen *in vitro* bis zur Häutung adulter Bienen aufgezogen. Täglich wurde kontrolliert, ob Puppen abstarben. Das Überleben der so behandelten Puppen wurde durch die Anfärbung allerdings nur wenig beeinträchtigt. Dies ergaben übereinstimmend alle Versuche mit Arbeiterinnen- und Drohnenpuppen verschiedener Stadien (Abb. 1A–D). Das giftige Trypanblau verursachte höchstens leichte toxische Effekte. Künstliche Stichwunden bewirkten eine geringere Mortalität als die von Milbenstichen verursachten Verletzungen (Abb. 1E). Auch der Vorgang der Wundheilung verlief normal (Abb. 2). Puppen mit zuvor Trypanblaugefärbten Hautwunden können daher auch für länger dauernde Versuche verwendet werden. Dies ist für künftige Studien über Vektor-Funktionen von *Varroa*-Milben bei der Übertragung bakterieller und viraler Pathogene von Interesse. Entsprechende Erkrankungen werden mit zunehmender Häufigkeit weltweit in den Honigbienen-Populationen registriert.

***Apis mellifera* / *Varroa destructor* / Stichwunden bei Puppen / Vitalfärbung / Trypanblau / Überlebensrate**

REFERENCES

- Ball B.V. (1997) Secondary infections and diseases associated with *Varroa jacobsoni*, Opt. Méditerr. 21, 49–58.
- Brødsgaard C.J., Ritter W., Hansen H., Brødsgaard H.F. (2000) Interactions among *Varroa jacobsoni* mites, acute paralysis virus, and *Paenobacillus larvae* larvae and their influence on mortality of larval honeybees *in vitro*, Apidologie 31, 543–554.
- Donzé G., Guerin P.M. (1994) Behavioral attributes and parental care of *Varroa* mites parasitizing honey bee brood, Behav. Ecol. Sociobiol. 34, 305–319.
- Donzé G., Guerin P.M. (1997) Time-activity budgets and spacing structure by the different life stages of *Varroa jacobsoni* in capped brood of the honey bee, *Apis mellifera*, J. Insect Behav. 10, 371–393.
- Duay P., De Jong D., Engels W. (2003) Weight loss in drone pupae (*Apis mellifera*) multiple infested by *Varroa destructor* mites, Apidologie 34, 61–65.
- Excel Statistics (2004) <http://www.mathtools.net/Excel/Statistics/> (checked on 7 December 2004).
- Falbe J., Regitz M. (1995) Römpp Chemie-Lexikon, 9th ed., Vol. 5.
- Hartfelder K., Engels W. (1998) Social insect polymorphism – hormonal regulation of plasticity in development and reproduction in the honey bee, Curr. Top. Dev. Biol. 40, 45–77.
- Ifantidis M.D., Rosenkranz P. (1988) Reproduktion der Bienenmilbe *Varroa jacobsoni* (Acarina: Varroidae), Entomol. Gen. 14, 111–122.
- Kanbar G., Engels W. (2003) Ultrastructure and bacterial infection of wounds in honey bee (*Apis mellifera*) pupae punctured by *Varroa* mites, Parasitol. Res. 90, 349–354.
- Kanbar G., Engels W. (2004a) Visualisation by vital staining with trypan blue of wounds punctured by *Varroa destructor* mites in pupae of the honey bee (*Apis mellifera*), Apidologie 35, 25–29.
- Kanbar G., Engels W. (2004b) Number and position of wounds on honey bee (*Apis mellifera*) pupae infested by a single *Varroa* mite, Eur. J. Entomol. 101, 323–326.
- Matheson A. (1993) World bee health report, Bee World 74, 176–212.
- Martin S.J. (2001) The role of *Varroa* and viral pathogens in the collapse of honeybee colonies: a modelling approach, Exp. Appl. Acarol. 25, 321–325.
- Rath H.W. (1999) Co-adaptation of *Apis cerana* Fabr. and *Varroa jacobsoni* Oud., Apidologie 30, 97–110.
- Schatton-Gadelmayer K., Engels W. (1988) Hämolympheproteine und Körpergewicht frischgeschlüpfter Bienen-Arbeiterinnen nach unterschiedlich starker Parasitierung durch Brutmilben (Hymenoptera: Apidae: *Apis mellifera* / Acarina: Varroidae: *Varroa jacobsoni*), Entomol. Gen. 14, 93–101.
- Spivak M., Gilliam M. (1998) Hygienic behavior of honey bees and its application for control of brood diseases an *Varroa*, Bee World 79, 124–134; 169–186.