



**HAL**  
open science

## In vivo studies on goose liver development by means of computer tomography

László Locsmándi, Róbert Romvári, Ferenc Bogenfürst, András Szabó,  
Marcell Molnár, Gabriella Andrásy-Baka, Péter Horn

### ► To cite this version:

László Locsmándi, Róbert Romvári, Ferenc Bogenfürst, András Szabó, Marcell Molnár, et al.. In vivo studies on goose liver development by means of computer tomography. *Animal Research*, 2005, 54 (2), pp.135-145. hal-00890032

**HAL Id: hal-00890032**

**<https://hal.science/hal-00890032v1>**

Submitted on 11 May 2020

**HAL** is a multi-disciplinary open access archive for the deposit and dissemination of scientific research documents, whether they are published or not. The documents may come from teaching and research institutions in France or abroad, or from public or private research centers.

L'archive ouverte pluridisciplinaire **HAL**, est destinée au dépôt et à la diffusion de documents scientifiques de niveau recherche, publiés ou non, émanant des établissements d'enseignement et de recherche français ou étrangers, des laboratoires publics ou privés.

## In vivo studies on goose liver development by means of computer tomography

László LOCSMÁNDI, Róbert ROMVÁRI\*, Ferenc BOGENFÜRST, András SZABÓ, Marcell MOLNÁR, Gabriella ANDRÁSSY-BAKA, Péter HORN

University of Kaposvár, Faculty of Animal Science, 7400 Kaposvár, Guba Sándor 40, Hungary

(Received 9 July 2004; accepted 18 November 2004)

**Abstract** – Commercial geese (Gray Landes) were examined by means of high-resolution spiral computer tomography in order to follow their liver development in vivo. Three ganders were scanned six times before, within and after a force-feeding period. 3D images of the liver were reconstructed from the 2D transverse slices with segmentation and rendering methods. The changes in the external surface, the volume of the liver and also the characteristic Hounsfield values were determined. The livers of another 70 ganders were examined by CT, then by direct chemical analysis (days 0, 13, 18, 19, 20 and 21 of force-feeding). To estimate the chemical composition of the tissue, prediction equations were developed based on the pixel frequency distributions. With partial least squares (PLS) regression, the ether extract and crude protein content could be estimated with  $R^2 = 0.97$  and  $R^2 = 0.96$  accuracy, respectively. Data analysis was complemented with serial blood serum measurements characteristic of liver steatosis. The method applied may be a unique possibility to study the real geometrical relations of liver development and also to describe the qualitative changes of tissue composition during the force-feeding period in vivo, with special regards to selection purposes.

**goose liver / computerized tomography / liver yield / liver composition**

**Résumé** – **Études in vivo du développement du foie d'oie par tomographie.** Le développement du foie des oies (Landaise grise) a été examiné « in vivo » par tomographie spirale à haute résolution (CT). Les coupes ont été préparées sur six jours différents, avant, pendant et après le gavage, sur trois jars. Les images en trois dimensions (3D) ont été reconstituées à partir des images en 2D, par l'ajustement selon la méthode d'ajustement par segments. La modification de la surface externe et du volume du foie ont été définies par les valeurs Hounsfield. Outre les foies des trois jars, 70 jars ont été encore examinés par la même méthode (CT), ensuite des analyses chimiques directes ont été réalisées aux jours 0, 13, 18, 19, 20 et 21 du gavage. La composition chimique du foie a été estimée par la création d'équations de régression en fonction de la division de fréquence des pixels. À l'aide d'équations des moindres carrés la teneur en graisse et en protéines du foie ont été prédites avec une bonne précision ( $R^2 = 0,97$  et  $0,90$ , respectivement). L'analyse du développement de la stéatose hépatique a été complétée par la mesure des caractéristiques sanguines. La méthode de tomographie

---

\* Corresponding author: romvari.robert@freemail.hu

« in vivo » donne la possibilité unique de caractériser les corrélations géométriques réelles au cours du développement du foie et de décrire les modifications qualitatives dans la composition du tissu pendant l'engraissement par gavage. Cette méthode pourrait être utilisée en sélection.

## **foie gras / oie / tomographie / rendement / composition**

### **1. INTRODUCTION**

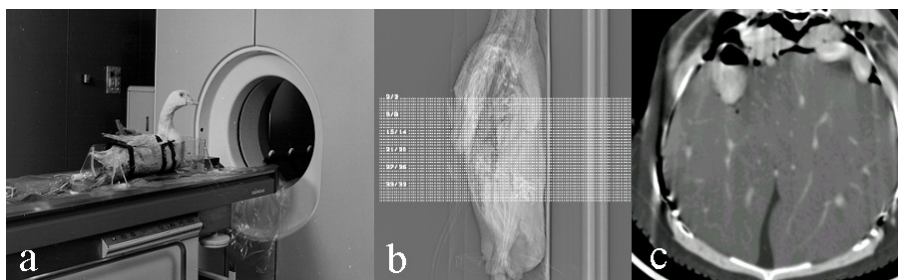
One of the main objectives of goose breeders is to maximize the accessible liver volume during the force-feeding period and also to keep its fat content at an optimum level for the processing industry and consumers. Under natural conditions some degree of hepatic steatosis occurs in wild waterfowl, as a consequence of energy storage before migration. In poultry production, this specific capacity is used for the production of commercial fatty liver. The excess of triglycerides is normally stored in the cytoplasmic storage vesicles of the liver. When overproduction of triglycerides occurs, which is the case during force-feeding, the liver responds in two ways: triglycerides are secreted into plasma as VLDL increases and since force-feeding does not allow the birds to fast, the liver continues to accumulate triglycerides [20]. It is well known that geese breeds differ in their susceptibility to liver steatosis, considering that the response to force-feeding is partly under genetic control [11]. According to Rouvier et al. [19] the direct genetic effects due to autosomal and sex linked genes were high and positive for fatty liver weight in selected strains of geese. It is notable that the liver weight could be increased by selection without a great effect on "paletot" weight as Larzul et al. [13] established. The Landes goose – used in the present study – is among the best in response to overfeeding as described by Mourot et al. [15]. To a certain extent the high susceptibility of the breed is explainable by the high activity of malic enzyme and also by the fact that hepatic lipogenesis remains very active until the end of the over-feeding period in order to improve the quality and quantity of the liver.

At present our experiments are partly focused on the preliminary step (preparation) of force-feeding and the development of new, non invasive, in vivo, CT imaging based selection methods for liver yield [4]. With special regards to the expectable severity in fatty liver production, the improvement of the so-called force-feeding free methods seems to be reasonable in the near future. These developing methods are based on voluntary feed intake that is improved by the limited time to access the feed.

Conventionally, the lipid content of the liver can be measured by direct chemical analysis. According to Guy [10], the total lipid content of the fatty goose liver is around 50–55%. Storage lipids are predominant, with 95% triglycerides and 1–2% cholesteryl esters. Structural (membrane) lipids, such as phospholipids and free cholesterol, account for only 1–2 and <1%, respectively [9]. Force-feeding induces a large hypertrophy of hepatic cells in relation to the accumulation of triglycerides. Reaching high liver weights, geese provide good technological liver quality with a fat loss limited to 13.9% during autoclaving, as established by Guy [10].

In studies with chickens [2] and turkeys [3, 6] it has been shown that computer tomography (CT) is a suitable non-invasive technique to measure the volume or mass of the pectoralis muscle and abdominal fat permitting single or repetitive measurements. Romvári et al. [17] published a new in vivo 3D method to estimate the volume or yield and the geometrical conformation of the breast muscle of broiler chickens by computer tomography.

In the present study different in vivo CT methods were applied to follow the liver morphologic development of geese and to



**Figure 1.** Fixed goose in the container (a), side taken topogram (b), cross section of the liver (c).

analyze the changes in the liver composition during the force-feeding period.

## 2. MATERIALS AND METHODS

### 2.1. Animals

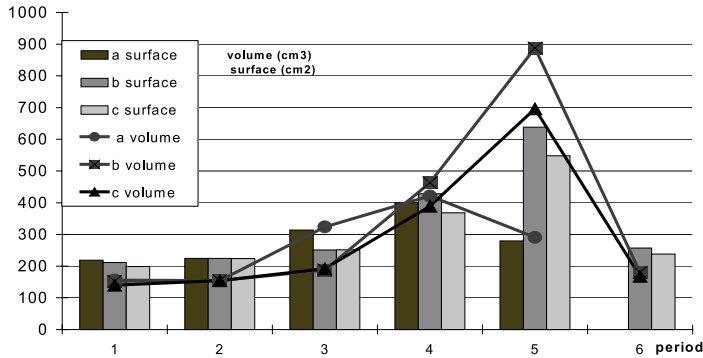
In the first methodological experiment commercial type Landes ganders were examined at 11, 15, 16, 17, 18, 20 weeks of age, four weeks before (period 1), within (periods 2–5) and two weeks after (6) the force-feeding period. The three repeatedly examined animals (A, B, C) were selected from a larger population representing the average weight at a given age. In the second trial altogether 70 ganders were scanned at the end of the preparation period, at 13, 18, 19, 20, 21 and 22 days of the force-feeding period. The rearing conditions and the nutrition procedure corresponded to the common intensive management technology widely practiced in Hungary. A commercial pelleted goose feed (3.01 g EE (ether extract)·100 g<sup>-1</sup> DM, 21.72 g CP·100 g<sup>-1</sup> DM, 6.09 g C Ash·100 g<sup>-1</sup> DM, ME: 11.2 MJ·kg<sup>-1</sup>) was fed ad libitum. The force-feeding diet contained 4.91 g EE·100 g<sup>-1</sup> DM, 12.78 g CP·100 g<sup>-1</sup> DM, 2.33 g C Ash·100 g<sup>-1</sup> DM and 12.4 MJ·kg<sup>-1</sup> ME. A so-called preparation period was started twenty-eight days before force-feeding. During that interval, the total daily feeding time was decreased continuously. At the end of the preparation period, birds only had access to feed for 30 minutes, two times per day. Later on, as

a result of this technological process, the geese were able to consume the sufficient amount of feed for fatty liver production.

### 2.2. CT procedure

The ganders were scanned in vivo by means of a Siemens Somatom Plus S40 spiral CT scanner at the Institute of Diagnostic and Oncological Radiation of the Kaposvár University. The high resolution CT scans were taken from the geese using a zoom factor of 3.4. During the examination, the animals were fixed with belts in a plastic cradle without using anaesthetics (Fig. 1). In the methodological experiment depending on the size of the birds, 25 to 40 pictures – with five mm slice thickness covering the whole region of the liver – were acquired.

The picture-forming pixels (512 × 512 in a single slice, 0.98 × 0.98 mm area of each) are in fact small prisms with a definite volume (pixel area multiplied by the slice thickness, i.e. 5 or 10 mm) and are called voxels. Each pixel or voxel is characterized by a defined X-ray density value (expressed in Hounsfield Units). We are able, therefore, to determine the part of the total volume of the examined scan that falls into the Hounsfield (HU) interval of interest [12]. Two picture evaluation methods were applied. As a first approach the liver surface and volume data were determined from the series of cross sectional images. In parallel to this, the mean and also the most frequent Hounsfield values of the liver tissue were measured. In addition, a special imaging process



**Figure 2.** Changes of the liver total surface and volume during the force-feeding and in the post-feeding period (animals a, b, c).

was applied to handle the 2D slices, and a segmentation method was used to generate the boundary data. Finally surface rendering was undertaken to obtain a real 3D view of the liver.

In the second experiment, the serial scans of the liver were taken with 10 mm thickness. The post processing of the images was based on the frequency distribution of the voxels. In the present work, the extreme density values were excluded and only those corresponding to the liver were retained, i.e. the range from  $-80$  to  $+100$  on the Hounsfield scale (water = 0).

### 2.3. Blood samples and chemical analysis

In the second experiment at every scanning event, blood samples were drawn from *v. brachialis*. Blood was allowed to clot at room temperature and serum was centrifuged on 5500 rpm for 10 minutes. Serum metabolite (triglyceride, total and HDL cholesterol, inorganic phosphorus, total protein, albumin, uric acid, total bilirubin) concentrations and enzyme activity (lactate dehydrogenase,  $\gamma$ -glutamyl transpeptidase) values were determined on a Konelab 20i automatic equipment, using Konelab reagent kits. Immediately after the CT examination, experimental slaughter was performed after

electrical stunning; EE and CP content of the liver were determined by direct chemical analysis [1].


### 2.4. Data processing and statistical methods

Based on the similarity of the X-ray frequency distribution diagrams with the absorption spectra [7] Partial Least Squares (PLS) regression was applied to diminish the multi-co-linearity of the neighboring HU values (HU<sub>v</sub>) [14]. The principal components (PC) were calculated from the HU variables of the liver tissue. Prediction equations were developed by linear regression from the previously calculated principal components or factors.

## 3. RESULTS AND DISCUSSION

### 3.1. Methodological experiment

There was no negative effect of the repeated CT scanning on liver development, since the final liver volume at the end of force-feeding (period 5) was similar to the rest of the geese from the original stock in the methodological experiment. Substantial changes were observed in the liver volume and surface area within the examined period (Fig. 2).



**Figure 3.** 3D reconstruction of a goose liver during force-feeding (1–5) and two weeks after stopping force-feeding (6).

At the time of preparation (period 1) and the beginning of force-feeding (period 2), the measured values were similar. At the end of the 21-day period (5), the volume data became three times higher compared to the starting point. Two weeks later, as a consequence of feed withdrawal, the birds B and C reached their starting weight. A similar observation was made by Prehn [16] monitoring the fate of birds, which returned to basic conditions within approximately four weeks after reaching the terminal stage of force-feeding. After the early rapid increase (period 3), the A bird showed a fall-back in liver tissue development (period 5) probably caused by its individual susceptibility to force-feeding, which resulted in fatal gastro enteritis.

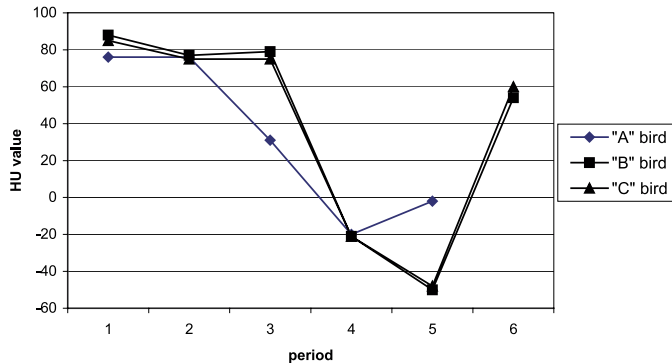
Quantitative changes of the liver were demonstrated by creating index values from the surface and the volume data. Index values (liver surface / liver volume) give information about the liver surface falling on one liver volume unit. At the time of preparation (period 1) and the beginning of force-feeding (period 2) the estimated values were similar. Fast cross development of the liver of the B and the C bird was observed from the beginning of the force-feeding period to the end of the 21st day (2–5 period). Index values were about 1.4 and 0.7 at periods 2 and 5, respectively. The liver substance became more compact. The birds marked B

and C were investigated after the force-feeding period (5–6 period) for the regenerative capacity of the pathologically developed liver. According to the values (1.43 and 1.41), the liver substance restored its normal physiological condition within two weeks.

The 3D reconstruction in Figure 3 shows the real in vivo anatomic characteristics of the lobes of a liver (B bird) from a lateral view. This is not examinable by means of slaughtering, caused by the loss of the original geometrical conformation of the organ. It can be remarked that the geometry of the post preparation (period 2) and post force-fed (period 6) states are very similar proving the reversibility of the process. The large proportional changes of the liver tissue within the force-feeding period (3, 4, 5) are also perceptible in the figure.

In addition to the quantitative and morphological evaluations, a certain qualitative analysis of the liver was also performed. The goose liver tissue has a characteristic (the most frequent HU value) X-ray density value (around 80 HU) in its normal, physiological status. Substantial changes can be seen in Figure 4, in the HU values throughout the period.

Similarly with the geometrical and volumetric changes the measured density values sensitively follow the force-feeding process. The characteristic HU values within the



**Figure 4.** Changes of the characteristic (most frequent) Hounsfield values (HU) of the liver within the examined period.

**Table I.** Analyzed composition of the livers during force-feeding (experiment 2).

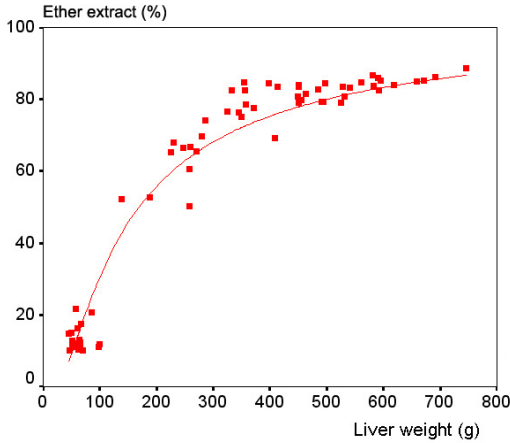
Days	N	Liver weight (g)		Dry Matter DM (g)		Ether extract (g·100 g <sup>-1</sup> DM)		crude protein (g·100 g <sup>-1</sup> DM)	
		Mean	SD	Mean	SD	Mean	SD	Mean	SD
0	20	64	15	29	1.4	13	3.4	76	6.7
13	8	331	131	54	7.9	70	11	23	9.1
18	11	391	122	61	5	77	7.8	18	4
19	7	428	94	60	6	79	5.3	18	4.7
20	7	515	213	63	4.6	83	4.5	14	4.4
21	7	429	146	60	8.7	79	12	18	10
22	8	518	156	61	9.5	78	12	18	9.7

period of preparation (1–2) and post force-feeding (6) are nearly similar (55–80 HU). In the course of force-feeding (2, 3, 4 and 5), the density values were 80, 80, –20 and –50 HU respectively. The latter value approximates the typical fat tissue density, referring to the high fat content of the fatty liver. In certain cases fat deposition becomes irreversible together with the depreciation of the product. According to Bogin et al. [5] (cited in SCAHAW [20]), if force-feeding is continued after three to four days, the level of cell damage rises significantly. In Hungary, 6–10% of processed fatty livers show the so-called extreme fatty liver syndrome.

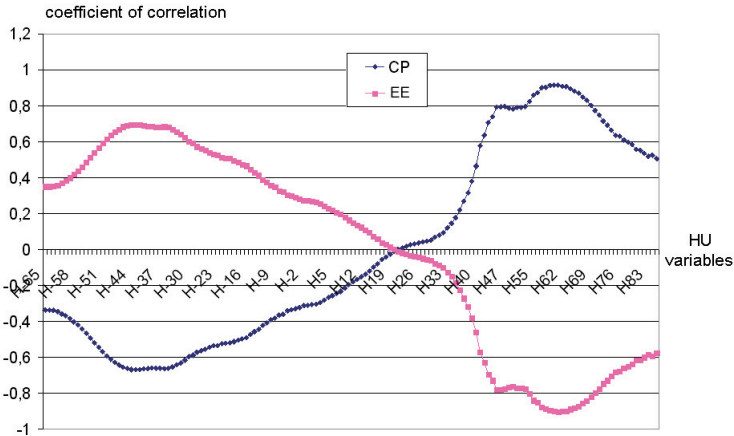
### 3.2. Chemical content determination

Data of liver weight and the results of chemical analysis of the livers are summarized in Table I. It is clearly visible that after day 18, practically no developmental changes can be measured in the characteristic data measured. Dominant compositional changes of the liver occurred mainly before this time, showing a likewise saturation process.

Different models were used to characterize the relation between the liver weight and the chemically determined ether extract content. The highest correlation ( $R^2 = 0.91$ ) resulted with the “S” curve fitting procedure (Fig. 5). It can be remarked that the fat



**Figure 5.** Correlation between the goose liver weight and the ether extract content.



**Figure 6.** Changes in the correlation coefficients obtained from the HU variables of the liver tissue and the ether extract (EE) and crude protein (CP) content.

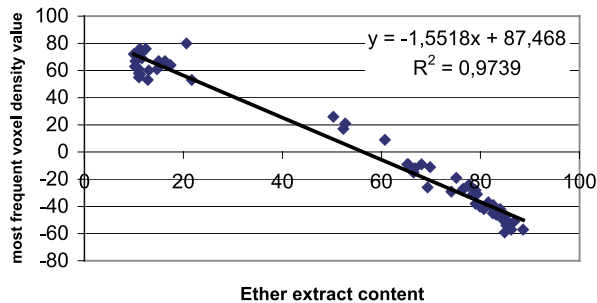
content remained constant above the liver weight of 350 g.

For the better understanding of the applied estimation method some basic relations can be seen in Figure 6, where the curve of the correlation coefficients between HU variables and fat content values show a high, blunt peak in the interval corresponding to fat tissue. The second, slightly higher positive peak is located in the interval of muscle explaining the high accuracy of prediction of the chemical content demonstrated hereafter.

First the fat content of the liver was characterized with the most frequent HU<sub>v</sub> of the tissue, based on the relation described in the methodological part. Figure 7 shows a strong linear relation between the most frequent voxel density value and the fat content ( $R^2 = 0.97$ ).

A slightly weaker correlation ( $R^2 = 0.97$ ) was found between the most frequent voxel density value and the crude protein content. The result of the estimation of chemical composition ( $R^2 = 0.9604$  and  $0.9216$ , EE





**Figure 7.** Correlations between the most frequent voxel density value (characteristic HU) and ether extract content of the livers.

and CP respectively) based on the average HU<sub>v</sub> of the liver tissue was very similar to that of the latter.

The use of prediction equations in CT based experiments aimed at predicting the chemical content of the total body is general. In previous studies on rabbits, fish, broiler chickens and turkeys [2, 3, 17, 18], the variables of the prediction equations originated from the summation of the neighboring 10–10 density values of the Hounsfield intervals between –200 and +200, corresponding to the fat and muscle tissue. These values varied between –80 and 100 without any reduction in the investigated ganders. The reliability of the prediction of ether extract and/or crude protein may be decreased by the strong linear connection between the neighboring HU variables. With the applied PLS regression this effect has been diminished, by finding latent variables that explain most of the variability (Tab. II). In general, the closer the validation variance is to the calibration variance, the more reliable are the model conclusions. It can be seen that in both cases (CF and CP) above PC7 (principal component), the validation variances are decreasing, and thus the so-called noise level has been reached.

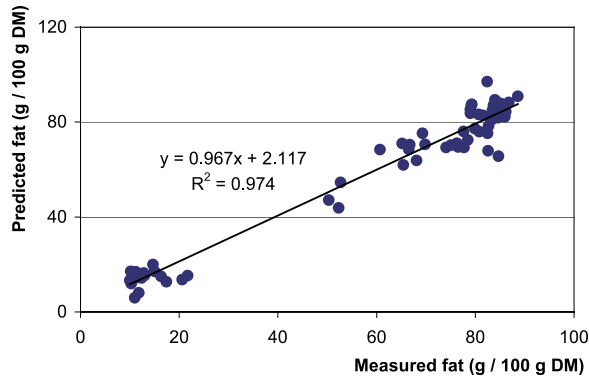
Figures 8 and 9 show the correlations between the measured and estimated liver fat and protein content (calculated for dry matter) on the basis of voxel density data. The MGLH equations were developed from

PC with a stepwise procedure of the multivariate linear regression procedure. The basic data of the two prediction equations are presented in Table II.

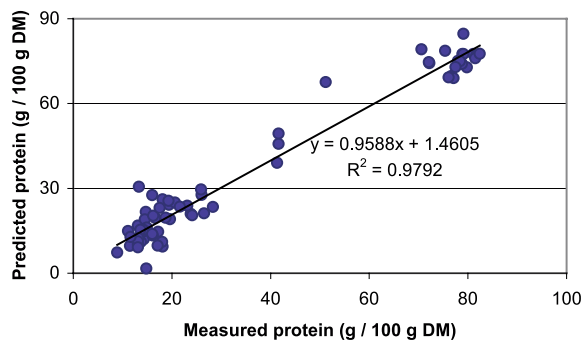
The validation of the above mentioned predictions resulted in a SEC (standard error of calibration) value of 5.64 and 6.73 for EE and CP, respectively. In the authors' experience in CT imaging, this was the first case when the approach based on the most frequent- and average HU<sub>v</sub> resulted in a similar correlation with the chemical content based on the use of prediction equations. The liver tissue with its homogenous texture seems to be an ideal object for CT

**Table II.** The explained calibration (Cal) and validation (Val) variance values of the latent variables.

	Crude protein		Ether extract	
	Cal	Val	Cal	Val
PC1	67.327	66.966	70.701	69.874
PC2	82.299	81.056	84.544	83.108
PC3	90.635	89.138	92.122	91.118
PC4	94.135	92.635	95.302	94.255
PC5	94.751	93.433	95.813	94.906
PC6	95.676	93.604	96.429	94.917
PC7	95.883	94.144	96.601	95.070
PC8	96.443	93.750	97.125	94.723
PC9	96.614	93.590	97.177	94.747
PC10	96.682	93.398	97.237	94.725



**Figure 8.** Correlation between the measured and estimated fat content values of the livers.



**Figure 9.** Correlations between the measured and estimated protein content values of the livers.

based analysis, since any changes in the tissue composition coincide with considerable changes in its X-ray density value.

While the liver substance is relatively constant, a few CT scans seem to be sufficient to grade the fatty liver. The large variation in the characteristic HU values corresponding to the liver tissue of the different ganders encourages the development of this in vivo method for selection purposes. It seems worth screening the top breeder candidates at least in order to get one's own performance data on liver development.

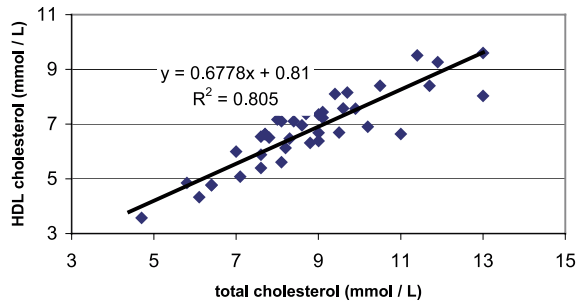
### 3.3. Blood serum parameters

Making serum measurements had a double goal. The first was to characterize the

metabolic and physiological status of the birds along the feeding regime, while the second goal was to determine possible relationships among in vivo determined liver characteristics and blood serum data.

In blood lipids, triglyceride, total cholesterol and HDL cholesterol were determined. When plotted against the EE content of the liver, all the above mentioned parameters showed significant correlations ( $r = 0.681$ ,  $0.792$  and  $0.824$ , respectively,  $P < 0.05$  in all cases).

Serum cholesterol concentration was found to be highly indicative of the physiological status of the birds. In general, when sorting the birds according to their serum cholesterol concentration within the every day-category (i.e. slaughtered at the 18th,



**Figure 10.** Correlation between serum total and HDL cholesterol concentration.

19th, 20th, 21st or 22nd day of force-feeding), the birds having the highest total cholesterol values showed serum total protein, triglyceride, uric acid, total bilirubin and inorganic phosphorus concentrations, as well as lactate dehydrogenase and  $\gamma$ -glutamyl transpeptidase activities highly exceeding the within group average. Furthermore, it was found that birds with high metabolic and enzymatic values did not show average-exceeding liver weight values. Moreover, these birds were characterized by liver EE content values below the group mean. It was thus supposed that geese with markedly high serum lipid values are most likely non-responders to force-feeding, since lower liver lipid accumulation was paralleled, in these cases, to strong lipid traffic in the blood.

Between total and HDL cholesterol, a strong ( $r=0.897$ ,  $P<0.001$ ) correlation was found (Fig. 10). However, no correlation was found between liver weight and serum parameters as well as serum enzymes, which is consistent with the findings of Davail et al. [8], in Landes geese.

#### 4. CONCLUSION

The applied *in vivo* CT examination method seems to be suitable to follow liver development and to analyze the liver composition of geese during the force-feeding period. The procedure is non-invasive and

could be a powerful tool for the development of new liver producing technologies by genetic selection with or without force-feeding.

#### ACKNOWLEDGEMENT

The financial support of the National Research Fund (No. NKFP4/034) is gratefully acknowledged.

#### REFERENCES

- [1] Association of Official Analytical Chemists, Official Methods of Analysis, Washington, DC, AOAC, 1980, pp. 69–82.
- [2] Andrásy-Baka G., Romvári R., Milisits G., Sütö Z., Szabó A., Locsmándi L., Horn P., Non-invasive body composition measurement of broiler chickens between 4–18 weeks of age by computer tomography, *Arch. Tierz.* 46 (2003) 585–595.
- [3] Andrásy-Baka G., Romvári R., Sütö Z., Szabó A., Horn P., Comparative study of the body composition of different turkey genotypes by means of CT, *Arch. Tierz.* 46 (2003) 285–292.
- [4] Bogenfürst F., Handbook of the goose breeders (in Hungarian), Új Nap Lap és Könyvkiadó, Budapest, 1992.
- [5] Bogin E., Avidar Y., Merom M., Israeli B., Malkinson M., Soback S., Kulder Y., Biochemical changes associated with fatty liver in geese, *Avian Pathol.* 13 (1984) 683–701.
- [6] Brenoe U.T., Kolstad K., Body composition and development measured repeatedly by computer tomography during growth in two

- types of turkeys, *Poultry Sci.* 79 (2000) 546–552.
- [7] Dobrowolski A., Branscheid W., Romvári R., Horn P., Allen P., X-ray computed tomography as possible reference for the pig carcass evaluation, *Fleischwirtschaft* 84 (2004) 109–112.
- [8] Davail S., Guy G., Andre J., Hermier D., Hoo-Paris R., Metabolism in two breeds of geese with moderate or large overfeeding induced liver-steatosis, *Comp. Biochem. Physiol. A* 126 (2000) 91–99.
- [9] Fournier E., Peresson R., Guy G., Hermier D., Relationships between storage and secretion of hepatic lipids in two breeds of geese with different susceptibility to liver steatosis, *Poultry Sci.* 76 (1997) 599–607.
- [10] Guy G., Physiological terms of quality liver production, *Proceeding of the 3rd International Poultry Breeding Symposium, Kaposvár, Hungary, 2000*, pp. 51–67.
- [11] Hermier D., Saadoun A., Salichon M.R., Sellier N., Rousselot-Paillet D., Chapman M.J., Plasma lipoproteins and liver lipids in two breeds of geese with different susceptibility to hepatic steatosis: changes induced by development and force-feeding, *Lipids* 5 (1991) 331–339.
- [12] Hounsfield G.N., Computed medical imaging, Nobel Lecture, 1979 Dec. 8, *J. Comput. Assist. Tomo.* 4 (1980) 665–674.
- [13] Larzul C., Rouvier R., Rousselot-Pailley D., Guy G., Estimation of genetic parameters for growth, carcass and overfeeding traits in a white geese strain, *Genet. Sel. Evol.* 4 (2000) 415–427.
- [14] Lorber A., Wangen L.E., Kowalski B.R., A theoretical foundation for the PLS algorithm, *J. Chemometr.* 1 (1987) 19–31.
- [15] Mourot J., Guy G., Lagarrigue S., Peiniau P., Hermier D., Role of hepatic lipogenesis in the susceptibility to fatty liver in the goose (*Anser anser*), *Comp. Biochem. Physiol. B Biochem. Mol.* 126 (2000) 81–87.
- [16] Prehn D., Contribution à l'étude du bien-être du canard (*Cairina moschata* × *Anas platyrhynchos*) en gavage : études biométriques, cliniques, histologiques et fonctionnelles (1996), in: *Welfare Aspects of the Production of Foie Gras in Ducks and Geese, Report of the Scientific Committee on Animal Health and Animal Welfare, 1998*.
- [17] Romvári R., Szendrő Zs., Jensen J.F., Sorensen P., Milisits G., Bogner P., Horn P., Csapó J., Noninvasive measurement of body composition of two rabbit populations between 6–16 week of age by computer tomography, *J. Anim. Breed. Genet.* 115 (1998) 383–395.
- [18] Romvári R., Hancz Cs., Petrási Zs., Molnár T., Horn P., Non-invasive measurement of fillet composition of four freshwater fish species by computer tomography, *Aquacult. Int.* 10 (2002) 231–240.
- [19] Rouvier R., Poujardieu B., Rousselot-Pailley D., Larrue P., Esteve D., Genetic effects on growth, force-feeding and fatty liver traits in crosses of two selected strains of geese (*Anser anser*), *Genet. Select. Evol.* 1 (1992) 53–69.
- [20] SCAHAW (The Scientific Committee on Animal Health and Animal Welfare), Report of the Scientific Committee on Animal Health and Animal Welfare on Welfare Aspects of the Production of Foie Gras in Ducks and Geese, 1998 [Online] Available: [http://europa.eu.int/comm/food/fs/sc/scawah/out17\\_en.html](http://europa.eu.int/comm/food/fs/sc/scawah/out17_en.html) [1 Aug. 2004].