



HAL
open science

Brain activations in speech recovery process after intra-oral surgery: an fMRI study

Audrey Acher, Marc Sato, Laurent Lamalle, Coriandre Emmanuel Vilain,
Arnaud Attye, Alexandre Krainik, Georges V. Bettega, Christian Adrien
Righini, Brice Carlot, Muriel Brix, et al.

► **To cite this version:**

Audrey Acher, Marc Sato, Laurent Lamalle, Coriandre Emmanuel Vilain, Arnaud Attye, et al.. Brain activations in speech recovery process after intra-oral surgery: an fMRI study. Interspeech 2013 - 14th Annual Conference of the International Speech Communication Association, Aug 2013, Lyon, France. pp.2252-2256. hal-00860235

HAL Id: hal-00860235

<https://hal.science/hal-00860235v1>

Submitted on 10 Sep 2013

HAL is a multi-disciplinary open access archive for the deposit and dissemination of scientific research documents, whether they are published or not. The documents may come from teaching and research institutions in France or abroad, or from public or private research centers.

L'archive ouverte pluridisciplinaire **HAL**, est destinée au dépôt et à la diffusion de documents scientifiques de niveau recherche, publiés ou non, émanant des établissements d'enseignement et de recherche français ou étrangers, des laboratoires publics ou privés.

Brain activations in speech recovery process after intra-oral surgery: an fMRI study

Audrey Acher¹, Marc Sato¹, Laurent Lamalle², Coriandre Vilain¹, Arnaud Attye², Alexandre Krainik², Georges Bettega³, Christian Adrien Righini⁴, Brice Carlot⁵, Muriel Brix³ and Pascal Perrier¹

¹ Gipsa-Lab, Dpt. Parole & Cognition, UMR 5216 CNRS/Université Grenoble-Alpes, France

² SFR1 RMN Biomédicale et Neurosciences – Unité IRM Recherche 3T, CHU Grenoble, France

³ Service de chirurgie plastique et maxillo-faciale – CHU Grenoble, France

⁴ Clinique Universitaire d'ORL, Pôle Tête et cou et Chirurgie Réparatrice – CHU Grenoble, France

⁵ Hôpital Privé de la Casamance – Aubagne, France

Audrey.Acher@gipsa-lab.grenoble-inp.fr, Pascal.Perrier@gipsa-lab.grenoble-inp.fr

Abstract

This study aims at describing cortical and subcortical activation patterns associated with functional recovery of speech production after reconstructive mouth surgery. Our ultimate goal is the understanding of how the brain deals with altered relationships between motor commands and auditory/orosensory feedback, and establishes new inter-articulatory coordination to preserve speech communication abilities. A longitudinal sparse-sampling fMRI study involving orofacial, vowel and syllable production tasks on 9 patients and in three different sessions (one week before, one month and three months after surgery) was conducted. Healthy subjects were recorded in parallel. Results show that for patients in the pre-surgery session, activation patterns are in good agreement with the classical speech production network. Crucially, lower activity in sensorimotor control brain areas during orofacial and speech production movements is observed for patients in all sessions. One month after surgery, the superior parietal lobule is more activated for simple vowel production suggesting a strong involvement of a multimodal integration process to compensate for loss of tongue motor control. Altogether, these results indicate both altered and adaptive sensorimotor control mechanisms in these patients.

Index Terms: Neurophonetics, fMRI, speech recovery, motor control, glossectomy, whole-brain analysis, sparse-sampling.

1. Introduction

Intra-oral reconstructive surgery usually induces dramatic changes in the speech apparatus and often requires the patient to go through a long process to recover orofacial motor functions, and in particular speech production. After surgery, some of muscles at the core of these orofacial gestures can be seriously damaged, the volume of the soft tissues can be dramatically modified and their elastic properties strongly altered due to scarification, reconstruction or/and radiotherapy[1]. Thus, after surgery these patients are often in a condition where, despite altered motor abilities, they have to achieve basic gestures, for which they used to be extremely well-trained and to have a strong expertise. Patients have to adapt their speech to the new configuration of their oral cavity. Haupage et al. [2] have investigated cortical patterns associated with swallowing and tongue tapping with fMRI before and after partial tongue surgery. These patterns were compared across sessions for patients and also to a reference pattern of healthy subjects achieving the same motor tasks.

The conclusion was that after surgery patients show increased brain activity in the superior parietal lobule (SPL), the supplementary motor area (SMA) and the anterior cingulate cortex (ACC) compared to pre-surgery. These regions are known for their role in planification (SMA) and selection of motor plans (ACC) and in orosensory feedback integration (SPL). Moreover, region of interest (ROI) analysis of the precentral gyrus shows that averaged volume of activation in the tongue area is lower for patients in all sessions compared to healthy subjects. For speech production, more specifically, reorganization of motor strategies can include both the recruitment of different muscles with new spatio-temporal coordinations and a redefinition of the sensorimotor goals. The goal of the present study is to know more about the cortical reorganization process underlying the functional recovery of speech after mouth surgery.

2. Methodology

2.1. Theoretical expectations

Dramatic changes in peripheral motor apparatus may induce different reorganization of speech motor control. Reorganization of the representation of the limb/hand in primary sensorimotor cortex has been shown both after amputation and graft of hands [3]. Despite the loss of tongue mobility, compensatory strategies possibly supplied by healthy articulators can help to reach well known articulatory and acoustic goals. The elaboration of these strategies could induce neural changes in sensorimotor articulatory representations in the primary sensorimotor cortex, in relation to the respective contribution of each articulator to vocal tract shaping [4] [5] as well as in the anterior part of the insula, involved in the coordination of speech articulation [6]. Articulatory and acoustic speech goals could also be redefined when usual motor goals cannot be achieved anylonger. Finally, new internal representations of the orofacial motor apparatus could be elaborated taking into account modifications between motor commands and orosensory and auditory feedbacks. The emergence of these new representations could take place in the parietal and temporo-parietal cortices, which stores associations between auditory and motor goals, and in the cerebellum often considered to be associated with temporal control of speech [7] and to be involved in learning new internal representations [8].

2.2. Data acquisition

Magnetic resonance images were acquired with a 3.0 T whole-body MR scanner (Philips Achieva TX). Participants laid supine in the scanner with head movements minimized with a standard birdcage 32 channel head coil and foam cushions. Visual instructions were presented using Presentation software (Neurobehavioral Systems, Albany, USA) and displayed on a screen situated behind the scanner via a mirror placed above the subject's eyes. Functional images were obtained in two consecutive functional runs using a T2*-weighted, echo-planar imaging (FE-EPI) sequence with whole-brain coverage (TR = 10s, acquisition time = 2700ms, TE = 30ms, flip angle = 90°, 3mm isotropic resolution). Each functional scan comprised fifty three axial slices parallel to the anteroposterior commissural plane acquired in non-interleaved order (72 x 72 matrix; field of view: 256 mm). A 3D high-resolution T1-weighted whole-brain structural image was then acquired for each participant. In order to minimize movement-related artifacts due to speech production and based on neurophysiological properties of the slowly rising hemodynamic response, with its peak occurring with a 4-6s delay, a "sparse sampling" acquisition paradigm was used [5][9][10][11]. This technique also avoid producing speech in a noisy environment. For each TR, the time interval between the visual instruction onset and the midpoint of the following functional scan acquisition was varied between 4s, 5s or 6s. The order of delay times was pseudorandomly counterbalanced within both runs and conditions. In addition, each motor or resting condition occurred 24 times in a pseudorandomized order. Altogether, 168 functional scans were therefore acquired, anylonger, 6+1 conditions x 24 trials. Three "dummy" scans at the beginning of each run were added to allow for equilibration of the MRI signal and were removed from the analyses.

2.3. Participants

Nine patients (mean age: 55 years old; 3 females and 6 males) and nine healthy adult paired by age (mean age: 55 years old; 4 females and 5 males), all native French speakers, participated in the study after giving their informed consent. They were right-handed according to a standard handedness inventory [12], had normal or corrected-to-normal vision and reported no history of motor, speaking or hearing disorders. They were screened for neurological, psychiatric, other possible medical problems and contraindications to MRI. All patients had a carcinologic surgery (four hemiglossectomy; three pelvi-glosso-mandibulectomy and two mouth of floor resections) with or without flap reconstruction (two anterolateral thigh free flap, two pectoralis major free flap, one antibrachial free flap, one nasolabial flap, one fibula free flap and two direct sutures). Eight of them received radiotherapy post-surgery. The protocol was approved by an ethics committee and was carried out in accordance with the ethical standards of the 1964 Declaration of Helsinki. All participants completed 3 fMRI sessions (one hour each). Patients were scanned in a preoperative session (preop), one week before the surgery; in a postoperative session one month after surgery (postop1) and in a third session 3 months after surgery (postop3). The healthy subjects were recorded regarding these delays.

2.4. Tasks

Two orofacial and four speech motor tasks were performed independently in two consecutive functional runs of 14 minutes. The orofacial motor tasks consisted of either a lip movement (protrusion or spread movements), or a tongue movement (front or back movements). The speech tasks consisted of the production either a simple vowel (/a/ and /ə/), a complex vowel (/i/ and /u/), or simple syllable (/pa/ and /fa/) or a complex syllable (/sa/ and /ʃa/). The term "complex" refers to the difficulty to produce phoneme that require precise articulation regarding tumor and resection. A resting condition, without any movement, served as baseline. For all motor conditions, participants were instructed to initiate and end each movement from a resting state position, with the mouth closed and the tongue and jaw relaxed as soon as they perceived the visual instruction. In each trial, a 1000ms visual instruction informed the participants about the motor condition or the resting baseline, and indicated the onset of the task to be produced. They were instructed to maintain the final position of the articulators for one second. They were trained a few days prior to the scanning session and all the motor tasks were practiced again just before entering into the scanner. No participant reported any difficulty performing the tasks.

2.5. Data analysis

Data were analyzed using the SPM8 software package (Wellcome Department of Imaging Neuroscience, Institute of Neurology, London, UK) running on Matlab 7.1 (Mathworks, Natick, MA, USA).

Preprocessing: For each participant, the functional series were first realigned by estimating the 6 movement parameters of a rigid-body transformation in order to control head movements between scans. After segmentation of the T1 structural image and coregistration of this image to the mean functional image, all functional images were spatially normalized into standard stereotaxic space of the Montreal Neurological Institute (MNI) using segmentation parameters of the T1 structural image. All functional images were smoothed using a 6mm full-width at half maximum Gaussian kernel, in order to improve the signal-to-noise ratio and to compensate for anatomical variability among individual brains.

Postprocessing: Twenty-four functional images were acquired for each motor task (lip movement, tongue movement, simple and complex vowel production, simple and complex syllable production) and for the baseline. The blood-oxygen-level dependence (BOLD) response for each event was modeled using a single-bin finite impulse response (FIR) spanning the time of acquisition (2.7s). Before estimation, a high-pass filtering with a cutoff period of 128s was applied. Beta weights associated with the modeled FIR responses were then computed to fit the observed BOLD signal time course in each voxel for each condition.

Individual analysis: For each participant and each session, the neural correlates related to the motor tasks were analyzed using a General Linear Model (GLM; [13]). The GLM included regressors of interest related to the six motor tasks and realignment parameters. Individual statistical maps were calculated for each motor task contrasted with the baseline. More specifically, for each session separately, six t-contrasts were calculated to determine brain regions specifically activated for each of the motor tasks.

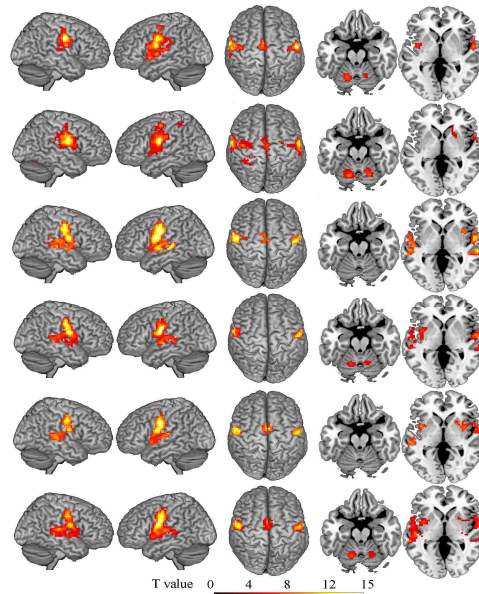


Figure 1: Surface rendering of brain regions activated for patients in the preoperative session (single effect), for the speech and orofacial motor tasks in the top-down order (lips, tongue, simple vowels, complex vowels, simple syllables and complex syllables); $p < .0001$ uncorrected, cluster extent threshold of 25 voxels, group analysis. Views: right hemisphere, left hemisphere, top view, transverse view $z = -20$, $z = 0$. The transverse view helps the visualisation of cerebellum, basal ganglia and insula activations. The more the color is clear, the more the activation is significant.

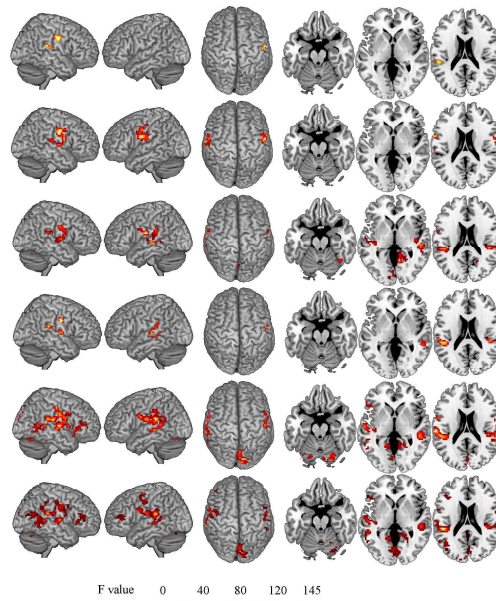


Figure 2: Surface rendering of brain regions activated for main effect of the group, for the speech and orofacial motor tasks in the top-down order (lips, tongue, simple vowels, complex vowels, simple syllables and complex syllables); $p < .0001$ uncorrected, cluster extent threshold of 25 voxels, group analysis. Views: right hemisphere, left hemisphere, top view, transverse view $z = -20$, $z = 0$, $z = 20$. Different colors refer to level of significance for patients or healthy subjects.

Group analysis: For each task, a two-way repeated measures analysis of variance (ANOVA) was performed, with the group (2 levels) as a between-subject factor and the session (3 levels) as a within-subject factor and the subjects treated as a random factor; t-contrasts related to the task were calculated for both the patient and the healthy subject groups (single-effects). In addition, three F-contrasts were calculated to determine the

main effect of the group, the main effect of the session and the interaction between group and session. Significant activations were reported at an uncorrected level of $p < 0.0001$ for the single effects and the main effect of the group, and at an uncorrected level of $p < 0.001$ for the main effect of the session and the interaction between group and session. Significant activations were all reported at a cluster extent of

at least 25 voxels. Each cluster was taken in account and labeled via MRICroN [14]. Group results are presented using an explicit mask with normalized intensity of 0.2 to discard activations that would be clearly located in the white matter.

3. Results

3.1. Single effects of the different tasks

Single effects are presented for the preoperative session. They are congruent with classical orofacial and speech motor control activations (Fig.1). For the orofacial tasks, the network includes bilateral parts of the precentral and postcentral gyri involved in motor execution and proprioceptive feedback. The supplementary motor area and the premotor cortex (both active in action trigger), the inferior frontal gyrus (phonological process), the basal ganglia (planning and motor loops), the lobule VI of the cerebellum (muscular coordination centre), the insula (articulatory planning), the supramarginal gyrus (phonological processing) and the parietal operculum (sensorimotor integration) are also parts of the network. For the speech motor tasks, activations finely correspond to the speech production cortical network observed in earlier studies [15]. As expected auditory areas are also activated.

3.2. Main effect of the group

All the significant differences shown in Fig.2 reflect a lower activity for patients compared to healthy subjects. Left postcentral gyrus is less activated for patients compared to healthy subjects for all sessions in all tasks. For simple vowel and syllable tasks, right postcentral gyrus, bilateral precentral gyrus, bilateral cerebellum (lobule VI), bilateral supramarginal gyrus and bilateral superior temporal gyrus (STG) are less activated for patients versus healthy subjects. In addition, for syllables, the inferior frontal gyrus (IFG pars triangularis) show more activity for healthy subjects than for patients. Lower activations are not located in multimodal associative regions as superior parietal areas. Simple and complex tasks already spread out different patterns of activation, i.e. the simpler the task is, the weaker the activations are.

3.3. Main effect of the session

For the simple vowel tasks, a variation of the activation in the left superior parietal lobule (MNI: -3, -49, 55) is observed for patients across pre- and first post-surgery session, but not for healthy subjects: a larger activity characterizes the first post-operative session possibly reflecting the emergence of new motor strategies (Fig.3).

4. Discussion

Compared to healthy subjects, and in agreement with Haupage et al. [2], reduced activation for patients was specifically observed in precentral gyrus but also in other sensorimotor brain areas classically involved in orofacial/speech sensorimotor control for all tasks. This reduced activity suggests a decrease of the processing efficiency of these brain regions during orofacial movements and speech production and likely indicates altered sensorimotor control mechanisms. Importantly, the fact that this effect kept constant throughout the sessions (preop, postop1, postop3) provides evidence for long-lasting sensorimotor alterations caused first by the tumor and then by its resection. Importantly, compared to healthy

subjects, reduced activation for patients was also observed in speech tasks in the cerebellum (lobules VI). Internal models, assumed to be strongly linked with the cerebellum, are involved in predictive sensorimotor action goal [16] and in trajectory planning [8][17]. In our view, reduced activity in the cerebellum might indicate altered internal speech sensorimotor goals in these patients. Similarly, the decrease of activation in the STG could be explained by the fact that patients partly inhibit auditory feedback because of the incongruity between motor and auditory outputs. Less activation in the IFG (Broca's area) and supramarginal gyrus could also be due to altered regulation processes of speech. The IFG is involved in the monitoring of error [16]. In the DIVA model, somatosensory error map is hypothesized to be located in the supramarginal gyrus, a region that has been implicated in phonological processing for speech perception [18]. On the contrary, stronger activity observed in the left superior parietal lobule (precuneus) in postop1 suggests some adaptive motor mechanisms, also in agreement with Haupage et al. This region is known to contribute to subsequent behavioral adjustment by predictive switching of internal models [16] and is critical for multimodal sensorimotor integration, by maintaining an internal representation of the body's state [19].

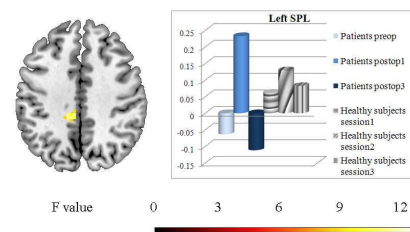


Figure 3: Surface rendering and contrast estimates of left SPL for simple vowel task; $p < .001$ uncorrected, cluster extent threshold of 25 voxels, group analysis. View: $z=40$.

5. Conclusions

Oral surgery affect sensorimotor control processes, with related sensorimotor areas showing lower activity during orofacial and speech production movements for patients in all sessions. This does not match our original expectation of a stronger use of biological feedback control, due to the inadequacy of internal representations, and need to be clarified. However, to face the changes caused by, brain areas devoted to multimodal adjustment show stronger activity one month after surgery. This provides evidence for specific efforts in predictive switching of internal models. Both findings are consistent. However, further investigations are necessary to understand how switching operates when use of biological feedback is reduced and internal models are not accurate. Other recordings are in progress and longitudinal results including the study of the last session (9 months after surgery) will be of a great interest. A region of interest analysis is also planned.

6. Acknowledgements

This research is supported by a grant from the "Gueules Cassées" Foundation (Paris, France). Special thanks to Krystyna Grabski for fruitful advices and discussions. We'd like to thank the three reviewers for their constructive and helpful comments.

7. References

- [1] Buchaillard, S., Brix, M., Perrier, P. and Payan, Y., "Simulations of the consequences of tongue surgery on tongue mobility: Implications for speech production in post-surgery conditions", *International Journal of Medical Robotics and Computer Assisted Surgery*, 3(3), 252-261, 2007.
- [2] Haupage, S., Peck, K.K., Branski, R.C., Hsu, Meier, Holodny, A., and Kraus D., "Functional MRI of tongue motor tasks in patients with tongue cancer: observation before and after partial glossectomy", *Neuroradiology*, 52, 1185-1191, 2010.
- [3] Giraux, P., Sirigu, A., Schneider, F. and Dubernard, J.-M., "Cortical reorganization in motor cortex after graft of both hands", *Nature Neuroscience*, 4, 691-692, 2001.
- [4] Penfield, W., and Rasmussen, T., "The Cerebral Cortex of Man", in Macmillan [Ed], New York, 1950.
- [5] Grabski, K., Lamalle, L., Vilain, C., Schwartz, J.-L, Vallée, N. Tropès, I., Baciú, M. Le Bas, J.-F and Sato, M., "Functional MRI assessment of orofacial articulators: neural correlates of lip, jaw, larynx and tongue movements", *Human Brain Mapping*, 33(10): 2306-2321, 2012.
- [6] Dronkers, N.F., "A new brain region for coordinating speech articulation", *Nature*, 384:159-161, 1996.
- [7] Ackermann, H., "Cerebellar contributions to speech production and speech perception: psycholinguistic and neurobiological perspectives", *Trends in Neurosciences*, 31:265-272, 2008.
- [8] Wolpert, D. M., Miall, R. C. and Kawato, M., "Internal models in the cerebellum", *Trends in Cognitive Sciences*, 2:338-347, 1998.
- [9] Birn, R. M, Bandettini, P. A., Cox, R. W. and Shaker, R., "Event-related fMRI of tasks involving brief motion", *Human Brain Mapping*, 7:106-114, 1999.
- [10] Hall, D. A., Haggard, M. P., Akeroyd, M.A., Palmer, A.R., Summerfield, A. Q., Elliott, M. R., Gurney, E. M. and Bowtell, R. W., "Sparse temporal sampling in auditory fMRI", *Hum Brain Mapping* 7:213-223, 1999.
- [11] Gracco, V. L., Tremblay, P. and Pike, G.B., "Imaging speech production using fMRI", *NeuroImage*, 26:294-301, 2005.
- [12] Oldfield, R. C., "The assessment and analysis of handedness: The Edinburgh inventory", *Neuropsychologia*, 9:97-114, 1971.
- [13] Friston, K. J., Holmes, A. P., Poline J. B., Grasby, P. J., Williams S. C., Frackowiak, R. S. and Turner, R., "Analysis of fMRI time-series revisited", *Neuroimage*, 2:45-53, 1995.
- [14] Rorden, C., Brett, M., "Stereotaxic display of brain lesions", *Behavioural Neurology*, 12, 191-200, 2000.
- [15] Grabski, K., Schwartz, J.-L, Lamalle, L., Vilain, C., Vallée, N., Baciú, M. Le Bas, J.-F and Sato, M., "Shared and distinct neural correlates of vowel perception and production", *Journal of Neurolinguistics* 26(3): 384-408, 2013.
- [16] Imamizu, H. and Kawato, M., "Brain mechanisms for predictive control by switching internal models: implications for higher-order cognitive functions", *Psychological Research*, 73:527-544, 2009.
- [17] Kawato, M., "Internal models for motor control and trajectory planning", *Current Opinion in Neurobiology*, 9:718-772, 1999.
- [18] Guenther, F. H., "Cortical interactions underlying the production of speech sounds", *Journal of Communication Disorders*, 39, 350-365, 2006.
- [19] Wolpert, D.M., Goodbody, S.J. and Husain, M., "Maintaining internal representations: the role of the human superior parietal lobe.", *Nature Neuroscience*, 1(6), 529-533, 1998