



Relief map of the upper cortical subarachnoid space

Alain Lebet, Yukiko Kenmochi, Jérôme Hodel, Alain Rahmouni, Philippe Decq, Eric Petit

► To cite this version:

Alain Lebet, Yukiko Kenmochi, Jérôme Hodel, Alain Rahmouni, Philippe Decq, et al.. Relief map of the upper cortical subarachnoid space. 27th International Congress and Exhibition of Computer Assisted Radiology and Surgery, Jun 2013, Heidelberg, Germany. pp.s282-s284. hal-00840054v2

HAL Id: hal-00840054

<https://hal.science/hal-00840054v2>

Submitted on 19 Apr 2014

HAL is a multi-disciplinary open access archive for the deposit and dissemination of scientific research documents, whether they are published or not. The documents may come from teaching and research institutions in France or abroad, or from public or private research centers.

L'archive ouverte pluridisciplinaire **HAL**, est destinée au dépôt et à la diffusion de documents scientifiques de niveau recherche, publiés ou non, émanant des établissements d'enseignement et de recherche français ou étrangers, des laboratoires publics ou privés.

Noname manuscript No.
(will be inserted by the editor)

Relief map of the upper cortical subarachnoid space*

A. Lebreton · Y. Kenmochi · J. Hodel · A.
Rahmouni · P. Decq · E. Petit

the date of receipt and acceptance should be inserted later

1 Purpose

Hydrocephalus is a neurological disorder that usually results from obstruction of the cerebrospinal fluid outflow in the ventricles or in the subarachnoid space. Magnetic resonance imaging offers a great deal of information to specialists in the clinical diagnosis and treatment processes of hydrocephalus. Recently we have proposed a new magnetic resonance imaging sequence that significantly highlights the cerebrospinal fluid and a segmentation method for its space volumes assessment [3]. Those studies indicate us that the fluid distribution in the cortical subarachnoid space varies significantly, according to whether or not there is a pathology. However, visualization and analysis of the fluid distribution, particularly that of cortical sulci, remain difficult in three dimensions.

This paper proposes a method to retrieve a two-dimensional relief map of the cerebrospinal fluid distribution in the upper cortical subarachnoid space from our three-dimensional images. We define the upper cortical subarachnoid space as the region located above the plane that passes through the anterior and the posterior commissures. The posterior commissure is located behind the top of the cerebral aqueduct that can be readily detected in our images (see Fig. 1). This new representation provides both qualitative and quantitative information on the fluid distribution that surrounds the brain.

* corrected version – 07/02/2013

A. Lebreton · E. Petit
Université Paris-Est, LISSI EA3956, Créteil, France
E-mail: alain.lebreton@univ-paris-est.fr

Y. Kenmochi
Université Paris-Est, LIGM, UMR 8049 CNRS, Marne-la-Vallée, France

J. Hodel
Hôpital Saint-Joseph, 185 Rue Raymond Losserand, 75014 Paris, France

A. Rahmouni · P. Decq
Hôpital Henri Mondor, 51 Av du Maréchal de Lattre de Tassigny, 94010 Créteil, France

2 Methods

A relief map is generated as a two-dimensional digital image where each pixel corresponds to the amount of fluid between the center of the cortical subarachnoid space, *i.e.* the posterior commissure, and an observation point of the outside of the head. Such three-dimensional observation points are positioned on the hemisphere that covers the upper cortical subarachnoid space. We explain how to generate a relief map from a three-dimensional volume data in the following.

2.1 Positioning the hemisphere and image pre-processing

The center \mathbf{c} of the projection hemisphere is manually set by a specialist with respect to the given cerebrospinal fluid data from the anatomical viewpoint. After setting \mathbf{c} , the radius r is then calculated such that it is more than the maximum distance from \mathbf{c} to voxel points of the cerebrospinal fluid volume (see Fig. 1). Images are then cropped through the cut-off plane and the ventricular space is removed, then they are binarized to obtain a voxel set.

2.2 Projection of voxel centers onto the hemisphere

Once we have the hemisphere with center \mathbf{c} and radius r , we project each voxel center point \mathbf{v} onto the hemisphere by drawing a three-dimensional line going through \mathbf{c} and \mathbf{v} and obtaining its intersection with the hemisphere. This intersection is the projected point of \mathbf{v} on the hemisphere, denoted by \mathbf{p} .

2.3 Mapping from the hemisphere to the plane

All the points \mathbf{p} on the hemisphere are now projected on a two-dimensional plane. For this goal, we use the Lambert equal-area projection as it possesses the following interesting properties: bijection, diffeomorphism, and area-preservation [1]. On the other hand, it preserves neither angle nor distance, and thus shapes are distorted in the plane. However, such distortion is less observed if the projection is restricted to the hemisphere centered at the projection point.

The following formulas are applied for each point of the hemisphere $\mathbf{p}' = (x, y, z)$ such that $(x - c_x)^2 + (y - c_y)^2 + (z - c_z)^2 = r^2$ and $z \geq c_z$, to obtain the two-dimensional point $\mathbf{P} = (X, Y)$ located in the disc with center at the origin and radius $\sqrt{2}r$:

$$\begin{aligned} X &= \sqrt{\frac{2r}{r + z - c_z}}(x - c_x), \\ Y &= \sqrt{\frac{2r}{r + z - c_z}}(y - c_y). \end{aligned}$$

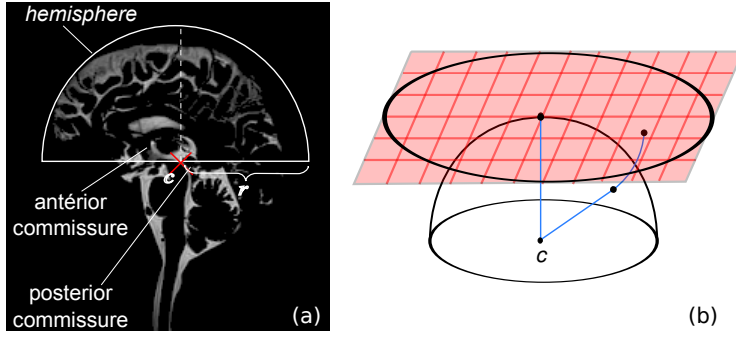


Fig. 1: Sagittal cross section of an original image (a) and Lambert projection on the 2D grid (b)

2.4 Voting in the two-dimensional digitized disc

For generating a relief map, we digitize the disc, obtained by the Lambert projection, with a square grid of pixel size $\frac{\sqrt{2}r}{N}$. The obtained two-dimensional image containing this digitized disc thus has the support of size $(N+1) \times (N+1)$. Each projected point \mathbf{P} then votes for the pixel that contains \mathbf{P} itself. After this voting procedure for all projected points, each pixel has a vote as its altitude, so that the relief map is produced.

The relief map has the following properties: the total amount of altitudes in the relief map is equal to the volume of the initial three-dimensional voxel set; each voxel is associated to only one pixel in the relief map. As we use the Lambert equal-area projection, we suppose that every pixel has a similar altitude for a digitized solid-hemispherical object at center (c_x, c_y, c_z) .

3 Results

Experiments were performed on 38 magnetic resonance images of different subjects between 23 and 91 years old (12 healthy volunteers and 26 patients with hydrocephalus). Figure 2 shows examples of relief maps obtained from those images with our method.

Quantitative assessments on relief maps were carried out by calculating the ratio of the fluid area to the projection disc area ($96.18\% \pm 0.78$ for healthy adults and $88.95\% \pm 5.97$ for pathological cases) and the first moments [2]. The latter indicate that for pathological cases the fluid distribution is depleted in the posterior region of the brain asymmetrically towards the frontal region: the relative change of the centroid position along the horizontal axis is -10.55% and that of the skewness is $+337\%$. This shows up the capability of this approach to quickly verify that the fluid distribution has returned to a normal state after a surgery as shown in Fig. 2.

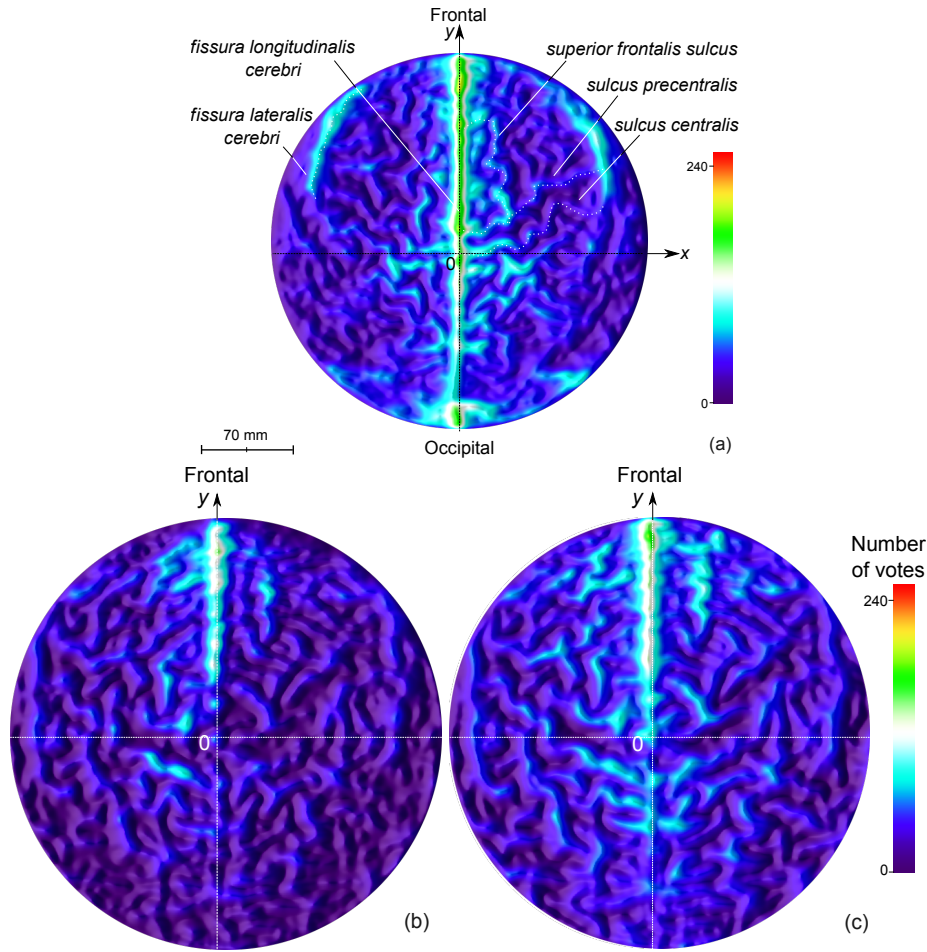


Fig. 2: Colored relief maps for an healthy adult (a), and a hydrocephalus patient before (b) and after (c) a surgery. The frontal region of the fluid is on the top part of the map. The sagittal plane separates the map vertically and appears brighter.

4 Conclusion

This work uses a new magnetic resonance imaging sequence that significantly highlights the cerebrospinal fluid, and succeeds in providing a relief map of the upper cortical subarachnoid space. Our tool allows to estimate the variation of the fluid volume and its distribution into the upper cortical subarachnoid space. This new ability to visualize in a two-dimensional way, the cerebrospinal fluid distribution into the upper cortical subarachnoid space, may represent an important breakthrough in the field of computer-aided neuro-imaging, for diagnosis and for monitoring patients, particularly those suffering from hydrocephalus, before and after surgery.

References

1. Bugaevskij, L.M., Snyder, J.: Map Projections: A Reference Manual. CRC Press (1995)
2. Flusser, J.: Moment invariants in image analysis. *Transactions on Engineering, Computing and Technology* **11**(2), 196–201 (2006)
3. Hodel, J., Lebre, A., Petit, E., Leclerc, X., Zins, M., Vignaud, A., Decq, P., Rahmouni, A.: Imaging of the entire cerebrospinal fluid volume with a multistation 3D SPACE MR sequence: feasibility study in patients with hydrocephalus. *European Radiology* **23**(6), 1450–1458 (2013)