



**HAL**  
open science

## Computer Aided Design for Diabetic Retinopathy

Fabrice Meriaudeau, Désiré Sidibé, Kedir Adal, Sharib Ali, Luca Giancardo,  
T.P. Karnowski, Edward Chaum

► **To cite this version:**

Fabrice Meriaudeau, Désiré Sidibé, Kedir Adal, Sharib Ali, Luca Giancardo, et al.. Computer Aided Design for Diabetic Retinopathy. QCAV2013, 11th International Conference on Quality Control by Artificial Vision, May 2013, Fukuoka, Japan. pp.241-247. hal-00831486

**HAL Id: hal-00831486**

**<https://hal.science/hal-00831486>**

Submitted on 7 Jun 2013

**HAL** is a multi-disciplinary open access archive for the deposit and dissemination of scientific research documents, whether they are published or not. The documents may come from teaching and research institutions in France or abroad, or from public or private research centers.

L'archive ouverte pluridisciplinaire **HAL**, est destinée au dépôt et à la diffusion de documents scientifiques de niveau recherche, publiés ou non, émanant des établissements d'enseignement et de recherche français ou étrangers, des laboratoires publics ou privés.

# Computer Aided Design for Diabetic Retinopathy

F. Mériaudeau, D. Sidibé, S. Ali, K. Adal,  
University of Burgundy  
LE2I –UMR CNRS 6306  
Le Creusot, France  
[Fabrice.meriaudeau@u-bourgogne.fr](mailto:Fabrice.meriaudeau@u-bourgogne.fr)

L. Giancardo  
Istituto Italiano di Tecnologia,  
Genoa, Italy  
[luca.giancardo@iit.it](mailto:luca.giancardo@iit.it)

T. Karnowski  
ORNL – ISML  
P.O. Box 2008,  
Oak Ridge National Laboratory,  
Oak Ridge, TN 37831-6075  
[karnowskitp@ornl.gov](mailto:karnowskitp@ornl.gov)

E. Chaum  
The University of Tennessee Health Science Center ·  
Hamilton Eye Institute  
[echaum@uthsc.edu](mailto:echaum@uthsc.edu)

**Abstract**— Computer aided diagnosis and follow up can help in prevention and treatment of diabetes and its related complications. This paper presents a summary of the results we obtained over the last few years regarding the development of a CAD system for diabetic retinopathy. We present a methodology for diagnosis of DME based on exudates segmentation, as well as an automated detection of micro-aneurysm (MA) and DR diagnosis; Our approach uses standard available public database and shows a high power of generalization through cross database experiments.

**Keywords**—Micro-aneurysms segmentation, exudates segmentation, pattern recognition, registration, diabetic Retinopathy.

## I. INTRODUCTION

Diabetic Retinopathy (DR) which damages the retinal blood vessels is among the most common blindness causes in the developed country. It is suggested that 80% of people which have diabetes for more than 10 years are affected by this problem. In spite of its highest risk factor, studies reported 90% of diabetic retinopathy cases can be prevented through early detection and treatment [1]. The problem is further complicated by the fact that DR does not exhibit any distinctive symptoms which the patient can easily perceive until a severe stage is reached. Therefore, regular eye check-up and timely treatment is needed. However, the lack of specialized ophthalmologists together with associated higher medical costs makes regular check up costly. To fill this gap, development of low cost and versatile Computer Aided Diagnosis (CAD) systems, which can be used in clinical environments, have drawn much more attention in recent years [12], [14], [22], [23]. These systems as any machine vision systems include the lighting, the acquisition, the processing and the segmentation/classification steps. In this paper, we present some of the recent methods, which we had investigated over the last 5 years, to analyze digital fundus images of diabetic patients. In particular, we concentrate on the development of the algorithmic components of an automatic screening system for diabetic retinopathy. The techniques developed can be categorized in: quality assessment

and improvement, lesion segmentation and diagnosis. For the first category, we present a fast algorithm to numerically estimate the quality of a single image by employing vasculature and colour-based features; additionally, we show how it is possible to increase the image quality by enhancing the contrast based on a SVD approach. For the second category, two families of lesions are targeted: exudates and micro-aneurysms; several new algorithms which work on single fundus images are proposed and compared with existing techniques in order to prove their efficacy; in the micro-aneurysms case, a new Radon transform-based operator coupled with a local scale selection technique were developed. In the last diagnosis category, we have developed an algorithm that diagnoses diabetic retinopathy and diabetic macular edema based on the lesions segmented; we further investigated this case through patient follow-up with the design of an atlas based segmentation. The rest of the paper is organized as follows: the first part gives some general background information: it presents the main anatomical structure and functionalities of human eye and how diabetic retinopathy affects them; it also briefly presents our hardware system. The second part will focus on preprocessing phases such as quality assessment as well as a novel contrast enhancement technique. The third part will focus on micro-aneurysm detection and DR evaluation, whereas the fourth part will mainly deal with exudates evaluation and follow up for DME (Diabetic macular edema) evaluation. The paper ends with a short conclusion.

## II. BACKGROUND INFORMATION

### A. Anatomy of the Human Eye

The anatomy of the human eye consists of different cellular structures which are responsible to maintain proper functioning of our vision system. Light entering the eye passes through the anterior and posterior regions before it is processed in the visual cortex. The anterior region which consists of cornea, iris, pupil, and lens mainly serves as a pre-processing step to control the amount of entering light and converges it on the retina. The posterior region contains retina which is a multi-layered sensory tissue made of millions of photo-receptors to capture

incoming light. The central area within retina is called the macula which consists of the central fovea, rich in cones, and a peripheral area, rich in rods. Cones are highly color sensitive photo-receptors and are mainly responsible for day vision. On the other hand rods are highly sensitive to contrast variations and active during night vision or dark light condition. “Fig. 1” shows the global anatomy of the human eye.

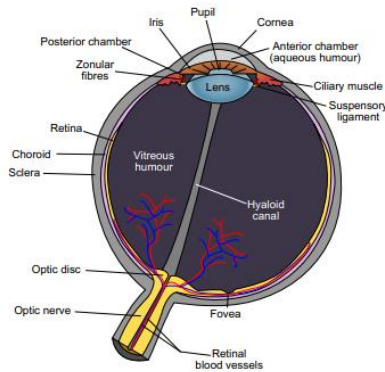


Fig. 1: Anatomy of the Human Eye

**B. Retinal and Related Diabetic Diseases.**

Diabetes mellitus (DM) is a chronic, systemic, life-threatening disease characterised by disordered metabolism and abnormally high blood sugar (hyperglycaemia) resulting from low levels of the hormone insulin with or without abnormal resistance to insulin’s effects. DM has many complications that can affect the eyes and nervous system, as well as the heart, kidneys and other organs. Diabetes is the leading cause of new cases of blindness among adults aged between 20 and 74 years. The Centers for Disease Control and Prevention estimates that 25.8 million people currently have DM in the United States alone. The World Diabetes Foundation estimates that over 439 million people will have diabetes worldwide by 2030. Diabetic retinopathy and diabetic macular edema are the two retina diseases directly caused by diabetes.

*a) Diabetic Retinopathy*

Diabetic retinopathy (DR) is a complication of diabetes which disrupts proper functioning of retinal blood vessels and photoreceptors within retina cells. The primary causes of retina blood vessel damages are vessel closure and permeability. These two factors affect the proper flow of oxygen, blood, and other fluids within the retinal cells; consequently, retinal abnormalities start to develop and results in deteriorating proper vision. Usually, diabetic retinopathy may not be perceived until a severe stage is reached and hence it might even create blindness through time.

Fig.2 shows a comparison of normal vision against vision affected by diabetic retinopathy.

DR is generally graded in four subsequent stages [2]:

- **Mild Nonproliferative Retinopathy** (Mild NPDR): At this earliest stage, only micro-aneurysms (Fig 3) occur and possibly hemorrhage or hard exudates.

- **Moderate Nonproliferative Retinopathy** (Moderate NPDR): As the disease progresses, some blood vessels that nourish the retina are blocked and consequently cotton wool spots start to appear. Also, initial vascular abnormalities such as tortuous vessels or IRMAs (intraretinal microvascular abnormalities) can be found.
- **Severe Nonproliferative Retinopathy** (Severe NPDR): Many more blood vessels are blocked, depriving several areas of the retina with their blood supply. These areas of the retina send signals by the means of VEGF proteins and neovascularization starts.



(a) Normal Vision. (b) Vision with Diabetic Retinopathy.

Fig. 2: Normal Human Vision vs. Vision affected by Diabetic Retinopathy [3].

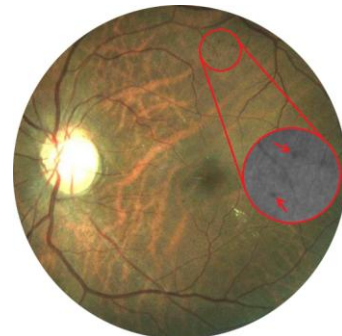


Fig 3: Example of micro-aneurysms

*b) Diabetic Macular Edema*

Diabetic macular edema (DME) is a complication of DR and is the most common cause of vision loss and blindness [4]. DME is defined as swelling of the retina in diabetic patients due to leakage of fluid within the central macula from micro-aneurysms that form as the result of chronic damage due to elevated blood sugar levels. The presence of clinically significant DME is an important indication for the initiation of laser treatment. One particular characteristic of DME is thickening of the retina, which cannot be directly quantified from a single 2-D image because of the lack of depth information. Instead, ophthalmologists can infer the presence of the fluid that causes the retina thickening from photos, by the presence of accompanying lipid deposits called exudates or by multiple fundus images which help to infer 3D

structures. Exudates appear (Fig.4) as bright structures with well defined edges and variable shapes .

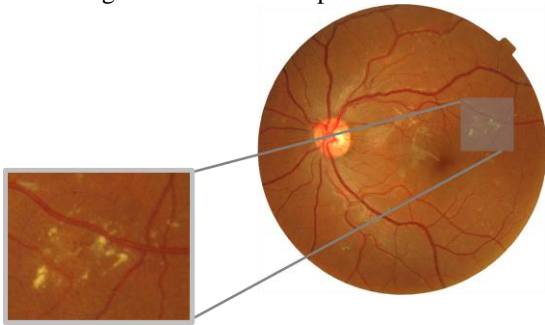


Fig 4: Example of exudates

According to the Early Treatment Diabetic Retinopathy Study Research Group (ETDRS), the patient’s retina should be immediately treated when DME is graded as clinically significant. This happens if any of the following points is satisfied [2]:

- There is a significant retinal thickening within 500 mm distance from the centre of the macula.
- There is exudation within 500 mm distance from the centre of the macula with retinal thickening in the bordering retina.
- There is a retinal thickened area by the size of at least one papilla diameter within the distance of one papilla diameter from the centre of the macula. The papilla roughly corresponds to the visible area covered by the ON in an image of the retina fundus.

### c) Age-related Macular Degeneration

Another retinal disease that has similar effect to diabetic retinopathy but other causes is age-related macular degeneration (AMD). AMD refers to a degenerative condition affecting the macular or central area of the retina. The main characteristic of early AMD is the presence of soft drusen. While their presence does not necessarily indicate that a person has macular degeneration, there has been a strong correlation between the two and the presence of drusen substantially raises a person’s risk to develop macular degeneration. Late AMD includes 2 distinct forms, dry AMD or wet. “Dry” AMD does not involve any leakage of blood or serum. Loss of vision may still occur. Patients with this “dry” form may have good central vision but substantial functional limitations including: fluctuating vision, difficulty reading because of their limited area of central vision and limited vision at night or under conditions of reduced illumination. In the “wet” type of macular degeneration, abnormal blood vessels grow under the retina and macula. In this case the patient will lose at least part of their central vision [5].

### C. Hardware set-up and databases

Fundus camera was introduced as an imaging technique for analyzing and studying anatomical structures of human retina [6]. A fundus camera allows capturing the interior surface of eye, including retina, optic disc, macula, and other

retinal tissues using low power microscopes equipped with an embedded camera system. A camera view of 30 to 50 degrees of retinal area with a magnification of 2.5x is the most commonly used technique in diabetic retinopathy screening applications. A typical fundus camera, which is used to capture all the images used in this work is shown on fig. 5.

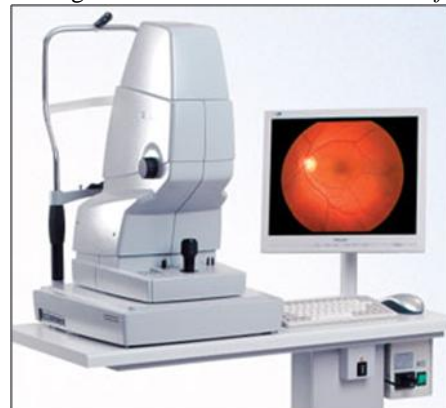

Fig 5 : Example of a fundus Camera

The design, implementation and testing of ARIA (Automated Retinal Image Analysis) algorithms requires high quality annotated data. In the literature, there are some publicly available annotated datasets of retinal images which have different goals, characteristics, and levels of completeness [14]. In our work paper, we employed five different datasets all containing mydriatic and non-mydriatic macula centred colour fundus images mainly at 45 degrees of field of view: ROC challenge [24], HEI-MED [19], Messidor [21], Diaretdb1[25] and a private retina image database which is collected from a teleophthalmology network managed by the Department of Ophthalmology at the University of Tennessee.

## III. PREPROCESSING

### A. Image quality

Various systems for automatic or semi-automatic detection of retinopathy with fundus images have been developed. The results obtained are promising but the initial image quality is a limiting factor [7]; this is especially true if the machine operator is not a trained photographer. Algorithms to correct the illumination or increase the vessel contrast exist, however they cannot restore an image beyond a certain level of quality degradation. On the other hand, a fast and accurate quality assessment algorithm would automatically warn the operator to re-take the fundus image, eliminating or reducing the need for correction algorithms. In addition, a quality metric permits the automatic submission of the best images, if many are available. The QA we developed is accurate in its QA of patients of different ethnicities, robust enough to be able to deal with the vast majority of the images that a fundus camera can produce (outliers included), independent of the camera used, computationally inexpensive so that it can produce a QA in a reasonable time and in a range from 0 to 1, value which can be used as input for further processing. Our approach [8] is based on the hypothesis that a vessel segmentation algorithm’s ability to detect the eye vasculature correctly is partly correlated to the overall quality of an image. The algorithm presented is divided

in three stages: Preprocessing (field of view detection, vessel segmentation [9], Features Extraction (ELVD, color, vessel luminosity and LBP) and Classification (linear SVM) and can be summarized by the Fig 6. The novelty is on the Elliptical Local Vessel Density (ELVD) which is obtained by measuring the vessel area under each local window, then normalized with zero mean and unit variance. The local windows are obtained through sampling of  $r$  (radius) and  $\theta$  (angle). Different values of  $r$  and  $\theta$  will tolerate or emphasize different problems with the image quality.

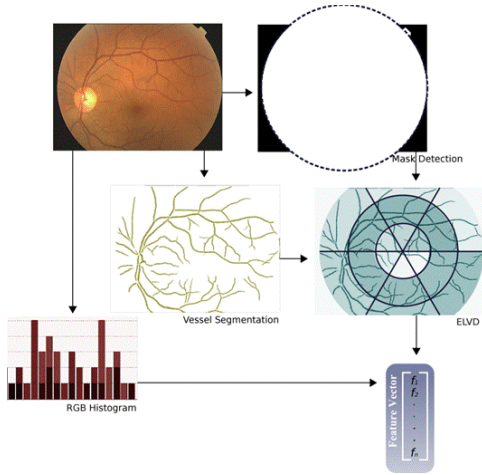


Fig 6 : Schematic of a our Quality Assessment tool.

### B. Contrast enhancement

Due to the external lighting source, color fundus images suffer from variation in illumination change, contrast, and shading. Contrast enhancement and shading removal is thus required before subsequent image analysis. The conventional approach is to apply either local or global histogram equalization techniques [10]. However, these contrast enhancement techniques either does not give satisfactory result or are prone to local noise enhancement [11]. On the other hand, our technique [12] can reduce the shading effect while increasing the contrast of fundus images using Singular Value Decomposition (SVD). The main idea behind this approach is to analyze the intensity distribution of pixels indirectly from the singular values instead of using direct intensity histogram information. Indeed, it is observed that the singular value distribution of good quality retinal images is equivalent but the corresponding distribution of low quality fundus images is low compared to the good ones. The proposed contrast enhancement method is done by replacing all the singular values of any low quality image by the corresponding values of the reference image. The replacement is done in a weighted manner to avoid any over-saturation effect which might be introduced when replacing very high singular values. Fig 7 is an example of the obtained results.

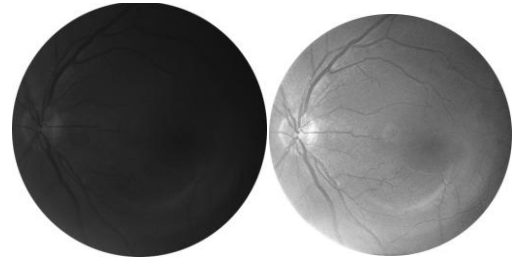


Fig 7 : original Image and Contrast enhanced Image

## IV. MICRO-ANEURYSMS DETECTION

Microaneurysms (MAs) are dilated, aneurismal retina vessels that appear as small red dots in colour retina fundus images. These lesions can leak fluid and blood into the retina, leading to vision threatening exudates, macular edema and hemorrhages. These MAs are the primary target lesions for laser treatment of diabetic retinopathy or macular edema. Apart from the conventional definition which states that “micro-aneurysm are dark-round red structures”, no other information is available for CAD system designers [14]. In our work, we modeled the problem of MA detection as round blob detection [13]; hence different categories of low-level robust blob descriptors which are commonly used in interest point detection of computer vision tasks are used. The scale-space framework which characterizes images at different scales is integrated [27] with the SURF descriptors [28] to extract discriminative attributes of circular-dark blobs which are essentially similar to micro-aneurysms. Moreover, additional features from the fundus images as well as from Radon Transform [15] are added [16]. We used a similar approach with a 3D extension for the detection of micro-bleeds in brain SWI images with both a high sensitivity and high specificity [29].

Fig. 8 presents the flow chart of the whole process which was implemented and fully described in [16].

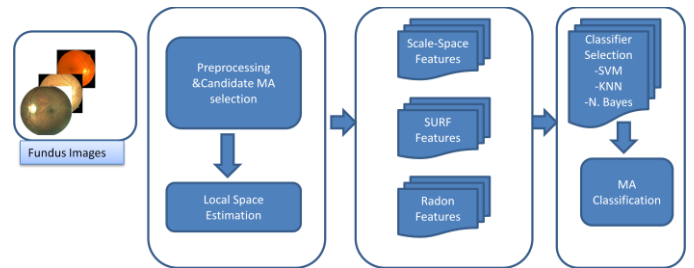


Fig 8 : Flow chart of the micro-aneurysms detection system

The performance of the overall system is evaluated on both the Retinopathy Online Challenge (ROC) and the University of Tennessee Health Science Center (UTHSC) private database of fundus images. As a training dataset, few manually annotated images consisting of 80 MA samples and 300 unlabeled images from UTHSC database of fundus images have been used. Both ROC database training and testing databases are used only as a test dataset. Four supervised classifiers: K-Nearest Neighbor (KNN), Naïve Bayes, and Support Vector Machines (SVM) are selected as underlying classifiers. An exhaustive performance

test was conducted to select an optimal classifier-feature pairing. Table I summarizes these results.

Classifier	Best Features	Parameters
<b>KNN</b>	SURF	K=15, Eucli. Distance
<b>Naïve Bayes</b>	Scale-Space	Preceded by PCA
<b>SVM</b>	Radon, SURF	Radial Basis

Table I: Optimal classifier-feature pairs.

For each optimal classifier-feature pair, a self-training semi-supervised learning model is applied. The performance of each system is then evaluated on Retinopathy Online Challenge (ROC) training images database. Figure 9 shows the FROC curve plot where the system is evaluated on lesion bases.

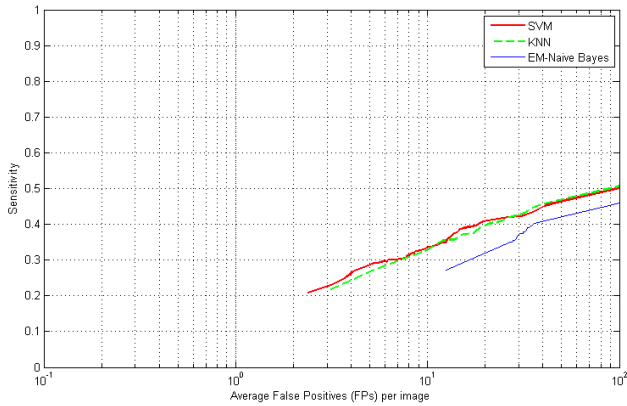


Figure 9: FROC curve using the three classifiers in Self-training mode.

A second set of experiments have also been conducted using co-training approach. The two best performing classifiers i.e SVM and KNN have been chosen to train each other based on their degree of confidence; The performance of each classifier have been improved further especially at medium false positive. The evaluation results on the ROC training dataset also shows that the proposed MA candidate selection algorithm outperforms previously published methods [17] as published in [16]. Our method reduces the false candidate detection by about 52% compared to the best performing technique proposed by Lazar et al. [18] with a comparable sensitivity of 44.64%. The performance of the proposed CAD system has also been evaluated on a private retina image database which is collected from a teleophthamology network managed by the Department of Ophthalmology at the University of Tennessee Health Science Center (UTHSC) in Memphis, Tennessee. This evaluation is done to assess the feasibility of the system to be used in a standalone mode in public DR-screening systems where patients can quickly be screened for the disease in their primary care doctor’s office and other remote sites. This is very crucial in reducing the amount of time spent by ophtamologists to screen out each and every retinal image. A set of 50 images where 37 of them are diagnosed with diabetic retinopathy and the remaining 13 images are free of diabetic retinopathy have been used as an evaluation set. Except the category of each image, a lesion-based annotation is not given for all the images. The

performance of the CAD system is then evaluated on its ability to categorize these images either as “Normal” or “Abnormal”. Fig. 10 shows image level detection result using the two best classifier models. The result shows that when the SVM classifier model is used, the system can achieve a maximum sensitivity of 81.08% at a specificity of 92.31%. Moreover, the area under curve (AUC) of the KNN classifier can reach up to 0.8805. In general, the overall performance of the proposed CAD system is highly promising to be used in public diabetic retinopathy screening programs and teleophthamology networks; where computers are being used to do automated diagnosis and generate medical reports for clinicians review.

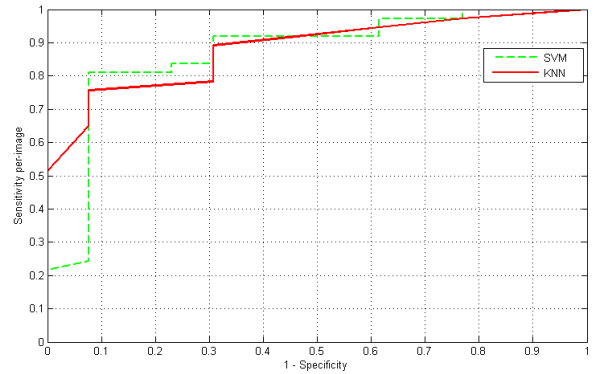


Figure 10: Performance Evaluation on UTHSC database.

## V. EXUDATES DETECTION AND DME

Diabetic macular edema (DME) is a common vision threatening complication of diabetic retinopathy. In a large scale screening environment DME is usually assessed by detecting exudates and their evolution over time. We mainly investigated two approaches, a general pattern recognition approach, [18] where we introduced a new methodology for diagnosis of DME using a novel set of features based on colour, wavelet decomposition and automatic lesion segmentation as well as a technique relying on a atlas based segmentation, which proved to be useful for patient follow-up [20].

For the first approach, [18] features are employed to train a classifier able to automatically diagnose DME through the presence of exudation. We are able to achieve diagnosis performance comparable to retina experts on the MESSIDOR [21] with cross-dataset testing (e.g., the classifier was trained on an independent dataset and tested on MESSIDOR). Our algorithm obtained an AUC between 0.88 and 0.94 depending on the dataset/features used. Additionally, it does not need ground truth at lesion level to reject false positives and is computationally efficient, as it generates a diagnosis on an average of 4.4 s (9.3 s, considering the optic nerve localisation) per image on an 2.6 GHz platform with an unoptimised Matlab implementation file.

For the second approach [20], our method is built on 3 main steps:

1) Building a statistical atlas of retinal images based on ethnicity using automatically generated landmarks.

A statistical atlas from 200 fundus images of good quality (without lesions and artefacts) of each eye of an ethnic group was created. Our purpose of building the statistical atlas is to represent the retinal pigmentation of a patient and landmarks like vascular arches, optic disc and macula of a particular ethnic group, into a reference map.




Fig. 11 Statistical ATLAS image for African American a) Right Eye b) Left Eye

2) Computing the distance map of a given test fundus image to the atlas.

Once the atlas is built, any new test fundus image is first registered to the atlas co-ordinate system. Then, the distance map between the registered image and the atlas is computed. The distance map not only shows the lesions but also other potential imaging artefacts.

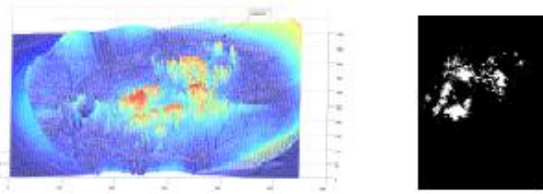


Fig. 12: Distance image with the atlas. Distance image before and after thresholding.

3) Using steerable Riesz transform for enhancing the edges of the bright lesions.

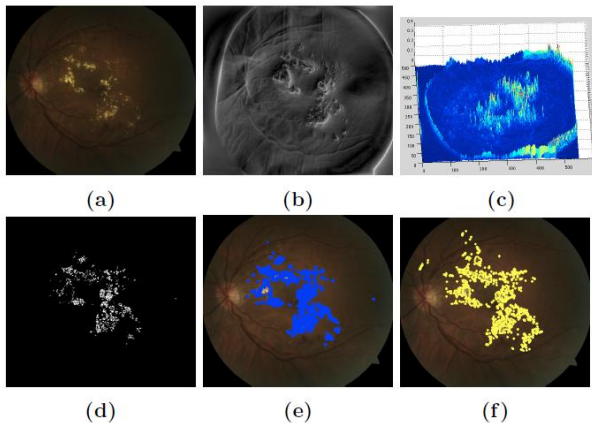


Fig 13: Exudate segmentation using steerable wavelets on atlas space (a) Original image (b) Result from steerable wavelet (c) Mesh plot (d) Result from thresholding absolute image (e) Lesions plotted on the original image after unwarping (f) Ground truth labelled by an expert.

For evaluation purpose we use the HEI-MED public dataset from Hamilton Eye Institute [19]. The dataset consists of 169 fundus images with mixed ethnicities. In our work, we use the 104 images from African Americans to validate our exudates segmentation method. An example of segmentation result is given in *fig. 13*. As can be seen, a simple thresholding of the distance map in atlas space provides good segmentation result. Our experiments show that using the steerable filters for the enhancement of the edge-like exudates improves the results. Furthermore, combining steerable filters with Kirsch edge detector response led to better results, with an achieved accuracy of about 82%. The different results are presented in *fig.14*.

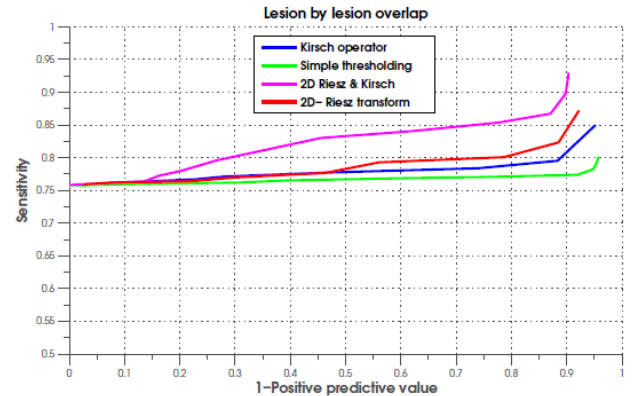


Fig 14. FROC Curves

## VI. CONCLUSION

In this paper, we presented some of our recent work aiming at building a CAD system for diabetic retinopathy screening. As usually done for a machine vision system, investigations were carried out in all aspects of the system : quality assessment, contrast enhancement, micro-aneurysms detection followed by DR diagnosis and Exudates detection followed by DME evaluation. The obtained results are computationally efficient and have been tested over a variety of broad databases showing the high generalization power of our techniques.

## REFERENCES

- [1] P.J. Kertes and T.M. Johnson. "Evidence-based eye care". Lippincott Williams & Wilkins, 2007.
- [2] A. Joussen, T. Gardner, T., and B. Kirchhof," Retinal vascular disease". Springer Verlag. (Chapter 19), 2007.
- [3] St. luke's retinal cataract and laser institute. <http://www.stlukesretina.com/conditions/diabeticretinopathy.html>, Accessed on April 12, 2013.
- [4] D.E. Singer, D.M. Nathan, H.A. Fogel, and A.P. Schachat, "Screening for diabetic retinopathy", in Ann Intern Med, 116(8):660–671, 1992.
- [5] S. Parmet, "Age-related macular degeneration", in JAMA, 288(18), 2001.
- [6] PJ Saine. "Fundus photography: What is a fundus camera", In Ophthalmic Photographers Society, 2006.
- [7] N. Patton, T. M. Aslam, T. MacGillivray, I.J. Deary, B. Dhillon, R. H. Eikelboom, K. Yogesana, and I. J. Constabl , "Retinal image analysis: concepts, applications and potential" in Progress in Retinal and Eye Research, 25(1):99–127, 2006.

- [8] L. Giancardo, M. Abramoff, E. Chaum, T. Karnowski, F. Meriaudeau, K. Tobin, "Elliptical local vessel density: a fast and robust quality metric for retinal images". In Proc. Annual International Conference of the IEEE Engineering in Medicine and Biology Society EMBC 2008.
- [9] F. Zana and J.C. Klein, "Segmentation of vessel-like patterns using mathematical morphology and curvature evaluation" in IEEE Transactions on Image Processing, 10(7):1010–1019, 2001.
- [10] R.C. Gonzalez and E. Richard. Woods, digital image processing, 2002.
- [11] A. Youssif, A.Z. Ghalwash, and A.S. Ghoneim. "A comparative evaluation of preprocessing methods for automatic detection of retinal anatomy". In Proc. 5th Int. Conf. Informatics Syst.(INFOS2007), pages 24-30, 2007.
- [12] M. L. Giger , H.P. Chan , J. Boon, "Anniversary Paper: History and status of CAD and quantitative image analysis: The role of Medical Physics and AAPM", In Med. Phys. 35 12, 5799-5820, December 2008.
- [13] L. Giancardo, F. Meriaudeau, T. P. Karnowski, K. W. Tobin Jr, and E. Chaum, "Validation of Microaneurysm-based Diabetic Retinopathy Screening across Retina Fundus Datasets", accepted to IEEE CBMS 2013.
- [14] E. Trucco, A. Ruggeri, T. Karnowski, L. Giancardo, E. Chaum, J. Hub-schman, B. al Diri, C. Cheung, D. Wong, M. Abramoff, G. Lim, D. Kant Kumar, B. P. M., N. M. Bressler, H. F. Jelinek, F. Meriaudeau, G. Quelled, T. J. MacGillivray, and B. Dhillon, "Validating retinal fundus image analysis algorithms: Issues and a proposal," Investigative Ophthalmology & Visual Science, 2013 (in press).
- [15] L. Giancardo, F. Meriaudeau, T. Karnowski, K. Tobin Jr, Y. Li, and E. Chaum, "Microaneurysms detection with the radon cliff operator in retinal fundus images," in Proceedings of SPIE , vol. 7623, p. 76230U, 2010.
- [16] K. Adal, D. Sidibé, S. Ali, T.P. Karnowski, F. Mériaudeau, "Automated Detection of Micro-aneurysms using Blob Analysis and Semi-supervised Learning," Under correction, IEEE TBME, 2013.
- [17] B. Antal and A. Hajdu, "An ensemble-based system for microaneurysm detection and diabetic retinopathy grading," Biomedical Engineering, IEEE Transactions on, vol. 59, no. 6, pp. 1720–1726, 2012.
- [18] I. Lazar, A. Hajdu, and R. Quareshi, "Retinal microaneurysm detection based on intensity profile analysis," in 8th International Conference on Applied Informatics, 2010.
- [19] L. Giancardo, F. Meriaudeau, T. P. Karnowski, Y. Li, S. Garg, K. W. Tobin, Jr, and E. Chaum, "Exudate-based diabetic macular edema detection in fundus images using publicly available datasets." Medical Image Analysis , vol. 16, no. 1, pp. 216–226, Jan 2012.
- [20] S. Ali, K. Adal, D. Sidibé, T. Karnowski, F. Mériaudeau, "Steerable Transform for Atlas-Based Retinal Lesion Segmentation", in SPIE Medical Imaging, Orlando, Florida - USA, 9-14 February 2013.
- [21] Messidor, Methods to evaluate segmentation and indexing techniques in the field of retinal ophthalmology. <http://www.messidor.crihan.fr>, 2010.
- [22] M. Niemeijer, M. D. Abramoff, and B. van Ginneken, "Information fusion for diabetic retinopathy cad in digital color fundus photographs", in IEEE Transactions on Medical Imaging, vol. 28, no. 5, pp. 775–785, 2009.
- [23] C. I. Sanchez, M. Niemeijer, A. V. Dumitrescu, M. S. A. Suttrop Schulten, M. D. Abramoff, and B. van Ginneken, "Evaluation of a computer-aided diagnosis system for diabetic retinopathy screening on public data." Invest Ophthalmol Vis Sci, vol. 52, no. 7, pp. 4866–4871, Jun 2011.
- [24] M. Niemeijer, B. van Ginneken, M. J. Cree, A. Mizutani, G. Quelled, C. I. Sanchez, B. Zhang, R. Hornero, M. Lamard, C. Muramatsu, X. Wu, G. Cazuguel, J. You, A. Mayo, Q. Li, Y. Hatanaka, B. Cochener, C. Roux, F. Karray, M. Garcia, H. Fujita, and M. D. Abramoff, "Retinopathy online challenge: Automatic detection of microaneurysms in digital color fundus photographs," IEEE Transactions on Medical Imaging, vol. 29, no. 1, pp. 185–195, Jan. 2010.
- [25] T. Kauppi, V. Kalesnykiene, J.-K. Kamarainen, L. Lensu, I. Sorri, A. Raninen, R. Voutilainen, H. Uusitalo, H. K'alvi'ainen, and J. Pietil'a, "Diaretdb1 diabetic retinopathy database and evaluation protocol," In Proc. Medical Image Understanding and Analysis (MIUA), pp. 61–65, 2007.
- [26] L. Giancardo, F. Meriaudeau, T. P. Karnowski, K. W. Tobin, P. Favaro, E. Grisan, A. Ruggeri and E. Chaum, "Texture-less Macula Swelling Detection with Multiple Retinal Fundus Images", IEEE Transactions on Biomedical Engineering Letters, 58 (3), pp. 795-799, January 2011.
- [27] T. Lindeberg, "Feature detection with automatic scale selection," In International journal of computer vision, vol. 30, no. 2, pp. 79–116, 1998.
- [28] H. Bay, A. Ess, T. Tuytelaars, and L. Van Gool, "Speeded-up robust features (surf)," Computer Vision and Image Understanding, vol. 110, no. 3, pp. 346–359, 2008.
- [29] A. Fazlollahi, Pierrick Bourgeat, Fabrice Meriaudeau, Luca Giancardo, Victor L. Villemagne, Christopher C. Rowe, Paul Yates, Olivier Salvado, "Automatic Detection of Cerebral Microbleed in SWI using Radon Transform", ISMRM, Salt Lake City, 20-26 April 2013.