



## Evaluation of bio-integration of rat knee cartilage repair using in vivo MRI at 7T

J.-C. Goebel, E. Roeder, A.-L. Perrier, D. Grenier, P. Gillet, A. Pinzano, O.  
Beuf

### ► To cite this version:

J.-C. Goebel, E. Roeder, A.-L. Perrier, D. Grenier, P. Gillet, et al.. Evaluation of bio-integration of rat knee cartilage repair using in vivo MRI at 7T. *Nouvelles méthodologies en imagerie du vivant*, Dec 2012, Lyon, France. hal-00829530

**HAL Id: hal-00829530**

**<https://hal.science/hal-00829530>**

Submitted on 26 Jun 2018

**HAL** is a multi-disciplinary open access archive for the deposit and dissemination of scientific research documents, whether they are published or not. The documents may come from teaching and research institutions in France or abroad, or from public or private research centers.

L'archive ouverte pluridisciplinaire **HAL**, est destinée au dépôt et à la diffusion de documents scientifiques de niveau recherche, publiés ou non, émanant des établissements d'enseignement et de recherche français ou étrangers, des laboratoires publics ou privés.

### **Introduction**

High-field Magnetic Resonance systems allowing high-resolution Magnetic Resonance Imaging (HR-MRI) is a powerful research tool to visualize and examine hyaline cartilage of small joints non-invasively. Different studies have shown that qualitative assessment of degenerative joint disease, derived from MR images, was reliable (1). The capability to show pathologic changes throughout the time course of the disease from three-dimensional (3D) datasets has also been demonstrated. However, *in vivo* quantitative imaging for an accurate determination of cartilage thickness and volume is challenging due to small size of rodent joints and dedicated coils are mandatory (2-3). Surgical articular cartilage repair therapies for cartilage defects such as osteochondral autograft transfer, autologous chondrocyte implantation or matrix associated autologous cell transplantation require non-invasive technique to evaluate longitudinally the biointegration of the graft. The aim of this study was to follow using 7T MRI the biointegration of biomaterials colonized by mesenchymal stem cells or not after implantation in a calibrated full thickness focal lesion in the rat knee.

### **Material and Methods**

Ethics guidelines for experimental investigations in animals were strictly followed after acceptance by the animal experimentation ethics committee from Université de Lyon. The knee joint were exposed by medial parapatellar incision, and the trochlear groove were exposed by lateral dislocation of the patella. A 1.8 mm outer diameter drill was used to create osteochondral defects (1.8 - 2.0 mm). 24 adult male lewis rats (7-week-old animals) et 12 adult male nude rats underwent surgically a focal calibrated defect of their right femoral articular cartilage on the medial side according to a validated procedure: 12 lewis rats underwent a parapatellar incision without defect, 12 lewis rats underwent a full-thickness cartilage defect, 12 nude rats underwent a full-thickness cartilage defect treated by collagen sponges seeded with human mesenchymal stem cells. MR exploration of rat knee was performed at D7, D14, D28 and D120. After MR exploration, 3 rats were sacrificed at each time course and knees were fixed for further histological confrontation. A four-channel surface coil designed for the simultaneous acquisition of both knee joints of a rat on a Bruker 7T Biospec MR system was used. 3D HR-MRI of the rat knees were obtained using a 3D FLASH sequence with the following parameters: 30° flip angle, 50 ms TR, 3.6 ms TE, 27.8 kHz receiver bandwidth. A total of 256 partitions (98 µm thick) were acquired in two volumes, one for each knee, with a FOV of 1.25 x 1.88 cm<sup>2</sup>. Due to the simultaneous signal acquisition of large matrix on four channels not handled by the proprietary Bruker Paravision 5.1 software, a home-made script using Matlab was written to obtain the reconstructed slices (in-plane pixel: 49 x 49 µm<sup>2</sup>, thickness: 98 µm). The scan time for the FLASH sequence was 1h22 min. The 3D-MRI data sets were used to compute the femoral condylar groove as well as medial and lateral tibial plateaus cartilage volumes. The knee cartilage compartments were drawn directly on interactive touch-sensitive screen this screen using the pen provided. Manual contouring and pixel counting were done using AMIRA software.

## Results

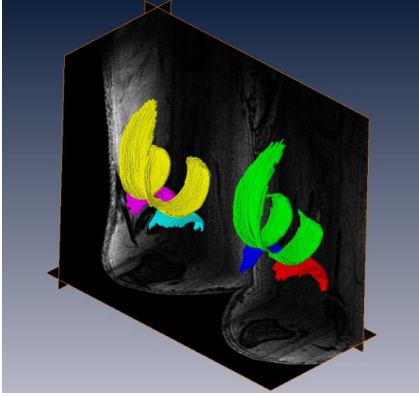


Fig.1: Segmented cartilage compartments of both knee in control rat.

On sham group, volumes of femoral, medial and lateral tibial cartilages were comparable for the right ( $9.2 \pm 0.5$ ;  $1.7 \pm 0.5$ ;  $2.5 \pm 0.4$  mm<sup>3</sup> respectively) and left ( $9.1 \pm 0.7$ ;  $1.9 \pm 0.2$ ;  $2.1 \pm 0.6$  mm<sup>3</sup> respectively) rat knee joint and are constant over the time. Segmentation of rat cartilages with defect (with or without biomaterial) was more difficult to achieve. Rats with calibrated defect on the right knee showed a lower femoral cartilage volume at D7 compared to sham group. The femoral cartilage volume of the right knee was significantly lower compared to the left knee.

## Conclusion

The quality of the MR images obtained with the developed array coils allowed the segmentation of cartilage compartments and measurements of cartilage thickness and volumes. HR-MRI allowed the follow up of cartilage to evaluate in vivo therapeutical responses after chondrogenic biomaterial grafting. Additional information is however required to estimate the real bio-functionality of such biomaterial.

## References

### Acknowledgements

This work is funded by ANR with grant ref. ANR-09-BLANC-0150-01 and is conducted in the framework of the LabEX PRIMES.

1. J. Tessier et al., Osteoarthritis Cartilage 11:845-53 (2003).
2. R. Bolbos et al., Osteoarthritis Cartilage 15:656-65 (2007).
3. [JC. Goebel](#) et al., Rheumatology 49:1654-1664 (2010).