



HAL
open science

Treatment of venous malformations: First experience with a new sclerosing agent-a multicenter study

Martin Schumacher, Patrick Dupuy, Jean-Michel Bartoli, Ulrike Ernemann, Denis Herbreteau, Corinne Ghienne, Laurent Guibaud, Dirk A. Loose, Raul Mattassi, Philippe Petit, et al.

► To cite this version:

Martin Schumacher, Patrick Dupuy, Jean-Michel Bartoli, Ulrike Ernemann, Denis Herbreteau, et al.. Treatment of venous malformations: First experience with a new sclerosing agent-a multicenter study. European Journal of Radiology, 2011, 80 (3), 10.1016/j.ejrad.2010.12.074 . hal-00820364

HAL Id: hal-00820364

<https://hal.science/hal-00820364>

Submitted on 4 May 2013

HAL is a multi-disciplinary open access archive for the deposit and dissemination of scientific research documents, whether they are published or not. The documents may come from teaching and research institutions in France or abroad, or from public or private research centers.

L'archive ouverte pluridisciplinaire **HAL**, est destinée au dépôt et à la diffusion de documents scientifiques de niveau recherche, publiés ou non, émanant des établissements d'enseignement et de recherche français ou étrangers, des laboratoires publics ou privés.

Manuscript Number: HI 675-10R1

Title: Treatment of venous malformations: First experience with a new sclerosing agent - a multicenter study

Article Type: Original Research Article

Keywords: venous malformation, sclerosing therapy, ethanol gel

Corresponding Author: Prof. Martin Schumacher,

Corresponding Author's Institution: University Hospital

First Author: Martin Schumacher

Order of Authors: Martin Schumacher; Patrick Dupuy, MD; Jean-Michel Bartoli, MD; Ulrike Ernemann, MD; Denis Herbreteau, MD; Corinne Ghienne, Pharm.D.; Laurent Guibaud, MD; Dirk A Loose, MD; Paul Matassi, MD; Philippe Petit, MD; Jochen K Rössler, MD; Francesco Stillo, MD; Johannes Weber, MD

Abstract: Purpose

To study the efficacy and safety of a new sclerosing gel of absolute ethanol in the percutaneous treatment of venous malformations (VM).

Materials and Methods

In this prospective, non-randomized multicenter study patients with clinically and by magnetic resonance imaging diagnosed VM were treated. Efficacy of the gel was compared with spontaneous evolution of the test lesion during a previous 2 month control period. Therapeutic outcome was compared with published historical data from VM treated with absolute ethanol solution. Blood ethanol levels of ethanol were measured after each infusion. Local and systemic adverse events were recorded.

Results

Seventy five (75) patients (age 4 - 46 y, mean 26 y) were treated in 172 sessions. Compared to no treatment, ethanol gel showed a cure rate of about 15% per session ($p < 0.00001$). At the end of the last session, therapeutic outcome was complete (score 2) and partial (score 1) in 28 (37%) and 42 patients (56%), respectively, whereas treatment failure (score 0) was observed in 5 patients (7%). Compared to published historical data with absolute ethanol, results were in favor of the gel ($p < 0.003$). The plasmatic ethanol levels were very low (mean \pm SEM 0.03 ± 0.06 g.L⁻¹), with only one patient above the legal 0.5 g/L intoxication limit (0.6 g.L⁻¹). Forty six (46) product-related adverse events (all local, none systemic) were reported. All local complications resolved spontaneously, except for 2 skin necroses requesting surgical paring.

Conclusion

Ethanol gel is a embosclerosing substance that provides high efficiency and improves safety of ethanol in the treatment of VM lesions.

Treatment of venous malformations: First experience with a new sclerosing agent – a multicenter study

1
2
3
4 Martin Schumacher¹, MD
5 Patrick Dupuy², MD
6 Jean-Michel Bartoli³, MD
7 Ulrike Ernemann⁴, MD
8 Denis Herbreteau⁵, MD
9 Corinne Ghienne², Pharm.D.
10 Laurent Guibaud⁶, MD
11 Dirk A. Loose⁷, MD
12 Raul Mattassi⁸, MD
13 Philippe Petit⁹, MD
14 Jochen K. Rössler¹⁰, MD
15 Francesco Stillo¹¹, MD
16 Johannes Weber¹, MD

20 ¹ Department of Neuroradiology, University Hospital Freiburg, Breisacher Str. 64, 79106 Freiburg, Germany
21 Tel.: ++49 761 2705180, Fax: 0049 761 2705195; E-Mail: martin.schumacher.nrad@uniklinik-freiburg.de; johannes.weber@uniklinik-
22 freiburg.de

23 ² Division of Research and Development, Orfagen, CRDPF – Langlade, 3, avenue Hubert Curien,
24 BP 13562, 31035 TOULOUSE Cedex 1, France

25 Tel. ++33 (0)534506455, Fax: ++33 (0)534503458, E-Mail: patrick.dupuy@orfagen.com; corinne.ghienne@orfagen.com

26 ³ Department of Neuroradiology, Hôpital adultes de la Timone, Marseille, 264 rue Saint-Pierre, 13385
27 Marseille Cedex, France

28 Tel.: ++ 33 (0)4-91-32-43-95, Fax: ++33 (0)4-91-32-43-96, E-Mail: Jean-Michel.bartoli@ap-hm.fr

29 ⁴ Department of Neuroradiology, University Hospital Tübingen, Hoppe-Seyler-Str. 3, 72076
30 Tübingen, Germany

31 Tel.: ++49 7071 2986024, Fax: ++49 7071 295638, E-Mail: ulrike.ernemann@med.uni-tuebingen.de

32 ⁵ Department of Neuroradiology, Hôpital Bretonneau, Tours, 2, boulevard Tonnelle, Tours, Cedex, 37044
33 France

34 Tel.: ++33 (0)2 47 47 37 25, Fax: ++33 (0)2 47 47 47 84, E-Mail: herbreteau@med.univ-tours.fr

35 ⁶ Department of Pediatric Radiology Hôpital Debrousse, 29, Rue Soeur Bouvier, 69005 Lyon, France

36 Tel.: ++33 (0)4 72 38 56 66, Fax: ++33 (0)4 72 38 58 61, E-Mail: laurent.guibaud@chu-lyon.fr

37 ⁷ Department of Angiology and Vascular Surgery, Klinik Dr. Guth, Jürgensallee 46-48, 22609 Hamburg,
38 Germany

39 Tel. ++33 (0)40 822810, Fax: ++33 (0)40 823945, E-Mail: info@prof-loose.de

40 ⁸ Department of Vascular Surgery, Azienda Ospedaliera „Guido Salvini“ Milano, Italy

41 Tel.: ++39 02.994301, E-Mail: rmatassi@yahoo.it

42 ⁹ Department of Paediatric Radiology Pr Devred, La Timone University Hospital, 264 rue St Pierre, 13385
43 Marseille Cedex, France

44 Tel. ++33 (0)491386797, Fax: ++33 (0)491387866, E-Mail: philippe.petit@mail.ap-hm.fr

45 ¹⁰ Department of Pediatrics, University Hospital Freiburg, Mathildenstr. 1, 79106 Freiburg, Germany

46 Tel.: ++49 (0)761 2704514, Fax: ++49 (0)761 2704518, E-Mail: jochen.roessler@uniklinik-freiburg.de

47 ¹¹ Istituto Dermopatico dell'Immacolata, Via Dei Monti Di Creta, 104, 00167 Roma (RM), Italy

48 Tel.: ++39 06.66.461, E-Mail: f.stillo@idi.it

49 P.Dupuy² at equal position with M. Schumacher

Funding information:

51 The study was sponsored by Orfagen, Toulouse, France.

Corresponding author:

52
53
54 Prof. Dr. Martin Schumacher
55 Department of Neuroradiology
56 University Hospital Freiburg
57 Breisacher Str. 64
58 D-79106 Freiburg
59 Tel. 0761/270-5180 - Fax 0761/270-5195
60
61
62
63
64
65

E-Mail: martin.schumacher.nrad @uniklinik-freiburg.de

1
2
3
4
5
6
7
8
9
10
11
12
13
14
15
16
17
18
19
20
21
22
23
24
25
26
27
28
29
30
31
32
33
34
35
36
37
38
39
40
41
42
43
44
45
46
47
48
49
50
51
52
53
54
55
56
57
58
59
60
61
62
63
64
65

1
2
3
4
5
6
7
8
9
10
11
12
13
14
15
16
17
18
19
20
21
22
23
24
25
26
27
28
29
30
31
32
33
34
35
36
37
38
39
40
41
42
43
44
45
46
47
48
49
50
51
52
53
54
55
56
57
58
59
60
61
62
63
64
65

**Treatment of venous malformations:
First experience with a new sclerosing agent –
a multicenter study**

Abstract

Purpose

To study the efficacy and safety of a new sclerosing gel of absolute ethanol in the percutaneous treatment of venous malformations (VM).

Materials and Methods

In this prospective, non-randomized multicenter study patients with clinically and by magnetic resonance imaging diagnosed VM were treated. Efficacy and safety of the gel was evaluated. Therapeutic outcome was judged at day 56 after the last sclerosing therapy. Blood ethanol levels of ethanol were measured after each infusion. Local and systemic adverse events were recorded.

Results

Seventy five (75) patients (age 4 - 46 y, mean 26 y) were treated in 172 sessions. Compared to no treatment, ethanol gel showed a complete cure rate of about 15% per session ($p < 0.00001$). At the end of the last session, therapeutic outcome was complete (score 2) and partial (score 1) in 28 (37%) and 42 patients (56%), respectively, whereas treatment failure (score 0) was observed in 5 patients (7%). The plasmatic ethanol levels were very low (mean \pm SEM 0.03 ± 0.06 g.L⁻¹), with only one patient above the legal 0.5 g/L intoxication limit (0.6 g.L⁻¹). Forty six (46) product-related adverse events (all local, none systemic) were reported. They included temporary mild isolated pain (N=21), inflammatory reactions (N=4), and local complications (7 skin necroses, 7 compressive neuropathies, 4 product leakage/fistula, 2 intralesional fibrous or granulomatous tissue, 1 dense node; 12.2% of the infusions). All local complications resolved spontaneously, except for 2 skin necroses requesting surgical paring.

Conclusion

Ethanol gel is a embosclerosing substance that provides high efficiency and improves safety of ethanol in the treatment of VM lesions.

Key words: venous malformation, sclerosing therapy, ethanol gel

Introduction:

1 Percutaneous sclerosing therapy for slow-flow venous malformations (VM) has used
2 several embolic and sclerosing agents such as Thrombovar®, Ethibloc® or pure absolute
3 ethanol. Depending on the speed of injection, absolute ethanol induces embolizing
4 microaggregates by plasma protein denaturation and red cell lysis at low speed and
5 plurivascular necrosis per direct cell toxicity at high speed (1). Though absolute ethanol
6 has been proved to be highly effective, it remains difficult to manipulate. It is diffusible due
7 to its low viscosity and disseminates into surrounding uninvolved vessels and tissue with a
8 significant risk of major adverse effects (1-6). In 2001, Tiret et al. described a new gelified
9 solution of ethanol with ethylcellulose for the treatment of VM (7). In a pilot single center
10 study on 23 patients, the alcohol gel was found to be efficacious, safe and easy-to-handle
11 in VM (8). The aim of the present multicenter study was to establish the efficacy and
12 safety profile of this new sclerosing gel with a pharmaceutical grade, as well as precise its
13 therapeutic dose, indication and procedure of administration.
14
15
16
17
18
19
20
21
22
23
24
25
26
27
28
29
30
31
32
33
34
35
36
37
38
39
40
41
42
43
44
45
46
47
48
49
50
51
52
53
54
55
56
57
58
59
60
61
62
63
64
65

Materials and Methods

1
2
3 This study was designed as a prospective, open-labeled, observational and multicenter (9
4 centers) study. The study was part of a clinical development programme, with the aim to
5 make the test product as an approved orphan medicinal product in VM by the
6 percutaneous route. The objectives were to evaluate the therapeutic outcome (efficacy,
7 safety, local tolerance and acceptability), the conditions in which the therapeutic effects
8 are achieved (therapeutic doses, product safety margin) and the procedure of
9 administration of the gel in patients including children of at least 1 year of age, with a
10 clinically and radiologically (MRI) diagnosis of VM. The test product was indicated as first
11 line therapy or as follow-up treatment of previous therapies (surgery, embolosclerotherapy)
12 that were unsuccessful or insufficient. Patients were not includable during episodes of
13 local inflammatory reactions or abnormal clotting parameters (platelets, prothrombin time,
14 fibrinogen, D-dimers). The study was approved by the local Ethics Committees, and all
15 patients signed a written informed consent for their participation. It was conducted under
16 Good Clinical Practice (GCP) and Standard Operative Procedures (SOP).
17
18
19
20
21
22
23
24
25
26
27

Sclerosing agent

28
29
30 The gelified solution (L0122) used consisted of a mixture of 3.86g ethanol (with a
31 concentration of 96%) and 0.24g ethylcellulose (5.88%) resulting in a viscosity of 300
32 mPa. The test product was manufactured under GMP conditions by the sponsor, Orfagen
33 Laboratories (Toulouse, France). In-vitro testing (M.S. unpublished data) showed
34 precipitation within 1-2 seconds in a solution of sodium chloride or full blood but no gluing
35 effect (Figure 1). Animal testing in one minipig demonstrated that the material is not
36 suitable for arterial injection because it passes the capillary bed (M. S., personal data).
37 Animal toxicological studies were performed to investigate the safety margin of the test
38 product (unpublished data; Orfagen's file). Its use by the intravenous route, mimicking
39 accidental systemic exposure, revealed a maximum tolerated dose of 1mL for a body
40 weight (bw) of around 10 Kg in beagle dogs (0.1 mL/Kg). Its local administration in
41 cutaneous tissue induced an inflammatory process associated with a mild granuloma
42 formation that resolved within weeks.
43
44
45
46
47
48
49
50
51
52
53
54
55
56
57
58
59
60
61
62
63
64
65

Treatment protocol and administration procedure

1 A maximum number of 4 sessions per patient was authorized, separated by 2-month
2 follow-up intervals. Sessions at incremental doses of the product were performed with
3 patient accrual: a maximum dose of 5 mL was allowed in the first set of 15 patients,
4 followed by a maximum dose of 10 mL for the rest of the study, when the 5 mL dose was
5 seen as safe (no systemic absorption of ethanol). At any stage, a strict limitation to 0.6
6 ml/Kg bw per session was required.

7
8 Before treatment, local cutaneous anesthesia was applied using Emla® patches (mixture
9 of prilocaine and lidocaine). Dependent on the size and location of the lesion, the
10 investigators were allowed to additionally apply local intra- and subcutaneous anesthesia
11 with injection of lidocain or to perform the procedure under general anesthesia.

12 Administration of the gel was done percutaneously by direct puncture of the lesion using
13 20-22 G needles. The procedure of administration required two measures : firstly,
14 administration should be strictly preceded by injection of contrast medium under
15 fluoroscopy (Fig. 2), in order to verify the intralesional position of the needle and assess
16 the amount of gel to infuse ; and secondly, a pilot dose of 0.1 mL/Kg bw should be
17 administered first under fluoroscopic control before the infusion of the therapeutic dose, in
18 order to prevent any major systemic complication by incidental infusion into a large
19 draining vein. Like for ethanol solution, product infusion had to be stopped when contrast
20 medium was displaced into large draining veins, or a significant resistance to product
21 infusion was observed. The administration procedure thus followed general practice of
22 percutaneous treatment of VM with sclerosing agents. This means, that a permanent slow
23 injection of the agent was performed depending of the size of the venous pouches ranging
24 between 2 and 5 minutes. If the previous contrast test injection demonstrated connections
25 to draining veins these were compressed by manual external pressure. After
26 administration of the total amount of the gel and removal of the needle compression
27 dressing was applied for one day.

Evaluation parameters

28 Efficacy of the gel 2 months after each session was judged, using a 3-point scale (0 = no
29 change, 1 = lesion size or signs reduced, 2 = lesion size or signs resolved). The following
30 management-driven scale integrating efficacy and safety outcome was used for
31 therapeutic outcome at day 56 visit after the last injection: 0 = failure due to inefficacy or
32 major side-effect, other treatment required; 1 = lesion or signs clinically reduced but still
33 present and no major side-effect, new session required; and 2 = lesion or signs clinically
34 resolved and no major side-effect, no more treatment required. Other evaluation
35
36
37
38
39
40
41
42
43
44
45
46
47
48
49
50
51
52
53
54
55
56
57
58
59
60
61
62
63
64
65

1 parameters included the severity of the functional signs (pain, swelling) as well as the
2 aesthetic damage by the patients at baseline and day 56 of each session through a 100-
3 mm visual analog scale(VAS) using the Wilcoxon signed-rank test, and the mode of
4 anaesthesia (none, local, loco-regional, neurosedation, general) was reported.

5 For safety analysis, measurement of blood ethanol levels 20 mn after starting gel infusion
6 was carried out. Biological tests (haematology, chemistry and coagulation) was performed
7 within 14 days prior to each session and at study end. Finally, local and systemic adverse
8 events were recorded all over the study.
9
10
11
12
13

14 **Results**

15
16
17
18 A total of seventy seven (77) patients with VM were screened to enter the study. Among
19 them, one patient withdrew his consent before first product administration, and one patient
20 had abnormal coagulation parameters at baseline and never received the test product. No
21 patient was lost to follow-up. Accordingly, the study population comprised 75 patients,
22 whose demographic data and lesional status are summarized in Table 1. A total of one
23 hundred and seventy two (172) sessions (median: 2, range: 1-4) was performed.

24 The efficacy outcome at the end of each session demonstrated that, compared to no
25 treatment, ethanol gel contributed to lesional or sign reduction from the very first infusion,
26 with a steady cure rate (score 2) of about 15% at the end of each session ($p < 0.00001$;
27 Table 2). For the overall therapeutic outcome at the end of the last session, a complete
28 response was observed in 27 patients (36 %), partial response in 43 patients (57.3 %),
29 and failure in 5 patients (6.7 %).

30 The evaluation of functional signs and aesthetic damage, as assessed by the patients
31 using the 100-mm Visual Analog Scale (VAS), showed that pain was greatly reduced by
32 ethanol gel (at the end of study, mean \pm SEM reduction: -21.72 ± 3.10 mm, compared to
33 baseline value : 29.06 ± 3.38 mm ; $p < 0.0001$). Swelling was also significantly decreased
34 (-31.51 ± 3.53 mm, baseline value: 44.05 ± 3.54 mm; $p < 0.0001$) and aesthetic damage
35 of the test lesion was significantly improved by ethanol gel treatment (-21.41 ± 3.35 mm,
36 baseline value: 39.67 ± 3.84 mm; $p < 0.0001$). In most cases, resolution of functional signs
37 and aesthetic damage was associated with lesional size reduction at MRI (Fig. 3). During
38 the infusion procedures (N = 172), the mode of anaesthesia was general anaesthesia in
39 132 infusions (76.7 %), neurosedation in 1 infusion (0.6 %) and local anaesthesia in 39
40 infusions (22.7 %).
41
42
43
44
45
46
47
48
49
50
51
52
53
54
55
56
57
58
59
60
61
62
63
64
65

1
2
3
4
5
6
7
8
9
10
11
12
13
14
15
16
17
18
19
20
21
22
23
24
25
26
27
28
29
30
31
32
33
34
35
36
37
38
39
40
41
42
43
44
45
46
47
48
49
50
51
52
53
54
55
56
57
58
59
60
61
62
63
64
65

Out of a total of one hundred and fifty-eight (158) sessions for which ethanolaemia was available (91.9% of the 172 sessions completed), blood ethanol levels were found below the limit of quantification (i.e. 0.05 to 0.2 g.L⁻¹, according to centres) in 116 cases (73.4 %) and only one infusion resulted in an ethanol level above the 0.5 g.L⁻¹ legal intoxication limit (0.6 g.L⁻¹). The mean value \pm SEM of ethanolaemia in the assessed samples was 0.03 \pm 0.06 g.L⁻¹. No abnormal laboratory blood tests of clinical significance was found in any patient, neither before nor at the end of the sessions. Similarly, in the 141 infusions where cardio-pulmonary data (arterial pressure, heart rate, pulmonary rate, O₂ and CO₂ blood saturations) were recorded no clinically significant abnormal values were found, either. A total of forty six (46) local adverse events related to test product were noticed, all occurring within days or weeks after the product infusion (26.7% of the total infusions). The majority of them (N = 25, 14.5%) were actually events of usual occurrence after sclerotherapy with ethanol: 21 mild isolated pain, and 4 inflammatory reactions or swellings (Fig 4). All remitted spontaneously or under nominal therapy (analgesics, antiinflammatories; range of treatment duration: 2-84 days). Twenty-one (21) local complications were observed (12.2% of the infusions). They comprised the following: 7 skin necroses (4%), 7 compressive neuropathies (4%), 4 product leakage/fistula (2.3%), 2 fibrous or granulomatous tissue within the test lesion (1.2%), and 1 dense satellite node (0.6%). Skin necrosis occurred only in superficial VM and resolved within a range from 1 day to 141 days (median: 39 days), without sequelae in 6 patients and with sequelae in 1 patient (small scar). In 2 cases, resumed surgery (paring of skin necrosis) was performed, without sequelae in both cases. Neuropathies occurred in lesions adjacent to a major nerve. They were transitory (range of duration: 54 to 290 days, median: 60 days) and resolved spontaneously without sequelae, leading to a final diagnosis of compressive neuropathy. Product leakage/fistula were all reported when investigators experienced their first sessions. When the infusion procedure was re-explained (needle to be placed at small distance from the lesion), no further product leakage was observed in the study. Product leakage/fistula cases were also transitory (range of duration: 2 to 89 days, median: 44 days) and resolved on their own completely, as did the fibrous/granulomatous tissue and dense node within 3 months after the causal infusion. One (1) systemic adverse event was reported (bradycardia). It was considered to result from pain provoked by the combination of product infusion and insufficient anaesthesia, and rapidly resolved under atropin. It was not associated with any significant systemic exposure to ethanol (level under detection limit, i.e. < 0.1 g.L⁻¹).

The strict precautions of administration that were applied during the infusion procedure did not lead to apparent accidental infusion into arterial or large venous vessels. The amount of ethanol gel administered per session corresponded to 30-50% of the contrast medium volume used prior to the gel infusion. Less amount was infused (15-30%) when a large remaining vein was identified.

1
2
3
4
5
6
7
8
9
10
11
12
13
14
15
16
17
18
19
20
21
22
23
24
25
26
27
28
29
30
31
32
33
34
35
36
37
38
39
40
41
42
43
44
45
46
47
48
49
50
51
52
53
54
55
56
57
58
59
60
61
62
63
64
65

Discussion

1
2 Treatment of VM is still a challenge for interventional radiologists and surgeons. Formerly,
3 surgery was the only therapeutic approach but could not be established as standard
4 method due to the lack of complete and curable therapy for VMs. The availability of new
5 sclerosing agents such as polyvinyl alcohol and IBCA (isobutyl-2-cyanoacrylate) cleared
6 the way for new therapeutic strategies (9). Over the years, endolesional embolization of
7 any kind of vascular lesions was improved and nowadays reaches very sophisticated levels.
8 However, up to now, no sclerosing agent has been approved in the European Union or, to
9 our knowledge, elsewhere for the indication of percutaneous sclerosing of VM. Ethibloc®
10 was successfully used in this indication as "off-label" agent (10,11), but is no longer
11 available. This viscous mixture of zein, oleum papavaris and absolute alcohol exhibited
12 excellent filling properties for VM without distal embolization of the draining veins and
13 produced intravascular necrosis. Unfortunately, Ethibloc® residues which did not resorb
14 spontaneously usually required additional surgery for removing the induced granulomatous
15 tissue.

16
17 Absolute ethanol solution has also been widely used for VM treatment and was proved to
18 be highly effective (1-6). It destroys the endothelial cells, thereby breaking down the vessel
19 wall resulting in permanent obliteration of the vessel lumen. However, the liquid properties
20 are likely to produce ischemia and necrosis in adjacent tissue such as skin and nerves
21 (12). Additionally, possible systemic side effects require anesthesia in a reanimation
22 environment. Overall, systemic and local complications make this effective product difficult
23 to handle.

24
25 An ideal embolizing agent would combine the favorable properties of Ethibloc® and
26 absolute alcohol i.e., controllable viscous filling properties with a high rate in lesion
27 necrosis and spontaneous resorption. This would represent favorable characteristics for an
28 effective low-risk agent. The new gelified ethanol product, described first in 2000, seems to
29 achieve these criteria (7). In the clinical setting, this agent revealed very promising results
30 with marked improvement of VM lesions and limited side effects (8). Patients experienced
31 a decrease in pain, inflammatory episodes and esthetic aspect. Concerning side effects,
32 post-treatment surgery was necessary in 2 patients (9%), to remove necrotic tissue. Other
33 secondary side-effects included an inflammatory reaction in one patient that remitted with
34 corticosteroid administration, a benign ulceration with spontaneous resolution in 3 patients,
35 and a fistula with spontaneous recovery in one patient.

1
2
3
4
5
6
7
8
9
10
11
12
13
14
15
16
17
18
19
20
21
22
23
24
25
26
27
28
29
30
31
32
33
34
35
36
37
38
39
40
41
42
43
44
45
46
47
48
49
50

These promising data led us to conduct an open-labeled, multicenter study evaluating the therapeutic outcome of an ethanol gel product of pharmaceutical grade in VM. In theory, the comparison group in this study would be a patient group treated with a placebo (serum saline or at best test product vehicle). In practice, this design is not acceptable for the two following reasons: 1°) it appears unethical to invasively administer placebo infusion knowing that the placebo agent will have no effect, and that general anesthesia may be necessary in these patients; and 2°) it is technically impossible to elaborate a usable vehicle of the test product (the viscosing agent precipitates in non-alcoholic solutions). Similarly, a clinical study comparing ethanol gel vs solution was rejected based on the basis that the solution does not offer enough safety margin (high systemic exposure to ethanol with the solution). On the one hand, the use of ethanol solution is widespread and widely accepted, even as an “off-label” product. On the other hand, it is a dangerous product that requires special skill and handling. Local and systemic adverse events of ethanol solution are directly related to the amount of injected absolute alcohol. The administration of ethanol solution, which has the diffusion capacity of water, is rapidly washed-off from the lesion towards the blood circulation, resulting in high ethanol plasmatic levels (24% of patients above the 0.5 g/L⁻¹ intoxication limit, 13). Consequently, major acute complications may occur, including cardiac arrhythmia, bronchospasm and pulmonary embolism (14). Death, which has been observed in children at lower ethanol plasmatic ethanol levels (from 0.2 g/L⁻¹), has been reported (15). Furthermore, macroscopic hematuria may be observed at a high rate when carefully searched (16). Severe local complications such as extensive skin necrosis and nerve palsy with motor loss, which result from extensive diffusion of ethanol solution in the healthy tissue surrounding the treated lesion, are another issue (13,15). Accordingly, the risk/benefit assessment plan that was discussed before study initiation was clearly in defavor of a direct comparison between the gel and absolute alcohol in a large multicentric study. Instead, a direct comparison between the solution and the gel in a smaller study addressing the pharmacokinetic profile of both products was preferred (study in progress).

51
52
53
54
55
56
57
58
59
60
61
62
63
64
65

The therapeutic outcome evaluation system used in the study comprised both efficacy and safety components. By comparison with the size and clinical signs of the lesion at baseline session, ethanol gel was shown to be steadily effective in reducing completely lesional size or signs by about 15% after each session.

1 This resulted in a high therapeutic outcome of the gel at the end of the study, with 36% of
2 patients with a complete success (complete cure, no major side-effect) and 57% of
3 patients with a partial success (partial cure, no major side-effect). By comparison to
4 historical data with ethanol solution (1, 2, 4, 5, 6), ethanol gel greatly outperformed ethanol
5 solution as regard to therapeutic response, the safety component being the major
6 contributor for the benefit of the gel (data not shown).
7
8
9

10 One likely explanation is the viscous property of the gelified ethanol, which allows
11 controlled delivery into the lesion with no or low leakage into the venous draining system
12 and, therefore, instillation of relatively small amounts of the embolizing agent (higher
13 safety margin). In this study where escalating doses (maximum delivery dose of 5 mL
14 then 10 mL) were used sequentially during patient accrual, only 30-50% of the volume
15 used for contrast medium was necessary for achieving the therapeutic dose of the gel,
16 whereas 100% or more of the volume of contrast medium is often needed with the solution
17 (17). This also participates in the opinion of the authors that ethanol gel offers an easier
18 and better controlled handling than absolute ethanol does. Similarly, the better therapeutic
19 outcome of the gel is associated with a substantial benefit perceived by the patients, as
20 demonstrated by the significant reduction in pain, swelling and aesthetic damage at study
21 end.
22
23
24
25
26
27
28
29
30
31
32

33 The good safety profile of ethanol gel was confirmed by the very low systemic absorption
34 of ethanol in the study (mean \pm SEM: 0.03 \pm 0.06g/L) and a concentration below legal
35 intoxication limits in all cases except one. Thus, systemic exposure to ethanol with the gel
36 was by far lower than reported with the solution (2,13,18). Consequently, no systemic
37 adverse events related to test product was observed.
38
39
40
41

42 Although local adverse events were reported in a substantial number of cases (26.7% of
43 the infusions), a majority of them was post-infusion inflammatory signs (pain, swelling,
44 inflammatory reactions; 14.5%) that are also very common after infusions with ethanol
45 solution (3). Like with the solution, they remitted rapidly either spontaneously or under
46 symptomatic treatment course. Similarly, some local complications (7 skin necroses, 4%; 7
47 neuropathies, 4%) were those typically observed with ethanol solution. However, they
48 appeared to be less severe than with the solution (2,3,5,16,19,20). In large clinical series,
49 local complications following intra-lesional administration of ethanol solution occurred in 15
50 to 30% of the cases (13,15). This explains the better therapeutic outcome of the gel, as
51 shown in the study. Skin necroses and neuropathies spontaneously resolved with no
52 ultimate sequelae, which indicates in the latter that the motor function of the nerves
53
54
55
56
57
58
59
60
61
62
63
64
65

involved was not affected. Both may be prevented by excluding superficial VM and VM adjacent to a major nerve from ethanol gel treatment. Product leakage and fistula also occurred at the beginning of the study (2.3%), and could be secondarily prevented by placing the needle at small distance from the treated lesion. The other local complications (2 fibrous tissues/granuloma, 1 dense node) was more particularly described after Ethibloc infusions (11), and may be attributed to a granulomatous reaction with the viscosing agent ethylcellulose. Again, they resorb within months without any treatment.

In all patients, the fluoroscopy-guided injection of the gel permitted controlled and harmless infusion of a therapeutic dose of the gel, which corresponded to an amount as low as 15-50% of the contrast medium dose. According to our practice as well as the literature (17), this amount was definitely less than that commonly used with ethanol solution, i.e. by around 50%.

Conclusion

Ethanol gel was shown to provide favorable efficacy and safety profile in the treatment of venous malformations with no significant systemic absorption. Local side-effects were minimal and easily managed with no ultimate sequelae. VM adjacent to major nerve should be contra-indicated. Ethanol gel exerts its clinical effects at low dose.

References

- 1 [1] Goyal M, Causer PA, Armstrong D. Venous vascular malformations in pediatric
2 patients: comparison of results of alcohol sclerotherapy with proposed MR imaging
3 classification. *Radiology* 2002; 223:639-44.
- 4 [2] Berthelsen B, Fogdestam I, Svendsen P Venous malformations in the face and neck.
5 Radiologic diagnosis and treatment with absolute ethanol. *Acta Radiol Diagn (Stockh)*
6 1986; 27:149-55.
- 7 [3] Lee BB, Do YS, Byun HS, Choo IW, Kim DI, Huh SH. Advanced management of
8 venous malformation with ethanol sclerotherapy: mid-term results. *J Vasc Surg* 2003;
9 37:533-8.
- 10 [4] Rimon U, Garniek A, Galili Y, Golan G, Bensaid P, Morag B. Ethanol sclerotherapy of
11 peripheral venous malformations. *Eur J Radiol* 2004; 52:283-7.
- 12 [5] Shireman PK, McCarthy WJ, Yao JS, Vogelzang RL. Treatment of venous
13 malformations by direct injection with ethanol. *J Vasc Surg* 1997; 26:838-44.
- 14 [6] Yao Y, Lomis NN, Scott SM, Yoon HC, Miller FJ. Percutaneous sclerotherapy for
15 congenital venous malformations in the extremities. *Orthopedics* 2001; 24:45-51.
- 16 [7] Tiret I, Hecquard C, Leroyer R, et al. [Mise au point d'un gel sclérosant alcoolique
17 d'éthylcellulose utilisé pour le traitement des malformations veineuses] Formulation of
18 a sclerosing ethylcellulose alcoholic gel in the treatment of venous malformations.
19 *Journal de pharmacie clinique* 2001; 20:12-6.
- 20 [8] Sannier K, Dompmartin A, Théron J, et al. A new sclerosing agent in the treatment of
21 venous malformations. A study on 23 cases. *Interventional Neuroradiology* 2004;
22 10:113-27.
- 23 [9] Rao VR, Mandalam KR, Gupta AK, Kumar S, Joseph S. Dissolution of isobutyl 2-
24 cyanoacrylate on long-term follow-up. *AJNR Am J Neuroradiol* 1989; 10:135-41.
- 25 [10] Baud AV, Breton P, Guibaud L, Freidel M. [Treatment of low-pressure vascular
26 malformations by injection of Ethibloc. Study of 19 cases and analysis of
27 complications]. *Rev Stomatol Chir Maxillofac* 2000; 101:181-8.
- 28 [11] Riche MC, Hadjean E, Tran-Ba-Huy P, Merland JJ. The treatment of capillary-venous
29 malformations using a new fibrosing agent. *Plast Reconstr Surg* 1983; 71:607-14.
- 30 [12] Yakes WF, Luethke JM, Parker SH, et al. Ethanol embolization of vascular
31 malformations. *Radiographics* 1990; 10:787-96.
- 32 [13] Hammer FD, Boon LM, Mathurin P, Vanwijck RR. Ethanol sclerotherapy of venous
33 malformations: evaluation of systemic ethanol contamination. *J Vasc Interv Radiol*
34 2001; 12:595-600.
- 35 [14] Hanafi M, Orliaguet G, Meyer P, Blanot S, Brunelle F, Carli P. [Pulmonary embolism
36 in sclerotherapy for a venous malformation in a child under general anesthesia]. *Ann*
37 *Fr Anesth Reanim* 2001; 20:556-8.
- 38 [15] Mitchell SE, Shah AM, Schwengel D. Pulmonary artery pressure changes during
39 ethanol embolization procedures to treat vascular malformations: can cardiovascular
40 collapse be predicted? *J Vasc Interv Radiol*. 2006 ; 17:253-62.
- 41 [16] Berenguer B, Burrows PE, Zurakowski D, Mulliken JB. Sclerotherapy of craniofacial
42 venous malformations: complications and results. *Plast Reconstr Surg* 1999; 104:1-
43 11; discussion 12-15.
- 44 [17] Burrows PE and Mason KP. Percutaneous treatment of low flow vascular
45 malformations. *J. Vasc. Interv. Radiol*. 2004; 15:431-45.
- 46 [18] Mason KP, Michna E, Zurakowski D, Koka BV, Burrows PE. Serum ethanol levels in
47 children and adults after ethanol embolization or sclerotherapy for vascular
48 anomalies. *Radiology* 2000; 217:127-32.
- 49
- 50
- 51
- 52
- 53
- 54
- 55
- 56
- 57
- 58
- 59
- 60
- 61
- 62
- 63
- 64
- 65

[19] Pappas DC, Jr., Persky MS, Berenstein A. Evaluation and treatment of head and neck venous vascular malformations. *Ear Nose Throat J* 1998; 77:914-6, 918-22.

[20] Suh JS, Shin KH, Na JB, Won JY, Hahn SB. Venous malformations: sclerotherapy with a mixture of ethanol and lipiodol. *Cardiovasc Intervent Radiol* 1997; 20:268-73.

1
2
3
4
5
6
7
8
9
10
11
12
13
14
15
16
17
18
19
20
21
22
23
24
25
26
27
28
29
30
31
32
33
34
35
36
37
38
39
40
41
42
43
44
45
46
47
48
49
50
51
52
53
54
55
56
57
58
59
60
61
62
63
64
65

Tables

Table 1

Demographic data and lesional status of the study population (N = 75) before the first infusion of ethanol gel.

Variables	Values
Age (y):	
Mean ± SEM	24.5 ± 1.6
Min/max	3/62
Number of patients < 16 y	20 (27%)
Gender (N, %):	
Male	32 (43%)
Female	43 (57%)
Localisation of lesion (N, %)	
Head and neck	31 (41%)
Limbs	36 (48%)
Trunk	8 (11%)
Lesional size at MRI (cm³)	
Mean ± SEM	223 ± 75
Min/max	1.6/1539
Functional signs (N, %)	
Pain	47 (63%)
Swelling	64 (85%)
Aesthetic damage	58 (77%)
Severity of functional signs when present (VAS, mm):	
Pain (mean ± SEM)	29 ± 3.4
Swelling (mean ± SEM)	44 ± 3.5
Aesthetic damage (mean ± SEM)	39.7 ± 3.8
Objective signs (N,%):	
Clinical phlebolites	34 (45%)
Organ compression/bone or joint deformities	12 (16%)
Previous treatment history of the lesions (N, %):	
Embolosclerotherapy alone	14 (19%)
Surgery alone	13 (17%)
Both	9(12%)

Table 2

Efficacy outcome of ethanol gel 2 months after each session, compared to the initial size of lesion.

Sessions	N (%)	Score*			p-value
		0	1	2	
Session 1	75	7 (9%)	56 (75%)	12 (16%)	p < 0.0001
Session 2	52	6 (12%)	38 (73%)	8 (15%)	p < 0.0001
Session 3	27	0	23 (85%)	4 (15%)	p < 0.0001
Session 4	18	0	15 (83%)	3 (17%)	p < 0.0001

* 0 = no change, 1 = lesion size or signs reduced, 2 = lesion size or signs resolved.

Figures

1
2
3
4
5
6
7
8
9
10
11
12
13
14
15
16
17
18
19
20
21
22
23
24
25
26
27
28
29
30
31
32
33
34
35
36
37
38
39
40
41
42
43
44
45
46
47
48
49
50
51
52
53
54
55
56
57
58
59
60
61
62
63
64
65

Fig.1

Precipitation of ethanol gel (white) immediately after injection into a solution of sodium chloride

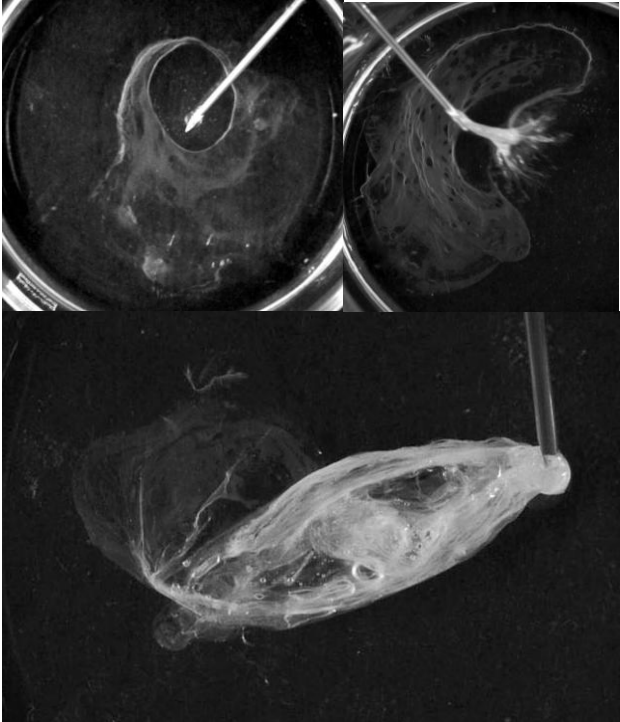


Fig. 2

Percutaneous puncture of the venous lesion and injection of contrast medium to opacify the size of the venous pouches to estimate the amount of sclerosing agent to be injected.

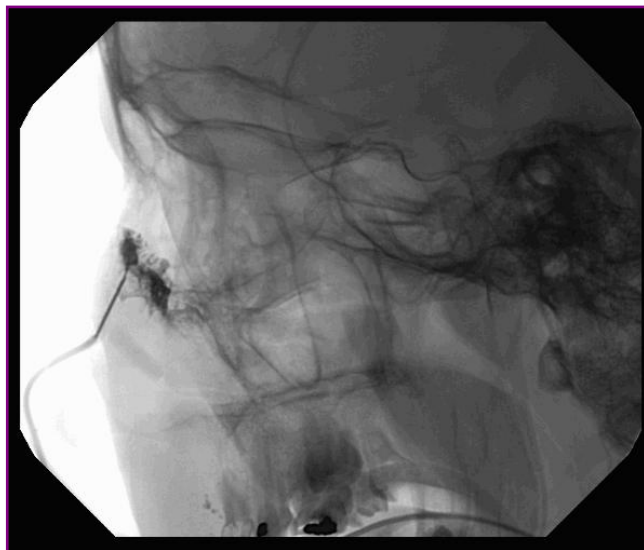
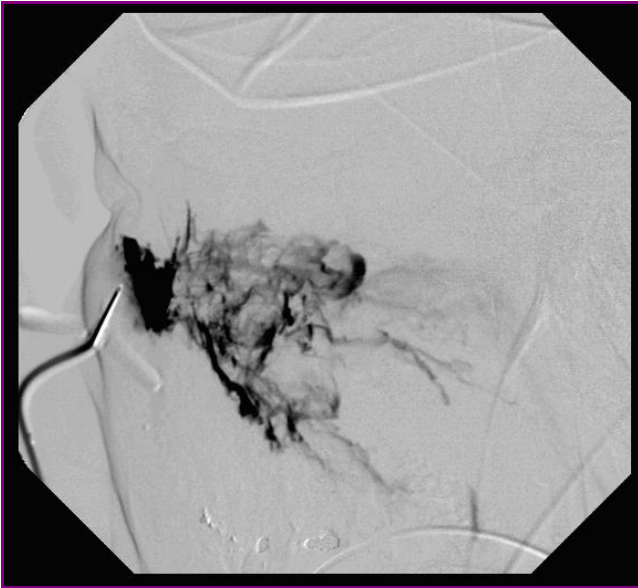
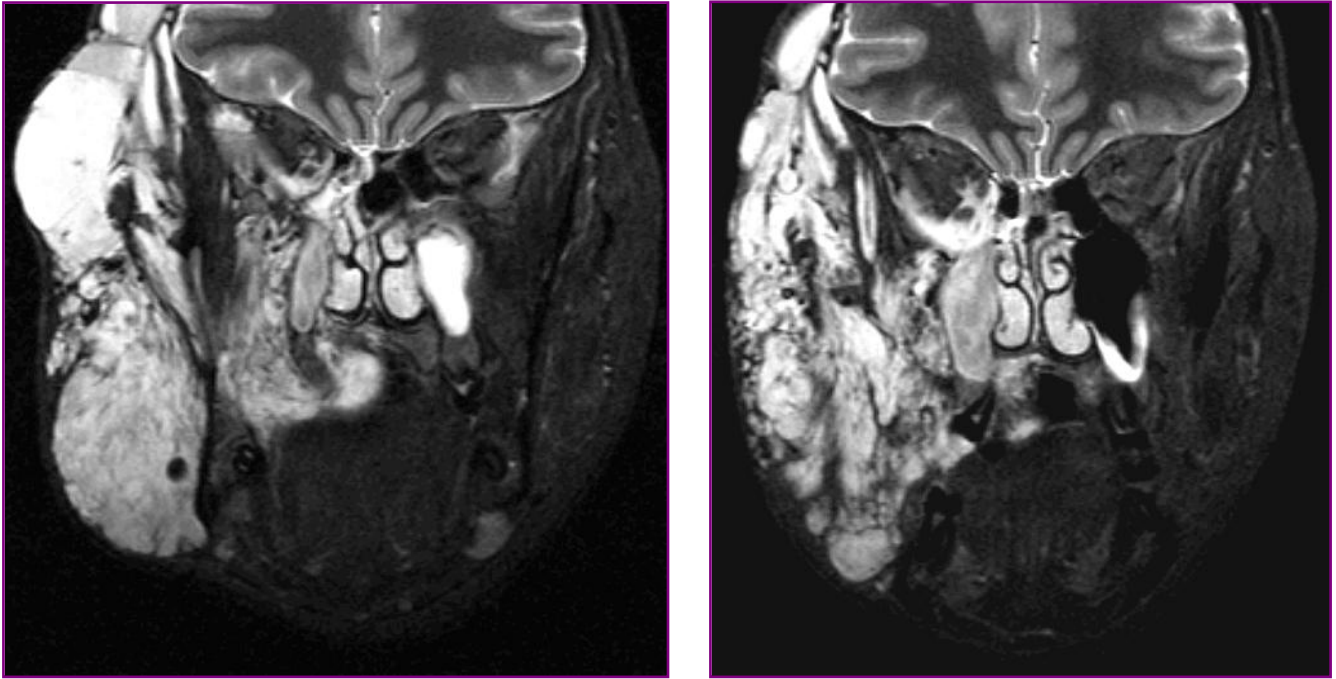


Fig. 3 a

1 **Coronar T2 MRI of a huge facial venous malformation before sclerotherapy (left) and**
2 **after two sessions of treatment with ethanol gel (right) showing a considerable**
3 **shrinkage of the large venous pouches.**
4
5



33 Fig. 3 b

34 Same patient as in 3 a before (left) and after (right) sclerotherapy with ethanol gel.
35
36

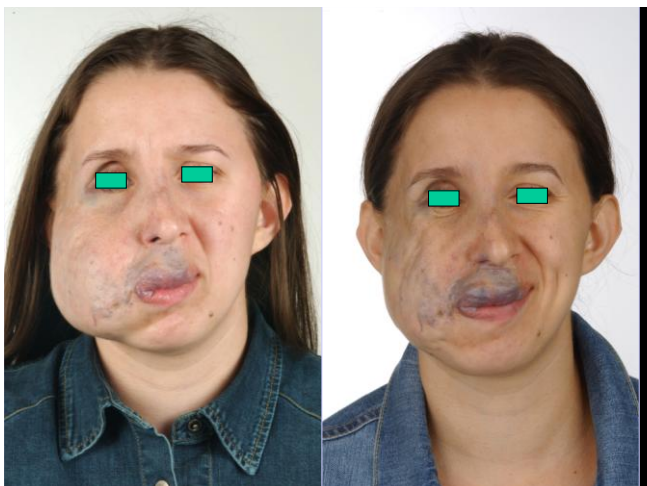
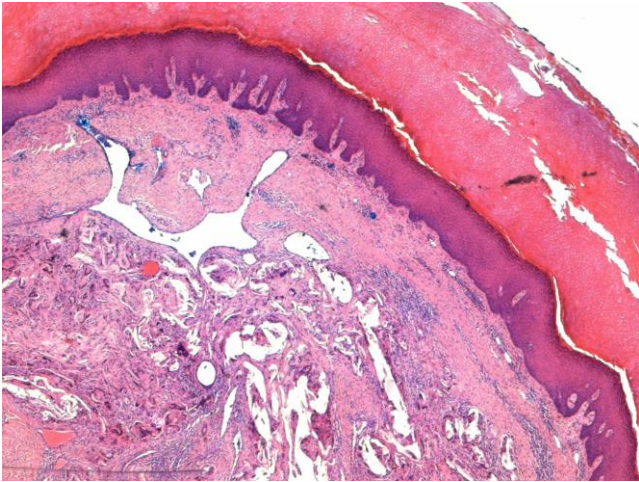


Fig. 4



Specimen of a VM 5 weeks after sclerosing therapy with ethanol gel. HE staining, 20 x, showing diffuse inflammatory reaction with development of a scar without destroying the endothelium (Courtesy of Ergin Kilic, Institute of Pathology, University Medical Center, Hamburg, Germany)

1
2
3
4
5
6
7
8
9
10
11
12
13
14
15
16
17
18
19
20
21
22
23
24
25
26
27
28
29
30
31
32
33
34
35
36
37
38
39
40
41
42
43
44
45
46
47
48
49
50
51
52
53
54
55
56
57
58
59
60
61
62
63
64
65

Tables

Table 1

Demographic data and lesional status of the study population (N = 75) before the first infusion of ethanol gel.

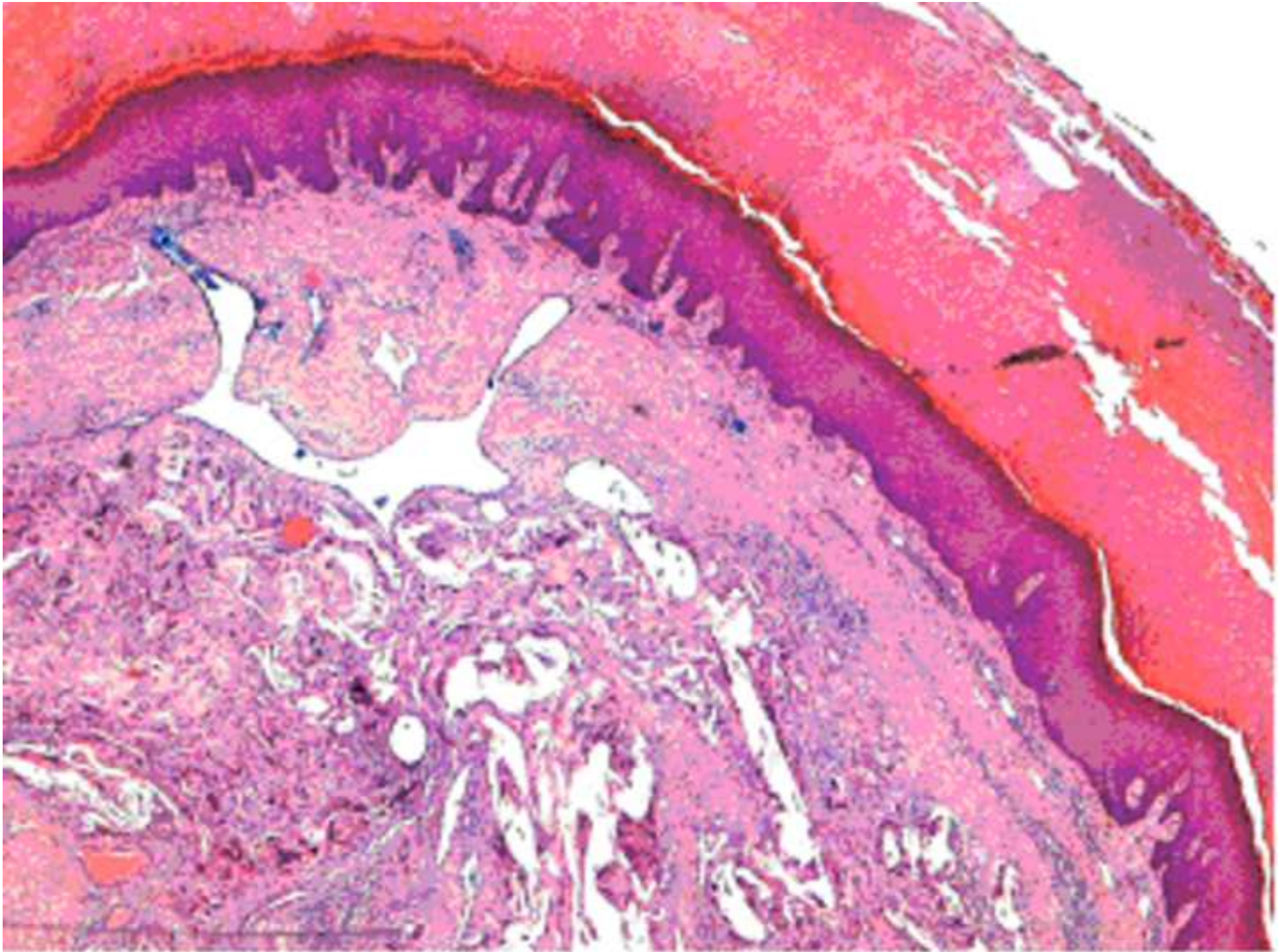
Variables	Values
Age (y): Mean \pm SEM Min/max	24.5 \pm 1.6 3/62
Number of patients < 16 y	20 (27%)
Gender (N, %): Male Female	32 (43%) 43 (57%)
Localisation of lesion (N, %) Head and neck Limbs Trunk	31 (41%) 36 (48%) 8 (11%)
Lesional size at MRI (cm ³) Mean \pm SEM Min/max	223 \pm 75 1.6/1539
Functional signs (N, %) Pain Swelling Aesthetic damage	47 (63%) 64 (85%) 58 (77%)
Severity of functional signs when present (VAS, mm): Pain (mean \pm SEM) Swelling (mean \pm SEM) Aesthetic damage (mean \pm SEM)	29 \pm 3.4 44 \pm 3.5 39.7 \pm 3.8
Objective signs (N,%): Clinical phlebolites Organ compression/bone or joint deformities	34 (45%) 12 (16%)
Previous treatment history of the lesions (N, %): Embolosclerotherapy alone Surgery alone Both	14 (19%) 13 (17%) 9(12%)

Table 2**Efficacy outcome of ethanol gel 2 months after each session, compared to the 2 months of no treatment preceding first session (Pre-treatment)**

Sessions	N (%)	Score*			p-value compared to pre-treatment
		0	1	2	
Pre-treatment	68	67 (99%)	1 (1%)	0 (0%)	
Session 1	75	7 (9%)	56 (75%)	12 (16%)	p < 0.0001
Session 2	52	6 (12%)	38 (73%)	8 (15%)	p < 0.0001
Session 3	27	0	23 (85%)	4 (15%)	p < 0.0001
Session 4	18	0	15 (83%)	3 (17%)	p < 0.0001

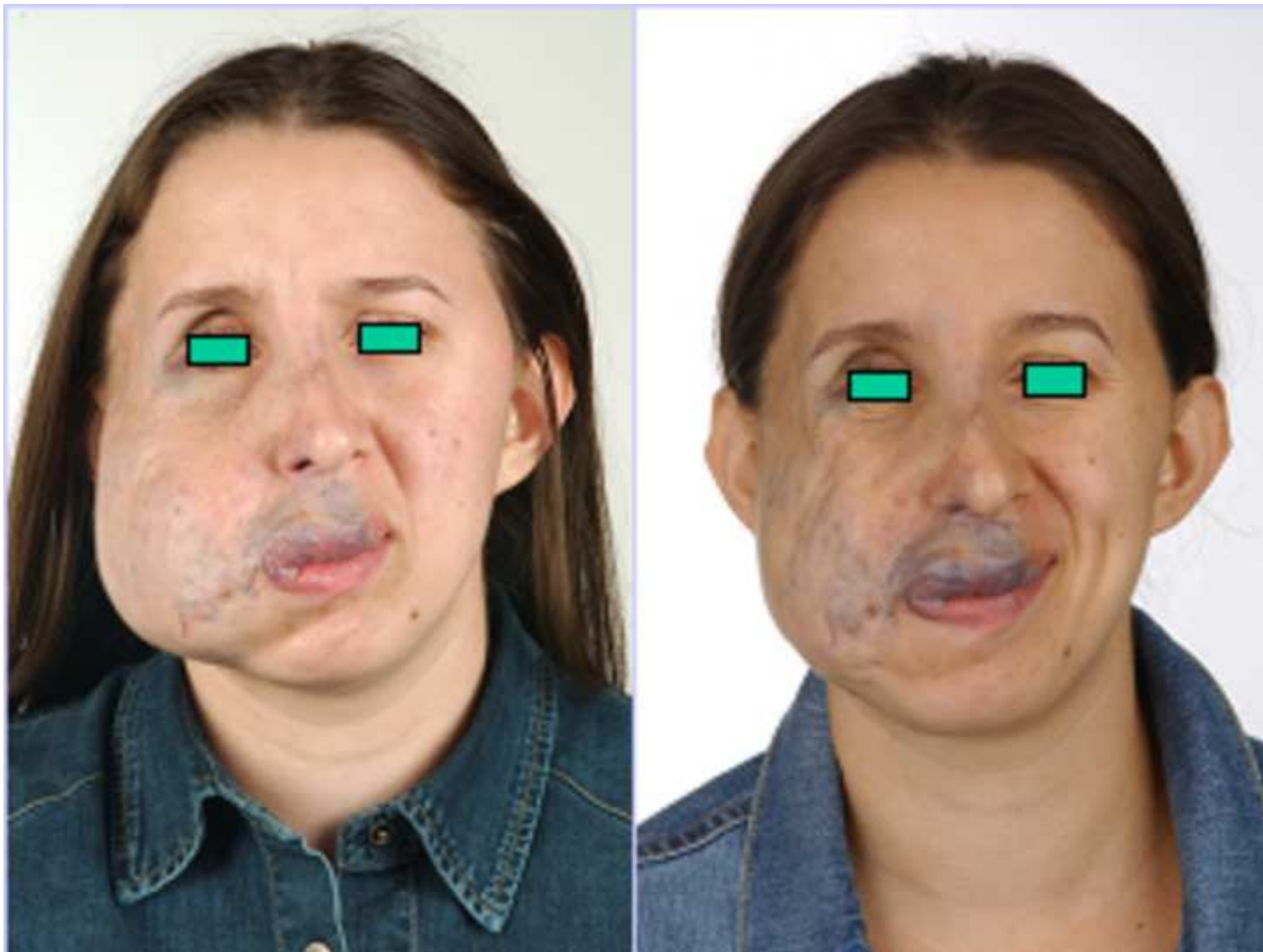
* 0 = no change, 1 = lesion size or signs reduced, 2 = lesion size or signs resolved.

Figure(s)
[Click here to download high resolution image](#)

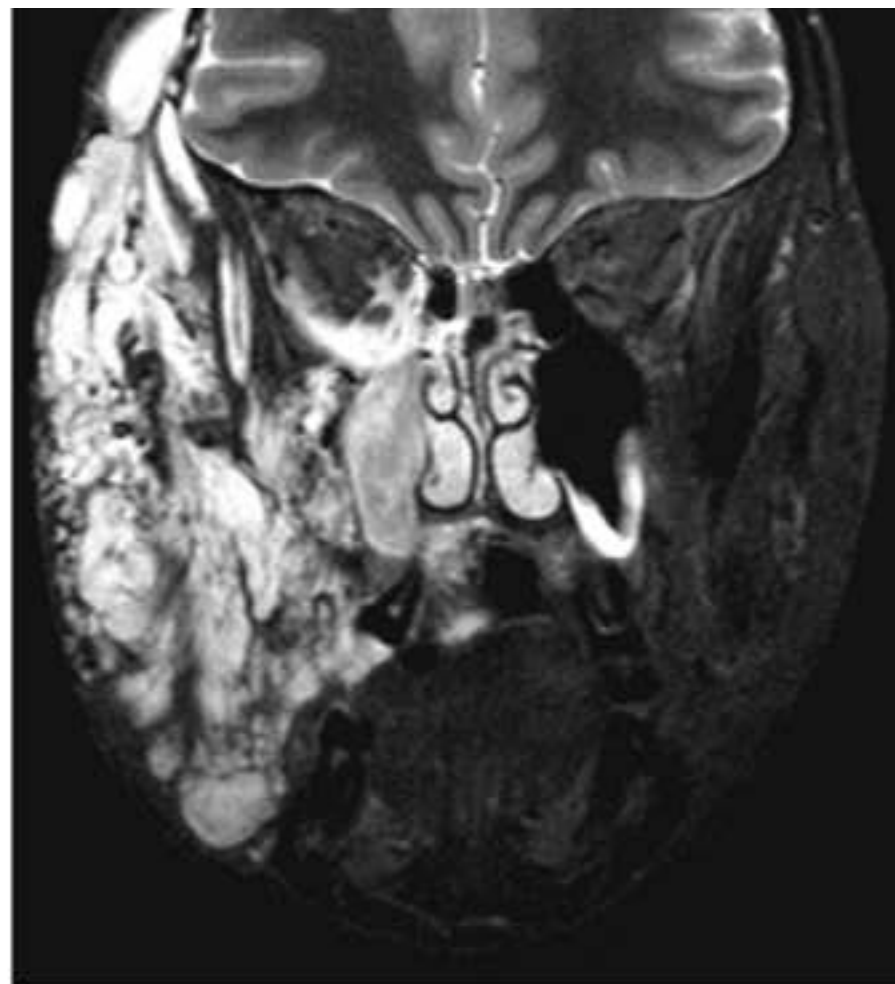
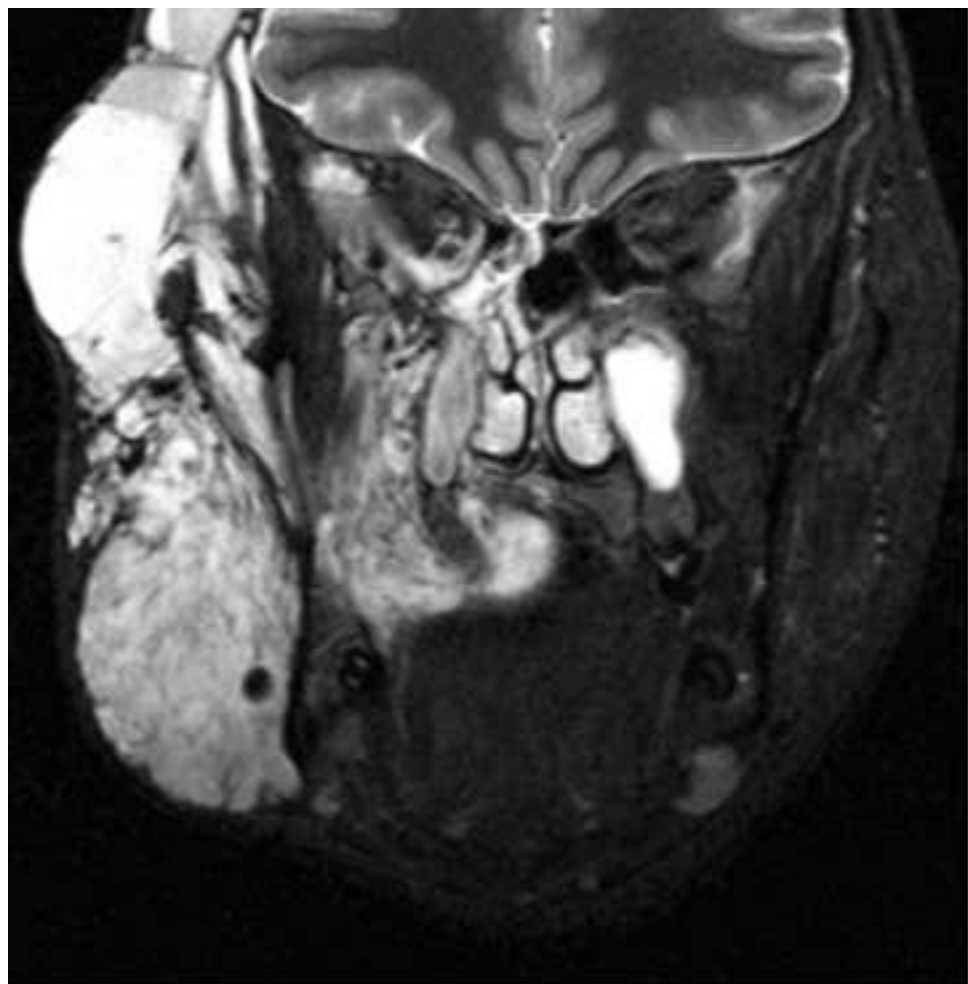


Figure(s)

[Click here to download high resolution image](#)

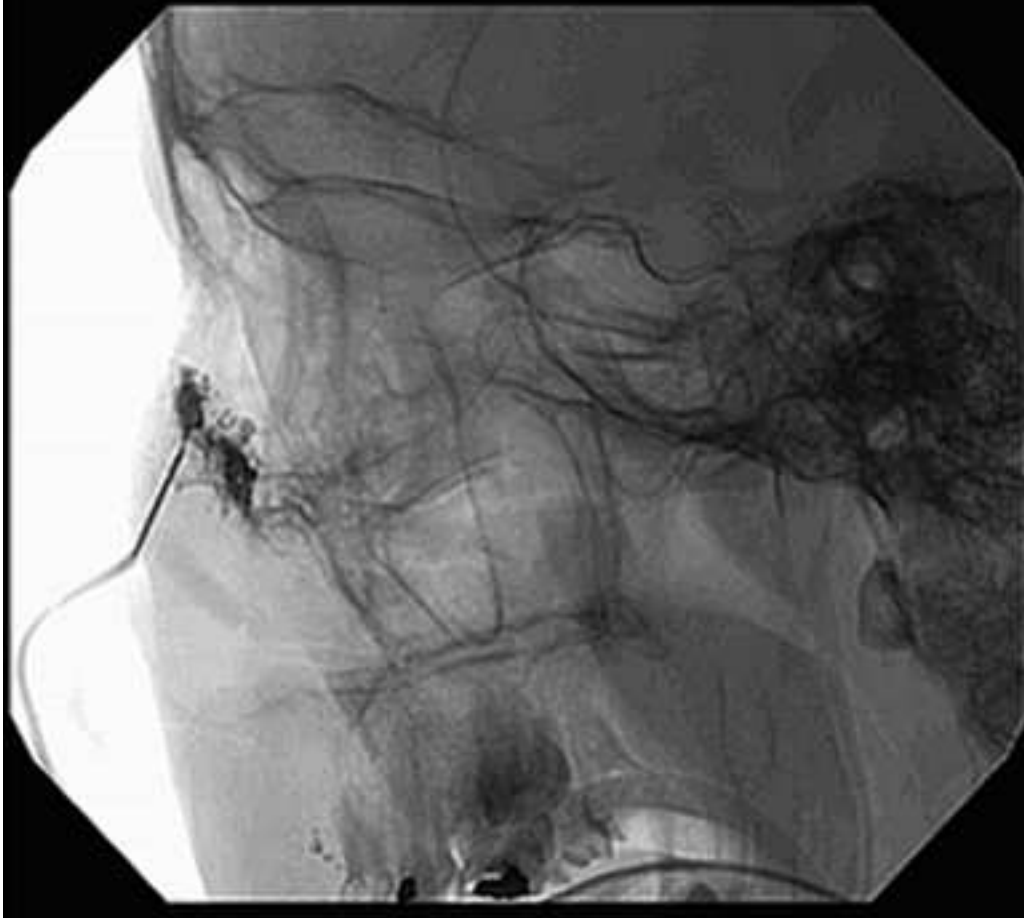
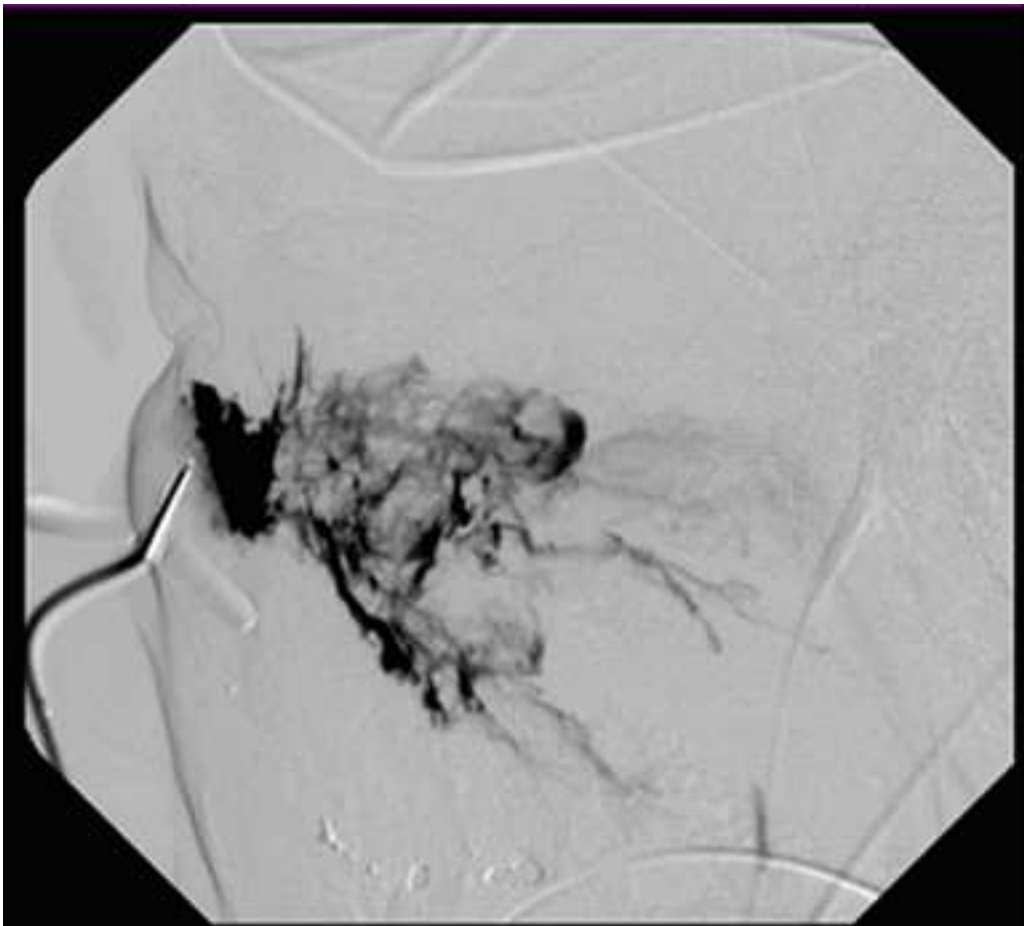


Figure(s)
[Click here to download high resolution image](#)

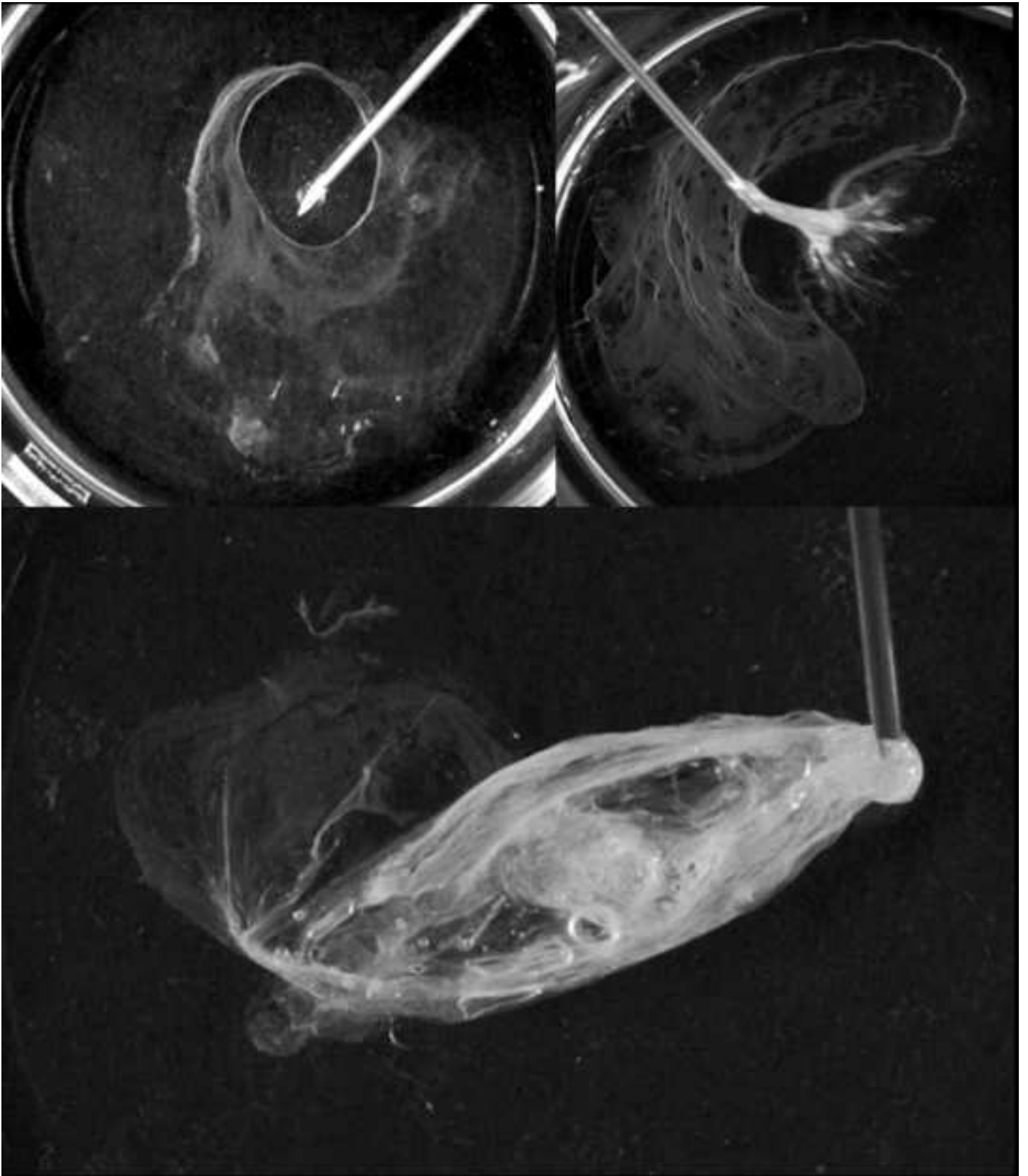


Figure(s)

[Click here to download high resolution image](#)



Figure(s)
[Click here to download high resolution image](#)



UNIVERSITÄTSKLINIKUM FREIBURG, Neurozentrum
Klinik für Neuroradiologie, Breisacher Str. 64, D-79106 Freiburg

To the Editor

**KLINIK FÜR NEURORADIOLOGIE
Neurozentrum**

Zertifiziert nach DIN EN ISO 9001

Ärztlicher Direktor: Prof. Dr. M. Schumacher

Tel: 0761/270-5180

Fax: 0761/270-5195

E-Mail: martin.schumacher.nrad @uniklinik-freiburg.de
www.uniklinik-freiburg.de/neuroradiologie

August 16, 2010

Ref: Treatment of venous malformations: First experience with a new sclerosing agent - a multicenter study
Martin Schumacher et al.

Dear Editor,

We submit the above-mentioned manuscript for publication. The list of authors is longer than regularly accepted, because the study is a multicenter investigation with contributions by participants from Germany, Italy and France. All authors contributed by recruiting patients, providing all treatment data and clinical follow-up and reviewed the manuscript mainly written by Martin Schumacher and Johannes Weber. We hope that all contributing colleagues can be accepted as co-authors. Additional to the signed forms of conflict of interest, we declare with this letter that there is no conflict of interest except of Patrick Dupuy and Corinne Ghienne who contributed as pharmacist and data monitors. Their conflict of interest derives from their position as employees of the sponsoring company.

We confirm, that the article is not under consideration for publication elsewhere. No separate parts of the publication have been sent by mail. The publication is approved by all authors and tacitly or explicitly by the responsible authorities were the work was carried out.

Sincerely yours,

Prof. Dr. M. Schumacher

Corresponding author:

Prof. Dr. Martin Schumacher
Clinic for Neuroradiology
University Hospital Freiburg
Breisacher Str. 64
D-79106 Freiburg
Tel. 0761/270-5180
Fax 0761/270-5195
E-Mail: martin.schumacher.nrad @uniklinik-freiburg.de

Treatment of venous malformations: First experience with a new sclerosing agent – a multicenter study

Martin Schumacher¹, MD
Patrick Dupuy², MD
Jean-Michel Bartoli³, MD
Ulrike Ernemann⁴, MD
Denis Herbreteau⁵, MD
Corinne Ghienne², Pharm.D.
Laurent Guibaud⁶, MD
Dirk A. Loose⁷, MD
Raul Mattassi⁸, MD
Philippe Petit⁹, MD
Jochen K. Rössler¹⁰, MD
Francesco Stillo¹¹, MD
Johannes Weber¹, MD

¹ Department of Neuroradiology, University Hospital Freiburg, Breisacher Str. 64, 79106 Freiburg, Germany

Tel.: ++49 761 2705180, Fax: 0049 761 2705195; E-Mail: martin.schumacher.nrad@uniklinik-freiburg.de; johannes.weber@uniklinik-freiburg.de

² Division of Research and Development, Orfagen, Parc Technologique du Canal, 4 rue Marie Curie, 31521 Ramonville, France

Tel. ++33 (0)562247678, Fax: ++33 (0)562247686, E-Mail: patrick.dupuy@orfagen.com; corinne.ghienne@orfagen.com

³ Department of Neuroradiology, Hôpital adultes de la Timone, Marseille, 264 rue Saint-Pierre, 13385 Marseille Cedex, France

Tel.: ++ 33 (0)4-91-32-43-95, Fax: ++33 (0)4-91-32-43-96, E-Mail: Jean-Michel.bartoli@ap-hm.fr

⁴ Department of Neuroradiology, University Hospital Tübingen, Hoppe-Seyler-Str. 3, 72076 Tübingen, Germany

Tel.: ++49 7071 2986024, Fax: ++49 7071 295638, E-Mail: ulrike.ernemann@med.uni-tuebingen.de

⁵ Department of Neuroradiology, Hôpital Bretonneau, Tours, 2, boulevard Tonnelle, Tours, Cedex, 37044 France

Tel.: ++33 (0)2 47 47 37 25, Fax: ++33 (0)2 47 47 47 84, E-Mail: herbreteau@med.univ-tours.fr

⁶ Department of Pediatric Radiology Hôpital Debrousse, 29, Rue Soeur Bouvier, 69005 Lyon, France

Tel.: ++33 (0)4 72 38 56 66, Fax: ++33 (0)4 72 38 58 61, E-Mail: laurent.guibaud@chu-lyon.fr

⁷ Department of Angiology and Vascular Surgery, Klinik Dr. Guth, Jürgensallee 46-48, 22609 Hamburg, Germany

Tel. ++33 (0)40 822810, Fax: ++33 (0)40 823945, E-Mail: info@prof-loose.de

⁸ Department of Vascular Surgery, Azienda Ospedaliera „Guido Salvini“ Milano, Italy

Tel.: ++39 02.994301, E-Mail: rmatassi@yahoo.it

⁹ Department of Paediatric Radiology Pr Devred, La Timone University Hospital, 264 rue St Pierre, 13385 Marseille Cedex, France

Tel. ++33 (0)491386797, Fax: ++33 (0)491387866, E-Mail: philippe.petit@mail.ap-hm.fr

¹⁰ Department of Pediatrics, University Hospital Freiburg, Mathildenstr. 1, 79106 Freiburg, Germany

Tel.: ++49 (0)761 2704514, Fax: ++49 (0)761 2704518, E-Mail: jochen.roessler@uniklinik-freiburg.de

¹¹ Istituto Dermopatico dell'Immacolata, Via Dei Monti Di Creta, 104, 00167 Roma (RM), Italy

Tel.: ++39 06.66.461, E-Mail: f.stillo@idi.it

P. Dupuy² at equal position with M. Schumacher

Funding information:

The study was sponsored by Orfagen, Ramonville, France.

Corresponding author:

Prof. Dr. Martin Schumacher
Department of Neuroradiology
University Hospital Freiburg
Breisacher Str. 64
D-79106 Freiburg

Tel. 0761/270-5180 - Fax 0761/270-5195
E-Mail: martin.schumacher.nrad @uniklinik-freiburg.de

UNIVERSITÄTSKLINIKUM FREIBURG, Neurozentrum
Klinik für Neuroradiologie, Breisacher Str. 64, D-79106 Freiburg

KLINIK FÜR NEURORADIOLOGIE
Neurozentrum

Zertifiziert nach DIN EN ISO 9001

Ärztlicher Direktor: Prof. Dr. M. Schumacher

Tel: 0761/270-5180

Fax: 0761/270-5195

E-Mail: martin.schumacher.nrad @uniklinik-freiburg.de
www.uniklinik-freiburg.de/neuroradiologie

To the Editor

August 16, 2010

Ref: Treatment of venous malformations: First experience with a new sclerosing agent - a multicenter study

Martin Schumacher et al.

Dear Editor,

We submit the above-mentioned manuscript for publication. The list of authors is longer than regularly accepted, because the study is a multicenter investigation with contributions by participants from Germany, Italy and France. All authors contributed by recruiting patients, providing all treatment data and clinical follow-up and reviewed the manuscript mainly written by Martin Schumacher and Johannes Weber. We hope that all contributing colleagues can be accepted as co-authors. Additional to the signed forms of conflict of interest, we declare with this letter that there is no conflict of interest except of Patrick Dupuy and Corinne Ghienne who contributed as pharmacist and data monitors. Their conflict of interest derives from their position as employees of the sponsoring company.

We confirm, that the article is not under consideration for publication elsewhere. No separate parts of the publication have been sent by mail. The publication is approved by all authors and tacitly or explicitly by the responsible authorities were the work was carried out.

Sincerely yours,

Prof. Dr. M. Schumacher

Corresponding author:

Prof. Dr. Martin Schumacher

Clinic for Neuroradiology

University Hospital Freiburg

Breisacher Str. 64

D-79106 Freiburg

Tel. 0761/270-5180

Fax 0761/270-5195

E-Mail: martin.schumacher.nrad @uniklinik-freiburg.de

UNIVERSITÄTSKLINIKUM FREIBURG, Neurozentrum
Abteilung für Neuroradiologie, Breisacher Str. 64, D-79106 Freiburg

Prof. Dr. Herwig Imhof
Editor-in-Chief
European Journal of Radiology

ABTEILUNG FÜR NEURORADIOLOGIE
Neurozentrum

Zertifiziert nach DIN EN ISO 9001

Ärztlicher Direktor: Prof. Dr. M. Schumacher

Tel: 0761/270-51800

Fax: 0761/270-51950

E-Mail: martin.schumacher.nrad@uniklinik-freiburg.de
www.uniklinik-freiburg.de/neuroradiologie

December 23, 2010/AFH

Ref. No.: HI 675-10

"Treatment of venous malformations: First experience with a new sclerosing agent - a multicenter study"
Martin Schumacher et al.

Dear Editor,

As required from reviewer #1 we changed our manuscript as follows:

General comments:

We accept, that it is indeed problematic for a non randomized study of a very slow growing venous malformation, to compare the results with a previous two months control period. Further we cancelled the comparison of our data with published historical data from the literature focussing only on effectiveness and safety.

In detail the following changes and corrections have been made:

Page 3, line 14-20 was deleted

Page 3, line 35-37 was deleted

Page 3, line 42: The new sentence "They included temporary mild isolated pain (N=21)....." was added.

Page 5, line 19-21 was deleted

Page 6, line 38: Two sentences were added: "This means, that a permanent slow injection of the agent was performed....."

Page 6, line 42-44 was deleted

Page 6, line 48-51 was modified: "The following management-driven scale integrating efficacy"

Page 6, line 59 to page 7 line 24 was deleted and a new text added: "Other evaluation parameters included the security of the function signs"

Page 7, line 60 to page 8 line 11 was deleted

Page 8, line 31-35 was deleted

Page 8, line 61: Additional text was added: ("Analgesics, antiinflammatories....."

Page 11, line 58 to page 12, line 3 was deleted and a modified text was added: "This resulted in a high therapeutic outcome of the gel"

Page 12, line 19-21 was deleted

Page 17, legend of table 2 has been modified. In the same table line 12 "Pre-treatment" has been deleted in order not to reference to a pre-treatment two months control period.

Page 18, table 3 has been deleted.

Reviewers detail requirements were:

1. "Type and duration of the nominal therapy": This has been described on page 9 (final manuscript)
2. "The mean duration of the reversible complications" have been described on page 7 (final manuscript).
3. "The functional results of the irreversible complications needing surgery" have been described on page 9.

We thank for the valuable proposals and hope that we were able to correctly modify our manuscript.

With kind regards,
Sincerely

Prof. Dr. M. Schumacher