



**HAL**  
open science

## Automatic evaluation of the peri-infarct area of myocardial infarction from delayed enhancement MRI

Alain Lalande, Vanya V. Valindria, Marion Angue, Nicolas Vignon, Alexandre Cochet, François Brunotte

► **To cite this version:**

Alain Lalande, Vanya V. Valindria, Marion Angue, Nicolas Vignon, Alexandre Cochet, et al.. Automatic evaluation of the peri-infarct area of myocardial infarction from delayed enhancement MRI. European Society for Magnetic Resonance in Medicine and Biology (ESMRMB), Oct 2012, Lisbonne, Portugal. pp.123. hal-00787301

**HAL Id: hal-00787301**

**<https://hal.science/hal-00787301>**

Submitted on 11 Feb 2013

**HAL** is a multi-disciplinary open access archive for the deposit and dissemination of scientific research documents, whether they are published or not. The documents may come from teaching and research institutions in France or abroad, or from public or private research centers.

L'archive ouverte pluridisciplinaire **HAL**, est destinée au dépôt et à la diffusion de documents scientifiques de niveau recherche, publiés ou non, émanant des établissements d'enseignement et de recherche français ou étrangers, des laboratoires publics ou privés.

Abstract 45432

Automatic evaluation of the peri-infarct area of myocardial infarction from delayed enhancement MRI

Category: Scientific Session Communications

Topic: Preclinical Studies and Basic Science / Processing and quantification: imaging

Authors: A. Lalande<sup>1,2</sup>, V. Valindria<sup>2</sup>, M. Angue<sup>1</sup>, N. Vignon<sup>1</sup>, A. Cochet<sup>1,2</sup>, F. Brunotte<sup>1,2</sup>; <sup>1</sup>Dijon,FR,University Hospital of Dijon,Department of MR Spectroscopy, <sup>2</sup>Dijon,FR,University of Burgundy,LE2I (UMR CNRS 6306)

### Purpose / Introduction

Delay Enhancement - Magnetic Resonance Imaging (DE-MRI) can be considered as the gold standard for the assessment of myocardial viability after myocardial infarction (MI). Around the infarcted areas that appear with hyper-enhanced signal, there is a peri-infarct border zone that may be an important arrhythmogenic substrate. The extent of this area is an independent predictor of post-MI mortality (1). However, it is difficult to separate peri-infarct border zones from infarct core or normal areas, because of their intermediate signal intensity. We propose a new automatic approach to detect this area, based on a modified Gaussian Mixture Model (GMM) and spatial-weighted fuzzy clustering.

### Subjects and Methods

DE-MRI images were acquired with PSIR sequence 10 minutes after injection of a gadolinium-based contrast agent on 20 patients with acute MI. A series of short axis slices cover the left ventricle. Myocardial borders were manually drawn. The myocardium area was segmented as normal and pathologic areas via a GMM. By considering all images, the false positive pixels are eliminated thanks to 3D connectivity analysis and feature analysis. Using assumptions that pixels of the peri-infarct area have a signal intensity intermediate between remote myocardium and infarct core, and that their location is surrounding the infarct core, spatial fuzzy clustering allows their detection, modifying the initial GMM (Figure 1). No reflow was defined as a dark area surrounded by MI area. The automatic segmentation was visually evaluated by three independent observers, by classifying the quality of the segmentation from 1 (very poor

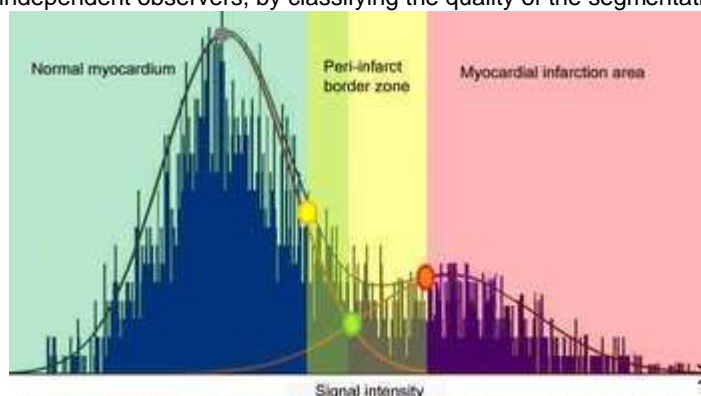


Figure 1: Signal histogram with the cluster of the myocardium area by a modified Gaussian mixture model (in a case without no-reflow area).

segmentation) to 5 (perfect).

### Results

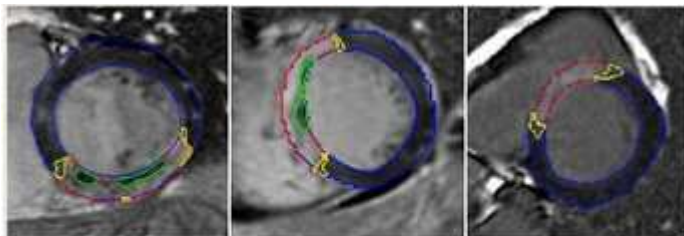


Figure 2 : Examples of the automatic segmentation of the myocardial areas. Infarct core in red, peri-infarct area in yellow and no-reflow area in green.

Figure 2 show examples of segmentation. The overall scores of the visual evaluation are high (table 1), validating the robustness of our method. However the score for the peri-infarct area is the smallest, perhaps because the gray-zone is also very hard to be seen by the human eye.

Table 1: Visual evaluation results

	Infarct core	Peri-infarct area	No-reflow area
Mean	4.69	4.35	4.72
Standard deviation	0.69	0.81	0.86

### **Discussion/Conclusion**

This paper presents a promising contribution for automatic segmentation of infarct area, and particularly for the detection of the peri-infarct border zone. Compared with previous publications (1-3), our main contributions consist in the 3D connectivity analysis, the use of a priori information concerning the area shapes and the spatial fuzzy clustering to define the pixels of the peri-infarct areas.

### **References**

- (1) Yan, A.T. et al, 2006, Circulation, 32-39.
- (2) Schmidt, A. et al, 2007, Circulation, 2006-2014.
- (3) Hundley, W.G. et al, 2010, JACC, 2614-2664.

Print