



**HAL**  
open science

## Antibiotic treatment for acute haematogenous osteomyelitis of childhood: moving towards shorter courses and oral administration

M. Pääkkönen, H. Peltola

► **To cite this version:**

M. Pääkkönen, H. Peltola. Antibiotic treatment for acute haematogenous osteomyelitis of childhood: moving towards shorter courses and oral administration. *International Journal of Antimicrobial Agents*, 2011, 38 (4), pp.273. 10.1016/j.ijantimicag.2011.04.007 . hal-00725396

**HAL Id: hal-00725396**

**<https://hal.science/hal-00725396>**

Submitted on 26 Aug 2012


**HAL** is a multi-disciplinary open access archive for the deposit and dissemination of scientific research documents, whether they are published or not. The documents may come from teaching and research institutions in France or abroad, or from public or private research centers.

L'archive ouverte pluridisciplinaire **HAL**, est destinée au dépôt et à la diffusion de documents scientifiques de niveau recherche, publiés ou non, émanant des établissements d'enseignement et de recherche français ou étrangers, des laboratoires publics ou privés.

## Accepted Manuscript

Title: Antibiotic treatment for acute haematogenous osteomyelitis of childhood: moving towards shorter courses and oral administration

Authors: M. Pääkkönen, H. Peltola



PII: S0924-8579(11)00197-X  
DOI: doi:10.1016/j.ijantimicag.2011.04.007  
Reference: ANTAGE 3609

To appear in: *International Journal of Antimicrobial Agents*

Received date: 30-3-2011  
Accepted date: 5-4-2011

Please cite this article as: Pääkkönen M, Peltola H, Antibiotic treatment for acute haematogenous osteomyelitis of childhood: moving towards shorter courses and oral administration, *International Journal of Antimicrobial Agents* (2010), doi:10.1016/j.ijantimicag.2011.04.007

This is a PDF file of an unedited manuscript that has been accepted for publication. As a service to our customers we are providing this early version of the manuscript. The manuscript will undergo copyediting, typesetting, and review of the resulting proof before it is published in its final form. Please note that during the production process errors may be discovered which could affect the content, and all legal disclaimers that apply to the journal pertain.

## Antibiotic treatment for acute haematogenous osteomyelitis of childhood: moving towards shorter courses and oral administration

M. Pääkkönen<sup>a,b,\*</sup>, H. Peltola<sup>a</sup>

<sup>a</sup> *Helsinki University Central Hospital, Hospital for Children and Adolescents, Helsinki, Finland*

<sup>b</sup> *Turku University Hospital, Turku, Finland*

### ARTICLE INFO

#### *Article history:*

Received 30 March 2011

Accepted 5 April 2011

#### *Keywords:*

Osteomyelitis

Child

Clindamycin

First-generation cephalosporin

\* Corresponding author. Present address: Turku University Hospital, P.O. Box 52, 20521 Turku, Finland. Tel.: +358 2 313 5092; fax: +358 2 313 3613.

*E-mail address:* Markus.Paakkonen@helsinki.fi (M. Pääkkönen).

## ABSTRACT

Acute haematogenous osteomyelitis (AHOM) of childhood usually affects the long bones of the lower limbs. Although almost any agent may cause AHOM, *Staphylococcus aureus* is the most common bacterium, followed by *Streptococcus pneumoniae* and, in some countries, *Salmonella* spp. and *Kingella kingae*. Magnetic resonance imaging (MRI) has improved the diagnostic accuracy of traditional radiography and scintigraphy. Except for the pre-treatment diagnostic sample from bone before the institution of antibiotic therapy, no other surgery is usually required. Traditionally, non-neonatal AHOM has been treated with a 1–3-month course of antibiotics, including an intravenous (i.v.) phase for the first weeks, but recent prospective randomised studies challenge this approach. For most uncomplicated cases, a course of 20 days including an i.v. period of 2–4 days suffices, provided large enough doses of a well absorbed agent (clindamycin or a first-generation cephalosporin, local resistance permitting) are used, administration is four times daily and most symptoms and signs subside within a few days. Serum C-reactive protein (CRP) is a good guide in monitoring the course of illness, and the antimicrobial can usually be discontinued if CRP has decreased to <20 mg/L. Newer and costly agents, such as linezolid, should be reserved for cases due to resistant *S. aureus* strains. AHOM in neonates and immunocompromised patients probably requires a different approach. Because sequelae may develop slowly, follow-up for at least 1 year post hospitalisation is recommended.

## 1. Introduction

Acute haematogenous osteomyelitis (AHOM) is defined as an acute infection of the bone or bone marrow diagnosed within 2 weeks from the onset of signs and symptoms [1,2]. Further definitions vary, but the usual consensus is that if the history is longer than 2 weeks the disease is subacute, and if much longer (months) then osteomyelitis is chronic.

AHOM may affect any bone of the body, although most cases are found in the long bones of the lower limbs (Figs 1 and 2) [1,3]. The humerus is the most common location in the upper limb. Of the non-tubular bones, the calcaneus is especially prone as it is affected in 10% of cases [3]. Males experience AHOM more often than females, with the ratio being 2.0:1.2 [4]. Following the neonatal period, a small peak occurs at early school age (Fig. 1). The proneness of boys is explained by strenuous physical activity that leads to mini trauma caused by overloading of the growing bone structures. The same gender and age differences have been observed in many countries and for all the causative agents [5,6].

## 2. Pathogenesis

The routes by which bacteria reach a bone are direct spread from an adjacent infected soft tissue or joint, direct inoculation during trauma or a surgical procedure, or by haematogenous seeding [1,4]. In children, haematogenous spread is most common. The anatomy of growing bone plays a major role in the pathogenesis. AHOM usually commences from the metaphysis of a long tubular bone. As already suggested in the 1920s [7], sluggish blood flow in the sinusoids of the epiphyseal–

metaphyseal junction and a defective reticuloendothelial system with impaired phagocytosis allow bacteria to stick in the sinusoidal structures [4,8]. It also has been hypothesised that AHOM develops by two different mechanisms [9]. The more common is local: blunt trauma causes oedema and haematoma and this local process is secondarily infected haematologically by bacteria that occasionally gain access to the bloodstream. Alternatively, one or multiple non-traumatised locations are infected during primary septicaemia [9].

In contrast to adults, chronic osteomyelitis and AHOM complicating prosthetic surgery or following an underlying illness are rare in children of high-income countries. In the developing world the situation is reversed, as AHOM and chronic disease are rampant. A sad reality is that these patients often have a history of failed or absent primary treatment, or one may find an underlying illness such as human immunodeficiency virus (HIV) infection or malaria [10].

### *2.1. Important distinction between infection and inflammation*

An important concept to recognise is the difference between infection and inflammation (a host response). Inflammation is often triggered by infection, but these phenomena are not synonymous. Infection is treated, of course, with antibiotics, whereas halting inflammation requires other agents such as non-steroidal anti-inflammatory drugs. Recognising this important difference has direct reflections on treatment.

No less than 70 years ago, Penberthy and Weller showed that AHOM sometimes healed with a 3-day course of sulphonamides [11]. However, the fact that the

infection was cured did not necessarily imply that the entire disease process was over. Complications of AHOM may develop slowly, even long after discontinuation of antibiotics. This is because the host continues its 'response' by maintaining inflammation and osteoblast activity, which ultimately heal the destruction of AHOM.

In Africa, up to three out of four pathological fractures are due to 'chronic osteomyelitis' [12]. An assumed reason is that the initial antibiotic treatment did not end the infection but allowed a chronic process and further bone destruction. This might be the case, but in our opinion the sequence described in Fig. 3 may also take place: infection was terminated, but longstanding inflammation may lead to pathological fracture, which is a risk if the affected bone is not supported with a splint or other device for weeks after initial 'healing'.

### **3. Causative organisms and susceptibility to antibiotics**

*Staphylococcus aureus* is overwhelmingly the most common causative organism (Fig. 1). *Staphylococcus aureus* was initially susceptible to penicillin, but penicillinase production was reported early [13]. Antistaphylococcal penicillins, such as cloxacillin [14], methicillin and flucloxacillin, were adopted for use, followed by cephalosporins. Another line in the development of new agents was the class of lincosamides (lincomycin and clindamycin). Then, the 1990s saw a new problem, methicillin-resistant *S. aureus* (MRSA). Most of these strains were not more virulent than methicillin-sensitive *S. aureus*, but in the recent years the hypervirulent MRSA USA300 strain [15] has emerged. Details of this development of hypervirulence are not fully understood [16].

These unwelcome events have forced the search for alternative treatments.

Clindamycin is still an option in many cases of MRSA [17], but vancomycin or (costly) linezolid are among the alternatives if clindamycin resistance is encountered [18].

Since susceptibility varies from country to country, some authors have suggested taking into account the prevalence of resistance in the community (Table 1) [2].

Streptococci are generally the second most common causative agents in AHOM, responsible for 10–15% of cases [3]. *Streptococcus pyogenes* remains invariably susceptible to penicillin, whereas *Streptococcus pneumoniae* has shown a somewhat lessened minimal inhibitory concentration (MIC). The prevalence of penicillin 'resistance' depends on the breakpoint used. Using a low MIC value of 0.12 µg/mL, resistance could be as high as 35%, whilst the current definition for pneumococcal full resistance is at an MIC of 8 µg/mL. This cut-off decreases the prevalence to a mere 0.24% [23]. Overall, high-dose penicillin G may be used as a first-line agent in pneumococcal AHOM, especially if high doses and four times daily (q.i.d.) dosing are used. However, because of better palatability and absorbance, high-dose ampicillin or amoxicillin is well justified for oral therapy.

For unknown reasons and in contrast to septic arthritis, *Haemophilus influenzae* type b (Hib) causes AHOM infrequently. Large-scale Hib vaccination has essentially eradicated Hib diseases in many affluent countries [24,25], but this aetiology should be borne in mind in an unvaccinated child under 5 years who presents with AHOM with adjacent septic arthritis (AHOM+SA). Depending on the prevalence of β-lactamase production in the region, ampicillin/amoxicillin or a second- or third-



generation cephalosporin are the first-line antibiotics for  $\beta$ -lactamase-negative and -positive Hib infections, respectively.

In some countries, *Kingella kingae* is an important organism. In Israel, it even surpasses *S. aureus* in joint infections [19–21]. The pathogen is difficult to culture [26,27], but this problem alone does not explain the differences between countries. This said, *K. kingae* has been encountered in AHOM with increasing frequency in some regions [28]. In Switzerland, it caused 23/43 cases (53%) of osteoarticular infections in children under 4 years [27].

*Salmonella* spp. are found rarely in high-income countries, but if detected the patient often has some immunodeficiency [29]. In contrast, *Salmonella* AHOM is rather common in the tropics where it may cause up to 71% of cases in patients with sickle cell disease [30]. Inexpensive trimethoprim/sulfamethoxazole, ampicillin and chloramphenicol used to be good therapeutic choices, but today resistance problems have made *Salmonella* AHOM more complicated; usually, ceftriaxone is still effective [31]. Fluoroquinolones are also effective, but the fear of joint/cartilage destruction hinders their paediatric use. However, this problem has been encountered only in animal experiments, not in children [32]. Therefore, quinolones are accepted in the treatment of severe invasive *Salmonella* infections if no safer alternative is available [33,34].

#### **4. Clinical manifestations**

Classical AHOM manifests as local pain in the affected limb. A distinctive feature is gradual worsening of the symptoms and signs within days [3,4]. Local swelling and

redness may be present, more commonly in infants and young children, but may be inconspicuous and appear only after spread of the infection to beneath the periosteum (subperiosteal). Fever is common, but may be absent, as shown by a series of *K. kingae* AHOM in which fewer than 15% of patients presented with a body temperature  $>38.5$  °C [35]. Any bone can be affected, but again the long bones of the lower limbs are most prone. A small child presenting limping or unwilling to use a limb should raise suspicion of AHOM. Usually the child is less ill than a patient with septic arthritis. Antecedent trauma may have taken place [9]. If so, infection is sometimes shadowed by signs of trauma.

AHOM+SA manifests as limited motion of the adjacent joint. As one would expect, these children are clinically more ill than those with plain AHOM. C-reactive protein (CRP) and the erythrocyte sedimentation rate (ESR) are higher [36]. Occasionally, septic arthritis is found in a non-adjacent joint and this surprising event is explained by haematogenous seeding [9].

## 5. Diagnosis

A scheme for the management of AHOM is depicted in Fig. 4. Once the child's history and clinical symptoms and signs suggest AHOM, serum CRP and ESR should be determined, because at presentation they almost always exceed 20 mg/L and 20 mm/h, respectively [36–38]. Occasionally, the first CRP value remains non-increased, whilst the ESR is increased [36]; therefore, measurement of both indices on admission is beneficial. Later on, follow-up of CRP alone suffices [36].

If CRP is  $<20$  mg/L or ESR is  $<20$  mm/L and the history is  $>6-12$  h [36–38], AHOM is so unlikely that mere observation is justified, keeping in mind other diagnostic alternatives. However, should one of these unspecific, though reliable, parameters be increased, blood culture and diagnostic bone aspiration are to be performed [3]. If discharge is obtained, it should be cultured; if not, the aspiration needle is sent for bacterial culture. Blood culture is important because ca. 40% of AHOM is only blood culture-positive [3].

The diagnosis can be tricky. An old clinical wisdom says that unless the history is a fortnight or so (rare), a radiograph without lytic changes more supports than discards the diagnosis of AHOM. However, newer imaging techniques have changed the picture. In particular, magnetic resonance imaging (MRI) improves the chances of making the correct diagnosis swiftly because it detects inflammatory changes in and around bone early. Computerised tomography (CT) is also valuable, particularly as it detects a sequestrum and other bone changes such as pathological fractures [39]. In contrast to septic arthritis, ultrasound is of lesser importance. Scintigraphy is another traditional method [40]. It still defends its position against MRI, since among 213 cases it equalled MRI in sensitivity, with 100% for both methods [41]. In our own series of 131 bacteriologically proven AHOM, the bone scan was initially negative in 4 cases (3%) [3].

Besides MRI, positron emission tomography (PET) or single-photon emission computed tomography (SPECT) are very sensitive and specific diagnostic methods in various osteomyelitides [39,42]. However, MRI has gained popularity because it shows the extent of infection. The bone scan is not helpful in detecting abscesses,

adjacent pyomyositis or fasciitis [42]. Using gadolinium contrast in MRI remains controversial and should not be used routinely as non-contrast MRI usually suffices [43]. Moreover, fat-suppressed contrast-enhanced MRI does not add to the sensitivity or specificity of the diagnosis, albeit it may bring a little more information in the search for an abscess [44]. Repeated MRI is indicated only if the recovery is not as expected, although even then the information thus obtained changes the treatment for only 10% of patients [45]. In vertebral osteomyelitis, repeated MRI might be useful because the endplate subchondral changes are sometimes unspecific and benign [46].

## **6. Acute haematogenous osteomyelitis complicated with adjacent septic arthritis**

Concurrent adjacent septic arthritis appears to occur more often in AHOM than realised, as joint involvement has been found in up to one-third to one-half of cases [8,47]. Neonates are especially prone to AHOM+SA [4,8], probably because of the transphyseal blood vessels that may persist for up to 18 months [8]. In older children, joint involvement is considered a special risk in the hip and shoulder regions (and, to some extent, the ankle), since the entire joint is intracapsular [4,48]. Contrary to this concept, one series on AHOM [8] showed that the most commonly affected joint was the knee. In our series (Fig. 2), spread from the proximal tibia to the knee was especially common [3].

As one would expect, AHOM+SA triggers a fiercer inflammatory response, which one can see by high CRP levels and ESR [36,48,49]. Many experts share the opinion that

AHOM+SA commences from AHOM [3,9], but we see no reason why the sequence could not also be vice versa. Current literature shows little data on either way.

## 7. Choosing the antibiotic

If a relevant bacterium is identified from the local specimen or blood culture, choosing the antibiotic is rather simple: some current recommendations are listed in Table 1. More of a problem is the first-line 'empirical' selection, as are cases in which no aetiology is identified. If so, one should first re-evaluate the patient asking oneself whether he or she has AHOM at all.

The antimicrobial should cover the common pathogens in the region, taking into account the resistance pattern. For years clindamycin or a first-generation cephalosporin have been used [36] and both have worked well in circumstances where MRSA is uncommon. These inexpensive agents are notably well tolerated by children as well as when large oral doses are used. As observed decades ago [50], clindamycin may infrequently cause diarrhoea in children. Cephalosporins penetrate bone more poorly than lincosamides [51], but we have not detected any major difference in clinical effectiveness.

As most MRSA strains have remained susceptible to clindamycin [17], this time-proven agent well defends its position against newer and often very costly (e.g. linezolid) antimicrobials. If resistance of MRSA to clindamycin in the community exceeds 25% [22,52], initial combination with vancomycin might be indicated. Sometimes, linezolid is a valid option [15,18]. Notably, *K. kingae* is usually non-susceptible to clindamycin or vancomycin [19–21].

Antistaphylococcal penicillins are probably in widest use globally for osteoarticular infections. We have little experience because they appear to cause diarrhoea if large doses are given orally (as in AHOM). Otherwise, they no doubt are an option. Interestingly, in one study of 58 patients [53] no clindamycin recipient developed chronic osteomyelitis, whilst sequelae were observed in 9 patients treated with cloxacillin.

## 8. Intravenous versus oral administration

Treatment of AHOM is almost always instituted intravenously [54–56]. Historically, it is of interest that no good data support the necessity of this practice, provided the patient tolerates the oral route, a well absorbed agent and exceptionally large doses (Table 1) are used, and administration is q.i.d. or more frequent. At least for time-dependent antimicrobials, where effectiveness correlates with the time their plasma concentration exceeds the MIC, such as  $\beta$ -lactams and lincosamides, tight dosing is probably of paramount importance. Penberthy (1941) treated his patients with sulphonamides mostly orally [11]. However, in those days a surgical intervention was done routinely. Only decades later was it proven that generally oral administration is effective even when surgery is kept at a minimum [3].

We start medication with a 2–4-day course of intravenous (i.v.) high-dose antibiotic (Fig. 4) and have doubts whether even this short period is truly needed in milder cases. The same high doses are used in oral administration. As shown in Table 2, the duration of i.v. administration has shortened elsewhere as well [57–59]. Serum antimicrobial assays before switch to the oral route were once recommended [54] but

are no longer used. However, good compliance is of course necessary. To achieve better compliance, we have slightly modified our 'q.i.d.' administration: the drug is to be taken in four equal doses during the time the patient is awake.

## 9. Duration of treatment

The new 'miracle drugs' (antibiotics) also turned the page in AHOM, a disease that used to kill up to one-quarter of patients [60]. As antibiotics were initially in great shortage, very short courses (and small amounts) were used. It was learned that sometimes a mere 3-day course of sulphonamide healed the patient completely [11]. Generally, medication lasted for 3–20 days, the average being 11 days.

Once availability of antibiotics improved, courses lengthened. A retrospective analysis of patients mainly treated with penicillin [61] concluded that a course of 5–10 days was associated with a poor outcome. Another risk factor was duration of symptoms for >3 days before admission. As a result, treatments lengthened, although there was never a consensus as to what the optimum treatment length should be.

Some experts recognised this uncertainty. In 1967, Green aptly wrote that the antibiotic (cloxacillin) was given 'arbitrarily for a period of five weeks' [14]. This arbitrariness stood time surprisingly well, as shown in Table 3. Since no prospective, sufficiently powered, randomised trials were available, treatment was based on animal studies [68], expert opinions and the rationale that bone revascularisation after debridement lasts 4 weeks [65]. For years, treatment of AHOM stagnated under the belief that medication should last for 4–6 weeks [2,3,62–67], including an i.v.

phase of 1–2 weeks [54–56]. Slowly-reacting ESR was often another guide for treatment length [69].

A large retrospective series of 655 patients from Australia [70] concluded that 3 weeks was a sort of cut-off; if AHOM was treated for longer no benefit was obtained, and with a shorter duration problems were encountered. However, reoccurrences have been observed even after an 11-week treatment [55]. Clearly, there is no single length of treatment that would guarantee a successful outcome every time. In this regard, AHOM is equal to any other infectious disease.

During the past 10 years or so, evidence has been accumulating that AHOM could be treated with shorter courses [71,72], at least in industrialised countries where patients present early (usually within 1–4 days). Few prospective trials have been performed (Table 2). With this rationale, we performed a large treatment trial in which all 131 cases were bacteriologically proven AHOM [3]. Patients were treated, at random, for 20 days or 30 days with clindamycin or a first-generation cephalosporin using a dose of 40 mg/kg/day q.i.d. and 150 mg/kg/day q.i.d., respectively. The i.v. phase was 2–4 days. Oral administration began if the response was good as observed by subsiding symptoms and signs and decreasing CRP levels. Since ESR has been the traditional laboratory index, it was also measured repeatedly, but the results did not affect the treatment. The antimicrobial was discontinued when most (but not all) symptoms had subsided and CRP had decreased to <20 mg/L. The characteristics of the study are summarised in Table 4.



Not a single failure of the treatment occurred, although sometimes the treatment was prolonged [3]. Thus, we recommend to start medication with high-dose clindamycin or a first-generation cephalosporin intravenously q.i.d. If the patient responds well, and the second- to fourth-day CRP levels are descending [36], the route is switched to oral. In most cases, a total course of 20 days suffices [3]. AHOM+SA is also often curable with this course, but as CRP decreases more slowly [36] medication may sometimes be prolonged. Our cut-off-value for 'normal' CRP levels has been  $\leq 19$  mg/L [3,36–38,73,74], but we do not say that some higher level would not serve equally well.

## **10. Surgery versus antimicrobials only**

Before the antibiotic era, the attending surgeon had a dilemma [60]: if he operated early, mortality increased but sequelae decreased, and vice versa; waiting for a week or so decreased mortality, but sequelae were more frequent. Anyway, surgery was essential.

The necessity of a surgical intervention has also been the general thinking in the era of antibiotics [4,57]. We consider that the need for surgery varies. We usually only aspirate/drill the focus, mainly in order to obtain a representative sample for bacteriology. In AHOM+SA, we prefer arthrocentesis to immediate arthrotomy [75]. All larger interventions are reserved for patients in whom recovery does not seem uneventful [3,74]. Needle aspiration is often easier in children than in adolescents whose cortical bone is thicker. To what extent our conservative approach applies to AHOM in other regions, especially the developing world, remains to be seen. Also cases due to MRSA may warrant a more aggressive surgical approach [2,76].

Sometimes an intervention is no doubt needed. Besides children who do not quickly respond to the otherwise adequate treatment, perhaps also those with exceptionally destructive AHOM fall in this category. No data confirm these hypotheses; it may even be that 'whole bone' osteomyelitis should not initially be operated on.

## **11. Follow-up**

When moving towards shorter treatments, close monitoring is mandatory. Besides clinical signs, sequential CRP determinations are a good yardstick. CRP peaks to high values (often >100 mg/L) in 2–3 days, but then normalises within 11 days if the recovery is uneventfully [36]. If CRP levels continue to rise, or remain high on the 4th day of treatment, a complication should be suspected [77].

The ESR decreases slowly and a value of 20 mm/h is reached on average only after 25 days [36]. Sluggish normalisation of the ESR is one of the explanations why antibiotics for AHOM have been administered for such long periods. We usually discontinue antibiotics if the CRP has descended to <20 mg/L, provided the clinical response was good. Whether normalised CRP alone justifies drug discontinuation would require its own study. If surgery is performed, the tissue destruction elevates CRP transiently [75,78].

Since sequelae may develop slowly, follow-up for at least a year is warranted. Our check-ups have been at 2 weeks, 3 months and 1 year from discharge, taking into consideration the child's individual needs. Plain radiographs are sufficient for the detection of potential sequelae, whilst MRI is reserved for special cases [45]. CRP, or

if not available ESR, is also checked because increasing values may hint towards sequelae [3,36,74,75,77].

## 12. Uneven global distribution of sequelae, and caveats

AHOM is a potentially devastating disease that may still be fatal or cause permanent disability [10,12]. Although full or nearly full recovery can usually be expected in the affluent world [3], this is not the case in low-income countries. Whilst only two mild complications (1.5%) occurred among 131 cases in Finland [3], complication rates no less than 11–29% have been reported from Nigeria, India and Tunisia [5,6,79].

Several factors (different aetiology, underlying illnesses, late presentation, etc.) may explain dissimilar prognosis to some extent, but probably not entirely. One may thus argue that our simplified treatment would not work in those circumstances. However, it is in these environments of limited resources in which inexpensive but functioning solutions are desperately needed.

Although we are confident with our results, a few caveats should be mentioned. First, although 89% of our patients had *S. aureus* disease, no MRSA was encountered. We have no experience on the treatment of MRSA AHOM but recognise its usual susceptibility to clindamycin. Nor do we comment on cases caused by *Salmonella* or *K. kingae*, which are essentially non-existent in Finland.

Second, we have used clindamycin or first-generation cephalosporins or, previously, ampicillin/amoxicillin for Hib disease. We assume that antistaphylococcal penicillins in high doses can also be used along the same lines, unless diarrhoea becomes a problem.

Third, although we have been very restrictive in surgical procedures (in most cases only diagnostic aspiration was done) we realise that sometimes an intervention is needed. Finally, although we base our views on the largest prospective, randomised trial on childhood AHOM [3], we do not insist that all patients would be cured that simply. Exceptions exist and each child should be taken as an individual. Local conditions must also be taken into account.

**Funding**

None.

**Competing interests**

Support from Orion Pharma Co. by a grant through the University of Helsinki (project code 34490).

**Ethical approval**

Ethical Committee Jorvi, 30 May 1983; Ethical Committee Päijät-Häme, 7 March 1983 (03-8192980); Ethical Committee Lappeenranta, 1 March 1983.

## References

- [1] Lew DP, Waldvogel FA. Osteomyelitis. *Lancet* 2004;364:369–79.
- [2] Harik NS, Smeltzer MS. Management of acute hematogenous osteomyelitis in children. *Expert Rev Anti Infect Ther* 2010;2:175–81.
- [3] Peltola H, Pääkkönen M, Kallio P, Kallio MJ. Short- versus long-term antimicrobial treatment for acute hematogenous osteomyelitis of childhood: prospective, randomized trial on 131 culture-positive cases. *Pediatr Infect Dis J* 2010;29:1123–8.
- [4] Krogstad P. Osteomyelitis and septic arthritis. In: Feigin RD, Cherry J, Demmler-Harrison GJ, Kaplan SL. *Feigin & Cherry's Textbook of pediatric infectious diseases*, Vol. 1. 6th ed. Philadelphia, PA: Saunders; 2009. p. 725–48.
- [5] Tindimwebwa G, Adeyokunnu AA, Effiong CE. Acute hematogenous osteomyelitis in childhood. *Niger J Paediatr* 1983;10:93–7.
- [6] Kharbanda Y, Dhir RS. Natural course of hematogenous pyogenic osteomyelitis (a retrospective study of 110 cases). *J Postgrad Med* 1991;37:69–75.
- [7] Hobo T. Zur Pathogenese der Akuten Haematogenen Osteomyelitis, mit Berücksichtigung der Vitalfärbungslehre [in German]. *Acta Sch Med Univ Kioto* 1921;4:1–29.
- [8] Perlman MH, Patzakis MJ, Kumar PJ, Holtom P. The incidence of joint involvement with adjacent osteomyelitis in pediatric patients. *J Pediatr Orthop* 2000;20:40–3.
- [9] Labbe JL, Peres O, Leclair O, Goulon R, Scemama P, Jourdel F, et al. Acute osteomyelitis in children: the pathogenesis revisited? *Orthop Traumatol Surg Res* 2010;96:268–75.

- [10] Ibingira CB. Chronic osteomyelitis in a Ugandan rural setting. *East Afr Med J* 2003;80:242–6.
- [11] Penberthy CG, Weller CN. Chemotherapy as an aid in the management of acute osteomyelitis. *Ann Surg* 1941;114:129–46.
- [12] Akinyoola AL, Orimolade EA, Yusuf MB. Pathologic fractures of long bones in Nigerian Children. *J Child Orthop* 2008;6:475–9.
- [13] David JB, Brindle MJ. Penicillin resistance in staphylococci isolated in a casualty department. *J Clin Pathol* 1960;13:336–8.
- [14] Green JH. Cloxacillin in treatment of acute osteomyelitis. *Br Med J* 1967;2:414–6.
- [15] Kaplan SL, Afghani B, Lopez P, Wu E, Fleishaker D, Edge-Padbury B, et al. Linezolid for the treatment of methicillin-resistant *Staphylococcus aureus* infections in children. *Pediatr Infect Dis J* 2003;22(9 Suppl):S178–85.
- [16] Li M, Diep BA, Villaruz AE, Braughton KR, Jiang X, DeLeo FR, et al. Evolution of virulence in epidemic community-associated methicillin-resistant *Staphylococcus aureus*. *Proc Natl Acad Sci U S A* 2009;106:5883–8.
- [17] Martínez-Aguilar G, Hammerman WA, Mason EO Jr, Kaplan SL. Clindamycin treatment of invasive infections caused by community-acquired, methicillin-resistant and methicillin-susceptible *Staphylococcus aureus* in children. *Pediatr Infect Dis J* 2003;22:593–8.
- [18] Chen CJ, Chiu CH, Lin TY, Lee ZL, Yang WE, Huang YC. Experience with linezolid therapy in children with osteoarticular infections. *Pediatr Infect Dis J* 2007;26:985–8.

- [19] Yagupsky P, Bar-Ziv Y, Howard CB, Dagan R. Epidemiology, etiology and clinical features of septic arthritis in children younger than 24 months. *Arch Pediatr Adolesc Med* 1995;35:2410–2.
- [20] Yagupsky P, Katz O, Peled N. Antibiotic susceptibility of *Kingella kingae* isolates from respiratory carriers and patients with invasive infections. *J Antimicrob Chemother* 2001;47:191–3.
- [21] Yagupsky P, Porsch E, St Geme JW 3rd. *Kingella kingae*: an emerging pathogen in young children. *Pediatrics* 2011;127:557–65.
- [22] Saphyakhajon P, Joshi AY, Huskins WC, Henry NK, Boyce TG. Empiric antibiotic therapy for acute osteoarticular infections with suspected methicillin-resistant *Staphylococcus aureus* or *Kingella*. *Pediatr Infect Dis J* 2008;27:765–7.
- [23] Mera RM, Miller LA, Amrine-Madsen H, Sahm DF. Impact of new Clinical Laboratory Standards Institute *Streptococcus pneumoniae* penicillin susceptibility testing breakpoints on reported resistance changes over time. *Microb Drug Resist* 2011;17:47–52.
- [24] Bowerman SG, Green NE, Mencio GA. Decline of bone and joint infections attributable to *Haemophilus influenzae* type b. *Clin Orthop Relat Res* 1997;341:128–33.
- [25] Peltola H, Kallio MJ, Unkila-Kallio L. Reduced incidence of septic arthritis in children by *Haemophilus influenzae* type-b vaccination. Implications for treatment. *J Bone Joint Surg Br* 1998;80:471–3.
- [26] Host B, Schumacher H, Prag J, Arpi M. Isolation of *Kingella kingae* from synovial fluids using four commercial blood culture bottles. *Eur J Clin Microbiol Infect Dis* 2000;19:608–11.

- [27] Ceroni D, Cherkaoui A, Ferey S, Kaelin A, Schrenzel J. *Kingella kingae* osteoarticular infections in young children: clinical features and contribution of a new specific real-time PCR assay to the diagnosis. *J Pediatr Orthop* 2010;30:301–4.
- [28] Másson A, Gudnason B, Gudmundur K. Osteomyelitis and septic arthritis in Icelandic children during 1996–2005. In: 5th World Congress of the World Society for Pediatric Infectious Diseases (WSPID); 15–18 November 2007; Bangkok, Thailand. Gennep, The Netherlands WSPID; 2007.
- [29] Atkins BL, Price EH, Tillyer L, Novelli V, Evans J. *Salmonella* osteomyelitis in sickle cell disease children in the East End of London. *J Infect* 1997;34:133–8.
- [30] Bennett OM, Namnyak SS. Bone and joint manifestations of sickle cell anemia. *J Bone Joint Surg Br* 1990;72:494–9.
- [31] Sherman JW, Conte JE Jr. Ceftriaxone treatment of multidrug-resistant *Salmonella* osteomyelitis. *Am J Med* 1987;83:137.
- [32] Schaad UB. Fluoroquinolone antibiotics in infants and children. *Infect Dis Clin North Am* 2005;19:617–28.
- [33] Leibovitz E. The use of fluoroquinolones in children. *Curr Opin Pediatr* 2006;18:64–70.
- [34] Rosanova MT, Lede R, Capurro H, Petrunaro V, Copertari P. Assessing fluoroquinolones as risk factor for musculoskeletal disorders in children: a systematic review and meta-analysis [in Spanish]. *Arch Argent Pediatr* 2010;108:524–31.
- [35] Ceroni D, Regusci M, Pazos J, Dayer R, Kaelin A. Acute bone and joint infections in children: how much attention should be paid to persistent fever



during intravenous antibiotic therapy? [in French]. *Rev Chir Orthop Reparatrice Appar Mot* 2003;89:250–6.

- [36] Pääkkönen M, Kallio MJ, Kallio PE, Peltola H. Sensitivity of erythrocyte sedimentation rate and C-reactive protein in childhood bone and joint infections. *Clin Orthop Relat Res* 2010;468:861–6.
- [37] Peltola H, Räsänen JA. Quantitative C-reactive protein in relation to erythrocyte sedimentation rate, fever, and duration of antibiotic therapy in bacteraemic diseases of childhood. *J Infect* 1982;5:257–67.
- [38] Peltola H. C-reactive protein in rapid differentiation of acute epiglottitis from spasmodic croup and acute laryngotracheitis: a preliminary report. *J Pediatr* 1983;102:713–5.
- [39] Piñeda C, Vargas A, Rodríguez AV. Imaging of osteomyelitis: current concepts. *Infect Dis Clin North Am* 2006;20:789–825.
- [40] Wegener WA, Alavi A. Diagnostic imaging of musculoskeletal infection. Roentgenography; gallium, indium-labeled white blood cell, gammaglobulin, bone scintigraphy; and MRI. *Orthop Clin North Am* 1991;22:401–18.
- [41] Connolly LP, Connolly SA, Drubach LA, Jaramillo D, Treves ST. Acute hematogenous osteomyelitis of children: assessment of skeletal scintigraphy-based diagnosis in the era of MRI. *J Nucl Med* 2002;43:1310–6.
- [42] Ma LD, Frassica FJ, Bluemke DA, Fishman EK. CT and MRI evaluation of musculoskeletal infection. *Crit Rev Diagn Imaging* 1997;38:535–68.
- [43] Kan JH, Young RS, Yu C, Hernanz-Schulman M. Clinical impact of gadolinium in the MRI diagnosis of musculoskeletal infection in children. *Pediatr Radiol* 2010;40:1197–205.

- [44] Averill LW, Hernandez A, Gonzalez L, Peña AH, Jaramillo D. Diagnosis of osteomyelitis in children: utility of fat-suppressed contrast-enhanced MRI. *AJR Am J Roentgenol* 2009;192:1232–8.
- [45] Courtney PM, Flynn JM, Jaramillo D, Horn BD, Calabro K, Spiegel DA. Clinical indications for repeat MRI in children with acute hematogenous osteomyelitis. *J Pediatr Orthop* 2010;30:883–7.
- [46] Dunbar JA, Sandoe JA, Rao AS, Crimmins DW, Baig W, Rankine JJ. The MRI appearances of early vertebral osteomyelitis and discitis. *Clin Radiol* 2010;65:974–81.
- [47] Chen WL, Chang WN, Chen YS, Hsieh KS, Chen CK, Peng NJ, et al. Acute community-acquired osteoarticular infections in children: high incidence of concomitant bone and joint involvement. *J Microbiol Immunol Infect* 2010;43:332–8.
- [48] Jackson MA, Burry VF, Olson LC. Pyogenic arthritis associated with adjacent osteomyelitis: identification of the sequela-prone child. *Pediatr Infect Dis J* 1992;11:9–13
- [49] Unkila-Kallio L, Kallio MJ, Peltola H. Acute haematogenous osteomyelitis in children in Finland. Finnish Study Group. *Ann Med* 1993;25:545–9.
- [50] Wilson DH. Clindamycin in the treatment of soft tissue infections: a review of 15 019 patients. *Br J Surg* 1980;67:93–6.
- [51] Darley ES, MacGowan AP. Antibiotic treatment of Gram-positive bone and joint infections. *J Antimicrob Chemother* 2004;53:928–35.
- [52] Young TP, Maas L, Thorp AW, Brown L. Etiology of septic arthritis in children: an update for the new millennium. *Am J Emerg Med* 2010 Jul 30 [Epub ahead print].

- [53] Glover SC, McKendrick MW, Padfield C, Geddes AM, Dwyer NS. Acute osteomyelitis in a district general hospital. *Lancet* 1982;1:609–11.
- [54] Tetzlaff TR, McCracken GH Jr, Nelson JD. Oral antibiotic therapy for skeletal infections of children. II. Therapy of osteomyelitis and suppurative arthritis. *J Pediatr* 1978;92:485–90.
- [55] Syrogiannopoulos GA, Nelson JD. Duration of antimicrobial therapy for acute suppurative osteoarticular infections. *Lancet* 1988;1:37–40.
- [56] Dagan R. Management of acute hematogenous osteomyelitis and septic arthritis in the pediatric patient. *Pediatr Infect Dis J* 1993;12:88–92.
- [57] Jaber FM, Shahcheraghi GH, Ahadzadeh M. Short-term intravenous antimicrobial treatment of acute hematogenous bone and joint infection in children: a prospective randomized trial. *J Pediatr Orthop* 2002;22:317–20.
- [58] Prado SMA, Lizama CM, Pena DA, Valenzuela MC, Viviani ST. Short duration of initial intravenous treatment in 70 pediatric patients with osteoarticular infections [in Spanish]. *Rev Chilena Infectol* 2008;25:30–6.
- [59] Jagodzinski NA, Kanwar R, Graham K, Bache CE. Prospective evaluation of a shortened regimen of treatment for acute osteomyelitis and septic arthritis in children. *J Pediatr Orthop* 2009;29:518–25.
- [60] Kenney WE. The prognosis in acute haematogenous osteomyelitis with and without chemotherapy. *Surgery* 1944;16:477–84.
- [61] Harris NH. Some problems in the diagnosis and treatment of acute osteomyelitis. *J Bone Joint Surg Br* 1960;42:535–41.
- [62] Dieckmann R, Harges J, Ahrens H, Flieger S, Gosheger G, Götze C, et al. Treatment of acute and chronic osteomyelitis in children [in German]. *Z Orthop Unfall* 2008;146:375–80.

- [63] Milcent K, Guitton C, Kone-Paut I. French nationwide survey about management of acute osteomyelitis in children [in French]. *Arch Pediatr* 2009;16:7–13.
- [64] Vinod MB, Matussek J, Curtis N, Graham HK, Carapetis JR. Duration of antibiotics in children with osteomyelitis and septic arthritis. *J Paediatr Child Health* 2002;38:363–7.
- [65] Lazzarini L, Mader JT, Calhoun JH. Osteomyelitis in long bones. *J Bone Joint Surg Am* 2004;86:2305–18.
- [66] Weichert S, Sharland M, Clarke NM, Faust SN. Acute haematogenous osteomyelitis in children: is there any evidence for how long we should treat? *Curr Opin Infect Dis* 2008;21:258–62.
- [67] Rasmont Q, Yombi JC, van der Linden D, Docquier PL. Osteoarticular infections in Belgian children: a survey of clinical, biological, radiological and microbiological data. *Acta Orthop Belg* 2008;74:374–85.
- [68] Norden CW, Dickens DR. Experimental osteomyelitis. 3. Treatment with cephaloridine. *J Infect Dis* 1973;127:525–8.
- [69] Kolyvas E, Ahronheim G, Marks MI, Gledhill R, Owen H, Rosenthal L. Oral antibiotic therapy of skeletal infections in children. *Pediatrics* 1980;65:867–71.
- [70] Gillespie WJ, Mayo KM. The management of acute hematogenous osteomyelitis in the antibiotic era: a study of the outcome. *J Bone Joint Surg Br* 1981;63:126–31.
- [71] Le Saux N, Howard A, Barrowman NJ, Gaboury I, Samson M, Moher D. Shorter courses of parenteral antibiotic therapy do not appear to influence

response rates for children with acute hematogenous osteomyelitis: a systematic review. *BMC Infect Dis* 2002;2:16.

- [72] Malcius D, Trumpulyte G, Barauskas V, Kilda A. Two decades of acute haematogenous osteomyelitis in children: are there any changes? *Pediatr Surg Int* 2005;21:356–9.
- [73] Unkila-Kallio L, Kallio MJ, Peltola H. The usefulness of C-reactive protein levels in the identification of concurrent septic arthritis in children who have acute hematogenous osteomyelitis. A comparison with the usefulness of the erythrocyte sedimentation rate and the white blood-cell count. *J Bone Joint Surg Am* 1994;76:848–53.
- [74] Peltola H, Pääkkönen M, Kallio P, Kallio MJ. Prospective, randomized trial on 10 versus 30 days of antimicrobial treatment, including a short-term course of parenteral therapy, for childhood septic arthritis. *Clin Infect Dis* 2009;48:1201–10.
- [75] Pääkkönen M, Kallio MJ, Peltola H, Kallio PE. Pediatric septic hip with or without arthrotomy: retrospective analysis of 62 consecutive nonneonatal culture-positive cases. *J Pediatr Orthop B* 2010;19:264–9.
- [76] Shetty AK, Kumar A. Osteomyelitis in adolescents. *Adolesc Med State Art Rev* 2007;18:79–94, ix.
- [77] Roine I, Faingezicht I, Arguedas A, Herrera JF, Rodriguez F. Serial serum C-reactive protein to monitor recovery from acute hematogenous osteomyelitis in children. *Pediatr Infect Dis J* 1995;14:40–4.
- [78] Kallio P, Michelsson JE, Lalla M, Holm T. C-reactive protein in tibial fractures. Natural response to the injury and operative treatment. *J Bone Joint Surg Br* 1990;72:615–7.

- [79] Jenzri M, Safi H, Nessib MN, Jalel C, Smida M, Ammar C, et al. Acute hematogenous osteomyelitis of the neck of femur in children: 28 cases [in French]. *Rev Chir Orthop Reparatrice Appar Mot* 2008;94:434–42.

Accepted Manuscript

**Fig. 1.** Age distribution (upper panel) and causative agents and localisation (lower panel) of 131 cases of acute haematogenous osteomyelitis of children [3]. Hib, *Haemophilus influenzae* type b; GAS, group A streptococci.

**Fig. 2.** Distribution of acute haematogenous osteomyelitis (AHOM) in the largest-up-to-date prospective series of AHOM [3] ( $N = 131$ ), depicted on the left. Percentages on the right side show the frequency with which AHOM involved septic arthritis (SA) of an adjacent joint.

**Fig. 3.** Inflammation can continue even after infection has subsided; pathological fracture may result.

**Fig 4.** Our recommendation for an antibiotic treatment scheme in acute haematogenous osteomyelitis of childhood. CRP, C-reactive protein; ESR, erythrocyte sedimentation rate.

**Table 1**

Currently recommended antimicrobials for acute haematogenous osteomyelitis with the causative organism identified

Agent	Antimicrobial	Dose	Reference
<i>Staphylococcus aureus</i>			
When >90% of strains in community MSSA	1GC	≥150 mg/kg/day q.i.d.	Peltola et al., 2010 [3]
	or clindamycin	≥40 mg/kg/day q.i.d.	
	Clindamycin	≥40 mg/kg/day q.i.d.	
When >10% of strains MRSA	Clindamycin	≥40 mg/kg/day q.i.d.	Martínez-Aguilar et al., 2003 [17]
When >10% of strains MRSA and clindamycin resistance >25%	Vancomycin	≥40 mg/kg/day q.i.d.	Harik and Smeltzer, 2010 [2]
Not responding to vancomycin	Linezolid	≥30 mg/kg/day t.i.d.	Chen et al., 2007 [18]
<i>Streptococcus pyogenes</i>			
	Penicillin G i.v.	≥300 mg/kg/day q.i.d.	Peltola et al., 2010 [3]
	or 1GC	≥150 mg/kg/day q.i.d.	
	or clindamycin	≥40 mg/kg/day q.i.d.	



<i>Streptococcus pneumoniae</i> <sup>a</sup>	Penicillin G i.v.	≥300 mg/kg/day q.i.d.	Peltola et al., 2010 [3]
	or 1GC	≥150 mg/kg/day q.i.d.	
<i>Haemophilus influenzae</i> type b			
Non-β-lactamase-producing strains	Ampicillin/amoxicillin	≥200 mg/kg/day q.i.d.	Peltola et al., 2010 [3]
β-Lactamase-producing strains	Cefuroxime	≥150 mg/kg/day q.i.d.	
	or ceftriaxone	≥100 mg/kg/day q.i.d.	
<i>Kingella kingae</i>	Penicillin G i.v.	≥300 mg/kg/day q.i.d.	No evidence-based guideline [19–22]
	or 1GC	≥150 mg/kg/day q.i.d.	

MSSA, methicillin-sensitive *S. aureus*; 1GC, first-generation cephalosporin; q.i.d., four times daily in equal doses; MRSA, methicillin-resistant *S. aureus*; t.i.d., three times daily in equal doses; i.v., intravenous.

<sup>a</sup> Using the current definition for penicillin resistance (minimal inhibitory concentration ≥8 µg/mL), strains exceeding this level are exceedingly rare.

**Table 2**

Prospective trials to shorten antibiotic treatment for acute haematogenous osteomyelitis (AHOM) from the last 10 years <sup>a</sup>

Patients in total (N)	Length of treatment (of which i.v.) (days)		Antibiotic(s)	Recovery rate (%)		Reference
	Short course [N]	Long course [N]		Short course	Long course	
12	38 (10) [6]	49 (21) [6]	N/D	100	100	Jaberi et al., 2002 [57]
70	28–42 (7) [no randomisation]		CLO+CRO/AMG	100	100	Prado et al., 2008 [58]
37	24 (4) [no randomisation]		FCX	100	100	Jagodzinski et al., 2009 [59]
131	20 (3–4) [67]	30 (3–4) [64]	CLI/CPH	99	98	Peltola et al., 2010 [3]

i.v., intravenous; N/D, not defined; CLO, cloxacillin; CRO, ceftriaxone; AMG, aminoglycoside; FCX, flucloxacillin; CLI, clindamycin;

CPH, first-generation cephalosporin.

<sup>a</sup> *Staphylococcus aureus* was the most common causative organism in all studies.

**Table 3**

Total length of antimicrobial therapy for acute haematogenous osteomyelitis: reports from some high-income countries during the past 10 years

Country	Treatment (weeks)	Reference
Germany	8	Dieckmann et al., 2008 [62]
France	6	Milcent et al., 2009 [63]
Australia	5	Vinod et al., 2002 [64]
Italy	4–6	Lazzarini et al., 2004 [65]
UK	4–6	Weichert et al., 2008 [66]
USA	4–6	Harik and Smeltzer, 2010 [2]
Belgium	4	Rasmont et al., 2008 [67]
Finland	3	Peltola et al., 2010 [3]

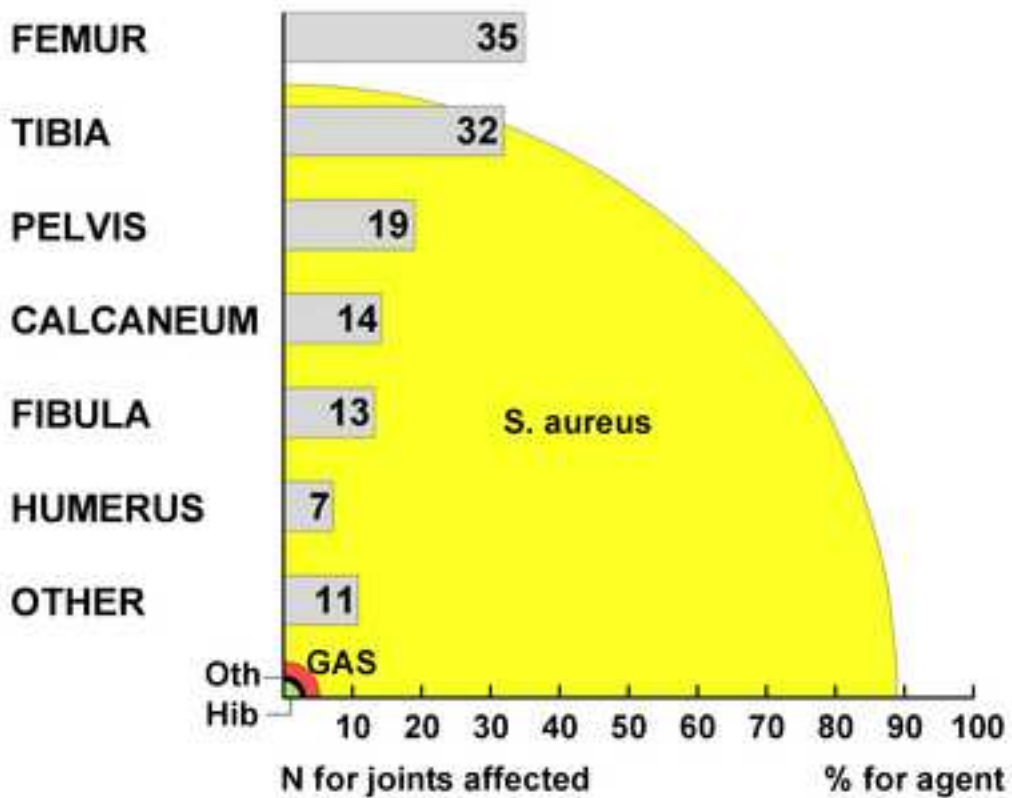
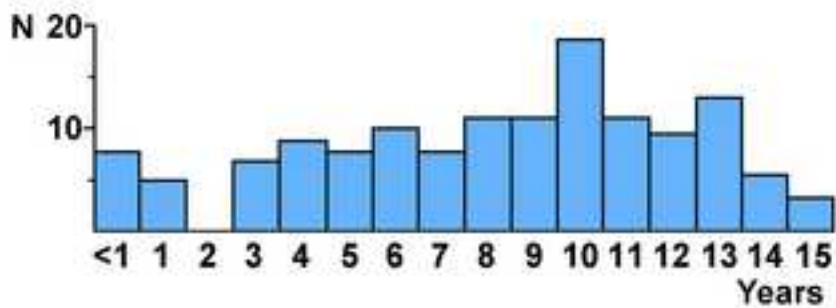
**Table 4**

Our prospective randomised trial on 131 patients with culture-positive paediatric acute haematogenous osteomyelitis (AHOM) [3]

	Randomised total antimicrobial course	
	20 days ( <i>N</i> = 67)	30 days ( <i>N</i> = 64)
Gender (male/female) ( <i>n</i> )	40/27	42/22
Age (years) (median)	9.00	9.30
Time from first symptoms before hospital admission (days) (median)	4.15	5.3
Agent cultured from		
Bone and blood	16	19
Bone only	20	24
Blood only <sup>a</sup>	31	21
Initial value (mean ± S.E.M.)		
CRP (mg/mL)	95 ± 11	90 ± 10
ESR (mm/h)	46 ± 3	49 ± 4
Duration of antimicrobial therapy (days)		
Median	20	30
90% range	10–21	30–43
Normalisation of CRP (days) (mean ± S.E.M.)	10 ± 1	9 ± 1
Recrudescence or relapse	0	0
Full recovery at last check-up (%)	66/67 (99)	63/64 (98)

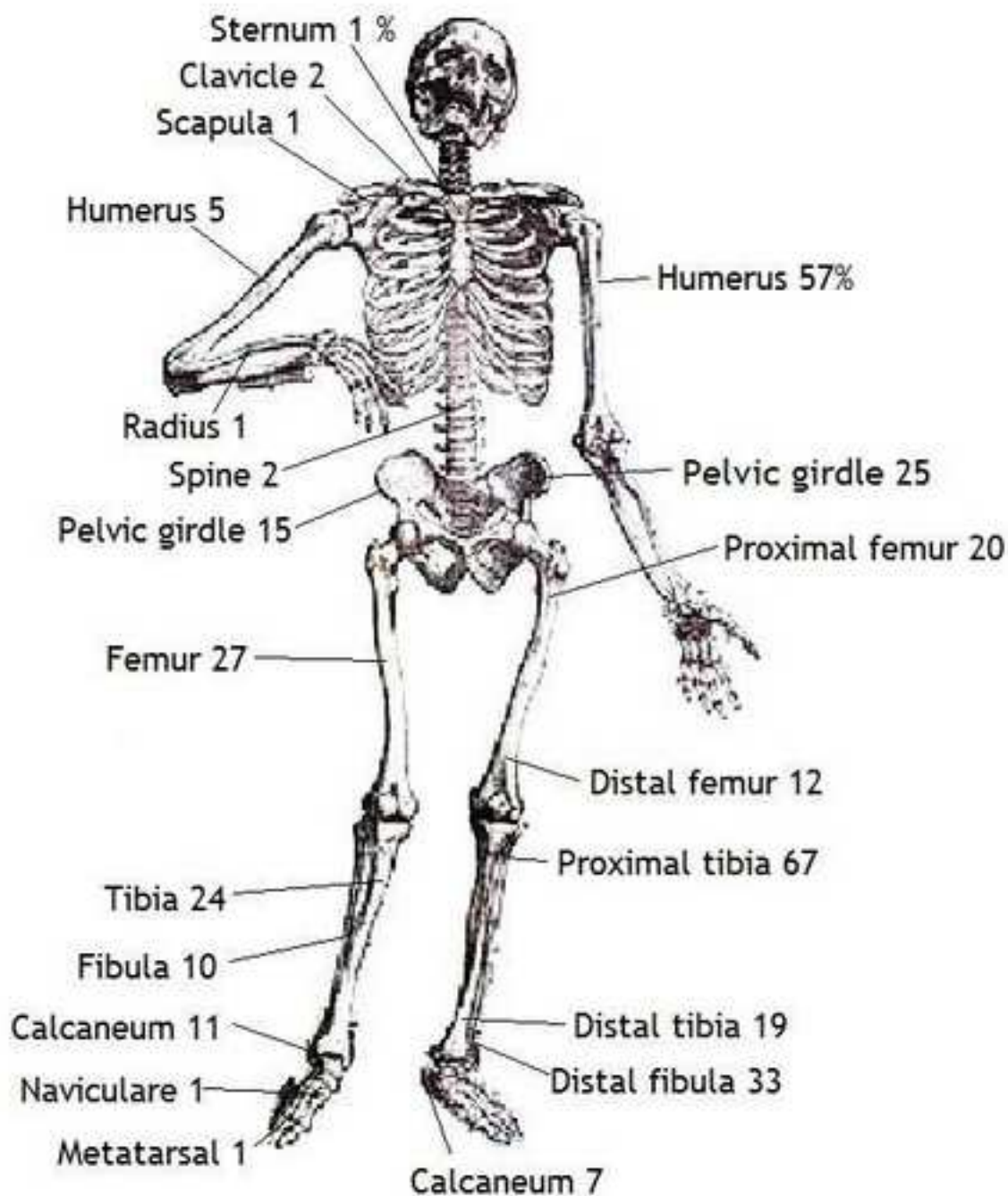
S.E.M., standard error of the mean; CRP, C-reactive protein; ESR, erythrocyte sedimentation rate.

<sup>a</sup> All patients with compatible symptoms and signs of AHOM. Localisation and causative agent presented in Fig. 1.



AHOM

AHOM + SA



scrip

