



HAL
open science

Eimeria involved in a field case of coccidiosis in red-legged partridges (*Alectoris rufa*) in France: oocyst isolation and gross lesion description after experimental infection

Muriel Naciri, Jean-Michel Réperant, Geneviève Fort, Joséphine Crespin, Joël Duperray, Gaëlle Benzoni

► To cite this version:

Muriel Naciri, Jean-Michel Réperant, Geneviève Fort, Joséphine Crespin, Joël Duperray, et al.. Eimeria involved in a field case of coccidiosis in red-legged partridges (*Alectoris rufa*) in France: oocyst isolation and gross lesion description after experimental infection. *Avian Pathology*, 2011, 40 (5), pp.1. 10.1080/03079457.2011.606798 . hal-00724619

HAL Id: hal-00724619

<https://hal.science/hal-00724619>

Submitted on 22 Aug 2012

HAL is a multi-disciplinary open access archive for the deposit and dissemination of scientific research documents, whether they are published or not. The documents may come from teaching and research institutions in France or abroad, or from public or private research centers.

L'archive ouverte pluridisciplinaire **HAL**, est destinée au dépôt et à la diffusion de documents scientifiques de niveau recherche, publiés ou non, émanant des établissements d'enseignement et de recherche français ou étrangers, des laboratoires publics ou privés.



Eimeria involved in a field case of coccidiosis in red-legged partridges (*Alectoris rufa*) in France : oocyst isolation and gross lesion description after experimental infection

Journal:	<i>Avian Pathology</i>
Manuscript ID:	CAVP-2011-0033.R2
Manuscript Type:	Original Research Paper
Date Submitted by the Author:	22-Jun-2011
Complete List of Authors:	Naciri, Muriel; INRA, Centre de Tours R��perant, Jean-Michel; anses Fort, Genevi��ve; INRA, Centre de Tours Crespin, Jos��phine; IN VIVO NSA, Research Duperray, Jo��l; IN VIVO NSA, Research Benzoni, Gaelle; IN VIVO NSA, Research
Keywords:	Coccidia, Partridge, <i>Alectoris rufa</i> , Oocyst

SCHOLARONE™
Manuscripts

Eimeria involved in a case of coccidiosis in farmed red-legged partridges (*Alectoris rufa*) in France: oocyst isolation and gross lesion description after experimental infection

M. Naciri¹, J.M. Répérant², G. Fort¹, J. Crespin³, J. Duperray³ and G. Benzoni^{3*}

¹INRA, Centre de Tours, 37380 Nouzilly, France ²ANSES, BP 53, 22440 Ploufragan, France

³IN VIVO NSA, Talhouët, 56250 Saint Nolf, France

Running title: Coccidia of red-legged partridges (*Alectoris rufa*) in France

* Corresponding author

Telephone: (33) 2 97 48 55 13

Fax: (33) 2 97 48 54 61

e-mail: gbenzoni@invivo-nsa.com

Abstract

The aim of this work was, after a coccidiosis outbreak in a farm rearing red-legged partridges (*Alectoris rufa*) in Brittany (France), to identify the *Eimeria* species and describe gross lesions induced by three of them (*E. kofoidi*, *E. caucasica* and *E. legionensis*) after experimental infection. *E. kofoidi* oocysts measured 19.3 x 16.3 µm on average; neither micropyle nor oocyst residuum were present, but one, two or more small polar granules were visible. After inoculation of 300,000 oocysts per partridge, severe gross lesions were observed in duodenum and jejunum, characterised by thickened oedematous mucosa and lumen filled with thick mucous, gas and sometimes false-membrane due to sloughed epithelium. *E. caucasica* oocysts were on average 29.8 x 19.5 µm in size; no oocyst residuum was observed, but a large granule was well visible. *E. caucasica* also invaded both duodenum and jejunum, causing hemorrhagic points on the serosal surface, as well as mucoid duodenitis and catarrhal enteritis when 30,000 oocysts were inoculated per bird. *E. legionensis* oocysts measured 22.6 x 14.9 µm on average; they presented a clear micropyle beneath which one or two granulations were present. *E. legionensis* mainly invaded the caeca; low mortality was observed at the dosage of 200,000 oocysts per bird. Caecal walls were thickened and caseous material was condensed into off-white cheesy cores. For each species, oocyst shedding started 5 days post inoculation (DPI), peaked at 9, 8 and 6 DPI for *E. kofoidi*, *E. caucasica* and *E. legionensis*, respectively, then decreased and persisted until 15 DPI (end of examinations).

Introduction

Much appreciated by gourmets and hunters, the partridge is a very popular game bird. Belonging to Gallinaceae, partridges are Phasianidae, of which the two main genera live in France: *Perdix* and *Alectoris*. The red-legged partridge (*Alectoris rufa*) native to the Iberian Peninsula, is currently present in Southern and Central France, and in the North-West of Italy (Millan, 2009). Considering the high demand for red-legged partridge hunting and the rarity of wild birds, in-captivity breeding and raising of red-legged partridges has highly developed and has nowadays a significant economic importance. Vallance *et al.* (2006) reported that 15 million partridges were reared in France, of which two thirds were exported to England, Spain, Portugal and Italy. According to Ponce-Boutin (2000), 1.7 million red-legged partridges were hunted in 1998 in France. In 2010, 6 million partridges were produced for the French market, 70 to 80% of which were red-legged partridges (Duperray, personal communication). With 3 million birds officially hunted yearly in Spain, the red-legged partridge has a deep socio-economic relevance, representing 20 million Euros regarding only the value of the partridge flesh carcasses, and between 30-40 million Euros in indirect benefits (Millan, 2009). Red-legged partridge grows and reproduces easily in captivity if hygienic and therapeutic measures to prevent diseases are taken. Red-legged partridges are particularly sensitive to pathogenic agents which may cause at best 10-15% mortality and in the worst 70 to 80%, discouraging some breeders to continue to raise these birds (Duperray personal communication). Bolognesi *et al.* (2006) reported outbreak mortalities of 46.5% and 52.1% in red-legged partridges starting from the 26th or 31st day of life and lasting 5 or 10 days respectively. Indeed, the concentration of animals enhances disease risks, and among the most severe diseases, coccidiosis is a frequent cause of mortality or morbidity. Coccidiosis is caused by the development of highly specific protozoan parasites of the *Eimeria* genus,

several species of which can invade specific segments of bird intestine. Very little is known about coccidiosis in red-legged partridges. The aim of this study was, after a coccidiosis outbreak in a red-legged partridge farm, to identify the *Eimeria* species observed in droppings and to describe gross lesions induced by three of them after a single *Eimeria* experimental infection.

Materials and Methods

Collection of field coccidia. The coccidia used were originally obtained from droppings sampled in a commercial red-legged partridge farm in which a coccidiosis outbreak with 11% mortality occurred, in Brittany (France). Coccidia were harvested by flotation technique, aseptized in chlorine, sporulated in 2.5% potassium dichromate for 72 hours at 27°C and stored at 4°C. The method proposed by Joyner & Long (1974) for chicken coccidia, based on both morphological and biological features including intestinal location of endogenous stages, lesion gross appearance, prepatent period and oocyst morphology was used to distinguish the species. As little literature is available on partridge coccidiosis, on its real diffusion and on the involved coccidia species as mentioned by Bolognesi *et al.*, (2006), the field sample was temporarily identified according to oocyst morphology (length x width and shape index, wall thickness and colour) as a mixture of at least 4 species: *E. kofoidi*, *E. caucasica*, *E. procera* and *E. legionensis*.

Isolation of coccidia species. 40 one-day-old red-legged partridges obtained from a local breeder (REYGIB', 37240 Bournan, France) were reared in coccidia-free conditions under uniform temperature and controlled lighting, with free access to water and to a commercial

starter diet without coccidiostats (Progibier Super Starter, IN VIVO NSA, France). At 14 days of age (D0 = Day of inoculation), they were inoculated individually by oral route with 0.2 ml of a suspension containing 250,000 sporulated oocysts of the previously described coccidia mixture in order to isolate intestinal from caecal coccidia. Faeces were collected daily from D4 to D11 and 5 birds were humanely euthanized by well trained person before examining the intestine and taking the caeca in order to identify the localization of the lesions when a new kind of oocysts appeared in the feces. From these different samples, those containing most oocysts of a given species were selected. Oocysts were separated from faeces by flotation technique, suspended in 2.5% potassium dichromate for sporulation at 27°C and stored at 4°C until use. After sporulation, single oocysts characteristic of every presumed species were isolated by method described by Shirley and Harvey (1996). Briefly, oocysts in mixture were concentrated to 400/ml and 2.5µL aliquots dropped on to glass microscope slides and examined with a microscope (x 40 objective and a x 10 eye-piece). 50 µL of molten (37°C) 1% low-gelling temperature agarose in phosphate-buffered saline at pH 7.0 was added to those drops that contained only a single oocyst. Each agarose-buffer drop was microscopically examined again for the presence and species determination of a single oocyst then transferred into a gelatine capsule for immediate oral inoculation to coccidia-free 14 day-old red-legged partridges reared in isolator. From 4 to 9 days post inoculation, partridge droppings were daily collected and examined for oocysts. Any oocysts found were allowed to sporulate and serially passaged 3 times to amplify each strain. During the 3rd passage, three doses (50,000, 200,000 and 500,000 oocysts/bird) were inoculated to partridges (4 birds/dose) to estimate the effect of the dose size on mortality and morbidity. After this last passage, 300,000 – 30,000 – 200,000 oocysts of respectively *E. kofoidi*, *E. caucasica* and *E. legionensis* were chosen as the dose that do not provoke mortality but that create sufficient morbidity to allow a good observation of gross lesions and pathogenic features.

Isolation was performed for 3 of the 4 observed species: *E. kofoidi*, *E. caucasica* and *E. legionensis*. Seasonal production of young partridges did not allow another attempt to isolate *E. procera*.

Evaluation of coccidia pathogenic features. 184 one day-old red-legged partridges were purchased from a commercial hatchery (L'envol de Retz, 44270 Machecoul, France). They were reared in a coccidia-free building under lighting and temperature conditions adapted to their needs. Experiment was conducted under the research agreement B56-102 - IN VIVO NSA delivered by the French veterinarian authorities and persons in charge of the animals were holder of the animal experimentation diploma of Nantes veterinary school, certifying their ability to conduct experimentations in respect of animal welfare. At 31 days of age, partridges were divided into 4 groups with 2 replications of 23 birds per group: 3 groups were inoculated either with *E. kofoidi* at the dose of 300,000 sporulated oocysts, or *E. caucasica* with 30,000 sporulated oocysts or *E. legionensis* with 200,000 sporulated oocysts, as determined during the coccidia isolation study presented in the previous paragraph to assess gross lesions and oocyst excretion. The fourth group was kept uninfected, being inoculated with water as placebo.

At 4, 5 and 6 days post inoculation, 6 birds per day and per group (3 per replicate) were humanely euthanized and the entire intestine was removed, opened from duodenum to caeca and rectum to look for the presence of gross lesions due to coccidiosis. From 0 to 15 days post inoculation (DPI), faecal material was collected daily for each replicate and the faeces of the 2 replicates of the same group were pooled. Therefore, 4 faeces samples were obtained each day. Oocysts were counted microscopically using a McMaster counting chamber and oocyst excretion was expressed as the number of oocysts per gram (OPG) of faeces. In order to compare the excretion potential of the 3 coccidia, the area under the

excretion curve (AUC) from 4 to 15 DPI of each coccidia was measured using the image treatment free software Measurim Pro.

Results

Neither clinical signs (Figure 1a), nor intestinal or caecal gross lesions (Figure 1c, d & e) or oocyst excretion were observed in non-inoculated red-legged partridges.

Partridges inoculated with *E. kofoidi*, *E. caucasica* or *E. legionensis* presented clinical signs of coccidiosis and became weak and emaciated (Figure 1b). The main signs were those observed in other poultry like chickens (Naciri, 2000) or turkeys (Anonym, 1999; McMullin, 2004; Réperant, 2006): huddling, drooping wings, ruffled feathers, half-closed eyes, depression, loss of appetite, poor weight gain, scanty to slightly fluid up to watery droppings or droppings containing clumps of mucus or shed sloughed mucosa or caecal caseous cores.

Characteristics of the 3 described species of coccidia are summarized in tables 1 & 2.

***E. kofoidi* species determination.** *Oocysts.* In the field mixture, oocysts spherical to broadly ovoid (Figure 2a), measuring 14.0-21.4 μm x 12.0-19.5 μm (average: 19.3 x 16.3 μm), with a shape index of 1.18 (length/width = 1.18) were identified as *Eimeria kofoidi* (Yakimoff and Matikaschwili, 1936). They had brown bilayered walls which consisted of a yellowish outer and a bluish inner layer, varying according to the focus of the microscope. There was neither micropyle nor oocyst residuum, but one or two or more small polar granules were present, as shown by Dumanli and Ozer (1985). The ovoid almond-shaped sporocysts (Figure 2b) had a small prominent Stieda body pointing at an end; they measured 9.4 x 5.3 μm on average and contained a granular residuum.

Gross lesions. *E. kofoidi* invaded essentially the duodenum loop and jejunum, and in some birds infection spread down to the ileum without inducing mortality with 300,000 sporulated oocysts inoculated per bird. Caeca were normal (Figure 3a). Severe changes were observed in affected areas of intestine. Duodenum and jejunum were whitish, dilated and swollen. Whitish streaks or spots were clearly visible from serosal surface (Figure 3b). After splitting, no normal intestinal content was observed. Duodenal spots were visible in the duodenum (Figure 3c) or most often, the mucosa initially thickened, oedematous, covered by coalescent whitish streaks on 4 DPI, sloughed and became thinner on 5 DPI. Duodenal and jejunal lumina were filled with white-yellowish or yellow-greenish or fluorescent green thick mucous, gas (Figure 3d) and sometimes false-membrane due to sloughed epithelium which caused mucoid droppings. In the ileum, the mucosa was normal in most cases, but the ileal lumen was either empty or filled with liquid or mucous most often green as bile (Figure 3e). Caecal content was normal. On 6 DPI, birds fed again; feed was present in the duodenum and the mucosa was in the process of recovery.

Oocyst excretion. Red-legged partridges orally inoculated with 300,000 *E. kofoidi* sporulated oocysts began to shed oocysts 5 DPI. The excretion level of 4 million oocysts per gram of faeces at 5 DPI was maintained between 10 to 13 x 10⁶ oocysts from 6 DPI to 8 DPI, peaked at 9 DPI (23.2x10⁶ OPG) and then decreased from 9 DPI to 13 DPI and persisted above 2 x 10⁶ OPG until D15 (end of examinations) (Figure 6a). Thus, the prepatent period was of 5 days and the patent period lasted more than 10 days (15 DPI = end of examinations).

***E. caucasica* species determination.** *Oocysts.* In the field mixture, ellipsoid-ovoid oocysts (Figure 2c) were also found measuring 26.0-33.5 µm x 16.7-23.3 µm (average: 29.8 x 19.5

μm) with a shape index of 1.53. They had no micropyle. Their morphology was fairly comparable to that of *E. caucasica* originally described by Yakimoff and Buewitsch (1932), measuring 25.2-36.0 μm x 14.4-21.6 μm (average: 32.7 x 19.0 μm) in chukka partridge (*Alectoris chukar*). The oocysts had a yellowish-blue-green bilayered wall (Figure 2c). Sporulated oocysts contained a large granule which did not always occupy a polar position. No oocyst residuum was seen. After grinding, the oocyst wall was broken; sporocysts were freed as well as the large oocyst granule, as showed on figure 2d. Sporocysts measured 12.7 μm x 7.8 μm on average and bore prominent, plug-like Stieda body, also well visible inside the oocyst on figure 2c. Sporocyst residuum consisted of dark granules interspersed between sporozoites.

Gross lesions. No mortality was recorded in birds inoculated with 30,000 sporulated *E. caucasica* oocysts. This species invaded the duodenum and jejunum, causing mucoid duodenitis and catarrhal enteritis (inflammation and hypersecretion of mucus). *E. caucasica* had the same location as *E. kofoidi*, but the main difference in gross lesions was the duodenal serosal surface which was pinkish or reddish. On 4 DPI, the duodenal lumen was filled with copious orange-yellowish mucous (Figure 4a) while whitish-orange mucous floated in colourless fluid and gas in jejunum (Figure 4b).

At 6 DPI, the duodenal and jejunal mucosa was coated with a whitish membrane which initially adhered closely to the intestinal wall. Then, after sloughing of mucosa, false membrane floated in colourless fluid (Figures 4 c & d). After sloughing, mucosal surface was eroded and intestine was very pale and fragile (Figure 4c). In most cases, the ileum was normal, either empty or with fluorescent green contents (Figures 4 e & f); in a few cases, it was white and thickened (Figure 4g). No lesions were observed in the caeca (Figure 4g).

Oocyst excretion. Red-legged partridges aged 31 days old, orally inoculated with 30,000 *E. caucasica* oocysts, began to shed oocysts 5 DPI (1.3×10^6 OPG), then excretion peaked at 8 DPI (8.6×10^6 OPG) and dropped quickly 9 DPI (2.5×10^6 OPG) (Figure 6b). From 11 DPI, oocyst excretion was below 1×10^6 OPG, but persisted beyond D15. Thus, the prepatent period was of 5 days and the patent period of at least 10 days (15 DPI = end of examinations).

***E. legionensis* species determination.** *Oocysts.* In our field mixture, elliptic oocysts with almost symmetrical flattened walls, measuring 18.6-26 μm x 13-16.7 μm (average: 22.6 x 14.9 μm), with a shape index of 1.52, were identified as *Eimeria legionensis* (Figure 2e). They were comparable to those described by Cordero del Campillo and Pla Hernandez (1966) measuring 18-24 μm x 12-16 μm (average: 21.3 x 14.6 μm ; index 1.46) in the red-legged partridge (Pellerdy, 1974). The oocyst wall was smooth, bilayered, with a yellow-brown outer and a bluish-greenish inner layer. A clear micropyle was detected, a small opening slightly marked, around or beneath which one or two granulations are present. In sporulated oocysts, there is no oocyst residuum. Almond-shaped sporocysts (Figure 2f), measuring 9.8 μm x 6.2 μm on average, had a small not very prominent Stieda body pointing at an end. A small sporocyst-residuum was visible between sporozoites.

Gross lesions. *E. legionensis* mainly invaded the caeca. Low mortality was observed (1 out of 23 birds). On 5 DPI, compared to a caecum from a healthy bird (Figure 5a), caeca were pale, whitish or cream-coloured, enlarged (Figure 5b) and shortened. After splitting, no normal caecal content was observed; in some birds, pinpoint haemorrhages were visible on the crest of longitudinal or transverse folds. No blood was found in the caecal lumen, but caseous material condensed into off-white cheesy cores (Figures 5 c & d), sometimes

fragmented, was later shed as such in the faeces. On 6 DPI, in most cases, folds were not visible in the caeca; walls were thickened, oedematous and showed typical catarrhal inflammatory changes. Whitish or yellowish cores floated in a whitish transudate in the caecal lumen (Figure 5d); after discarding this transudate, an inflamed mucosa appeared (Figure 5e). In most cases, both caeca were affected (Figure 5f), but sometimes, one was more affected (caseous cores) than the other (frothy fluid), as shown in figure 5g. Caseous cores stuffed with oocysts were excreted in droppings. No blood was found in the caeca as can be seen in chickens infected with *E. tenella* (Johnson and Reid, 1970); however, on 4 and 5 DPI, reddish droppings were observed.

Oocyst excretion. In red-legged partridges inoculated with 2×10^5 *E. legionensis* sporulated oocysts, the first oocysts were detected 5 DPI (1.1×10^6 OPG of faeces), then oocyst shedding peaked 6 DPI (6.4×10^6 OPG), remained high 7 DPI, decreased 8 DPI and persisted between 1 to 2×10^6 OPG up to D15 (Figure 6c). Thus, the prepatent period was of 5 days and the patent period of more than 10 days (15 DPI = end of examinations).

No oocysts belonging to other species of *Eimeria* reported in red-legged partridge, e.g. *E. gonzalezi* (Lizcano Herrera and Romero Rodriguez, 1972) or *E. padulensis* (Romero Rodriguez J. and Lizcano Herrera J., 1974) – were found.

Discussion

Today, polymerase chain reaction (PCR) based assay may be used for detection, identification and differentiation of chicken *Eimeria* species (Beate *et al.*, 1998; Kawahara *et al.*, 2008). However, for partridge *Eimeria*, species-specific primers are right now not available. Then,

the examination of oocysts, size, colour, shape, thickness of wall, presence or absence of a micropyle, a polar granule, an oocyst residuum, sporocyst residuum and size of sporocysts are helpful in identification of the species in comparison with original description and literature references; Table 3 compares our results to those found in literature.

Oocysts identified as *Eimeria kofoidi* measuring 14.0-21.4 μm x 12.0-19.5 μm (19.3 x 16.3 μm in average, shape index 1.18) were slightly smaller than those originally described by Yakimoff and Matikaschwili (1936) from faeces collected in a cage housing both chukka partridge (*Alectoris chukar*) and grey partridge (*Perdix perdix*) and than those described by Dumanli and Ozer (1985) but having the same shape index (1.18) in the rock partridge (*Alectoris graeca*). Lizcano Herrera and Romero-Rodriguez (1972) reported oocysts presenting a different index of 1.43 in the red-legged partridge, which were considered as a different species by Hernandez Rodriguez *et al.* (1974); these authors re-describing smaller oocysts (17.2 x 14.0 μm) with a shape index of 1.23. In our case, the smallest observed oocysts measured 14 x 12 μm with a shape index of 1.16.

Oocysts identified as *Eimeria caucasica* measuring 26.0-33.5 μm x 16.7-23.3 μm (29.8 x 19.5 μm in average, shape index 1.53) had a morphology fairly comparable to that of *E. caucasica* originally described by Yakimoff and Buewitsch (1932) or that observed by Svanbaev and Utebaeva (1973) in chukka partridges. *E. caucasica* were also reported with a smaller shape index in the Rock partridge by Davronov (1985) and Dumanli and Ozer (1985). Musaev and Veisov (1963) considered *E. caucasica* as a synonym of *E. coturnicis* described by Chakravarty and Kar (1947), which are coccidia of the common grey quail (*Coturnix coturnix coturnix*) measuring 26-39 μm x 20-26 μm (Pellerdy, 1974).

Oocysts identified as *Eimeria legionensis* measuring 18.6-26 μm x 13-16.7 μm (22.6 x 14.9 μm in average, shape index 1.52), were comparable to those described by Cordero del Campillo and Pla Hernandez (1966) in the red-legged partridge (Pellerdy, 1974) and those

described by Bolognesi *et al.*, (2006) in the same host. Sporocyst size (9.8 x 6.2 μm) was comparable to that (9.7 x 5.6 μm) reported by Bolognesi *et al.*, (2006).

E. kofoidi and *E. caucasica* invaded mainly the duodenum and jejunum without inducing mortality at the inoculated doses of 300,000 and 30,000 oocysts, respectively. *E. kofoidi* lesions reminded *E. acervulina* lesions in chickens (Johnson and Reid, 1970), causing white streaks or spots clearly visible on the intestinal serosal and mucosal surfaces. As *E. acervulina* (McMullin, 2004), a high inoculation dose (300,000 oocysts / bird) did not cause mortality. *E. caucasica*, with its large oocysts, and petechia observed on the serosa, was closer to *E. maxima* in chickens (Johnson and Reid, 1970), or with false membranes to *E. meleagrimitis* in turkeys (anonym, 1999; McMullin, 2004; Répérant, 2006). *E. caucasica* was inoculated at a 10-time lower dose than *E. kofoidi* because mortality (1 out of 4 birds) had been observed during multiplication in partridges inoculated with 50,000 *E. caucasica* oocysts. It appeared more pathogenic than *E. kofoidi*; this seems to be confirmed in this study, considering the number of oocysts inoculated and the intensity of gross lesions. To compare the pathogenicity of these two intestinal species, their incidence on partridge mortality, zootechnical and economic performance must be assessed from the same inoculation dose. In our trial, only multiplication rates could be calculated and compared, by evaluating the area under the different excretion curves (AUC). As the number of inoculated oocysts was different from one coccidia to another, the AUC of each coccidia was divided by the number of inoculated oocysts to express the multiplication potential for one inoculated oocysts (AUC/1 oocyst). *E. caucasica* AUC/1 oocyst (860) was higher than that of *E. kofoidi* (327), indicating a higher multiplication potential; this difference in multiplication potential could also be explained by a crowding effect, as shown by Williams (1973) in chickens. In that case, *E. kofoidi* multiplication may have been limited because of the higher number of inoculated oocysts (compared to *E. caucasica*), creating a bias in the comparison. However, it

must be reminded that the multiplication rate does not reflect coccidia pathogenicity; for example, among the species commonly encountered in *Gallus*, *E. acervulina* is more prolific (Williams, 1973) and less pathogenic than *E. tenella* or *E. necatrix*. For both *E. kofoidi* and *E. caucasica*, coccidiosis symptoms were observed between 4 and 7 days post inoculation. Birds were droopy, ate less and excreted slimy, mucoid faeces; then they recovered and returned to normal towards 10-11 DPI.

E. legionensis invaded the caeca and induced lesions closer to *E. adenoides* in turkeys (Anonym, 1999; McMullin, 2004; Répérant, 2006) than *E. tenella* in chickens (Naciri, 2000). Its multiplication rate (AUC/1 oocyst) was lower (148) than that of *E. kofoidi* (327) and *E. caucasica* (860).

For these three species, the life cycle was of short duration because the first oocysts appeared from 5 days post inoculation, then, the prepatent period was of 5 days and the patent period of over 10 days. The extended patent period might be explained either by schizogonic stages overlapping the gamogony stage as in *E. necatrix* infection (Davies, 1956), or *E. grenieri* infection in the guinea fowl (Yvoré and Aycardi, 1967; Long and Millard, 1978) or by the recycling of type I merozoites as observed in other coccidia of the genus *Cryptosporidium* (Current et al., 1986) that may also explain why partridges develop heavy intestinal infections lasting over 10 days. This extended patent period generates a high environmental contamination that may explain some features of the coccidiosis in partridge farms, for example the difficulty to eliminate this parasite from the facilities. The parasite control is today more difficult in Europe, by the ban of preventive coccidiostats for game birds (European Directive of 14 April 2008). Indeed, curative treatments are often decided when the breeder notices coccidiosis signs on a large number of birds, but because of short coccidia cycle, most of the time, oocysts have already begun to spread when treatment is settled. As a consequence, prevention is better than cure.

The current study evaluated the pathogenic features of single coccidial infection, which nearly never happen in field conditions. It would then be interesting to study the incidence of the development of each species on one hand and their association on the other hand, on mortality and zootechnical performance of birds.

Acknowledgments

We are grateful to Thierry Chaumeil and Maud Renouard from the “Plate-Forme d’Infectiologie Expérimentale” (PFIE) for their technical assistance, and to Marie-Estelle Esnault from the documentation department for the research of documents related to partridge coccidiosis.

References

- Anonym, (1999). Coccidiose de la dinde. Bayer avec la participation de l’AFSSA-Ploufragan. Edition Bayer Pharma Santé Animale, Puteaux, France, 56 p.
- Beate, E.S., Per, L.T., Jens, G.M., Fiona, M.T. & Martin, W.S., (1998). Development of diagnostic PCR assay for the detection and discrimination of four pathogenic *Eimeria* species of the chicken. *Avian Pathology*, 27, 490-497.
- Bolognesi, P.G., Galuppi, R., Catelli, E., Cecchinato, M., Frasnelli, M., Raffini, E., Marzadori, F. & Tampieri, M.P. (2006). Outbreak of *Eimeria kofoidi* and *E. legionensis* coccidiosis in red-legged partridges (*Alectoris rufa*). *Italian Journal of Animal Science*, 5, 318-320.

- Chakravarty, M. & Kar, A.B. (1947). A study on the coccidia of Indian birds. *Proceedings of the Royal Society of Edinburgh* 62, 225-233.
- Cordero del Campillo, M. & Pla Hernandez, M. (1966). Sobre las coccidiosis de las perdices, con descripcion de *E. legionensis* n. sp., parasita de *Alectorix rufa* L. y una clave para su diferenciacion. *Revista Iberica de Parastologia*, 26, 27-41.
- Current, W.L., Upton, S.J. & Haynes, T.B. (1986). The life cycle of *Cryptosporidium baileyi* n. sp. (Apicomplexa, Cryptosporidiidae) infecting chickens. *Journal of Eukaryotic Microbiology*, 33, 289-296.
- Davies, S.F.M. (1956). Intestinal coccidiosis in chickens caused by *Eimeria necatrix* . *Veterinary Record*, 68, 853-857.
- Davronov, O. (1985). On the coccidial fauna of partridges in Uzbekistan. *Uzbekskii Biologicheskii Zhurnal*, 1, 47-49.
- Dumanli, N. & Ozer, E. (1985). The incidente of the *Eimeria* species in partridges (*Alectoris graeca*) in Elazig vicinity. *Selçuk Universitesi Veteriner Fakultesi Dergisi*, 1, 95-99.
- Duperray, J. (2010). Personal communication.
- European Directive of 14 April 1983. [Arrêté du 14 avril 2008 abrogeant l'arrêté du 24 août 1983 fixant la liste et les conditions d'incorporation des additifs aux aliments pour gibier de tir (NOR : ECEC08002678A)]
- Hernandez Rodriguez, S., Martinez Gomez, F., & Calero Carretero, R. (1974). Life cycle of coccidia of Spanish partridges. *Proceedings of the 3rd International Congress of Parasitology*, 1, (pp. 95-96). Facta Publication, Vienna.
- Johnson, J. & Reid, W.M. (1970). Anticoccidial drugs: lesion scoring techniques in battery and floor-pen experiments with chickens. *Experimental Parasitology*, 28, 30-36.
- Joyner, L.P. & Long, P.L. (1974). The specific characters of *Eimeria*, with special reference to the coccidian of the fowl. *Avian Pathology*, 3, 145-157.

- Kawahara, F., Taira, K., Nagai, S., Onaga, H., Onuma, M. & Nunoya, T. (2008). Detection of five avian *Eimeria* species by species-specific real-time polymerase chain reaction assay. *Avian Disease*, 52, 652-656.
- Lizcano Herrera J. & Romero Rodriguez J. (1972). Contribucion al estudio de las coccipatias del *Alectoris rufa* (L.). *Revista Iberica de Parastologia*, 32, 95-113.
- Long, P.L., & Millard, B.J. (1978). Studies on *Eimeria grenieri* in the guinea fowl. *Parasitology*, 76, 1-9.
- McMullin, P. (2004). A pocket guide to poultry health and disease.
<http://www.thepoultrysite.com/diseaseinfo/84/coccidiosis-of-turkeys>
- Millan, J. (2009). Diseases of the red-legged partridge (*Alectoris rufa* L.): a review. *Wildlife Biology in Practice*, 5, 70-88.
- Musaev, M.A. & Veisov, A.M. (1963). New species of coccidia belonging to the genus *Eimeria* from the jerboa (*Allactaga elater* Licht., 1825). *Zoologicheskii Zhurnal*, 42, 126-128.
- Naciri, M. (2000). Coccidioses du poulet. INRA-Bayer. Edition Bayer Pharma Santé Animale, Puteaux, France, 124 p.
- Pellerdy, L. (1974). *Coccidia and coccidiosis*. 2nd ed. Paul Parey, Berlin and Hambourg, West Germany.
- Ponce-Boutin, F. (2000). La perdrix rouge [Red-legged partridge]. *Gibier Faune Sauvage*, 251, 46-53.
- Répérant, J.M. (2006). Coccidies du dindon. Fiches techniques de parasitologie. Ceva SA, 24p.
- Romero Rodriguez J. & Lizcano Herrera J. (1974). *Eimeria padulensis* n sp. Protozoa-eimeriidae parasite del *Alectoris rufa* (L.). *Revista Iberica de Parastologia*, 34, 29-32.

- Shirley, M.W. & Harvey, D.A. (1996). *Eimeria tenella*: infection with a single sporocyst gives a clonal population. *Parasitology*, 112, 523-528.
- Svanbaev, S.K. & Utebaeva, M.K. (1973). Coccidial infections in some species of wild galliform birds in Kazakhstan. *Vestnik Sel'yaskochochozyaystvennoy Nauk Kazakhstana*, pp. 11.
- Vallance, M., Queney, G., Soyez, D. & Ricci J.C. (2006). Mise au point et validation d'un système de marqueurs génétiques pour les perdrix rouges hybrides. *ONCSF Rapport scientifique*, 76-80.
- Williams, R.B. (1973). Effect of different infection rates on the oocyst production of *Eimeria acervulina* or *Eimeria tenella* in the chickens. *Parasitology*, 67, 279-288.
- Yakimoff, W. L., & Buewitsch, B. (1932). Zur Frage der Coccidien wildlebender Vögel in Aserbaidshen (Transcaucasus). *Archiv für Protistenkunde*, 77, 187-191.
- Yakimoff, W.L. & Matikaschwili, I.L. (1936). Coccidiosis of the grey and stone partridge. *Parasitology*, 28, 146-147.
- Yvoré, P. & Aycardi, J. (1967). Une nouvelle coccidie *Eimeria grenieri* n.sp. (Protozoa : Eimeriidae) parasite de la pintade *Numida meleagris*. *Comptes Rendus de l'Académie des Sciences, Paris*, t.264, 73-76.

Figure legends

Figure 1. *Red-legged partridges (36 days old):*

Uninoculated (a) and Eimeria infected (b)

Intestine of uninoculated bird : duodenum and jejunum (c);

jejunum (d); ileum, caecum and rectum (e)

Figure 2. *E. kofoidi sporulated oocysts (a) and sporocysts (b);*

E. caucasica sporulated oocyst (c) and sporocysts (d);

E. legionensis sporulated oocysts (e) and sporocysts (f).

(PG = Polar granule; SB = Stieda body; G = Granule; M = Micropyle).

Figure 3. *E. kofoidi gross lesions : whitish swollen intestine and normal caeca (a) ; whitish streaks in duodenum and jejunum visible through the serosa (b) and clearly present in duodenal mucosa (c) ; distended duodenum filled with whitish/orange mucus and gas (d); ileal bottle-green content (e)*

Figure 4. *E. caucasica: copious orange-yellowish mucus in duodenum (a); whitish-orange mucus floating in colourless fluid and gas in jejunum (b); colorless fluid and whitish membrane coating duodenal mucosa due to the sloughed mucosa (c); false membrane floating in colourless fluid in jejunum (d); fluorescent green content of ileum (e, f); whitish thickened ileal mucosa and normal caeca (g).*

Figure 5. *E. legionensis gross lesions: normal caecum (a); infected caecum (b);*

core formation on 5 DPI (c); core floating in whitish transudate (d) and thickened and inflamed cecal wall on 6 DPI (e); both caeca similarly affected (f) or one more than the other (g)

Figure 6. *Oocyst excretion of 31 day-old red-legged partridges inoculated*

with 300,000 sporulated oocysts E. kofoidi (a) ; Oocyst excretion of 31 day-old red-legged partridges inoculated with 30,000 sporulated oocysts E. caucasica (b) ; Oocyst excretion of 31 day-old red-legged partridges inoculated with 200,000 sporulated oocysts E. legionensis (c)




Figure 1. Red-legged partridges (36 days old):
Uninoculated (a) and *Eimeria* infected (b)
Intestine of uninoculated bird: duodenum and jejunum (c);
jejunum (d); ileum, caecum and rectum (e)

Table 1. Differential characteristics of oocysts for 3 *Eimeria* species of red-legged partridges (*Alectoris rufa*)

<i>Eimeria</i> species	Shape	Oocyst					Sporocyst			
		length (µm)	width (µm)	Shape index	Wall layers	Micropyle	Granule	Shape	Average size (µm)	Granules
<i>E. kofoidi</i>	Spherical to broadly ovoid	19.3 [14.0 - 21.4]	16.3 [12.0 - 19.5]	1.18	Brown, bilayered Outer: yellowish Inner: bluish	No	1, 2 or more polar granules	Almond shape	9.4 x 5.3	Granular residuum
<i>E. caucasica</i>	Ellipsoid-ovoid	29.8 [26.0 - 33.5]	19.5 [16.7 - 23.3]	1.53	Yellow-blue-green bilayered	No	1 large granule	Ovoid	12.7 x 7.8	Dark granules interspersed between sporozoites
<i>E. legionensis</i>	Elliptic Symmetrical flattened walls	22.6 [18.6 - 26.0]	14.9 [13.0 - 16.7]	1.52	Smooth, bilayered Outer: yellow, brown Inner: bluish, greenish	Yes	1 or 2 granules around micropyle	Almond shape	9.8 x 6.2	Small residuum

Table 2. Results summarized for each of 3 *Eimeria* species inoculated to red-legged partridges: intestinal site of development, gross lesions, prepatent periods, date of oocysts excretion peak (in days post inoculation d.p.i.) and number of oocysts per gram of faeces (opg) at peak of excretion

<i>Eimeria</i> species	Inoculation dose oocysts/bird	Intestinal site of development	Gross lesions	Mortality (%)	Prepatent period (days)	Peak of oocyst excretion (opg)
<i>E. kofoidi</i>	300,000	Duodenum, jejunum	Whitish steaks or spots were clearly visible from serosal or mucosal surfaces. Mucosa initially thickened, oedematous, covered by coalescent whitish streaks on 4 d.p.i., sloughed and became thinner on 5 d.p.i. Upper intestine was filled with white-yellowish or yellow-greenish or fluorescent green thick mucous, gas and false-membrane.	No	5	23.2x10 ⁶ (9 d.p.i.)
<i>E. caucasica</i>	30,000	Duodenum, jejunum	Duodenal serosal surface was pinkish or reddish. Mucoïd duodenitis and catarrhal enteritis were observed. On 4 d.p.i., copious orange-yellowish mucous in duodenal lumen and whitish-orange mucous floated in colourless fluid and gas in jejunum. On 6 d.p.i., after sloughing, false-membrane floated in colourless fluid, mucosal surface was eroded and intestine was pale and fragile.	No	5	8.6 x 10 ⁶ (8 d.p.i.)
<i>E. legionensis</i>	200,000	Caeca	On 5 d.p.i., caeca were pale, whitish or cream-coloured, swollen and shortened. After splitting, no normal caecal content but off-white cheesy cores in the caecal lumen and pinpoint haemorrhages were observed on the crest of longitudinal or transverse folds. On 6 d.p.i., folds were invisible; caecal walls were thickened, oedematous, showing catarrhal inflammatory changes. Whitish or yellowish cores floated in a whitish transudate in the caecal lumen.	4.3	5	6.4 x 10 ⁶ (6 d.p.i.)

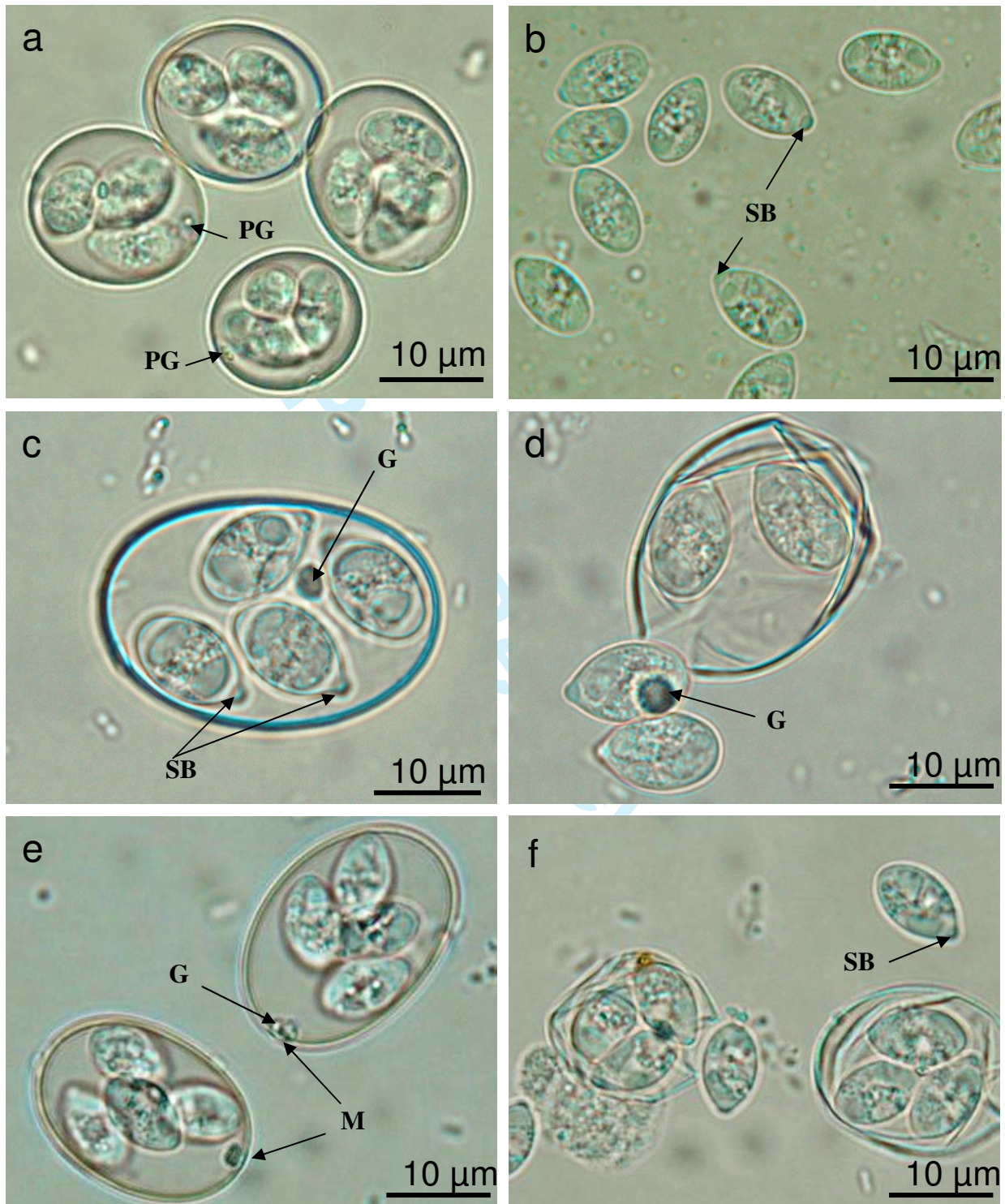


Figure 2. *E. kofoidi* sporulated oocysts (a) and sporocysts (b);
E. caucasica sporulated oocyst (c) and sporocysts (d);
E. legionensis sporulated oocysts (e) and sporocysts (f).
(PG = Polar granule; SB = Stieda body; G = Granule; M = Micropyle).

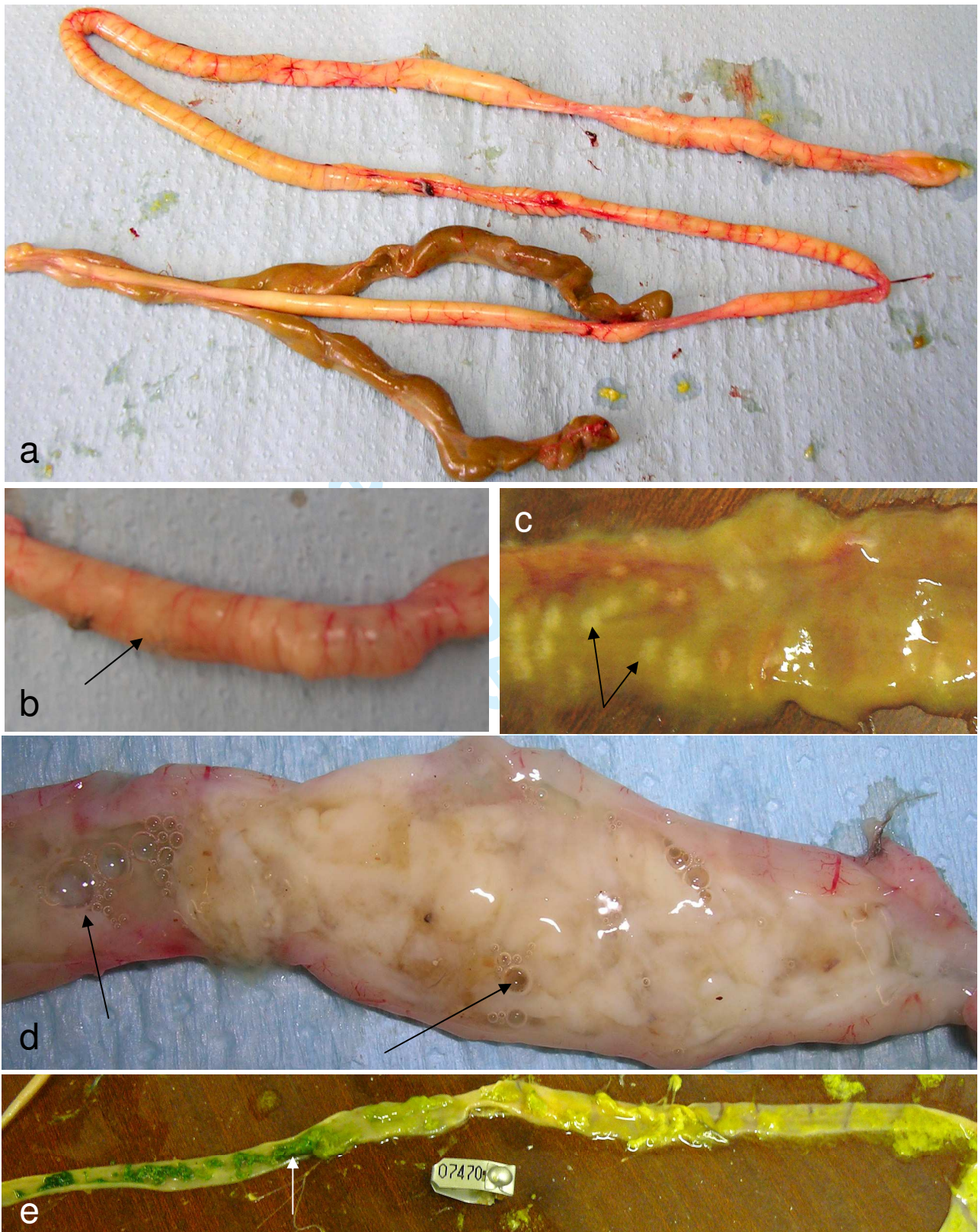


Figure 3. *E. kofoidi* gross lesions: whitish swollen intestine and normal caeca (a); whitish streaks in duodenum and jejunum visible through the serosa (b) and clearly present in duodenal mucosa (c); distended duodenum filled whitish/orange mucus and gas (d); green ileal content (e)

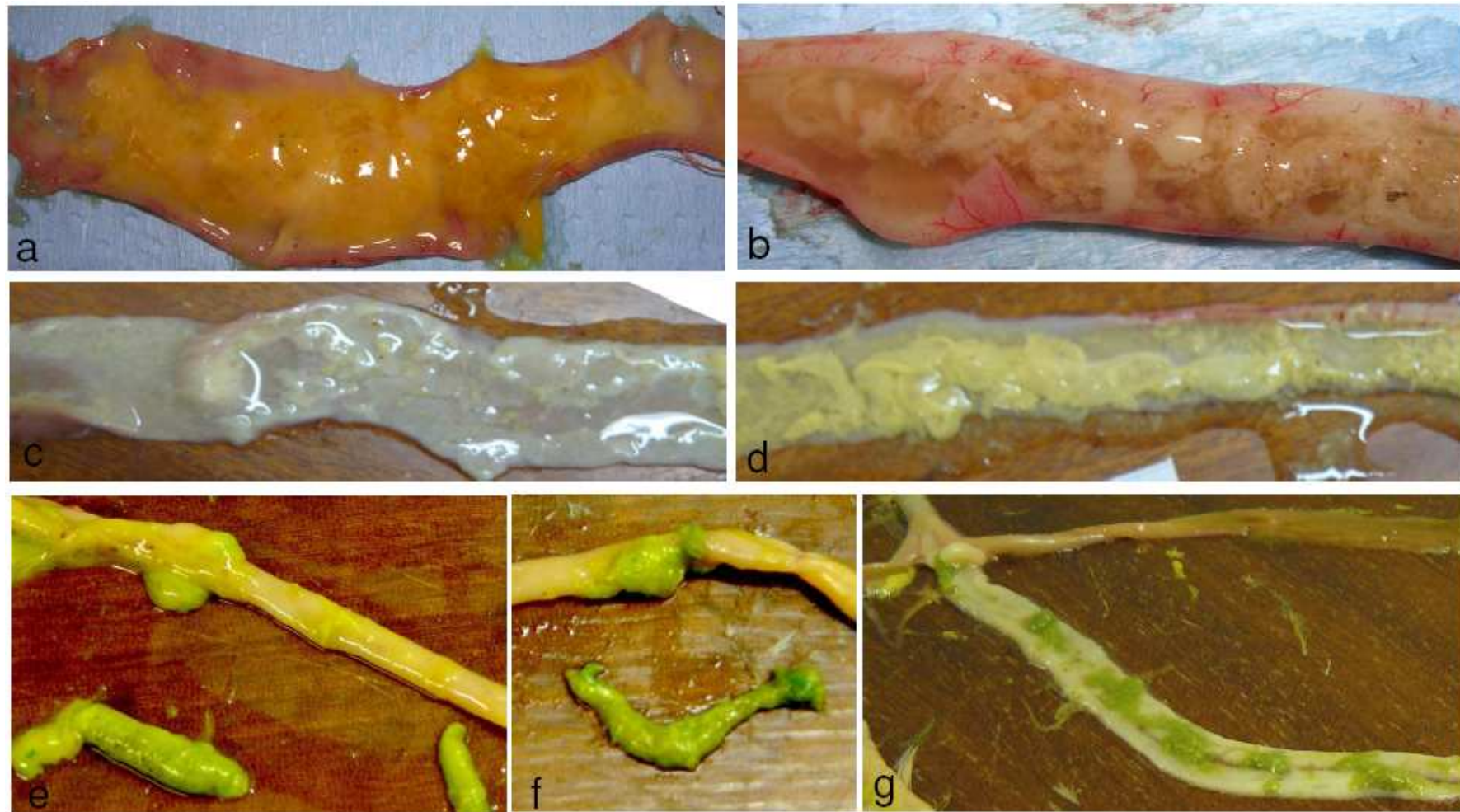


Figure 4. *E. caucasica*: copious orange-yellowish mucus in duodenum (a); whitish-orange mucus floated in colourless fluid containing gas in jejunum (b); colourless fluid and whitish membrane coating duodenal mucosa due to the sloughed mucosa (c); false membrane floating in colourless fluid in jejunum (d); fluorescent green content of ileum (e, f); whitish thickened ileum mucosa and normal caeca (g).

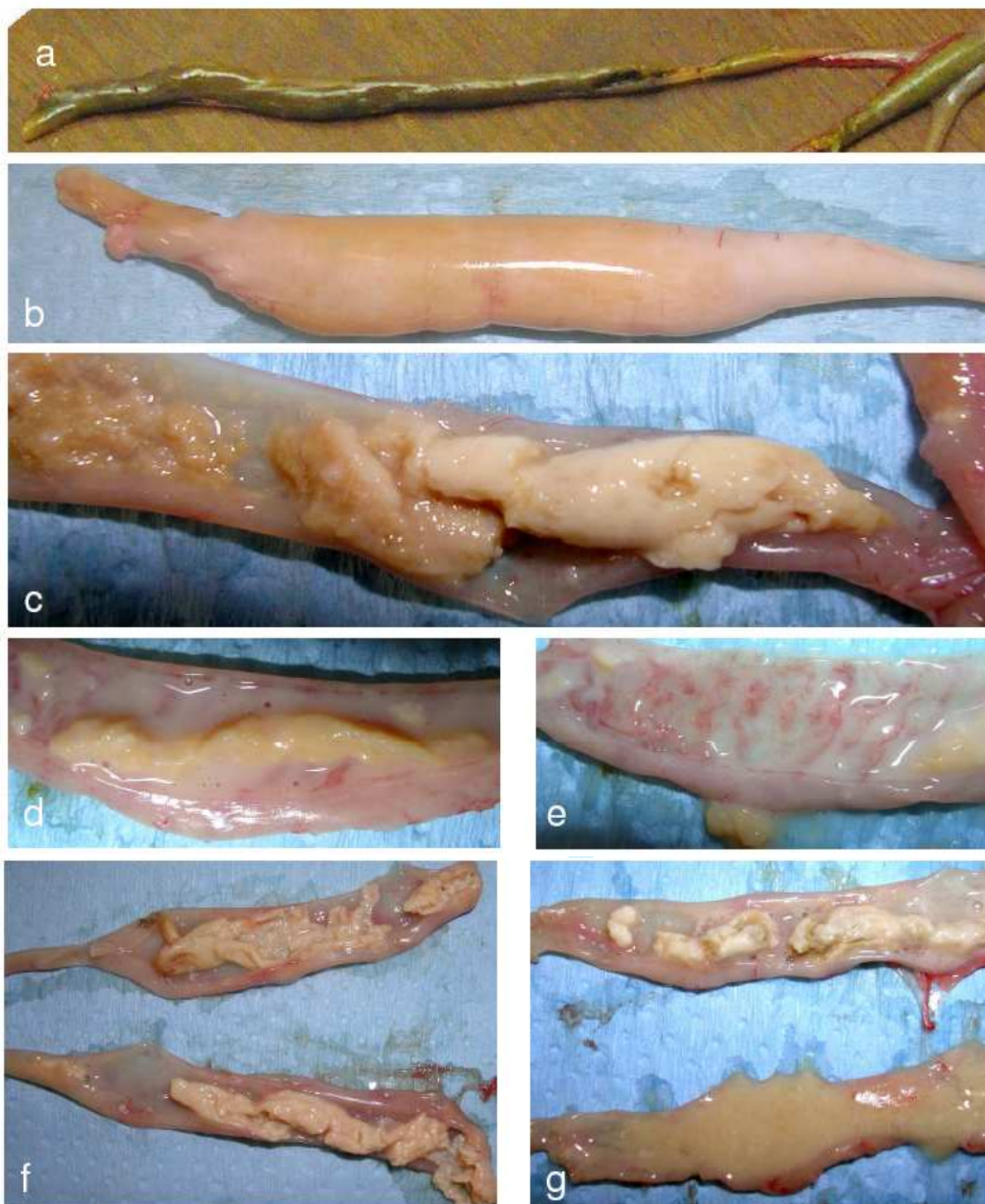


Figure 5. *E. legionensis* gross lesions: normal caecum (a); infected caecum (b); core formation on 5 dpi (c); core floating in whitish transudate (d) and thickened and inflamed cecal wall on 6 dpi (e); both caeca similarly affected (f) or one more than the other (g)

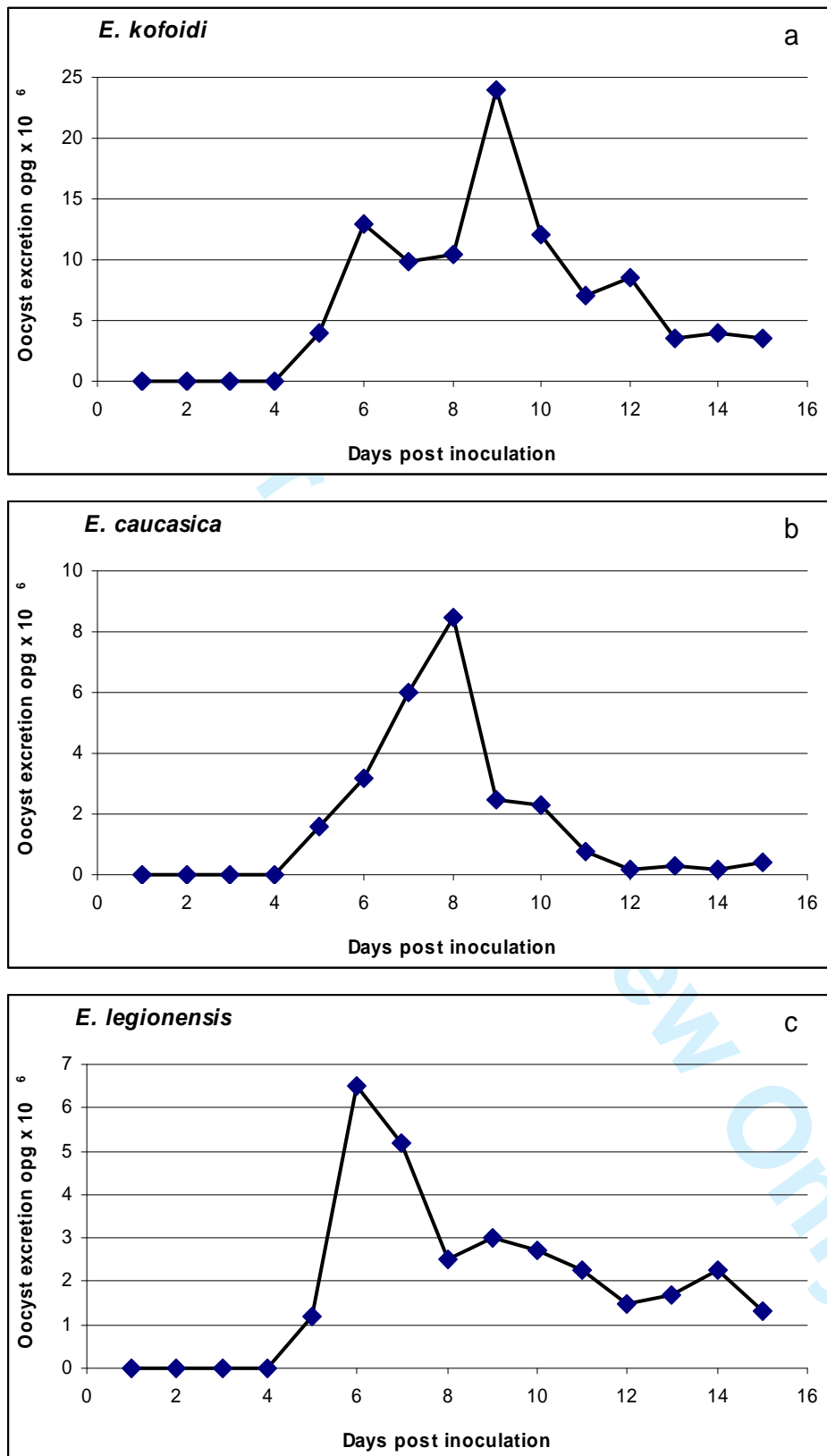


Figure 6. Oocyst excretion of 31 day-old red-legged partridges inoculated with 300,000 sporulated oocysts *E. kofoidi* (a) ; Oocyst excretion of 31 day-old red-legged partridges inoculated with 30,000 sporulated oocysts *E. caucasica* (b) ; Oocyst excretion of 31 day-old red-legged partridges inoculated with 200,000 sporulated oocysts *E. legionensis* (c)

Table 3. Comparison of current study results with literature references

<i>Eimeria</i> species	Host	Size length x width (µm)	Average size (µm)	Shape index (length / width)	Literature references
<i>E. kofoidi</i>	<i>Alectoris rufa</i>	14.0-21.4 x 12.0-19.5	19.3 x 16.3	1.18	Current study
	<i>Alectoris chukar</i>	16-25 x 14-20	20 x 17.6	1.14	Yakimoff & Matikaschwili, 1936 Pellerdy, 1974
	<i>Perdix perdix</i>				
	<i>Alectoris graeca</i>	19.7-24.0 x 16.9-19.7	21.7 x 18.4	1.18	Dumanli & Ozer, 1985
	<i>Alectoris rufa</i>	13.6-20.9 x 7.6-15.2	19 x 13.3	1.43	Lizcano Herrera & Romero-Rodriguez, 1972
	<i>Alectoris rufa</i>		17.2 x 14.0	1.23	Hernandez Rodriguez <i>et al.</i> , 1974
	<i>Alectoris rufa</i>	16-19 x 14-16	17.4 x 14.9	1.16	Bolognesi <i>et al.</i> , 2006
<i>E. caucasica</i>	<i>Alectoris rufa</i>	26.0-33.5 x 16.7-23.3	29.8 x 19.5	1.53	Current study
	<i>Alectoris chukar</i>	25.2-36.0 x 14.4-21.6	32.7 x 19.0	1.72	Yakimoff & Buewitsch, 1932
	<i>Alectoris chukar</i>	23.2-32.8 x 17.4-26.1			Svanbaev & Utebaeva, 1973
	<i>Alectoris graeca</i>	23.8-32.3 x 17.0-25.5	27.8 x 20.4	1.36	Davronov, 1985
	<i>Alectoris graeca</i>	23.0-31.2 x 18.3-24.0	25.9 x 20.4	1.27	Dumanli & Ozer, 1985
= <i>E. coturnicis</i>	<i>Coturnix coturnix coturnix</i>	26-39 x 20-26			Musaev & Veisov, 1963
<i>E. legionensis</i>	<i>Alectoris rufa</i>	18.6-26 x 13-16.7	22.6 x 14.9	1.52	Current study
	<i>Alectoris rufa</i>	18-24 x 12-16	21.3 x 14.6	1.46	Cordero del Campillo & Pla Hernandez, 1966
	<i>Alectoris rufa</i>	19-24 x 13-16	22.0 x 15.3	1.43	Bolognesi <i>et al.</i> , 2006