



HAL
open science

Decreased myeloperoxidase expressing cells in the aged rat brain after excitotoxic damage

Oscar Campuzano, Maria del Mar Castillo-Ruiz, Laia Acarin, Berta Gonzalez, Bernardo Castellano

► **To cite this version:**

Oscar Campuzano, Maria del Mar Castillo-Ruiz, Laia Acarin, Berta Gonzalez, Bernardo Castellano. Decreased myeloperoxidase expressing cells in the aged rat brain after excitotoxic damage. *Experimental Gerontology*, 2011, 46 (9), pp.723. 10.1016/j.exger.2011.05.003 . hal-00720179

HAL Id: hal-00720179

<https://hal.science/hal-00720179>

Submitted on 24 Jul 2012

HAL is a multi-disciplinary open access archive for the deposit and dissemination of scientific research documents, whether they are published or not. The documents may come from teaching and research institutions in France or abroad, or from public or private research centers.

L'archive ouverte pluridisciplinaire **HAL**, est destinée au dépôt et à la diffusion de documents scientifiques de niveau recherche, publiés ou non, émanant des établissements d'enseignement et de recherche français ou étrangers, des laboratoires publics ou privés.

Accepted Manuscript

Decreased myeloperoxidase expressing cells in the aged rat brain after excitotoxic damage

Oscar Campuzano, Maria del Mar Castillo-Ruiz, Laia Acarin, Berta Gonzalez, Bernardo Castellano

PII: S0531-5565(11)00123-9
DOI: doi: [10.1016/j.exger.2011.05.003](https://doi.org/10.1016/j.exger.2011.05.003)
Reference: EXG 8882

To appear in: *Experimental Gerontology*

Received date: 22 December 2010
Revised date: 12 April 2011
Accepted date: 6 May 2011



Please cite this article as: Campuzano, Oscar, Castillo-Ruiz, Maria del Mar, Acarin, Laia, Gonzalez, Berta, Castellano, Bernardo, Decreased myeloperoxidase expressing cells in the aged rat brain after excitotoxic damage, *Experimental Gerontology* (2011), doi: [10.1016/j.exger.2011.05.003](https://doi.org/10.1016/j.exger.2011.05.003)

This is a PDF file of an unedited manuscript that has been accepted for publication. As a service to our customers we are providing this early version of the manuscript. The manuscript will undergo copyediting, typesetting, and review of the resulting proof before it is published in its final form. Please note that during the production process errors may be discovered which could affect the content, and all legal disclaimers that apply to the journal pertain.

**DECREASED MYELOPEROXIDASE EXPRESSING CELLS IN THE AGED RAT BRAIN AFTER
EXCITOTOXIC DAMAGE**

Oscar Campuzano, PhD*; Maria del Mar Castillo-Ruiz, MSc*; Laia Acarin, PhD; Berta Gonzalez, PhD and
Bernardo Castellano, PhD

Department of Cell Biology, Physiology and Immunology, Unit of Medical Histology, Faculty of Medicine and
Institute of Neurosciences, Autonomous University of Barcelona, Bellaterra 08193, Barcelona, Spain.

* Both authors contributed equally to the work

Corresponding authors:

Dr. Oscar Campuzano and Dr. Laia Acarin

Medical Histology Unit, Torre M5,

Department of Cell Biology, Physiology and Immunology, Institute of Neurosciences

Autonomous University of Barcelona,

08193 Bellaterra (Barcelona), Spain

Tel: +34 935811826

Fax: +34 935812392

E-mail: oscar@brugada.org

laia.acarin@uab.cat

ABSTRACT

Brain aging is associated to several morphological and functional alterations that influence the evolution and outcome of CNS damage. Acute brain injury such as an excitotoxic insult induces initial tissue damage followed by associated inflammation and oxidative stress, partly attributed to neutrophil recruitment and the expression of oxidative enzymes such as myeloperoxidase (MPO), among others. However, to date, very few studies have focused on how age can influence neutrophil infiltration after acute brain damage. Therefore, to evaluate the age-dependent pattern of neutrophil cell infiltration following an excitotoxic injury, intrastriatal injection of N-methyl-D-aspartate was performed in young and aged male Wistar rats. Animals were sacrificed at different times between 12 hours post-lesion (hpl) to 14 days post-lesion (dpl). Cryostat sections were processed for myeloperoxidase (MPO) immunohistochemistry, and double labeling for either neuronal cells (NeuN), astrocytes (GFAP), perivascular macrophages (ED-2), or microglia/macrophages (tomato lectin histochemistry). Our observations showed that MPO+ cells were observed in the injured striatum from 12 hpl (when maximum values were found) until 7 dpl, when cell density was strongly diminished. However, at all survival times analyzed, the overall density of MPO+ cells was lower in the aged versus the adult injured striatum. MPO+ cells were mainly identified as neutrophils (especially at 12 hpl and 1 dpl), but it should be noted that MPO+ neurons and microglia/macrophages were also found. MPO+ neurons were most commonly observed at 12 hpl and reduced in the aged. MPO+ microglia/macrophages were the main population expressing MPO from 3 dpl, when density was also reduced in aged subjects.

These results point to neutrophil infiltration as another important factor contributing to the different response of the adult and aged brain to damage, highlighting the need of using aged animals for the study of acute age-related brain insults.

Key words: Aging; Striatum; Excitotoxicity; Neutrophil; MPO; inflammation.

INTRODUCTION

Acute injury to the central nervous system (CNS), such as traumatic brain injury, brain ischemia or excitotoxicity induces primary tissue damage which elicits an inflammatory response [1]. This response is associated with secondary damage to surrounding tissue, contributing to delayed cell death and determining the final extent of tissue damage and lesion outcome [2]. Besides the endogenous glial cell population, it is known that endothelial cells and leukocytes recruited from the blood are also significant cellular components of the neuroinflammatory process [3-5]. Among leukocytes, neutrophils enter into the sites of CNS injury during the first hours after the insult, forming the first line of defense [6, 7], being followed by monocytes at longer survival times [8]. Neutrophils are the most abundant type of circulating white blood cells and belong to the polymorphonuclear cell family (PMNs) due to their multilobulated nuclei [9]. Massive neutrophil infiltration and accumulation in sites of CNS injury induces the release of toxic substances such as reactive oxygen species (ROS) [5], which contribute to tissue damage [10], BBB dysfunction [11, 12] and delayed neuronal death. Myeloperoxidase (MPO) is a heme-containing peroxidase that constitutes the most abundant component in azurophilic granules in neutrophils, has often been used as an histopathological marker for neutrophils [13, 14], and has recently been used as an *in vivo* marker of brain inflammation [15].

It is well known that aging is associated with an enhanced susceptibility to suffer CNS chronic and acute diseases combined with poor post-injury recovery, which becomes an important health challenge considering the increasing life expectancy [16-18]. At the cellular level, non-pathological age-related brain changes include metabolic disarrangements, excessive production of ROS and other morphological and functional alterations in neuronal and glial cells, inducing basal glial reactivity and decreased BBB permeability [19-22]. However, although it is assumed that these characteristics influence the response to brain injury, currently most studies still use young adult animals for the analysis of post-injury inflammatory processes.

In this regard, we have previously reported that neuronal, glial and inflammatory responses to acute striatal excitotoxic injury show significant age-differences in rats [23, 24]. Aged (22-24 months old) animals display a delay in the neurodegenerative process, tissue damage and edema, concomitant with an earlier astroglial and microglial/macrophagic responses [23, 24]. In addition, aged animals display increased basal levels of cytokines, but attenuated post-injury induced cytokine response [24, 25], in parallel with reduced expression of the inflammatory enzyme inducible nitric oxide synthase (iNOS) and increased expression of cyclooxygenase-2 (COX2) [24, 25]. As neutrophils are important contributors to the production of these inflammatory mediators which show age-related differences, and MPO is an enzyme contributing to oxidative stress, the aim of the present study was to identify and assess putative changes in the presence of MPO expressing cells after acute striatal damage in the aged versus the adult rat brain.

MATERIALS AND METHODS

Animals

For this study we have used a total of 94 male Wistar rats: 47 adult (3–4 months of age) and 47 aged (22–24 months) rats. Animals of both ages were distributed into three groups: intact controls (n=5 in each age group), saline-injected controls (n=12 in each age group) and N-methyl-D-aspartate (NMDA)-lesioned animals (n=30 in each age group). Animals were housed individually in cages with free access to food and water, controlled temperature (22°C), humidity (55%) and light/dark cycle (12h, 8pm-8am). All experimental work was conducted according to established European Union bioethical directives and was approved by the ethical commission of the Universitat Autònoma de Barcelona. During all experimental procedures, unnecessary animal suffering was avoided.

Excitotoxic Lesions

Rats were placed in a stereotaxic frame under isofluorane anesthesia, the skull was opened using a surgical drill, and 1µl of saline solution (0.9% NaCl, pH 7.4) containing 120 nmols of N-methyl-D-aspartate (NMDA) (Sigma, M-3262) was injected into the right striatum (caudate-putamen, bregma coordinates A=+0.12, L=-0.3; V=-0.45 cm) [26] using a 1µl Hamilton microsyringe coupled to an automatic microinjector (Stoelting, Illinois, USA) at a speed of 0.2µl/minute. After the injection, the needle was kept 10 minutes in order to facilitate diffusion into the striatum and minimize reflux. Saline-injected control animals received an injection of 1µl of the vehicle saline solution. After suture, rats were placed in a thermal pad and maintained at normothermia until they recovered from anesthesia.

Sacrifice and tissue processing

For histological and immunohistochemical analysis, after 12 hours (hpl), 1 day, 3 days, 5 days, 7 days and 14 days after injection (dpl), a minimum of 5 NMDA-lesioned animals and 2 saline-injected controls for each age group and survival time were anesthetized and intracardially perfused for 10 min with 4% formaldehyde in 0.1 M phosphate buffer (pH 7.4). After perfusion, brains were quickly removed, postfixed for 4 hr at 4°C in the same fixative, washed twice in buffer and immersed for cryoprotection in a 30% saccharose solution in 0.1M phosphate buffer (pH 7.4) until they sunk and were quickly frozen with dry CO₂. Intact control animals were processed equally. Thirty-micron-thick parallel frozen coronal sections were obtained with a Leica cryostat and were either stored floating free in antifreeze solution at -20°C or mounted on gelatin-coated slides.

Toluidine Blue Staining

Sections mounted on slides were rinsed, stained with toluidine blue (0.1% toluidine blue solution in Walpole buffer -pH 4.5- for 15 min), rinsed, dehydrated, and differentiated in n-butyl alcohol. After rinsing, slides were air dried, cleared in xylene, and coverslipped in DPX. These sections were used for the histological control of the intracerebral injection and to determinate the sites of cell counting (Fig 1).

Single immunohistochemistry

Free-floating parallel sections were rinsed thoroughly in tris buffered saline (TBS) (0.05M Trizma base, 150 mM NaCl, pH 7.4) and endogenous peroxidase was blocked with 2% H₂O₂ in 70% methanol. After rinsing, sections were treated with blocking buffer (BB) (10% fetal calf serum in tris buffered saline (TBS) + 1% triton X-100) for 30 min, and incubated overnight at 4°C and then for one hour at room temperature (RT) with primary antibody diluted in BB (Table 1). Sections were rinsed and incubated for one hour at room temperature with the corresponding secondary antibody diluted in BB (Table 1). After incubation, sections were rinsed with TBS + 1% triton (TBS-T) and incubated in avidin-peroxidase (P-0364, Dakopatts) (1:400 in BB) for one hour at RT. Finally, the peroxidase reaction product was visualized in 100 ml of TB (0.05 M Trizma base, pH 7.4) with 50 mg of 3'-diaminobenzidine (DAB) and 33µl of hydrogen peroxide. Negative controls were incubated without primary antibodies (data not shown). After washing, slides were mounted on gelatin-coated slides, air-dried, dehydrated in alcohol, cleared in xylene, and cover slipped with DPX.

Double immunolabeling

For double immunohistochemical labeling, free-floating parallel sections were rinsed in TBS, treated with BB for 30 min, and incubated overnight at 4°C and then for one hour at RT with the first primary antibody diluted in BB (Table 1). Sections were then rinsed and further incubated for one hour with the corresponding secondary antibody, linked to a cyanine fluorochrome. For the second immunostaining, sections were rinsed in TBS-T and incubated overnight at 4°C and then for 1 hour at RT in a second primary antibody obtained in different species. After rinsing, sections were incubated for 1 hour at RT with the corresponding secondary antibody linked to a fluorochrome or conjugated with biotin (Table 1). In the case of biotin-conjugated secondary antibodies, sections were then further incubated for 1 hour at RT in streptavidin-Cy2 or avidin-Cy3 (Table 1).

For the demonstration of microglia/macrophages, tomato lectin (TL) histochemistry was used. Briefly, sections were incubated in biotin-labeled tomato lectin (6µg/ml, Sigma, L0651) diluted in TBS-T overnight at 4°C and 1 hour RT. After rinsing with TBS-T, sections were incubated for 1 hour RT with streptavidin-Cy3 (Table 1). After the last incubation, sections were rinsed in TBS and TB, mounted on gelatin-coated slides, air-dried,

counterstained with DAPI (Sigma, D9542) and coverslipped with fluorescent mounting media (Dakopatts). Sections processed for double immunofluorescence were first analyzed using a Nikon Eclipse E-600 and next, using a LEICA-TCS-SP2 confocal microscope in order to perform an exhaustive double labeling study.

Cell density quantification

MPO labeled sections from NMDA-injected animals were analyzed using a Nikon Eclipse E 600 microscope interfaced to a DXM 1200 camera (Nikon) and a PC. Pictures of representative areas were taken at different magnifications using the software ACT-1 2.20 (Nikon Corporation). A minimum of 4 NMDA-injected animals for each survival time and age group were analyzed. For each animal, 4 selected sections ranging from 1mm to -0.3mm from bregma and containing the lesion core were analyzed (Fig. 1). Anatomical landmarks (size and position of the anterior commissures, corpus callosum, septum, lateral ventricles, striatum, and nucleus accumbens) were used to ensure that parameters were analyzed at similar levels within and between groups. For MPO+ cell density quantification, the striatum was delimited in each section by the lateral ventricle medially, the corpus callosum dorsally and laterally, and by a line drawn between the two anterior commissures ventrally. In each section, 4 pictures of the striatum were taken at 10x (covering an area of 0.6 mm² each) and only MPO positive profiles clearly identified as specifically labeled cell somas were counted. The obtained number of profiles per section was corrected using the Abercrombie method to adjust for potential biases in counting methodology [27, 28]. Results are expressed as MPO+ cells/mm². For the quantification of double immunolabeled cells, 15-20 pictures covering the whole striatal area were taken at 40x (area of 0.037 mm²) in each section. Only profiles clearly identified as specifically double labeled cell somas were counted.

Statistical analysis

Statistical analysis was performed using StatView 4.5. One-way ANOVA and Fisher post-hoc comparisons were used. All results are presented as mean values \pm S.E.M. and $p \leq 0.05$ was considered significant.

RESULTS

In both age groups rats, injection of saline solution induced slight tissue disruption in the striatum, restricted to the needle track up to 3 days post-injection. However, intrastriatal injection of NMDA produced tissue degeneration involving neuronal loss mainly in the striatum (caudate–putamen) but also in the frontal cortex and the corpus callosum (Fig. 1), as previously described in detail [23].

The aged injured striatum showed decreased density of MPO+ cells

In intact control animals of both ages, no MPO expression was observed in the cortex or striatum. Similarly, no MPO+ cells were detected in the contralateral non-lesioned hemispheres of lesioned animals of both ages. Saline-injected control aged and adult animals showed scattered MPO+ cells in the mechanically injured cortex and in the striatal tissue surrounding the needle track (data not shown).

Following intrastriatal NMDA injection, animals of both ages showed slight MPO immunoreactivity in the cortex (similar to that observed in saline-injected animals, data not shown), although most MPO+ cells were seen in the damaged striatum, mainly in the lesion core but also in its periphery at both ages (Fig.2B-G). From 1dpl, MPO+ cells were often observed around blood vessels of the injured striatal zone. Quantitative analysis by cell counting showed that in both age groups, peak values of MPO+ cell density were observed at 12 hpl (Fig.2A). However, the density of MPO+ cells at this survival time was 24.32% lower in the aged versus the adult injured striatum; at 1dpl and 3dpl, the aged injured striatum showed a further 36.76% and 50.14% reduction, respectively. By 5 dpl a 25.40% reduction was still seen in the aged versus the adult injured striatum, whereas at 7 dpl the number of MPO+ cells had decreased and there were no significant differences between ages. No MPO labeling was observed at 14 dpl at any age (data not shown).

MPO is expressed in neutrophils but is also present in neurons and microglia/macrophages

Analysis of MPO immunostaining showed that, whereas many MPO+ cells displayed typical polymorphonuclear morphology and MPO+ vesicular cytoplasmic structures (Fig. 4 and the bottom of this section), significant numbers of MPO+ cells lacking neutrophil morphology were also observed.

Double immunohistochemical analysis of MPO and several glial and neuronal specific markers demonstrated that, in lesioned animals of both ages, MPO was also found in some NeuN+ neurons and TL+ microglia/macrophages showing amoeboid morphology in the injured striatum (Fig. 3), however, MPO expression was never found in (GFAP)+ astrocytes or ED2+ perivascular macrophages (data not shown). Quantitative analysis showed that MPO expression in NeuN+ neurons followed a similar temporal pattern compared to that of overall MPO labelling, peaking at 12 hpl at both ages (Fig. 3A). Similarly, the overall

density of neuronal cells expressing MPO was decreased in the aged injured striatum when compared to the adult. However, as total MPO+ cells were decreased in the aged, at 12 hpl, when peak density of MPO+ cells occurred, MPO+/NeuN+ represented a 25.60% of total MPO cells in the adult, while they were 26.19% of all MPO+ cells in the aged injured striatum. At 1 and 3dpl, the percentage of MPO+/NeuN+ decreased, representing a 14.16% and 7.75% in the aged, and 18.18% and 18.50% of total MPO+ cells in the adult. At 5 dpl, MPO+/NeuN+ cells represented the 22.22% of MPO cells in the adult, whereas no labelling of MPO/NeuN+ cells was detected in the aged injured striatum. At 7 dpl neither adult nor aged injured striatum showed double MPO+/NeuN+ cells.

MPO expression in TL+ microglia/macrophages, showed peak values at 12 hpl in the aged injured striatum, and then progressively decreased until 7 dpl, when MPO+/TL+ microglia/macrophages were still observed at both ages (Fig 3B). In contrast, in the adult, maximum density of MPO+ microglia/macrophages was not observed until 3 dpl, the only time point when the density of TL+/MPO+ cells was significantly higher than in the aged. Notably, the proportion of MPO+ cells identified as microglia/macrophages showed important age-related differences and was generally increased in the aged. At 12 hpl and 1 dpl, whereas in the adult injured striatum 21.94% and 25%, respectively, of MPO+ cells were identified as microglia/macrophages, this population accounted for the 30.95% and the 35.71% of total MPO+ cells in the aged. Notably, from 3 dpl, microglia/macrophages were the main population expressing MPO, representing 55.51% and 55.55% of total MPO+ cells in the adult injured striatum at days 3 and 5 respectively, and the 61.53% and the 85.74% in the same survival times in the aged.

Quantification of MPO+ cells with polymorphonuclear morphology and cytoplasmatic MPO labeling lacking NeuN and TL labeling (Fig. 4) showed that neutrophil cell density followed a similar temporal pattern than total MPO+ cells, showing maximum neutrophil presence at 12 hpl at both ages (Fig. 3A) and decreasing thereafter. In comparison to the adult brain, the aged striatum showed a significant neutrophil reduction of 38.16% at 12 hpl, 44.21% at 1 dpl, a 41.05% seen at 3 dpl and 52.11% at 5 dpl. Data analysis showed that at 12 hpl, when peak density of total MPO+ cells and MPO+ neutrophils occurred, MPO+ neutrophils represented a 52.44% of total MPO cells in the adult, while they were 42.85% of all MPO+ cells in the aged injured striatum. This percentage increased at 1 dpl for both ages, when MPO+ neutrophils represented a 56.81% of total MPO cells in the adult, and 50.11% in the aged injured striatum, decreasing at later time points (25.97% vs 30.70% of total MPO+ cells at 3 dpl and 22.22% vs 14.28% at 5 dpl).

DISCUSSION

In this study we describe important age-differences in the rapid MPO+ cell accumulation that takes place throughout the striatum after excitotoxicity. Notably, MPO+ cell density was decreased in the aged injured striatum when compared to the adult. Although most MPO+ cells showed typical morphology of neutrophils (especially at 12 hpl and 1 dpl), we also identified MPO+ cells showing neuronal or reactive microglia/macrophage markers. At both ages, neuronal MPO expression in injured striatum showed peak values at 12 hpl. In contrast, the maximal density of MPO+ reactive microglia/macrophages was found at earlier times in the aged striatum.

Aged-induced changes in neutrophil density

The tightly regulated and restrictive permeability to cells and molecules is the most important feature of the BBB [12, 22], including control of leukocyte trafficking to the healthy CNS [29]. In the normal aged brain, BBB morphology is modified and permeability is altered as compared to the adult brain [30-32]. Aging-associated BBB modifications are due, at least in part, to a significant age-dependent reduction in the number of laminin-positive [20] and collagen-type-IV-containing vessels [33], and reduced capillary density [34]. In addition, in several pathological conditions of the CNS, associated inflammation alters BBB morphology and function, inducing adherence of leukocytes to the vasculature, and penetration into the CNS [11, 35, 36].

In the present study we show that following excitotoxic damage to the adult and aged rat striatum, peak values of infiltrated neutrophils are seen at 12 hpl in both ages. However, MPO+ neutrophils are significantly reduced in the aged injured striatum at all survival times, in agreement with a previous study reporting diminished neutrophil infiltration in aged rats after intracerebral hemorrhage [37]. Reduced presence of MPO+ neutrophils at sites of neuroinflammation in the aged may be attributed to several factors: A first explanation could be an age decrease in circulating neutrophils [38]; however, it has been shown that the number of bone marrow precursor cells remain unaltered in human aging, and the number of circulating polymorphonuclear cells has been claimed to be either significantly increased in the elderly [39], or remain unchanged with age [40, 41]. Secondly, changes may be attributed to an impairment of neutrophil recruitment in the elderly, but literature is again contradictory: whereas Biasi and colleagues reported no differences in migration between elderly and young neutrophils in vivo [42], and Esparza et al. found that the migratory response of PMN is also not affected by age [43]; other groups have reported reduced chemotaxis with increasing age [37, 44, 45]. Thirdly, age-induced reduction in CNS neutrophil presence could also be attributed to a compromised function by an accelerated entry into apoptosis at the site of injury [46] as it is known that neutrophils have a short lifespan and die by apoptosis few hours after activation [47-49]. In this sense, although there are few studies analyzing

neutrophil apoptosis in the elderly, they have shown that the susceptibility of unstimulated PMNs to apoptosis is slightly increased in aging, which has been related to the fact that aged neutrophils show a diminished capacity to be rescued by anti-apoptotic mediators [50, 51]. Finally, age-related changes in lymphocyte function might also further compromise efficiency of neutrophils, reducing their phagocytic capacity, superoxide generation and/or degranulation [52].

Besides the age-related reduction in the number of infiltrated neutrophils, which is reported here, important factors determining the extent of tissue injury include neutrophil capacity for the production of inflammatory mediators, which may also change in aging. In addition to MPO, infiltrated neutrophils express other proinflammatory enzymes like cyclooxygenase-2 (COX2) and inducible nitric oxide synthase (iNOS) which have been implicated in delayed neuronal death by increasing oxidative stress [53-55]. Interestingly, we have previously reported, after striatal excitotoxicity, maximum number of MPO+ neutrophils expressing COX2 at 1 dpl at both ages; although adult animals showed double the density of MPO/COX-2+ neutrophils than aged rats. In addition, we also described a maximum number of MPO+ neutrophils expressing iNOS at 1 dpl in adult injured striatum while in aged rats the maximum value was seen at 12 hpl [24]. In this sense, It has been suggested that early endogenous NO production exerts a neuroprotective effect reducing neutrophil infiltration after brain damage [56]. As such, the reduced number of neutrophils and their earlier expression of iNOS in the injured aged striatum could be implicated, among other factors, in the delayed expansion of tissue injury and the later onset of neurodegeneration previously described in the excitotoxically damaged aged striatum [23].

Another factor determining the extension of neuronal damage after acute injury in the aged brain is BBB disruption and edema formation that potentiate lesion extension [57]. In this regard, we have previously shown that edema formation is delayed after striatal excitotoxicity in the aged rat brain [23], which may possibly be related to a reduction in BBB permeability [58], and is certainly related to the reduced neutrophil infiltration reported in this study. Neutrophils have been implicated in the generation of vasogenic cerebral edema and may play a role in BBB breakdown [59]. Therefore, in addition to being influenced by edema, the reduced neutrophil infiltration in the aged injured brain could in turn, contribute to the reduced edema observed in the aged brains at 1 dpl [23].

MPO expression in microglia/macrophages and neurons

MPO expression has been described in circulating neutrophils and monocytes [9, 60] as well as in tissue infiltrated neutrophils and monocytes at early times post-lesion, and in macrophages at later times [15, 61-63], as we also report here. This delayed presence of MPO in macrophages may be in part attributed to the engulfment of other MPO expressing cells by reactive microglia/macrophages. Notably, the higher density of

MPO microglia/macrophages we report in the adult injured striatum at 3 dpl coincides with an earlier neuronal cell death and a higher phagocytic capacity of microglia/macrophages after adult lesions, observations suggested by our previous research [23, 24].

In addition, MPO expression was also seen in injured neurons at early time points, as previously reported in neuronal cultures and in studies of patients with Alzheimer disease [64], where MPO expression was found both at the mRNA and protein levels, and was associated with aging-associated increase in neuronal oxidative stress. This data together with our results suggest that neuronal MPO expression may contribute to increased oxidative stress in progressive neurodegenerative diseases as well as after acute injuries [65, 66].

In conclusion, this work points to reduced neutrophil infiltration in the aged striatum as another factor involved in the age-differences in the response to striatal excitotoxic injury. Notably, the presence of MPO in neurons and microglia/macrophages should not be underestimated and further research to elucidate its role in injured aged brain is promising. All these results highlight the importance of using aged animals for experimental models of brain lesions associated to the elderly.

ACKNOWLEDGEMENTS

This work was supported by BFU2008-04407 (Ministry of Science and Innovation), Marató TV3 Foundation 061710 and 2005SGR-00956 (AGAUR) and Fundación Alicia Koplowitz. The authors thank Miguel A. Martil for his outstanding technical help.

REFERENCES

- [1] Jin R, Yang G, Li G. Inflammatory mechanisms in ischemic stroke: role of inflammatory cells. *J Leukoc Biol* 2010.
- [2] Mancuso C, Scapagini G, Curro D, Giuffrida Stella AM, De Marco C, Butterfield DA, Calabrese V. Mitochondrial dysfunction, free radical generation and cellular stress response in neurodegenerative disorders. *Front Biosci* 2007;12:1107.
- [3] McColl BW, Rothwell NJ, Allan SM. Systemic inflammatory stimulus potentiates the acute phase and CXC chemokine responses to experimental stroke and exacerbates brain damage via interleukin-1- and neutrophil-dependent mechanisms. *J Neurosci* 2007;27:4403.
- [4] Justicia C, Panes J, Sole S, Cervera A, Deulofeu R, Chamorro A, Planas AM. Neutrophil infiltration increases matrix metalloproteinase-9 in the ischemic brain after occlusion/reperfusion of the middle cerebral artery in rats. *J Cereb Blood Flow Metab* 2003;23:1430.
- [5] Wang Q, Tang XN, Yenari MA. The inflammatory response in stroke. *J Neuroimmunol* 2007;184:53.
- [6] Man S, Ubogu EE, Ransohoff RM. Inflammatory cell migration into the central nervous system: a few new twists on an old tale. *Brain Pathol* 2007;17:243.
- [7] Pardridge WM. Blood-brain barrier delivery. *Drug Discov Today* 2007;12:54.
- [8] Chen LP, Xu HM, Zhao W, Zhang SH, Zhu ZY, Zhang Q, Yu GL, Chu SL, Wei EQ. [Photomicrography of brain surface for evaluating blood-brain barrier disruption within 24 h after focal cerebral ischemia in mice]. *Zhejiang Da Xue Xue Bao Yi Xue Ban* 2005;34:523.
- [9] Dale DC, Boxer L, Liles WC. The phagocytes: neutrophils and monocytes. *Blood* 2008;112:935.
- [10] Weston RM, Jones NM, Jarrott B, Callaway JK. Inflammatory cell infiltration after endothelin-1-induced cerebral ischemia: histochemical and myeloperoxidase correlation with temporal changes in brain injury. *J Cereb Blood Flow Metab* 2007;27:100.
- [11] Pun PB, Lu J, Mochhala S. Involvement of ROS in BBB dysfunction. *Free Radic Res* 2009;43:348.
- [12] Abbott NJ, Patabendige AA, Dolman DE, Yusof SR, Begley DJ. Structure and function of the blood-brain barrier. *Neurobiol Dis* 2010;37:13.
- [13] Rausch PG, Pryzwansky KB, Spitznagel JK. Immunocytochemical identification of azurophilic and specific granule markers in the giant granules of Chediak-Higashi neutrophils. *N Engl J Med* 1978;298:693.
- [14] Klebanoff SJ. Myeloperoxidase: friend and foe. *J Leukoc Biol* 2005;77:598.
- [15] Breckwoldt MO, Chen JW, Stangenberg L, Aikawa E, Rodriguez E, Qiu S, Moskowitz MA, Weissleder R. Tracking the inflammatory response in stroke in vivo by sensing the enzyme myeloperoxidase. *Proc Natl Acad Sci U S A* 2008;105:18584.
- [16] Popa-Wagner A, Carmichael ST, Kokaia Z, Kessler C, Walker LC. The response of the aged brain to stroke: too much, too soon? *Curr Neurovasc Res* 2007;4:216.
- [17] Rutten BP, Schmitz C, Gerlach OH, Oyen HM, de Mesquita EB, Steinbusch HW, Korr H. The aging brain: accumulation of DNA damage or neuron loss? *Neurobiol Aging* 2007;28:91.
- [18] Hayflick L. The future of ageing. *Nature* 2000;408:267.
- [19] Peinado MA, del Moral ML, Esteban FJ, Martinez-Lara E, Siles E, Jimenez A, Hernandez-Cobo R, Blanco S, Rodrigo J, Pedrosa JA. [Aging and neurodegeneration: molecular and cellular bases]. *Rev Neurol* 2000;31:1054.

- [20] Campbell SJ, Carare-Nnadi RO, Losey PH, Anthony DC. Loss of the atypical inflammatory response in juvenile and aged rats. *Neuropathol Appl Neurobiol* 2007;33:108.
- [21] Popescu BO, Toescu EC, Popescu LM, Bajenaru O, Muresanu DF, Schultzberg M, Bogdanovic N. Blood-brain barrier alterations in ageing and dementia. *J Neurol Sci* 2009;283:99.
- [22] Farrall AJ, Wardlaw JM. Blood-brain barrier: ageing and microvascular disease--systematic review and meta-analysis. *Neurobiol Aging* 2009;30:337.
- [23] Castillo-Ruiz MM, Campuzano O, Acarin L, Castellano B, Gonzalez B. Delayed neurodegeneration and early astrogliosis after excitotoxicity to the aged brain. *Exp Gerontol* 2007;42:343.
- [24] Campuzano O, Castillo-Ruiz MM, Acarin L, Castellano B, Gonzalez B. Distinct pattern of microglial response, cyclooxygenase-2, and inducible nitric oxide synthase expression in the aged rat brain after excitotoxic damage. *J Neurosci Res* 2008;86:3170.
- [25] Campuzano O, Castillo-Ruiz MM, Acarin L, Castellano B, Gonzalez B. Increased levels of proinflammatory cytokines in the aged rat brain attenuate injury-induced cytokine response after excitotoxic damage. *J Neurosci Res* 2009.
- [26] Paxinos G, Watson C. *The rat brain in stereotaxic coordinates*. Second edition. 1986.
- [27] Abercrombie M. Estimation of nuclear population from microtome sections. *Anat Rec* 1946;94:239.
- [28] Guillery RW. On counting and counting errors. *J Comp Neurol* 2002;447:1.
- [29] Hickey WF. Leukocyte traffic in the central nervous system: the participants and their roles. *Semin Immunol* 1999;11:125.
- [30] Mooradian AD. Blood-brain barrier transport of choline is reduced in the aged rat. *Brain Res* 1988;440:328.
- [31] Mooradian AD. Effect of aging on the blood-brain barrier. *Neurobiol Aging* 1988;9:31.
- [32] Shah GN, Mooradian AD. Age-related changes in the blood-brain barrier. *Exp Gerontol* 1997;32:501.
- [33] Uspenskaia O, Liebetrau M, Herms J, Danek A, Hamann GF. Aging is associated with increased collagen type IV accumulation in the basal lamina of human cerebral microvessels. *BMC Neurosci* 2004;5:37.
- [34] Farkas E, Luiten PG. Cerebral microvascular pathology in aging and Alzheimer's disease. *Prog Neurobiol* 2001;64:575.
- [35] Turowski P, Adamson P, Greenwood J. Pharmacological targeting of ICAM-1 signaling in brain endothelial cells: potential for treating neuroinflammation. *Cell Mol Neurobiol* 2005;25:153.
- [36] Joice SL, Mydeen F, Couraud PO, Weksler BB, Romero IA, Fraser PA, Easton AS. Modulation of blood-brain barrier permeability by neutrophils: in vitro and in vivo studies. *Brain Res* 2009;1298:13.
- [37] Gong Y, Xi G, Wan S, Gu Y, Keep RF, Hua Y. Effects of aging on complement activation and neutrophil infiltration after intracerebral hemorrhage. *Acta Neurochir Suppl* 2008;105:67.
- [38] Schroder AK, Rink L. Neutrophil immunity of the elderly. *Mech Ageing Dev* 2003;124:419.
- [39] Cakman I, Kirchner H, Rink L. Zinc supplementation reconstitutes the production of interferon-alpha by leukocytes from elderly persons. *J Interferon Cytokine Res* 1997;17:469.
- [40] Chatta GS, Andrews RG, Rodger E, Schrag M, Hammond WP, Dale DC. Hematopoietic progenitors and aging: alterations in granulocytic precursors and responsiveness to recombinant human G-CSF, GM-CSF, and IL-3. *J Gerontol* 1993;48:M207.
- [41] Born J, Uthgenannt D, Dodt C, Nunninghoff D, Ringvolt E, Wagner T, Fehm HL. Cytokine production and lymphocyte subpopulations in aged humans. An assessment during nocturnal sleep. *Mech Ageing Dev* 1995;84:113.

- [42] Biasi D, Carletto A, Dell'Agnola C, Caramaschi P, Montesanti F, Zavateri G, Zeminian S, Bellavite P, Bambara LM. Neutrophil migration, oxidative metabolism, and adhesion in elderly and young subjects. *Inflammation* 1996;20:673.
- [43] Esparza B, Sanchez H, Ruiz M, Barranquero M, Sabino E, Merino F. Neutrophil function in elderly persons assessed by flow cytometry. *Immunol Invest* 1996;25:185.
- [44] Niwa Y, Kasama T, Miyachi Y, Kanoh T. Neutrophil chemotaxis, phagocytosis and parameters of reactive oxygen species in human aging: cross-sectional and longitudinal studies. *Life Sci* 1989;44:1655.
- [45] Wenisch C, Patruta S, Daxbock F, Krause R, Horl W. Effect of age on human neutrophil function. *J Leukoc Biol* 2000;67:40.
- [46] Koedel U, Frankenberg T, Kirschnek S, Obermaier B, Hacker H, Paul R, Hacker G. Apoptosis is essential for neutrophil functional shutdown and determines tissue damage in experimental pneumococcal meningitis. *PLoS Pathog* 2009;5:e1000461.
- [47] Savill JS, Wyllie AH, Henson JE, Walport MJ, Henson PM, Haslett C. Macrophage phagocytosis of aging neutrophils in inflammation. Programmed cell death in the neutrophil leads to its recognition by macrophages. *J Clin Invest* 1989;83:865.
- [48] Savill J. Apoptosis in resolution of inflammation. *J Leukoc Biol* 1997;61:375.
- [49] Arruda MA, Barja-Fidalgo C. NADPH oxidase activity: In the crossroad of neutrophil life and death. *Front Biosci* 2009;14:4546.
- [50] Fulop T, Jr., Fouquet C, Allaire P, Perrin N, Lacombe G, Stankova J, Rola-Pleszczynski M, Gagne D, Wagner JR, Khalil A, Dupuis G. Changes in apoptosis of human polymorphonuclear granulocytes with aging. *Mech Ageing Dev* 1997;96:15.
- [51] Tortorella C, Piazzolla G, Spaccavento F, Pece S, Jirillo E, Antonaci S. Spontaneous and Fas-induced apoptotic cell death in aged neutrophils. *J Clin Immunol* 1998;18:321.
- [52] Lord JM, Butcher S, Killampali V, Lascelles D, Salmon M. Neutrophil ageing and immunosenescence. *Mech Ageing Dev* 2001;122:1521.
- [53] Gong C, Hoff JT, Keep RF. Acute inflammatory reaction following experimental intracerebral hemorrhage in rat. *Brain Res* 2000;871:57.
- [54] Lerouet D, Beray-Berthet V, Palmier B, Plotkine M, Margail I. Changes in oxidative stress, iNOS activity and neutrophil infiltration in severe transient focal cerebral ischemia in rats. *Brain Res* 2002;958:166.
- [55] Beck J, Stummer W, Lehmborg J, Baethmann A, Uhl E. Activation of leukocyte-endothelial interactions and reduction of selective neuronal death after global cerebral ischemia. *Neurosci Lett* 2007;414:159.
- [56] Bateur-Parmentier S, Margail I, Plotkine M. Modulation by nitric oxide of cerebral neutrophil accumulation after transient focal ischemia in rats. *J Cereb Blood Flow Metab* 2000;20:812.
- [57] DiNapoli VA, Huber JD, Houser K, Li X, Rosen CL. Early disruptions of the blood-brain barrier may contribute to exacerbated neuronal damage and prolonged functional recovery following stroke in aged rats. *Neurobiol Aging* 2008;29:753.
- [58] Kawai N, Kawanishi M, Okauchi M, Nagao S. Effects of hypothermia on thrombin-induced brain edema formation. *Brain Res* 2001;895:50.
- [59] Plateel M, Teissier E, Cecchelli R. Hypoxia dramatically increases the nonspecific transport of blood-borne proteins to the brain. *J Neurochem* 1997;68:874.
- [60] Nauseef WM. Myeloperoxidase deficiency. *Hematol Oncol Clin North Am* 1988;2:135.

- [61] Daugherty A, Dunn JL, Rateri DL, Heinecke JW. Myeloperoxidase, a catalyst for lipoprotein oxidation, is expressed in human atherosclerotic lesions. *J Clin Invest* 1994;94:437.
- [62] Nagra RM, Becher B, Tourtellotte WW, Antel JP, Gold D, Paladino T, Smith RA, Nelson JR, Reynolds WF. Immunohistochemical and genetic evidence of myeloperoxidase involvement in multiple sclerosis. *J Neuroimmunol* 1997;78:97.
- [63] Sugiyama S, Okada Y, Sukhova GK, Virmani R, Heinecke JW, Libby P. Macrophage myeloperoxidase regulation by granulocyte macrophage colony-stimulating factor in human atherosclerosis and implications in acute coronary syndromes. *Am J Pathol* 2001;158:879.
- [64] Reynolds WF, Hiltunen M, Pirskanen M, Mannermaa A, Helisalmi S, Lehtovirta M, Alafuzoff I, Soininen H. MPO and APOEepsilon4 polymorphisms interact to increase risk for AD in Finnish males. *Neurology* 2000;55:1284.
- [65] Green PS, Mendez AJ, Jacob JS, Crowley JR, Growdon W, Hyman BT, Heinecke JW. Neuronal expression of myeloperoxidase is increased in Alzheimer's disease. *J Neurochem* 2004;90:724.
- [66] Reynolds WF, Rhees J, Maciejewski D, Paladino T, Sieburg H, Maki RA, Masliah E. Myeloperoxidase polymorphism is associated with gender specific risk for Alzheimer's disease. *Exp Neurol* 1999;155:31.

FIGURE LEGENDS

FIGURE 1.- Toluidine blue stained coronal sections of excitotoxically damaged adult and aged brains. Representative micrographs showing the striatal injured area (surrounded by a line) in the adult (A-C) and the aged (D-F) at different post-lesion survival times. Representative micrographs showing the area and the number of photographs performed at 10x for single MPO+ cell counts (G), and at 40x for double-stained cells (H). Scale bars = 2mm.

FIGURE 2.- Temporal pattern of MPO+ cell expression (A) both in the adult (white columns) and aged (black columns) animals. The analysis of MPO+ cell density shows peak values at 12 hpl at both ages but significantly lower values in aged animals at all survival times except at 7 dpl . Data are presented as mean \pm s.e.m. Asterisks (*) show statistically significant differences between ages at the specific time-point ($p < 0.05$) while pluses (+) shows statistically significant maximum values within each age group ($p < 0.05$). Representative micrographs (B-G) show MPO+ cells both in the adult (B-D) and the aged (E-G) at different survival times. At 12hpl cells were scattered all over the injured striatum, while they were closer related to vessels later on. Scale bars = 30 μ m.

FIGURE 3.- Temporal pattern of MPO/NeuN (A) and MPO/TL (B) cell expression both in the adult (white columns) and aged (black columns) injured striatum. In A, the analysis of MPO/NeuN+ cell density shows significantly lower values in the aged striatum at all survival times and a significant peak in MPO/NeuN+ cell density at 12 hpl at both ages. In B, the analysis of MPO/TL+ cell density shows significantly lower values in the aged striatum only at 3 dpl and a significant peak in MPO/TL+ cell density at 12 hpl in the aged and at 3 dpl in the adult. Data are presented as means \pm s.e.m. Asterisks (*) show statistically significant differences between ages at the specific timepoint ($p < 0.05$), while pluses (+) show statistically significant maximum values within each age group ($p < 0.05$ (C-F) Representative confocal images of both ages showing double labeling for MPO+ cells and NeuN (C,D), and TL (E,F) at different survival times. Arrowheads show cytoplasmatic co-localization of MPO with NeuN and TL. Scale bars = 10 μ m.

FIGURE 4.- Temporal pattern of MPO expression in neutrophils (A) both in the adult (white columns) and aged (black columns) animals. The analysis of MPO+ neutrophil density shows labeling from 12 hpl to 5 dpl at both ages but significantly lower values in the aged striatum at all survival times. The peak of MPO+ neutrophil density occurs at 12 hpl at both ages. Data are presented as means \pm s.e.m. Asterisks (*) show statistically

significant differences between ages at the specific time-point ($p < 0.05$), while pluses (+) show statistically significant maximum values within each age group ($p < 0.05$). (B-D) Confocal images showing MPO+ neutrophils (B), nuclear morphology labeled with DAPI (C) and the merged image (D). (E) Representative image of typical neutrophil morphology labeled with DAB. Scale bars = $10\mu\text{m}$.

ACCEPTED MANUSCRIPT

Table 1.- Primary and secondary antibodies used for immunohistochemical labeling.

Primary Antibodies	Species	Dilution	Source	Code
Anti-ED2	Mouse	1:500	Serotec	MCA342R
Anti-Glial fibrillary acidic protein (GFAP)	Rabbit	1:1000	DAKO	Z0334
Anti-Myeloperoxidase (MPO)	Rabbit	1:400	DAKO	A0398
Anti-Neuronal Nuclear Antigen (NeuN)	Mouse	1:500	Chemicon	MAB377

Secondary Antibodies and Reagents	Dilution	Source	Code
Cy2-linked Goat anti-rabbit	1:750	Amersham	PA42004
Cy3-linked Goat anti-rabbit	1:1000	Amersham	PA43004
Biotinylated Donkey anti-rabbit	1:200	Amersham	RPN1004
Cy3-linked Goat anti-mouse	1:1000	Amersham	PA43002
Biotinylated Sheep anti-mouse	1:200	Amersham	RPN1001
Cy2-linked Avidin	1:750	Amersham	PA42000
Streptavidin-peroxidase	1:400	Vector	SA5004
Cy3-linked Streptavidin	1:1000	Amersham	PA43000

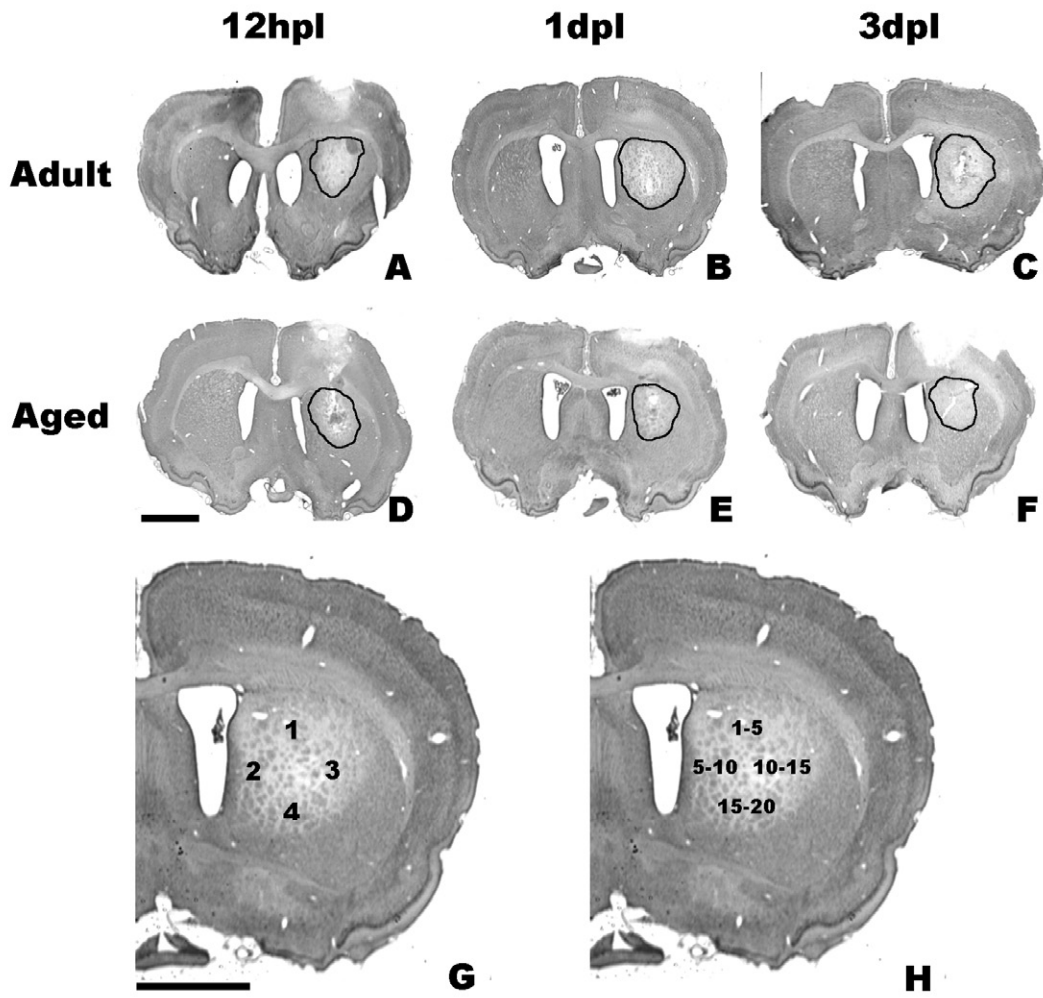


Figure 1

AC

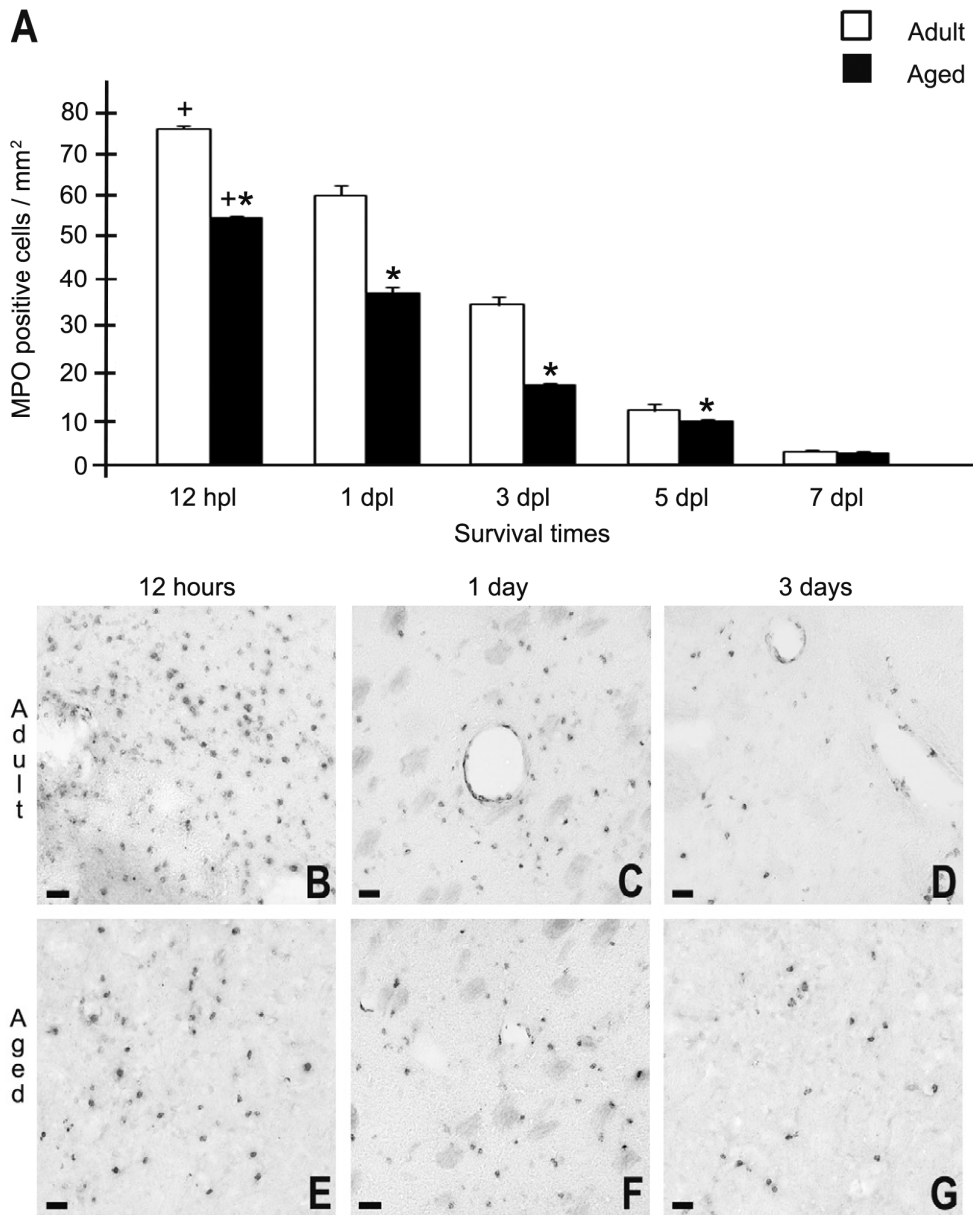


Figure 2

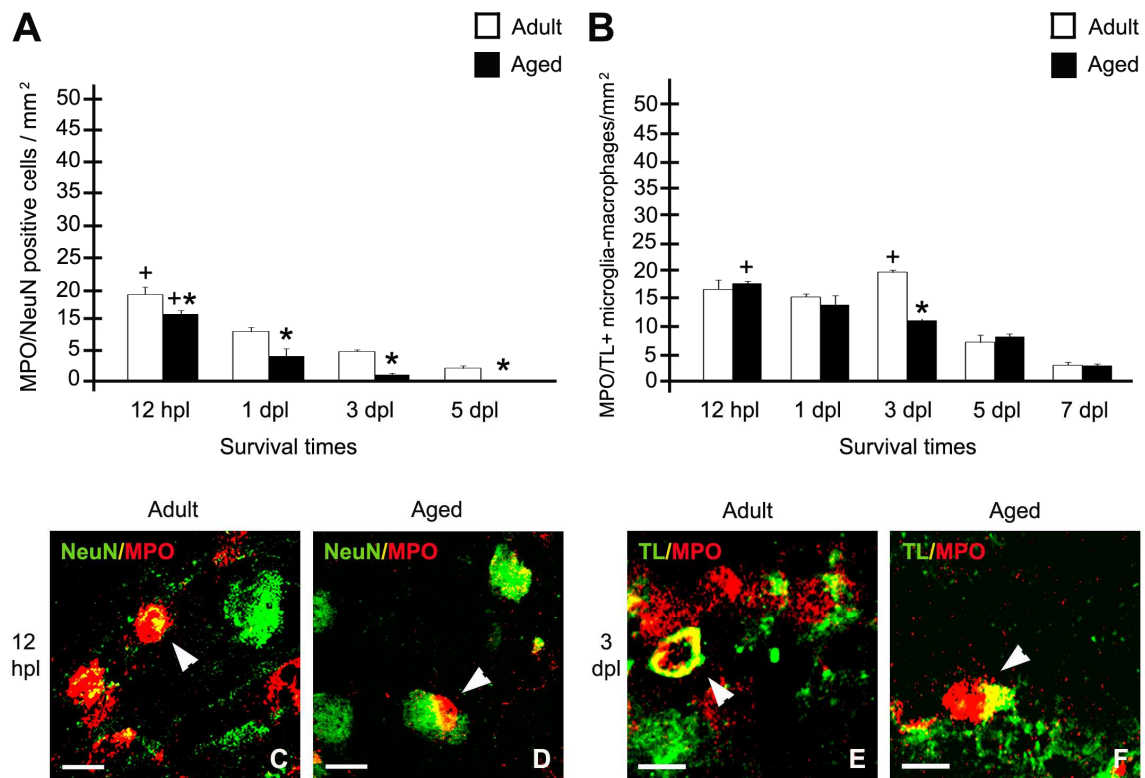


Figure 3

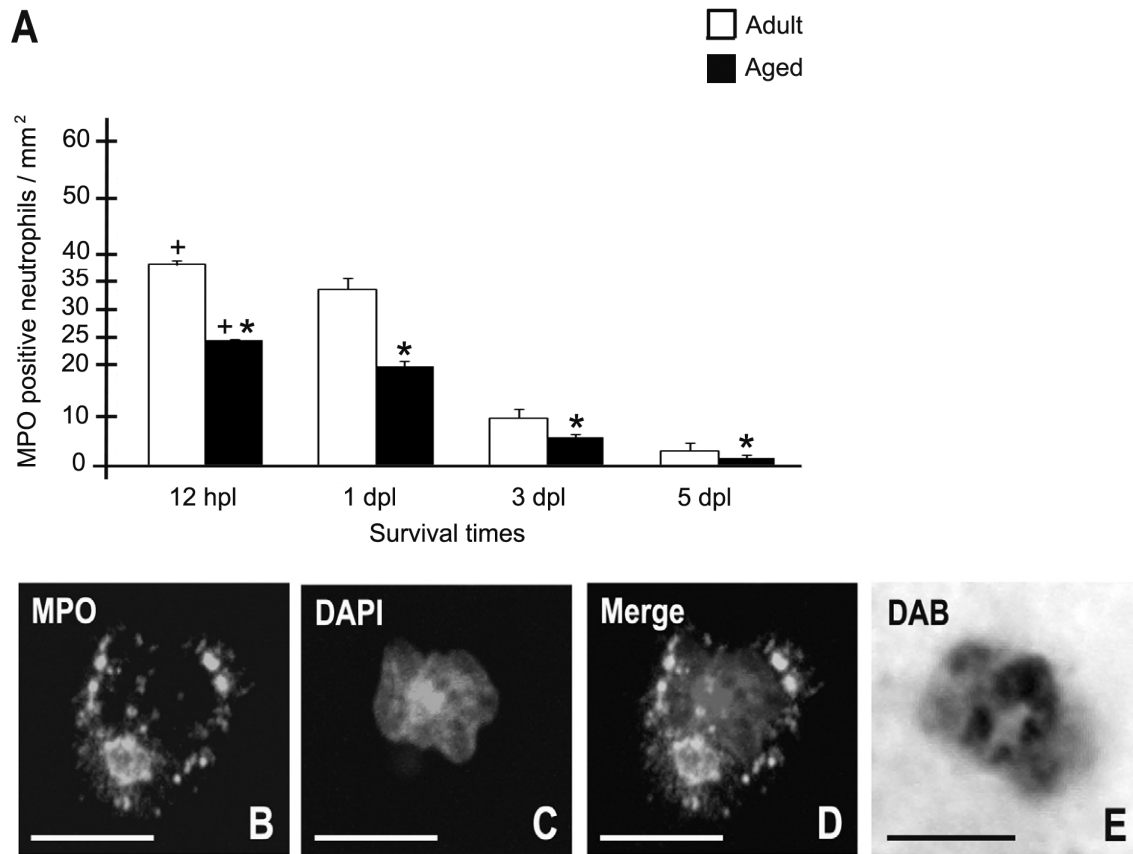


Figure 4

DECREASED MYELOPEROXIDASE EXPRESSING CELLS IN THE AGED RAT BRAIN AFTER
EXCITOTOXIC DAMAGE by Campuzano et al.

Research Highlights

- Density of myeloperoxidase-positive (MPO+) cells is reduced in the aged injured striatum
- MPO+ cells are mainly identified as neutrophils both in the aged and the adult
- MPO is used as a marker for neutrophils, but MPO+ neurons and microglia/macrophages are also seen
- Neutrophil infiltration is an important factor in the different response of the aged brain to damage
- The need of using aged animals for the study of acute age-related brain insults

ACCEPTED MANUSCRIPT