



HAL
open science

Investigations into an outbreak of corvid respiratory disease associated with *Pasteurella multocida*

Benjamin William Strugnell, Mark Dagleish, Colin Bayne, Mike Browne, Heather Ainsworth, Robin a J Nicholas, Alisdair Wood, Chris Hodgson

► To cite this version:

Benjamin William Strugnell, Mark Dagleish, Colin Bayne, Mike Browne, Heather Ainsworth, et al.. Investigations into an outbreak of corvid respiratory disease associated with *Pasteurella multocida*. Avian Pathology, 2011, 40 (03), pp.329-336. 10.1080/03079457.2011.571659 . hal-00710056

HAL Id: hal-00710056

<https://hal.science/hal-00710056>

Submitted on 20 Jun 2012

HAL is a multi-disciplinary open access archive for the deposit and dissemination of scientific research documents, whether they are published or not. The documents may come from teaching and research institutions in France or abroad, or from public or private research centers.

L'archive ouverte pluridisciplinaire **HAL**, est destinée au dépôt et à la diffusion de documents scientifiques de niveau recherche, publiés ou non, émanant des établissements d'enseignement et de recherche français ou étrangers, des laboratoires publics ou privés.



Investigations into an outbreak of corvid respiratory disease associated with *Pasteurella multocida*

Journal:	<i>Avian Pathology</i>
Manuscript ID:	CAVP-2010-0168.R2
Manuscript Type:	Original Research Paper
Date Submitted by the Author:	28-Jan-2011
Complete List of Authors:	Strugnell, Benjamin; Veterinary laboratories Agency, Thirsk Regional laboratory Dagleish, Mark; Moredun Research Institute, Pathology department Bayne, Colin; Moredun Research Institute, Pathology department Browne, Mike; British Trust for Ornithology Ainsworth, Heather; Veterinary Laboratories Agency, Bury St. Edmunds regional laboratory Nicholas, Robin; Veterinary Laboratories Agency, Statutory and Exotic Bacteria Wood, Alisdair; Veterinary Laboratories Agency, Lasswade Hodgson, Chris; Moredun Research Institute, Pathology department
Keywords:	corvid, pasteurella multocida, respiratory disease, UK

SCHOLARONE™
Manuscripts

Cavp-2010-0168.R2

Investigations into an outbreak of corvid respiratory disease associated with
Pasteurella multocida

¹Strugnell, B., ²Dagleish, M.P., ²Bayne, C.W., ³Browne, M., ⁴Ainsworth, H., ⁵Nicholas, R.A.J., ⁶Wood, A. and ²Hodgson, J.C.

¹VLA Thirsk, West House, Station Road, Thirsk, North Yorkshire YO7 1PZ. ²Moredun Research Institute, Pentlands Science Park, Bush Loan, Penicuik, Midlothian EH26 0PZ.

³British Trust for Ornithology (BTO), BTO Regional Representative for Yorkshire (Harrogate). ⁴VLA Bury St. Edmunds, Rougham Hill, Bury St. Edmunds, Suffolk IP33 2RX.

⁵Mycoplasma Group, VLA Weybridge, New Haw, Addlestone, Surrey KT15 3NB.

⁶VLA Lasswade, Pentlands Science Park, Bush Loan, Penicuik, Midlothian EH26 0PZ.

Short title: fowl cholera

Received: 28 January 2011

Author for correspondence: Ben Strugnell

email: b.strugnell@vla.defra.gsi.gov.uk

Tel: 018455 22065

Fax: 01845 525224

Abstract

The possible cause of disease and mortality in corvids on an outdoor pig unit in the north of England between August 2007 to March 2008 was investigated. Nine carrion crows (*Corvus corone corone*) and 9 rooks (*Corvus frugilegus*), comprising five live-caught birds with clinical signs of respiratory disease, one live-caught bird without respiratory disease, and 12 birds submitted dead were examined. Clinical signs, gross and histopathological examination, microbiology and toxicology indicated that *Pasteurella multocida* infection was the cause of disease. Molecular and serotyping analyses showed that *P. multocida* isolates (obtained from live-caught birds with clinical respiratory disease) were all capsular type F with a mix of somatic serotypes 3, 4 and 7. Immunohistochemistry (IHC) increased the diagnostic sensitivity of the analysis and detected *P. multocida* within the pulmonary lesions of all affected live-caught birds and 10 of 12 birds found dead. These findings suggest that wild corvids in the UK can suffer from lung pathology associated with *P. multocida* and, as potential vectors of *P. multocida*, may pose a risk to domestic poultry.

Introduction

The Gram-negative bacterium *Pasteurella multocida* comprises 5 capsule serogroups (A, B, D, E and F) and 16 somatic serotypes. Serogroup A is isolated most frequently in fowl cholera, a disease of major economic importance in commercially reared birds and outbreaks in England are associated primarily with somatic serotypes 1,3 and 3,4 (Rhoades & Rimler, 1990). Molecular typing has shown that wild birds, and possibly mammals, may be the source of infection in some disease outbreaks in commercial poultry (Christensen & Bisgaard, 2000). The species and age of affected birds, their environment and the strain of *P. multocida* involved influence the severity and incidence of disease and mortality varies from a few to 100 percent (Rimler & Glisson, 1997).

Corvids are intelligent, highly adaptable birds which have frequently capitalised on changes in agriculture and land use resulting in thriving populations, often in close proximity to farmed livestock and crops. Outdoor pig units are a particular niche to which corvids have become adapted (Marchant & Gregory, 1999). However, there is little information on the susceptibility of corvids to, or their ability to transmit, bacterial disease such as fowl cholera. The aim of this study was to investigate the aetiology of disease among corvids found either dead or displaying clinical signs of respiratory disease. Similar outbreaks of disease have been reported previously in the UK, sometimes referred to as corvid respiratory disease, without a definitive cause being determined (Pennycott 2005).

Materials & Methods

Background, case definition, inclusion criteria and clinical signs. In August 2007, the carcasses of seven rooks (*Corvus frugilegus*, birds 1-7) were submitted to the Veterinary Laboratories Agency (VLA) Thirsk regional laboratory for post-mortem examination under the UK Department of Environment, Food and Rural Affairs (Defra) Wildlife Incident Investigation Scheme (WIIS) and the VLA Diseases of Wildlife Scheme (VLADoWS). They represented an estimated 30 birds found dead in a 1.62 hectare wood comprised of deciduous trees, mainly ash, beech and oak, adjacent to a 1000-sow outdoor weaner producer pig unit near York, UK. Over the next six months, amid continuing mortality in this population of corvids, there were a further eight submissions (Table 1), comprising: three carrion crows (birds 9, 11 & 14) and two rooks (birds 8 & 12) caught live showing clinical signs of respiratory disease; one live carrion crow (with a humeral fracture) showing no clinical signs of respiratory disease (bird 15) and five carrion crows found dead (birds 10, 13, 16, 17 & 18). Live-caught birds were held in a large crow trap (for at most 8 hours) and were delivered alive to VLA Thirsk except bird 12 which died in the trap. Clinical signs included moderate to severe dyspnoea, a reduced ability or inability to fly, a snicking cough and weakness (Table 1). Disease was considered to have been progressive, culminating in birds that were either easy to catch or found dead.

Ornithological and natural history investigations. The site was visited on six occasions at regular intervals during the period from September 2007 until June 2008, in collaboration with the British Trust for Ornithology (BTO), to determine the feeding, roosting and other behaviours of corvids and other wild birds. Estimates of the sizes of corvid populations, population dynamics and interactions were performed subjectively by an experienced local ornithologist (M. Browne).

Gross post-mortem examination. Post-mortem examinations were performed on all 18 birds. Live birds were euthanased with an intravenous overdose of pentobarbitone (Euthatal, Merial Animal Health) via a brachial vein. Samples of lung from at least one bird from all submissions (except submission 6), and other tissues abnormal on gross examination (Table 1), were placed into 10% formal saline for histopathology. Where indicated (Table 1) samples for bacteriological, virological and toxicological examination were collected from each bird using aseptic (seared surface) techniques. Selection of tissues for bacteriology was on the basis of abnormal appearance as determined by the pathologist performing the post-mortem examination (BS) and samples plated out immediately (see below). A different range of tissues was therefore taken from each bird. Tissue samples for virological examination were stored at -80°C (maximum of 3 weeks) prior to investigation and those for toxicology stored at -80°C until required.

Microbiology. Each sample was concomitantly cultured on sheep blood agar (SBA, Oxoid, Basingstoke, UK), SBA with a 'nurse streak' of *Staphylococcus intermedius*, SBA cultured in 5% CO₂ or MacConkey's agar (Oxoid). Direct and enrichment cultures for *Salmonella* using brilliant green agar (Oxoid) and Selenite broth ((Oxoid) were performed on pooled large intestinal contents from the first four submissions (birds 1-7 in 2 pools; 8-11 individually). Fungal enrichment cultures were performed on all samples of lung and/or air sac which were selected for bacterial cultures using Sabourard's agar (SAB, Oxoid) alone or containing penicillin and streptomycin (SABA, Oxoid). Bacteria were identified using standard laboratory techniques. *P. multocida* was identified by characteristic smell and colonial morphology, Gram staining and microscopic appearance, lack of growth on MacConkey's agar, a positive indole reaction and a negative urease reaction (Blackall & Norskov-Lauritsen 2008; Dziva *et al* 2008). Samples of lung, airsac and/or sinus at the discretion of the

pathologist from all but the first seven birds (omitted due to autolysis) were placed in Friss pre-enrichment broth (Bradbury, 1998) and checked for *Mycoplasma* growth at 24 and 48hrs, then at weekly intervals for 4 weeks. Positive cultures were identified using denaturing gradient gel electrophoresis (McAuliffe *et al.*, 2005).

Bacterial DNA extraction. Isolated bacteria were cultured overnight in brain heart infusion (BHI) broth (Oxoid, UK) at 37°C and DNA extracted from 1ml of suspension using a DNeasy kit (Qiagen Ltd., Crawley, UK) according to manufacturer's instructions and quantified (NanoDrop Spectrophotometer, Nanodrop Products, Wilmington, USA). Samples were stored at -20°C until required.

Determination of capsule type, serotype and presence of virulence associated genes.

Isolates of *P. multocida* were analysed by PCR for the presence of species-specific sequence KMT1 (Townsend *et al.*, 1998), capsule biosynthesis genes *capA*, *B*, *D*, *E* & *F* (Townsend *et al.*, 2001) and the virulence associated genes *pfhA*, *hgbB* (Ewers *et al.*, 2006), *tbpA* (Ogunnariwo & Schryvers, 2001) and *toxA* (Lichtensteiger *et al.*, 1996), using amplification conditions and primer sequences described by these authors. Primers were tested against positive control isolates which had been typed by conventional methods to confirm capsule type. For all PCR reactions 50 ng of extracted DNA were taken as template and added to the reaction mixture (50 µl) containing 0.2 µM of each primer (Eurofins MWG Operon, Wolverhampton, UK), 0.2 mM of each of the four deoxynucleotide triphosphates (Invitrogen Ltd., Paisley, UK), 1 × PCR buffer, 1.5 mM MgCl₂ (except for *capA* PCR reactions which contained 2 mM MgCl₂) and 1 unit of Platinum Taq (Invitrogen). Samples were subjected to 35 cycles of amplification in a Lehne Thermocycler TC-3000 Techne Thermal cycler (Bibby Scientific Ltd., Staffordshire, UK). Amplified products were analysed

by electrophoresis in a 1.5% Tris acetate EDTA agarose gel, stained with Gel Red (Cambridge Biosciences, Cambridge, UK), visualised under UV transillumination and photographed. Serotypes of *P. multocida* isolates from birds 8, 9, 12 and 14 were determined by conventional methods by VLA, Lasswade, UK.

Virology. A real time PCR for the detection of the matrix gene of influenza A virus (Anon, 2006) was performed separately on two sample sets from the first 8 birds examined (birds 1-8, submissions 1 and 2) comprising pooled bulk viscera; brain, liver, spleen, lung, kidney, trachea and intestine. For birds 1-11 samples of brain and kidney were tested for West Nile virus (WNV) by reverse transcription-polymerase chain reaction employing specific primers directed at the C-terminal of the C gene and the N-terminal of the prM gene and via 20% (w/v) suspensions of the same samples of brain and kidney after two passages in Vero C1008 (ATCC) cells (Gough *et al.*, 1998; Phipps *et al.*, 2007). Scanning electron microscopy was performed on selected tissues from bird 8 (pooled bursa and spleen, and a pool of kidney and lung) to investigate the presence of other viruses. 3 mm Copper/Rhodium (100 µm mesh) support grids were used for the analyses. Each grid was pre-treated by immersing into 0.4% formvar in chloroform (w/v), followed by carbon coating, to provide a stable sample platform. Treatment was then completed, by subjecting each grid to plasma glow discharge, to ensure the grids were highly hydrophilic. Each sample analysed (approx. 0.25 cm³) was ground in 2 cm³ of 0.1 M Sorenson's phosphate buffer (pH 6.6), to form a suspension. An aliquot of each sample suspension (50 µl) was pipetted onto a piece of dental wax and a support grid was then placed copper side upwards onto the aliquot for 30 seconds and excess sample removed by wicking dry. Each grid was then placed as before onto a drop of 2% phosphotungstic acid (w/v) (pH 6.6), for 10 seconds to counter-stain the grid and again excess stain removed by wicking dry. Analysis of each sample was undertaken on a Phillips

CM10 microscope at $\times 34,000$ magnification, at 80 kV. Analysis time was standardised to 20 minutes viewing of the sample grid or assessment of 25 grid squares for the presence of virus particles, whichever was the shortest

Histopathology and Immunohistochemistry. Tissues for histopathology from 17 birds (Table 2) were processed routinely to wax blocks within 72 hours of collection. Sections (5 μm) were mounted on glass microscope slides and stained with haematoxylin and eosin or subjected to Gram's stain (ProLab Diagnostics, Neston, UK) for bacteria or Grocott Gomori methenamine silver (GGMS) for fungal hyphae.

Further sections, including duplicates for negative control preparations, were mounted on Superfrost™ slides (Menzel-Gläser, Braunschweig, Germany) and subjected to immunohistochemistry (IHC) with polyclonal antiserum raised in a rabbit against *P. multocida* A:3 as described previously (Dagleish *et al.*, 2010). A positive control sample consisting of a section of lung from a calf infected experimentally with *P. multocida* A:3 and containing typical lesions of suppurative broncho-pneumonia was included for comparison of the pattern of immunolabelling with that of *P. multocida* serotype F isolated from crows in this study. All slides were blind-coded and examined for morphological lesions and the presence and distribution of immunolabelling relative to histological lesions.

Toxicology. Screens for alpha chloralose and rodenticides were performed under the Wildlife Incident Investigation Scheme at the Central Science Laboratories, York, UK, using the methods described by Brown *et al* (2005), on pooled kidneys and livers respectively from birds 1, 3 & 4 (the least autolysed in submission 1).

Results

Ornithological investigations and observations. The corvid population at the site was estimated at 200-300 birds comprising 65% carrion crows, 25% rooks and 10% jackdaws (*Corvus monedula*). The nesting capacity of the wood could not accommodate this number of birds suggesting that a large proportion travelled daily some considerable distance to the farm. Approximately 60% of the birds found dead were in and around the wood, the remainder on grass pastures and nearby pig paddocks where it was common for large flocks of all 3 species to forage together.

Gross post-mortem findings. The commonest lesion, present in all 17 birds with lesions suggestive of infectious disease (Table 1), was fibrinous proliferation on at least one serosal surface (pericarditis, perihepatitis or airsacculitis). No gross lesions were present in the viscera of bird 15, live-caught due to a simple fracture of the left humerus with no clinical signs of respiratory disease. Airsacculitis (Figure 1) was present in 12 (70%) of the 17 affected birds. Necrotising pneumonia was seen in 3 (19%) of the 17 diseased birds, including bird 12 (Figure 2) which died awaiting collection. In most cases the gizzards were empty or contained little food and in 3 cases (birds 5, 8 and 14) ascarid worms were present. Ectoparasites (lice) were noted on live-caught birds 8, 9 and 11. Cestodes were a common finding in the small and large intestines (6 (66%) of 9 rooks; birds 2, 4, 5, 7, 8 and 12 and 3 (33%) of 9 carrion crows; birds 9, 14 and 11). The findings suggested a spectrum of disease from relatively acute (*e.g.* bird 17) to chronic (*e.g.* bird 13) pneumonia and polyserositis. No gross lesions suggestive of haemorrhagic meningitis, congestion of meningeal vessels or brain oedema were present in any of the birds examined.

Microbiological findings. *P. multocida* was isolated from at least one of either the lung, airsac, sinus, heart blood, liver or pericardium in all five affected live-caught birds (birds 8, 9, 11, 12 and 14) (Table 1). In bird 9 pure growths of *P. multocida* were recovered from the lung, air sac, liver and heart blood indicative of a septicaemic distribution. *Salmonella* spp. were not isolated from large intestinal contents from birds 1-11 using direct or enrichment culture techniques and no further *Salmonella* cultures were performed. *Escherichia coli*, *Proteus* spp. and other saprophytic bacteria were recovered only from birds found dead (Table 1). Fungal cultures were negative from all tissues examined.

Capsular type, virulence associated genes and serotype. Four *P. multocida* isolates (from birds 8, 9, 12 & 14) were available for further testing. All four demonstrated the presence of *capF* capsule gene only, the species specific gene sequence KMT1 and virulence associated genes haemoglobin binding protein (*hgbB*) and the filamentous haemagglutinin (*pfhA*). However, transferrin binding protein gene (*tbpA*) and dermonecrotxin gene *toxA* were not detected. Somatic serotypes were 4 (bird 8), 3,4,7 (bird 9) and 3 (bird 12). The isolate from bird 14 failed to type.

***Mycoplasma* enrichment cultures.** Four different *Mycoplasma* species (*M. gallopavonis*, *M. gallinarum*, *M. colomborale*, and *M. sturni*, Table 1) were identified. Neither *M. gallisepticum* nor *M. synoviae* were isolated from any sample.

Virology. All samples examined for WNV and High Pathogenicity Avian Influenza (HPAI) were negative and no other viruses were identified in the cell cultures performed to detect WNV. No virus particles were seen on electron microscopy where performed. Testing for

WNV ceased after the first 11 birds proved negative on the basis of a low risk during the winter months (little mosquito activity) and a lack of consistent gross and histopathological findings. The EU target species list for HPAI surveillance (Anon 2010a) does not feature corvids so this testing was also restricted to the first two submissions on the basis of low risk and likelihood. Furthermore, histopathological lesions did not suggest avian influenza.

Toxicological findings. Samples of kidney for alpha chloralose and liver for rodenticides were all negative. Further samples for toxicology were retained but not tested on the basis that the lesions were more typical of an infectious process.

Histopathology and Immunohistochemistry. Pneumonia and/or air sacculitis was the most consistent lesion in the birds found dead or live-caught with clinical signs of respiratory disease. The character of the pneumonia varied between granulocytic and fibrino-granulocytic both with and without areas of necrosis (Figure 3). Positive labelling for *P. multocida* was present in the lungs (Figures 4a & b) and/or air sacs of all but one of the affected birds examined by specific IHC (Table 2). Bird 17 did not have pneumonia or air sacculitis but a small focus of necrosis present in the lung was positive for *P. multocida* by IHC. Gram-negative coccobacillary bacterial colonies present extra-cellularly and also within the foamy cytoplasm of macrophages within the lungs and air sacs of some birds were positive for *P. multocida* by IHC. Bird 15 had a mild cholangiohepatitis. However, no significant lesions were found in the lung, brain or spleen and all tissues were devoid of immunolabelling in this bird. All negative control preparations were devoid of labelling. Nematode parasite profiles were present in the respiratory systems of three birds and a trematode in one (Table 2). No fungal hyphae or other fungal forms were present in any of

the tissues examined using special stains (GGMS) nor any structures suggestive of viral inclusions in the bursas or spleens that were available for examination.

Discussion

There are early reports of disease in wild corvids from the UK (Keymer, 1958; McDairmid, 1965) but detailed and recent descriptions are lacking. A syndrome of 'corvid respiratory disease' featuring varying degrees of fibrinous airsacculitis, perihepatitis, pericarditis and pneumonia has been reported (Pennycott, 2005) but most cases were submitted dead and no consistent aetiology was identified.

In this study *P. multocida* was isolated from the five corvids displaying clinical signs of respiratory disease which were submitted live. All had gross lesions in the respiratory tract. In all but two of the birds submitted dead, Gram-negative coccobacilli bacteria were associated intimately with the pulmonary histological lesions and showed positive labelling for *P. multocida* by IHC. No gross or histological pulmonary lesions, immunolabelling or isolation of *P. multocida* were observed in a live-submitted bird that did not have clinical signs of respiratory disease. Samples from further birds unaffected by respiratory disease was unfortunately not available. Taken together, these results suggest that *P. multocida* was the cause of the pathology.

It was unusual for *P. multocida* to type only as serogroup F, as avian isolates analysed by traditional methods are more usually reported as serogroup A (Christensen & Bisgaard, 2000). However, a comparison of PCR and conventional methods for typing avian isolates of *P. multocida*, including serogroup F, showed good agreement (Shivachandra *et al.*, 2006) and our findings may reflect the greater discrimination between serogroups possible with PCR,

highlighted in a study when a proportion of avian *P. multocida* isolates characterised previously by traditional methods as serogroup A were shown by PCR to belong to the closely related serogroup F (Townsend *et al.*, 2001).

The failure to isolate *P. multocida* from birds found dead was surprising as others have isolated it readily from carcasses of birds which have succumbed to fowl cholera (Glisson *et al* 2008; Dziva *et al.*, 2008). It may have been that the strain of *P. multocida* involved was sensitive to changes in temperature, pH and/or other factors as well as competition from other species of bacteria proliferating post-mortem, especially if bacterial loads were low in this chronic manifestation of disease (see below). Future studies of similar disease outbreaks may benefit from using PCR techniques in addition to bacterial culture to detect *P. multocida* within tissue samples although the technique does not allow the specific localisation within lesions obtainable with IHC.

Corvids have been reported as becoming infected with *P. multocida* after feeding on the carcasses of birds which have recently succumbed to fowl cholera and in these reports, the disease course in corvids is longer than in waterfowl. (Zinkl *et al.*, 1977; Taylor & Pence, 1981). This observation is consistent with our findings where sometimes progressive clinical signs were seen in affected corvids, and histopathological findings showed a chronic disease course. The feeding adaptability and ubiquity of scavenging birds such as corvids makes contact between them and domestic species likely and creates a risk of disease transmission from diseased or sub-clinically affected birds. There is experimental and epidemiological evidence to suggest that in some outbreaks of disease in domestic poultry wild birds were responsible for introducing infection (Snipes *et al.*, 1988, Petersen *et al.*, 2001), and risks may be increased if disease (and shedding) is chronic. Challenge studies using the *P. multocida* F isolates from corvids in this series would establish their potential pathogenicity to domestic poultry and therefore the risk infected corvids may pose. However, this work was

out-with the scope of this study. In the USA corvids are considered important in the epidemiology of WNV as they are highly susceptible, developing a substantial viraemia prior to death (Reisen *et al.*, 2006; (Murray *et al.*, 2010). In Western Europe reports of human fatalities due to encephalitis caused by this disease have been recently reported (Papa *et al.* 2010), and surveillance for this agent is important (Zoller *et al.* 2010). However, to date WNV has not been detected in the UK and all tests in this series were negative.

Although several of the birds were parasitised by lice, ascarid nematodes and cestodes, burdens were low and not considered out-with normal limits for wild birds. It is possible that the empty gizzards were a result of the respiratory disease rather than a cause of it. There was histological evidence of infestation with *Syngamus trachea* in one bird (bird 10, see table 2), diagnosed with caseous airsacculitis. Parasitic bronchitis may have predisposed to opportunistic bacterial infection (*E. coli*, not *P. multocida*, was isolated) in this bird. However, in general, parasitism was not considered a major factor in this disease outbreak. Of the *Mycoplasma* species isolated only *M. sturni* has been reported to be of pathological significance, being associated initially with conjunctivitis in songbirds in the USA (Ley *et al.*, 1998). In Europe it is associated with a range of clinical signs, though not conjunctivitis (Pennycott *et al.*, 2005). In common with the latter study, *M. sturni*-positive birds in the present report were not suffering from conjunctivitis, and the significance of mycoplasma carriage remains unclear.

The pig unit was closed down during the submission period and before samples could be obtained, consequently it was not possible to investigate whether commensal carriage of *P. multocida* by pigs on this unit contributed to the epidemiology of the disease. However, serogroup F is rarely isolated in this species (Rimler & Brogden 1986, Pijoan 2006), making a link with the observed disease in corvids unlikely.

On the basis of the findings reported here, *P. multocida* infection should be considered as a major differential diagnosis for respiratory disease in wild corvids, the diagnostic rate will be enhanced by the use of IHC for *P. multocida* in such investigations, especially in those birds submitted dead. Additionally, corvids may act as a reservoir of *P. multocida* for infections in domestic poultry.

Acknowledgments

The authors thank Steven Newlove (owner of the outdoor pig unit) for his diligence and co-operation and Clare Underwood and Jeanie Finlayson (MRI) for expert preparation of histological and immunohistochemical sections. MPD, CWB and JCH are funded by the Scottish Government. The Wildlife Incident Investigation Scheme (WIIS) is funded by Defra. Some work was funded by the Scanning Surveillance VLA Diseases in Wildlife Scheme (ED1600), funded by Defra's food and farming group (FFG).

References

- Anon. (2006). Diagnostic manual for Avian Influenza, Ch. VI, Molecular tests and evaluation of results. *Official Journal of the European Union*, 49, L237/1-L237/27. At: http://eur-lex.europa.eu/LexUriServ/site/en/oj/2006/l_237/l_23720060831en00010027.pdf
- Anon. (2010a) Commission Decision on the implementation by member states of surveillance programmes for avian influenza in poultry and wild birds. Annex II, Part 1: Guidelines on the implementation of surveillance programmes for avian influenza in wild birds. *Official Journal of the European Union*, 53, L166/22-L166/32. At: <http://faolex.fao.org/docs/pdf/eur96321.pdf>
- Blackall, P. & Norskov-Lauritsen, N. (2008) *Pasteurellaceae*- the view from the diagnostic laboratory. In P. Kuhnert & H. Christensen (Eds.). *Pasteurellaceae* Biology, Genomics and Molecular Aspects (pp. 227-261). *Pasteurellaceae, Biology, genomics and molecular aspects*. Norfolk: Caister Acad. Press.
- Bradbury, J.M. (1998). Recovery of mycoplasmas from birds. In R. Miles & R.A.J, Nicholas (Eds). *Mycoplasma Protocols* (pp. 37-44). Totowa: Humana Books.
- Brown, P.M., Turnbull, G., Charman, S., Charlton A.J.A. & Jones, A. (2005). Analytical methods used in the United Kingdom Wildlife Incident Scheme for the detection of animal poisoning by pesticides. *Journal of the Association of Official Analytical Chemists (AOAC)*, 1, 204-220.
- Christensen, J.P. & Bisgaard, M. (2000). Fowl Cholera. *Revue scientifique et technique (International Office of Epizootics)*, 19, 626-637.
- Dagleish, M.P., Finlayson, J., Bayne, C., MacDonald, S., Sales, J. & Hodgson, J.C. (2010). Characterisation and time course of pulmonary lesions in calves after intratracheal

- challenge with *Pasteurella multocida* A:3. *Journal of Comparative Pathology*, 142, 157-169.
- Dziva, F., Muhhairwa, P., Bisgaard, M. & Christensen, H. (2008) Diagnostic and typing options for investigating diseases associated with *Pasteurella multocida*. *Veterinary Microbiology*, 128, 1-22.
- Ewers, C., Lübke-Becker, A., Bethe, A., Kiebling, S., Filter, M. & Wieler, L.H. (2006). Virulence genotype of *Pasteurella multocida* strains isolated from different hosts with various disease status. *Veterinary Microbiology*, 31, 304-317.
- Glisson, J.R, Hofacres, C.L & Christensen, J.P. (2008). Fowl Cholera. In Y.M. Saif (Ed). *Diseases of Poultry*, 12th Edition (pp. 739-758). Ames: Blackwell Publishing.
- Gough, R.E., Alexander, D.J., Collins, M.S., Lister, S.A. & Cox, W.J. (1998). Routine virus isolation or detection in the diagnosis of diseases of birds. *Avian Pathology*, 17, 893-907.
- Keymer, I.F. (1958). A survey and review of the causes of mortality in British birds and the significance of wild birds as disseminators of disease. *The Veterinary Record*, 70, 713-720.
- Ley, D.H., Geary, S.J., Berkhoff, J.E., McLaren, J.M., & Lavisohn, S. (1998). *Mycoplasma sturni* from Blue Jays and Northern Mockingbirds with conjunctivitis in Florida. *Journal of Wildlife Diseases*, 34, 403-406.
- Lichtensteiger, C.A., Steenbergen, S.M., Lee, R.M., Polson, D.D. & Vimr, E.R. (1996) Direct PCR Analysis for Toxigenic *Pasteurella multocida*. *Journal of Clinical Microbiology*, 37, 3035-3039
- Marchant, J. H & Gregory, R. D. (1999). Number of nesting rooks *Corvus frugilegus* in the United Kingdom in 1996. *Bird Study*, 46, 258-273.

- McAuliffe, L., Ellis, R., Lawes, J., Ayling, R.D. and Nicholas, R.A.J. (2005). 16S rDNA and DGGE: a single generic test for detecting and differentiating *Mycoplasma* species. *Journal of Medical Microbiology*, 54, 1-9.
- McDiarmid, A. (1965). Modern trends in animal health and husbandry, some infectious diseases of free-living wildlife. *British Veterinary Journal*, 121, 245-257.
- Murray, K.O., Mertens, E. & Despres, P. (2010) West Nile Virus and its emergence in the United States of America. *Veterinary Research*, 41, 67-81
- Ogunnariwo, J.A., & Schryvers, A.B. (2001). Characterization of a Novel Transferrin Receptor in Bovine Strains of *Pasteurella multocida*. *Journal of Bacteriology*, 183, 890–896.
- Papa, A., Danis, K., Bakas, A., Douglas, G. Lytras, T., Theocharopoulos, G., Chrysagis, D., Vassiliadou, E., Kamaria, F., Liona, A., Mellou, K., Saroglou, G. & Panagiotopoulos, T. (2010) Ongoing outbreak of West Nile virus infections in humans in Greece, July-August 2010. *Euro Surveillance*, 15, 19644. At: <http://www.eurosurveillance.org/images/dynamic/EE/V15N34/art19644.pdf>
- Pennycott, T.W., Dare, C.M, Yavari, C.A & Bradbury, J.M. (2005). *Mycoplasma sturni* and *Mycoplasma gallisepticum* in wild birds in Scotland. *The Veterinary Record*, 156, 513-515.
- Pennycott, T.W. (2005). SAC October 2005 Monthly Report. www.sac.ac.uk/consultancy/veterinary/publications/monthlyreports/2005/oct/
- Petersen, K.D, Christensen, J.P, Permin, A. & Bisgaard, M. (2001). Virulence of *Pasteurella multocida* subsp. *Multocida* from outbreaks of fowl cholera in wild birds for domestic poultry and game birds. *Avian Pathology*, 30, 27-31.

- Phipps, L.P., Gough, R.E., Ceeraz, V., Cox, W.J. & Brown, I.H. (2007) Detection of West Nile Virus in tissues of specific pathogen free chickens and serological response to laboratory infection: a comparative study. *Avian Pathology*, 36, 301-305.
- Pijoan, C. (2006) Pneumonic pasteurellosis. In B. Straw, J.J. Zimmerman, S. D'Allaire & D. Taylor (Eds.). *Diseases of Swine*, 9th Edition (pp. 719-726), Ames: Blackwell Publishing.
- Reisen, W. K, Barker, C.M., Carney, R., Lothrop, H.D., Wheeler, S.S., Wilson, J.L., Madon, M.B., Takahashi, R., Carroll, B., Garcia, S., Fang, Y., Shafii, M., Kahl, N., Ashtari, S., Kramer, V., Glaser, C. & Jean, C. (2006). Role of corvids in Epidemiology of West Nile Virus in Southern California. *Journal of Medical Entomology*, 43, 356-367.
- Rhoades, K.R. & Rimler, R.B. (1990). Somatic serotypes of *Pasteurella multocida* strain isolated from avian hosts (1976-1988). *Avian Diseases*, 34, 193-195.
- Rimler, R.B. and Glisson, J.R. (1997). Fowl cholera. In B.W. Calnek, H.J. Barnes, C.W. Beard, L.R. McDougald, & Y.M. Sail (Eds.). *Diseases of Poultry* 10th edn (pp.143-161). Ames: Iowa State University Press.
- Rimler, R.B. & Brogden, K.A. (1986) *Pasteurella multocida* isolated from rabbits and swine: Serologic types and toxin production. *American Journal of Veterinary Research*, 47, 730-736.
- Shivachandra, S. B., Kumar, A. A., Gautam, R., Singh, V. P., Saxena, M. K. & Srivastava, S. K. (2006) Identification of avian strains of *Pasteurella multocida* in India by conventional and PCR assays. *The Veterinary Journal*, 172, 561-564.
- Snipes, K.P., Carpenter, T.E., Corn, J.L., Kasten, R.W., Hirsh, D.C., Hird, D.W., & McCapes, R.H. (1988) *Pasteurella multocida* in wild mammals and birds in California: prevalence and virulence for turkeys. *Avian Diseases*, 32, 9-15.

- Taylor, T.T. & Pence, D.B. (1981). Avian cholera in common crows, *Corvus brachyrhynchos*, from the central Texas panhandle. *Journal of Wildlife Diseases*, 17, 511-514.
- Townsend, K.M., Boyce, J.D., Chung, J.Y., Frost, A.J. & Adler, B. (2001). Genetic organization of *Pasteurella multocida cap* loci and development of a multiplex capsular pcr typing system. *Journal of Clinical Microbiology*, 39, 924–929.
- Townsend, K. M., Frost, A. J., Lee, C. W., Papadimitriou, J. M. & Dawkins, H. J. (1998). Development of PCR assays for species- and type-specific identification of *Pasteurella multocida* isolates. *Journal of Clinical Microbiology*, 36, 1096-1100.
- Zinkl, J.G., Dey, N., Hyland, J.M., Hurt, J.J. & Heddleston, K.L. (1977). An epornitic of avian cholera in waterfowl and common crows in Phelps county, Nebraska, in the spring, 1975. *Journal of Wildlife Diseases*, 13, 194-198.
- Zoller, H., Lenglet, A., & Van Bortel, W. (2010) West Nile Virus: The need to strengthen preparedness in Europe. *Euro Surveillance*, 15, 19647.
<http://www.eurosurveillance.org/ViewArticle.aspx?ArticleId=19647>

Sub	Bird	Sp.	Live/ Dead	Clinical Signs	Gross Pathology	Microbiology Tissue Samples	Routine Cultures	Fungal Cultures	Mycoplasma Cultures/ ID
	1	CF				Lung		ND	-
	2	CF			Severe autolysis (all).	Lung, AS		ND	-
	3	CF			Fibrinous airsacculitis (4 birds).	Pericardium	All overgrown with	-	-
1	4	CF	Dead	FD	Fibrinous perihepatitis (2 birds).	Heart blood	<i>Proteus</i>	-	-
	5	CF			Severe fibrinous pericarditis (2 birds).	Liver		-	-
	6	CF			Necrotic pneumonia (2 birds).	AS		-	-
	7	CF				-	-	-	-
				Severe dyspnoea, paresis, mucoid discharge sinuses	Fibrinopurulent airsacculitis. Purulent pneumonia. Mucopurulent Sinusitis.	AS Sinus Liver	Pure PM Mixed including PM No growth	ND ND -	<i>M. sturni</i> -
				Snicking cough and severe dyspnoea	Gritty fibrinous airsacculitis. Sero-fibrinous pericarditis	Lung AS Heart blood Liver	Pure PM Pure PM Pure PM Pure PM	ND ND - -	<i>M. sturni</i> <i>M. gallopavonis</i> -
	10	CC	Dead	FD	Caseous airsacculitis.	Lung AS	No growth <i>E. coli</i>	ND	ND
4				Reduced flying ability (able to be caught)	Necrotic plaques on air sacs.	Lung AS	PM No growth		<i>M. gallinarum</i> <i>M. gallopavonis</i> <i>M. sturni</i> (pooled Lung &AS)
				Died while in trap, poor flight, severe dyspnoea	Focal necrotic pneumonia. Generalised fibrinous airsacculitis. Mild fibrinous perihepatitis. Mild fibrinous pericarditis.	Lung AS	PM and <i>Proteus</i> Pure PM	ND ND	<i>M. columborale</i> Unidentified Mycoplasma
					Severe fibrinous pericarditis. Severe fibrino-purulent airsacculitis. Purulent pneumonia.	Lung AS	<i>Proteus</i> <i>Proteus</i>	ND ND	<i>M. sturni</i> <i>M. sturni</i>
				Mild respiratory signs	Mild fibrinous airsacculitis. Focal pneumonia. Mild pericarditis.	Lung Pericardium	Pure PM Pure PM	ND -	ND ND
				Dropped wing	Simple fracture left humerus. Diffuse fibrinous airsacculitis.	Liver, lung Lung	No growth <i>E. coli</i> only	ND ND	ND ND
					Mild fibrinous pericarditis. Multifocal beige necrotic lesions up to 2mm in diameter throughout liver parenchyma.	AS Lung	No growth No growth	ND ND	ND
9					Hepatomegaly. Splenomegaly Focal fibrinous perihepatitis.	Liver Lung	No growth No growth	- ND	
					Multifocal petechiation of distal intestine.	Liver	No growth	-	ND

Table 1. Summary of clinical signs, gross pathology and bacteriological findings from this case series. CC= *Corvus corone*; CF= *Corvus frugilegus*; AS=Air sacs; ND = Not detected; - = Not done; FD = Found dead; Sub= submission number; PM = *Pasteurella multocida*

Bird No.	Status	Species	Tissues taken for histopathology	Pneumonia/air sacculitis	IHC lung/air sacs	Pulmonary parasites	Comments
1-7	dead	All CF	lung, air sac, liver, heart & brain	extensive necrotising fibrino-granulocytic	+	+ nematode	severe autolysis (all), multiple granulomatous foci in the liver (birds 1, 2 & 3), fibrinous pericarditis (bird 4)
8	live	CF	lung	severe fibrino-granulocytic	+	-	none
9	live	CC	lung, air sac, spleen, bursa, liver, kidney & heart	severe fibrino-granulocytic	+	+ nematode	granulocytic foci in liver
10	dead	CC	lung, air sac, liver, kidney, spleen & brain	granulocytic foci	+	+ nematode*	mineralised foci in liver
11	live	CC	lung, air sac, liver, bursa, spleen & brain	necrotising fibrino-granulocytic	+	-	suppurative foci in liver
12	live	CF	lung, air sac & heart	severe fibrino-granulocytic	+	-	myxomatous changes in myocardium adjacent to heart valves
13	dead	CC	none	N/A	N/A	N/A	whole carcass sent for <i>Mycoplasma</i> testing
14	live	CC	lung	localised fibrino-granulocytic	-	+ trematode	trematode parasite in bronchi at centre of localised pneumonia
15	live	CC	lung, brain, spleen & liver	No significant lesions	-	+ nematode	mild non-suppurative cholangiohepatitis
16	dead	CC	lung & heart	none found	+/-	-	none
17	dead	CC	lung	small necrotic focus	+	-	acute necrotising splenitis, suppurative hepatitis both IHC negative
18	dead	CC	lung, liver & spleen	small granulomatous focus	+	-	multifocal necrotic hepatitis

Table 2 : Histological lesions present and immunohistochemistry results in birds available for examination

(CF = rook, CC = carrion crow, N/A = not available, + = positive labelling/presence of parasites, - = no labelling/presence of parasites, +/- = inconclusive result). *Likely *Syngamus trachea*

Figure Legends

Figure 1. *Gross lesions of fibrino-purulent air sacculitis (bird 8) typical of those found in many of the birds submitted. Note presence of fibrin and caseous deposits on surface of air sacs and lungs.*

Figure 2. *Severe necrotic pneumonia, confirmed histologically, in an ex situ lung sample from bird 12, which died after capture and suffering from clinical signs of poor flight and dyspnoea. This bird's carcass was fresh and not autolysed.*

Figure 3. *Histological preparation of lung (bird 12) showing severe fibrino-granulocytic pneumonia with areas of necrosis (arrows) (haematoxylin and eosin).*

Figure 4a. *Immunohistochemical preparation labelling *Pasteurella multocida* (brown pigment) in lung tissue. Note large areas of labelled bacteria (black arrows) surrounded by granulocytes (blue arrows) (counter-stained with haematoxylin).*

Figure 4b. *Higher power image showing immunolabelling (brown pigment) of *P. multocida* within the cytoplasm of macrophages (arrows) within the lung (counter-stained with haematoxylin).*

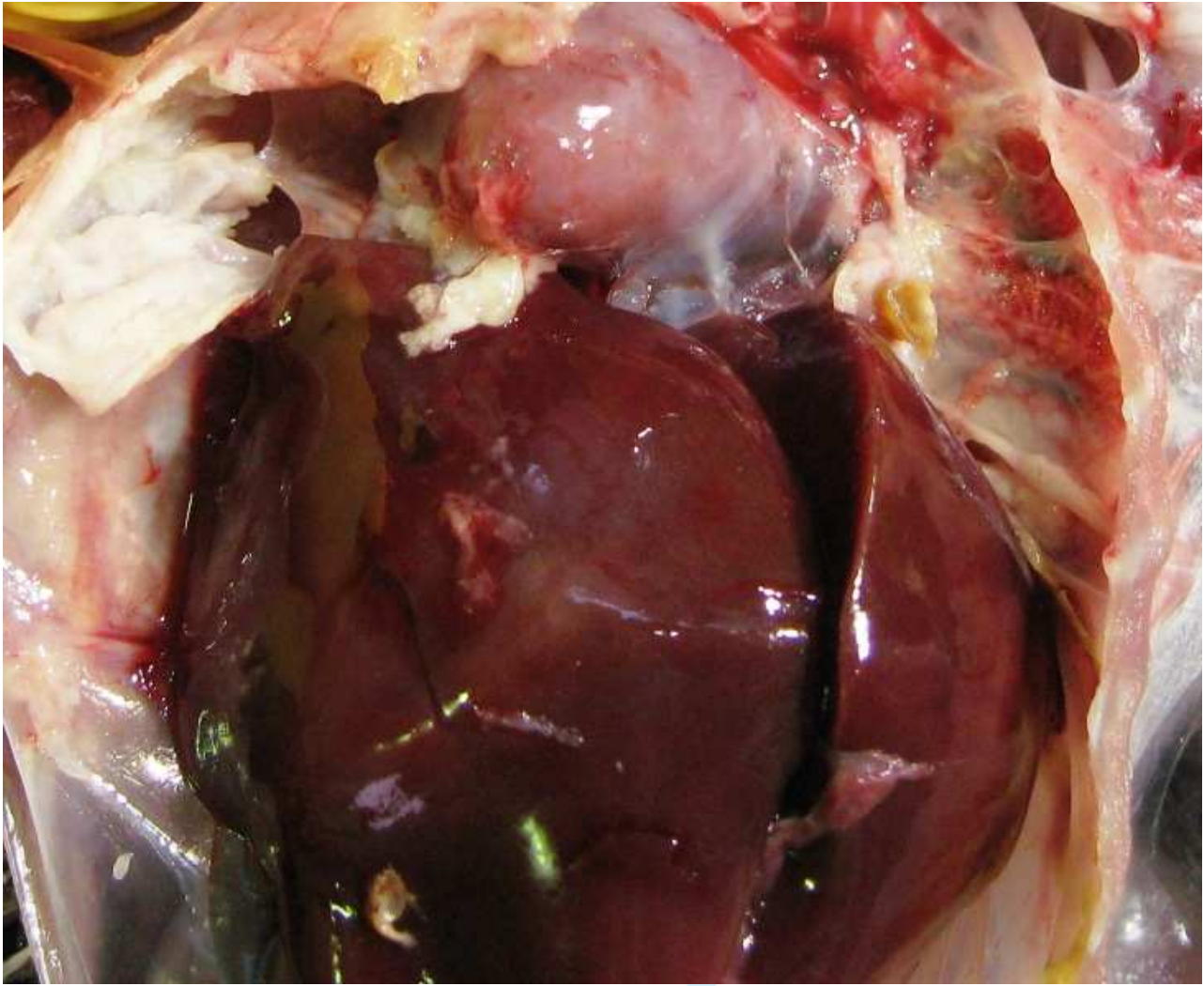


Fig 1

View Only

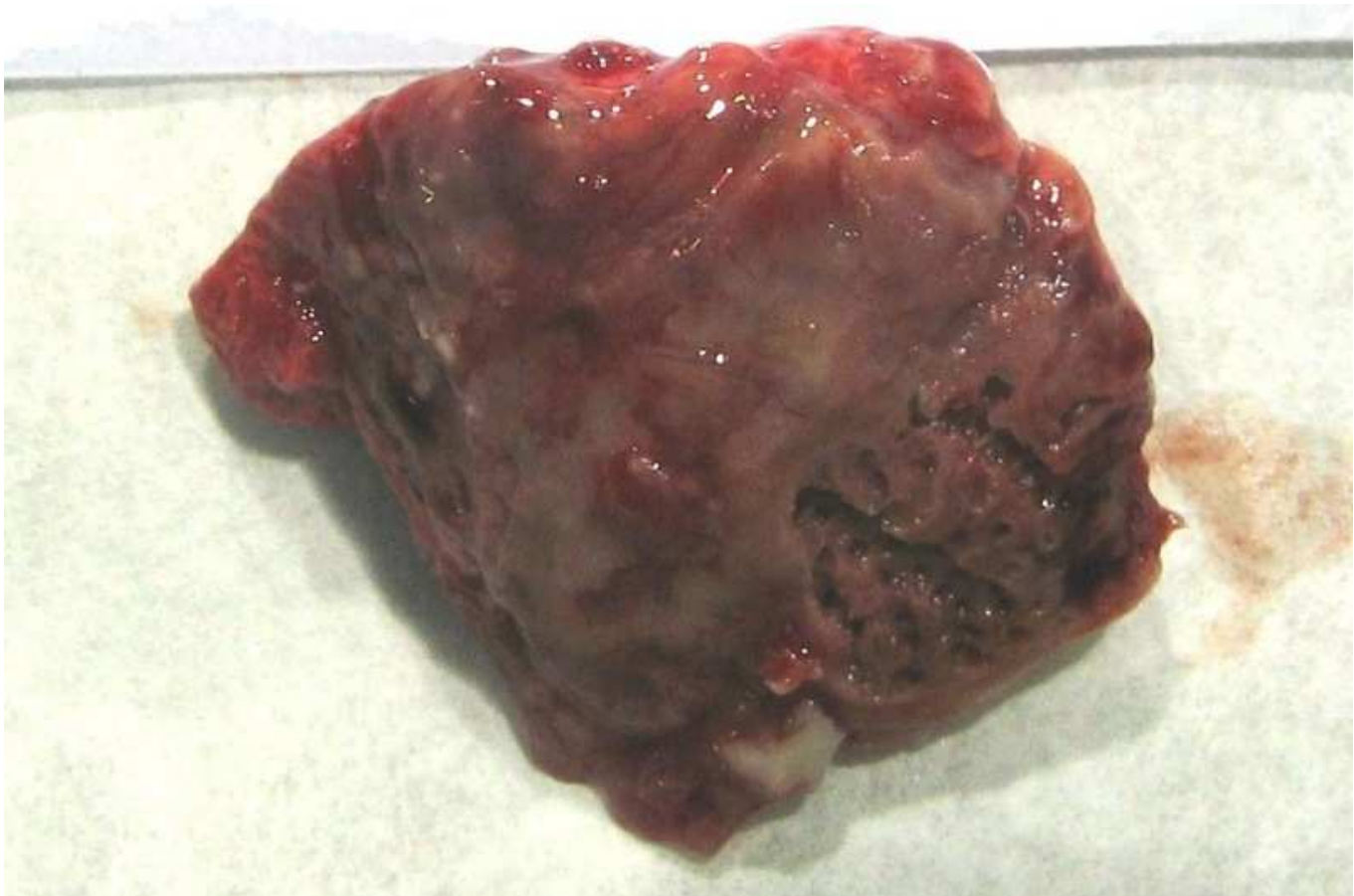

Fig 2

Review Only

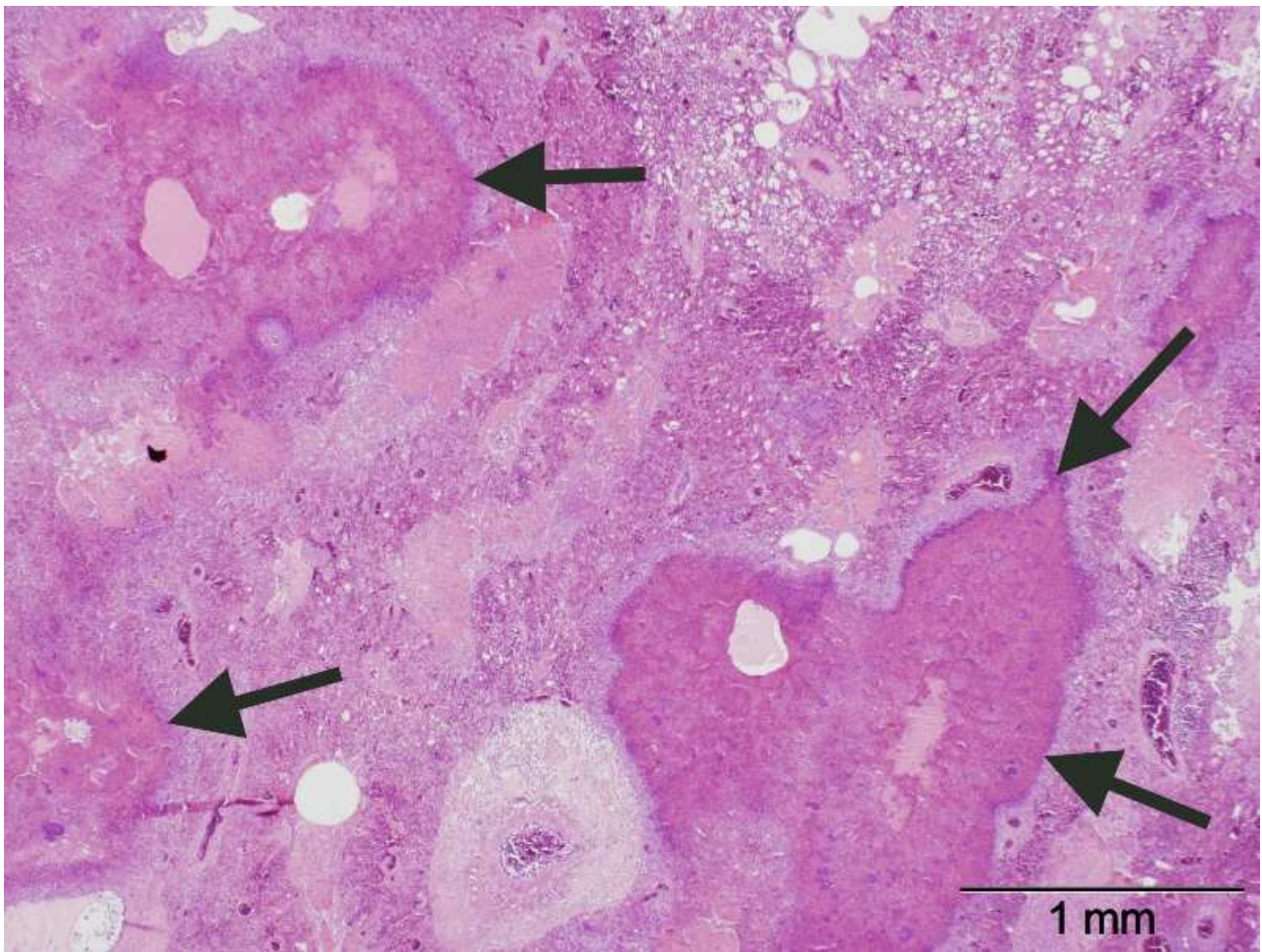


Fig 3

View Only

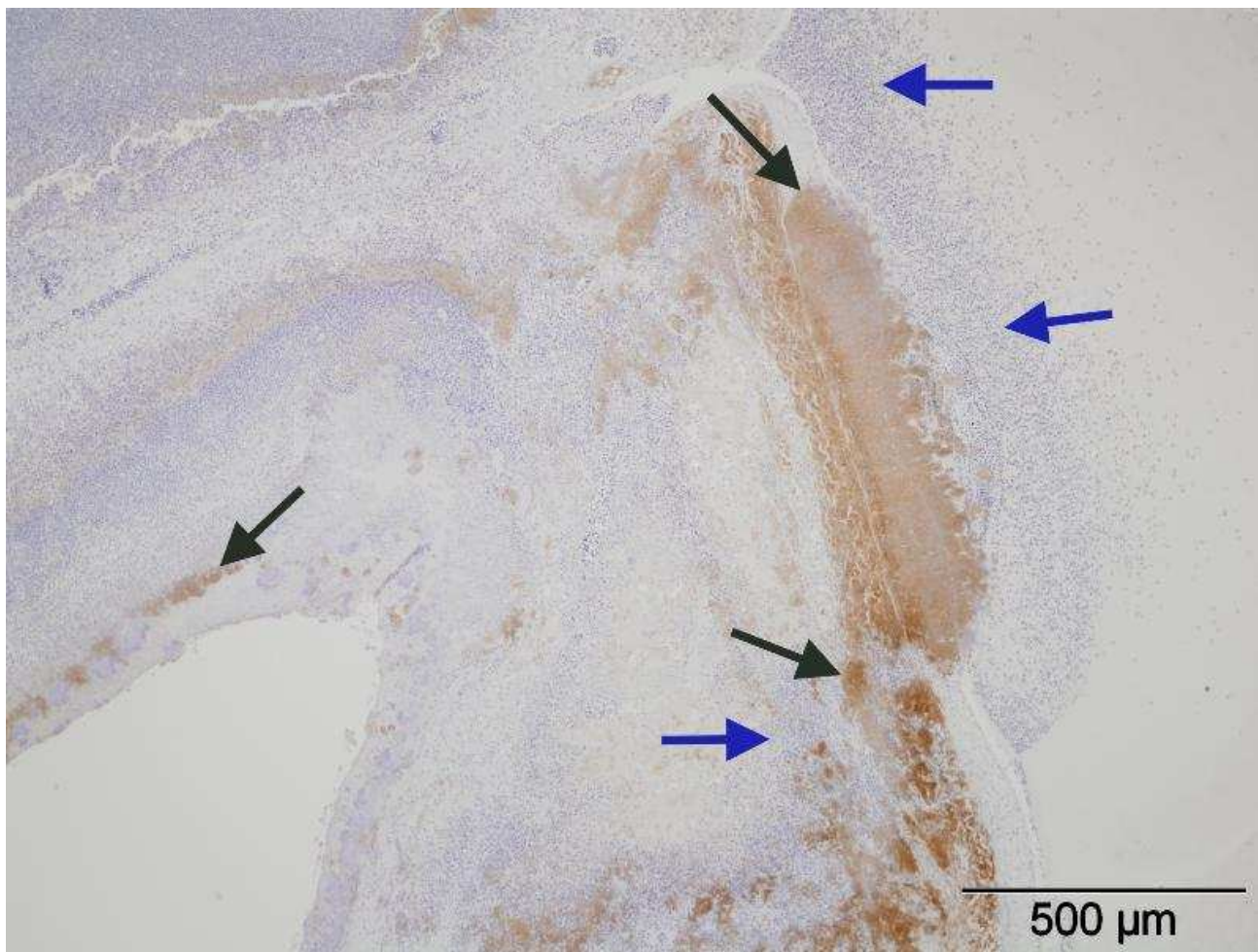


Figure 4a

Pre-view Only

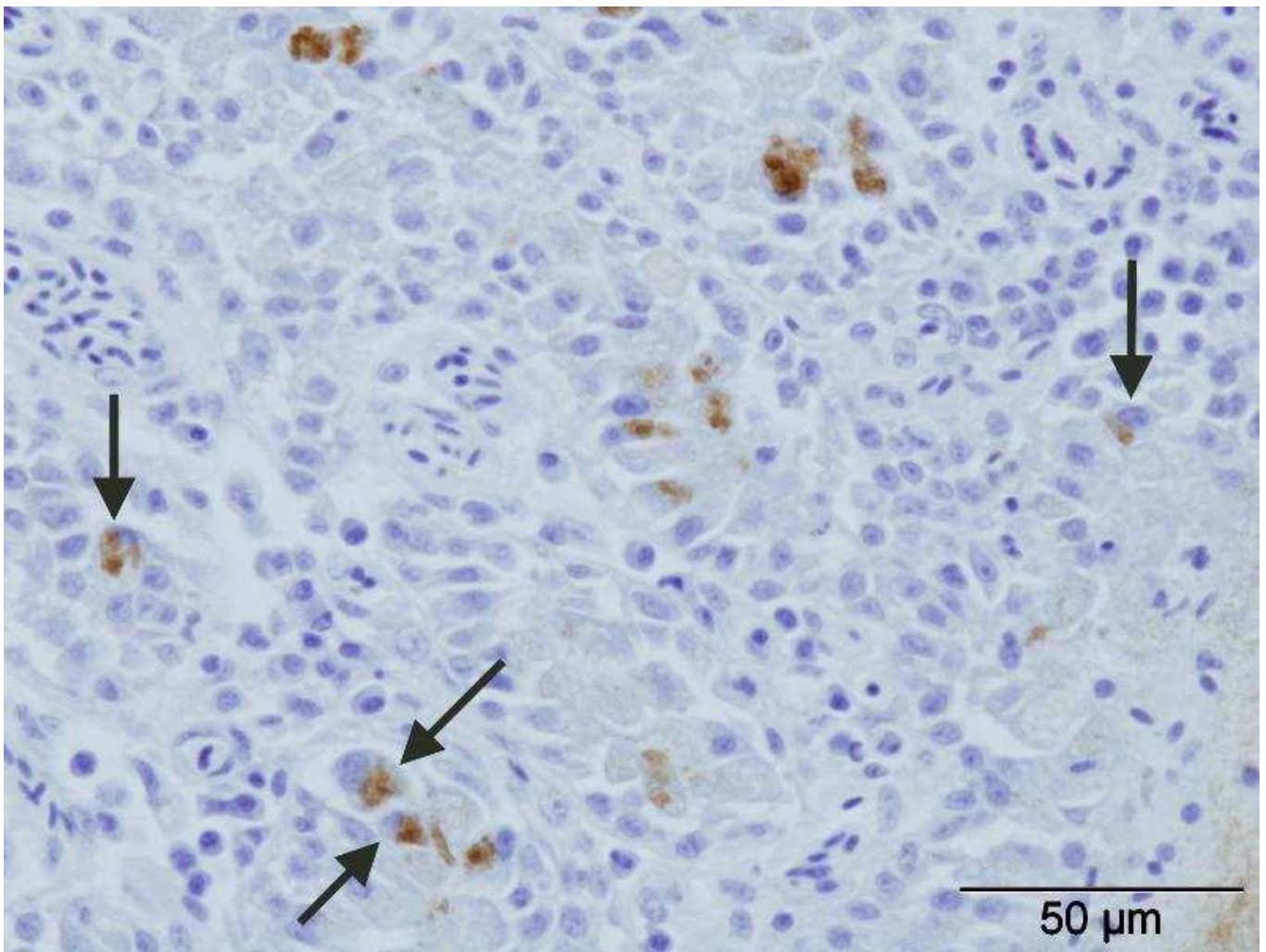


Figure 4b.