



HAL
open science

Application of in-situ hybridization for the detection and identification of avian malaria parasites in paraffin wax-embedded tissues from captive penguins

Nora Dinhopf, Meike Mostegl, Barbara Richter, Nora Nedorost, Anton Maderner, Karin Fragner, Herbert Weissenböck

► To cite this version:

Nora Dinhopf, Meike Mostegl, Barbara Richter, Nora Nedorost, Anton Maderner, et al.. Application of in-situ hybridization for the detection and identification of avian malaria parasites in paraffin wax-embedded tissues from captive penguins. *Avian Pathology*, 2011, 40 (03), pp.315-320. 10.1080/03079457.2011.569533 . hal-00710054

HAL Id: hal-00710054

<https://hal.science/hal-00710054>

Submitted on 20 Jun 2012

HAL is a multi-disciplinary open access archive for the deposit and dissemination of scientific research documents, whether they are published or not. The documents may come from teaching and research institutions in France or abroad, or from public or private research centers.

L'archive ouverte pluridisciplinaire **HAL**, est destinée au dépôt et à la diffusion de documents scientifiques de niveau recherche, publiés ou non, émanant des établissements d'enseignement et de recherche français ou étrangers, des laboratoires publics ou privés.



Application of in-situ hybridization for the detection and identification of avian malaria parasites in paraffin wax-embedded tissues from captive penguins

Journal:	<i>Avian Pathology</i>
Manuscript ID:	CAVP-2010-0170.R1
Manuscript Type:	Original Research Paper
Date Submitted by the Author:	12-Jan-2011
Complete List of Authors:	Dinhopl, Nora Mostegl, Meike; University of Veterinary Medicine, Institute of Pathology and Forensic Veterinary Medicine Richter, Barbara; University of Veterinary Medicine, Institute of Pathology and Forensic Veterinary Medicine Nedorost, Nora Maderner, Anton Fragner, Karin Weissenböck, Herbert; University of Veterinary Medicine, Department of Pathobiology
Keywords:	avian malaria, penguin, in situ hybridization, Plasmodium

SCHOLARONE™
Manuscripts

Application of in-situ hybridization for the detection and identification of avian malaria parasites in paraffin wax-embedded tissues from captive penguins

Nora Dinhopf, Meike M. Mostegl, Barbara Richter, Nora Nedorost, Anton Maderner, Karin Fragner, Herbert Weissenböck *

Institute of Pathology and Forensic Veterinary Medicine, Department of Pathobiology, University of Veterinary Medicine, Veterinärplatz 1, 1210 Vienna, Austria

Running title: malaria parasite identification in wax embedded tissue using in situ hybridization

Received: 12 January 2011

* Corresponding author:

E-mail adress: herbert.weissenboeck@vetmeduni.ac.at

Tel.: +43 125077 2418

Fax: +43 125077 2490

Abstract

In captive penguins avian malaria due to *Plasmodium* parasites is a well-recognized disease problem as these protozoa may cause severe losses among valuable collections of zoo birds. In blood films from naturally infected birds, identification and differentiation of malaria parasites based on morphological criteria is difficult because parasitaemia is frequently light and blood stages, which are necessary for identification of parasites, are often absent. Post mortem diagnosis by histological examination of tissue samples is sometimes inconclusive due to the difficulties in differentiating protozoal tissue stages from fragmented nuclei in necrotic tissue.

The diagnosis of avian malaria would be facilitated by a technique with the ability to specifically identify developmental stages of *Plasmodium* in tissue samples. Thus, a chromogenic in-situ hybridization (ISH) procedure with a digoxigenin-labelled probe, targeting a fragment of the 18S rRNA was developed for the detection of *Plasmodium* parasites in paraffin wax-embedded tissues. This method was validated in comparison with traditional techniques (histology, PCR), on various tissues from 48 captive penguins that died at the zoological garden Schönbrunn, Vienna. Meronts of *Plasmodium* gave clear signals and were easily identified using ISH. Potential cross-reactivity of the probe was ruled out by the negative outcome of the ISH against a number of protozoa and fungi. Thus, ISH proved to be a powerful, specific and sensitive tool for unambiguous detection of *Plasmodium* parasites in paraffin wax-embedded tissue samples.

Introduction

Avian haemosporidian blood parasites (Sporozoa, Haemosporida) which comprise the genera of *Haemoproteus*, *Plasmodium* and *Leucocytozoon*, are responsible for severe disease in domestic, zoo and wild birds and are transmitted by blood-sucking dipteran insect vectors (Valkiūnas, 2005).

These protozoal parasites are cosmopolitan in their distribution over all the warm continents, show close genetic relationship (Hellgren *et al.*, 2004) and have been subjects of extensive research for over a hundred years.

Parameters defining these genera and also species include the morphology of developmental stages as determined by light microscopy of blood films, characteristic features of life cycles and host-range (Valkiūnas, 2005). The diagnosis of avian malaria has been based traditionally on cytological examination of blood smears, occasionally supported by serology (Atkinson *et al.*, 2001) and histopathology. In blood films from naturally infected birds, identification of malaria parasites based on morphological criteria is difficult because the parasitaemia is frequently light and blood stages, which are necessary for the identification of the parasites, are often absent (Valkiūnas, 2005). Additionally, a blood smear from one bird may contain several species of parasites belonging to one or more genera of haemosporidians, which complicates identification, even for experts (Valkiūnas *et al.*, 2008).

However, none of these methods allows reliable species- and in some cases even genus discrimination of haemosporidian parasites. Several problems associated with the traditional diagnostic approaches can be solved with molecular methods, which are much more sensitive (Perkins *et al.*, 1998; Richard *et al.*, 2002). Polymerase chain reaction (PCR) techniques - frequently complemented by sequencing - have greatly increased the detection and identification of low-intensity infections, although in cases of simultaneous infections

with different haemosporidian parasites, which are common in wildlife, this approach often does not identify all the involved species (Valkiūnas *et al.*, 2006; Palinauskas *et al.*, 2007).

Infection of wild passerines with *Plasmodium* and *Haemoproteus* is prevalent worldwide (Valikiūnas and Iezhova, 2001) with the exception of some arctic and forest tundra regions due to low vector density and it has been estimated that 68% of all bird species are susceptible to haemosporidians (Atkinson *et al.*, 2000). Large numbers of birds originating from circumpolar regions (families: Spheniscidae, Alcidae) kept in zoological collections of temperate parts of the world succumb each year to avian malaria (Fleischmann *et al.*, 1964; Fix *et al.*, 1988; Loupal and Kutzer, 1995; Sturrock *et al.*, 2007). Penguins and other susceptible birds are not adapted evolutionarily and physiologically to the local species of haemosporidians and become infected when they are placed in the nidi of local malaria. The sources of infection are wild passerine birds living free in the zoo, and the parasites are transmitted by insect vectors. Reports of malaria in penguins have implicated three parasite species, *Plasmodium relictum* (Fix *et al.*, 1988; Cranfield *et al.*, 1990), *P. elongatum* (Fleischmann *et al.*, 1968; Cranfield *et al.*, 1990; Graczyk *et al.*, 1994) and *P. juxtannucleare* (Grim *et al.*, 2003).

Any naïve penguin can contract the disease, but chicks and juveniles are most susceptible. Due to low parasitaemia, the destruction of red blood cells usually does not cause clinical anaemia in penguins, and they often die without detectable parasitaemia (Stoskopf *et al.*, 1979). However, the most common clinical signs are anorexia, depression, dyspnoea and regurgitation (Stoskopf *et al.*, 1979).

The typical findings at necropsy and histological examination include splenomegaly, pulmonary edema, hydropericardium and the presence of parasites in the reticuloendothelial system (Grim *et al.*, 2003).

In tissue samples of dead birds the diagnosis of infection may prove complex because histological identification of meronts in tissue samples, especially in cases of low parasite

numbers, may be difficult and long searches may be required. On the other hand, fragmented nuclei within necrotic tissue may be erroneously considered as meronts.

To overcome the problems with unequivocal identification of tissue stages the aim of this study was to establish a specific detection method for avian *Plasmodium* species in birds and to relate tissue lesions with the presence of these protozoal parasites.

Materials and Methods

Probe design. An oligonucleotide probe labelled with digoxigenin at the 3' end (Eurofins MWG Operon, Ebersberg, Germany) was designed to detect a part of small subunit (SSU; 18S) ribosomal RNA sequence of all avian *Plasmodium* species which were available from GenBank database.

These sequences were aligned using Sci Ed Central software package (Scientific & Educational software, Cary, NC, USA) and a region of homology was selected as probe sequence. The probe sequence was:

5'-TTTAATAACTCGTTATATATATCAGTGTAGCAC-3'. To ensure probe specificity and to exclude unintended cross hybridization with other organisms the sequence was submitted to Basic Local Alignment Search Tool (BLAST; www.ncbi.nlm.nih.gov/blast.cgi).

The sequence was 100% complementary to a segment of 18S ribosomal RNA of a number of avian *Plasmodium* species (including *P. relictum*, *P. juxtannucleare*, *P. reichenowi*, *P. gallinaceum* and many not further characterized avian *Plasmodium* species), and there was only one nucleotide difference to avian *P. elongatum* and *P. lophurae* as well as to many simian and human *Plasmodium* species, including *P. vivax* and *P. falciparum*. The probe showed no complementarity with other related protozoa and is thus considered highly specific for *Plasmodium* and cross-hybridization is unlikely to occur.

Tissue samples and histopathology. Formalin fixed, paraffin wax-embedded tissues including spleen, liver, kidneys, lung, skeletal muscle, small intestine and brain from 48 captive penguins (33 Humboldt penguins [*Spheniscus humboldti*], 10 rockhopper penguins [*Eudyptes chrysocome*] and 5 king penguins [*Aptenodytes patagonicus*]), that had died between 2000 and 2008 at the zoological garden Schönbrunn, Vienna were examined in this retrospective study. Five of these penguins (4 Humboldt penguins, 1 rockhopper penguin) had a tentative diagnosis of infection with avian malaria parasites by standard histological investigation.

Supplementary tissue sections from a bobwhite quail (*Colinus virginianus*) infected with *Haemoproteus lophortyx* (courtesy of H. L. Shivaprasad, Davis, California, USA) and cultured *P. falciparum* parasites (courtesy of F. Petry, Mainz, Germany) were examined using the *Plasmodium* probe. The protozoal culture containing an unknown number of *P. falciparum* parasites was fixed in 10% buffered formalin and embedded in paraffin wax. Prior to embedding the culture was soaked with rice starch (3.3 mg/ml) for 5 h and centrifuged at 6000×g for 10 min to produce a pellet. The pellet was overlaid with agar, hardened at 4 °C, carefully removed from the tube and finally embedded in paraffin wax.

In addition, archived paraffin wax-embedded tissues from different animal species naturally infected with protozoal parasites of the genera *Cryptosporidium*, *Sarcocystis*, *Eimeria*, *Toxoplasma*, *Giardia*, *Entamoeba*, or fungi (*Aspergillus*, *Candida*, *Encephalitozoon*) and viruses (canine adenovirus 2, canine parvovirus 2, West Nile virus, Usutu virus) were investigated with the *Plasmodium* probe in order to exclude cross hybridization. Application of an irrelevant oligonucleotide probe (*Leishmania* spp. probe) to positive control slides was carried out as additional negative control.

All sections used for in-situ hybridization were also stained by Giemsa and with hematoxylin and eosin (H&E) to demonstrate parasites.

In-situ hybridization (ISH). The paraffin wax-embedded tissue samples were sectioned (~3 µm) and placed on Superfrost Plus slides. They were dewaxed in Neoclear and rehydrated in a series of graded alcohols (100%, 96%, 70%) and distilled water. Proteolytic treatment was done with proteinase K (Roche, Basel, Switzerland) 6 µg/ml in Tris-buffered saline at 37 °C for 50 min and the slides were rinsed with distilled water and dehydrated in 96% ethanol and 100% isopropanol followed by air-drying.

Afterwards the slides were covered with hybridization mixture, 100 µl of which were composed of 12 µl distilled water, 20 µl 20x standard sodium citrate (SSC), 50 µl formamide (50%), 2 µl Denhardt's solution, 10 µl dextran sulphate (50%, w/v), 5 µl herring sperm DNA (50 mg/ml) and 1 µl *Plasmodium* probe at a concentration of 100 ng/ml.

Then the slides were incubated at 95° C for 6 min and immediately afterwards placed on crushed ice. After cooling the slides were hybridized overnight in a humid chamber at 40° C. On the second day the slides were washed in 2x SSC, 1x SSC and 0.1x SSC at room temperature (RT).

Then the slides were incubated with anti-digoxigenin-AP Fab fragments (Roche) (dilution 1:200) for 1 h at RT. After washing the signal was visualized with 5-bromo-4-chloro-3-indolyl phosphate (BCIP) and 4-nitro blue tetrazolium chloride (NBT) (Roche) for 1 h at RT in the dark. The staining reaction was terminated by placing the slides in TE buffer (pH 8.0) for 10 min.

Finally the slides were counterstained with hematoxylin and mounted under coverslips with Aquatex (VWR International, Vienna, Austria).

Polymerase chain reaction (PCR). For confirmation of all ISH results, PCR assays (Richard *et al.*, 2002; Martínez *et al.*, 2009) targeting part of the parasite cytochrome *b* gene were applied.

Amplification of parasite DNA was attempted using the primer pair Palu-F/ Palu-R (Martínez *et al.*, 2009) which amplified a 390 bp sequence from a conserved region of the cytochrome *b* gene of *Plasmodium* and *Haemoproteus*. In case this PCR amplification was successful, a second PCR assay, using the primers 621/983 (Richard *et al.*, 2002) which amplified a 341 bp sequence of the cytochrome *b* gene of *Plasmodium*, was carried out. For PCR amplification paraffin wax sections (10 µm) were dewaxed in xylene and afterwards washed in ethanol and dried. DNA was extracted using Nexttec Clean Columns (Nexttec, Leverkusen, Germany) according to the manufacturer's instructions.

The 25 µl reaction mixture was composed of 10 µl HotMasterMix (5Prime, Eppendorf, Hamburg, Germany), 1 µl of each forward and reverse primer (10 pM), 11 µl of distilled water and 2 µl of template DNA. The PCR amplification started with denaturation for 2 min at 94 °C, was followed by 40 cycles of heat denaturation at 94 °C for 30 s, primer annealing at 50 °C for primers 621/983 or 56 °C for primers Palu-F/Palu-R for 30 s and DNA extension at 72 °C for 1 min, and ended with a final extension at 72 °C for 10 min. A 10 µl aliquot of each PCR product was analyzed by gel electrophoresis on a 2% Tris acetate-EDTA-agarose gel. The agarose gel was stained with ethidium bromide and visualized with a BioSens SC-Series 710 gel documentation system using the BioSens gel imaging system software (GenXpress, Wiener Neudorf, Austria). Positive PCR controls were not used. The negative control was a PCR mixture containing laboratory grade water instead of template DNA.

Gene Sequence Analysis. PCR products, using the primers Palu-F and Palu-R were sequenced according to Bakonyi *et al.* (2004), except that DNA purification after

amplification was carried out using the QIAquick gel extraction kit (QIAGEN, Hilden, Germany) in accordance with the manufacturer 's instructions instead of ethanol precipitation. The obtained nucleotide sequences were identified by BLAST search against GenBank database.

GenBank Accession numbers. The nucleotide sequences determined in this study were deposited in GenBank database under the accession numbers HQ404522-HQ404534.

Results

Tissue samples and histopathology. Lesions typical of avian malaria, including splenomegaly, hepatomegaly and severe pulmonary edema were present in nine of 48 penguins.

Histologically, in five of these nine penguins (four Humboldt penguins, one rockhopper penguin) numerous protozoal meronts were evident in the capillary endothelium of various tissues, especially lung, liver, spleen and brain by standard H&E staining. Severe hyperaemia and fibrinoid necrosis was observed in the lung; in endothelial cells of the capillaries numerous roundish or oval exoerythrocytic meronts, containing a variable number of merozoites, were present (Fig. 1 A). In the brain characteristic histological lesion were absent, although many elongated exoerythrocytic meronts (phanerozoites) were observed in the capillary endothelium (Fig. 1 B). The spleen showed focal necrosis and karyorrhexis as well as the formation of microthrombi and several exoerythrocytic meronts in the endothelial cells of the capillaries. In some cases, it was difficult to distinguish between nuclear fragments and meronts which made their unequivocal identification challenging. In the liver, perivascular nonsuppurative inflammatory infiltrates containing mainly plasma cells were

found. Additionally meronts were observed in the sinusoidal endothelium and the cytoplasm of hepatocytes (Fig. 1 C). In the remaining four of these nine penguins, which had a tentative diagnosis of avian malaria neither histological lesions nor the presence of avian malaria parasites were noticed in any of the tissues investigated.

In none of the 39 penguins without macroscopic changes suggestive of avian malaria characteristic histological lesions or presence of meronts were noticed.

In-situ hybridization (ISH). *Plasmodium* tissue stages (meronts) were readily identified by a distinct purple to black signal within the capillary endothelium. Clearly stained parasites were found in various tissues, especially lung (Fig. 2 A), brain (Fig. 2 B), liver (Fig. 2 C) and spleen of 13 penguins (11 Humboldt penguins, two rockhopper penguins). These included all five histologically diagnosed cases, the four animals with macroscopic changes suggestive of avian malaria but without histological lesions and four additional penguins without macroscopic and histological alterations. In the latter four cases the quantity of protozoa was markedly lower. Cultured *P. falciparum* parasites were clearly labelled with the *Plasmodium* probe.

There was no cross reactivity with *Haemoproteus lophortyx* (Fig. 3), other protozoal parasites, fungi and viruses.

PCR. The PCRs, using the primers Palu-F/Palu-R and 621/983 yielded distinct amplification products of the expected sizes from various DNA extracts of lung, brain, liver and spleen of the 13 ISH-positive penguins and confirmed the tentative diagnosis of an infection with avian malaria parasites. In the 35 ISH-negative samples parasite DNA was not detectable using the primer pair Palu-F/Palu-R.

Gene Sequence Analysis. DNA sequences from the 13 penguins were edited and aligned using the Sci Ed Central software package. In all these cases no double peaks could be observed in the electropherograms; therefore the presence of double infections seemed unlikely.

DNA sequences from nine penguins proved to be 99-100% identical with published sequences from unambiguously determined *P. elongatum* (DQ368381, DQ659588, AY733089 [Valkiūnas *et al.*, 2008]). Sequences from the other four birds were 99-100% identical with published sequences from avian *Plasmodium* spp. (DQ847263, EU810610, DQ991068, DQ368384).

Discussion

This report describes an in-situ hybridization procedure with a digoxigenin-labelled oligonucleotide probe for the detection of avian malaria parasites in tissue sections of penguins. Identification of these protozoal parasites is usually based on microscopic examination of stained blood smears, or on the use of PCR assays. However, none of these techniques is able to specifically identify haemosporidians in histological slides. Thus we attempted to achieve this goal using a technique which had previously successfully identified protozoa of different phyla (Chvala *et al.*, 2006; Liebhart *et al.*, 2006; Richter *et al.*, 2008; Mostegl *et al.*, 2010). In the present project, the approach to design species- or even genus-specific oligonucleotide probes was expected to be complex due to the fact that morphologically based taxonomy distinguishes a few hundred haemosporidian species. This enormous number, however, largely overestimates the number of genetically defined species, because morphologically identical parasites were given different names when observed in different bird species (Garnham, 1966). Hence, identification to species level is a challenge

and requires screening of many parasite cells in a blood smear, because morphological characteristics may overlap for some species (Valkiūnas, 2005). These difficulties obviously led to some incorrect linkages of morphology and DNA sequences which unfortunately are also deposited in GenBank (Valkiūnas *et al.*, 2008). Thus, a strategy to minimize incorrect species identification has been recommended by Valkiūnas *et al.* (2008). They suggest vigorous comparison of morphological criteria of parasites and their DNA lineages with the expertise of taxonomists and to establish a database for reference DNA sequences from unambiguously identified parasites. A further challenge was that the *Plasmodium* probe needed, had to be designed against 18S rRNA sequences, because only these target molecules seem to be present in sufficient abundance to allow robust labelling of the respective parasite cells. This is clearly documented by the successful application of this approach for a number of other protozoa (Chvala *et al.*, 2006; Liebhart *et al.*, 2006; Richter *et al.*, 2008; Mostegl *et al.*, 2010). Unfortunately only very few reliable (i.e. convincingly identified to species level) rRNA gene sequences from avian *Plasmodium* species are found in GenBank. So, probe design had to be based on these fragmentary genetic data. From parasites belonging to *Haemoproteus* and *Leucocytozoon* genera, there are no 18S rRNA gene sequences available in the GenBank. For this reason, hypothetical cross reactivity of the *Plasmodium* probe could not be evaluated *in silico*. The negative outcome of the ISH of a bobwhite quail (*Colinus virginianus*) infected with *Haemoproteus lophortyx*, however, suggests that the probe does not crossreact with members of the genus *Haemoproteus* and may thus be considered specific for *Plasmodium*.

For species identification of haemosporidians, geneticists predominantly rely on cytochrome *b* gene sequences; thus there is an abundance of such data. Unfortunately, ISH using these sequences as the target produced no staining (personal observation, unpublished). For genetic identification of the involved *Plasmodium* species, we relied on comparing our cytochrome *b* sequences with GenBank entries. To avoid incorrect assignments we only

accepted sequences as valid when they were derived from organisms which had been identified by both morphological and molecular methods or when they showed a high degree of homology to such sequences. Sequences with a higher amount of nucleotide differences and sequences with very close genetic relationships to other than the indicated species were not considered valid and were not used for the alignments on which species identification of parasites were based. In our cases nine strongly similar sequences were closely related to *P. elongatum* and another four sequences of high similarity were closely related to *P. elongatum*-like, unclassified *Plasmodium* species. As only these two *Plasmodium* variants were present in several independent malaria outbreaks over a time span of nine years it seems that the natural avian hosts in and around Vienna are predominantly infected with these *P. elongatum*-like parasites. This aspect will be further investigated in the future.

PCR detects amplified parasite DNA and not necessarily the intact parasite, and does not reflect the stage of disease or the severity of infection. Additionally, the localization of the parasites within tissue lesions and simultaneous evaluation of their morphology and distribution is not feasible with this method.

Histological identification of meronts in tissue samples, especially in cases with low parasite numbers may be cumbersome and long searches may be required.

Also other objects viewed by light microscopy may be erroneously considered as meronts. In contrast, meronts were easily identified by ISH, even at low magnification and in different penguin tissues. This method has the advantage of high specificity due to nucleic acid detection and offers the possibility of correlating the presence of parasites with associated lesions. Unfortunately, the ISH technique described here does not allow discrimination of different subgenera or species of haemosporidians, especially due to the previously mentioned lack of 18S rRNA gene sequence information of a large number of defined *Plasmodium* species. Future directions of the ongoing research are generating rRNA gene sequences of defined species of the genera *Haemoproteus* and *Leucocytozoon* in order to

design specific probes which may allow distinguishing between genera, subgenera and maybe discrimination to species level.

In any case, the ISH procedure described here proved to be a powerful tool for unambiguous detection of *Plasmodium* parasites in paraffin wax-embedded tissues, which will also be widely applicable for post mortem examination of suspicious cases.

Acknowledgments

We thank the staff of the Zoo Schönbrunn for submission of the dead birds and for their good cooperation.

Thanks are due to Prof. H. L. Shivaprasad (Davis, California) for the generous gift of tissue sections from a bobwhite quail (*Colinus virginianus*) infected with *Haemoproteus lophortyx* and Dr. F. Petry (Mainz, Germany) for the generous gift of cultured *P. falciparum* parasites.

We are grateful to Klaus Bittermann for the professional digital artwork and wish to thank Nora Nedorost and Anton Maderner for their excellent technical support.

This study was funded by the Austrian Science Fund (FWF) grant P20926.

References

- Atkinson, C. T., Dusek, R. J., Woods, K. L. & Iko, W. M. (2000). Pathogenicity of avian malaria in experimentally infected Hawaii amakihi. *Journal of Wildlife Disease*, 36, 197-204.
- Atkinson, C. T., Dusek, R. J. & Lease, J. K. (2001). Serological response and immunity to superinfection with avian malaria in experimentally –infected Hawaii amakihi. *Journal of Wildlife Disease*, 37, 20-27.
- Bakonyi, T., Gould, E. A., Kolodziejek, J., Weissenböck, H. & Nowotny, N. (2004). Complete genome analysis and molecular characterization of Usutu virus that emerged in Austria in 2001: comparison with the South African strain SAAR-1776 and other flaviviruses. *Virology*, 328, 310-310.
- Chvala, S., Fragner, K., Hackl, R., Hess, M. & Weissenböck, H. (2006). *Cryptosporidium* infection in domestic geese (*Anser anser f. domestica*) detected by in-situ hybridization. *Journal of Comparative Pathology*, 134, 211-218.
- Cranfield, M. R., Shaw, M., Beall, F., Skjoldager, M. & Ialeggio, M. (1990). A review and update of avian malaria in the African penguin (*Spheniscus demersus*). *Proceedings of the American Association of Zoo Veterinarians*, 243-248.
- Fix, A. S., Waterhouse, C., Greiner, E. C. & Stoskopf, M. K. (1988). *Plasmodium relictum* as a cause of avian malaria in wild-caught Magellanic penguins (*Spheniscus magellanicus*). *Journal of Wildlife Disease*, 24, 610-619.
- Fleischmann, R. W., Sladen, W. J. L. & Melby E. C. (1968). Malaria (*Plasmodium elongatum*) in captive African penguins (*Spheniscus demersus*). *Journal of the American Veterinary Medical Association*, 153, 928-935.
- Garnham, P. C. C. (1966). Malaria parasites and other haemosporidia. *Blackwell Scientific Publications*, Oxford, U. K.

- Graczyk, T. K., Cranfield, M. R., McCutchan, T. F. & Bicknese, E. J. (1994). Characteristics of naturally acquired avian malaria infections in naïve juvenile African black-footed penguins (*Spheniscus demersus*). *Parasitology Research*, 80, 634-637.
- Grim, C. K., van der Merwe, E., Sullivan, M., Parson, N., McCutchan, T. F. & Cranfield M. (2003). *Plasmodium juxtannucleare* associated with mortality in black footed penguins (*Spheniscus demersus*) admitted to a rehabilitation center. *Journal of Zoo and Wildlife Medicine*, 34, 250-255.
- Hellgren, O., Waldenström, J. & Bensch, S. (2004). A new PCR assay for simultaneous studies of *Leucocytozoon*, *Plasmodium*, and *Haemoproteus* from avian blood. *Journal of Parasitology*, 90, 797-802.
- Liebhart, D., Weissenböck, H. & Hess, M. (2006). In-situ hybridization for the detection and identification of *Histomonas meleagridis* in tissues. *Journal of Comparative Pathology*, 135, 237-242.
- Loupal, G. & Kutzer, E. (1995). Infektionen mit *Plasmodium* spec. bei Papageitauchern (*Fratercula arctica*). *Kleintierpraxis*, 41, 901-906 (german).
- Martínez, J., Martínez-de la Puente, J., Herrero, J., Del Cerro, S., Lobato, E., Rivero-de Aguilar, J., et al. (2009). A restriction site to differentiate *Plasmodium* and *Haemoproteus* infections in birds: on the inefficiency of general primers for detection of mixed infection. *Parasitology*, 136, 713-722.
- Mostegl, M. M., Richter, B., Nedorost, N., Maderner, A., Dinhopl, N., Kulda, J., et al. (2010). Design and validation of an oligonucleotide probe for the detection of protozoa from the order Trichomonadida using chromogenic in situ hybridization. *Veterinary Parasitology*, 171, 1-6.
- Palinauskas, V., Kosarev, V., Shapoval, A., Bensch, S. & Valkiūnas, G. (2007). Comparison of mitochondrial cytochrome b lineages and morphospecies of two avian malaria

- parasites of the subgenera *Haemamoeba* and *Giovannolaia* (Haemosporida: Plasmodiidae). *Zootaxa*, 1626, 39-50.
- Perkins, S. L., Osgood, S. M. & Schall, J. J. (1998). Use of PCR for detection of subpatent infections of lizard malaria: implications for epizootiology. *Molecular Ecology*, 7, 1587-1590.
- Richard, A. F., Sehgal, R. N. M., Jones, H. I. & Smith, T. B. (2002). A comparative analysis of PCR-based detection methods for avian Malaria. *Journal of Parasitology*, 88, 819-822.
- Richter, B., Küber-Heiss, A., Weissenböck, H. & Schmidt, P. (2008). Detection of *Cryptosporidium* spp., *Entamoeba* spp. and *Monocercomonas* spp. in the gastrointestinal tract of snakes by in-situ hybridization. *Journal of Comparative Pathology*, 138, 63-71.
- Stoskopf, M. K. & Beier, J. (1979). Avian malaria in African black-footed penguins. *Journal of the American Veterinary Medicine Association*, 175, 944-947.
- Sturrock, H. J. W & Tompkins, D. M. (2007). Avian malaria (*Plasmodium* spp.) in yellow-eyed penguins: Investigating the cause of high seroprevalence but low observed infection. *New Zealand Veterinary Journal*, 55, 158-160.
- Valkiūnas, G. & Iezhova, T. A. (2001). A comparison of the blood parasites in three subspecies of the yellow wagtail *Motacilla flava*. *Journal of Parasitology*, 87, 930-934.
- Valkiūnas, G. (2005). Avian malaria parasites and other Haemosporidia. *CRC Press*, Boca Raton, Florida.
- Valkiūnas, G., Bensch, S., Iezhova, T. A., Križanauskienė, A., Hellgren, O. & Bolshakov, C. V. (2006). Nested cytochrome *b* polymerase chain reaction diagnostics underestimate mixed infections of avian blood haemosporidian parasites: microscopy is still essential. *Journal of Parasitology*, 92, 418-422.
- Valkiūnas, G., Zehtindjiev, P., Dimitrov, D., Križanauskienė, A., Iezhova, T. A. & Bensch, S. (2008). Polymerase chain reaction-based identification of *Plasmodium* (*Huffia*)

elongatum, with remarks on species identity of haemosporidian lineages deposited in GenBank. *Parasitology Research*, 102, 1185-1193.

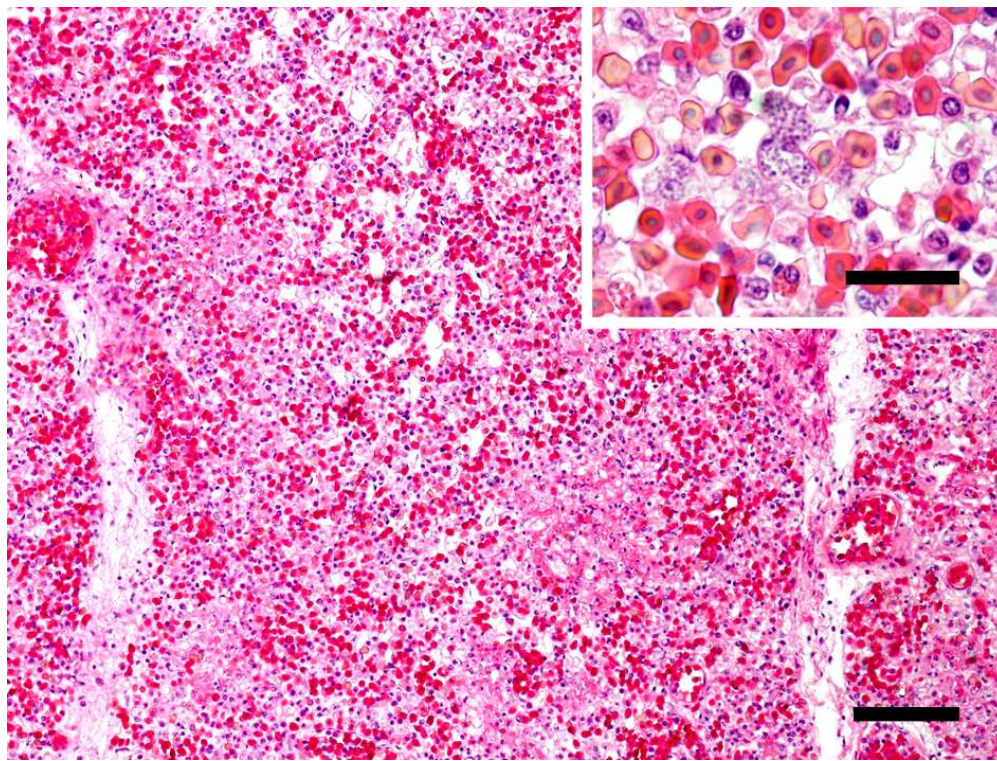
For Peer Review Only

Figure legends

Figure 1. *Histological sections of lung (A), brain (B) and liver (C) of penguins naturally infected with Plasmodium elongatum parasites. Several exoerythrocytic meronts in the capillary endothelium are present; in brain elongated exoerythrocytic meronts are present, H&E, bar 150 μm ; inset bar 40 μm*

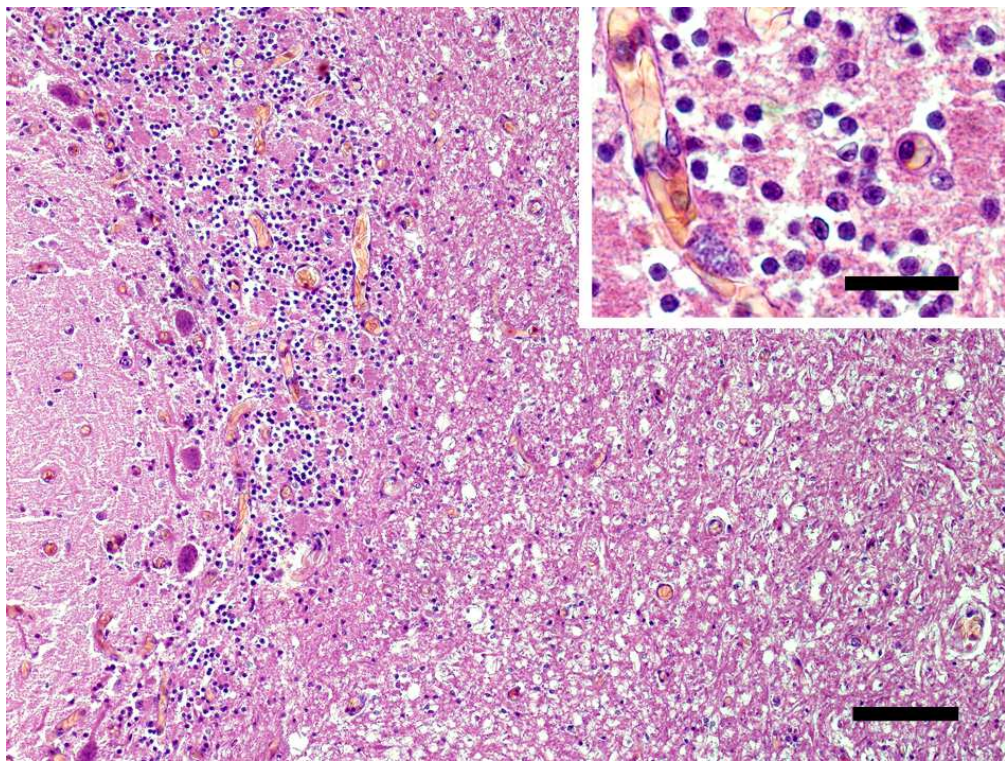
Figure 2. *In-situ hybridization of lung (A), brain (B) and liver (C) shows numerous Plasmodium meronts which are readily discernible by their distinct purple to black signal, bar 150 μm ; inset bar 40 μm*

Figure 3. *By in-situ hybridization Haemoproteus lophortyx megaloschizonts in skeletal muscle of a Bobwhite quail (Colinus virginianus) show no specific signal, bar 40 μm*



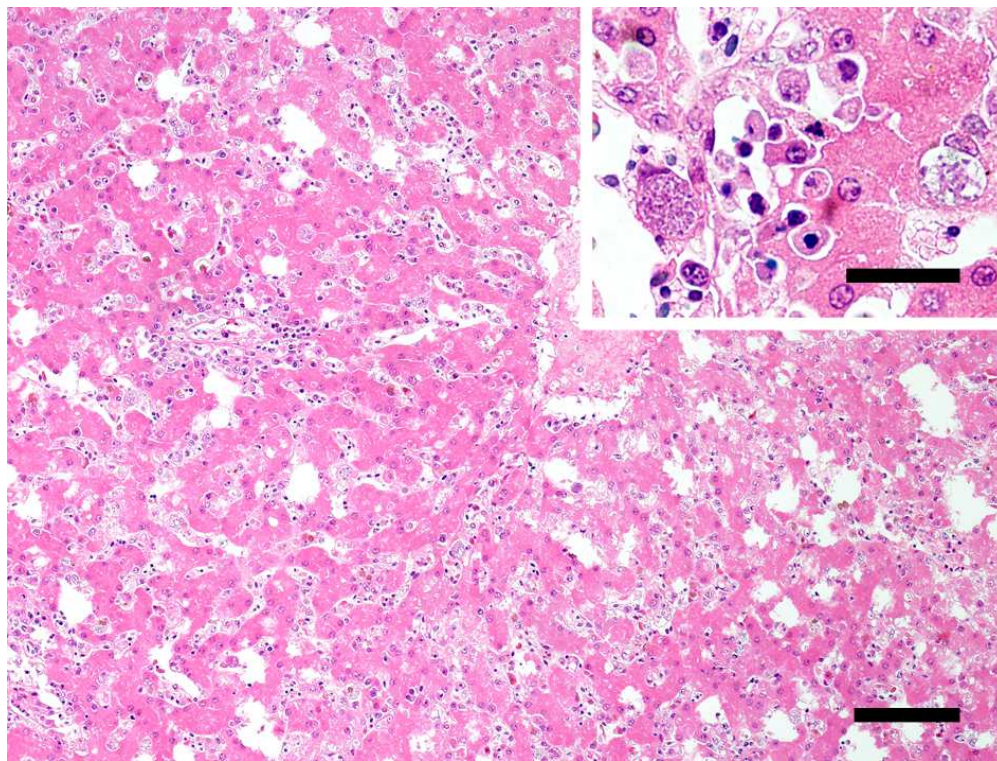
80x60mm (300 x 300 DPI)

View Only



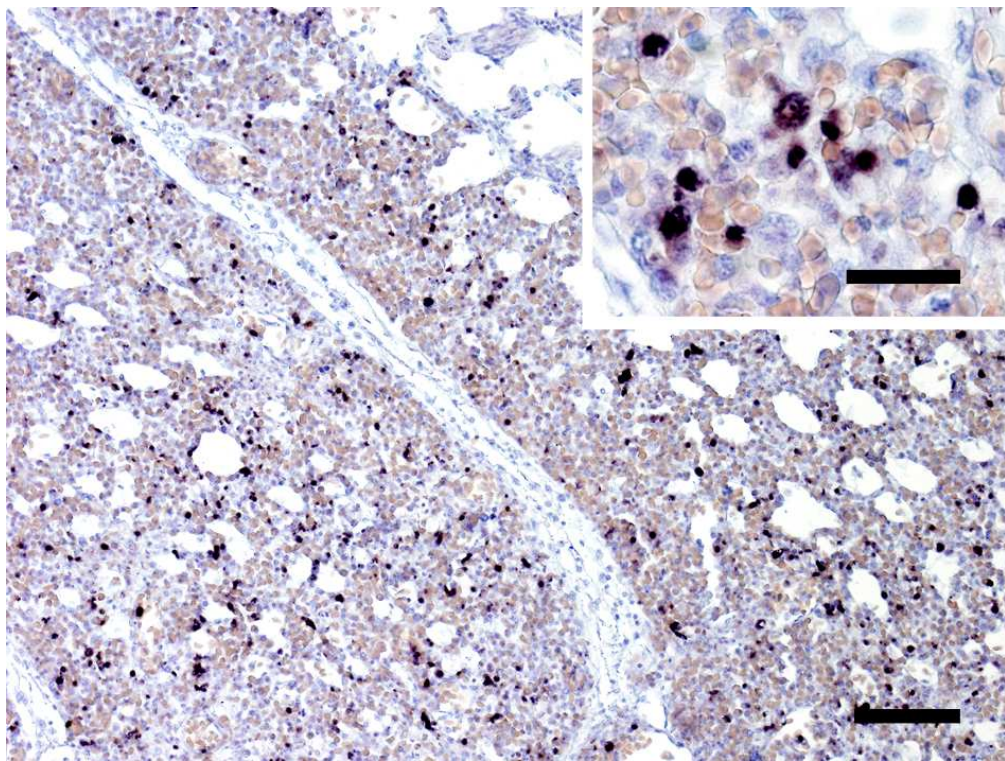
80x60mm (300 x 300 DPI)

View Only



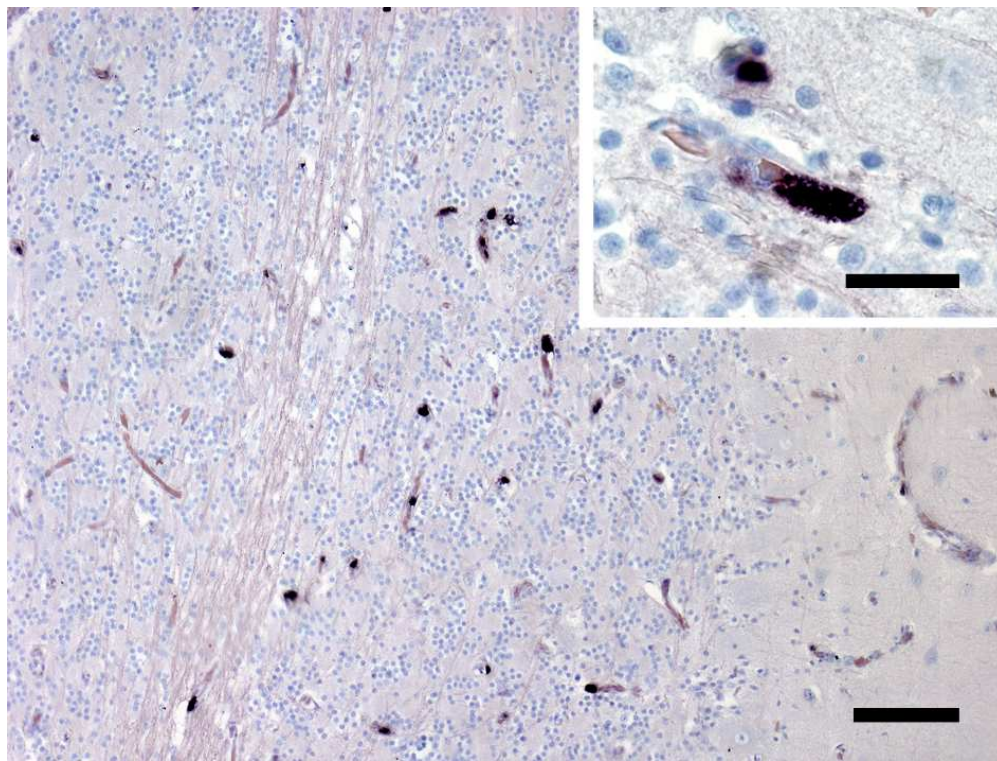
80x60mm (300 x 300 DPI)

View Only



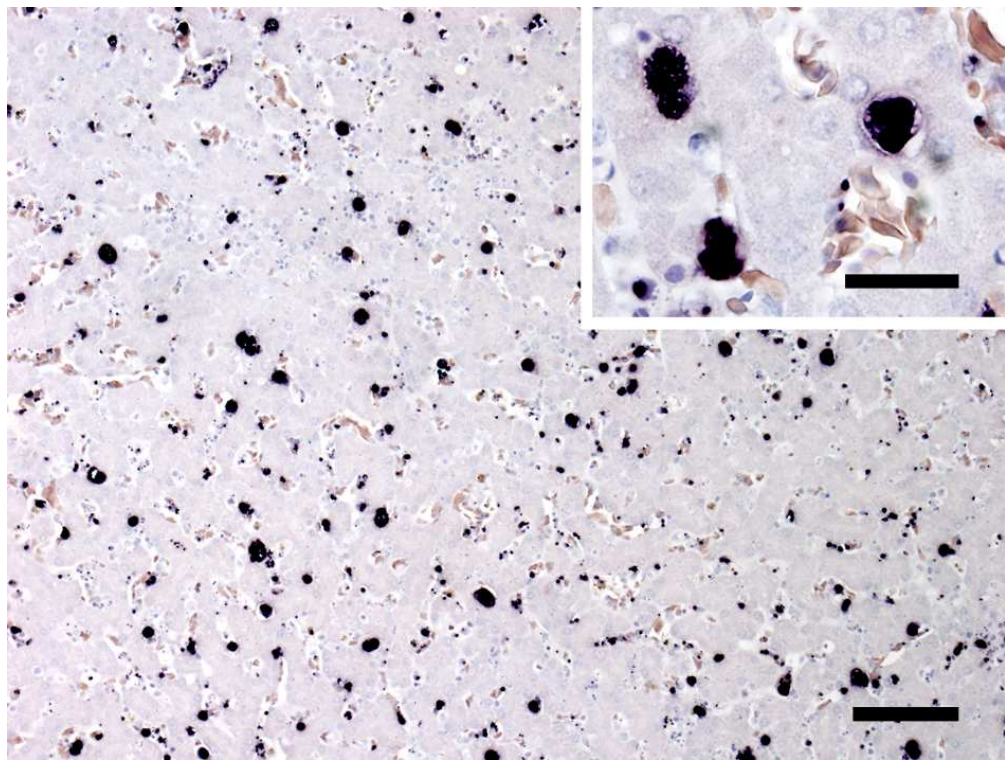
80x60mm (300 x 300 DPI)

ew Only



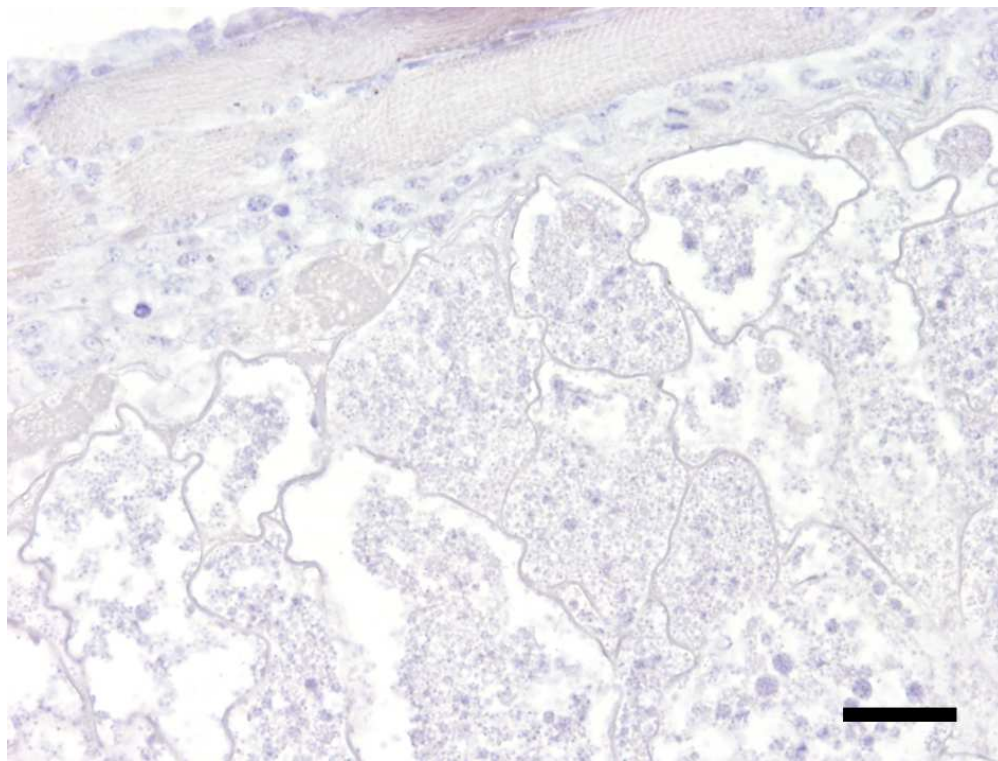
80x60mm (300 x 300 DPI)

View Only



80x60mm (300 x 300 DPI)

View Only



80x60mm (300 x 300 DPI)

View Only