HAL
open science

Pathobiology of Heterakis gallinarum mono- and co-infection with Histomonas meleagridis in layer chicken

Anna Schwarz, Matthias Gauly, Hansjörg Abel, Gürbüz Das, Julia Humburg, Weiss Th. A. Alexander, Gerhard Breves, Silke Rautenschlein

To cite this version:

Anna Schwarz, Matthias Gauly, Hansjörg Abel, Gürbüz Das, Julia Humburg, et al.. Pathobiology of Heterakis gallinarum mono- and co-infection with Histomonas meleagridis in layer chicken. Avian Pathology, 2011, 40 (03), pp.277-287. 10.1080/03079457.2011.561280 . hal-00710042

HAL Id: hal-00710042

https://hal.science/hal-00710042v1

Submitted on 20 Jun 2012

HAL is a multi-disciplinary open access archive for the deposit and dissemination of scientific research documents, whether they are published or not. The documents may come from teaching and research institutions in France or abroad, or from public or private research centers.

L'archive ouverte pluridisciplinaire **HAL**, est destinée au dépôt et à la diffusion de documents scientifiques de niveau recherche, publiés ou non, émanant des établissements d'enseignement et de recherche français ou étrangers, des laboratoires publics ou privés.

Pathobiology of Heterakis gallinarum mono- and co-infection with Histomonas meleagridis in layer chicken

Journal:	*Avian Pathology*
Manuscript ID:	CAVP-2010-0146.R1
Manuscript Type:	Original Research Paper
Date Submitted by the Author:	18-Nov-2010
Complete List of Authors:	Schwarz, Anna; Clinic for Poultry, University of Veterinary Medicine Hannover Gauly, Matthias; Department of Animal Sciences, University of Göttingen Abel, Hansjörg; Department of Animal Sciences, University of Göttingen Das, Gürbüz; Department of Animal Sciences, University of Göttingen Humburg, Julia; Department of Animal Sciences, University of Göttingen Alexander, Weiss; Department of Veterinary Pathology, Freie Universität Berlin Breves, Gerhard; Department of Physiology, University of Veterinary Medicine Hannover Rautenschlein, Silke; University of Veterinary Medicine Hannover, Clinic for Poultry
Keywords:	Heterakis gallinarum, Histomonas meleagridis, chicken, gut immunity

SCHOLARONE™
Manuscripts

For Peer Review Only

Cavp-2010-0146.R1

Pathobiology of *Heterakis gallinarum* mono- and co-infection with *Histomonas meleagridis* in layer chickens

Anna Schwarz[1], Matthias Gauly[2], Hansjörg Abel[3], Gürbüz Daş[2], Julia Humburg[3], Alexander Th. A. Weiss[5], Gerhard Breves[4], Silke Rautenschlein[1]*

[1]University of Veterinary Medicine Hannover, Clinic for Poultry, Bünteweg 17, 30559 Hannover, Germany, [2]University of Goettingen, Department of Animal Sciences, Albrecht Thaer Weg 3, 37075 Goettingen, Germany, [3]Department of Animal Sciences, University of Göttingen, Kellnerweg 6- 37077 Göttingen, Germany, [4]University of Veterinary Medicine Hannover, Institute for Physiology, Bischofsholer Damm 15, 30173 Hannover, Germany, [5]Freie Universitaet Berlin, Department of Veterinary Pathology, Robert-von-Ostertag-Str. 15, 14163 Germany

For Peer Review Only

Short title: *H. gallinarum* infection in chickens

*To whom correspondence should be addressed. Tel: +49 511 9538763. Fax: ++49 511 9538580. E-mail: silke.rautenschlein@tiho-hannover.de

Received: 18 November 2010

Abstract

Little is known about the induction and modulation of gut-associated immune reactions after nematode infection in the chicken. The objective of this study was to compare the pathogenesis, induction of immune reactions and electrophysiological changes of the gut after mono-infection with *Heterakis gallinarum* and after dual infection with and *Histomonas* in layer chickens. In two experiments three-week old chickens were inoculated with embryonated *H. gallinarum* eggs, which were positive for *H. meleagridis*. While birds of the first experiment were left untreated, those of the second experiment were treated with dimetridazol to prevent *H. meleagridis* co-infection. Mild to moderate histological lesions and local immune reactions with a significant increase in CD4+, CD8α+, TCRαβ+ and TCRδγ+ cells in the lamina propria and induction of the Th2- cytokine IL-13 dominated the *H. gallinarum* immune response at two weeks post infection (pi). Co-infection with *H. gallinarum* and *H. meleagridis* induced an increase in mRNA expression of the Th1 cytokine IFN-γ, a decrease in splenic CD4+ cells and severe destruction of the caecal mucosa in association with strong T cell infiltration in the caecal lamina propria. There was no obvious effect on the chloride secretion of the caecal epithelium, which was investigated once the mucosa had almost recovered from the infection, in either experiment. These results suggest that the local T cell reactions to nematode infections in chickens may be comparable to mammals and may be shifted from a Th2 to a Th1 dominated response when accompanied by a protozoan infection.

For Peer Review Only

Introduction

Due to changes in the legal requirements for housing of layer chickens a shift from cage to alternative production systems is occurring in European countries. This shift to more housing on litter and free-range production has led to the re-emergence of parasitic infections, such as infection with *Heterakis gallinarum* (Permin *et al.*, 1999; Maurer *et al.*, 2009). *H. gallinarum* is one of the most frequently diagnosed nematode within the digestive tract of galliform birds (Lund *et al.*, 1970). Infection with *H. gallinarum* is generally subclinical, but the parasite may also function as a vector for *Histomonas meleagridis*, which is known to induce severe pathological lesions in the gut and liver and leads to high mortality rates in susceptible hosts (Gibbs, 1962; Springer *et al.*, 1969; Lund & Chute, 1974; Esquenet *et al.*, 2003). In contrast to the turkey, histomoniasis in the chicken is known to show a high morbidity but low mortality (McDougald, 2005). Direct transmission of *H. meleagridis* has not been demonstrated for chickens in some studies (Hu *et al.*, 2006) or may occur at lower rates than observed in turkeys (Hess *et al.*, 2006). This emphasises the importance of *H. gallinarum* as a vector for *H. meleagridis* in chickens.

Although many studies have investigated the prevalence of *H. gallinarum* in the chicken (Kurt & Acici, 2008; Mungube *et al.*, 2008; Maurer *et al.*, 2009) and the induction of pathological lesions after *H. gallinarum* infection (Kaushik & Deorani, 1969; Riddell & Gajadhar, 1988), no information is available on specific gut-associated immune reactions following the infection. A variety of studies in mammalian species demonstrated the importance of cell-mediated immune reactions in the clearance of nematode infection. The Th2 immune response is especially dominant following a nematode infection (Dawson *et al.*, 2005; Little *et al.*, 2005; Scales *et al.*, 2007). In mice it has been shown that local activation of T cells may play a role in the expulsion of the caecal nematode *Trichuris muris*. In resistant mice, which develop a Th2 response, the number of infiltrating CD4+ and CD8+ cells in the

For Peer Review Only

epithelium and lamina propria of the gut was highest at the time of worm expulsion (Little *et al.*, 2005). Increased numbers of T cells, particularly CD4+ and TCR γδ+ lymphocytes were observed in the abomasal mucosa of goats following primary infection with *Haemonchus contortus* (Perez *et al.*, 2008). The few studies on *Ascaridia galli* infection in chickens demonstrated the systemic and local increase in IL-4 and IL-13 mRNA expression in splenic and ileal tissues (Degen *et al.*, 2005; Kaiser, 2007) and induction of circulating IgG antibodies starting two to three weeks pi (Marcos-Atxutegi *et al.*, 2009).

With regard to the caeca as the major site of *H. gallinarum* and *H. meleagridis* infection it may be hypothesized that the secretory response might also be affected by the infection. Pigs infected with *Oesophagostomum dentatum* showed, depending on the parasite stage, alterations in chloride secretion (Leonhard-Marek & Daugschies, 1997), which in turn is correlated to the water content of digesta (Leonhard-Marek *et al.*, 2009). Significant increase in Cl^- secretion in response to histamine during the period of self-healing was also observed in *Ascaris suum*-infected pigs suggesting a net rise in fluid in the intestinal lumen at this stage (Dawson *et al.*, 2005).

At present, the use of many effective antihelmintic drugs is prohibited or restricted due to consumer safety reasons. New ways to influence chicken health by feed additives are under investigation (Owens *et al.*, 2008; Mountzouris *et al.*, 2009; Solis de los Santos *et al.*, 2009). It was shown in different mammalian models that non-starch polysaccharides (NSP) may have a beneficial effect on systemic and local immune functions and general performance of the animal (Kelly-Quagliana, 2003; Roller *et al.*, 2004; Seifert & Watzl, 2007). Inulin-fed rats showed an increased proportion of dendritic cells in the Peyer's patches and higher *ex vivo* secretion of IL-2, IL-10 and IFN-γ in spleen and mesenteric lymph node cell cultures (Ryz *et al.*, 2008). Furthermore, NSP influenced the course of intestinal nematode infection in mammalian species (Petkevicius *et al.*, 1997; Pearce, 1999; Petkevicius *et al.*, 2001; Petkevicius *et al.*, 2003; Petkevicius *et al.*, 2007). There is no information available on the

For Peer Review Only

influence of NSP on gut immunity, nematode infection and electrophysiological parameters in chickens.

The objective of this study was to investigate immunological and electrophysiological parameters of the intestine of layer chickens in response to experimental infection with the nematode *H. gallinarum.* In addition, we characterised the influence of a co-infection of *H. gallinarum* and *H. meleagridis* on these parameters, as well as the impact of NSP on the outcome of the infections.

For Peer Review Only

Materials and Methods

Chickens. One day old female Lohmann Selected Leghorn (LSL) chickens were obtained from Lohmann Animal Breeding GmbH, Cuxhaven, Germany. They were housed in two isolation rooms; infected and non-infected groups were kept separately. They were divided randomly into three separate groups within each room and kept according to the regulations laid down for Animal Welfare. Water and feed was offered *ad libitum*. No vaccination programme was applied.

H. gallinarum. The adult female worms were collected from infected chickens, which had been obtained from different farms. The collected worm eggs were positive for *Histomonas meleagridis*. After incubation of the eggs in 0.5% (w/v) formalin for 3 weeks at room temperature the embryonated eggs were stored at 4°C for one to eight months until inoculation.

Diets. Animals of the non-infected and infected groups were allotted to one of three different diets: control feed; control feed containing 9.1% of pea bran meal as a source of insoluble

non-starch polysaccharides (NSP); control feed containing 9.1% of chicory root meal as a source of soluble NSP. The diets were offered in pelleted form. The percentages of the ingredients and the analysis of the diets are given in Table 1.

Haematoxylin & eosin staining and histopathology. Samples of distal caecum were fixed for 24 h in 4% phosphate-buffered formalin and then processed for histopathological examination by standard methods after haematoxylin and eosin (H&E) staining. The H&E-stained tissue sections were examined by light microscopy for lesions such as epithelial erosion and ulceration, lymphocyte and heterophil infiltration and cell aggregation as well as accumulation of fibrinoous exudate in the lumen.

Flow cytometric analysis. Single cell suspensions of spleen leukocytes were prepared using a slight modification to the method described by Liman & Rautenschlein (2007). The combination of the following antibodies was used to detect splenic T cells: mouse-anti-chicken-CD4 and -CD8α antibodies (Experiment 1 & 2) (Chan *et al.*, 1988) and mouse-anti-chicken-TCRαβ ($V\beta_1$) and -TCRγδ antibodies (Experiment 2) (Chen *et al.*, 1988), conjugated to phycoerythrin (R-PE) and to fluorescein (FITC), respectively (Southern Biotech, provided by Biozol, Eching, Germany). The antibodies were diluted in FACS buffer to a final concentration of 0.5 µg (anti-CD4), 0.8 µg (anti-CD8α), 2 µg (anti-TCRαβ ($V\beta_1$)) and 5 µg (anti-TCRγδ) per ml. The percentage of stained cells was determined using a Beckman Coulter Epics XL© flow cytometer and EXPO 32 ADC software program (Beckman Coulter Company, Miami, Florida). The lymphocyte population was gated according to size and granularity, and 10,000 events per sample were analysed based on positive staining with FITC and R-PE.

For Peer Review Only

Immunohistochemistry. Cryostat sections of distal caeca (8-µm thick) were processed as described previously (Vervelde *et al.*, 1996; Berndt *et al.*, 2007). Sections were stained with the following mouse-anti-chicken unlabeled monoclonal antibodies: anti-CD4, anti-CD8α, anti-TCRαβ ($V\beta_1$), anti-TCRγδ (at 0.5 µg/ml each) and anti-IgA (0.05 µg/ml) (Southern Biotech, provided by Biozol). The secondary anti-mouse IgG biotinylated antibody, ABC reagent (Vectastain® Elite® ABC Kit,Vector Laboratories Inc.) and the 3,3´-diaminobenzidine (DAB) peroxidase substrate Kit (Vector Laboratories Inc.) were used according to the manufacturer's instructions. The different lymphocyte populations in the caecal lamina propria were evaluated semi-quantitatively using the abundance score (Figure 3).

Real-time quantitative RT-PCR. Total RNA was isolated from distal caecum with 1000 µl TrifastGOLD (Peqlab, Erlangen, Germany) per sample according to the manufacturer's instructions.

Cytokine mRNA expression levels were quantified using TaqMan quantitative RT-PCR. Details of specific primers, cloning primers and probes are provided in Table 2 (Rautenschlein *et al.*, 2007; Powell *et al.*, 2009). Real-time quantitative RT-PCR was performed using the Brilliant® II QRT-PCR one-step master mix kit (STRATAGENE, Agilent Technologies Company, USA). Amplification and quantification of specific products was done using the Mx3005P™ thermal cycle system and Mx3005P™ Q PCR Software (STRATAGENE, Agilent Technologies Company). The following cycle profile was applied: one cycle at 50°C for 30 min and 95°C for 10 min, and 40 cycles at 95°C for 20 s and 60°C for 1 min. Results are expressed as x-fold change in mRNA expression levels in the tissues of inoculated birds compared to non-inoculated controls. The differences in template RNA levels of individual transcripts were normalised to 28S rRNA as previously described (Powell *et al.*, 2009). Expression levels of 28S rRNA stayed constant in the tissues of inoculated and non-inoculated animals showing the same threshold cycle values (C_t) throughout both

For Peer Review Only

experiments. GADPH was tested as an additional house-keeping gene (Rautenschlein *et al.*, 2007) but its expression levels in the caecal samples were not as stable as the expression level of 28S rRNA. In order to generate standard curves the target gene segment of chicken IFN-γ was cloned into the pCR3.1 vector (Invitrogen, Germany) (Rautenschlein *et al.*, 2007) and target gene segments of chicken IL-4 and IL-13 – into the pCR®4-TOPO® vector (Invitrogen) following standard procedures.

Electrophysiological measurements. After removing the tunica serosa the segments of the distal caecum were mounted in Ussing chambers with the exposed area of 1 cm^2. The standard buffer solutions contained (mmol/l): NaCl 113.6; KCl 5.4; $CaCl_2.2H_2O$ 1.2; $MgCl_2.6H_2O$ 1.2; $Na_2HPO_4.2H_2O$ 1.2; $NaH_2PO_4.H_2O$ 0.3; $NaHCO_3$ 21.0; glucose 10.0; HCl 0.4 and mannitol 23.0 at the serosal side, and NaCl 113.6; KCl 5.4; $CaCl_2.2H_2O$ 1.2; $MgCl_2.6H_2O$ 1.2; $Na_2HPO_4.2H_2O$ 1.2; $NaH_2PO_4.H_2O$ 0.3; $NaHCO_3$ 21.0; HCl 0.4 and mannitol 31.96 at the mucosal side of the tissues. All chemicals were obtained from Merck KG, Darmstadt, Germany. The buffer solutions had an osmolarity of 300 mosmol/l and pH of 7.45, when aerated with carbogen at 37 °C. To reduce endogenous production of prostaglandin the buffers were supplemented with Indomethacin (10 µmol/l). Short-circuit currents (Isc) and transepithelial tissue conductances (Gt) were measured using a computer-controlled voltage-clamp device (Mußler Ingenieurbüro für Mess- und Datentechnik, Aachen, Germany). Gt were determined by applying a current pulse of 100 µA for 200 ms every 6 s. The following chemicals were added to the chambers with recovery intervals of 20-30 min: amiloride (0.1 mmol/l) in combination with tetraethylammonium (TEA) (5 mmol/l) and Ba^{2+} (1mmol/l) mucosal to inhibit apical Na^+ and K^+ channels; Carbachol (0.1 mmol/l) and Forskolin (0.01 mmol/l) serosal as stimulators of the chloride secretion, 4,4´-diisothiocyanostilbene-2,2´-disulfonic acid (DIDS) (0.2 mmol/l) mucosal to inhibit alternative chloride channels and 5-nitro-2-(3-phenylpropylamino) benzoate (NPPB) (0.5 mmol/l) serosal

For Peer Review Only

as an inhibitor of the cystic fibrosis transmembrane conductance regulator (CFTR) channel. The substances, with the exception of Ba^{2+} (Merck KG, Darmstadt, Germany), were obtained from Sigma-Aldrich Chemicals, St. Louis, MO, USA. Three caecal segments from each bird in Experiment 1 and two segments from each bird in Experiment 2 were used. The electrical responses were measured as a difference of an average of two to three basal values before and two to three values after reaching the maximal response to the application of the respective substance.

Experimental protocol. Experiment 1. One hundred and twenty animals were divided randomly into three groups of 40. The groups were kept on control diets or diets containing 9.1% of soluble or insoluble NSP. At 3 weeks of age 20 birds per group were selected randomly and inoculated orally with 200 embryonated *H. gallinarum* eggs that were positive for *H. meleagridis.* Throughout the experiments clinical examinations were carried out daily and of body weight gain was measured weekly. Necropsy was carried out 2, 3 and 5 weeks post infection (pi). Four to five birds chosen at random from each subgroup were necropsied and examined for pathological lesions. Samples of distal caecum were taken for histo-pathological and immunohistochemical examination and spleen samples for flow cytometric analysis. Distal caecal tissue of three birds per inoculated and non-inoculated group allotted to control diet was taken for quantification of cytokine mRNA expression levels by quantitative RT-PCR. On the last necropsy day parasite numbers from one caecum per animal were counted and the faeces of the birds were examined for the presence of *H. gallinarum* eggs. For electrophysiological measurements four to five birds chosen at random per diet and infection group were necropsied at five weeks pi, and samples of distal caeca were analysed in the Ussing chamber.

For Peer Review Only

Experiment 2. The birds were treated prophylactically via the drinking water with dimetridazole (0.05% w/v) (Chevi-col, Chevita GmbH, Germany) against infection with *H. meleagridis* from two days before inoculation until day 7 post inoculation with *H. gallinarum* embryonated eggs. The experimental setup was identical to Experiment 1 except that caecal samples for immunohistochemical examination were only taken 2 and 5 weeks pi, and at 9 weeks pi, a total of 30 animals (five birds chosen at random from each subgroup) were necropsied for electrophysiological measurements.

Statistical methods. All data are expressed as mean per group ± standard deviation (SD). The differences between groups were determined by paired t-test and Wilcoxon Rank Sum Test. The effects of diets and infection as two independent factors were investigated by two-way ANOVA. *P* values of <0.05 were considered as significant. The statistical analyses were performed using the SAS® 9.1 programme.

Results

Influence of diet on performance, lesion development and immune parameters. No difference was seen between the feeding groups with regard to clinical signs, pathological and histopathological lesions or local and systemic immune reactions. Therefore, for the evaluation of these parameters the three different feeding groups were treated as replicates and combined to one inoculated and non-inoculated animal group.

Clinical and post-mortem observations. In Experiment 1 birds in the dual-infected group showed mild clinical signs such as depression and ruffled feathers beginning at one week pi. The mortality throughout this experiment was 0.8% - one bird died on day 13 pi. In

For Peer Review Only

Experiment 2 animals treated prophylactically with dimetridazol (0.05% w/v) against *H. meleagridis* co-infection showed no clinical signs or mortality. Dual-infected birds in Experiment 1 showed a significant reduction in body weight beginning at two weeks pi until the end of the trial ($P < 0.05$), while in Experiment 2 a significant drop in body weight was only observed at 2 weeks pi ($P < 0.05$) (data not shown).

Pathological examination of dual-infected birds in Experiment 1 showed formation of fibrinous to fibrino-hemorrhagic exudates in caecal lumen of 14 out of 15 inoculated chickens at 2 and 3 weeks pi (Table 3). One to three focal hepatic necrotic areas were found in six out of 15 birds 2 weeks pi. At 5 weeks pi only one bird out of 15 showed macroscopic lesions in the caeca. No pathological lesions were observed in *H. gallinarum* mono-infected birds in Experiment 2 (Table 3).

The infection rate for *H. gallinarum* (% of worm-positive birds out of inoculated birds) was 13% in the dual-infected group in Experiment 1 and 93% in the mono-infected group in Experiment 2. No faeces sample of inoculated birds in Experiment 1 and 33% of the faeces samples of inoculated birds in Experiment 2 were positive for *H. gallinarum* eggs at 5 weeks pi (Table 3). In Experiment 1 the average number of *H. gallinarum* worms per bird detected in caeca at 5 weeks pi was 0.33 (min 0 and max three worms) and in Experiment 2 was 12.1 (min 0 and max 37 worms).

Non-inoculated birds showed no clinical signs or pathological lesions and were worm-negative in both experiments.

Histopathology. The development and incidence of histopathological lesions after inoculation of the chickens with embryonated *H. gallinarum* eggs are shown in Table 3. In the case of *H. meleagridis* co-infection severe interstitial lymphocyte, heterophil and macrophage infiltration, complete ulceration of intestinal epithelium and accumulation of fibrin exudates and detritus in the lumen of caeca was observed in 93% (14 of 15) of

For Peer Review Only

inoculated birds 2 weeks pi (Figure 1b, Experiment 1). Numerous histomonads and moderate numbers of bacterial colonies were found in the severely hyperplasic tunica muscularis. Three weeks pi, all inoculated birds still showed histopathological lesions. The structure of the mucosa showed reorganisation and re-epithelisation and still contained severe lymphocyte and heterophil infiltration in the lamina propria (Figure 1c, d). Five weeks pi, 93% (14 of 15) of inoculated birds showed moderate lymphocyte infiltration in the lamina propria and formation of lymphoid centers in cecal mucosa (Figure 1e).

Mono-infection with *H. gallinarum* (Experiment 2) resulted in mild to moderate lymphocyte infiltration of the lamina propria and formation of lymphoid aggregations. Bacterial colonies were not observed. Two, 3 and 5 weeks pi 93%, 86%, 80% of inoculated chickens showed the indicated microscopic lesions, respectively (Figure 1f), while the remaining birds were free of detectable histopathological changes.

No microscopic lesions were observed in the non-inoculated groups of either experiment (Figure 1a).

Changes in local lymphocyte populations. Different T cell subsets were investigated immunohistochemically in the lamina propria of the caeca of control and inoculated birds (Figure 2, 3). For the semi-quantitative evaluation we used an abundance score based on the incidence of positive stained cells in the caecal mucosa and on the changes in the tissue structure due to the infection (Figure 2). The changes in local T lymphocyte populations were comparable for the different T cell subtypes in each experiment (Figure 3). Dual-infected birds (Experiment 1) showed severe T lymphocyte infiltration in the lamina propria (Figure 2e, f). The increase in the abundance score of CD4+, CD8α+, TCRαβ ($V\beta_1$)+ and TCRγδ+ T cells in the gut-mucosa 2 weeks pi was 5- to 6-fold compared to non-inoculated animals (Figure 3, $P < 0.05$). Mono-infected birds (Experiment 2) reacted with mild to moderate T lymphocyte infiltration in the caecal lamina propria 2 weeks pi (Figure 2b, c). The abundance

For Peer Review Only

score increase was 2- to 3- fold in infected birds compared to non-inoculated animals (Figure 3, $P< 0.05$). Three to 5 weeks pi, dual-infected birds (Experiment 1) showed moderate to severe CD4+, CD8α+, TCRαβ ($V\beta_1$)+ and TCRγδ+ T-cells infiltration (Figure 2c, d, Figure 3 , $P< 0.05$). Five weeks pi, animals in Experiment 2 showed a small increase in the abundance score that was only significant for CD4+, CD8α+ and TCRγδ+ T-lymphocytes (Figure 3, $P< 0.05$).

Following *H. gallinarum* and *H. meleagridis* co-infection, no IgA+ B lymphocytes were detected in the destroyed caecal mucosa 2 weeks pi (Experiment 1). Five weeks pi, there were no differences in the abundance score of IgA+ cells between control and inoculated birds, when the mucosal structure was almost restored. No changes in IgA+ B cell populations were observed between mono-infected and parasite-free birds in Experiment 2 (data not shown).

Flow cytometric analysis of splenic lymphocyte populations. Co-infection of *H. gallinarum* and *H. meleagridis* induced a significant decrease in the relative number of CD4+ splenic T lymphocytes at 2 weeks pi but not at 3 and 5 weeks pi in comparison to non-inoculated layers (Experiment 1), (Figure 4, $P< 0.05$). In the case of dimetridazol treated birds no changes in the relative number of splenic CD4+ cell were detected compared to worm free controls (Experiment 2, Figure 4). No differences were seen in the percentages of splenic CD8α+ (Experiment1 & 2) and TCRαβ ($V\beta_1$)+ and TCRγδ+ (Experiment 2) T lymphocyte populations between infected and parasite-free birds.

Detection of IFN-γ, IL-4 and IL-13 cytokine mRNA expression levels by real-time quantitative RT-PCR. Dual infection with *H. gallinarum* and *H. meleagridis* (Experiment 1) induced a statistically significant increase in IFN-γ mRNA expression in the caeca of inoculated birds in comparison to non-inoculated controls at 2 weeks pi (Figure 5a, $P< 0.05$).

For Peer Review Only

The changes in IL-4 and IL-13 cytokine mRNA expression were not significantly different compared to the control group in this experiment (P>0.05). Mono-infection with *H. gallinarum* (Experiment 2) resulted in a statistically significant increase in IL-13 mRNA expression 2 weeks pi in inoculated birds compared to worm-free controls (Figure 5c, P< 0.05). The changes in IFN-γ and IL-4 mRNA expression in *H. gallinarum* mono-infected birds were not significantly different compared to the worm free control group.

Electrophysiological measurements. The maximal changes in short-circuit currents in caeca of *H. gallinarum* and *H. meleagridis* co-infected birds (Experiment 1) and *H. gallinarum* mono-infected birds (Experiment 2) in response to the addition of carbachol, forskolin and NPPB are shown in Figure 6. Mono-infected birds (Experiment 2) showed responses to carbachol and forskolin, whereas no significant effect of the infection or the diet was seen in dually infected birds (Experiment 1). Both substances induced a significantly lower increase in the maximal Isc response in mono-infected birds compared to non-inoculated birds (Experiment 2) when insoluble NSP were fed (Figure 6a, b, P< 0.05). Forskolin also induced smaller maximal Isc responses in non-inoculated birds fed with soluble NSP than in non-inoculated birds fed with insoluble NSP. Moreover, forskolin caused lower short-circuit current responses in inoculated birds fed with soluble NSP than in inoculated birds receiving control feed (Figure 6b, P< 0.05). NPPB addition resulted in decreases in Isc in all birds. Dual infection of *H. gallinarum* and *H. meleagridis* (Experiment 1) induced a significantly smaller decrease in the maximal Isc responses in inoculated compared to non-inoculated birds when fed insoluble NSP. Mono-infection with *H. gallinarum* (Experiment 2) led to smaller Isc decreases in tissues of inoculated birds fed soluble or insoluble NSP instead of control diet. Maximal Isc response was also less pronounced in non-inoculated birds fed with soluble NSP compared to non-inoculated birds receiving insoluble NSP (Figure 6c, P< 0.05). DIDS had no effect on Isc response in both experiments (data not shown).

For Peer Review Only

Discussion

Mucosal immunity and the secretory response of the intestine play an important role in the control of parasitic intestinal infections (Khan & Collins, 2004). In this study we investigated for the first time the gut-associated immune parameters and secretory responses of caeca in layer chickens in the light of different diets following mono-infection with *H. gallinarum* and dual infection with *H. gallinarum* and *H. meleagridis*

While NSP showed immunomodulatory effects in the T cell compartment in mammalian species (Lim *et al.*, 1997; Trushina *et al.*, 2005; Watzl *et al.*, 2005), we did not observe any NSP-influence on the splenic and caecal T cell numbers in worm-free or in nematode-infected birds at the points investigated. In broiler chickens fructo-oligosaccharide enhanced IgG antibody titres in plasma and reduced the proportion of B cells but did not affect the percentage of T cells in caecal tonsils (Janardhana *et al.*, 2009). It may be speculated that splenic and gut T cell populations in the layer chicken are not influenced by NSP, but further studies investigating other immune parameters are needed to support our findings.

Previous studies on nematode infection in mammals showed that T cells are attracted locally to the site of infection (Almeria *et al.*, 1997; Bozic *et al.*, 2000; Balic *et al.*, 2002; Perez *et al.*, 2008). It was suggested that T lymphocytes, especially CD4+ cells, may play a significant role in resistance to worm infection (Betts *et al.*, 2000; Khan & Collins, 2004; Little *et al.*, 2005; Rausch *et al.*, 2008; Patel *et al.*, 2009). In this study we demonstrated for the first time that, similar to mammals, *H. gallinarum* infection in chickens also leads to recruitment of T lymphocytes to the intestinal mucosa. In our experiments the local accumulation of immune cells in the caecal lamina propria was most pronounced 2 weeks pi for both mono- and dual-infected birds. The observed increase in CD4+, CD8α+, TCRαβ ($V\beta_1$)+ and TCRγδ+ T cell subpopulation was similar for subsets within each experiment. Co-

For Peer Review Only

infection of *H. gallinarum* and *H. meleagridis* resulted in a significantly higher T cell infiltration rate compared to mono-infection with *H. gallinarum*, which may be due to a higher invasiveness of the protozoan parasite (Brener *et al.*, 2006).

Flow cytometric analysis of splenic T lymphocyte population revealed a significant decrease in CD4+ T cells in dual-infected birds at 2 weeks pi. This effect was not detected for splenic CD8α+ lymphocytes. This observation may suggest a significant role of CD4+ cells in *H. meleagridis* infection, as previously reported for other protozoan parasites (Vervelde *et al.*, 1996; Yun *et al.*, 2000) and provide evidence of an increased intestinal recruitment of CD4+cells to the caecal lamina propria (Taylor *et al.*, 2009). Mono-infection with *H. gallinarum* did not cause any changes in the percentage of splenic T lymphocytes, which suggests that, in contrast to high invasive intestinal nematodes (Dondji *et al.*, 2008; Dondji *et al.*, 2010), the immune response following *H. gallinarum* infection is mainly localised in the gut.

Analysis of T helper (Th)1 and Th2 cytokine mRNA expression in caecal tissues demonstrated an increase in IFN-γ mRNA level in dually infected birds and an increase in IL-13 mRNA level in mono-infected birds compared to worm-free animals. Our data suggest that mono-infection with *H. gallinarum* elicit local Th2 type immune reactions in the caecal lamina propria as was shown for nematode infections in mammals (Dawson *et al.*, 2005; Patel *et al.*, 2009). Following *H. gallinarum* and *H. meleagridis* co-infection the local immunological reactions are dominated by *H. meleagridis* with induction of Th1 type cytokines comparable to the effect reported for other protozoan infections (Lillehoj, 1998; Yun *et al.*, 2000; Hong *et al.*, 2006).

Previous studies in mammals have demonstrated that nematode infection influences secretory functions of intestine (Madden *et al.*, 2004; Dawson *et al.*, 2005). To study electrogenic Cl^- secretion in the caeca of chicken we used a modified protocol, which had been established for the diagnosis of cystic fibrosis in humans and for the characteristics of

For Peer Review Only

Cl^- secretion in mice and pigs. Changes in short-circuit current can be attributed to changes in Cl^- secretion after inhibition of the apical Na^+ and K^+ channels (De Jonge *et al.*, 2004; Bleich *et al.*, 2007; Leonhard-Marek *et al.*, 2009). Major chloride secretion in intestine epithelium takes place via the CFTR channel (Barrett & Keely, 2000). This channel can be stimulated in a Ca-dependent manner by carbachol or in a cAMP-dependent way by forskolin, and is inhibited by NPPB.

No obvious effects of the diet or infection were observed on electrogenic Cl^- secretion. Previous studies in rats showed significant decreases in Cl^- ion transport in the proximal jejunum after dietary supplementation with cellulose or pectin (Schwartz *et al.*, 1982). Our data did not reproduce this observation in caeca of chickens, where NSP fermentation takes place. Reduced caecal Cl^- secretion of mono-infected birds fed soluble NSP instead of the control diet suggests that soluble NSP in combination with nematode infection may reduce intestinal fluid. Reduced Cl^- secretion was also observed in *H. gallinarum* mono-infected animals fed with the insoluble NSP diet compared to non-inoculated birds. Experiments with pigs have shown that insoluble NSP benefit nematode infection (Petkevicius *et al.*, 1997; Petkevicius *et al.*, 2001). Reduction of intestinal fluid may be considered as a reaction of the host to a parasitic developmental stage. Pigs infected with *Oesophagostomum dentatum* showed higher Isc responses during the time of nematode penetration into the epithelium (high expulsion chances) and lower Isc responses at the histiotrophic phase (low expulsion chances) (Leonhard-Marek & Daugschies, 1997). It is also possible that nematodes modulate the activation of Cl^- channels by their excretory/secretory products to prevent expulsion.

The changes in electrogenic Cl^- secretion showed a similar pattern for mono- and dual-infected birds despite the high grade of destruction of caecal tissue in the course of *H. meleagridis* co-infection. We suggest that the secretory response of the intestine was not significantly affected by the co-infection at 5 weeks pi, when the intestinal epithelia had already largely recovered from pathological lesions, as shown histologically.

For Peer Review Only

In our experiments we observed clinical signs and pathological changes only in *H. gallinarum* and *H. meleagridis* co-infected chickens. The birds had completely recovered from clinical signs and most histological lesions by 5 weeks pi. This recovery is consistent with previous studies in chickens (Hess *et al.*, 2006; Powell *et al.*, 2009). Mono-infection with *H. gallinarum* induced only mild to moderate local histological reaction in the caecal lamina propria. Bacterial colonies, which were detected in the damaged mucosa of *H. meleagridis* infected birds, were absent. The absence of pathological lesions and detectable bacterial colonies in the caecal tissue may indicate the long-term adaptation of *H. gallinarum* in the chicken. Possibly, the dimetridazol treatment may also have affected the bacterial flora of the gut.

In our study *H. meleagridis* has clearly influenced the establishment of *H. gallinarum* infection in the caeca. Previously it had been demonstrated that chickens with pathological evidence of histomoniasis had lower numbers of *H. gallinarum* worms compared to those mono-infected with *H. gallinarum* (Lund, 1958; Lund, 1967). The low infection rate and the absence of *H. gallinarum* eggs observed in our experiments suggest that the severe inflammation induced by *H. meleagridis* may provide unfavourable conditions for the establishment of *H. gallinarum* and decelerate the development of the nematode.

In summary, local T cell immune reactions in the caecal lamina propria with induction of the Th2-type cytokine IL-13 dominate the *H. gallinarum* immunopathogenesis in chickens. NSP did not influence the gut-associated cellular immune response after *H. gallinarum* infection. Co-infection of *H. gallinarum* and *H. meleagridis* altered the local immune response and induced an increase in mRNA expression of the Th1-type cytokine IFN-γ, and elicited systemic immune reactions in the spleen. Furthermore, we did not observe obvious effects of the infection or different feed diets on the chloride secretion in intestinal epithelia.

With this study we have contributed to the understanding of immunological and electrophysiological responses of the chicken intestine following nematode infection.

For Peer Review Only

References

Almeria, S., Canals, A., Zarlenga, D.S. & Gasbarre, L.C. (1997). Isolation and phenotypic characterization of abomasal mucosal lymphocytes in the course of a primary *Ostertagia ostertagi* infection in calves. *Veterinary Immunology and Immunopathology, 57*, 87-98.

Bail, A., Bowles, V.M. & Meeusen, E.N. (2002). Mechanisms of immunity to *Haemonchus contortus* infection in sheep. *Parasite Immunology, 24*, 39-46.

Barrett, K. E. & Keely, S.J. (2000). Chloride secretion by the intestinal epithelium: molecular basis and regulatory aspects. *Annual Review of Physiology, 62*, 535-572.

Berndt, A., Wilhelm, A., Jugert, C., Pieper, J., Sachse, K. & Methner, U. (2007). Chicken cecum immune response to *Salmonella enterica* serovars of different levels of invasiveness. *Infection and Immunity, 75*, 5993-6007.

Betts, J., deSchoolmeester, M.L. & Else, K.J. (2000). *Trichuris muris*: CD4+ T cell-mediated protection in reconstituted SCID mice. *Parasitology, 121,* 631-637.

Bleich, E. M., Leonhard-Marek, S., Beyerbach, M. & Breves, G. (2007). Characterisation of chloride currents across the proximal colon in CftrTgH(neoim)1Hgu congenic mice. *Journal of Comparative Physiology B, 177*, 61-73.

Bozic, F., Marinculic, A. & Durakovic, E. (2000). Analysis of intestinal intraepithelial lymphocyte populations in experimental *Trichinella spiralis* infection of mice. *Folia Parasitologia (Praha), 47*, 55-59.

Brener, B., Tortelly, R., Menezes, R.C., Muniz-Pereira, L.C. & Pinto, R.M. (2006). Prevalence and pathology of the nematode *Heterakis gallinarum*, the trematode *Paratanaisia bragai*, and the protozoan *Histomonas meleagridis* in the turkey, *Meleagris gallopavo*. *Memórias do Instituto Oswaldo Cruz, 101*, 677-681.

For Peer Review Only

Chan, M.M., Chen, C.L., Ager, L.L. & Cooper, M.D. (1988). Identification of the avian homologues of mammalian CD4 and CD8 antigens. *Journal of Immunology, 140*, 2133-2138.

Chen, C.L., Cihak, J., Losch, U. & Cooper, M.D. (1988). Differential expression of two T cell receptors, TcR1 and TcR2, on chicken lymphocytes. *European Journal of Immunology, 18*, 539-543.

Dawson, H.D., Beshah, E., Nishi, S., Solano-Aguilar, G., Morimoto, M., Zhao, A., Madden, K.B., Ledbetter, T.K., Dubey, J.P., Shea-Donohue, T., Lunney, J.K. & Urban, J.F., Jr. (2005). Localized multigene expression patterns support an evolving Th1/Th2-like paradigm in response to infections with *Toxoplasma gondii* and *Ascaris suum*. *Infection and Immunity, 73*, 1116-1128.

De Jonge, H.R., Ballmann, M., Veeze, H., Bronsveld, I., Stanke, F., Tummler, B. & Sinaasappel, M. (2004). Ex vivo CF diagnosis by intestinal current measurements (ICM) in small aperture, circulating Ussing chambers. *Journal of Cystic Fibrosis, 3 Suppl 2*, 159-163.

Degen, W.G., Daal, N., Rothwell, L., Kaiser, P. & Schijns, V.E. (2005). Th1/Th2 polarization by viral and helminth infection in birds. *Veterinary Microbiology, 105*, 163-167.

Dondji, B., Bungiro, R.D., Harrison, L.M., Vermeire, J.J., Bifulco, C., McMahon-Pratt, D. & Cappello, M. (2008). Role for nitric oxide in hookworm-associated immune suppression. *Infection and Immunity, 76*, 2560-2567.

Dondji, B., Sun, T., Bungiro, R.D., Vermeire, J.J., Harrison, L.M., Bifulco, C. & Cappello, M. (2010). CD4 T cells mediate mucosal and systemic immune responses to experimental hookworm infection. *Parasite Immunology, 32*, 406-413.

Esquenet, C., De Herdt, P., De Bosschere, H., Ronsmans, S., Ducatelle, R. & Van Erum, J. (2003). An outbreak of histomoniasis in free-range layer hens. *Avian Pathology, 32*, 305-308.

For Peer Review Only

Gibbs, B.J. (1962). The occurrence of the protozoan parasite *Histomonas meleagridis* in the adults and eggs of the cecal worm *Heterakis gallinae*. *Journal of Protozoology, 9*, 288-293.

Hess, M., Grabensteiner, E. & Liebhart, D. (2006). Rapid transmission of the protozoan parasite *Histomonas meleagridis* in turkeys and specific pathogen free chickens following cloacal infection with a mono-eukaryotic culture. *Avian Pathology, 35*, 280-285.

Hong, Y.H., Lillehoj, H.S., Lillehoj, E.P. & Lee, S.H. (2006). Changes in immune-related gene expression and intestinal lymphocyte subpopulations following *Eimeria maxima* infection of chickens. *Veterinary Immunology and Immunopathology, 114*, 259-272.

Hu, J., Fuller, L., Armstrong, P.L. & McDougald, L.R. (2006). *Histomonas meleagridis* in chickens: attempted transmission in the absence of vectors. *Avian Diseases, 50*, 277-279.

Janardhana, V., Broadway, M.M., Bruce, M.P., Lowenthal, J.W., Geier, M.S., Hughes, R.J. & Bean, A.G. (2009). Prebiotics modulate immune responses in the gut-associated lymphoid tissue of chickens. *Journal of Nutrition, 139*, 1404-1409.

Kaiser, P. (2007). The avian immune genome - a glass half-full or half-empty? *Cytogenetic and Genome Research, 117*, 221-230.

Kaushik, R.K. & Deorani, V.P. (1969). Studies on tissue responses in primary and subsequent infections with *Heterakis gallinae* in chickens and on the process of formation of caecal nodules. *Journal of Helminthology, 43*, 69-78.

Kelly-Quagliana, N., Buddington (2003). Dietary oligofructose and inulin modulate immune functions in mice. *Nutrition Research, 23*, 257-267.

Khan, W.I. & Collins, S.M. (2004). Immune-mediated alteration in gut physiology and its role in host defence in nematode infection. *Parasite Immunology, 26*, 319-326.

Kurt, M. & Acici, M. (2008). Cross-sectional survey on helminth infections of chickens in the Samsun region, Turkey. *Deutsche Tierärztliche Wochenschrift, 115*, 239-242.

For Peer Review Only

Leonhard-Marek, S. & Daugschies, A. (1997). Electro- and transport-physiological changes in pig proximal colon during parasitic infection - neuronal and epithelial muscarinic responses. *Comparative Biochemistry and Physiology Part A Physiology, 118*, 345-347.

Leonhard-Marek, S., Hempe, J., Schroeder, B. & Breves, G. (2009). Electrophysiological characterization of chloride secretion across the jejunum and colon of pigs as affected by age and weaning. *Journal of Comparative Physiology B, 179*, 883-896.

Lillehoj, H.S. (1998). Role of T lymphocytes and cytokines in coccidiosis. *International Journal for Parasitology, 28*, 1071-1081.

Lim, B.O., Yamada, K., Nonaka, M., Kuramoto, Y., Hung, P. & Sugano, M. (1997). Dietary fibers modulate indices of intestinal immune function in rats. *Journal of Nutrition, 127*, 663-667.

Liman, M. & Rautenschlein, S. (2007). Induction of local and systemic immune reactions following infection of turkeys with avian Metapneumovirus (aMPV) subtypes A and B. *Veterinary Immunology and Immunopathology, 115*, 273-285.

Little, M.C., Bell, L.V., Cliffe, L.J. & Else, K.J. (2005). The characterization of intraepithelial lymphocytes, lamina propria leukocytes, and isolated lymphoid follicles in the large intestine of mice infected with the intestinal nematode parasite *Trichuris muris*. *Journal of Immunology, 175*, 6713-6722.

Lund, E.E. (1958). Growth and development of *Heterakis gallinae* in turkeys and chickens infected with *Histomonas meleagridis*. *Journal of Parasitology, 44*, 297-301.

Lund, E.E. (1967). Response of four breeds of chickens and one breed of turkeys to experimental *Heterakis* and *Histomonas* infections. *Avian Diseases, 11*, 491-502.

Lund, E.E., Chute, A.M. & Myers, S.L. (1970). Performance in chickens and turkeys of chicken-adapted *Heterakis gallinarum*. *Journal of Helminthology, 44*, 97-106.

Lund, E.E. & Chute, A.M. (1974). The reproductive potential of *Heterakis gallinarum* in various species of galliform birds: implications for survival of *H. gallinarum* and

For Peer Review Only

Histomonas meleagridis to recent times. *International Journal for Parasitology, 4*, 455-461.

Madden, K.B., Yeung, K.A., Zhao, A., Gause, W.C., Finkelman, F.D., Katona, I.M., Urban, J.F., Jr. & Shea-Donohue, T. (2004). Enteric nematodes induce stereotypic STAT6-dependent alterations in intestinal epithelial cell function. *Journal of Immunology, 172*, 5616-5621.

Marcos-Atxutegi, C., Gandolfi, B., Aranguena, T., Sepulveda, R., Arevalo, M. & Simon, F. (2009). Antibody and inflammatory responses in laying hens with experimental primary infections of *Ascaridia galli*. *Veterinary Parasitology, 161*, 69-75.

Maurer, V., Amsler, Z., Perler, E. & Heckendorn, F. (2009). Poultry litter as a source of gastrointestinal helminth infections. *Veterinary Parasitology, 161*, 255-260.

McDougald, L.R. (2005). Blackhead disease (histomoniasis) in poultry: a critical review. *Avian Diseases, 49*, 462-476.

Mountzouris, K.C., Balaskas, C., Xanthakos, I., Tzivinikou, A. & Fegeros, K. (2009). Effects of a multi-species probiotic on biomarkers of competitive exclusion efficacy in broilers challenged with *Salmonella enteritidis*. *British Poultry Science, 50*, 467-478.

Mungube, E.O., Bauni, S.M., Tenhagen, B.A., Wamae, L.W., Nzioka, S.M., Muhammed, L. & Nginyi, J.M. (2008). Prevalence of parasites of the local scavenging chickens in a selected semi-arid zone of Eastern Kenya. *Tropical Animal Health and Production, 40*, 101-109.

Owens, B., Tucker, L., Collins, M.A. & McCracken, K.J. (2008). Effects of different feed additives alone or in combination on broiler performance, gut microflora and ileal histology. *British Poultry Science, 49*, 202-212.

Patel, N., Kreider, T., Urban, J.F., Jr. & Gause, W.C. (2009). Characterisation of effector mechanisms at the host:parasite interface during the immune response to tissue-dwelling intestinal nematode parasites. *International Journal for Parasitology, 39*, 13-21.

For Peer Review Only

Pearce, G.P. (1999). Interactions between dietary fibre, endo-parasites and *Lawsonia intracellularis* bacteria in grower-finisher pigs. *Veterinary Parasitology, 87*, 51-61.

Perez, J., Zafra, R., Buffoni, L., Hernandez, S., Camara, S. & Martinez-Moreno, A. (2008). Cellular phenotypes in the abomasal mucosa and abomasal lymph nodes of goats infected with *Haemonchus contortus*. *Journal of Comparative Pathology, 138*, 102-107.

Permin, A., Bisgaard, M., Frandsen, F., Pearman, M., Kold, J. & Nansen, P. (1999). Prevalence of gastrointestinal helminths in different poultry production systems. *Britsh Poultry Science, 40*, 439-443.

Petkevicius, S., Knudsen, K. E., Nansen, P., Roepstorff, A., Skjoth, F. & Jensen, K. (1997). The impact of diets varying in carbohydrates resistant to endogenous enzymes and lignin on populations of *Ascaris suum* and *Oesophagostomum dentatum* in pigs. *Parasitology, 114*, 555-568.

Petkevicius, S., Knudsen, K.E., Nansen, P. & Murrell, K.D. (2001). The effect of dietary carbohydrates with different digestibility on the populations of *Oesophagostomum dentatum* in the intestinal tract of pigs. *Parasitology, 123*, 315-324.

Petkevicius, S., Bach Knudsen, K.E., Murrell, K. D. & Wachmann, H. (2003). The effect of inulin and sugar beet fibre on *Oesophagostomum dentatum* infection in pigs. *Parasitology, 127*, 61-68.

Petkevicius, S., Thomsen, L.E., Bach Knudsen, K.E., Murrell, K. ., Roepstorff, A. & Boes, J. (2007). The effect of inulin on new and on patent infections of *Trichuris suis* in growing pigs. *Parasitology, 134*, 121-127.

Powell, F.L., Rothwell, L., Clarkson, M.J. & Kaiser, P. (2009). The turkey, compared to the chicken, fails to mount an effective early immune response to *Histomonas meleagridis* in the gut. *Parasite Immunology, 31*, 312-327.

Rausch, S., Huehn, J., Kirchhoff, D., Rzepecka, J., Schnoeller, C., Pillai, S., Loddenkemper, C., Scheffold, A., Hamann, A., Lucius, R. & Hartmann, S. (2008). Functional analysis of

For Peer Review Only

effector and regulatory T cells in a parasitic nematode infection. *Infection and Immunity, 76*, 1908-1919.

Rautenschlein, S., von Samson-Himmelstjerna, G. & Haase, C. (2007). A comparison of immune responses to infection with virulent infectious bursal disease virus (IBDV) between specific-pathogen-free chickens infected at 12 and 28 days of age. *Veterinary Immunology and Immunopathology, 115*, 251-260.

Riddell, C. & Gajadhar, A. (1988). Cecal and hepatic granulomas in chickens associated with *Heterakis gallinarum* infection. *Avian Diseases, 32*, 836-838.

Roller, M., Rechkemmer, G. & Watzl, B. (2004). Prebiotic inulin enriched with oligofructose in combination with the probiotics *Lactobacillus rhamnosus* and *Bifidobacterium lactis* modulates intestinal immune functions in rats. *Journal of Nutrition, 134*, 153-156.

Ryz, N.R., Meddings, J.B. & Taylor, C.G. (2008). Long-chain inulin increases dendritic cells in the Peyer's patches and increases ex vivo cytokine secretion in the spleen and mesenteric lymph nodes of growing female rats, independent of zinc status. *British Journal of Nutrition,* 1-11.

Scales, H.E., Ierna, M.X. & Lawrence, C.E. (2007). The role of IL-4, IL-13 and IL-4Rα in the development of protective and pathological responses to *Trichinella spiralis*. *Parasite Immunology, 29*, 81-91.

Schwartz, S.E., Levine, G.D. & Starr, C.M. (1982). Effects of dietary fiber on intestinal ion fluxes in rats. *American Journal of Clinical Nutrition, 36*, 1102-1105.

Seifert, S. & Watzl, B. (2007). Inulin and oligofructose: review of experimental data on immune modulation. *Journal of Nutrition, 137*, 2563S-2567S.

Solis de los Santos, F., Donoghue, A.M., Venkitanarayanan, K., Metcalf, J.H., Reyes-Herrera, I., Dirain, M.L., Aguiar, V.F., Blore, P.J. & Donoghue, D.J. (2009). The natural feed additive caprylic acid decreases *Campylobacter jejuni* colonization in market-aged broiler chickens. *Poultry Science, 88*, 61-64.

For Peer Review Only

Springer, W.T., Johnson, J. & Reid, W.M. (1969). Transmission of histomoniasis with male *Heterakis gallinarum* (nematoda). *Parasitology, 59*, 401-405.

Taylor, M.D., van der Werf, N., Harris, A., Graham, A.L., Bain, O., Allen, J.E. & Maizels, R. M. (2009). Early recruitment of natural CD4+ Foxp3+ Treg cells by infective larvae determines the outcome of filarial infection. *European Journal of Immunology, 39*, 192-206.

Trushina, E.N., Martynova, E.A., Nikitiuk, D.B., Mustafina, O.K. & Baigarin, E.K. (2005). [The influence of dietary inulin and oligofructose on the cell-mediated and humoral immunity in rats]. *Voprosy pitaniia, 74*, 22-27.

Vervelde, L., Vermeulen, A.N. & Jeurissen, S.H. (1996). In situ characterization of leucocyte subpopulations after infection with *Eimeria tenella* in chickens. *Parasite Immunology, 18*, 247-256.

Watzl, B., Girrbach, S. & Roller, M. (2005). Inulin, oligofructose and immunomodulation. *British Journal of Nutrition, 93 Supplement 1*, S49-55.

Yun, C. H., Lillehoj, H. S. & Choi, K. D. (2000). *Eimeria tenella* infection induces local gamma interferon production and intestinal lymphocyte subpopulation changes. *Infection and Immunity, 68*, 1282-1288.

For Peer Review Only

Figure 1. Histopathological lesions of the caecal wall of chickens inoculated with 200 embryonated eggs of *Heterakis gallinarum (H. g.).* 1a: non-inoculated control bird. 1b-c-d-e: *H. gallinarum* and *Histomonas meleagridis* co-infection (Experiment 1). 1b: severe interstitial lymphocyte infiltration 2 weeks pi. Mucosal architecture is destroyed. Arrows show histomonads. 1c: mucosal structure is partly restored 3 weeks pi, severe lymphocyte and heterophil infiltration in the lamina propria. 1d: re-epithelialisation process 3 weeks pi. 1e: moderate lymphocyte infiltration in the lamina propria and formation of lymphoid centres in caecal mucosa 5 weeks pi. 1f: Experiment 2: mild to moderate lymphocyte infiltration in the lamina propria following *H. gallinarum* mono-infection. Bars = 300µm in 1a, 1b, 1c, 1e, 1f and =80 µm in 1d.

Figure 2. Abundance score of caecal T lymphocytes in the lamina propria of chickens orally infected with 200 *Heterakis gallinarum (H. g.)* eggs. 2a: non-inoculated bird. 2b: *H. gallinarum* mono-infection two or five weeks pi (Experiment 2). 2c: *H. gallinarum* mono-infection two weeks pi or *H. gallinarum* and *Histomonas meleagridis (H. meleagridis)* co-infection five weeks pi (Experiment 1). 2d, e, f: *H. gallinarum* and *H. meleagridis* co-infection two and three weeks pi. Black cells indicate positive lymphocytes. 2a: score 1-some scattered positive cells. 2b, c, d: score 2 = mild-, score 3 = moderate-, score 4 = severe lymphocyte infiltration, respectively, tissue architecture not affected. 2e, f: score 5 = moderate-, score 6 = severe lymphocyte infiltration, respectively, tissue architecture affected. Bars =300µm.

Figure 3. Changes in local T lymphocyte populations in the caecal lamina propria following *Heterakis gallinarum (H. g.)* and *Histomonas meleagridis* co-infection (Experiment 1) and *H. gallinarum* mono-infection (Experiment 2). Data represent the group mean of the abundance score ± standard deviation. 3a: CD4+ cells. 3b: CD8α+ cells. 3c: TCRαβ ($V\beta_1$)+ cells. 3d:

For Peer Review Only

TCRγδ+ cells. *Significantly different to the non-inoculated group of the same experiment (Experiment 1: n=15, Experiment 2: n=14-15, Wilcoxon Rank Sum Test, $P<0.05$)

Figure 4. Flow cytometric analysis of splenic CD4+ lymphocytes. In both experiments birds of one group were inoculated with 200 embryonated *Heterakis gallinarum (H. g.)* eggs. Experiment 1: dual infection with *H. gallinarum* and *Histomonas meleagridis.* Experiment 2: mono-infection with *H. gallinarum* *Significantly different to the non-inoculated group of the same experiment (Experiment 1: n=15, Experiment 2: n=14-15, t-test, $P<0.05$)

Figure 5. Quantification of cytokine mRNA expression levels in caecal tissue of chickens dually infected with *Heterakis gallinarum (H. g.)* and *Histomonas meleagridis* (Experiment 1) and mono-infected with *H. gallinarum* (Experiment 2). The data are corrected for variation in input RNA by 28S mRNA levels and are presented as x-fold change in mRNA expression levels in the ceca of inoculated birds in comparison to non-inoculated controls. 5a: IFN-γ, 5b: IL-4, 5c: IL-13. *Significantly different to the non-inoculated birds of the same experiment (n=3, t-test, $P<0.05$)

Figure 6. Maximal changes in short-circuit currents (ΔIsc) as a mass for the changes in chloride secretion in caecal epithelium of layer chickens inoculated with 200 embryonated *Heterakis gallinarum (H. g.)* eggs. Birds were allotted to three different diets. Experiment 1: dual infection with *H. gallinarum* and *Histomonas meleagridis.* Experiment 2: mono-infection with *H. gallinarum* 6a: addition of carbachol- stimulator of Ca-dependent chloride secretion. 6b: addition of forskolin-stimulator of cAMP-dependent chloride secretion. 6c: addition of NPPB- inhibitor of the CFTR channel, via major chloride secretion occurs. C: control diet, I: diet with 9.1% of insoluble NSP, S: diet with 9.1% soluble NSP. *Significant effect of the

For Peer Review Only

diet or infection between the bird groups of the same experiment (Experiment 1: n = 4-5, Experiment 2: n = 5, $P<0.05$)

For Peer Review Only

Table 1. *Ingredients and nutrient contents of experimental diets.*

Item	Diet[1]		
	C	I	S
Component, %			
Barley	29.0	26.4	26.4
Wheat	54.0	49.1	49.1
Fishmeal	8.0	7.3	7.3
Casein	4.5	4.1	4.1
Soybean oil	2.0	1.8	1.8
Premix 77046	1.0	0.9	0.9
MCP[2]	0.9	0.8	0.8
$CaCO_3$	0.6	0.5	0.5
Pea bran meal	-	9.1	-
Chicory root meal	-	-	9.1
Analyzed			
DM, g/kg	898	900	898
Nutrients[3], g/kg DM			
Crude ash	56	53	56
Crude protein	219	203	204
Crude lipids	40	35	37
Sugar	33	30	69
Starch	485	439	415
ADF	32	88	38
NDF	119	173	123
Insoluble NSP	102	173	104
Sol- NSP,g/kg	19	22	24
Inulin,g/kg	-	-	71
ME[4], MJ/kg DM	13.29	12.06	12.25

[1]C = control diet, I = diet with insoluble NSP, S = diet with soluble NSP

[2]MCP = mono-calcium phosphate, [3]DM = dry matter, ADF = acid detergent fibre, NDF = neutral detergent fibre, NSP = non-starch polysaccharides [4]ME = metabolizable energy

For Peer Review Only

Table 2. *Real-time quantitative RT-PCR primers and probes.*

RNA target		Probe/primer sequence (5´-3´)	Accession No.[a]
28S	P	HEX-AGGACCGCTACGGACCTCCACCA-BHQ2	X59733
	F	GGCGAAGCCAGAGGAAACT	
	R	GACGACCGATTTGCACGTC	
IL-4	P	FAM-AGCAGCACCTCCCTCAAGGCACC-3'TAMRA	AJ621735
	F	AACATGCGTCAGCTCCTGAAT	
	R	TCTGCTAGGAACTTCTCCATTGAA	
	F^C	TGCCGCTGATGGAGAGCATCC	
	R^C	GTGGAAGAAGGTACGTAGGTCTGCT	
IL-13	P	FAM-ACACCAGAGTGGCACAAGTGGCTTTCAA-BHQ1	AJ621735
	F	CAGAGGAGTGCAGGTCCCTTG	
	R	CAGTTCGTCATGCCGTGCAG	
	F^C	ACTGAAGGCTGCCCTTGCTC	
	R^C	GGTGTAGTTCCCCAGTGCCG	
IFN-γ	P	FAM-AAGCTCCCGATGAACGACTTGA-TAMRA	Y07922
	F	GTGAAAGATATCATGGACCTGG	
	R	TTCTGTAAGATGCTGAAGAGTTC	

P: probe, F: forward primer, R: reverse primer, F^C: cloning forward primer, R^C: cloning reverse primer. [a] refers to genomic DNA sequence

For Peer Review Only

Table 3. *Infection rate and development of macroscopic and microscopic lesions in chickens inoculated with 200 embryonated eggs of* Heterakis gallinarum (H. g.).

Experiment/ / treatment with dimetridazol	*H. g.* infection rate in %	% faeces samples with *H. g.* eggs	% birds per group with caecal lesions at weeks pi					
			Macroscopic			Microscopic (severity grade)		
			2	3	5	2	3	5
1 /no	13	0	93	93	7	93 (4.0)	100 (3.5)	93 (3.0)
2 / yes	93	33	0	0	0	93 (2.0)	86 (1.0)	80 (1.0)

n=14-15 birds per inoculated group. The macroscopically observed lesions were thickening of caecal wall, haemorrhagic exudate and cheesy core in caecal lumen. Severity grades of microscopical lesions: 4.0 = severe hyperplasy of tunica muscularis, numerous histomonads, massive lymphocyte, heterophil and macrophage infiltration, coagulation necrosis; 3.0 = severe lymphocyte infiltration in the lamina propria and lymphoid centres in caecal tissue; 2.0 = moderate lymphocyte infiltration in the lamina propria and formation of lymphoid aggregations; 1.0 = mild lymphocyte infiltration in the lamina propria. Non-inoculated birds were negative for lesions, worms and eggs.

For Peer Review Only

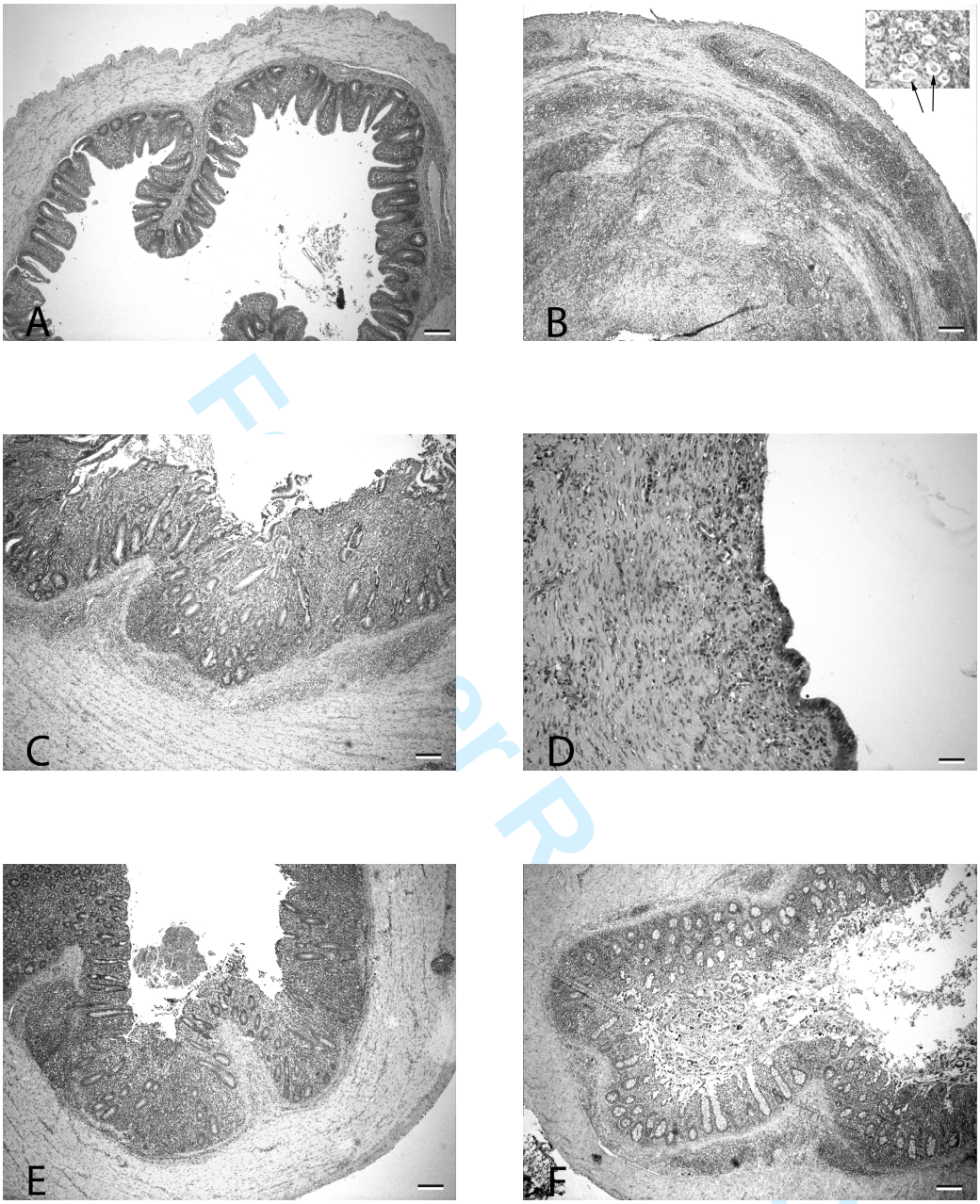

Figure 1.

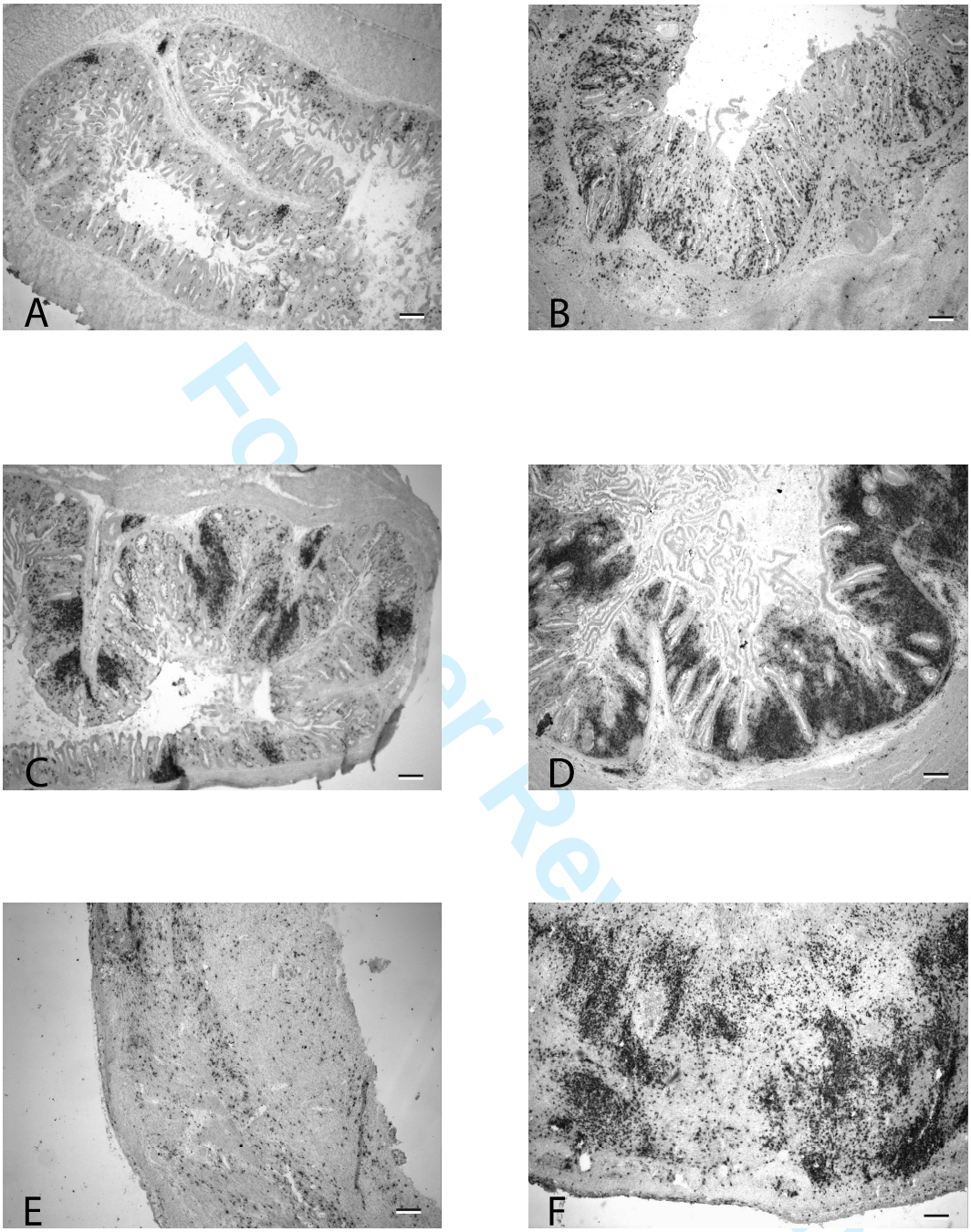

Figure 2.

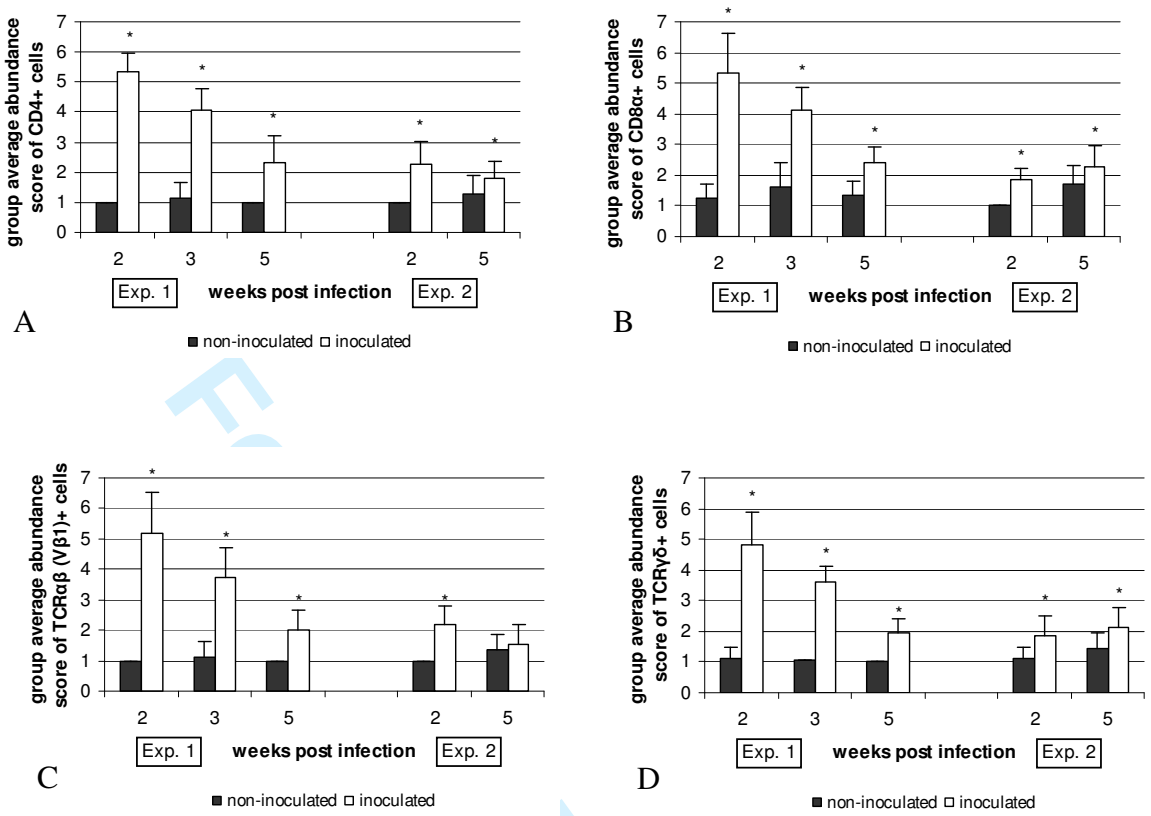

Figure 3.

For Review Only

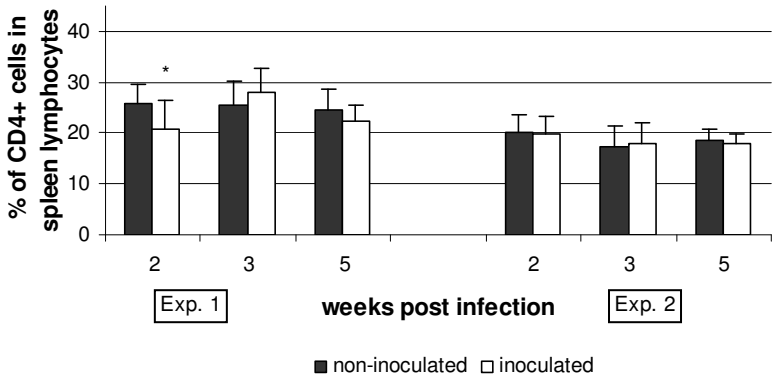

Figure 4.

For Peer Review Only

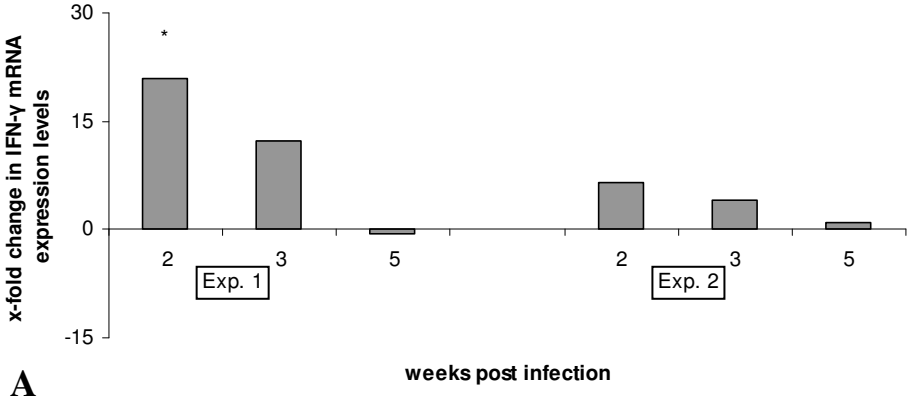
30
15
0
-15
x-fold change in IFN-γ mRNA expression levels
*
2
3
5
2
3
5
Exp. 1
Exp. 2
weeks post infection

A

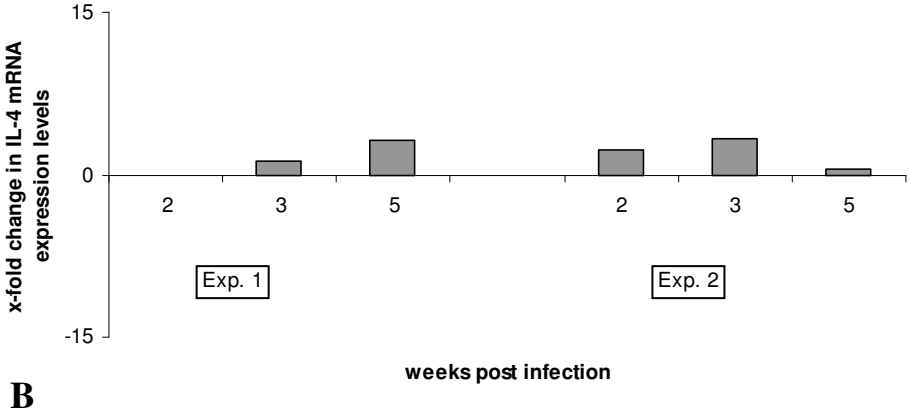
15
0
-15
x-fold change in IL-4 mRNA expression levels
2
3
5
2
3
5
Exp. 1
Exp. 2
weeks post infection

B

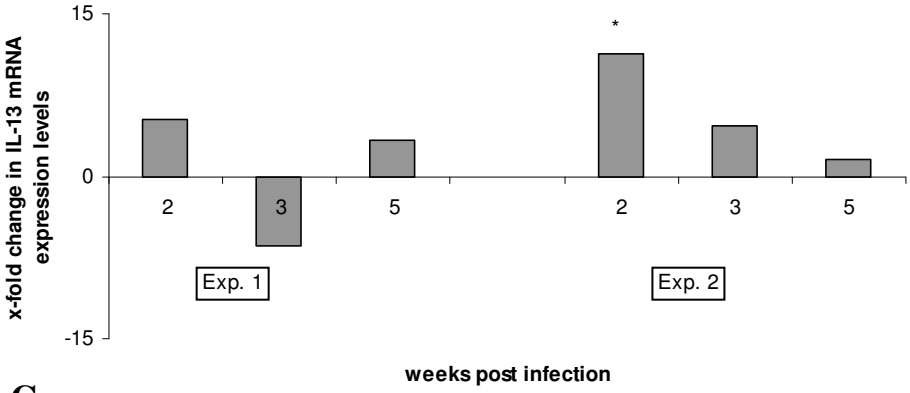
15
0
-15
x-fold change in IL-13 mRNA expression levels
*
2
3
5
2
3
5
Exp. 1
Exp. 2
weeks post infection

C

Figure 5.

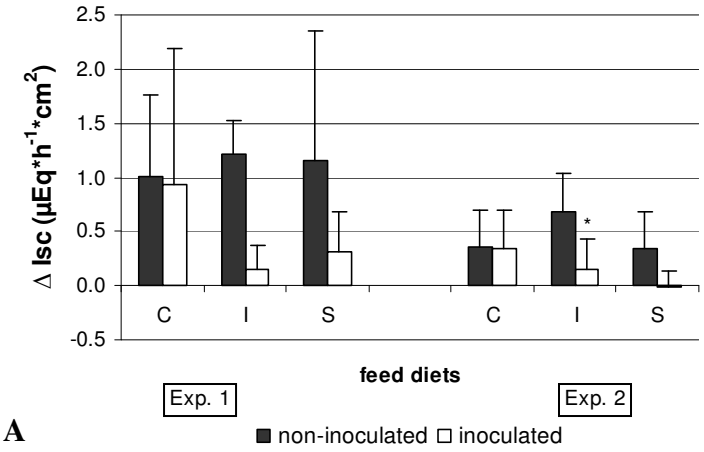
2.5
2.0
1.5
1.0
0.5
0.0
-0.5
Δ Isc (µEq*h-1*cm2)
C
I
S
C
I
S
feed diets
Exp. 1
Exp. 2
non-inoculated
inoculated

A

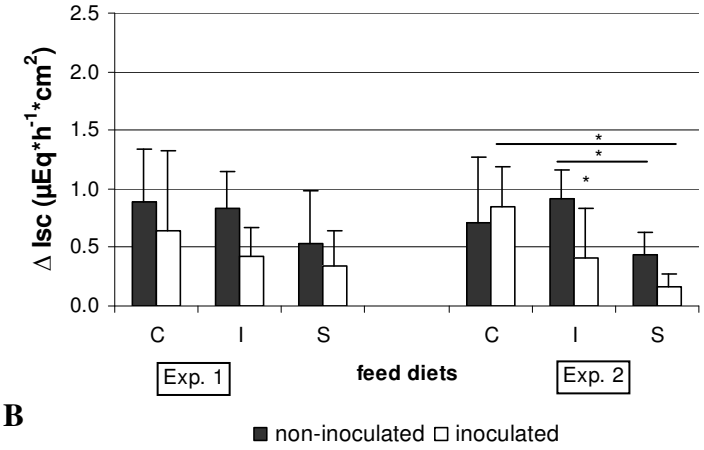
2.5
2.0
1.5
1.0
0.5
0.0
Δ Isc (µEq*h-1*cm2)
C
I
S
C
I
S
feed diets
Exp. 1
Exp. 2
non-inoculated
inoculated

B

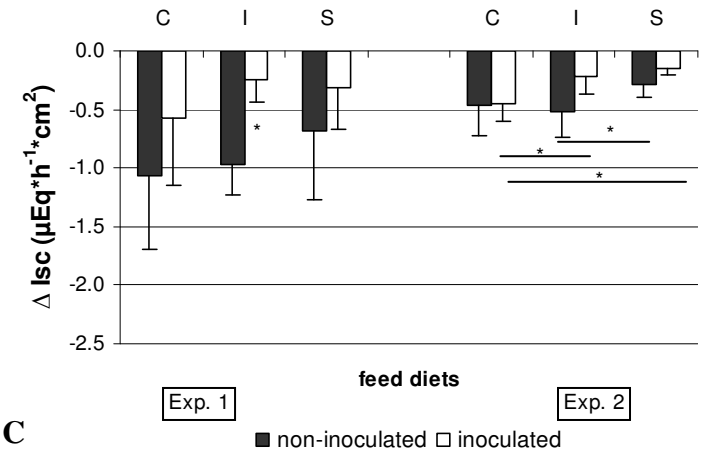
C
I
S
C
I
S
0.0
-0.5
-1.0
-1.5
-2.0
-2.5
Δ Isc (µEq*h-1*cm2)
feed diets
Exp. 1
Exp. 2
non-inoculated
inoculated

C

Figure 6.