HAL
open science

Novel clinical finding in duplication syndrome

Magdalena Budisteanu, Sorina Mihaela Papuc, Andreea Tutulan-Cunita, Bogdan Budisteanu, Aurora Arghir

To cite this version:

Magdalena Budisteanu, Sorina Mihaela Papuc, Andreea Tutulan-Cunita, Bogdan Budisteanu, Aurora Arghir. Novel clinical finding in duplication syndrome. European Child and Adolescent Psychiatry, 2011, 20 (7), pp.373-375. 10.1007/s00787-011-0184-2 . hal-00698873

HAL Id: hal-00698873

https://hal.science/hal-00698873

Submitted on 18 May 2012

HAL is a multi-disciplinary open access archive for the deposit and dissemination of scientific research documents, whether they are published or not. The documents may come from teaching and research institutions in France or abroad, or from public or private research centers.

L'archive ouverte pluridisciplinaire **HAL**, est destinée au dépôt et à la diffusion de documents scientifiques de niveau recherche, publiés ou non, émanant des établissements d'enseignement et de recherche français ou étrangers, des laboratoires publics ou privés.

Novel clinical finding in *MECP2* Duplication Syndrome: a case report

Magdalena Budisteanu[1,2*], Sorina Mihaela Chirieac[1*], Andreea Tutulan-Cunita[1], Bogdan Budisteanu[2], Aurora Arghir[1]

MECP2 Duplication Syndrome

1. "Victor Babes" National Institute of Pathology, 99-101 Splaiul Independentei, Sect. 5 – 050096, Bucharest, Romania
2. "Prof. dr. Alexandru Obregia" Clinical Hospital of Psychiatry, 10-12 Berceni Av., Sector 4, 041914, Bucharest, Romania

* These authors equally contributed to this paper.

Correspondence to: Dr. Magdalena Budisteanu, "Prof. dr. Alexandru Obregia" Clinical Hospital of Psychiatry, 10-12 Berceni Av., Sector 4, 041914, Bucharest, Romania
TEL/FAX 0040213349068, email adress magda_efrim@yahoo.com.

Sir,

MECP2 Duplication Syndrome (*MECP2* DS) is a newly described genetic condition, with approximately 120 affected males being reported insofar [1-11]. The clinical features of this syndrome are hypotonia with feeding difficulties in the first months of life, followed by spasticity in childhood; delayed motor developmental milestones; severe speech delay; dysmorphic features (brachycephaly, midfacial hypoplasia, large ears, and flat nasal bridge); moderate to severe intellectual disability; autistic features; seizures; recurrent respiratory infections; hypoplasia of the corpus callosum; severe constipation; less frequently, bladder dysfunction (urinary retention; bladder dilatation) [8]. Movement disorders (*i.e.* choreiform movements, stereotypies and repetitive behaviors - especially midline hand movements), were reported in various percentages of patients; rocking, spinning, and self-injurious behavior were also reported [11]. Most females heterozygous for *MECP2* duplication are asymptomatic, but can exhibit features of the broad autism phenotype or other symptoms like anxiety, depression, compulsions [12]. These patients management is multidisciplinary, including the treatment of feeding difficulties and of respiratory infection, physical therapy, speech therapy, ergotherapy, and specific behavioural therapy.

We report on a 6 year-old boy, the first child of healthy nonconsanguineous parents, born after an uneventful pregnancy, with a birth weight 2500 g, Apgar score 10. No movement disorders or attention disorders in the family history were reported. Shortly after birth, the boy presented hypotonia, with delayed psychomotor development: he held his head at 10 months, sat at 15 months, walked alone at 36 months, and spoke first words at 40 months. In the first year of life the patient had feeding difficulties and recurrent respiratory infections. The clinical examination showed: weight 23 kg (Pc 75), height 115 cm (Pc 50), occipitofrontal circumference 48 cm (< 2 DS); facial dysmorphism (hypertelorism; partial palpebral ptosis; open, carp-shaped

mouth; micrognatia) (figure 1); cryptorchidism; bilateral pyramidal syndrome; severe intellectual disability; severe speech delay; autistic features; drooling. A prominent feature of the clinical picture was severe hyperkinesis, manifested as random non-purposeful movements, occurring throughout the day, in any environment (at home, in kindergarten, in other public spaces), more prominent during the morning and in the afternoon, impairing daily activities (the child was not able to play or to stay at the table to do a task for more than 5 minutes, thus not being able to participate in different activities together with other children). The patient presented also stereotyped movements (hand-flapping movements) and agitation during sleep. Hyperkinesis was, actually, the main reason for referral to our Department. The patient had not chorea, tremor, or epileptic seizures. To our knowledge, this is the first case with confirmed *MECP2* duplication and hyperkinesis, the *MECP2* duplication syndrome patients being considered rather hypoactive [13]. Biological tests, EEG and cerebral MRI were normal.

Genetic tests included: GTG-banded karyotyping by standard procedures, which was normal, and aCGH on 44K Agilent platform which revealed a 1.43 Mb duplication of Xq28 (152824755-153262507, NCBI Build 36) (figure 2). This region contains the following genes *AVPR2, ARHGAP4, ARD1A, RENBP, HCFC1, TMEM187, IRAK1, MECP2, OPN1LW, OPN1MW, OPN1MW2, TEX28, TKTL1, FLNA, EMD* [14]

Our patient management included educational and rehabilitation support: speech therapy, cognitive stimulation, behavioural therapy, with slight improvement of autistic features, but with no progress in speech development. Association of behavioural therapy with neuroleptic (risperidone) improved the hyperkinesis.

Discussions

MECP2 duplications often involve several genes besides *MECP2*, including genes known to act in central nervous system development and/or reported in association with MR: *L1CAM, FLNA, EMD* [3]. Our case presents a duplication of Xq28, including *MECP2* gene, and *IRAK 1* but, notably, not *L1CAM*. Comparisons with two CNV public databases [15] found part of the duplicated loci reported as CNVs detected in healthy subjects, both as gains and losses (*IRAK1, OPN1LW, OPN1MW, OPN1MW2, TEX28, TKTL1, FLNA, EMD*); therefore, the role of these genes in the pathologic condition of the patient is unclear.

The clinical features of our patient largely overlap with those described by other authors, namely infantile hypotonia, followed by spasticity, feeding difficulties, severe speech delay, dysmorphic features, intellectual disability, and recurrent respiratory infections. A novel clinical feature, not reported by date in *MECP2* DS, was severe hyperkinesis. Clinical characterization of larger patient groups is required in order to establish if hyperkinesis might stand as a major sign or just add to the clinical variability of *MECP2* DS.

Acknowledgements:
This work was supported by the following grants: CNCSIS Project no. 1203, PN Project no 09330203 and PN II Project no. 42-130.

References

1. Ropers HH (2006) X-linked mental retardation: many genes for a complex disorder. Curr Opin Genet Dev 16:260–9.
2 Sanlaville D, Schluth-Bolard C, and Turleau C (2009) Distal Xq duplication and functional Xq disomy. J Rare Dis. 4: 4.
3. Meins M, Lehmann J, Gerresheim F, Herchenbach J, Hagedorn M, Hameister K, Epplen JT (2005) Submicroscopic duplication in Xq28 causes increased expression of the MECP2 gene in a boy with severe mental retardation and features of Rett syndrome. J Med Genet. 42:e12.
4. Van Esch H, Bauters M, Ignatius J, Jansen M, Raynaud M, Hollanders K, Lugtenberg D, Bienvenu T, Jensen LR, Gecz J, Moraine C, Marynen P, Fryns JP, Froyen G (2005) Duplication of the MECP2 region is a frequent cause of severe mental retardation and progressive neurological symptoms in males. Am J Hum Genet.77:442–53.
5. del Gaudio D, Fang P, Scaglia F, Ward PA, Craigen WJ, Glaze DG, Neul JL, Patel A, Lee JA, Irons M, Berry SA, Pursley AA, Grebe TA, Freedenberg D, Martin RA, Hsich GE, Khera JR, Friedman NR, Zoghbi HY, Eng CM, Lupski JR, Beaudet al Cheung SW, Roa BB (2006) Increased MECP2 gene copy number as the result of genomic duplication in neurodevelopmentally delayed males. Genet Med. 8:784–92.
6. Friez MJ, Jones JR, Clarkson K, Lubs H, Abuelo D, Bier JA, Pai S, Simensen R, Williams C, Giampietro PF, Schwartz CE, Stevenson RE (2006) Recurrent infections, hypotonia, and mental retardation caused by duplication of MECP2 and adjacent region in Xq28. Pediatrics 118:e1687-95.
7. Smyk M, Obersztyn E, Nowakowska B, Nawara M, Cheung SW, Mazurczak T, Stankiewicz P, Bocian E (2008) Different-sized duplications of Xq28, including MECP2, in three males with mental retardation, absent or delayed speech, and recurrent infections. Am J Med Genet B Neuropsychiatr Genet.147B:799–806.
8. Clayton-Smith J, Walters S, Hobson E, Burkitt-Wright E, Smith R, Toutain A, Amiel J, Lyonnet S, Mansour S, Fitzpatrick D, Ciccone R, Ricca I, Zuffardi O, Donnai D (2009) Xq28 duplication presenting with intestinal and bladder dysfunction and a distinctive facial appearance. Eur J Hum Genet.17:434–43.
9. Prescott TE, Rødningen OK, Bjørnstad A, Stray-Pedersen A (2009) Two brothers with a microduplication including the MECP2 gene: rapid head growth in infancy and resolution of susceptibility to infection. Clin Dysmorphol.18:78–82.
10. Echenne B, Roubertie A, Lugtenberg D, Kleefstra T, Hamel BC, Van Bokhoven H, Lacombe D, Philippe C, Jonveaux P, de Brouwer AP (2009) Neurologic aspects of MECP2 gene duplication in male patients. Pediatr Neurol. 41:187–91.
11. Ramocki MB, Peters SU, Tavyev YJ, Zhang F, Carvalho CM, Schaaf CP, Richman R, Fang P, Glaze DG, Lupski JR, Zoghbi HY (2009) Autism and other neuropsychiatric symptoms are prevalent in individuals with MeCP2 duplication syndrome. Ann Neurol. 66:771–82.
12. Carvalho CMB, Zhang F, Liu P, Patel A, Sahoo T, Bacino CA, Shaw C, Peacock S, Pursley A, Tavyev YJ, Ramocki MB, Nawara M, Obersztyn E, Vianna-Morgante AM, Stankiewicz P, Zoghbi HY, Cheung SW, Lupski JR (2009) Complex rearrangements in patients with duplication of MECP2 can occur by fork stalling and template switching. Hum Mol Genet. 18(12): 2188–2203.
13. Rhead B, Karolchik D, Kuhn RM, Hinrichs AS, Zweig AS, Fujita P, Diekhans M, Smith KE, Rosenbloom KR, Raney BJ, Pohl A, Pheasant M, Meyer L,

Hsu F, Hillman-Jackson J, Harte RA, Giardine B, Dreszer T, Clawson H,
Barber GP, Haussler D, Kent WJ (2010) The UCSC Genome Browser database: update 2010, Nucleic Acids Res. 38 D613-619, http://genome.ucsc.edu/
14. A.J. Iafrate, L. Feuk, M.N. Rivera, M.L. Listewnik, P.K. Donahoe, Y. Qi, S.W. Scherer, C. Lee (2004) Detection of large-scale variation in the human genome, Nat Genet. 36 949-951 http://projects.tcag.ca/variation/

Figures legend.

Figure. 1. Frontal view of the patient showing dysmorfic facial features.

Figure 2. aCGH profile of chromosome X showing a 1.43 Mb duplication of Xq28.

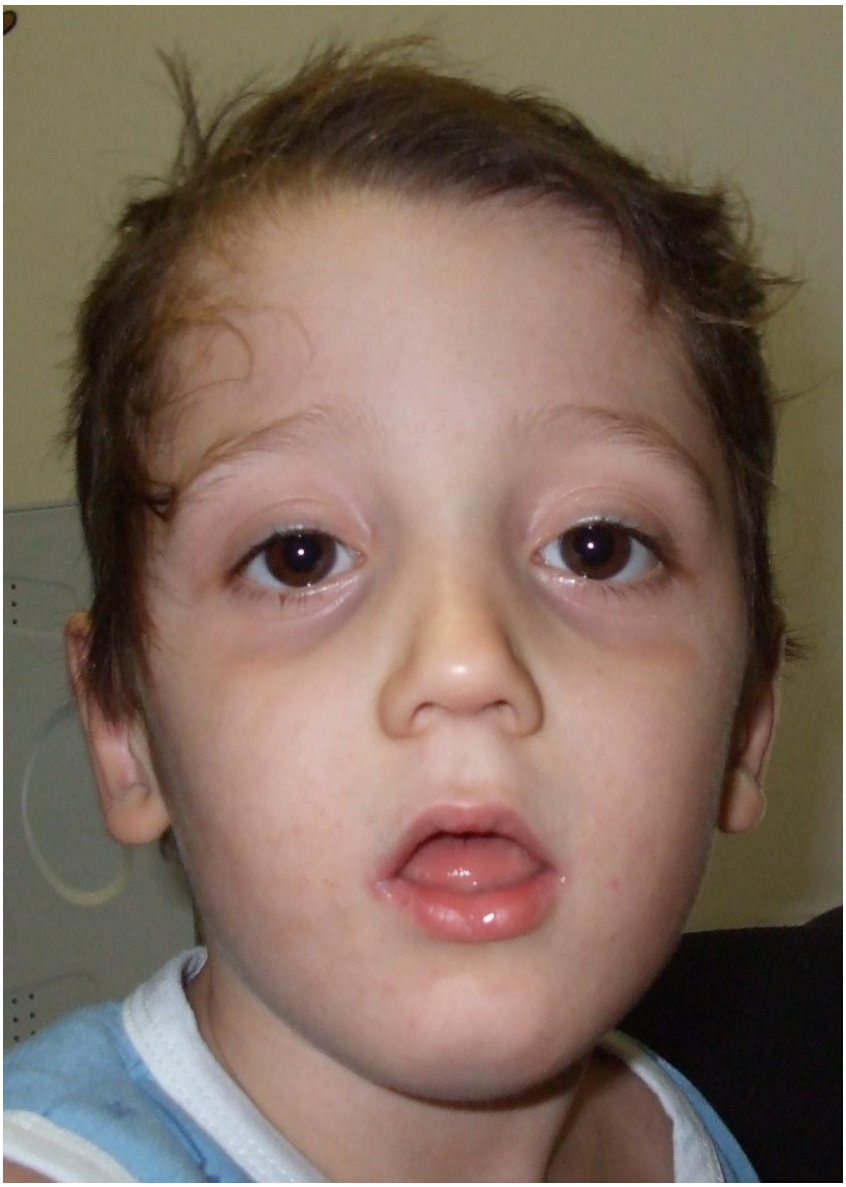


X
X: 150809636-154527618, 3.71 Mb
Scatter Plot
US83503544_251495022339_S01_CGH_107_Sep09_1_1
p22.32
p22.2
p22.12
p21.3
p21.1
p11.3
p11.22
q12
q13.2
q21.1
q21.31
q21.33
q22.2
q23
q25
q26.2
q27.1
q27.3
150.8 Mb
152.0 Mb
153.2 Mb
154.5 Mb