



**HAL**  
open science

## Outcome of Pathologic Fractures of the Proximal Femur in Non osteogenic Primary Bone Sarcoma

Coonoor R. Chandrasekar, Robert J. Grimer, Simon R. Carter, Roger M.  
Tillman, Adesegun T. Abudu, Lee M. Jays

► **To cite this version:**

Coonoor R. Chandrasekar, Robert J. Grimer, Simon R. Carter, Roger M. Tillman, Adesegun T. Abudu, et al.. Outcome of Pathologic Fractures of the Proximal Femur in Non osteogenic Primary Bone Sarcoma. *EJSO - European Journal of Surgical Oncology*, 2011, 10.1016/j.ejso.2011.02.007 . hal-00696632

**HAL Id: hal-00696632**

**<https://hal.science/hal-00696632>**

Submitted on 13 May 2012


**HAL** is a multi-disciplinary open access archive for the deposit and dissemination of scientific research documents, whether they are published or not. The documents may come from teaching and research institutions in France or abroad, or from public or private research centers.

L'archive ouverte pluridisciplinaire **HAL**, est destinée au dépôt et à la diffusion de documents scientifiques de niveau recherche, publiés ou non, émanant des établissements d'enseignement et de recherche français ou étrangers, des laboratoires publics ou privés.

# Accepted Manuscript

Title: Outcome of Pathologic Fractures of the Proximal Femur in Non osteogenic Primary Bone Sarcoma

Authors: Coonoor R. Chandrasekar, FRCS Robert J. Grimer, FRCS Simon R. Carter, FRCS Roger M. Tillman, FRCS Adesegun T. Abudu, FRCS Lee M. Jays, FRCS



PII: S0748-7983(11)00076-X

DOI: [10.1016/j.ejso.2011.02.007](https://doi.org/10.1016/j.ejso.2011.02.007)

Reference: YEJSO 3130

To appear in: *European Journal of Surgical Oncology*

Received Date: 5 October 2010

Revised Date: 27 January 2011

Accepted Date: 10 February 2011

Please cite this article as: Chandrasekar CR, Grimer RJ, Carter SR, Tillman RM, Abudu AT, Jays LM. Outcome of Pathologic Fractures of the Proximal Femur in Non osteogenic Primary Bone Sarcoma, *European Journal of Surgical Oncology* (2011), doi: 10.1016/j.ejso.2011.02.007

This is a PDF file of an unedited manuscript that has been accepted for publication. As a service to our customers we are providing this early version of the manuscript. The manuscript will undergo copyediting, typesetting, and review of the resulting proof before it is published in its final form. Please note that during the production process errors may be discovered which could affect the content, and all legal disclaimers that apply to the journal pertain.

**Outcome of Pathologic Fractures of the Proximal Femur in Non osteogenic Primary  
Bone Sarcoma**

Coonoor R. Chandrasekar FRCS<sup>1</sup>,

Robert J. Grimer FRCS<sup>2</sup>,

Simon R. Carter FRCS<sup>2</sup>,

Roger M. Tillman FRCS<sup>2</sup>,

Adesegun T. Abudu FRCS<sup>2</sup>,

Lee M. Jays FRCS

1- Royal Liverpool And Broadgreen University Hospitals NHS Trust, Liverpool, UK

2- Royal Orthopaedic Hospital, Birmingham, UK

C. R. Chandrasekar (corresponding author)

Royal Liverpool And Broadgreen University Hospitals NHS Trust, Liverpool, UK

Email [crc12@hotmail.com](mailto:crc12@hotmail.com)

## Abstract

Pathologic fractures of the proximal femur resulting from primary bone sarcomas are often difficult to treat and some are often not recognized resulting in inappropriate interventions prior to the correct diagnosis being made. The aim of the study was to identify factors determining the survival after pathologic fractures of the proximal femur resulting from nonosteogenic primary bone sarcomas.

**Patients and Methods:** We retrospectively reviewed 72 patients with nonosteogenic primary bone sarcomas of the proximal femur (chondrosarcoma in 34 patients, spindle cell sarcoma in 25 and Ewing's sarcoma in 13). There were 40 male and 32 female patients. The mean age was 49 years. We analyzed patient, tumour, and treatment factors in relation to overall survival. The mean follow up was 55 months (range 0-302 months).

**Results:** The overall 5-year survival rate was 44% (Ewing's sarcoma 60%, chondrosarcoma 57%, spindle cell sarcoma 30%, and dedifferentiated chondrosarcoma 0%). The diagnosis of spindle cell sarcoma and dedifferentiated chondrosarcoma was the only significant factor adversely affecting survival. There was no difference in survival resulting from timing of the fracture, site of the fracture, age at diagnosis, surgical margin, limb salvage or amputation.

**Conclusions:** The key factor adversely affecting the survival after pathologic fractures of the proximal femur resulting from nonosteogenic primary bone sarcomas is the histological diagnosis of dedifferentiated chondrosarcoma and spindle cell sarcoma

**Level of Evidence:** Level IV, prognostic study.

## **Introduction**

Primary bone sarcomas of the proximal femur are rare. There are many reports on primary bone sarcomas and pathological fractures [1-17]. 5%-10% of the patients with a primary bone sarcoma present with a pathological fracture [14]. A pathologic fracture can be the presenting feature or can occur during treatment. Progressive loss of bone, biopsy, and minor trauma are some of the reasons for pathologic fracture. Pathologic fractures of the proximal femur pose particular problems because the fracture hematoma (which should be considered to contain tumor cells) may either be intracapsular, thus contaminating the hip, or extra capsular when there is likely to be widespread contamination of surrounding tissues. Management is difficult because immobilization of the fracture with traction does not eliminate continued movement at the fracture site during preoperative chemotherapy and it may increase the risk of wider local spread and possibly metastases. Pathologic fractures of the proximal femur due to metastases are not uncommon and fractures due to a primary bone sarcoma are often not recognized resulting in inappropriate interventions and the purpose of our study was to identify the factors determining the survival after pathologic fractures of the proximal femur resulting from nonosteogenic primary bone sarcomas [chondrosarcoma, Ewing's sarcoma and spindle cell sarcoma]

## **Patients and Methods**

We retrospectively reviewed all 72 patients diagnosed and treated for nonosteogenic primary bone sarcoma of the proximal femur with a pathologic fracture between 1978 and 2008.

Patients were identified through an institutional database. We included intracapsular, intertrochanteric, and subtrochanteric fractures in the study. During the study period 340 tumors out of a total of 3173 primary bone sarcomas were located in the proximal femur (11%). Thirty-four of 117 patients with chondrosarcoma of the proximal femur had a fracture

(29%), 25 of 100 with a spindle cell sarcoma had a fracture (25%), and 13 of 69 patients with Ewing's sarcoma had a fracture (19%). Ten of the 72 patients were referred after unplanned surgery (four had THR and six had internal fixation). The mean age was 49 years. The diagnoses were chondrosarcoma in 34, spindle cell sarcoma in 25 and Ewing's sarcoma in 13. Sixty patients had a pathologic fracture at diagnosis and 12 patients had a fracture after the diagnosis. Ten patients had metastases at diagnosis. Twenty-one patients had an intracapsular fracture. The Patient, disease and treatment characteristics are illustrated in Table 1. Limb salvage was possible in 48 patients (67%), 13 patients had an amputation, and 11 patients had palliative treatment. Twenty-four patients were referred after an unplanned surgery. The mean follow up was 55 months (range, 0-302 months). No patients were lost to follow up.

All had staging studies with routine hematological and biochemical investigations, bone scan, MRI scan of the proximal femur, and CT of the chest (Fig 1). Tissue diagnoses were obtained in all patients, usually by needle biopsy.

Before operation, the fractures were immobilized by traction with the patient being on bed rest. The patients were offered preoperative chemotherapy according to the protocol in use at the time. In general, most patients younger than age 60 years with a diagnosis of Ewing's sarcoma and spindle cell sarcoma were offered neoadjuvant chemotherapy and were then restaged before a decision was made about surgery. Patients older than age 60 years usually had surgery (if possible) without chemotherapy.

The decision as to the operation to be undertaken to control the local disease was based on the local extent of the tumor as seen on the imaging scans, the response to preoperative chemotherapy, and patient preference. Proximal femoral endoprotheses (Fig 1), hip disarticulation, hindquarter amputation, and palliation were the treatment options.

We analyzed patient, tumour, and treatment factors in relation to overall survival. Differences between groups were assessed using Mann-Whitney U test. Survival was estimated using

Kaplan-Meier survival curves with patients censored at the time of last follow up. We used Stat view software for all analyses.

Thirty-four patients had chondrosarcoma. There were 19 males and 15 females. The mean age was 60 years (range 29-81 years). Seven patients were aged 50 years or younger, whereas 27 were older than 50 years. Six patients had a dedifferentiated chondrosarcoma and all of them were older than 50 years of age. Eight patients had low-grade tumors and 26 had intermediate, high-grade, or dedifferentiated tumors. Twenty-eight patients presented with a pathologic fracture and six patients sustained a fracture after the diagnosis. Only two patients had metastases at diagnosis. Ten patients had a fracture involving the hip. Twenty-one patients were treated with a proximal femoral endoprosthetic replacement, one patient had a total femur arthroplasty, two patients had hip disarticulation, and two patients had hindquarter amputation. Three patients who had a THA and three patients who had an intramedullary nail performed elsewhere did not have further surgery. Two patients had palliative treatment.

## Results

The overall 5-year survival rate was 44% (Figure 2), but this varied widely depending on the diagnosis. The estimated 5- year survival for Ewing's sarcoma was 60%, non dedifferentiated chondrosarcoma was 57%, spindle cell sarcoma 30%, and dedifferentiated chondrosarcoma was 0%. Comparing the survival between dedifferentiated chondrosarcoma and other diagnoses showed that the survival was significantly worse  $p=0.005$  (Figure 3). Comparing survival between spindle cell sarcoma and other diagnoses showed that the survival was significantly worse  $p=0.008$ . For the whole group, there was no difference in survival relating to the timing of the fracture, site of the fracture, age at diagnosis, surgical margin, local recurrence, or limb salvage or amputation (Table 2). The estimated 5-year survival rate was 57% for non dedifferentiated chondrosarcoma. There were no 5-year survivors with a dedifferentiated chondrosarcoma (mean survival 8 months; range, 3-18 months). The estimated 5-year survival rate for spindle cell sarcomas was 30%. Survival of patients with

spindle cell sarcoma was not influenced by previous treatment, metastasis at diagnosis, location of the fracture, local recurrence, or amputation (Table 2). The estimated 5-year survival rate for Ewing's sarcoma was 60%. The four patients who had a good response to chemotherapy (greater than 90%) are alive (13, 73, 117 and 291 months after the diagnosis). Survival with Ewing's sarcoma was not influenced by previous treatment, metastasis at diagnosis, location of the fracture, response to chemotherapy, local recurrence, or amputation.

## **Discussion**

Pathological fractures of the proximal femur due to non-osteogenic sarcoma are rare.

Previous studies have identified a proximal location as having a poor prognosis [2] and other studies have suggested that a pathological fracture has a poor prognosis [3]. Pathologic fractures of the proximal femur due to metastases are not uncommon and fractures due to a primary bone sarcoma are often not recognized resulting in inappropriate interventions. The purpose of this study was to analyze the factors affecting the survival after pathologic fracture of the proximal femur due to non osteogenic primary bone sarcoma

Different diagnoses, long study period, evolution of neo-adjuvant and adjuvant therapy and the smaller number of patients are some of the drawbacks of the present study typical of a single centre retrospective study.

The estimated overall five year survival was only 44% with particularly poor survival for patients with dedifferentiated chondrosarcoma and spindle cell sarcoma. Although ten of this group of seventy two patients already had metastases at diagnosis (14%), this is the same proportion of all patients with primary bone tumors with metastases (456/3216) [unpublished data from our oncology database]. A pathologic fracture also increases the likelihood of widespread local dissemination of haematoma and tumor cells due to difficulty in immobilisation prior to the definitive treatment. This means that any attempt at subsequent excision may have compromised margins with an increased risk of local recurrence. The local



recurrence was 24% in the present series but this was not found to be a significant factor affecting survival.

Twenty four patients (33%) were referred after surgery prior to the diagnosis being made and this will also increase tumor dissemination. The preferable management of a pathological fracture in primary bone sarcoma is to immobilize the fracture, establish the diagnosis and administer chemotherapy, if indicated, in the hope that the fracture will heal and the fracture/tumor haematoma will become walled off, thus allowing limb salvage [6]. In the proximal femur immobilization is difficult if not impossible either with traction or bed rest alone. If the fracture is internally fixed then this does allow the patient to be mobile while treatment is considered but on the other hand it will result in more widespread contamination of normal tissues and will then require even more extensive surgery to ensure clear margins can be obtained. Amputation may be the only safe option following inadvertent fixation of a proximal femoral pathological fracture, although the patients who had an amputation had no survival advantage in the present study compared with limb salvage surgery. It is also difficult to advise the best treatment [14] for those patients who are referred after inadvertent hip replacement for a chondrosarcoma or a spindle cell sarcoma with a pathological fracture involving the hip joint. Often they are over 50 years and the option of a modified hindquarter amputation aiming to achieve clear margins may appear drastic when there is a functioning joint replacement. Attempts at limb salvage may not always provide clear margins as a result of wide contamination. Nevertheless previous surgical intervention was not a significant prognostic factor in the present study.

Pathological fractures due to dedifferentiated chondrosarcoma [3, 5] and spindle cell sarcoma carry a significantly worse prognosis due to the aggressive nature of these tumors.

A report [6] on 31 patients with a pathological fracture due to primary bone sarcoma included seven patients with proximal femoral fractures. It was noted that limb salvage surgery was safe if adequate resection margins were obtained. Another study [3] from our centre reported

on pathological fractures due to primary bone sarcomas (all locations) found that the overall survival was worse in patients with a fracture in osteosarcoma and chondrosarcoma and not Ewing's sarcoma. A report [8] on 35 patients with pathological fracture due to Ewing's sarcoma showed that the survival was 60% at 10 years and a pathological fracture was not a negative prognostic factor for survival. These findings are similar to the present series indicating that pathologic fractures in Ewing's sarcoma do not adversely affect survival. Local control is important in chondrosarcoma which is resistant to chemotherapy. A report [11] on 227 patients with chondrosarcoma of whom 46 had a pathological fracture, found that the pathological fracture did not influence the oncological outcome. Patients with a fracture had a lower survival rate, but this was related to the grade of the tumor. Another study [7] reporting on 153 patients with chondrosarcoma found that extra compartmental spread, development of local recurrence and high grade tumors were independent risk factors for survival. In the present study, the only factor to affect survival for chondrosarcomas was dedifferentiation.

Given the rarity of proximal femoral fracture in primary bone sarcoma, providing evidence based guidelines are likely to be difficult but based on our results thus far we suggest the following: We believe that pathological fractures of the proximal femur should be avoided if possible. Any fracture of the proximal femur which occurs after minor trauma, with radiological evidence of a pre-existing lesion which is solitary on bone scan with no previous history of cancer should be referred to a tertiary centre for biopsy and appropriate management. If there is an extensive lytic process likely to lead to fracture following biopsy, early surgery should be considered, possibly doing a frozen section and being prepared to do a proximal femoral replacement using a modular endoprosthesis [4] if the lesion is operable. If the fracture has already arisen and been inadvertently stabilised then the patient should be treated conventionally with chemotherapy if indicated and reassessed. Though an amputation

may be the safest treatment option, a pathological fracture per se is not a contraindication for limb salvage and amputation does not convincingly provide a survival benefit.

The present study addresses survival following a pathologic fracture of the proximal femur due to non osteogenic primary bone sarcoma. This has not previously been addressed in the literature. The prognosis is significantly worse if the diagnosis is dedifferentiated chondrosarcoma or spindle cell sarcoma.

#### References

1. Abudu A, Sferopoulos NK, Tillman RM, Carter SR, Grimer RJ. The surgical treatment and outcome of pathological fractures in localised osteosarcoma. *J Bone Joint Surg Br.* 1996;78:694-698.
2. Bacci G, Ferrari S, Longhi A, Donati D, Manfrini M, Giacomini S, Briccoli A, Forni C, Galletti S. Nonmetastatic osteosarcoma of the extremity with pathologic fracture at presentation: local and systemic control by amputation or limb salvage after preoperative chemotherapy. *Acta Orthop Scand.* 2003;74:449-454.
3. Bramer JA, Abudu AA, Grimer RJ, Carter SR, Tillman RM. Do pathological fractures influence survival and local recurrence rate in bony sarcomas? *Eur J Cancer.* 2007;43:1944-1951.
4. Chandrasekar CR, Grimer RJ, Carter SR, Abudu AA, Tillman RM. Modular endoprosthetic replacement for tumours of the proximal femur. *J Bone Joint Surg Br.* 2009;91:108-112.
5. Cotterill SJ, Ahrens S, Paulussen M, Jürgens HF, Voûte PA, Gardner H, Craft AW. Prognostic factors in Ewing's tumor of bone: analysis of 975 patients from the European Intergroup Cooperative Ewing's Sarcoma Study Group. *J Clin Oncol.* 2000;18:3108-3114.
6. Ebeid WS, Abdelmegid AA. Limb salvage management of pathologic fractures of primary malignant bone tumors. *Cancer Control.* 2005;12:57-61.

7. Fiorenza F, Abudu A, Grimer RJ, Carter SR, Tillman RM, Ayoub K, Mangham DC, Davies AM. Risk factors for survival and local control in chondrosarcoma of bone. *J Bone Joint Surg Br.* 2002;84:93-99.
8. Fuchs B, Valenzuela RG, Sim FH. Pathologic fracture as a complication in the treatment of Ewing's sarcoma. *Clin Orthop Relat Res.* 2003;415:25-30.
9. Giuffrida AY, Burgueno JE, Koniaris LG, Gutierrez JC, Duncan R, Scully SP. Chondrosarcoma in the United States (1973 to 2003): an analysis of 2890 cases from the SEER database. *J Bone Joint Surg Am.* 2009;91:1063-1072.
10. Grimer RJ, Taminiu AM, Cannon SR. Surgical outcomes in osteosarcoma. *J Bone Joint Surg Br.* 2002;84:395-400.
11. Lee FY, Mankin HJ, Fondren G, Gebhardt MC, Springfield DS, Rosenberg AE, Jennings LC. Chondrosarcoma of bone: an assessment of outcome. *J Bone Joint Surg Am.* 1999;81:326-338.
12. Natarajan MV, Govardhan RH, Williams S, Rajagopal TS. Limb salvage surgery for pathological fractures in osteosarcoma. *Int Orthop.* 2000;24:170-172.
13. Ozger H, Eralp L, Atalar AC, Toker B, Ayan I, Kebudi R, Bağbek S, Başaran M, Ağaoğlu F, Dizdar Y, Bilgiç B. Survival analysis and the effects of prognostic factors in patients treated for osteosarcoma. *Acta Orthop Traumatol Turc.* 2007;41:211-219.
14. Papagelopoulos PJ, Mavrogenis AF, Savvidou OD, Benetos IS, Galanis EC, Soucacos PN. Pathological fractures in primary bone sarcomas. *Injury.* 2008;39:395-403.
15. Rüdiger HA, Dora C, Bode-Lesniewska B, Exner GU. Extra-articular resection of the hip with a posterior column-preserving technique for treatment of an intra-articular malignant lesion. A report of two cases. *J Bone Joint Surg Am.* 2005;87:2768-2774.
16. Scully SP, Ghert MA, Zurakowski D, Thompson RC, Gebhardt MC. Pathologic fracture in osteosarcoma: prognostic importance and treatment implications. *J Bone Joint Surg Am.* 2002;84:49-57.

17. Wunder JS, Paulian G, Huvos AG, Heller G, Meyers PA, Healey JH.

The histological response to chemotherapy as a predictor of the oncological outcome of operative treatment of Ewing sarcoma. *J Bone Joint Surg Am.* 1998;80:1020-1033

ACCEPTED MANUSCRIPT

Table 1 – Patient, disease and treatment characteristics

<b>Total no. of patients</b>	<b>72</b>		<b>Chondrosarcoma</b> 34		<b>Spindle cell sarcoma</b> 25		<b>Ewing's</b> 13	
<b>Age</b>	<b>Mean 49 years</b> <b>Range 6-83</b>		<b>Mean 60 years</b> <b>Range 29 -81</b>		<b>Mean 49 years</b> <b>Range 21-83</b>		<b>Mean 20 years</b> <b>Range 6-51</b>	
<b>Age &lt;50/&gt;51</b>	31	41	7	27	11	14	12	1
<b>Sex Male/ Female</b>	42	30	19	15	15	10	6	7
<b>Site intracapsular/ extracapsular</b>	21	51	10	24	9	16	2	11
<b>Grade low/high</b>			8	26				
<b>Metastases at diagnosis Yes/no</b>	10	62	2	32	4	21	4	9
<b>Fracture At diagnosis/ After</b>	59	13	28	6	21	4	10	3
<b>Surgery limb salvage/amputation</b>	48	13	24	4	14	8	10	1
<b>Margin wide/other</b>	22	25	9	13	8	7	5	5
<b>Local recurrence Yes/no</b>	17	55	10	24	7	18	0	13
<b>Previous fixation Yes/no</b>	22	50	10	24	12	13	0	13

Table 2 – Factors influencing survival in pathological fractures of the proximal femur due to non-osteogenic primary bone sarcoma

	<b>All patients</b>		<b>Hazard ratio</b>	<b>95% CI LOWER</b>	<b>95%CI UPPER</b>
	No	p value			
<b>Age</b> <50/>51	31/41	0.05	0.318	.098	1.038
<b>Sex</b> Male/ Female	42/30	0.79	0.711	.380	1.332
<b>Site</b> intracapsular/ extracapsular	21/51	0.91	1.036	.514	2.087
<b>Grade</b> low/high					
<b>Metastases at diagnosis</b> Yes/no	10/62	0.18	1.798	.740	4.369
<b>Fracture</b> At diagnosis/ After	59/13	0.62	0.817	.361	1,848
<b>Surgery</b> limb salvage/amputation	48/13	0.64	1.431	.615	3.330
<b>Margin</b> wide/other	22/25	0.40	0.802	.239	2.694
<b>Local recurrence</b> Yes/no	17/55	0.09	1.728	.898	3.323
<b>Previous fixation</b> Yes/no	22/50	0.10	1.511	.791	2.889

Figure 1 - Pre operative radiographs, MRI scan of chondrosarcoma of the proximal femur and post operative radiograph showing proximal femoral endoprosthesis

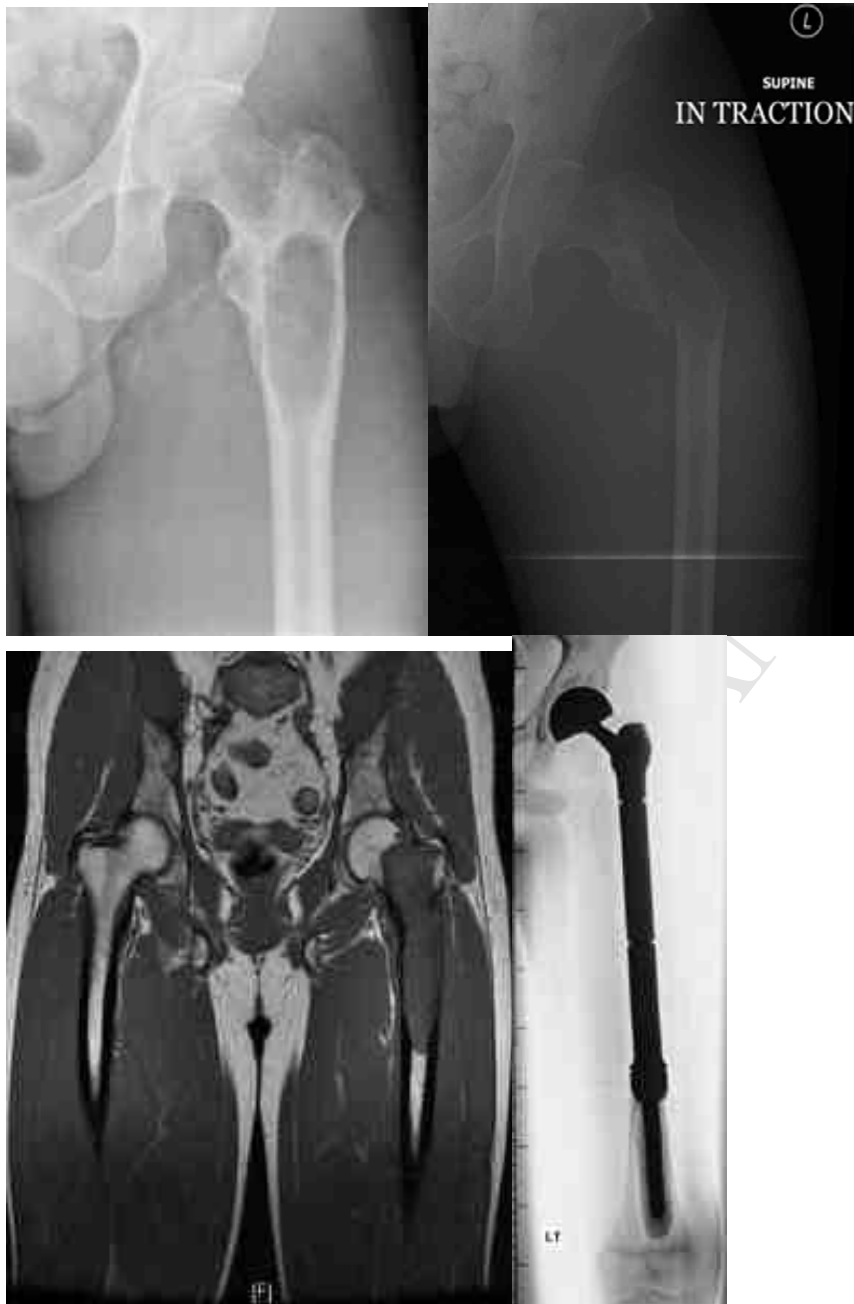



Fig 2. Kaplan Meier survival curve showing the survival of the patients with non-osteogenic primary bone sarcoma of the proximal femur with a pathological fracture -44% at 5 years

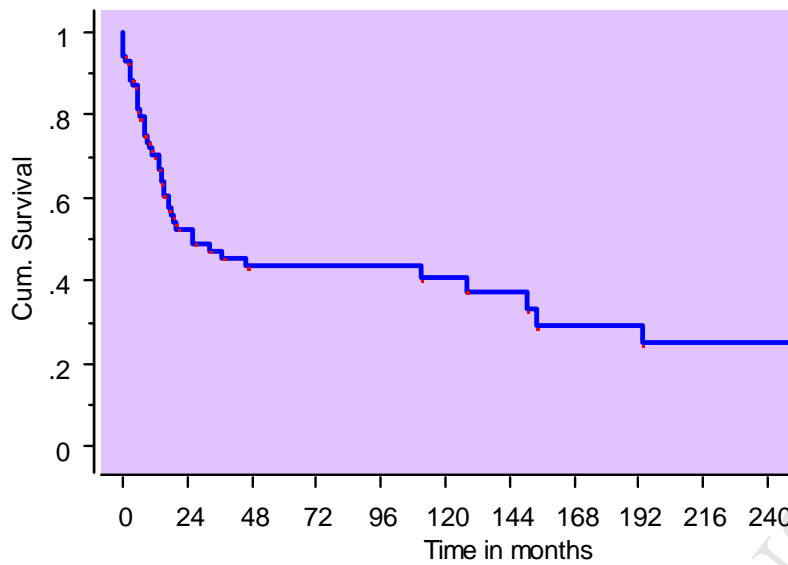


Fig 3. Kaplan Meier survival curve showing the survival of patients with non-osteogenic primary bone sarcoma of the proximal femur with a pathological fracture based on tissue diagnoses

