



**HAL**  
open science

## **Pathogenesis of Highly Pathogenic Avian Influenza A Virus (H7N1) infection in chickens inoculated with three different doses**

Aida Jeannette Chaves Hernández, Natàlia Majó I Masferrer, Ayub Darji, Nuria Busquets, Naiana Campos, Antonio Ramis, Raquel Rivas, Rosa Valle

► **To cite this version:**

Aida Jeannette Chaves Hernández, Natàlia Majó I Masferrer, Ayub Darji, Nuria Busquets, Naiana Campos, et al. Pathogenesis of Highly Pathogenic Avian Influenza A Virus (H7N1) infection in chickens inoculated with three different doses. *Avian Pathology*, 2011, 40 (02), pp.163-172. 10.1080/03079457.2011.551874 . hal-00687804

**HAL Id: hal-00687804**

**<https://hal.science/hal-00687804>**

Submitted on 15 Apr 2012

**HAL** is a multi-disciplinary open access archive for the deposit and dissemination of scientific research documents, whether they are published or not. The documents may come from teaching and research institutions in France or abroad, or from public or private research centers.

L'archive ouverte pluridisciplinaire **HAL**, est destinée au dépôt et à la diffusion de documents scientifiques de niveau recherche, publiés ou non, émanant des établissements d'enseignement et de recherche français ou étrangers, des laboratoires publics ou privés.



**Pathogenesis of Highly Pathogenic Avian Influenza A Virus (H7N1) infection in chickens inoculated with three different doses**

Journal:	<i>Avian Pathology</i>
Manuscript ID:	CAVP-2010-0150
Manuscript Type:	Original Research Paper
Date Submitted by the Author:	14-Sep-2010
Complete List of Authors:	Chaves Hernández, Aida; Universitat Autònoma de Barcelona, Sanitat Animal Majó i Masferrer, Natàlia; Universitat Autònoma de Barcelona, Pathology Darji, Ayub; Centre de Recerca en Sanitat Animal, Immunology Busquets, Nuria; Centre de Recerca en Sanitat Animal, Molecular Biology Campos, Naiana; Centre de Recerca en Sanitat Animal, Molecular Biology; Universitat Autònoma de Barcelona, Sanitat Animal Ramis, Antonio; Universitat Autònoma de Barcelona, Pathology Rivas, Raquel; Centre de Recerca en Sanitat Animal, Molecular Biology Valle, Rosa; Centre de Recerca en Sanitat Animal, Molecular Biology
Keywords:	Highly pathogenic influenza virus, H7N1, chickens, RT-qPCR

SCHOLARONE™  
Manuscripts

Cavp-2010-0150.R1

Pathogenesis of highly pathogenic avian influenza A Virus (H7N1)  
infection in chickens inoculated with three different doses

Aida J. Chaves<sup>1,2</sup>; Núria Busquets<sup>1</sup>; Naiana Campos<sup>1</sup>; Antonio Ramis<sup>a,b</sup>; Roser Dolz<sup>1</sup>; Raquel Rivas<sup>1</sup>; Rosa Valle<sup>1</sup>; F. Xavier Abad<sup>1</sup>; Ayub Darji<sup>1</sup>; and Natàlia Majó<sup>1,2</sup>

<sup>1</sup> *Centre de Recerca en Sanitat Animal (CRESA), UAB-IRTA, Campus de la Universitat Autònoma de Barcelona, 08193. Bellaterra, Barcelona, Spain*

<sup>2</sup> *Departament de Sanitat i Anatomia Animals, Universitat Autònoma de Barcelona, 08193. Bellaterra, Barcelona, Spain*

Short title: Pathogenesis of high path avian influenza

- Corresponding author at: E- mail address: natalia.majo@cresa.uab.es

*Received: 14 September 2010*

## Summary

To study the pathogenesis of a H7N1 highly pathogenic avian influenza virus (HPAIV) strain, specific pathogen free (SPF) chickens were inoculated with decreasing concentrations of virus:  $10^{5.5}$  ELD<sub>50</sub> (G1),  $10^{3.5}$  ELD<sub>50</sub> (G2) and  $10^{1.5}$  ELD<sub>50</sub> (G3). Disease progression was monitored over a period of 16 days and sequential necropsies and tissue samples were collected for histological and immunohistochemical examination. Viral RNA loads were also quantified in different tissues, blood, oropharyngeal swabs, and cloacal swabs using quantitative real time RT-PCR (RT-qPCR). Clinical signs of depression, apathy, listlessness, huddling and ruffled feathers were recorded in G1 and a few G2 birds, whilst neurological signs were only observed in chickens inoculated with the highest dose. Gross lesions of haemorrhages were observed in the unfeathered skin of the comb and legs, and skeletal muscle, lung, pancreas and kidneys of birds inoculated with  $10^{5.5}$  ELD<sub>50</sub> and  $10^{3.5}$  ELD<sub>50</sub> doses. Microscopic lesions and viral antigen was demonstrated in cells of the nasal cavity, lung, heart, skeletal muscle, brain, spinal cord, gastrointestinal tract, pancreas, liver, bone marrow, thymus, bursa of Fabricius, spleen, kidney, adrenal gland and skin. Viral RNA was detected by RT-qPCR in kidney, lung, intestine, and brain samples of G1 and G2 birds. However, in birds infected with the lowest dose, viral RNA was detected only in brain and lung samples in low amounts at 5 and 7 dpi. Interestingly, viral shedding was observed in oropharyngeal and cloacal swabs with proportionate decrease with the inoculation dose. We conclude that although an adequate infectious dose is critical in reproducing the clinical infection, chickens exposed to lower doses can be infected and shed virus representing a risk for the dissemination of the viral agent.

## Introduction

Avian influenza viruses (AIV) in poultry have been categorised into two groups according to their ability to produce clinical signs and the severity of disease. The low pathogenicity avian influenza viruses (LPAIV) do not cause clinical signs or produce a mild localised infection limited to the respiratory or gastrointestinal tracts. In contrast, the highly pathogenic avian influenza viruses (HPAIV) have been associated with an acute fatal disease as a consequence of systemic replication (Swayne & Halvorson, 2008).

Based on the antigenic diversity of the two surface glycoproteins of the AIV, 16 different haemagglutinin (HA) subtypes, and 9 different neuraminidase (NA) subtypes have been identified (Alexander *et al.*, 2007). Some viruses of H5 and H7 subtypes are associated with high pathogenicity in chickens, although the majority of the H5 and H7 are of low pathogenicity (Swayne & Halvorson, 2008; Panigrahy *et al.*, 2002). The difference in the pathogenicity is mainly determined by the HA gene and the presence of additional basic amino acids at the proteolytic cleavage site. HA of LPAIV are cleaved by trypsin-like proteases that are associated with respiratory and intestinal epithelial cells, confining the infection to these sites. In contrast, HA from HPAI viruses can be cleaved by the aforementioned proteases and also by ubiquitous furin proteases, leading to a generalized infection (Swayne, 2007).

Infections by some HPAIV produce serious outbreaks in poultry with mortality rates that approach 100% in the affected flocks (Alexander, 2000). HPAIVs have been shown to transmit from birds to people, representing a significant threat to human health (Joseph *et al.*, 2007). This is the case for the H5N1 HPAIV that emerged in Hong Kong

in 1997 affecting chicken farms and also causing infection and death in people (Shortridge *et al.*, 1998; Subbarao *et al.*, 1998). H7 subtype viruses have also been implicated in the direct transmission to humans: H7N7 and H7N3 viruses caused infection in people related with the poultry industry in the Netherlands in 2003 (Fouchier *et al.*, 2004) and in British Columbia, Canada, in 2007, respectively (Tweed *et al.*, 2004; Joseph *et al.*, 2007).

HPAIVs are able to produce clinical disease and death in poultry by a variety of mechanism including dysfunction of the nervous, cardiovascular and endocrine systems (Swayne, 1997). Although, the mechanism of pathogenicity and tissue tropism of many HPAIV strains show similar clinical presentations (Kobayashi *et al.*, 1996b; Nakamura *et al.*, 2008), an unique conclusion about the dynamics of the disease could not be generalized for all HPAIV strains (Feldman *et al.*, 2001). The aim of the present study was to assess the pathogenicity of the A/chicken/Italy/5093/99 H7N1 strain, which was associated with a serious epidemic in Italy (Capua *et al.*, 2000). To reproduce a natural infection, birds were inoculated by the intranasal route with one of three different doses ( $10^{5.5}$ ,  $10^{3.5}$  and  $10^{1.5}$  ELD<sub>50</sub>). Dynamics of infection, distribution of lesions and viral antigen, viraemic status and viral shedding was evaluated by means of immunohistochemical and RT-qPCR techniques.

## Materials and methods.

**Virus.** The avian influenza virus A/chicken/Italy/5093/99 H7N1 of fifth egg passage was kindly provided by Dr. Ana Moreno from the Istituto Zooprofilattico Sperimentale della Lombardia e dell' Emilia Romagna in Brescia, Italy. After arrival at the CReSA, the virus was passage once and propagated in 9- to 11-day-old specific pathogen free (SPF) embryonated fowls eggs. The median embryo lethal dose (ELD<sub>50</sub>) was calculated as described (Reed and Muench, 1938). The amino acid sequence at the HA0 cleavage site for the isolate used in the present experimental infection was PEIPKGSRVRR\*GLF, which was identical to the cleavage site sequence of H7N1 HPAIV strains isolated in Italy during the epidemic of 1999 and 2000 (Campitelli *et al.*, 2008). The intravenous pathogenicity index (IVPI) was performed as described (OIE, 2008), o a score of 2.8 was obtained, thereby confirming the highly pathogenic phenotype of this isolate.

**Experimental design.** *Birds.* Eighty specific pathogen free (SPF) chickens (Charles River, SPAFAS), were hatched and subsequently placed in negative pressure isolators under biosafety level 3 (BSL-3) containment conditions at the Centre de Recerca en Sanitat Animal (CReSA) for the duration of the experiment. Animal care and all procedures were performed in accordance with the regulations required by the Ethics Committee of Animal and Human Experimentation of the Universitat Autònoma de Barcelona.

*Infection.* Fifteen-day-old SPF chickens were divided into four groups and placed in separate negative pressure isolators. Each group was infected with different doses of virus through the intranasal route. The first group (G1) was inoculated with  $10^{5.5}$  ELD<sub>50</sub> H7N1 HPAI virus in a final volume of 0.05 ml. The second group (G2) was inoculated with  $10^{3.5}$  ELD<sub>50</sub> and the third group (G3) received  $10^{1.5}$  ELD<sub>50</sub> of virus. The remaining chickens were inoculated with phosphate buffered saline (PBS) and served as sham-inoculated control group (G4). Clinical signs and mortality were monitored daily throughout the 16 days of the experiment. On days 1, 3, 5, 7, 10, and 16 post inoculation (dpi), three birds of the infected and control groups (G4) were selected for necropsy (birds were randomly selected at 1 dpi and later biased toward sick or apparently unhealthy birds). Birds found dead, as well as, those killed humanely for ethical reasons were included in the study.

**Histology and immunohistochemistry.** Tissue samples from all necropsied birds in the four groups were collected and fixed by immersion in 10% buffered formalin for 24 hours. Samples selected included: nasal turbinates, trachea, oesophagus, gizzard, proventriculus, thymus, heart, lung, spleen, liver, small and large intestines (duodenum, jejunum, ileum, caecum/caecal tonsil, rectum), pancreas, adrenal gland, bursa of Fabricius, bone marrow, skin, central nervous system (CNS) (which included brain and the thoracic spinal cord), myocardium, skeletal muscle (face, breast, and muscle of the lumbar areas), sciatic and vagus nerves. All tissues were embedded in paraffin and duplicate 4µm sections were cut for haematoxylin and eosin (HE) staining and immunohistochemistry (IHC) for the detection of the type A influenza virus nucleoprotein (NP). Procedures for the IHC followed those described (Kreijtz *et al.*, 2007). Briefly, an antigen retrieval step was performed using protease XIV (Sigma-



Aldrich, USA) for 10 minutes at 37°C. Samples were then incubated with the primary antibody at a dilution of 1:250 at 4°C overnight. The primary antibody used was a commercially available mouse-derived monoclonal antibody (ATCC, HB-65, H16L-10-4R5), followed by 1 hour incubation with biotinylated goat antimouse IgG secondary antibody (Dako, immunoglobulins AS, Denmark). Finally, an avidin-biotin-peroxidase system (Thermo Fisher Scientific, Rockford, IL) was used and antigen-antibody reaction was visualized with diaminobenzidine (DAB) as chromogen. Sections were counterstained with Mayer's Hematoxylin. Contribution of nonspecific staining of the primary antibody was evaluated by substitution of the primary antibody with PBS and by performing the standard method with tissues of non-infected SPF chicken embryos. Positive control consisted of formalin-fixed paraffin-embedded tissues of chicken embryos inoculated with the H7N1 virus and that were positive by RT- qPCR.

**Viral RNA quantification in tissue samples, oropharyngeal and cloacal swabs and blood.** Blood samples were collected from G1 chickens at 1, 3 and 5 dpi with 1ml Alsever's solution (Sigma-Aldrich, USA). Oropharyngeal and cloacal swabs, as well as, brain, kidney, intestine and lung samples were collected from all birds and each placed in 500 µl of 'RNA later' (Qiagen, Hilden, Germany). All samples were kept at 4°C for 16 hours and then stored at -80°C. Viral RNA was extracted from tissue samples, oropharyngeal and cloacal swabs using QIAamp viral mini kit (Qiagen, Hilden, Germany) and following the manufacturer's instructions. Viral RNA was extracted from 15 mg of tissue samples or from 140 µl of swab, mixed with 'RNA later', and RNA was eluted in 40 µl. The resulting viral RNA extracts were tested by one-step RT-qPCR for the detection of a highly conserved region of the matrix (*M*) gene influenza A viruses using the primers described by Spackman *et al.* (2002) with the amplification conditions

described by Busquets *et al.* (2010a). This procedure uses an internal positive control (IPC) to avoid false negative results due to RT-qPCR inhibitors.

Viral RNA quantification was carried out as described by Busquets *et al.*, (2010b).

Briefly, standard curves were obtained by prior amplification of 99 bp of the M gene using the H7N1 strain RNA as template. The amplified M gene fragment was cloned into the pGEM-T vector (Promega, USA) and transformed by heat shock into *Escherichia coli* competent cells (Invitrogen, USA). The recombinant plasmid was purified using a QIAprep Spin kit (Qiagen, Hilden, Germany) followed by digestion with SacI restriction enzyme (New England Biolabs, UK) to obtain overhanging ends, and then converted to blunt ends using DNA polymerase I large (Klenow) fragment (Promega, USA). *In vitro*-transcribed RNA was generated from the T7 promoter (RiboMax kit, Promega, USA). The residual template plasmid was removed by several RNase-free DNase I (Roche, Switzerland) treatments. The RNA transcript obtained was quantified spectrophotometrically at 260 nm (Qubit, Invitrogen, USA). RNA copy numbers were calculated as described (Fronhoffs *et al.*, 2002). Tenfold RNA transcript dilutions, ranging from 6 to  $6 \times 10^7$  molecules, were used to obtain standard curves. The limit of virus detection (LoD) for the one step RT-qPCR assay used in this study was 6 viral RNA copies per reaction, which is equivalent to 1 ELD<sub>50</sub> per reaction. The LoD obtained on this assay was equivalent to 1.46 log<sub>10</sub> viral RNA copies per ml for swab and blood samples, and 2.28 log<sub>10</sub> viral RNA copies per gram of tissue.

## Results

**Clinical signs, mortality and gross lesions.** Clinical signs were limited to G1 and G2, and mortality was only seen in G1 group. Non-specific clinical signs consisting of moderate to severe depression, apathy, listlessness, huddling and ruffled feathers were first noted in 80% of birds from G1 at 2 dpi. More severe clinical signs of torticollis, lack of coordination and bilateral paralysis were observed at 6 dpi. Mortality was recorded at 3 (1 bird), 4 (1 bird), 5 (2 birds) and 6 (2 birds) dpi in this group, but two birds survived until day 10. Gross lesions were observed from 3 dpi and consisted of multifocal to diffuse haemorrhages and cyanosis of the comb and beak, mild diffuse oedema, multifocal haemorrhages in the unfeathered skin of the legs and slight mucous nasal discharge. At necropsy, petechial haemorrhages on leg skeletal muscles and serosal surfaces of the proventriculum were also detected and lasted until 6 dpi. From 5 to 7 dpi, paleness in the liver, kidney swelling with a prominent lobular pattern, splenomegaly and random multifocal areas of necrosis and haemorrhages in the pancreas were observed. In G2, one animal showed clinical signs and gross lesions similar to the G1 birds at 3 dpi while a second chicken showed necrosis in the comb, pulmonary congestion, kidney swelling and multifocal haemorrhages in the proventricular serosa at 5 dpi. The remaining chickens in the G2 group showed listlessness and ruffled feathers, from 3 to 6 dpi, and there was no mortality. In G3 and the sham infected group, no mortality, clinical signs or macroscopic lesions were observed.

**Histology and immunohistochemistry.** Histological lesions associated with the presence of viral antigen were observed in chickens from G1 and G2. In G1 chickens, lesions and specific immunostaining was observed from 3 dpi and persisted until 7 dpi in nearly all the tissues (Table 1). No lesions or immunostaining were detected in birds

at 1 dpi or in those birds that survived until 10 dpi in the G1 group. In G2, lesions and specific immunostaining were only detected in one animal on day 3 and another on day 5. In the first case, histological lesions and viral immunostaining were limited to the heart, pancreas and brain, whereas, samples collected from the animal at 5 dpi, showed lesions and distribution similar to those observed in G1 chickens at 5 dpi. No histological lesions or antigen positive cells were observed in tissues from birds of the sham infected and G3 groups.

Histological and immunohistochemical examination of G1 birds revealed severe morphological changes particularly in the respiratory tract, cardiovascular system, pancreas, kidney, adrenal glands and central nervous system. There was a strong correlation between the manifestation of viral antigen and the identification of histological lesions. Presence of viral antigen was not limited to the sites where the histopathologic alterations were visible by haematoxylin and eosin but was also distributed in the surrounding tissue. The brown antigenic staining was generally intense and compact in the nucleus, and, in some cells, it was also cytoplasmatic in distribution, although it was less intense and speckled.

In the respiratory tract, slight to moderate lymphoplasmacytic inflammation in the lamina propria of the nasal cavity, and multifocal areas of loss of cilia, vacuolar degeneration and necrosis of the respiratory epithelium were observed from 3 dpi to 7 dpi. Single cell necrosis was also observed in the olfactory epithelium of the posterior turbinate from 3 to 6 dpi. AIV antigen was demonstrated in individual cells in the respiratory and olfactory epithelium as well as in the Bowman's gland cells of the posterior turbinate (Fig. 1). Endothelial cells and intravascular inflammatory cells in the nasal cavity were also positive from 3 to 6 dpi. Necrosis and positive immunostaining was also observed in the lateral nasal glands located in the nasal cavity and,

sporadically, in salivary glands of the roof of the oral cavity. Interestingly, in one chicken sacrificed at 7 dpi, a focal area of nerve fibres degeneration and necrosis, associated with the presence of viral antigen, was observed in the ophthalmic medial branches of the trigeminal nerve located dorsally in the nasal cavity. Lung lesions consisting of an increase of cellularity in the air capillaries of the parabronchi were evident from 3 to 7 dpi, mainly due to the presence of heterophils and most probably macrophages inside the capillaries or within the air capillaries interstitium. Microthrombosis of capillaries and scattered single cells necrosis were also seen at these days. Presence of viral antigen was only detected in scattered endothelial cells and macrophages in the air capillaries. No lesions or immunostaining was observed in the trachea of any of the birds evaluated.

Randomly distributed multifocal to coalescing areas of myocardial degeneration and necrosis, with fibre hyalinization and fragmentation associated with a slight infiltration of macrophages and heterophils were observed in birds from 3 dpi. AIV antigen was observed in myocytes in the necrotic areas as well as in the adjacent inflammatory cells and endothelial cells. Skeletal muscle lesions were slight and were only observed in sections taken from the face and lumbar area. They consisted of scattered areas of fibre degeneration and necrosis surrounded by infiltrated macrophages. Muscle cells and macrophages were positive for viral antigen. Breast muscle lesions were rare and slight.

Histological lesions in the alimentary tract (oesophagus, gizzard, proventriculus, duodenum, colon, caecum, caecal tonsil and cloacae) of lymphocyte depletion and infiltration with macrophages were confined to the submucosa and lymphoid-associated areas in the proventricle and the caecal tonsils, where AIV antigen was detected in endothelial cells and infiltrating macrophages and heterophils in the submucosa of the

proventricle, caecal tonsil and in the gizzard. Similarly, only slight lesions were observed in the liver that consisted of slight periportal lymphoplasmacytic infiltration and marked Kupffer cell hypertrophy. Erythrophagocytosis in Kupffer cells and occasional fibrinous thrombi in the hepatic sinusoids were also observed from 3 to 5 dpi. Both, endothelial and Kupffer cells were positive for viral antigen, in addition to inflammatory cells in the portal vessels and periportal areas (Fig. 2). No positivity was observed on hepatocytes or biliary duct epithelial cells. More severe lesions were observed on pancreatic parenchyma, which showed focally extensive to diffuse areas of degeneration and necrosis and stained strongly for the presence of associated viral antigen. Occasionally, there was inflammatory infiltrate associated with necrotic areas, which was also positive for viral antigen from 3 to 7 dpi.

Moderate lesions were observed in kidney, in which proximal convoluted tubular epithelial cells showed multiple areas of tubular necrosis in association with the presence of viral antigen. AIV was also demonstrated on endothelial cells in the renal interstitium. Inflammatory infiltrate was rarely observed associated with necrotic areas. Severe lesions were detected in adrenal corticotrophic cells, and less frequently chromaffin cells, which showed disseminated vacuolar degeneration and necrosis associated with the presence of AIV antigen. Necrotic areas were infiltrated by macrophages and heterophils that were also positive.

In lymphohematopoietic organs, moderate erythroid and myeloid cellular depletion were noted in the bone marrow from 5 to 7 dpi. The spleen, thymus and bursa of Fabricius had slight to moderate lymphoid depletion of all histological compartments with apoptosis and/or necrosis of lymphocytes from 3 to 7 dpi. On these organs the antigen was restricted to endothelial cells and macrophages.

Skin lesions were confined to the face and comb samples, and consisted mainly in focal epidermal necrosis and diffuse oedema, hyperaemia and perivascular mixed inflammatory infiltrate (macrophages and heterophils) that was positive for viral antigen in the underlying dermis. There was microthrombosis and vasculitis affecting dermal vessels that caused focal areas of oedema, haemorrhage and necrosis. Positive staining was also observed in epidermal degenerated keratinocytes, dermal endothelial cells, follicular epithelial cells and endothelial and inflammatory cells in the follicular pulp. Nervous system lesions were detected in the grey matter and, less frequently, in the white matter, and consisted of multifocal areas of malacia that were evident in all regions of the CNS (spinal cord, cerebellum, brain stem, cerebral hemispheres, and olfactory bulb). These areas of malacia were characterized by neuropil vacuolation, neuronal central chromatolysis and neuronophagia, astro and microgliosis, and were associated with intranuclear and cytoplasmatic immunostaining on neurons and glial cells. Perivascular oedema was observed in capillaries near the affected areas, and endothelial cells as well as astrocytes of the glial limiting membrane were positive for AIV antigen. Progressive coalescence of the areas of malacia was observed from 3 to 7 dpi. Ependymocytes showed degenerative changes and necrosis and were also positive for AIV antigen from 3 dpi to 7 dpi. Slight inflammatory cell infiltration of the choroid plexus that consisted basically of macrophages was detected at 5 and 6 dpi. Choroid plexus epithelial cells were also positive for viral antigen.

Thoracic sections of the spinal cord showed necrosis of ependymal cells in the central canal and neurons in the ventral or dorsal gray matter columns in chickens from 3 to 6 dpi (Fig. 3). Peripheral nervous system did not show changes or the presence of viral antigen in any bird.

**Viral RNA quantification in blood and tissue samples by RT-qPCR.** In G1, viral RNA was detected in blood samples at 1 dpi (5.03 log<sub>10</sub> viral RNA copies/ml) 3 dpi (9.21 log<sub>10</sub> viral RNA copies/ml) and 5 dpi (7.70 log<sub>10</sub> viral RNA copies/ml). Regarding the viral load in all the sampled tissues (CNS, lung, kidney and intestine) viral RNA copies could be detected in G1 birds, inoculated with the highest ELD<sub>50</sub>, as early as 1 dpi in brain and kidney (Fig. 4a). In all the organs sampled viral RNA copies were found in birds killed humanely or found dead from 3-7 dpi. In birds from G1 sacrificed at 10 dpi no viral RNA load was detected. Central nervous system and kidney were the tissues that showed the highest viral load during the whole experiment. In G2, viral RNA was detected from 3 dpi and lasted until 7 dpi in all tissues. At 10 dpi, viral RNA was detected in kidney (4.16 log<sub>10</sub> viral RNA copies/g) (Fig 4b). High variability of the viral load was observed among individuals in this group. In G3, inoculated with the lowest ELD<sub>50</sub>, low amounts of viral genome in CNS and lung at 5 and 7 dpi were detected (Fig. 4c). Viral RNA copies were not detected in blood and tissue samples of control birds.

**Viral RNA quantification in oropharyngeal and cloacal swabs by RT-qPCR.** Viral RNA levels detected in oropharyngeal and cloacal swab samples were proportional to the inoculated ELD<sub>50</sub> dose, being highest in G1, intermediate in G2 and low in G3. In G1, one animal showed cloacal shedding at 1 dpi, but the viral load levels in oropharyngeal and cloacal swabs were high and similar between 3 dpi and 7 dpi (Fig. 5a). In G2, viral RNA copies were first detected on 3 dpi and gradually increased to peak levels for both samples (oropharyngeal and cloacal) on 5 dpi. Detection of viral RNA copies decreased on 7 dpi and reach the lowest level on 10 dpi in which oropharyngeal swabs were negative (Fig. 5b). In G3, viral RNA copies were detected in



cloacal and oropharyngeal swabs on 5 dpi and low levels could still be detected in cloacal swab samples on 7 dpi (Fig. 5c). Viral genome was not detected in oropharyngeal and cloacal swabs of control birds.

## Discussion

The H7N1 HPAIV used in the present study caused an important HPAI outbreak affecting different bird species in the late nineties in Northern Italy (Capua *et al.*, 2000a). A complete description of the clinical and pathological findings observed during the epidemic has already been published (Capua *et al.*, 2000a; Mutinelli *et al.*, 2003). However, the pathogenic mechanisms and the dynamics of infection in chickens have not truly been studied. Here, a time course evaluation of the clinical presentation, lesions and infection/disease outcome and histopathological lesions, as well as, virus distribution, detection of viraemia and viral shedding was assessed in SPF chickens by using three different doses of this HPAIV. Remarkable findings were observed that differed from the natural disease. Firstly, fibrinous peritonitis was a usual macroscopic lesion described during the H7N1 HPAIV natural outbreak (Capua *et al.*, 2000; Mutinelli *et al.*, 2003), but was not observed in the present experimental infection or in other HPAIV experimental infections (Swayne, 1997, 2007; Perkins & Swayne, 2001, Swayne & Beck, 2005; Jones & Swayne, 2004). Fibrinous peritonitis is a very common lesion in commercial birds, associated with secondary bacterial infections (Barnes *et al.*, 2008) and its description in a natural outbreak can reflect a simultaneous viral-bacterial infection (Zanella, 2003; Swayne and Halvorson, 2008). In the present study, evaluation of birds under experimental conditions allowed the identification of lesions caused only

by H7N1 HPAIV. During the outbreak only the pancreas, heart, and nervous tissues were positive for viral antigen by immunohistochemistry on samples of chickens and turkeys (Capua *et al.*, 2000a; Mutinelli *et al.*, 2003). In contrast, in the present study viral antigen was widely distributed in many tissues in chickens infected with the highest and middle doses. These differences in the extension of lesions and viral antigen distribution observed during the natural outbreak compared to the experimental infection can be attributed to the selection of a limited set of tissues (pancreas, kidney, spleen, brain and heart during the natural outbreak for a rapid diagnosis of the disease. In addition, this extensive distribution of the virus is comparable to other reports of natural and experimental infections caused by H7 and H5 subtype HPAIVs (Swayne, 1997; Perkins & Swayne, 2001, 2002, 2003a; Jones & Swayne, 2004; Pálmai *et al.*, 2007; Swayne, 2007; Nakamura *et al.*, 2008; Van Riel *et al.*, 2009). Finally, it cannot be ruled out that the detection of a wider distribution of viral antigen can be attributed to differences in the immunohistochemistry methodology used.

Most of the experimental infections with HPAIV strains are carried out using high concentrations of virus to reproduce the early onset and rapid progress observed during the natural infection (Alexander *et al.*, 1986; Perkins & Swayne, 2002; Swayne & Beck, 2005). In the present study, we also evaluated the infectivity of this H7N1 HPAIV strain using two lower doses ( $10^{3.5}$  ELD<sub>50</sub> and  $10^{1.5}$  ELD<sub>50</sub>). Our results revealed low morbidity and no mortality with the  $10^{3.5}$  ELD<sub>50</sub> and a subclinical infection with viral replication and shedding with the  $10^{1.5}$  ELD<sub>50</sub> doses. This strongly suggests that although an adequate, and usually high, infectious dose is critical in reproducing the clinical infection, chickens exposed to lower doses can be infected and shed virus representing a risk for the dissemination of the viral agent.

Viraemia has been observed at 1 dpi in chickens infected with H5 HPAIV strains, such as the H5N3 (A/tern/South Africa/61) and H5N2 (A/chicken/Pennsylvania/1379/83), and also in Pekin ducks infected with H5N1 (A/duck/Vietnam/12/05) at 3 dpi (Kishida *et al.*, 2004; Swayne and Beck, 2005; Beato *et al.*, 2007). Moreover, Toffan *et al.* (2008) have detected viraemia from 1 to 4 dpi in turkeys infected with H7N1 HPAIV. The capacity of those HPAIVs to produce viraemia may be attributed to the ability to infect endothelial cells, as demonstrated by Feldman *et al.* (2000, 2001) using chicken embryos infected with H7N1 HPAIVs A/Rostock/FVP/34 or by Capua *et al.* (2002b) using embryos of different avian species (chicken, turkey, Muscovy duck) infected with H7N1 HPAIV A/ty/Italy/4580/99. HPAIVs have been frequently reported in endothelial cells of poultry species naturally or experimentally infected (Brown *et al.*, 1992; Kobayashi *et al.*, 1996b; Mo *et al.*, 1996; Swayne, 1997; Hooper & Selleck, 1998; Suarez *et al.*, 1998; Subbarao *et al.*, 1998; Capua *et al.*, 1999, 2000; Feldman *et al.*, 2001; Park *et al.*, 2002; Perkins & Swayne, 2001, 2003a; Jones & Swayne, 2004; Muramoto *et al.*, 2006; Swayne *et al.*, 2007; Nakamura *et al.*, 2008; Van Riel *et al.*, 2009; Pasick *et al.*, 2010). A clear link between the degree of antigenic staining on endothelial cells and the severity of the disease in chickens has been reported (Perkins & Swayne, 2001). In addition, HPAIV antigen has also been demonstrated in leucocytes (Feldman *et al.*, 2001; Perkins and Swayne, 2003a), heterophils (Capua *et al.*, 1999; Jones & Swayne, 2004), and monocytes and macrophages (Jones & Swayne, 2004; Muramoto *et al.*, 2006). In our study, the presence of viral antigen in endothelial cells in venules, arterioles, and in capillary endothelial cells of many organs, in circulating mononuclear cells in association with the detection of viral RNA in blood samples from 1 dpi, provides evidence to indicate that this H7 subtype HPAIV strain is able to produce viraemia early

in the infection of chickens. This could explain the rapid dissemination of the virus to some tissues, i.e. brain and kidney did not show histological lesions or presence of AIV antigen at 1 dpi, but virus was detected by RT- qPCR on this day. Similarly, high levels of viral RNA copies were detected on intestine and lung, although lesions were almost absent on these organs and few cells were positive for viral antigen. Therefore, the detection of virus in these samples could be attributed to the presence of viral RNA copies in the bloodstream.

As observed in this study and in agreement with previous studies in chickens, ducks, and herring gulls infected with HPAIVs (Bingham *et al.*, 2009; Brown *et al.*, 2008; Swayne and Beck, 2005), oropharyngeal shedding was the principal route of excretion in birds from all groups. This could be explained by the detection of viral antigen in the respiratory and olfactory epithelial cells, as well as salivary and lateral nasal glands in birds inoculated with the higher dose and in some inoculated with the middle dose. With respect to the source for viral genetic material found in birds infected with HPAIV in cloacal swab samples, previous studies have suggested the intestinal contents, urine, bile and pancreatic excretions as sources of virus (Van Riel *et al.*, 2009), as all these tracts empty into the cloaca. However, the immunohistochemical results obtained in the present study indicate that the most likely source of virus in the cloacal samples was the kidney, because no viral antigen was found in intestinal epithelial cells, hepatocytes or bile canaliculus. Viral detection in the pancreas was evident, but the volume of pancreatic secretions that empty into the intestinal tract is very low in comparison with the urine (Denbow *et al.*, 1988).

The detection of high quantities of viral RNA in the CNS of all inoculated groups, even in the birds inoculated with the lower doses was also an interesting finding. These results corroborate the strong neurotropism of this particular HPAIV

strain as reported during the Italian outbreak in different poultry species, and also demonstrated experimentally in mice (Capua *et al.*, 2000; Rigoni *et al.*, 2007). Involvement of the central nervous system in HPAIV infections has been widely described (Kawaoka & Webster, 1988; Brown *et al.*, 1992; Kobayashi *et al.*, 1996a, b; Swayne, 1997; Perkins & Swayne, 2002, 2003b; Rowe *et al.*, 2003; Ellis *et al.*, 2004; Kwon *et al.*, 2005; Klopfleisch *et al.*, 2006; Pálmai *et al.*, 2007; Teifke *et al.*, 2007; Yamada *et al.*, 2007; Yamamoto *et al.*, 2007; Nakamura *et al.*, 2008; Brown *et al.*, 2009; Pantin-Jackwood & Swayne, 2009; Tang *et al.*, 2009; Goletic *et al.*, 2010). However, our study shows that, not only the encephalus, but also the spinal cord is consistently affected early in the infection with this H7 subtype HPAIV, which has been previously reported in chickens and mice infected with different HPAIV subtypes (Kobayashi *et al.*, 1996a; Lipatov *et al.*, 2003; Park *et al.*, 2000; Pasick *et al.*, 2010). Viral antigen detection was also described in ependymal cells lining the spinal canal of mute swan (*Cygnus olor*) and whooper swan (*Cygnus cygnus*) naturally infected with H5N1 HPAIV (Teifke *et al.*, 2007). Viral antigen has been also demonstrated in peripheral autonomic ganglia, plexi of the enteric tract and nerve in the skeletal muscle of turkeys, Japanese quail, Bobquail, pheasants and partridges infected with HPAIV (Perkins & Swayne, 2001). Moreover, it has been detected in peripheral ganglia that provides innervation to the heart, adrenal gland and gastrointestinal tract of house sparrows (Brown *et al.*, 2009), in the myenteric plexus of Pekin ducks (Vascellari *et al.*, 2007; Löndt *et al.*, 2008; Yamamoto *et al.*, 2007) and peripheral nerves and ganglia of domestic ducks (Kwon *et al.*, 2005). However, in the present study we did not detect virus in nerves or ganglia of the peripheral nervous system.

The presence and distribution of the viral antigen in the central nervous system of chickens infected with H7N1 HPAIV is of particular interest and different viral

pathways have been hypothesized: the virus can reach the CNS through the olfactory nerves (Majde *et al.*, 2007), through the peripheral nervous system (Matsuda *et al.*, 2004; Tanaka *et al.*, 2003) or through the bloodstream (Mori *et al.*, 1995). In our study, viral antigen was detected in the olfactory epithelium of birds inoculated with a higher dose during the first days post infection, but location of the viral antigen in the CNS at 3 dpi was widespread and did not correspond with an entry by the olfactory route; further studies aimed to determine whether the cells that support viral replication in the olfactory mucosa are neurons or supporting stromal cells would clarify this point. The viral entrance to the brain could be via the peripheral nervous system, especially the vagus nerve as demonstrated in mice infected with H5N3 HPAI (Matsuda *et al.*, 2004), but this seems also unlikely since the presence of virus in the vagus nerve was not detected. Therefore, based on our results, we suggest that virus dissemination to different organs and tissues and its entry to brain in chicken is most probably through the blood stream. This assumption is further supported by the finding that astrocytes of the glial limiting membrane were conspicuously positive to viral antigen detection by immunohistochemistry. Migration of the virus across the blood-brain barrier (BBB) may occur directly from the blood through opening of endothelial cell junctional complexes (para-cellular route) (Lossinsky *et al.*, 2004) or using vesiculo-tubular structures (VTS) (trans-cellular route) (Lossinsky *et al.*, 2004a; Liu *et al.*, 1997). Another possibility is the “Trojan horse mechanism” where viral particles are transported through the BBB using leukocytes and/or mononuclear cells (Verma *et al.*, 2009). Whether influenza viruses use any of these routes has not been investigated, therefore, more studies are needed to discern the underlying mechanism of BBB disruption that leads to the severe necrotizing encephalopathy and death of the birds.

## Acknowledgements

This work was partially supported by the European Project SP5B-CT-2007-044098 from the Sixth Framework Programme. We thank Dra. Ana Moreno for kindly provided the avian influenza virus A/chicken/Italy/5093/9 H7N1 strain. Aida J. Chaves is supported by the Programme Alβan, the European Union Programme of High Level Scholarships for Latin America, scholarship No. E07D400404CR.

## References

- Alexander, D.J., Parsons, G. & Manvell, R.J. (1986). Experimental assessment of the pathogenicity of eight avian influenza A viruses of H5 subtype for chickens, turkeys, ducks and quail. *Avian Pathology*, 15, 647-662. doi: 10.1080/03079458608436328.
- Alexander, D.J. (2000). A review of avian influenza in different bird species. *Vet. Microbiology*, 74, 3-13. doi:10.1016/S0378-1135(00)00160-7.
- Alexander, D.J. (2007). An overview of the epidemiology of avian influenza. *Vaccine*, 25, 5637-5644.
- Barnes, H.J., Nolan, L.K., Vaillancourt, J.P. (2008). Collibacillosis. In Saif, Y.M., Fadly, A.M., Glisson, J.R., McDougald, L. R., Nolan, L. K. & Swayne, D.E. (Eds.), *Diseases of Poultry*. Blackwell Pub, Iowa State Press, Iowa (pp. 691-712).
- Beato, M.S., Toffan, A., De Nardi, R., Cristalli, A., Terregino, C., Cattoli, G. & Capua, I. (2007). A conventional, inactivated oil emulsion vaccine suppresses shedding

and prevents viral meat colonisation in commercial (Pekin) ducks challenged with HPAI H5N1. *Vaccine*, 25, 4064-4072.

Bingham, J., Green, D.J., Lowther, S., Klippel, J., Burggraaf, S., Anderson, D.E., Wibawa, H., ... Daniels, P.W. (2009). Infection studies with two highly pathogenic avian influenza strains (Vietnamese and Indonesian) in Pekin ducks (*Anas platyrhynchos*), with particular reference to clinical disease, tissue tropism and viral shedding. *Avian Pathology*, 38, 267-278. doi:

10.1080/03079450903055371

Brown, C.C., Olander, H.J. & Senne, D.A. (1992). A pathogenesis study of highly pathogenic avian influenza virus H5N2 in chickens, using immunohistochemistry. *Journal of Comparative Pathology*, 107, 341-348. doi:10.1016/0021-9975(92)90009-J.

Brown, J.D., Stallknecht, D.E. & Swayne, D.E. (2008). Experimental infections of herring gulls (*Larus argentatus*) with H5N1 highly pathogenic avian influenza viruses by intranasal inoculation of virus and ingestion of virus-infected chicken meat, *Avian Pathology*, 37, 393-397. doi: 10.1080/03079450802216595.

Brown, J.D., Stallnecht, D.E., Berghaus, R.D. & Swayne, D.E. (2009). Infectious and lethal doses of H5N1 highly pathogenic avian influenza virus for house sparrows (*Passer domesticus*) and rock pigeons (*Columbia livia*). *Journal of Veterinary Diagnostic Investigation*, 21, 437-455.

Busquets, N., Alba, A., Napp, S., Sánchez, A., Serrano, E., Rivas, R., Núñez, J.I. & Majó, N. (2010). Influenza A virus subtypes in wild birds in North-Eastern Spain (Catalonia). *Virus Research*, 149, 10-18. doi: 10.1016/j.virusres.2009.12.005.

Busquets, N., Abad, F.X., Alba, A., Dolz, R., Allepuz, A., Rivas, R., Ramis, A., Darji, A. & Majó, N. (2010). Persistence of highly pathogenic avian influenza virus



- (H7N1) in infected chicken: feather as a suitable sample for diagnosis. *Journal of General Virology*. doi: 10.1099/vir.0.021592-0.
- Campitelli, L., Di Martino, A., Spagnolo, D., Smith, G.J., Di Trani, L., Facchini, M., ... Donatelli, I. (2008). Molecular analysis of avian H7 influenza viruses circulating in Eurasia in 1999-2005: detection of multiple reassortant virus genotypes. *Journal of General Virology*, 89, 48-59. doi: 10.1099/vir.0.83111-0.
- Capua, I., Marangon, S., Selli, L., Alexander, D.J., Swayne, D.E., Pozza, M. D., Cancellotti, F.M. (1999). Outbreaks of highly pathogenic avian influenza (H5N2) in Italy during October 1997 to January 1998. *Avian Pathology*, 28, 455-460. doi: 10.1080/03079459994470
- Capua, I., Mutinelli, F., Marangon, S. & Alexander, D.J. (2000a). H7N1 Avian influenza in Italy (1999-2000) in intensively reared chickens and turkeys. *Avian Pathology*, 29, 537-543. doi: 10.1080/03079450020016779.
- Capua, I., Mutinelli, F. & Habelvarid, M.H. (2002b). Avian embryo susceptibility to Italian H7N1 avian influenza viruses belonging to different genetic lineages. *Archives of Virology*, 147, 1611-1621. doi: 10.1007/s00705-002-0837-z.
- Denbow, D.M., Duke, G.E. & Chaplin, S.B. (1988). Food intake, gastric secretion, and motility as affected by avian pancreatic polypeptide administered centrally in chickens. *Peptides*, 9, 3, p449-454. doi: 10.1016/0196-9781(88)90146-5.
- Ellis, T.M., Bousfield, R. B., Bissett, L.A., Dyrting, K.C., Luk, G.S.M., Tsim, S.T., Sturm-Ramirez, K., ... Peiris, J.S.M. (2004). Investigation of outbreaks of highly pathogenic H5N1 avian influenza in waterfowl and wild birds in Hong Kong in late 2002. *Avian Pathology*, 33, 5, 492-505. doi: 10.1080/03079450400003601.

- Feldmann, A., Schafer, M.K.-H., Garten, W. & Klenk, H-D. (2000). Targeted infection of endothelial cells by avian influenza virus A/FPV/Rostock/34 (H7N1) in chicken embryos. *Journal of Virology*, 74, 8018-8027.
- Feldmann, A., Looser, N., Wagner, R. & Klenk, H-D. (2001). Targeted influenza virus infection of endothelial cells and leucocytes. *International Congress Series*, 1219, 557–571. doi:10.1016/S0531-5131(01)00397-1.
- Fouchier, R.A.M., Schneeberger, P.M., Rozendaal, F.W., Broekman, J.M., Kemink, S.A.G., Munster, V.J. ... Osterhaus, A.D. M. E. (2004). Avian influenza A virus (H7N7) associated with human conjunctivitis and a fatal case of acute respiratory distress syndrome. *Biological Science and Microbiology*, 101, 1356-1361. doi: 10.1073/pnas.0308352100.
- Fronhoffs, S., Totzke, G., Stier, S., Wernert, N., Rothe, M., Bruning, T., Koch, B., ... Ko, Y. (2002). A method for the rapid construction of cRNA standard curves in quantitative real-time reverse transcription polymerase chain reaction. *Molecular and Cellular Probes*, 16, 99-110. doi:10.1006/mcpr.2002.0405.
- Goletic, T., Gagic, A., Residbegovic, E., Kustura, A. & Kavazovic, A. (2010). Highly pathogenic avian influenza virus subtype H5N1 in mute swans (*Cygnus olor*) in central Bosnia. *Avian Diseases*, 54, 496-501.
- Hooper, P. & Selleck, P. (1998). Pathology of low and high virulent influenza virus infections. In D.E. Swayne & R.D. Slemons (Eds.). *Proceedings of the Fourth International Symposium on Avian Influenza, Athens, GA* (pp. 134-141). US Animal Health Association. Athens, GA. The University of Georgia.
- Jones, Y.J. & Swayne, D.E. (2004). Comparative pathobiology of low and high pathogenicity H7N3 Chilean avian influenza viruses in chickens. *Avian Diseases*, 48, 119-128. doi: 10.1637/7080.

- Joseph, T., McAuliffe, J., Lu, B., Jin, H., Kemble, G. & Subbarao, K. (2007). Evaluation of replication and pathogenicity of avian influenza A H7 subtype 1 viruses in a mouse model. *Journal of Virology*, 81, 10558-10566. doi:10.1128/JVI.00970-07.
- Kawaoka, Y. & Webster, R.G. (1988). Molecular mechanisms of acquisition of virulence in influenza virus in nature. *Microbial Pathogenesis*, 5, 311-318.
- Kishida, N., Sakoda, Y., Eto, M., Sunaga, Y. & Kida, H. (2004). Co-infection of *Staphylococcus aureus* or *Haemophilus paragallinarum* exacerbates H9N2 influenza A virus infection in chickens. *Archives of Virology*, 149, 2095-2104. doi: 10.1007/s00705-004-0372-1.
- Klopfleisch, R., Werner, O., Mundt, E., Harder, T. & Teifke, J.P. (2006) Neurotropism of highly pathogenic avian influenza virus A/chicken/Indonesia/2003 (H5N1) in experimentally infected pigeons (*Columbia livia f. domestica*). *Veterinary Pathology*, 43, 4, 463-70. doi: 10.1354/vp.43-4-463.
- Kobayashi, Y., Horimoto, Y., Kawaoka, Y., Alexander, D.J. & Itakura, C. (1996a). Neuropathological studies of chickens infected with highly pathogenic avian influenza viruses. *Journal of Comparative Pathology*, 114, 131-147. doi:10.1016/S0021-9975(96)80003-X.
- Kobayashi, Y. , Horimoto, T. , Kawaoka, Y. , Alexander, D.J. & Itakura, C. (1996b) Pathological studies of chickens experimentally infected with two highly pathogenic avian influenza viruses. *Avian Pathology*, 25, 285-304. doi: 10.1080/03079459608419142.
- Kreijtz, J.H.C.M., Bodewes, R., van Amerongen, G., Kuiken, T., Fouchier, R.A.M. Osterhaus, A.D.M.E., & Rimmelzwaan, G.F. (2007). Primary influenza A virus infection induces cross-protective immunity against a lethal infection with a

heterosubtypic virus strain in mice. *Vaccine*, 25, 612-620.

doi:10.1016/j.vaccine.2006.08.036.

Kwon, Y-K., Joh, S-J., Kim, M-C., Sung, H-W., Lee, Y-J., Choi, J-G., ... Kim, J-H.

(2005). Highly pathogenic avian influenza (H5N1) in the commercial domestic ducks of South Korea. *Avian Pathology*, 34, 367-370. doi:

10.1080/03079450500181257.

Lipatov, A.S., Krauss, S., Guan, Y., Peiris, M., Rehg, J.E., Perez, D.R. & Webster, R.G.

(2003). Neurovirulence in mice of H5N1 influenza virus genotypes isolated from Hong Kong poultry in 2001. *Journal of Virology*, 77, 3816-3823. doi:

10.1128/JVI.77.6.3816-3823.2003.

Liu, N.Q., Lossinsky, A.S., Popik, W., Li, X., Gujuluva, C., Kriederman, B., Roberts, J.,

... Fiala, M. (2002). Human immunodeficiency virus type 1 enters brain microvascular endothelia by macropinocytosis dependent on lipid rafts and the mitogen-activated protein kinase signaling pathway. *Journal of Virology*, 76, 6689-6700. doi: 10.1128/JVI.76.13.6689-6700.2002.

Löndt, B. Z., Nunez, A., Banks, J., Nili, Hassan, J., Linda K. & Alexander, D. J. (2008)

Pathogenesis of highly pathogenic avian influenza A/turkey/Turkey/1/2005 H5N1 in Pekin ducks (*Anas platyrhynchos*) infected experimentally. *Avian Pathology*, 37, 619- 627. doi: 10.1080/03079450802499126.

Lossinsky, A.S. & Shivers, R.R. (2004). Structural pathways for macromolecular and cellular transport across the blood-brain barrier during inflammatory conditions.

Review. *Histology and Histopathology*, 19, 535-564.

Majde, J.A., Bohnet, S.G., Ellis, G.A., Churchill, L., Leyva-Grado, V., Wu, M.,

Szentirmai, E., Krueger, J.M. (2007). Detection of mouse-adapted human influenza virus in the olfactory bulbs of mice within hours after intranasal

infection. *Journal of Neurovirology*, 13, 399-409. doi:  
10.1080/13550280701427069.

Matsuda, K., Park, C.H., Sunden, Y., Kimura, T., Ochiai, K., Kida, H. & Umemura, T. (2004). The vagus nerve is one route of transneural invasion for intranasally inoculated influenza A virus in mice. *Veterinary Pathology*, 41, 101-107. doi: 10.1354/vp.41-2-101.

Mo, I.P., Brugh, O.J., Fletcher, G. N., Rowland, M. & Swayne, D. E. (1996). Comparative pathology of chickens experimentally inoculated with avian influenza viruses of low and high pathogenicity. *Avian Diseases*, 41, 125-136.

Mori, I., Komatsu, T., Takeuchi, K., Nakakuki, K., Sudo, M. & Kimura, Y. (1995). Viremia induced by influenza. *Microbiology and Pathogenesis*, 19, 237-244. doi:10.1016/S0882-4010(95)90290-2.

Muramoto, Y., Ozaki, H., Takada, A., Park, C-H., Sunden, Y., Umemura, T., ... Kida, H. (2006). Highly pathogenic H5N1 influenza virus causes coagulopathy in chickens. *Microbiology and Immunology*, 50, 73-81.

Mutinelli, F., Capua, I., Terregino, C. & Cattoli, G. (2003). Clinical, gross, and microscopic findings in different avian species naturally infected during the H7N1 low- and high-pathogenicity avian influenza low- and high-pathogenicity avian influenza epidemics in Italy during 1999 and 2000. *Avian Diseases*, 47, 844-848. doi: 10.1637/0005-2086-47.s3.844.

Nakamura, K., Imada, T., Imai, K., Yamamoto, Y., Tanimura, N., Yamada, M., ... Yamaguchi, S. (2008). Pathology of specific-pathogen-free chickens inoculated with H5N1 avian influenza viruses isolated in Japan in 2004. *Avian Diseases*, 52, 8-13. doi: 10.1637/8027-060607-Reg.

- OIE. (2008). Avian Influenza. In: *Manual of Diagnostic test and vaccines for terrestrial animals 2008*. 6<sup>th</sup> edn. Office International des Epizooties (OIE).  
[http://www.oie.int/eng/normes/mmanual/2008/pdf/2.03.04\\_AI.pdf](http://www.oie.int/eng/normes/mmanual/2008/pdf/2.03.04_AI.pdf).
- Pálmai, N., Erdélyi, K., Bálint, Á., Márton, L., Dán, Á., Deim, Z., ... Glávits, R. (2007). Pathobiology of highly pathogenic avian influenza virus (H5N1) infection in mute swans (*Cygnus olor*), *Avian Pathology*, 36, 3, 245-249. doi: 10.1080/03079450701341957.
- Park, C.H., Ishinaka, M., Takada, A., Kida, H., Kimura, T., Ochiai, K. & Umemura, T.T. (2002). The invasion routes of neurovirulent A/Hong Kong/483/97 (H5N1) influenza virus into the central nervous system after respiratory infection in mice. *Archives of Virology*, 147, 1425-1436. doi: 10.1007/s00705-001-0750-x.
- Pasick, Y., Berhane, Y., Hisanaga, T., Kehler, H., Hooper-McGrevy, K., Handel, K., ... Leighton, F. (2010). Diagnostic test results and pathology associated with the 2007 Canadian H7N3 highly pathogenic avian influenza outbreak. *Avian Diseases*, 54, 213–219. doi: 10.1637/8822-040209-Reg.1.
- Pantin-Jackwood, M.J., Swayne, D.E. (2009). Pathogenesis and pathobiology of avian influenza virus infection in birds. *Revue Scientifique Et Technique*, 28, 1, 113-136.
- Perkins, L.E. & Swayne, D.E. (2001). Pathobiology of A/chicken/Hong Kong/220/97 (H5N1) avian influenza virus in seven gallinaceous species. *Veterinary pathology*, 38, 149-64. doi: 10.1354/vp.38-2-149.
- Perkins, L.E. & Swayne, D.E. (2002). Pathogenicity of a Hong Kong-origin H5N1 highly pathogenic avian influenza virus for emus, geese, ducks, and pigeons. *Avian Diseases*, 46, 53-63.

- Perkins, E. & Swayne, D.E. (2003a). Comparative susceptibility of selected avian and mammalian species to a Hong Kong-Origin H5N1 high-pathogenicity avian influenza virus. *Avian Diseases*, 47, 956-967.
- Perkins, E., & Swayne, D.E. (2003b). Varied pathogenicity of a Hong Kong-origin H5N1 avian influenza virus in four passerine species and budgerigars. *Veterinary Pathology*, 40, 1, 14-24. doi: 10.1354/vp.40-1-14.
- Reed, L.J. & Muench, H. (1938). A simple method of estimating fifty percent endpoints. *The American Journal of Hygiene*, 27, 493-497.
- Rigoni, M., Shinya, K., Toffan, A., Milani, A., Bettini, F., Kawaoka, Y., Cattoli, G. & Capua, I. (2007). Pneumo- and neurotropism of avian origin italian highly pathogenic avian influenza H7N1 isolates in experimentally infected mice. *Virology*, 364, 28-35. doi:10.1016/j.virol.2007.02.031.
- Rowe, T., Cho, D. S., Bright, R. A., Zitzow, L. A. & Katz, J. M. (2003). Neurological manifestations of avian influenza viruses in mammals. *Avian Diseases*, 47, 1122-1126.
- Shortridge, K.F., Zhou, N.N., Guan, Y., Gao, P., Ito, T., Kawaoka, Y., Krauss, S., ... Webster, R.G. (1998). Characterization of avian H5N1 influenza viruses from poultry in Hong Kong. *Virology*. 252, 331-342. doi.org/10.1006/viro.1998.9488
- Spackman, E., Senne, D.A., Bulaga, L.L., Myers, T.J., Perdue, M.L., Garber, L.P., ... Suarez, D.L. (2003). Development of real-time RT-PCR for the detection of avian influenza virus. *Avian Diseases*, 47, 1079-1082. doi: 10.1637/0005-2086-47.s3.1079.
- Suarez, D.L., Perdue, M.L., Cox, N., Rowe, T., Bender, C., Huang, J. & Swayne, D.E. (1998). Comparison of highly virulent H5N1 influenza A viruses isolated from humans and chickens from Hong Kong. *Journal of Virology*, 72, 6678-6688.

- Subbarao, K., Klimov, A., Katz, J., Regnery, H., Lim, W., Hall, H., Perdue, M., Cox, N. (1998). Characterization of an avian influenza A (H5N1) virus isolated from a child with a fatal respiratory illness. *Science*, *16*, 393-396. doi: 10.1126/science.279.5349.393.
- Swayne, D.E. (1997). Pathobiology of H5N2 Mexican avian influenza virus infections in chickens. *Veterinary Pathology*, *31*, 557-567. doi: 10.1177/030098589703400603.
- Swayne, D.E. (2007). Understanding the complex pathology of high pathogenicity avian influenza viruses in birds. *Avian Diseases*, *51*, 242-249. doi: 10.1637/7763-110706-REGR.1.
- Swayne, D.E. & Beck, J.R. (2005). Experimental study to determine if low-pathogenicity and high-pathogenicity avian influenza viruses can be present in chicken breast and thigh meat following intranasal virus inoculation. *Avian Diseases*, *49*, 81-85.
- Swayne, D.E. & Halvorson, D.A. (2008). Influenza. In Saif, Y.M., Fadly, A.M., Glisson, J.R., McDougald, L. R., Nolan, L. K. & Swayne, D.E. (Eds.), *Diseases of Poultry*. Blackwell Pub, Iowa State Press, Iowa (pp. 153-185).
- Tanaka, H., Park, C., Ninomiya, A., Ozaki, H., Takada, A., Umemura, T. & Kida, H. (2003). Neurotropism of the 1997 Hong Kong H5N1 influenza virus in mice. *Veterinary Microbiology*, *95*, 1-13. doi:10.1016/S0378-1135(03)00132-9.
- Tang, Y., Wu, P., Peng, D., Wang, X., Wan, H., Zhang, P., Long, J., Zhang, W., Li, Y., Wang, W., Zhang, X. & Liu, X. (2009). Characterization of duck H5N1 influenza viruses with differing pathogenicity in mallard (*Anas platyrhynchos*) ducks. *Avian Pathology*, *38*: 6, 457-467. doi: 10.1080/03079450903349147.



- Teifke, J.P., Klopfleisch, R., Globig, A., Starick, E., Hoffmann, B., Wolf, P.U., Beer, ...  
Harder, T.C. (2007). Pathology of natural infections by H5N1 highly pathogenic avian influenza virus in mute (*Cygnus Olor*) and whooper (*Cygnus cygnus*) swans. *Veterinary Pathology*, 44, 137-143. doi: 10.1354/vp.44-2-137.
- Toffan, A., Serena Beato, M., De Nardi, R., Bertoli, E., Salviato, A., Cattoli, G.,  
Terregino, C. & Capua, I. (2008). Conventional inactivated bivalent H5/H7 vaccine prevents viral localization muscles of turkeys infected experimentally with low pathogenic avian influenza and highly pathogenic avian influenza H7N1 isolates. *Avian Pathology*, 37, 407-412. doi: 10.1080/03079450802061124.
- Tweed, S.A., Skowronski, D.M., David, S.T., Larder, A., Petric, M., Lees, W., Li, Y., ... Mak, A. (2004). Human illness from avian influenza H7N3, British Columbia. *Emergent Infectious Diseases*, 10, 2196-2199.
- Van Riel, D., van den Brand, J.M.A., Munster, V.J., Bestebroer, T.M., Fouchier, R.A.M., Osterhaus, A.D.M.E. & Kuiken, T. (2009). Pathology and virus distribution in chickens naturally infected with highly pathogenic avian influenza A virus (H7N7) during the 2003 outbreak in The Netherlands. *Veterinary Pathology*. 46, 971-976. doi: 10.1354/vp.08-VP-0215-K-BC.
- Vascellari, M. Granato, A. Trevisan, L. Basilicata, L. Toffan, A. Milani, A. & Mutinelli, F. (2007). Pathologic findings of highly pathogenic avian influenza virus A/Duck/Vietnam/12/05 (H5N1) in experimentally infected Pekin ducks, based on immunohistochemistry and in situ hybridization. *Veterinary Pathology*, 44, 635-642. doi: 10.1354/vp.44-5-635.
- Verma, S., Lo, Y., Chapagain, M., Lum, S., Kumar, M., Gurjav, U., Luo, H., ... Nerurkar, V.R. (2009). West Nile virus infection modulates human brain microvascular endothelial cells tight junction proteins and cell adhesion

molecules: Transmigration across the in vitro blood-brain barrier. *Virology*, 382, 425-433. doi: 10.1016/j.virol.2008.11.047.

Yamada, M., Mase, M. & Narita, M. (2007). Severe nonpurulent encephalitis with mortality and feather lesions in call ducks (*Anas platyrhyncha var. domestica*) inoculated intravenously with H5N1 highly pathogenic avian influenza virus. *Avian Diseases*, 51, 52-57.

Yamamoto, Y., Nakamura, K., Kitagawa, K., Ikenaga, N., Yamada, M., Mase, M. & Narita, M. (2007). Severe nonpurulent encephalitis with mortality and feather lesions in call ducks (*Anas platyrhyncha var. domestica*) inoculated intravenously with H5N1 highly pathogenic avian influenza virus. *Avian Diseases*, 51, 52-57. doi: 10.1637/0005-2086.

Zanella, A. (2003). Avian influenza attributable to serovar H7N1 in light layers in Italy. *Avian Diseases*, 47, 1177-1180. doi: 10.1637/0005-2086-47.s3.1177.

**Table 1.** *Distribution of AIV nucleoprotein antigen determined by immunohistochemistry in tissue samples from G1 chickens inoculated with H7N1 HPAIV*

Tissue	Days post infection							Positive cells
	1	3	4	5	6	7	10	
Nasal cavity	-	+	+	+	+	+	-	Salivary and nasal epithelial cells (3 to 6 dpi <sup>a</sup> ), olfactory and respiratory epithelial cells, Bowman gland (3-7 dpi), trigeminal nerve branches (day 7), macrophages, heterophils, EC <sup>b</sup> (3 to 7 dpi)
Trachea	-	-	-	-	-	-	-	-
Lung	-	+	+	+	+	+	-	Macrophages, EC
Heart	-	+	+	+	+	+	-	Myocytes, macrophages, EC
Skeletal muscle	-	+	+	+	-	-	-	Myocytes, EC
CNS	-	+	+	+	+	+	-	Neurons, glial cells, ependymal cells, epithelial cells of choroid plexus, EC
Oesophagus	-	+	+	+	+	-	-	EC
Proventriculus	-	+	+	+	+	+	-	Macrophages, heterophils, EC
Gizzard	-	+	+	+	+	+	-	Mucosal epithelium, smooth muscle cells, macrophages, heterophils, EC
Intestine	-	+	+	+	+	-	-	EC
Caecal tonsil	-	+	+	+	+	+	-	Macrophages, heterophils, EC
Pancreas	-	+	+	+	+	+	-	Exocrine acinar cells, Langerhans islets cells, macrophages, EC
Liver	-	+	+	+	+	+	-	Kupffer's cells, EC
Bone Marrow	-	-	-	-	+	-	-	Myeloid cells
Thymus	-	+	+	+	+	-	-	Macrophages, EC
Bursa of Fabricius	-	+	+	+	+	-	-	Macrophages, EC
Spleen	-	+	+	+	+	-	-	Macrophages, EC
Kidney	-	+	+	+	+	+	-	Epithelial tubular cells, EC
Adrenal Gland	-	+	+	+	+	+	-	Corticotrophic and chromaffin cells, macrophages, EC
Skin	-	+	+	+	+	+	-	Keratinocytes, feather pulp inflammatory cells and follicular epithelial cells, macrophages, heterophils, EC

<sup>a</sup> dpi: days post infection, <sup>b</sup> EC: Endothelial cells.

**Figure legends.**

**Figure 1.** *Immunohistochemical detection of Influenza A viral nucleoprotein in the nasal cavity of SPF chickens inoculated intranasally with  $10^{5.5}$  ELD<sub>50</sub> of H7N1 A/Chicken/Italy/5093/99 at 7 dpi. Epithelial necrosis in the transition between respiratory and olfactory epithelium of the nasal cavity, associated with the presence of viral antigen (brown staining) in the olfactory (arrow), and respiratory epithelial cells, Bowman glands (a), mucous glands (b) and inflammatory cells in lamina propria from a G1 chicken at 7 dpi.*

**Figure 2.** *Immunohistochemical detection of Influenza A viral nucleoprotein in the liver of SPF chickens inoculated intranasally with  $10^{5.5}$  ELD<sub>50</sub> (G1) of H7N1 A/Chicken/Italy/5093/99 at 5 dpi. Influenza A viral antigen detected in Kupffer cells, endothelial cells and mononuclear intravascular cells in the liver.*

**Figure 3.** *Immunohistochemical detection of Influenza A viral nucleoprotein in the spinal cord of SPF chickens inoculated intranasally with  $10^{5.5}$  ELD<sub>50</sub> (G1) of H7N1 A/Chicken/Italy/5093/99 at 3 dpi. Viral antigen was detected on ependymal cells surrounding the central canal and in the nearest glial cells and neurons in the gray matter from a G1 chicken at 3dpi.*

**Figure. 4.** *Viral RNA detected by quantitative real time RT-PCR (RT-qPCR) expressed as log<sub>10</sub> viral RNA copies per g of tissue in samples of SNC, lung, intestine, and kidney collected from day 1 to 10 in G1 (A) birds and from day 1 to 16 in group G2 (B) and G3 (C). Rates above the bars indicate the relation between positive birds and the total of*

animals examined. Limit of the detection is indicated by the dashed line ( $2.28 \log_{10}$  viral RNA copies/gram of tissue).

**Figure 5.** Viral RNA levels detected by RT-qPCR in 1 ml oropharyngeal and cloacal swabs obtained from day 1 to 10 in G1 (A) birds and from day 1 to 16 in group G2 (B) and G3 (C). The dotted line indicates the limit of the detection. Rates above the bars indicate the relation between positive birds and the total of animals examined. Limit of the detection is indicated by the dashed line ( $1.46 \log_{10}$  viral RNA copies /ml).

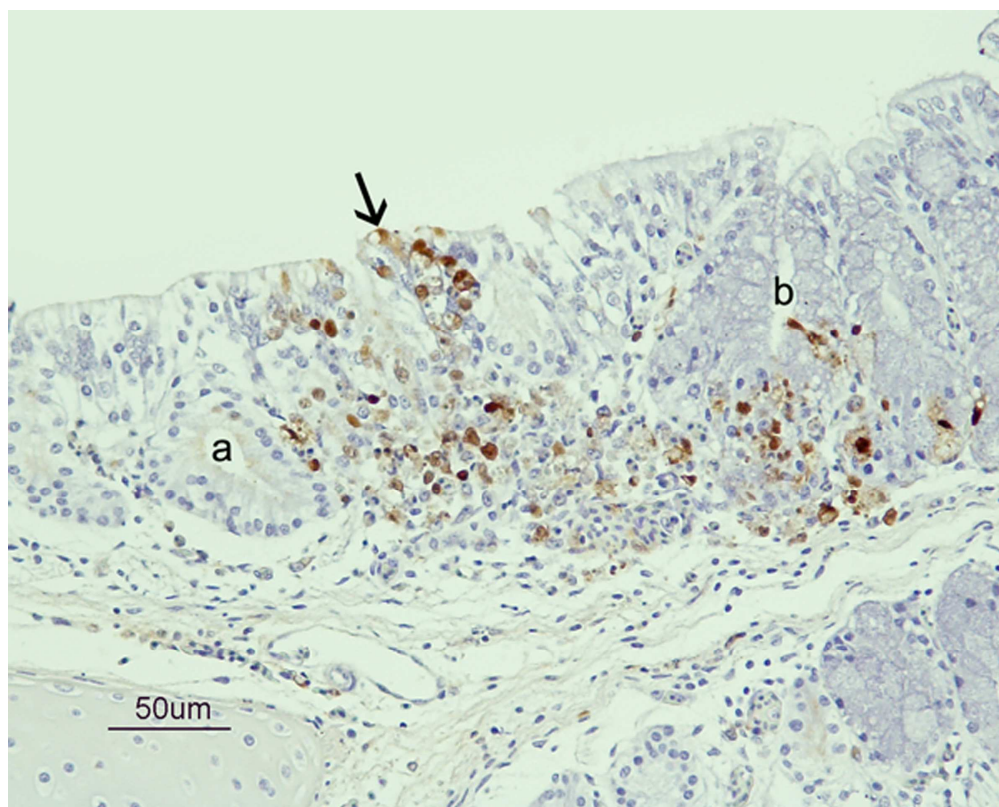


Figure 1. Immunohistochemical detection of Influenza A viral nucleoprotein in the nasal cavity of SPF chickens inoculated intranasally with 105.5 ELD<sub>50</sub> of H7N1 A/Chicken/Italy/5093/99 at 7 dpi. Epithelial necrosis in the transition between respiratory and olfactory epithelium of the nasal cavity, associated with the presence of viral antigen (brown staining) in the olfactory (arrow), and respiratory epithelial cells, Bowman glands (a), mucous glands (b) and inflammatory cells in lamina propria from a G1 chicken at 7 dpi.  
101x81mm (600 x 600 DPI)

Only

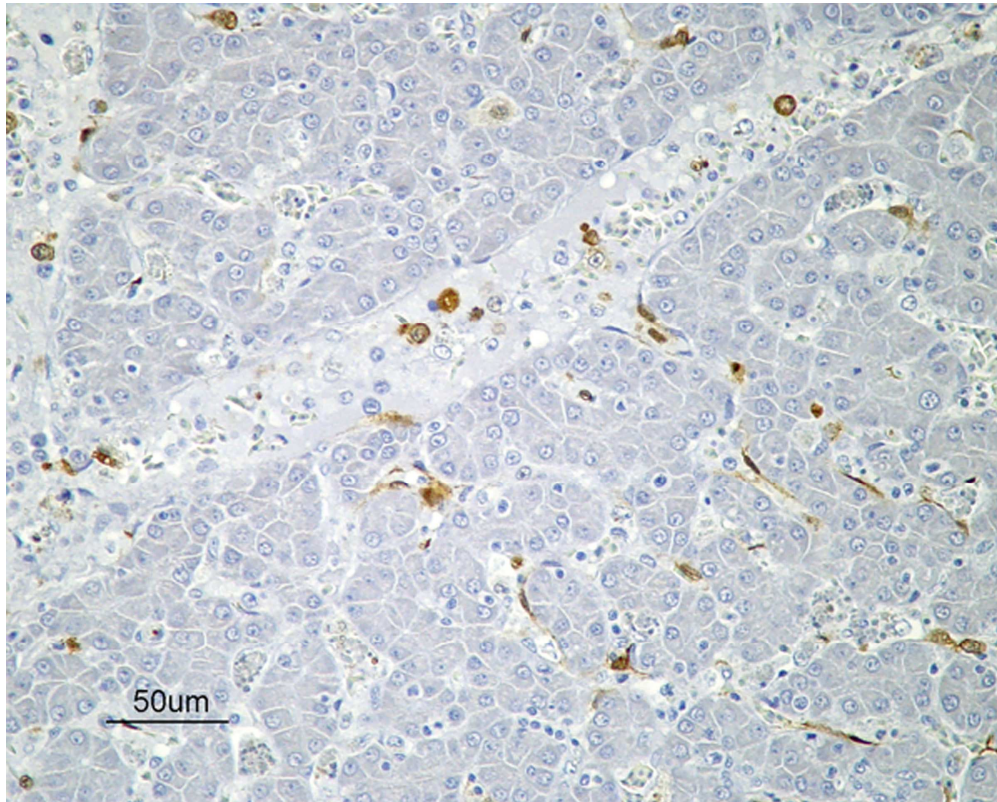


Figure 2. Immunohistochemical detection of Influenza A viral nucleoprotein in the liver of SPF chickens inoculated intranasally with 105.5 ELD<sub>50</sub> (G1) of H7N1 A/Chicken/Italy/5093/99 at 5 dpi. Influenza A viral antigen detected in Kupffer cells, endothelial cells and mononuclear intravascular cells in the liver.  
101x81mm (600 x 600 DPI)

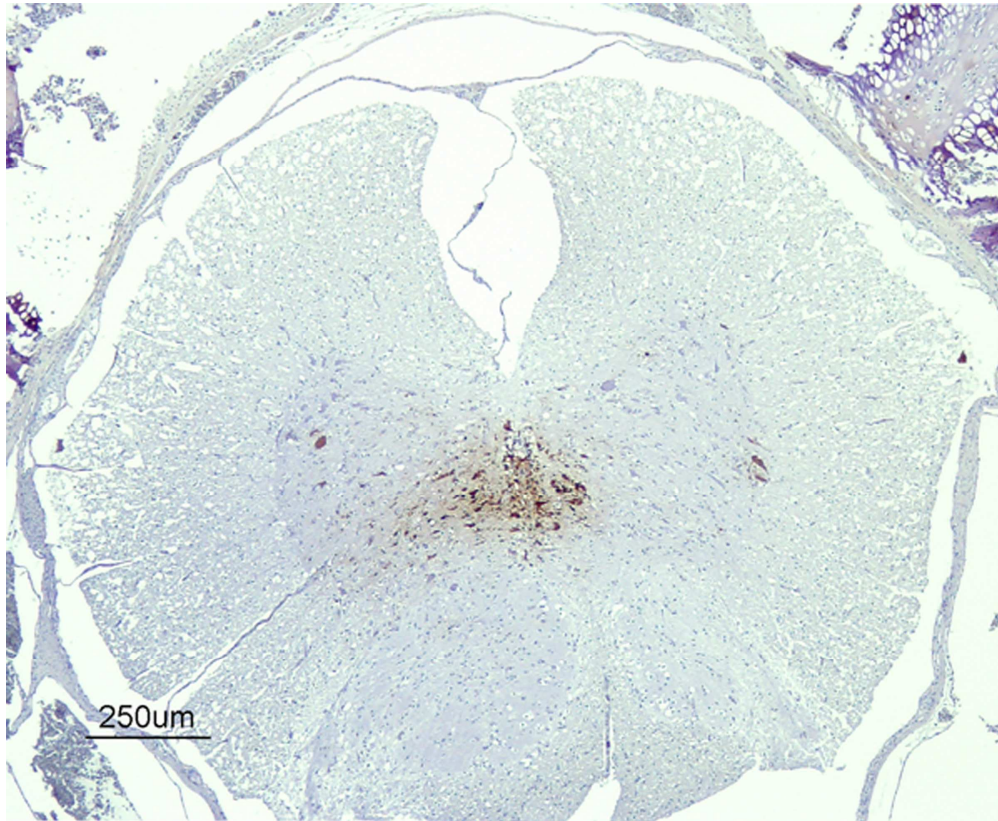


Figure 3. Immunohistochemical detection of Influenza A viral nucleoprotein in the spinal cord of SPF chickens inoculated intranasally with 105.5 ELD50 (G1) of H7N1 A/Chicken/Italy/5093/99 at 3 dpi. Viral antigen was detected on ependymal cells surrounding the central canal and in the nearest glial cells and neurons in the gray matter from a G1 chicken at 3dpi.  
101x83mm (600 x 600 DPI)



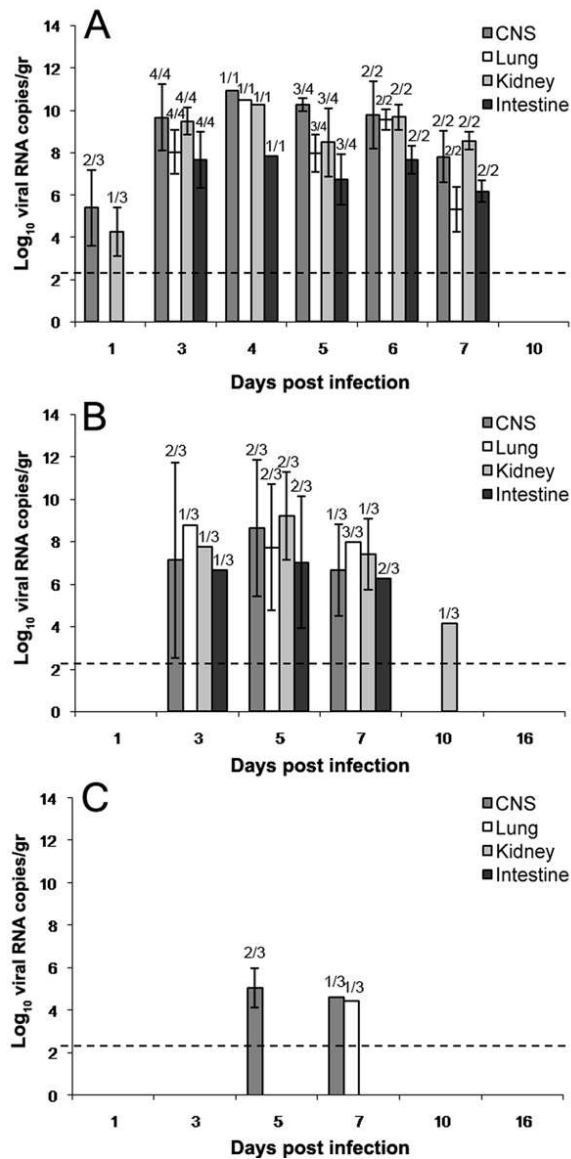


Figure 4. Viral RNA detected by quantitative real time RT-PCR (RT-qPCR) expressed as log<sub>10</sub> viral RNA copies per g of tissue in samples of SNC, lung, intestine, and kidney collected from day 1 to 10 in G1 (A) birds and from day 1 to 16 in group G2 (B) and G3 (C). Rates above the bars indicate the relation between positive birds and the total of animals examined. Limit of the detection is indicated by the dashed line (2.28 log<sub>10</sub> viral RNA copies/gram of tissue).

50x103mm (300 x 300 DPI)

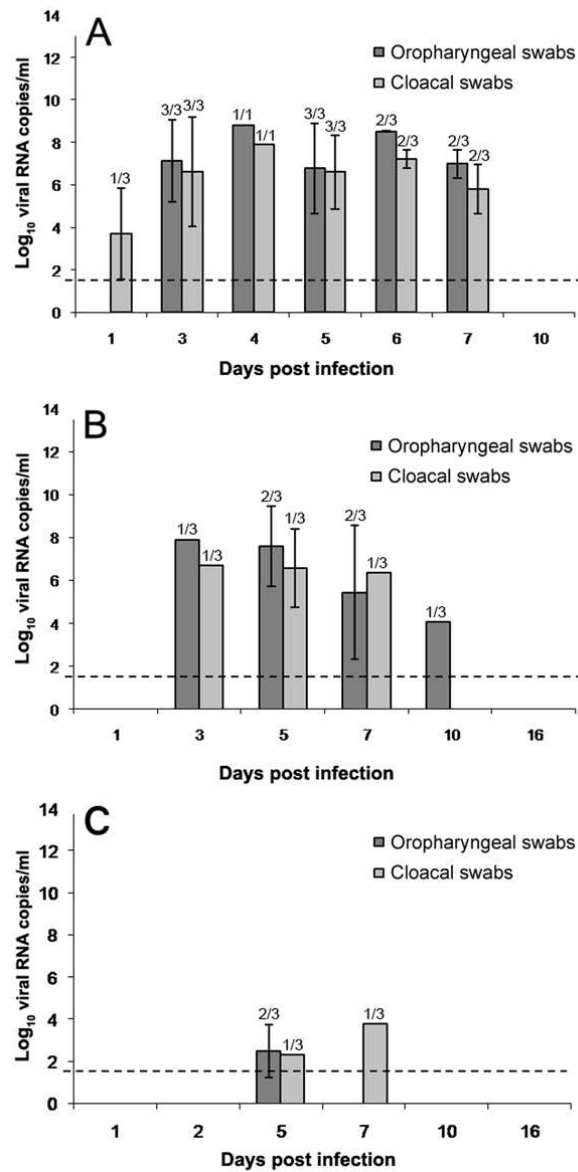


Figure 5. Viral RNA levels detected by RT-qPCR in 1 ml oropharyngeal and cloacal swabs obtained from day 1 to 10 in G1 (A) birds and from day 1 to 16 in group G2 (B) and G3 (C). The dotted line indicates the limit of the detection. Rates above the bars indicate the relation between positive birds and the total of animals examined. Limit of the detection is indicated by the dashed line (1.46 log<sub>10</sub> viral RNA copies /ml).  
50x101mm (300 x 300 DPI)