



HAL
open science

Oncological outcomes in patients undergoing radical nephrectomy and vena cava thrombectomy for renal cell carcinoma with venous extension: a single-centre experience

J. Parra, S.J. Drouin, V. Hupertan, E. Comperat, M.O. Bitker, M. Rouprêt

► **To cite this version:**

J. Parra, S.J. Drouin, V. Hupertan, E. Comperat, M.O. Bitker, et al.. Oncological outcomes in patients undergoing radical nephrectomy and vena cava thrombectomy for renal cell carcinoma with venous extension: a single-centre experience. *EJSO - European Journal of Surgical Oncology*, 2011, 37 (5), pp.422. <10.1016/j.ejso.2011.01.028>. <hal-00687020>

HAL Id: hal-00687020

<https://hal.science/hal-00687020v1>

Submitted on 12 Apr 2012

HAL is a multi-disciplinary open access archive for the deposit and dissemination of scientific research documents, whether they are published or not. The documents may come from teaching and research institutions in France or abroad, or from public or private research centers.

L'archive ouverte pluridisciplinaire **HAL**, est destinée au dépôt et à la diffusion de documents scientifiques de niveau recherche, publiés ou non, émanant des établissements d'enseignement et de recherche français ou étrangers, des laboratoires publics ou privés.




HAL Authorization

Accepted Manuscript

Title: Oncological outcomes in patients undergoing radical nephrectomy and vena cava thrombectomy for renal cell carcinoma with venous extension: a single-centre experience

Authors: J. Parra, S.J. Drouin, V. Hupertan, E. Comperat, M.O. Bitker, M. Rouprêt



PII: S0748-7983(11)00048-5

DOI: [10.1016/j.ejso.2011.01.028](https://doi.org/10.1016/j.ejso.2011.01.028)

Reference: YEJSO 3123

To appear in: *European Journal of Surgical Oncology*

Received Date: 26 September 2010

Revised Date: 30 December 2010

Accepted Date: 25 January 2011

Please cite this article as: Parra J, Drouin SJ, Hupertan V, Comperat E, Bitker MO, Rouprêt M. Oncological outcomes in patients undergoing radical nephrectomy and vena cava thrombectomy for renal cell carcinoma with venous extension: a single-centre experience, *European Journal of Surgical Oncology* (2011), doi: [10.1016/j.ejso.2011.01.028](https://doi.org/10.1016/j.ejso.2011.01.028)

This is a PDF file of an unedited manuscript that has been accepted for publication. As a service to our customers we are providing this early version of the manuscript. The manuscript will undergo copyediting, typesetting, and review of the resulting proof before it is published in its final form. Please note that during the production process errors may be discovered which could affect the content, and all legal disclaimers that apply to the journal pertain.

ONCOLOGICAL OUTCOMES IN PATIENTS UNDERGOING RADICAL NEPHRECTOMY AND VENA CAVA THROMBECTOMY FOR RENAL CELL CARCINOMA WITH VENOUS EXTENSION: A SINGLE-CENTRE EXPERIENCE

J. Parra,¹ S.J. Drouin,¹ V. Hupertan,¹ E. Comperat,² M.O. Bitker¹ and M. Rouprêt.^{1*}

Departments of Urology¹ and Pathology² of GHU EST, Assistance-Publique Hôpitaux de Paris ; Faculté de Médecine Pierre et Marie Curie, University of Paris VI, Paris, France.

Key Words (MeSH): renal cell carcinoma; vena cava; radical nephrectomy; prognosis; recurrence; survival; morbidity

Running head : Radical nephrectomy and vena cava thrombectomy.

Word Count: abstract (239); manuscript (2560)

* Corresponding author:

Morgan Rouprêt, MD, PhD

Academic Urology Department, Hôpital Pitié

47-83 bvd de l'Hôpital, 75013 Paris, France

E-mail: morgan.roupret@psl.aphp.fr

ABSTRACT

Objective: To report on the effectiveness of the surgical management of renal cell carcinoma (RCC) in patients with a neoplastic thrombus of the vena cava.

Patients and methods: We examined pre- and post-operative clinical data for all patients who had received a nephrectomy for the management of RCC with a neoplastic thrombus of the vena cava between spanning 10 years. The procedure depended on the exact location and size of the thrombus according to the Mayo Clinic and the 2009 TNM classifications.

Results: A total of 32 patients underwent surgery. Eight of these patients had stage I, nine had stage II, six had stage III and nine had stage IV thrombi according to the Mayo Clinic staging, and twenty were T3b, eight were T3c and four were T4 according to the 2009 TNM classifications. An open abdominal approach was performed in patients with stage I and II thrombi, whereas five of the stage III patients and all of the stage IV patients required combined sternotomies. Five patients whose thrombi extended to the right atrium were treated with a cardiac bypass. The complication rate was 53% and the peri-operative mortality rate was 12.5%. The median follow-up interval was 64 months. The overall and cancer-specific five-year survival rates for all stages combined were 47% and 52%, respectively.

Conclusion: Surgical resection remains the first-line treatment for patients with RCC infiltrating the vena cava, but surgical morbidity is prevalent and survival is poor.

INTRODUCTION

Renal cancer is relatively rare and represents only 3.1% of all adult cancers.¹ Extension to the venous system is a feature of cancer progression; however, at diagnosis, venous tumour thrombi are present in only 4-10% of cases.² Invasion of the inferior vena cava is not considered a negative prognostic indicator according to the 2002 TNM classification, and this remained the same following the recent 2009 update.^{3,4} Nevertheless, the gravity of this feature is still under debate.^{5,6} The surgical management of renal cancer with tumour thrombi has evolved substantially since it was first documented in 1913, with the first excision of an intracardiac neoplastic thrombus performed under cardiac bypass in 1970.⁷ Technical advances have progressively yielded more acceptable morbidity and mortality rates, even though surgical excision of neoplastic thrombi is much more complex than radical nephrectomy.⁸⁻¹¹ To date, the number of cases reported in the literature by individual centres is limited, and the available multi-centre studies are retrospective.^{11,12}

Therefore, we wished to review and report the oncological results from our experience with the surgical management of RCC patients with tumour thrombi that had invaded the vena cava.

MATERIALS AND METHODS

Population.

Between 1996 and 2006, 512 cancer patients underwent nephrectomies at our centres. We selected patients who received surgeries for RCC with caval thrombi during this period. The following data were examined retrospectively: age at diagnosis, sex, smoking status,

body mass index, family history, method of diagnosis, tumour size, presence or absence of a tumour thrombus, thrombus localisation, whether the thrombus involved the inferior or superior vena cava according to the Mayo Clinic classification,¹¹ comorbidities, surgical approach, peri-operative blood loss, pre- and post-surgical kidney function, histopathological classification, 2009 TNM stage,³ duration of hospitalisation in the intensive care and floor wards, tumour recurrence, adjuvant treatment, patient progression and survival.

Pre-surgical examination.

The pre-operative evaluation for all patients involved a clinical exam and laboratory tests (creatinine, albumin, haematocrit, electrolytes, coagulation), as well as thoracic, abdominal and pelvic imaging studies.

Surgery.

None of our patients were embolised. The surgical approach was determined by the superior limit of the venous thrombus. For stage I and II diseases, an abdominal approach with a subcostal incision allowed for resection of the thrombus in the retro- and suprahepatic vena cava. For stage III and IV diseases, access to the supradiaphragmatic vena cava was necessary. For stage III disease, this access was achieved either through an abdominal approach, a thoraco-diaphragmatic laparotomy or medial abdominal or subcostal incisions with sternotomy; we chose the approach that was best suited for each patient. For stage IV disease, access to the right atrium required a systematic sternotomy and systematic intervention in the cardiac operating suite.

Complications.

The peri- and immediate post-operative complications were defined according to the Clavien grading system for surgical morbidity.¹³ Events defined as Clavien grade I-II or those that required pharmacological intervention and/or nonprocedural deviation from the routine postoperative course were considered minor complications. Major complications (Clavien grade III-IV-V) were defined as events requiring reoperation or unexpected intensive care unit (ICU) management.

Monitoring.

Patients were seen for follow-up appointments 1, 3 and 6 months after surgery, every six months thereafter for two years, and every year thereafter for laboratory tests and thoracic-abdominal-pelvic scans. In cases of local recurrence or metastasis, appropriate treatment was provided.

Statistical analysis.

All patients were followed from diagnosis until death or until data were censored (and the patient was considered to be alive). Patients who had a follow-up period of less than 6 months were not included in the analysis of censored data. Overall survival was evaluated from the date of surgery to the last follow-up visit or death. Recurrence-free survival was defined as the period between the initial surgery and the subsequent appearance of recurrence or metastasis. Kaplan-Meier survival curves were calculated using censored data and compared by the log-rank test. Univariate analyses were used to assess associations between traditional prognostic factors (stage, Fuhrman grade),

potential prognostic factors (invasion of the caval wall) and survival. Significant variables in the univariate analyses were entered into a multivariate analysis (Cox stepwise-regression). A p-value of less than 0.05 was considered significant. All tests were carried out with the program SPSS[®] v16.0.

RESULTS

Population.

A total of 32 patients with vena caval tumour thrombi were included in this retrospective study. The male to female ratio was 2.2. The mean age at diagnosis was 66 ± 11 years (range 30-82). Eight of these patients had stage I, nine had stage II, six had stage III and nine had stage IV thrombi according to the Mayo Clinic staging, and twenty were T3b, eight T3c and four were T4 according to the 2009 TNM classification. In most cases, the renal tumour was symptomatic; only 12 tumours were incidental findings. The tumour developed in the right kidney in 22 cases. Additional imaging studies were necessary in 14 patients to determine the superior limit of venous involvement (11 MRIs and 3 trans-oesophageal ultrasounds). In few cases, adenopathy ($n = 3$) and/or metastases ($n = 2$) were found preoperatively. The general clinical characteristics of the patients are summarised in Table 1.

Surgery. Excision of the primary tumour and tumour thrombi was achieved in all cases ($n = 32$). A combined open sternotomy was necessary for all stage IV and two stage III cases; anterolateral thoracotomy was necessary for one stage III patient to resect a solitary pulmonary metastasis. Control of the tumour in the right atrium was achieved with cardiac bypass in five cases (two surgical teams operated). The mean duration of

cardiac bypass was 31 ± 18 min (range 15-66). The mean duration of surgery for all stages was 240 ± 108 min (range 100-540).

Involvement of the wall of the vena cava was found in ten cases, of which five were diagnosed by pre-operative imaging studies. Total ($n = 2$) or partial ($n = 1$) resection of the vena cava was required in three cases; venous grafts, either biologic or prosthetic, were unnecessary.

The mean blood loss was 1900 ± 1600 cc (range 400-7000). Twenty-six patients required intra-operative transfusions with approximately 4.3 ± 3.4 (range 1-17) units of packed red blood cells.

Post-operative period and complications.

The peri- and post-operative data are summarised in Table 2. The mean duration of hospitalisation was 13.6 ± 7.8 days (range 1-40), of which 3.6 ± 4.5 were in intensive care (range 0-20).

The complication rate was 53%, and seventeen patients experienced one or more post-operative complications. Overall, five patients experienced minor complications, and twelve experienced major complications. Four patients died in intensive care. Three of these patients had received a thoracotomy and died from pulmonary complications; the fourth patient, who had stage I disease, experienced heart failure. No patient required additional surgery in the immediate post-operative period. The following were additional complications: acute renal insufficiency ($n = 8$) that required temporary dialysis in two cases, sepsis of the pulmonary origin ($n = 4$), pulmonary embolism ($n = 1$) and pneumothorax ($n = 1$). No patient required dialysis after the acute post-operative period.

Survival and recurrence.

The median follow-up for all stages occurred at 64 months (range 54-100). The five-year overall survival rate for all stages combined was 47% (Figure 1). The five-year cancer specific survival rate for all stages was 52%. The median survival of patients was 33 months (range 6-122). Eleven patients underwent adjuvant immuno- or antiangiogenic therapy, either for metastases identified during staging (n = 2) or for local or distant recurrences identified at follow-up (n = 9). Seven patients died from disease progression an average of 56 ± 13 months (range 30-81) after surgery.

Local recurrence and/or metastasis were observed in 18 patients (74%). The mean delay until the first recurrence was 38 ± 10 months (range 19-57; median 17). The five-year recurrence-free survival rate for all stages was 18% (Figure 1). Local recurrences were discovered in eight patients after a mean interval of 76 ± 13 months (range 50-101). Four recurrences were in the region of the nephrectomy, and one of these recurrences was accompanied by a recurrence of venous thrombus. There was one recurrence of tumour thrombus alone, and three tumours recurred as retroperitoneal adenopathies, one of which was associated with pulmonary metastases. A single metastatic recurrence was discovered in 11 patients after a mean interval of 55 ± 13 months (range 30-81) from surgery. Local recurrences were treated by surgery alone (n = 2), interferon immunotherapy (n = 2) or anti-angiogenic therapy (n = 2). A unique instance of both local recurrence and metastasis was treated by interferon. Metastases were treated by interferon (n = 1), chemotherapy (n = 2), anti-angiogenic therapy (n = 2) or surgery alone (n = 2). The overall survival rate at five years for all disease stages was 47% (Figure 1).

The overall five-year survival rate for patients without nodal metastases was 55% compared to 0% for patients with N+ disease.

Univariate analyses revealed that ECOG performance status and Furhman grade expression were both significant factors in survival ($p=0.01$, $p=0.022$, respectively) but not venous involvement, regardless of whether that involvement was sub- or supra-diaphragmatic (i.e., stage and TNM). However, in a multivariate analysis, no factor was found to be an independent prognostic factor.

DISCUSSION

Survival of RCC patients with venous extension.

The survival of RCC patients who had involvement of the vena cava by tumour thrombi over the last twenty years has already been described.^{8,14-19} The rate of overall survival in our study, 47% at five years, was similar to rates that have been documented in previous studies (Table 4). Concomitant involvement of the vena cava at the time of RCC diagnosis was relatively rare; all previous studies are retrospective, are based on long periods (10-30 years) and have small sample sizes. Despite the weak evidence in these studies, they at least permit us to better comprehend these rare cases in terms of morbidity and mortality and give us an idea of the prognostic validity of venous involvement. We also compared this analysis with our study published in 1998, which described 51 patients who received operations at our centre between 1982 and 1995.²⁰ In that study, we found a five-year patient survival rate of 36% for all stages. The published studies are heterogeneous and in some cases cover periods in excess of 20 years, but the true survival rate for all stages is on the order of 45% after five years (Table 4). The

disease-free survival rate was 18% in our study, which again is consistent with the literature. The traditional prognostic factors are tumour grade and stage. However, the possibility of graduating clinical symptoms for a prognostic purpose has been established^{21,22} and is confirmed by our data because the ECOG performance status was significant. However, other traditional prognostic factors were not found to be significant, likely due to a limited population and lack of power.

TNM staging for RCC with tumour thrombus.

The prognostic significance of venous involvement and tumour thrombus level in RCC remains highly controversial and is still a subject of debate.^{5,6} According to the 2002 TNM classification, the involvement of the inferior vena cava by tumour thrombi is equivalent to involvement of the renal vein.⁴ We have described the difference in survival (overall or disease-free) as a function of the cephalic extension of the thrombus. In view of our high-complication rate, we believe that there is a need of a multidisciplinary surgical approach for this clinical presentation of RCC. In 2004, Kim et al. compared the survival of RCC patients with and without venous invasion (either renal or caval).²³ The risk of recurrence was greater in the group with venous involvement. That same year, Moinzadeh et al. reported on 107 patients and found a significant difference in survival between those with involvement of only the renal vein and those with involvement of the inferior vena cava.^{17,24} There was no decrease in survival as a function of the extension of the thrombus to the superior vena cava. Thus, several groups have called into question how appropriate the 2002 TNM classification is for stratifying patients into T3 and T4 as a function of thrombus site. A new and more precise classification that separates renal

vein from inferior vena cava involvement was proposed in 2005 by a group from the Mayo Clinic.^{25,26} Ficarra et al. also proposed a modification to the 2002 TNM classification that considers the extension of the thrombus to the superior vena cava as a negative prognostic indicator.¹² However, another multi-centre retrospective study of 1192 patients from the same data set that Ficarra used questioned the prognostic validity of this extension.⁶ Finally, the more recently established 2009 TNM classification does not take into account the propositions of Ficarra and Thompson and remained consistent with the 2002 classification with respect to caval thrombi.^{3,4} Thus, some of the sub-stages identified by the 2009 classification have overlapping prognoses, and other sub-stages include patients with heterogeneous outcomes.^{27,28} The minor modifications included in this updated TNM edition may have not responded to the most critical issues regarding the venous extension of the disease.²⁹

Further perspectives for the treatment of RCC with venous extension.

The role of anti-angiogenesis in the management of RCC with venous tumour thrombi is also not well defined. It is important to underline the "dilemma" and the ongoing debate about the role of systemic treatment with new drugs either in the preoperative or in the post-operative setting. In our study, we administered anti-angiogenic agents as a neoadjuvant therapy. The neoadjuvant use of these agents has two distinct objectives: either to enable resection of a lesion that is initially inoperable or to lower the tumour stage and limit peri-operative morbidity. One of the first cases that utilised anti-angiogenic neoadjuvant therapy with sunitinib was published in 2008 for a patient with a

caval thrombus and without documented metastasis.³⁰ This treatment resulted in regression of the caval thrombus so that surgical management was feasible.

Taking into account phase III trials that show a reduction in tumour stage with anti-VEGF therapy,³¹ the first instance of regression of a neoplastic thrombus by sunitinib was reported in 2008.³² That regression, from stage IV to stage II, enabled surgical excision through an abdominal incision, thereby avoiding sternotomy and cardiac bypass.⁹ There is currently no evidence to suggest that thrombus regression improves long-term patient survival, although the risk of clot or metastatic emboli is unknown. The delay until surgery necessitated by neo-adjuvant therapy (14 weeks in our case) is problematic if the tumour is initially resectable. A phase II trial is in progress to evaluate the utility of sunitinib neoadjuvant therapy for non-resectable local tumours.³³

Adjuvant anti-angiogenic therapy is also a complementary approach for surgery. Three studies are in progress in Europe (S-TRAC, SORCE)^{34,35} and the United States (ASSURE)³⁶ to evaluate the benefits of adjuvant treatment in addition to nephrectomy for tumours with poor prognoses; a vena caval thrombus is among the inclusion criteria for the studies.

CONCLUSION

Radical surgical excision remains the gold-standard treatment for RCC with vena caval thrombi and, according to our results, prolongs survival in almost 50% of cases. The prognosis for these tumours is still poor, although surgical morbidity has improved in recent years. The development of anti-angiogenic agents whose precise roles in the treatment of this disease remain to be determined allows for the possibility of multi-

modal treatments combining surgery with targeted therapy in a regimen that will be defined by on-going clinical trials.

REFERENCES

1. Jemal A, Siegel R, Ward E et al.: Cancer statistics, 2009. *CA Cancer J Clin* 2009; **59**: 225-49.
2. Rini BI, Campbell SC and Escudier B: Renal cell carcinoma. *Lancet* 2009; **373**: 1119-32.
3. Sobin L, Gospodarowicz M and Wittekind C: TNM Classification of Malignant Tumours. Urological Tumours. *7th revised edition, Wiley-Blackwell, uicc* 2009: 237-266.
4. Sobin L and Wittekind C: TNM Classification of Malignant Tumours. *6th revised edition, Wiley-Blackwell, UICC* 2002: 1-272.
5. Al Otaibi M, Abou Youssif T, Alkhaldi A et al.: Renal cell carcinoma with inferior vena caval extention: impact of tumour extent on surgical outcome. *BJU Int* 2009; **104**: 1467-70.
6. Wagner B, Patard JJ, Mejean A et al.: Prognostic value of renal vein and inferior vena cava involvement in renal cell carcinoma. *Eur Urol* 2009; **55**: 452-9.
7. Marshall VF, Middleton RG, Holswade GR et al.: Surgery for renal cell carcinoma in the vena cava. *J Urol* 1970; **103**: 414-20.
8. Ciancio G, Manoharan M, Katkooori D et al.: Long-term Survival in Patients Undergoing Radical Nephrectomy and Inferior Vena Cava Thrombectomy: Single-Center Experience. *Eur Urol* 2010; **57**: 667-672.
9. Ciancio G, Shirodkar SP, Soloway MS et al.: Renal carcinoma with supradiaphragmatic tumor thrombus: avoiding sternotomy and cardiopulmonary bypass. *Ann Thorac Surg* 2010; **89**: 505-10.
10. Rigaud J, Hetet JF, Braud G et al.: Surgical care, morbidity, mortality and follow-up after nephrectomy for renal cancer with extension of tumor thrombus into the inferior vena cava: retrospective study since 1990s. *Eur Urol* 2006; **50**: 302-10.

11. Zini L, Koussa M, Haulon S et al.: Results of endoluminal occlusion of the inferior vena cava during radical nephrectomy and thrombectomy. *Eur Urol* 2008; **54**: 778-83.
12. Ficarra V, Galfano A, Guille F et al.: A new staging system for locally advanced (pT3-4) renal cell carcinoma: a multicenter European study including 2,000 patients. *J Urol* 2007; **178**: 418-24.
13. Dindo D, Demartines N and Clavien PA: Classification of surgical complications: a new proposal with evaluation in a cohort of 6336 patients and results of a survey. *Ann Surg* 2004; **240**: 205-13.
14. Chatelain C, Jardin A, Bitker MO et al.: Treatment of neoplastic thromboses of the inferior vena cava secondary to adenocarcinomas of the kidney. Study of 40 cases. *Ann Urol (Paris)* 1986; **20**: 129-35.
15. Glazer AA and Novick AC: Long-term followup after surgical treatment for renal cell carcinoma extending into the right atrium. *J Urol* 1996; **155**: 448-50.
16. Lubahn JG, Sagalowsky AI, Rosenbaum DH et al.: Contemporary techniques and safety of cardiovascular procedures in the surgical management of renal cell carcinoma with tumor thrombus. *J Thorac Cardiovasc Surg* 2006; **131**: 1289-95.
17. Moinzadeh A and Libertino JA: Prognostic significance of tumor thrombus level in patients with renal cell carcinoma and venous tumor thrombus extension. Is all T3b the same? *J Urol* 2004; **171**: 598-601.
18. Skinner DG, Pritchett TR, Lieskovsky G et al.: Vena caval involvement by renal cell carcinoma. Surgical resection provides meaningful long-term survival. *Ann Surg* 1989; **210**: 387-94.
19. Ciancio G, Livingstone AS and Soloway M: Surgical management of renal cell carcinoma with tumor thrombus in the renal and inferior vena cava: the University of Miami experience in using liver transplantation techniques. *Eur Urol* 2007; **51**: 988-95.
20. Lebret T, Bohin D, Richard F et al.: Renal tumor with thrombus involving all of the lumen of the inferior vena cava: surgical indication, technique and results. *Prog Urol* 1998; **8**: 352-7.

21. Patard JJ, Leray E, Cindolo L et al.: Multi-institutional validation of a symptom based classification for renal cell carcinoma. *J Urol* 2004; **172**: 858-62.
22. Schips L, Lipsky K, Zigeuner R et al.: Impact of tumor-associated symptoms on the prognosis of patients with renal cell carcinoma: a single-center experience of 683 patients. *Urology* 2003; **62**: 1024-8.
23. Kim HL, Zisman A, Han KR et al.: Prognostic significance of venous thrombus in renal cell carcinoma. Are renal vein and inferior vena cava involvement different? *J Urol* 2004; **171**: 588-91.
24. Blute ML, Boorjian SA, Leibovich BC et al.: Results of inferior vena caval interruption by greenfield filter, ligation or resection during radical nephrectomy and tumor thrombectomy. *J Urol* 2007; **178**: 440-5.
25. Thompson RH, Cheville JC, Lohse CM et al.: Reclassification of patients with pT3 and pT4 renal cell carcinoma improves prognostic accuracy. *Cancer* 2005; **104**: 53-60.
26. Leibovich BC, Cheville JC, Lohse CM et al.: Cancer specific survival for patients with pT3 renal cell carcinoma-can the 2002 primary tumor classification be improved? *J Urol* 2005; **173**: 716-9.
27. Eggener S: TNM staging for renal cell carcinoma: time for a new method. *Eur Urol* 2010; **58**: 517-21.
28. Martinez-Salamanca JI, Huang WC, Millan I et al.: Prognostic Impact of the 2009 UICC/AJCC TNM Staging System for Renal Cell Carcinoma with Venous Extension. *Eur Urol* 2011; **59**: 120-127.
29. Novara G, Ficarra V, Antonelli A et al.: Validation of the 2009 TNM version in a large multi-institutional cohort of patients treated for renal cell carcinoma: are further improvements needed? *Eur Urol* 2010; **58**: 588-95.
30. Robert G, Gabbay G, Bram R et al.: Case study of the month. Complete histologic remission after sunitinib neoadjuvant therapy in T3b renal cell carcinoma. *Eur Urol* 2009; **55**: 1477-80.
31. Escudier B, Pluzanska A, Koralewski P et al.: Bevacizumab plus interferon alfa-2a for treatment of metastatic renal cell carcinoma: a randomised, double-blind phase III trial. *Lancet* 2007; **370**: 2103-11.

32. Karakiewicz PI, Suardi N, Jeldres C et al.: Neoadjuvant sunitinib induction therapy may effectively down-stage renal cell carcinoma arterial thrombi. *Eur Urol* 2008; **53**: 845-8.
33. Margulis V and Wood CG: Pre-surgical targeted molecular therapy in renal cell carcinoma. *BJU Int* 2009; **103**: 150-3.
34. S-TRAC trial: A Clinical Trial Comparing Efficacy And Safety Of Sunitinib Versus Placebo For The Treatment Of Patients At High Risk Of Recurrent Renal Cell Cancer. <http://www.clinicaltrials.gov/ct/show/NCT00375674>.
35. SORCE trial: Sorafenib in Treating Patients at Risk of Relapse After Undergoing Surgery to Remove Kidney Cancer. <http://clinicaltrials.gov/ct/show/NCT00492258>.
36. ASSURE trial: Sunitinib or Sorafenib in Treating Patients With Kidney Cancer That Was Removed By Surgery. <http://clinicaltrials.gov/ct2/show/NCT00326898>.

FIGURE TITLES AND LEGENDS

Figure 1. Overall survival curve (A) and recurrence-free survival curve (B) for 32 patients after surgical treatment for renal cell carcinoma extending into the vena cava.

ACCEPTED MANUSCRIPT

Table 1. Clinical and histopathological characteristics of patients and tumours (N=32)

	N (%)
SEX	
Male	22 (68)
Female	10 (32)
ECOG PS	
0	0
≥ 1	32 (100)
IMC	
<30	26 (82)
>30	6 (18)
Tobacco exposure	17 (53)
Symptomatic character of the masses	
Asymptomatic	12 (37.5)
Hematuria	8 (25)
Systemic symptoms	8 (25)
Lumbar pain	4 (12.5)
Right kidney	22 (68)
Left kidney	10 (32)
Stage of thrombus according to the Mayo Clinic classification ¹¹	
I	8 (25)
II	9 (27.5)
III	6 (20)
IV	9 (27.5)
2009 TNM stage ³	
T3b	20 (63)
T3c	8 (25)
T4	4 (12.5)
N+	4 (12.5)
M+	6 (18)

Table 2. Peri- and post-operative patient data

Mayo Clinic Stage	I	II	III	IV	Total
N	8	9	6	9	32
Mean blood loss (cc)	3400	1200	1600	2600	1900
Mean transfusion (<i>units of packed red blood cells</i>)	4.5	2.3	3.5	6.7	4.3
Sternotomy/thoracotomy	0	0	1/1	9/0	10 /1
Cardiac bypass	0	0	0	5	5
Mean duration of operation (minutes)	205	165	203	369	240
Involvement of vascular wall	3	3	1	3	10
Mean duration of hospital stay					
Intensive care	2	1.8	3	7.1	3.4
Urology department	13	8.8	15.5	16.7	13.6
Minor complications (Clavien I-II)	4	0	1	0	5
Major complications (Clavien III-IV-V)	2	2	1	7	12
Peri-operative mortality	1	0	0	3	4
Adjuvant treatment	3	3	3	2	11

Table 3. Mean length of survival according to recognised prognostic factors in RCC.

Patients (N)	Mean length of overall survival (95% CI)	Mean length of survival without recurrence (95% CI)
Stage		
I (8)	81 (35-128)	19 (0-37)
II (9)	69 (50-88)	39 (18-60)
III (6)	62 (27-97)	41 (0-82)
IV (9)	60 (41-79)	36 (13-58)
2009 TNM stage		
T3b (20)	71 (35-128)	36 (0-82)
T3c (8)	66 (53-97)	31 (0-41)
T4 (4)	46 (27-53)	22 (6-28)
ECOG Score		
0 (0)		
1 (12)	84 (50-118)	39 (10-68)
2 (17)	68 (51-84)	29 (17-41)
3 (3)	33 (25-39)	6 (6-6)
Fuhrman Grade *		
1-2 (11)	85 (53-117)	38 (20-56)
3-4 (20)	69 (39-101)	32 (9-56)
N+ (4)	33 (26-39)	5 (4-6)
N- (28)	85 (62-109)	43 (22-65)
Cardiac bypass		
Required (5)	49 (16-84)	20 (0-51)
Unnecessary (27)	76 (52-100)	42 (20-65)
Invasion of the caval wall		
Yes (10)	62 (47-76)	29 (8-50)
No (22)	74 (47-101)	34 (15-58)

* one adrenocortical carcinoma

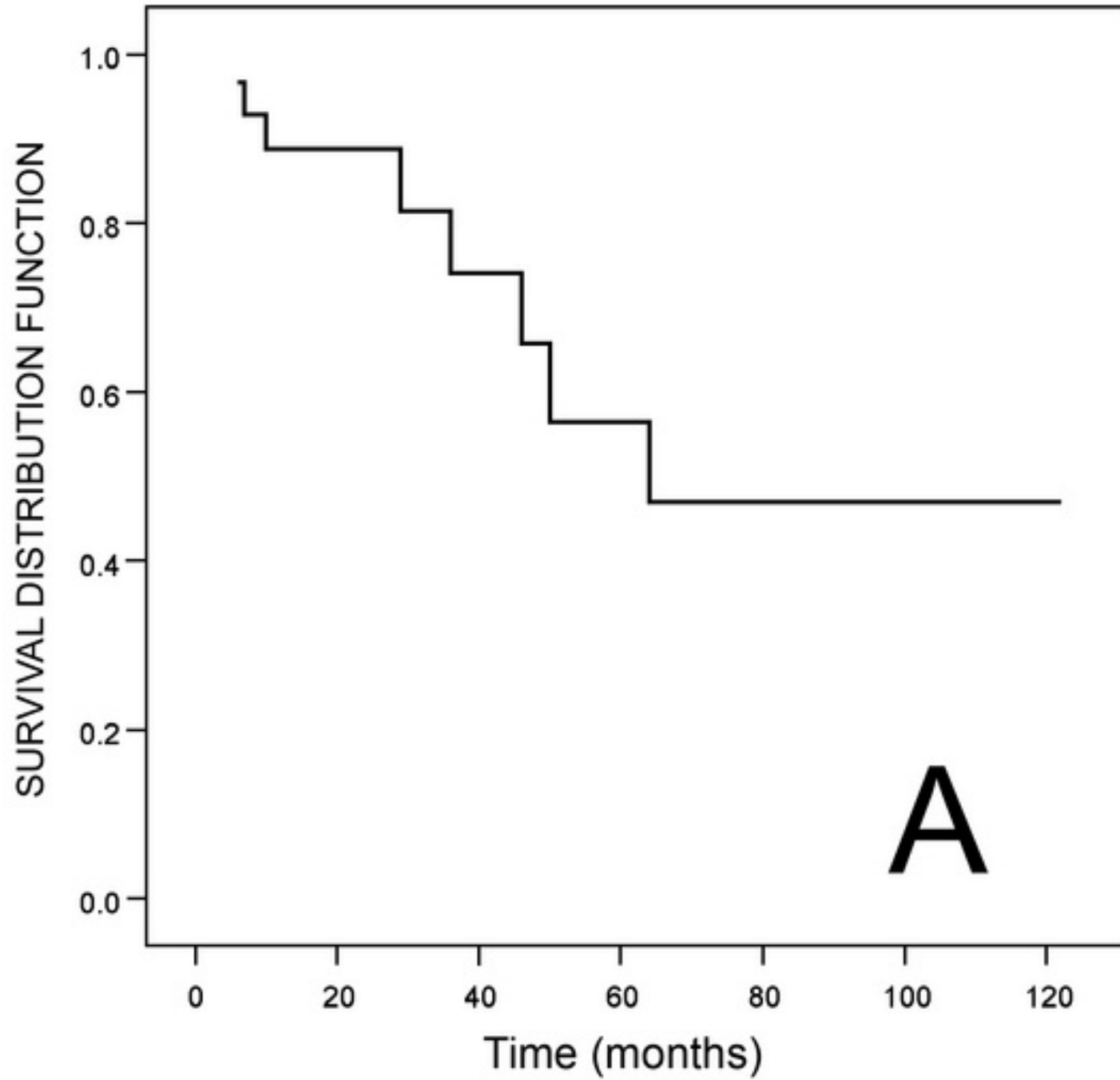
Table 4 : Overall 5-year survival for all stages in main recent publications

	Year of publication	Number of cases	Overall survival (%)	5-year
Chatelain et al., ¹⁴	1986	40	9.5*	
Skinner et al., ¹⁸	1989	43	57	
Glazer et al., ¹⁵	1996	18	18	
Lebret et al., ²⁰	1998	51	31	
Moinzadeh et al., ¹⁷	2004	97	29 (10 year)	
Lubahn et al., ¹⁶	2006	44	56	
Rigaud et al., ¹⁰	2006	40	38.7	
Ciancio et al., ¹⁹	2007	56	66 (3 year)	
Ficarra et al., ¹²	2007	87	60 † 27% ‡	
Al Otaibi et al., ⁵	2009	50	47	
Cianco et al., ⁸	2009	87	39	
Current study	2010	32	47	

*21 patients operated on and followed

†Inferior vena cava involvement

‡Superior vena cava involvement

[Click here to download high resolution image](#)

[Click here to download high resolution image](#)