



HAL
open science

Strategies for patients with newly diagnosed oral squamous cell carcinoma and a positive chest CT. A cohort study on the effects on treatment planning and incidence

G.W. Jaspers, M.J. Witjes, H.J. Groen, H. Groen, L.A. Rödiger, J.L. Roodenburg

► To cite this version:

G.W. Jaspers, M.J. Witjes, H.J. Groen, H. Groen, L.A. Rödiger, et al.. Strategies for patients with newly diagnosed oral squamous cell carcinoma and a positive chest CT. A cohort study on the effects on treatment planning and incidence. *EJSO - European Journal of Surgical Oncology*, 2011, 37 (3), pp.272. 10.1016/j.ejso.2010.12.012 . hal-00668063

HAL Id: hal-00668063

<https://hal.science/hal-00668063>

Submitted on 9 Feb 2012

HAL is a multi-disciplinary open access archive for the deposit and dissemination of scientific research documents, whether they are published or not. The documents may come from teaching and research institutions in France or abroad, or from public or private research centers.

L'archive ouverte pluridisciplinaire **HAL**, est destinée au dépôt et à la diffusion de documents scientifiques de niveau recherche, publiés ou non, émanant des établissements d'enseignement et de recherche français ou étrangers, des laboratoires publics ou privés.

Accepted Manuscript

Title: Strategies for patients with newly diagnosed oral squamous cell carcinoma and a positive chest CT. A cohort study on the effects on treatment planning and incidence

Authors: G.W. Jaspers, MD, DDS M.J. Witjes, MD, DDS, PhD H.J. Groen, MD, PhD H. Groen, MD, PhD L.A. Rödiger, MD, PhD J.L. Roodenburg, DDS, PhD

PII: S0748-7983(10)00611-6

DOI: [10.1016/j.ejso.2010.12.012](https://doi.org/10.1016/j.ejso.2010.12.012)

Reference: YEJSO 3091

To appear in: *European Journal of Surgical Oncology*


Received Date: 7 May 2010

Revised Date: 26 September 2010

Accepted Date: 14 December 2010

Please cite this article as: Jaspers GW, Witjes MJ, Groen HJ, Groen H, Rödiger LA, Roodenburg JL. Strategies for patients with newly diagnosed oral squamous cell carcinoma and a positive chest CT. A cohort study on the effects on treatment planning and incidence, *European Journal of Surgical Oncology* (2010), doi: 10.1016/j.ejso.2010.12.012

This is a PDF file of an unedited manuscript that has been accepted for publication. As a service to our customers we are providing this early version of the manuscript. The manuscript will undergo copyediting, typesetting, and review of the resulting proof before it is published in its final form. Please note that during the production process errors may be discovered which could affect the content, and all legal disclaimers that apply to the journal pertain.



Strategies for patients with newly diagnosed oral squamous cell carcinoma and a positive chest CT. A cohort study on the effects on treatment planning and incidence.

G.W. Jaspers, MD, DDS ^a, M.J. Witjes, MD, DDS, PhD ^a, H.J. Groen, MD, PhD ^b, H. Groen, MD, PhD ^c, L.A. Rödiger, MD, PhD ^d, J.L. Roodenburg, DDS, PhD ^a

^a Department of Oral and Maxillofacial Surgery, University Medical Center Groningen, Groningen, the Netherlands

^b Department of Pulmonary Diseases, University Medical Center Groningen, Groningen, the Netherlands

^c Department of Epidemiology, University Medical Center Groningen, University of Groningen, the Netherlands

^d Department of Radiology, University Medical Center Groningen, Groningen, the Netherlands

Corresponding author; GWC Jaspers, P.O. Box 30001, 9700 RB, Groningen, The Netherlands. Tel. +31 50 3613840, Fax. +31 50 3612831 E-mail:

g.w.c.jaspers@kchir.umcg.nl

Abstract

The purpose of this study was to establish how often routine CT scan of the chest yields positive findings in patients suffering from oral SCC and how it influences the treatment in terms of extra diagnostic procedures, treatment planning and treatment delay. Costs of this additional diagnostic approach for pulmonary tumors in a selected group were also calculated.

A retrospective study was conducted of a group of 196 patients who were newly diagnosed with a squamous cell carcinoma of the oral cavity between January 2004 and July 2006; 142 hospital files were eligible for reviewing.

In 20 (13%) patients chest abnormalities were observed on CT scan of the chest and in 6 (4%) patients malignancy was pathologically confirmed. Both pulmonary second primary tumors and pulmonary metastases were independent of stage of oral malignancy. We found that additional diagnostic procedures did not significantly lengthen the time interval between first consult and start of treatment. The cost of the screening for pulmonary malignancies in the group was € 8.214 per observed pulmonary malignancy.

We advocate that CT imaging of the chest should be routinely performed in the diagnostic work up of all patients with a newly discovered SCC of the oral cavity, irrespective of the tumor stage of the oral malignancy.

Key Words: Chest CT, Oncology, Treatment delay, Treatment planning, Cost analysis

Introduction

During the process of initial tumor staging of patients suffering from head & neck squamous cell carcinoma (HNSCC), the extent of the imaging required needs to be considered.

According to the National guidelines of the Dutch Cooperative Head and Neck Oncology Group, patients with three or more, bilateral, low jugular or N3-neck lymph node metastasis in the neck have the highest risk for distant metastasis.[1,2,3] In these patients a computed tomogram (CT) of the chest is indicated. For all other patients, a conventional X-ray of the chest is dictated by this guideline to screen for intrapulmonary tumor growth. In current practice a CT however is the golden standard for this purpose.[4,3,5,6,7]

There is a strong rationale for pulmonary diagnostic imaging in patients with SCC of the oral cavity. Besides the importance of excluding pulmonary metastasis, lung carcinoma and SCC of the oral cavity share much of the same etiology. It is therefore known that the patient with a SCC of the oral cavity can have a simultaneous lung carcinoma.[8,9] Incidence reports on these second primary tumors and intrapulmonary metastasis vary from 3% to 19%. This broad variance on risk of intrapulmonary metastasis or synchronous tumor depends on size and location of the squamous cell carcinoma of the head & neck. A tumor more distal in the upper aero digestive tract (larynx e.g.) will show a higher incidence of pulmonary metastasis than one located more proximal such as in the oral cavity.[9,10] Also patients with locally advanced or recurrent tumor show more distant metastasis.[11,12,13,14,15,16] It is this risk-assessment the guideline is based upon. The current Dutch guideline does not consider a diagnostic search for a synchronous second tumor in all HNSCC patients due to the low incidence.[17,18] However, the presence of a second primary pulmonary tumor will have a profound effect on treatment choices and planning. This is a valid reason for screening more extensively patients with newly diagnosed SCC of the oral cavity. The added value of a chest CT is either detecting a lung carcinoma in a curable stage or scaling down the treatment of

the index tumor in case of an incurable lung carcinoma or distant metastasis.[12,19] Known disadvantages of scanning patients with a low risk of distant metastasis are the radiation dose, unnecessary costs and delay in treatment start of the index tumors in case of false positive findings.[20]

The current study was initiated to investigate the value of a CT scan of the chest in newly diagnosed SCC of the oral cavity irrespective the tumor stage. Data were collected from a cohort of patients that was routinely subjected to a CT scan of the head and neck as well as the chest. The objectives of the study were to establish how often this diagnostic approach yields positive findings on a chest CT and how it influences the treatment of the patient in terms of extra diagnostic procedures and treatment delay. Next to this the cost effectiveness of diagnostic imaging for pulmonary tumors in this selected group was calculated.

Patients and methods

Incidence of secondary pulmonary tumors and clinical work up

From a cohort of 196 consecutive patients we selected the hospital files of 142 patients diagnosed with a biopsy proven squamous cell carcinoma in the oral mucosal lining, which were treated with a curative intent at the Department of Oral and Maxillofacial Surgery of the University Medical Center Groningen between January 2004 and July 2006. Information was collected on smoking behavior, disease stage, used imaging technique, additional imaging and start of treatment. Before treatment all patients underwent a diagnostic CT scan of the chest. CT's were performed with a Siemens Sensation 16 multislice and/or a Siemens Sensation 64 multislice scanner (Siemens, Erlangen, Germany) with a slice thickness of 1.5 or 2.5 mm respectively. During CT, 60 ml of contrast medium (Visipaque 320, iodixanol, GE Healthcare, Canada) was administered intravenously at a rate of 2.5 ml per second. A qualified radiologist assessed all CT scans. When reviewing the CT scan, distinction was made in

(1) no abnormalities

(2) non suspicious abnormalities such as micro-calcifications or lymph nodes smaller than 1 centimeter

(3) abnormalities suspicious for distant metastasis in lung parenchyma and/or lung (lymph nodes larger than 1 centimeter, pleural involvement, chest wall lesions)

(4) abnormalities suspicious for a primary carcinoma of the lung (solitary pulmonary nodule with irregular surface)

(5) abnormalities without clear radiological diagnosis that need additional diagnostics or follow up (infectious causes such as tuberculosis or pneumonia or an inflammatory condition such as sarcoidosis).

In case of suspicious findings (item 3, 4 and 5) a chest physician was consulted and subsequently procedures such as whole body FDG-PET, bronchoscopy and Trans-Esophageal Ultra Sound-Fine Needle Aspiration were performed to come to a definitive pulmonary diagnosis. In case of a small lesion (<1 cm) with a low incidence of suspicion a follow-up CT of the chest was performed within a maximum of 6 months. All cases were finalized in a multi-disciplinary panel. During the entire process of work up the following time points were defined:

(1) date of first presentation with known pathology of the index tumor

(2) date of conclusion of the CT scan

(3) date of FDG-PET scan

(4) date of consultation by the expert on pulmonary malignancies

(5) date of initial start of the treatment of the index tumor

The work up time was measured from (1) primary presentation with pathologic evidence to (5) start of the primary treatment.

Cost effectiveness

The extra costs to detect a second primary tumor and distant metastasis in the work up, were calculated by summing up costs of all additional diagnostic procedures (chest CT, FDG-PET and bronchoscopies), as well as costs of consultations and follow-up CT scans of the chest. These costs were divided by the number of patients that benefited from the CT scan to calculate the costs per additional malignancy detected. All diagnostic procedures were valued according to the Dutch tariffs or standard prices as issued by the Dutch Health Care Insurance Board.[21]

Results

Incidence of secondary pulmonary tumors

A total of 142 hospital files were eligible for reviewing because of completeness of required data, and possibility of a curative intent. Demographic and tumor characteristics are described in table 1. In all patients a chest CT was performed routinely. Twenty of 142 had abnormalities on the CT scan of the chest suspicious for malignancy (table 2). After additional diagnostic procedures (whole body FDG-PET, consultation with a chest physician, bronchoscopy) a biopsy proven second primary tumor of the lung was found in 4 patients and distant metastasis from the SCC of the oral cavity in 2 patients (total of 6 patients). The other 14 patients were also assessed with extensive further investigations to finalize a diagnosis on the chest abnormalities, including follow up CT of the chest. No pulmonary malignancies could be found during follow-up CT after 6 months. Tumor characteristics of the index tumors of all 6 true positive patients are described in table 3. This shows an incidence of 4% pulmonary malignancies in SCC of the oral cavity.

The treatment-plan for two patients with lung metastasis from the SCC of the oral cavity was altered from a curative intent to palliative radiotherapy. Two patients that had a primary lung carcinoma underwent a treatment with curative intent for both tumors, and are still free of disease 3 years after treatment. One patient had palliative radiotherapy and one patient was treated completely for his carcinoma of the head and neck and subsequently a thoracotomy, which showed irresectability for his lung carcinoma. In a total of six out of 142 patients the original treatment plan changed.

Clinical work up

The mean work up time (time between the first consult to start of treatment) for all patients was 35 ± 16.5 calendar days. Patients with an unsuspecting (negative) CT scan ($n=132$) had a work up time of 34 ± 16.6 calendar days. For those with a true positive CT scan ($n=6$) the work up time did not differ from those with a false positive CT scan ($n=14$) (41 ± 8.9 days versus 38 ± 18.3 days). The results are summarized in Table 4. These work up times were not statistically different.

Cost effectiveness

We collected all information on the costs of the diagnostic procedures from the Dutch Healthcare research board [21]. Besides the routine CT scan of the chest in all patients, 9 patients underwent a FDG-PET scan and 7 patients underwent a bronchoscopy for confirmation of the imaging diagnosis. All false positive patients underwent a follow up CT scan of the chest after six months. The total costs of 142 CT scans of the chest (€219 per CT), 9 FDG-PET scans (€1.172 per PET scan), 20 consultations with the pulmonary oncologist (€106 per consult), 7 bronchoscopies (€351 per bronchoscopy) and 14 follow-up CT scans of the chest were calculated, and divided by the 6 patients that all benefited from the CT scan. This resulted in the calculated amount of €8.214 per patient benefiting from the CT scan.

Discussion

Incidence of secondary pulmonary tumors

We found malignant lesions on CT scan of the chest in six patients out of 20 CT scans that were suspicious on the CT scan of the chest. Additional diagnostic procedures did not significantly lengthen the time interval between first consult and start of treatment. The costs of the diagnostic imaging for pulmonary malignancies in the group were €8.214 per observed pulmonary malignancy.

The low prevalence of 4% does seem to be within the range of the reported 3 – 19% of pulmonary malignancies.[11,13,14,15] The inclusion of all newly diagnosed SCC patients in the current study without making a selection on risk factors for a lung carcinoma may partially explain the low prevalence. Exclusion of all non-smoking patients would only slightly increase the incidence of pulmonary malignancies to 5.6%. However, the group of non-smokers should not be excluded since pulmonary metastasis of HNSCC can occur irrespective of smoking. In studies with a higher prevalence of pulmonary involvement the data analysis was performed on a selected group. In these studies patients with small head & neck tumors were excluded.[11,13,14,15] Other contributing factors to a higher prevalence are the inclusion of recurrent tumors and the selection of tumors more distally located such as in the hypopharynx and larynx. [9,10]

When analyzing the 6 patients with a proven pulmonary malignancy of this study it appeared that none of these patients met the criteria of the guidelines of the Dutch Cooperative Head and Neck Oncology Group for a CT scan of the chest.[2,3] This can be explained by the fact that the current guideline is based on the likeliness of the occurrence of a distant metastasis and not on the occurrence of a simultaneous second primary lung carcinoma. Both patients that had distant metastasis had stage IV disease without extended cervical lymph node metastasis. The other 4 patients had stage II and III disease and had a simultaneous second primary tumor of the lung without having complaints. All these patients underwent

preoperative screening by the anesthesiologist in preparation of possible resection, which included a plain X-ray of the chest. In all six patients with a positive CT of the chest there were no abnormalities on this X-ray of the chest. Without this diagnostic CT scan of the chest these patients would have underwent an extensive treatment for their index tumor irrespective of their pulmonary involvement. In all 6 patients the CT scan of the chest changed the treatment strategy. In 14 patients additional diagnostics were performed. This burden of imaging tests to exclude those patients with a false positive CT of the chest is a disadvantage of our approach.

Recent lung cancer screening studies found a prevalence between 0.36% - 2.7% at baseline screening, in a population with comparable risk on lung malignancies as our patient cohort.[22,23,24] The prevalence of 4% malignant finding of which 2.7% were primary lung carcinoma in the current study is high compared to these reports. It could be debated that patients with a SCC of the oral cavity may have a somewhat higher susceptibility for developing a second pulmonary tumor in this population of heavy smokers. When screening for second tumors one apparently finds a selection of patients who are more prone to develop malignancies due to smoking.

Clinical work up

Despite the extra diagnostic work up, there was no significant increase in work up time between patients with a true positive and false positive CT scan of the chest. Nor was there an increase in work up time between patients with a true positive or a negative CT scan of the chest. It should be mentioned that because of the retrospective character of the study there was no awareness that this study would be undertaken at the time of the work up. We therefore consider these data to be a reliable reflection of daily clinical practice. The majority of the patients that were screened did not benefit from the CT scan, but since the introduction of fast multislice CT scanners, the extra scan following the head and neck scan gives little extra discomfort. We therefore consider a chest CT as part of the routine

diagnostic work up for patients with a SCC of the oral cavity not as a significant burden for the patient.

Cost effectiveness

The costs of screening programs for breast and cervical cancer in The Netherlands are comparable to the cost per lung carcinoma and/or distant metastasis detected in this study. For breast and cervical cancer these costs are €8.134 and €10.270 for each observed malignancy respectively [25]. In this study costs were calculated to be €8.214 per observed lung malignancy. Given the radical interventions with profound impact on quality of life when treating patients with SCC of the oral cavity, we consider a chest CT as part of the routine diagnostic work up for patients with a SCC of the oral cavity. The 20 chest abnormalities in 142 patients leading to the detection of 6 chest malignancies and a change in management in these patients outweighed the diagnostic burden for the patient. In our daily practice we use the diagram as shown in figure 1, as a guide in our treatment planning.

In conclusion we would like to advocate that CT imaging of the chest should be routinely performed in the diagnostic work up of all patients with a newly discovered SCC of the oral cavity, irrespective of the tumor stage. The burden for the patient is low and additional diagnostics do not delay the start of treatment. From the cost analysis and the impact of the extra diagnostics on the total work up time we found no arguments against integration of this diagnostic tool. A true positive finding changes the treatment plan profoundly and may even improve the chance for survival.

Conflicts of interest: None declared.

References

1. Alvi A, Johnson JT. Development of distant metastasis after treatment of advanced-stage head and neck cancer. *Head Neck* 1997;19:500-505.
2. de BR, Deurloo EE, Snow GB, Leemans CR. Screening for distant metastases in patients with head and neck cancer. *Laryngoscope* 2000;110:397-401.
3. Loh KS, Brown DH, Baker JT, Gilbert RW, Gullane PJ, Irish JC. A rational approach to pulmonary screening in newly diagnosed head and neck cancer. *Head Neck* 2005;27:990-994.
4. Ong TK, Kerawala CJ, Martin IC, Stafford FW. The role of thorax imaging in staging head and neck squamous cell carcinoma. *J Craniomaxillofac Surg* 1999;27:339-344.
5. Tesche S, Habermann CR, Sagowski C, Wenzel S, Metternich FU. [The value of chest CT-scanning for staging of progressed or recurrent head and neck squamous cell carcinomas (HNSCC)]. *Laryngorhinootologie* 2006;85:93-98.
6. Warner GC, Cox GJ. Evaluation of chest radiography versus chest computed tomography in screening for pulmonary malignancy in advanced head and neck cancer. *J Otolaryngol* 2003;32:107-109.
7. Arunachalam PS, Putnam G, Jennings P, Messersmith R, Robson AK. Role of computerized tomography (CT) scan of the chest in patients with newly diagnosed head and neck cancers. *Clin Otolaryngol Allied Sci* 2002;27:409-411.
8. Schildt EB, Eriksson M, Hardell L, Magnuson A. Oral snuff, smoking habits and alcohol consumption in relation to oral cancer in a Swedish case-control study. *Int J Cancer* 1998;77:341-346.
9. Blot WJ, McLaughlin JK, Winn DM, Austin DF, Greenberg RS, Preston-Martin S, Bernstein L, Schoenberg JB, Stemhagen A, Fraumeni JF, Jr. Smoking and drinking in relation to oral and pharyngeal cancer. *Cancer Res* 1988;48:3282-3287.

10. Houghton DJ, Hughes ML, Garvey C, Beasley NJ, Hamilton JW, Gerlinger I, Jones AS. Role of chest CT scanning in the management of patients presenting with head and neck cancer. *Head Neck* 1998;20:614-618.
11. Keski-Santti HT, Markkola AT, Makitie AA, Back LJ, Atula TS. CT of the chest and abdomen in patients with newly diagnosed head and neck squamous cell carcinoma. *Head Neck* 2005;27:909-915.
12. Houghton DJ, McGarry G, Stewart I, Wilson JA, MacKenzie K. Chest computerized tomography scanning in patients presenting with head and neck cancer. *Clin Otolaryngol Allied Sci* 1998;23:348-350.
13. Keith DJ, Ong TK, Martin IC. The role of thoracic computed tomography in staging newly-diagnosed oral squamous cell carcinoma. *Br J Oral Maxillofac Surg* 2006;44:198-202.
14. Mercader VP, Gatenby RA, Mohr RM, Fisher MS, Caroline DF. CT surveillance of the thorax in patients with squamous cell carcinoma of the head and neck: a preliminary experience. *J Comput Assist Tomogr* 1997;21:412-417.
15. Deleyiannis FW, Thomas DB. Risk of lung cancer among patients with head and neck cancer. *Otolaryngol Head Neck Surg* 1997;116:630-636.
16. Jackel MC, Reischl A, Huppert P. Efficacy of radiologic screening for distant metastases and second primaries in newly diagnosed patients with head and neck cancer. *Laryngoscope* 2007;117:242-247.
17. Brouwer J, Bree R, Hoekstra OS, Langendijk JA, Castelijns JA, Leemans CR. Screening for distant metastases in patients with head and neck cancer: what is the current clinical practice? *Clin Otolaryngol* 2005;30:438-443.
18. Ferlito A, Buckley JG, Rinaldo A, Mondin V. Screening tests to evaluate distant metastases in head and neck cancer. *ORL J Otorhinolaryngol Relat Spec* 2001;63:208-211.

19. Reiner B, Siegel E, Sawyer R, Brocato RM, Maroney M, Hooper F. The impact of routine CT of the chest on the diagnosis and management of newly diagnosed squamous cell carcinoma of the head and neck. *AJR Am J Roentgenol* 1997;169:667-671.
20. Tan L, Greener CC, Seikaly H, Rassekh CH, Calhoun KH. Role of screening chest computed tomography in patients with advanced head and neck cancer. *Otolaryngol Head Neck Surg* 1999;120:689-692.
21. Oostenbrink JB, Bouwmans CAM, Koopmanschap MA, Rutten FFH. Manual for cost studies; methods and standard costs for economic evaluations in Health Care. Actualised version 2004.
22. Chong S, Lee KS, Chung MJ, Kim TS, Kim H, Kwon OJ, Choi YH, Rhee CH. Lung cancer screening with low-dose helical CT in Korea: experiences at the Samsung Medical Center. *J Korean Med Sci* 2005;20:402-408.
23. Nawa T, Nakagawa T, Kusano S, Kawasaki Y, Sugawara Y, Nakata H. Lung cancer screening using low-dose spiral CT: results of baseline and 1-year follow-up studies. *Chest* 2002;122:15-20.
24. Carter D, Vazquez M, Flieder DB, Brambilla E, Gazdar A, Noguchi M, Travis WD, Kramer A, Yip R, Yankelevitz DF, Henschke CI. Comparison of pathologic findings of baseline and annual repeat cancers diagnosed on CT screening. *Lung Cancer* 2007;56:193-199.
25. Ekwueme DU, Gardner JG, Subramanian S, Tangka FK, Bapat B, Richardson LC. Cost analysis of the National Breast and Cervical Cancer Early Detection Program: selected states, 2003 to 2004. *Cancer* 2008;112:626-635
26. Henschke CI. Survival of patients with clinical stage I lung cancer diagnosed by computed tomography screening for lung cancer. *Clin Cancer Res* 2007;13:4949-4950.

Table 1: Patient and tumor characteristics

	<i>Non Smoking</i>	<i>Smoking</i>	<i>Quitted Smoking</i>
<i>Smoking habits</i>	42	68	32
<i>Pack years</i>	0	31.45	30.76
<i>Mean patient age</i>	68	65	72
<i>Male / Female</i>	12/30	49/19	28/4
<i>Tumor Stage¹</i>			
I	18	15	9
II	9	16	9
III	2	10	7
IV	13	27	7
<i>Tumor Location</i>			
Tongue	15	12	17
Gingiva	12	18	6
Floor of mouth	4	23	9
Other	11	15	0
Primary Lung carcinoma	0	2	2
Metastasis	0	1	1

¹ According to TNM classification from the UICC 2002

Table 2: Number of patients with pulmonary tumors detected on preoperative CT of the chest.

	<i>Number of patients</i>	<i>%</i>
Total included	142	100
True positive for malignancy	6	4 ¹
False positive for malignancy	14	10
Negative	122	86

¹ Of these 2 patients had distant metastasis of their SCC of the oral cavity and 4 patients had a second primary tumor of the lung. All patients with suspicious CT had either pathological confirmation of the pulmonary tumor or during follow up no signs of malignancy.

Table 3: Tumor characteristics of patients with a pulmonary malignancy .

	<i>Localization primary tumor</i>	<i>Staging</i>	<i>Finding on CT Chest</i>	<i>Treatment goal</i>
Patient 1	Tongue	cT2N0	Primary lung	Curative
Patient 2	Maxilla	cT4N1	Primary lung	Curative
Patient 3	Tongue	cT1N1	Primary lung	Curative ¹
Patient 4	Floor of mouth	cT2N1	Primary lung	Palliative
Patient 5	Mandible	cT4N0	Metastasis	Palliative
Patient 6	Floor of Mouth	cT4N1	Metastasis	Palliative

¹ This patient was treated first for his carcinoma of the tongue. During this procedure, his pulmonary tumor became irresectable. Therefore he continued with chemotherapy for his pulmonary tumour.

Table 4: Comparison between findings on CT Chest and days between first presentation and primary treatment.

<i>Finding on CT Chest</i>	<i>Number of patients</i>	<i>Average calendar days until primary treatment</i>	<i>Average working days until primary treatment</i>	<i>Standard Deviation</i>
Negative	122	34.2	24.2	16.6
False positive	14	37.9 ¹	27.9	18.3
True positive	6	40.8 ²	28.8	8.9

¹ No significant difference in duration until treatment between negative and false positive ($p = 0.43$). ² No significant difference in duration until treatment between negative and true positive ($p = 0.33$).

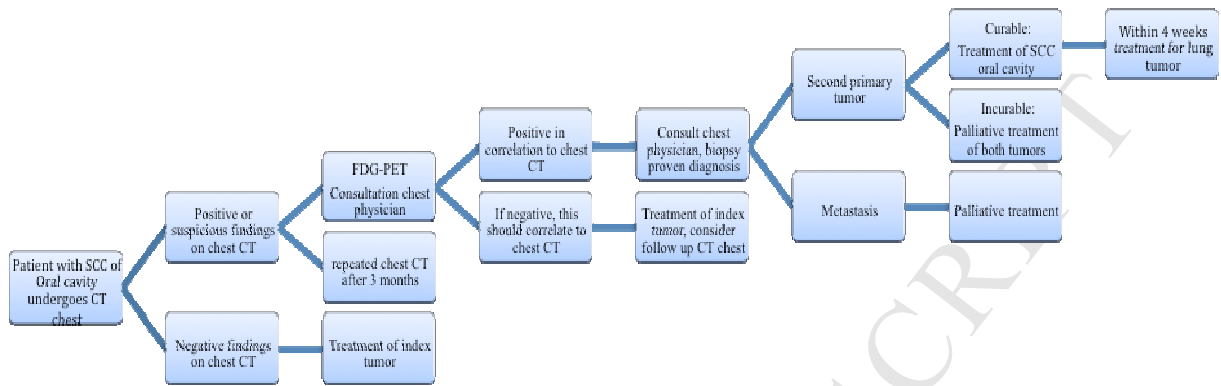


Figure 1. A schematic drawing of a diagnostic and treatment algorithm of patients with oral SCC. In case of a negative chest CT or only benign findings, treatment of the oral cavity SCC should follow. FDG-PET is considered the standard for analysing the lungs on suspicious lymph nodes or lesions. The FDG-PET shows a sensitivity and specificity for detecting distant disease in oral SCC of 92% and 93%, respectively[26,25]. Therefore, findings on a chest CT that do not show uptake on a FDG-PET can be considered negative. In case of a positive FDG-PET it is important that the chest physician determines if it is considered a metastasis or second primary tumor. In case of metastasis palliation is most likely the choice of treatment. When a second primary tumor is present in the lung, a decision should be made whether it is considered potentially curable. If the lung tumor is considered not curable but the oral cavity tumor is, than the average length of survival becomes important. Often the prognosis of a lung tumor extends the average progression of the oral cavity SCC, especially when the lung tumor is an accidental finding on a CT. It can be considered as a adequate form of palliation to treat the oral cavity carcinoma with curative intent, depending on its morbidity and prognosis. When both the lung and oral cavity SCC are considered curable,

the sequence of treatment should be established. Often the oral cavity SCC is treated first since the functional outcome of this tumor worsens sometimes at moderate growth of the tumor, whereas the morbidity of the treatment of the lung tumor most likely does not increase that much when it increases in size.

ACCEPTED MANUSCRIPT