



HAL
open science

A comparison of three methods for nonpalpable breast cancer excision A retrospective multicentre study

N.M.A. Krekel, B.M. Zonderhuis, H.B.A.C. Stockmann, W.H. Schreurs, H. van Der Veen, E.S.M. de Lange de Klerk, S. Meijer, M.P. van den Tol

► **To cite this version:**

N.M.A. Krekel, B.M. Zonderhuis, H.B.A.C. Stockmann, W.H. Schreurs, H. van Der Veen, et al.. A comparison of three methods for nonpalpable breast cancer excision A retrospective multicentre study. *EJSO - European Journal of Surgical Oncology*, 2011, 37 (2), pp.109. 10.1016/j.ejso.2010.12.006 . hal-00663074

HAL Id: hal-00663074

<https://hal.science/hal-00663074>

Submitted on 26 Jan 2012


HAL is a multi-disciplinary open access archive for the deposit and dissemination of scientific research documents, whether they are published or not. The documents may come from teaching and research institutions in France or abroad, or from public or private research centers.

L'archive ouverte pluridisciplinaire **HAL**, est destinée au dépôt et à la diffusion de documents scientifiques de niveau recherche, publiés ou non, émanant des établissements d'enseignement et de recherche français ou étrangers, des laboratoires publics ou privés.

Accepted Manuscript

Title: A comparison of three methods for nonpalpable breast cancer excision A retrospective multicentre study

Authors: N.M.A. Krekel, B.M. Zonderhuis, H.B.A.C. Stockmann, W.H. Schreurs, H. van der Veen, E.S.M. de Lange de Klerk, S. Meijer, M.P. van den Tol



PII: S0748-7983(10)00605-0

DOI: [10.1016/j.ejsso.2010.12.006](https://doi.org/10.1016/j.ejsso.2010.12.006)

Reference: YEJSO 3085

To appear in: *European Journal of Surgical Oncology*

Received Date: 6 September 2010

Revised Date: 17 November 2010

Accepted Date: 6 December 2010

Please cite this article as: Krekel NMA, Zonderhuis BM, Stockmann HBAC, Schreurs WH, van der Veen H, de Lange de Klerk ESM, Meijer S, van den Tol MP. A comparison of three methods for nonpalpable breast cancer excision A retrospective multicentre study, *European Journal of Surgical Oncology* (2010), doi: 10.1016/j.ejsso.2010.12.006

This is a PDF file of an unedited manuscript that has been accepted for publication. As a service to our customers we are providing this early version of the manuscript. The manuscript will undergo copyediting, typesetting, and review of the resulting proof before it is published in its final form. Please note that during the production process errors may be discovered which could affect the content, and all legal disclaimers that apply to the journal pertain.

A comparison of three methods for nonpalpable breast cancer excision

A retrospective multicentre study

Revised version

17 November 2010

N.M.A. Krekel^a, B.M. Zonderhuis^a, H.B.A.C. Stockmann^b, W.H. Schreurs^c, H. van der Veen^d, E.S.M. de Lange de Klerk^e, S. Meijer^a, M.P. van den Tol^a.

^aDepartment of Surgical Oncology, VU University Medical Center, De Boelelaan 1117, 1081 HV Amsterdam, the Netherlands

^bDepartment of Surgical Oncology, Kennemer Gasthuis, Boerhaavelaan 22, 2035 RC Haarlem, the Netherlands

^cDepartment of Surgical Oncology, Medical Centre Alkmaar, Wilhelminalaan 12, 1815 JD Alkmaar, the Netherlands

^dDepartment of Surgical Oncology, Rode Kruis Hospital Beverwijk, Vondellaan 3, 1942 LE Beverwijk, the Netherlands

^eDepartment of Epidemiology and Biostatistics, VU University Medical Center, De Boelelaan 1117, 1081 HV Amsterdam, the Netherlands

Email: NMA Krekel – n.krekel@vumc.nl; BM Zonderhuis – bm.zonderhuis@vumc.nl; HBAC Stockmann – stockmann@kg.nl; HWH Schreurs – w.h.schreurs@mca.nl; H van der Veen – hvanderveen@rkz.nl; ESM de Lange de Klerk – e.s.m.delange-deklerk@vumc.nl; S Meijer – s.meijer@vumc.nl; MP van den Tol – mp.vandentol@vumc.nl

Corresponding author:

N.M.A. Krekel, M.D.

VU University Medical Center

De Boelelaan 1117, Room 7F-020

1081 HV Amsterdam, the Netherlands

Email: n.krekel@vumc.nl

Tel: +31-20-4444400

Fax: +31-20-4444512

Abstract

Aims To evaluate the efficacy of three methods of breast-conserving surgery (BCS) for nonpalpable invasive breast cancer in obtaining adequate resection margins and volumes of resection.

Materials and methods A total of 201 consecutive patients undergoing BCS for nonpalpable invasive breast cancer between January 2006 and 2009 in four affiliated institutions were retrospectively analysed. Patients with pre-operatively diagnosed primary or associated ductal carcinoma in situ (DCIS), multifocal disease, or a history of breast surgery or neo-adjuvant treatment were excluded from the study. The resections were guided by wire localisation (WL), ultrasound (US), or radio-guided occult lesion localisation (ROLL). The pathology reports were reviewed to determine oncological margin status, as well as tumour and surgical specimen sizes. The optimal resection volume (ORV), defined as the spherical tumour volume with an added 1.0-cm margin, and the total resection volume (TRV), defined as the corresponding ellipsoid, were calculated. By dividing the TRV by the ORV, a calculated resection ratio (CRR) was determined to indicate the excess tissue resection.

Results Of all 201 excisions, 117 (58%) were guided by WL, 52 (26%) by US, and 32 (16%) by ROLL. The rate of focally positive and positive margins for invasive carcinoma was significantly lower in the US group (N = 2 (3.7%)) compared to the WL (N = 25 (21.3%)) and ROLL (N = 8 (25%)) groups ($p = 0.023$). The median CRRs were 3.2 (US), 2.8 (WL) and 3.8 (ROLL) (WL versus ROLL, $p < 0.05$), representing a median excess tissue resection of 3.1 times the optimal resection volume.

Conclusion US-guided BCS for nonpalpable invasive breast cancer was more accurate than WL- and ROLL-guided surgery because it optimised the surgeon's ability to obtain adequate margins. The excision volumes were large in all excision groups, especially in the ROLL group.

Keywords: Breast-conserving surgery, Nonpalpable breast cancer, Wire localisation, Ultrasonography, Radio-guided occult lesion localisation (ROLL), Resection volume, Margin status.

Abbreviations: BCS, breast-conserving surgery; WL, wire localisation; US, ultrasonography/ultrasound; ROLL, Radio-guided occult lesion localisation; CRR, calculated resection ratio; TRV, total resection volume; ORV, optimal resection volume; DCIS, ductal carcinoma in situ; WHO, World Health Organisation; SPSS, Statistical Package for the Social Sciences.

Introduction

Breast-conserving surgery (BCS) with adjuvant radiotherapy has become the local treatment of choice for early-stage breast cancer. In recent years, advances in early diagnosis have been achieved by widespread screening mammography, better imaging techniques, improved patient awareness and breast self-examination. As a consequence, the rate of BCS procedures for early-stage, nonpalpable lesions has increased. [1-3]

For these nonpalpable lesions, intra-operative guidance of the excision is indispensable and continues to develop. Wire localisation (WL) is still considered the gold standard for intra-operative tumour localisation. The WL procedure is technically demanding and depends on both the wire placement by the radiologist and on the experience and three-dimensional orientation abilities of the surgeon. The insertion of the wire can be uncomfortable for the patient; also, there is a risk of wire transaction, dislocation, or migration. [4-6] Intra-operative ultrasonography (US) was introduced in 1988 as a method of excising a tumour under direct visualisation. There is no need for additional interventions before surgery, but a possible restriction is the arrangement of a radiologist's presence in the operating theatre. In contrast to ductal carcinoma in situ (DCIS), most invasive lesions are echogenic. In situ lesions are mostly visualised by mammographically observable microcalcifications. [5-12] Recently, the radio-guided occult lesion localisation (ROLL) technique has emerged. In this procedure, a radioactive pharmaceutical is injected into the tumour pre-operatively, and a gamma probe is used to guide the surgical resection. Although the ROLL technique seems promising, failures in the placement of the radioactive tracer and widespread dispersal of the isotope have been described. [13,14]

In daily practice, the main goal of BCS is to achieve tumour-free resection margins and thus prevent local recurrence. However, the cosmetic outcome is receiving increasing attention because of its strong relation to the patient's well-being. [15,16] A number of studies have shown that the cosmetic outcomes following BCS are unacceptable in up to 40% of patients.

Resection of a large volume of breast tissue often proves to be the key determinant of these poor cosmetic outcomes; specifically, a lump size exceeding 50 to 85 cm³ results in a significantly higher rate of cosmetic failures. [17-21]

The aim of this study was to evaluate the efficacy of the three most commonly used methods of BCS for nonpalpable invasive breast cancer in obtaining adequate resection margins and volumes of resection. The excess breast tissue resection was determined using the calculated resection ratio (CRR), representing a comparison of the total resection volume (TRV) to the optimal resection volume (ORV).

Patients and Methods

Patient selection

All consecutive patients undergoing BCS for nonpalpable breast cancer in four affiliated hospitals over a three-year period were identified retrospectively (January 2006–January 2009). The pathology reports were reviewed for patients with invasive breast carcinoma as identified in a surgical specimen. Breast cancer had been diagnosed pre-operatively with mammography, US, and occasionally MRI, followed by image-guided core needle biopsy or cytological puncture. Patients with pre-operatively diagnosed primary or associated DCIS, multifocal disease, a history of neo-adjuvant therapy or previous surgical treatment or radiation therapy of the affected breast were excluded from the study.

Excision methods

The method of tumour excision was reported for all included patients. The three methods that were evaluated were the WL, the US guidance and ROLL techniques. In the WL procedure, a guide wire had been placed under mammographic or US guidance before surgery, and the tumour had been excised by using the wire for localisation. After excision, the specimen had been sent to the radiology department for radiography to check the completeness of the excision. In the US-guided excision, repeated intra-operative imaging with the US probe performed by a radiologist had guided the procedure and enabled the surgeon to maintain an appropriate surgical margin around the malignant tumour. Immediately after specimen removal, the radiologist had checked the completeness of the specimen ex vivo with US. In the ROLL technique, ^{99m}Tc -labelled serum albumin particles had been injected into the tumour prior to the surgical procedure under mammographic or US guidance. A gamma probe had been used to locate the tumour and guide the excision. After excision, the gamma probe had been used to search the resection bed for residual areas of high radioactivity. All surgical procedures had been performed by dedicated breast surgeons or by closely supervised residents. The method utilised had been selected according to the surgeon's

preference and the logistical feasibilities of the institution. In each institution, WL, US guidance or ROLL had been performed. However, when the lesions had not been reliably identifiable by US or when ROLL could not be performed, WL had been used as an alternative.

Tumour characteristics and margin status

The dimensions (in cm) of the surgical specimens, the tumour stage (T1a–T2) and the diameters of the tumours (in cm) as given in the final report were recorded. The following tumour histopathological subtypes were identified: invasive ductal carcinoma, invasive lobular carcinoma, and other types of invasive carcinoma. The presence and amount of tumour-associated DCIS, as found unexpectedly by the pathologist in the surgical specimen, were calculated and categorised. The oncological margin status was reported and defined as negative, focally positive, or positive for either invasive or in situ cancer according to the World Health Organisation (WHO) classification for breast cancer and the Dutch national guidelines. The presence of an additional intraductal component had not been expected by the surgeon. Therefore, the main outcome of resection margins was calculated for invasive carcinoma only. An outcome on the associated DCIS-involved resection margins was considered separately.

Calculations of the volumes and the calculated resection ratios

Both the tumour diameter and the three dimensions of the surgical specimen were used to calculate the ORVs and TRVs. The tumour was defined as a sphere (Fig. 1.a.). An ORV was calculated for each tumour as the spherical tumour volume plus a 1.0-cm margin of healthy breast tissue, calculated by the formula $4/3\pi(r+1.0 \text{ cm})^3$. The TRV was assumed to be ellipsoid and was calculated by the formula $4/3\pi(a \cdot b \cdot c)$ (Fig. 1.b.). If additional tissue was excised during the initial surgery, the final TRV comprised the sum of the resection volumes. CRR was defined to determine the amount of excess breast tissue resected and was

calculated by dividing TRV by ORV ($CRR=TRV/ORV$). In other words, in a perfect excision, in which TRV is equal to ORV, CRR is 1.0. If TRV is twice the size of ORV, CRR is 2.0.

Statistical analyses

The data were analysed using the Statistical Package for the Social Sciences (SPSS statistical software, Version 15.0; SPSS, Inc., Chicago, IL, USA). The medians were calculated. Groups were compared using one-way analysis of variance and the chi-square, Mann-Whitney or Fisher's exact test where appropriate. Univariate analysis was performed to calculate the relationships of the risk factors (tumour size, unexpected tumour-associated DCIS (absent, minor, major), histopathological tumour type, excision method, and institution) with margin positivity. A multivariate model was used to evaluate the influence of the excision method on margin status. The results are presented with the corresponding p-values, and differences were considered significant at $p < 0.05$.

Results

Patient and tumour characteristics

Two hundred and one patients who had been treated for nonpalpable invasive T1–2N0–1 breast carcinoma were identified; surgery was guided by WL in 117 patients (58.2%), by intra-operative US in 52 patients (25.9%), and by ROLL in 32 patients (15.9%). For patient and tumour characteristics, see Table 1. Seventy-five specimens (47.2%) presented with a tumour-associated DCIS component, as found unexpectedly by the pathologist. Most in situ lesions presented inside or within several millimetres surrounding the invasive tumour. There were no differences in patient age, tumour type, presence and amount of tumour-associated DCIS, tumour diameter, or tumour stage amongst the different excision groups (all $p > 0.05$).

Margin status

Table 2 shows the margin statuses for the total group and for the various methods of tumour excision. The tumours were grossly removed with adequately negative surgical margins. The differences amongst the three groups with regard to the margin status of invasive carcinoma were highly significant; focally positive or positive margins presented in 25 WL-guided tumours (21.4%) and in 8 ROLL-guided tumours (25%), whereas in the US-guided group, 2 tumours (3.8%) were focally positive ($p = 0.023$). The unexpected presence of tumour-associated DCIS resulted in an extra 15 resection margins (7.5%) that involved DCIS. The differences in margin status amongst the three excision groups still supported the use of US-guided excisions but did not reach significance ($p = 0.3$). Univariate and multivariate analysis showed that the excision method, the institution, and the presence of unexpected tumour-associated DCIS significantly influenced oncological margin status ($p = 0.009$, $p = 0.006$ and $p = 0.002$, respectively).

Resection volumes and calculated resection ratios

The median ORVs, TRVs, and CRRs for the total group and for the various methods of tumour excision are stated in Table 3. Median CRR was 3.1. There was no evidence of any

differences in median ORV or TRV amongst the different excision groups ($p > 0.05$).

However, median CRR was significantly higher in the ROLL group compared to the WL group (3.8 and 2.8, respectively; $p < 0.05$).

ACCEPTED MANUSCRIPT

Discussion

Margin status

This study of the methods of BCS for nonpalpable breast cancer clearly demonstrates that, of the three methods applied, US-guided surgery resulted in lower positive margin rates on final pathology, particularly for invasive carcinoma. Favourable oncological margin status is the primary goal for both the surgeon and the patient; tumour-positive margins are associated with an increased risk of locoregional recurrence, signifying the need for a second surgery to obtain definite clear pathological margins (via re-excision or even mastectomy); focally positive margins require either additional surgery or external beam radiotherapy, with a directed boost to the tumour bed. [22-24] Both options are psychologically stressful to the patient, reduce the patient's well-being, and increase hospital costs. Moreover, when additional tissue is removed or boost irradiation is administered, the cosmetic result is worsened.

Nearly half of all tumours presented with pre-operatively missed tumour-associated DCIS. This high rate of tumour-associated in situ structures corresponds well with previously reported data. [11] The unexpected ductal carcinomas resulted in only 7.5% DCIS-involved margins, while the invasive tumour was adequately removed. The surgeons in all three excision groups were unaware of the presence of an associated DCIS component. For this reason, they could not have anticipated a larger excision. In our opinion, the possible presence of tumour-associated DCIS does not justify excessively large resections in daily practice to prevent unexpected DCIS-involved margins.

In the present study, the institution significantly influenced margin positivity. This was probably caused by the strong relationship between the institution and the selected excision method. Previous studies show that tumour type (lobular carcinomas) and tumour size (large tumours) are typically associated with margin positivity as well. [21] The small sample sizes may explain why the present study failed to show a relationship. Surprisingly, about 15% of

all tumours were sized 2 cm or larger. In general, nonpalpable tumours are smaller. The nonpalpability of these relatively large tumours might be caused by their deep localisation in a large breast.

Resection volumes and calculated resection ratios

As previously stated, the volume of resected breast tissue is the main determinant of cosmetic outcome. In our series, the relative excision volumes were large, especially in the ROLL group. In fact, with a median CRR of 3.1, the volumes were over three times as large as they should be. In the ROLL group, the excision volumes were nearly four times too large. In a recent study, we showed that in daily practice, an unnecessarily large amount of adjacent healthy breast tissue is often excised along with both palpable and nonpalpable tumours. There was also a marked difference in the depths of the margins around the cancer, with very generous margins on some sides and a very narrow margin on one side. Furthermore, despite the large excision volumes, clear margins were not assured. A remarkable finding of that previous study was that the rate of positive margins was higher for the palpable tumours than for the nonpalpable tumours. This might be caused by the lack of intra-operative visualisation for the excision of palpable tumours. [21] The large excision volumes in both the previous and the present study might be explained by the surgeons' primary focus on obtaining tumour-free resection margins. The sparing of breast tissue was probably only a secondary aim and, therefore, was somewhat neglected.

Limitations of the study

To calculate the optimal excision volumes, optimal resection margins of 1.0 cm were arbitrarily chosen. Although local recurrence and overall survival have proven to be unrelated to a tumour-free resection margin wider than 1 mm, surgeons should aim for a 1.0-cm margin because this is technically feasible. [22,23] The formula for the prediction of the optimal excision volumes and the specimen volumes was based on the assumptions that tumours are spheres and specimens are ellipsoids. In actuality, they may vary in shape. However,

these assumptions permitted easy calculation from the measurements of the pathology reports.

Primary DCIS was not taken into account in this retrospective study. In situ cancer often escapes detection by US. This type of pathology is typically nonpalpable and noncontiguous in nature, and it contains calcifications that are not easily visualised by US. Therefore, the results of this study are only applicable for primary invasive carcinomas. [10,11,25,26]

The main limitations of this multicentre study are that the total sample size was relatively small and the numbers of patients in the various excision groups were not well balanced. The group of ROLL patients, in particular, was limited. The ROLL procedure is relatively new, and due to the learning curve the results from ROLL might be biased. Future studies may clarify whether ROLL is amenable to improvement.

Intra-operative ultrasonography

Despite these limitations, previous prospective studies support our observations on the efficacy of intra-operative US guidance and the rates of tumour-involved margins. In 1988, Schwartz and colleagues first reported the successful intra-operative use of US as an alternative to WL, and many reports followed. [5-12] Harlow et al. achieved an impressive overall success rate of 97% (65/67) of pathologically negative margins by US-guided lumpectomy. [7] In 2002, Rahusen and colleagues reported the superiority of US guidance as compared to WL with respect to tumour-free resection margins (89% (24/27) and 55% (12/22), respectively). [5] In 2007, Haid and coworkers demonstrated the efficacy of US-guided surgery in the hands of the surgeon, with 81% (242/299) negative margins in the US-group compared to 62% (38/61) in the WL group. [11] Studies comparing WL with ROLL reported similar clinical efficacies for both procedures, but these studies are not conclusive. [13,27,28]

On the basis of the present study and earlier studies, it can be theorised that the use of intra-operative US will offer several potential benefits for the patient desiring BCS. Most

importantly, continuous intra-operative tumour visualisation with US results in the highest margin clearance compared to WL and ROLL. This is probably attributable to the direct real-time visualisation of all six margin depths. This advantage of using intra-operative US to visualise close margins or additional suspicious tissue permits the immediate removal of potentially malignant satellite lesions and adequate margin clearance. After excision, the specimen is scanned ex vivo by US to assess the completeness of the resection. The improved margin clearance as achieved by US guidance will lessen the need for re-excisions due to positive margins, decrease the frequency and expense of additional surgical interventions and improve cosmetic results. Moreover, because US enables the surgeon to optimally position the incision on the breast and to focus on delineating a margin around a breast tumour, US-guided surgery may reduce the unnecessary sacrifice of healthy breast tissue, thereby improving cosmetic outcomes further. US is a widely available and feasible tool, and it is the most comfortable and least traumatic option for the patient because there is no need for additional interventions, such as the placement of a wire or injection of material. This allows the surgeon flexibility in scheduling patients. A potential disadvantage of intra-operative US is that the presence of a dedicated radiologist in the operating theatre is required. However, because US is clearly better for the patient, this cannot be considered a restriction. Studies using intra-operative US for breast surgery have shown that, after a certain learning period, surgeons became confident in interpreting US images and recording them themselves. In the future, after adequate training of the surgeons, the radiologist's presence will no longer be required for a successful procedure in simple cases. [7,11] In general, over 95% of invasive breast cancers and all palpable breast lesions are easily visualised on US. [10,25,26,29] For palpable breast cancer, US guidance might thus result in higher efficacy than palpation-guided surgery. It might provide the surgeon with more precision in localising tumours than palpation alone. To our knowledge, only one study has compared US-guided surgery with surgery without an imaging technique for palpable invasive ductal breast cancer. Margin status (96.3% (26/27) and 83.3% (20/24) negative

margins) and the amount of breast tissue excised (104 cm³ and 114 cm³) were both improved with US. [12]

Conclusion

The present study clearly shows that intra-operative guidance by US is the most efficient method of obtaining tumour-free margins in patients undergoing BCS for nonpalpable breast cancer. We propose the use of US for the accurate intra-operative assessment of all echogenic breast tumours because it is perfectly suited for detecting nonpalpable tumours intra-operatively and for outlining palpable lesions. A prospective randomised controlled clinical trial will be undertaken in our region to assess the surgical accuracy of intra-operative US guidance for palpable tumours and its effects on cosmetic outcomes and patient satisfaction. The results are expected in July 2011.

Conflict of interest: The authors report no conflicts of interest.

External Funding: The authors report no external funding.

References

1. Cady B, Stone MD, Schuler JG, et al.: The new era in breast cancer. Invasion, size, and nodal involvement dramatically decreasing as a result of mammographic screening. *Arch Surg* 1996; 131:301-308.
2. Gotzsche PC, Nielsen M: Screening for breast cancer with mammography. *Cochrane Database Syst Rev* 2009;CD001877.
3. Tabar L, Fagerberg CJ, Gad A, et al.: Reduction in mortality from breast cancer after mass screening with mammography. Randomised trial from the Breast Cancer Screening Working Group of the Swedish National Board of Health and Welfare. *Lancet* 1985; 1:829-832.
4. Kopans DB, Swann CA: Preoperative imaging-guided needle placement and localization of clinically occult breast lesions. *AJR Am J Roentgenol* 1989; 152:1-9.
5. Rahusen FD, Bremers AJA, Fabry HFJ, et al.: Ultrasound-guided lumpectomy of nonpalpable breast cancer versus wire-guided resection: a randomized clinical trial. *Ann Surg Oncol* 2002; 9:994-998.
6. Snider HCJ, Morrison DG: Intraoperative ultrasound localization of nonpalpable breast lesions. *Ann Surg Oncol* 1999; 6:308-314.
7. Harlow SP, Krag DN, Ames SE, Weaver DL: Intraoperative ultrasound localization to guide surgical excision of nonpalpable breast carcinoma. *J Am Coll Surg* 1999; 189:241-246.
8. Rahusen FD, Taets van Amerongen AH, van Diest PJ, et al.: Ultrasound-guided lumpectomy of nonpalpable breast cancers: A feasibility study looking at the accuracy of obtained margins. *J Surg Oncol* 1999; 72:72-76.
9. Schwartz GF, Goldberg BB, Rifkin MD, D'Orazio SE: Ultrasonography: an alternative to x-ray-guided needle localization of nonpalpable breast masses. *Surgery* 1988; 104:870-873.
10. James TA, Harlow S, Sheehey-Jones J, et al.: Intraoperative ultrasound versus mammographic needle localization for ductal carcinoma in situ. *Ann Surg Oncol* 2009; 16:1164-1169.
11. Haid A, Knauer M, Dunzinger S, et al.: Intra-operative sonography: a valuable aid during breast-conserving surgery for occult breast cancer. *Ann Surg Oncol* 2007; 14:3090-3101.
12. Moore MM, Whitney LA, Cerilli L, et al.: Intraoperative ultrasound is associated with clear lumpectomy margins for palpable infiltrating ductal breast cancer. *Ann Surg* 2001; 233:761-768.
13. Luini A, Zurrida S, Paganelli G, et al.: Comparison of radioguided excision with wire localization of occult breast lesions. *Br J Surg* 1999; 86:522-525.
14. Rampaul RS, Macmillan RD, Evans AJ: Intraductal injection of the breast: a potential pitfall of radioisotope occult lesion localization. *Br J Radiol* 2003; 76:425-426.
15. Al-Ghazal SK, Fallowfield L, Blamey RW: Does cosmetic outcome from treatment of primary breast cancer influence psychosocial morbidity? *Eur J Surg Oncol* 1999; 25:571-573.
16. Sneeuw KC, Aaronson NK, Yarnold JR, et al.: Cosmetic and functional outcomes of breast conserving treatment for early stage breast cancer. 2. Relationship with psychosocial functioning. *Radiother Oncol* 1992; 25:160-166.
17. Cochrane RA, Valasiadou P, Wilson ARM, et al.: Cosmesis and satisfaction after breast-conserving surgery correlates with the percentage of breast volume excised. *Br J Surg* 2003; 90:1505-1509.
18. Olivetto IA, Rose MA, Osteen RT, et al.: Late cosmetic outcome after conservative surgery and radiotherapy: analysis of causes of cosmetic failure. *Int J Radiat Oncol Biol Phys* 1989; 17:747-753.
19. Taylor ME, Perez CA, Halverson KJ, et al.: Factors influencing cosmetic results after conservation therapy for breast cancer. *Int J Radiat Oncol Biol Phys* 1995; 31:753-764.

20. Vrieling C, Collette L, Bartelink E, et al.: Validation of the methods of cosmetic assessment after breast-conserving therapy in the EORTC "boost versus no boost" trial. EORTC Radiotherapy and Breast Cancer Cooperative Groups. European Organization for Research and Treatment of Cancer. *Int J Radiat Oncol Biol Phys* 1999; 45:667-676.
21. Krekel N.M.A., Zonderhuis B.M., Muller S., et al.: Excessive resections in breast-conserving surgery: A retrospective multicentre study. *Breast J* 2011; 17(5).
22. Kaufmann M, Morrow M, von Minckwitz G, Harris JR: Locoregional treatment of primary breast cancer: consensus recommendations from an International Expert Panel. *Cancer* 2010; 116:1184-1191.
23. Park CC, Mitsumori M, Nixon A, et al.: Outcome at 8 years after breast-conserving surgery and radiation therapy for invasive breast cancer: influence of margin status and systemic therapy on local recurrence. *J Clin Oncol* 2000; 18:1668-1675.
24. Singletary SE: Surgical margins in patients with early-stage breast cancer treated with breast conservation therapy. *Am J Surg* 2002; 184:383-393.
25. Georgian-Smith D, Taylor KJ, Madjar H, et al.: Sonography of palpable breast cancer. *J Clin Ultrasound* 2000; 28:211-216.
26. Ohlinger R, Heyer H, Thomas A, et al.: Non-palpable breast lesions in asymptomatic women: diagnostic value of initial ultrasonography and comparison with mammography. *Anticancer Res* 2006; 26:3943-3955.
27. Rampaul RS, Bagnall M, Burrell H, et al.: Randomized clinical trial comparing radioisotope occult lesion localization and wire-guided excision for biopsy of occult breast lesions. *Br J Surg* 2004; 91:1575-1577.
28. van der Ploeg IMC, Hobbelink M, van den Bosch MAAJ, et al.: 'Radioguided occult lesion localisation' (ROLL) for non-palpable breast lesions: a review of the relevant literature. *Eur J Surg Oncol* 2008; 34:1-5.
29. Tresserra F, Feu J, Grases PJ, et al.: Assessment of breast cancer size: sonographic and pathologic correlation. *J Clin Ultrasound* 1999; 27:485-491.

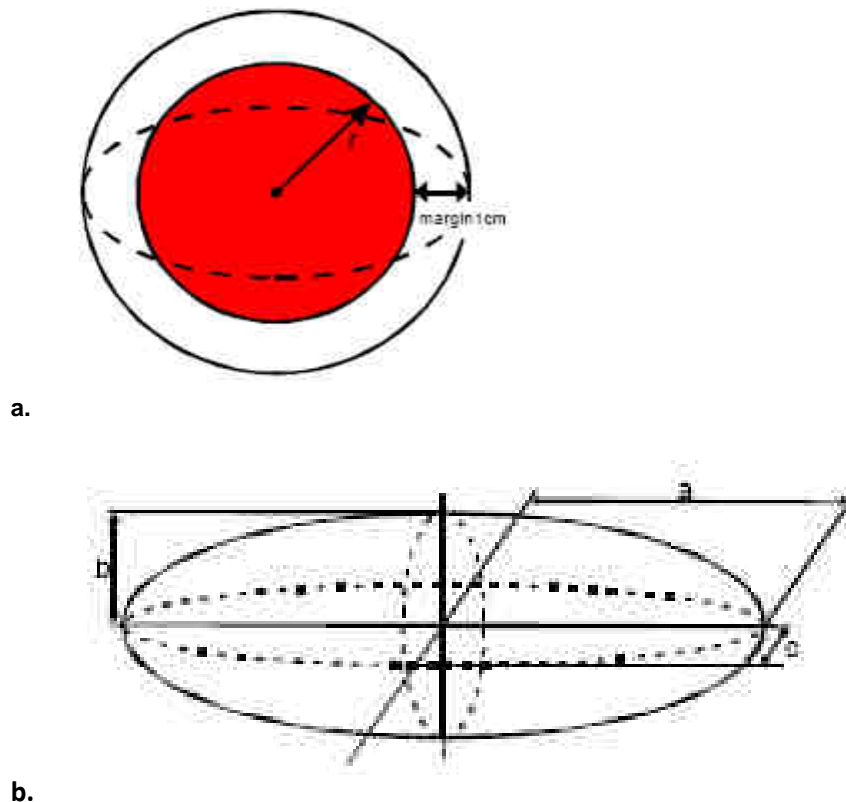


Figure 1. Mathematical calculation of the optimal resection volume (ORV) (1.a) and the total resection volume (TRV) (1.b)

- a. The tumour was defined as a sphere, and the tumour volume was calculated by the formula $4/3\pi r^3$. r represents the radius, which is equal to one half of the diameter measured by the pathologist. An ORV was calculated for each tumour. ORV was defined as the spherical tumour volume with an added 1.0-cm margin of healthy breast tissue, calculated by the formula $4/3\pi(r+1.0\text{cm})^3$.
- b. TRV represents the volume of the surgical specimen. TRV was assumed to be ellipsoid in shape and was calculated using the three dimensions of the surgical specimen (in cm) measured by the pathologist. The formula applied to calculate TRV was $4/3\pi(a-b-c)$, with a , b , and c representing one half of each of the three dimensions of the surgical specimen.

Excision method	WL N=117	US N=52	ROLL N=32	Total N=201
Age (median yrs) (range)	61.5 (33–77)	58.6 (42–82)	60.3 (39–79)	60.1 (33–82)
Histology (N) (%)				
Invasive ductal	104 (88.9)	46 (88.5%)	24 (75.0%)	174 (86.6%)
Invasive lobular	9 (7.7%)	4 (7.7%)	6 (18.8%)	19 (9.4%)
Others	4 (3.4%)	2 (3.8%)	2 (6.2%)	8 (4.0%)
Tumour diameter (median) (cm) (range)	1.10 (0.30–4.00)	1.20 (0.30–3.50)	1.15 (0.30–3.50)	1.20 (0.30–4.00)
Stage (pT) (N) (%)				
T1a	4 (3.4%)	2 (3.8%)	2 (6.2%)	8 (4.0%)
T1b	38 (32.5%)	16 (30.8%)	11 (34.4%)	65 (32.3%)
T1c	63 (53.8%)	19 (36.5%)	16 (50.0%)	98 (48.8%)
T2	12 (10.3%)	15 (28.9%)	3 (9.4%)	30 (14.9%)
Associated DCIS (N) (%)				
Minor	41 (35.0%)	24 (46.2%)	9 (28.1%)	74 (36.8%)
Major	12 (10.3%)	6 (11.5%)	3 (9.4%)	21 (10.4%)

Table 1.

Table 1. Patient and tumour characteristics

Distribution of age, tumour type, tumour diameter, tumour stage, and the presence and amount of tumour-associated DCIS in the WL, US and ROLL groups. The presence of tumour-associated DCIS, as found unexpectedly by the pathologist in the surgical specimen, was categorised. Minor associated DCIS represents DCIS inside or within several millimetres surrounding the invasive tumour; major associated DCIS represents an extended DCIS component surrounding the invasive tumour. There were no differences in patient age, tumour type, tumour diameter, tumour stage, or amount of associated DCIS amongst the different excision groups (all $p > 0.05$).

Table 2. Margin status for the various methods of tumour excision.

Excision method		WL N = 117	US N = 52	ROLL N = 32	Total N = 201
Margin status for invasive carcinoma	Negative	92 (78.6 %)	50 (96.2%)*	24 (75.0%)	166 (82.6%)
	Focally positive	17 (14.5%)	2 (3.8%)	6 (18.8%)	25 (12.4%)
	Positive	8 (6.9%)	0 (0.0%)	2 (6.2 %)	10 (5.0%)
Margin status for invasive carcinoma plus unexpected DCIS component	Negative	86 (73.5%)	43 (82.7%)**	22 (68.7%)	151 (75.1%)
	Focally positive	20 (17.1%)	4 (7.7%)	6 (18.8%)	30 (14.9%)
	Positive	11 (9.4%)	5 (9.6%)	4 (12.5%)	20 (10.0%)

* $p = 0.023$ (negative margins between US and WL or ROLL); Fisher's exact test.

** $p = 0.3$ (negative margins between US and WL or ROLL); Fisher's exact test.

A "negative" margin status represents clear margins; "focally positive" represents focally tumour-involved (or "close") margins; and "positive" represents tumour-involved margins.

Excision method		WL	US	ROLL	p-Value	Total
		N = 117	N = 52	N = 32		N = 201
ORV	(median) (cm ³) (range)	16.60 (6.37–113.10)	17.16 (6.37–87.11)	16.38 (6.37–87.11)	0.05*	17.16 (6.37–113.10)
TRV	(median) (cm ³) (range)	54.89 (3.93–381.70)	71.08 (20.94–383.86)	61.79 (6.28–321.62)	0.16*	60.75 (3.93–383.86)
CRR	TRV/ORV	2.8 (0.3–29.9)	3.2 (0.4–18.1)	3.8 (0.3–14.7)	0.55* 0.043**	3.1 (0.3–29.9)

Table 3. The optimal resection volumes (ORVs), the total resection volumes (TRVs), and the calculated resection ratios (CRRs) for the various methods of tumour excision.

* One-way analysis of variance; **Mann-Whitney test between WL and ROLL

ORVs (cm³) were calculated by adding a chosen 1.0-cm tumour-free margin to the tumour volumes, as calculated by using the diameters given in the pathology report; TRVs (cm³) were calculated using the three dimensions of the surgical specimen given in the pathology report; CRRs were calculated by dividing TRVs by ORVs.

Excision method	WL N=117	US N=52	ROLL N=32	Total N=201
Age (median yrs) (range)	61.5 (33–77)	58.6 (42–82)	60.3 (39–79)	60.1 (33–82)
Histology (N) (%)				
Invasive ductal	104 (88.9)	46 (88.5%)	24 (75.0%)	174 (86.6%)
Invasive lobular	9 (7.7%)	4 (7.7%)	6 (18.8%)	19 (9.4%)
Others	4 (3.4%)	2 (3.8%)	2 (6.2%)	8 (4.0%)
Tumour diameter (median) (cm) (range)	1.10 (0.30–4.00)	1.20 (0.30–3.50)	1.15 (0.30–3.50)	1.20 (0.30–4.00)
Stage (pT) (N) (%)				
T1a	4 (3.4%)	2 (3.8%)	2 (6.2%)	8 (4.0%)
T1b	38 (32.5%)	16 (30.8%)	11 (34.4%)	65 (32.3%)
T1c	63 (53.8%)	19 (36.5%)	16 (50.0%)	98 (48.8%)
T2	12 (10.3%)	15 (28.9%)	3 (9.4%)	30 (14.9%)
Associated DCIS (N) (%)				
Minor	41 (35.0%)	24 (46.2%)	9 (28.1%)	74 (36.8%)
Major	12 (10.3%)	6 (11.5%)	3 (9.4%)	21 (10.4%)

Table 1.