



HAL
open science

Prevalence of "follicular lymphoma in situ" in consecutively analysed reactive lymph nodes

Patrick Adam, Tobias Henopp, Leticia Quintanilla-Martinez, Falko Fend

► To cite this version:

Patrick Adam, Tobias Henopp, Leticia Quintanilla-Martinez, Falko Fend. Prevalence of "follicular lymphoma in situ" in consecutively analysed reactive lymph nodes. *Histopathology*, 2011, 59 (1), pp.139. <10.1111/j.1365-2559.2011.03897.x>. <hal-00661258>

HAL Id: hal-00661258

<https://hal.science/hal-00661258v1>

Submitted on 19 Jan 2012

HAL is a multi-disciplinary open access archive for the deposit and dissemination of scientific research documents, whether they are published or not. The documents may come from teaching and research institutions in France or abroad, or from public or private research centers.

L'archive ouverte pluridisciplinaire HAL, est destinée au dépôt et à la diffusion de documents scientifiques de niveau recherche, publiés ou non, émanant des établissements d'enseignement et de recherche français ou étrangers, des laboratoires publics ou privés.



HAL Authorization



Prevalence of "follicular lymphoma in situ" in consecutively analysed reactive lymph nodes

Journal:	<i>Histopathology</i>
Manuscript ID:	HISTOP-07-10-0361.R1
Wiley - Manuscript type:	Short Report
Date Submitted by the Author:	04-Nov-2010
Complete List of Authors:	Adam, Patrick; University of Tübingen, Institute of Pathology Henopp, Tobias; University of Tübingen, Institute of Pathology Quintanilla-Martinez, Leticia; University of Tübingen, Institute of Pathology Fend, Falko; University of Tübingen, Institute of Pathology
Keywords:	follicular lymphoma in situ, prevalence, reactive lymph nodes

SCHOLARONE™
Manuscripts

view

Prevalence of “follicular lymphoma in situ” in consecutively analysed reactive
lymph nodes

Short Report

Tobias Henopp, Leticia Quintanilla-Martínez, Falko Fend, Patrick Adam

Institute of Pathology and Comprehensive Cancer Center (CCC), University of
Tübingen, Liebermeisterstr. 8, 72076 Tübingen, Germany

Running head: **Prevalence** of “follicular lymphoma in situ”

Corresponding author:

PD Dr. Patrick Adam

Institut für Pathologie

Universität Tübingen

Liebermeisterstr. 8

72076 Tübingen

Germany

Tel.: +49-7071-29-83403

FAX: +49-7071-29-4421

Abstract

Background: Follicular lymphoma “in situ” is defined as strongly BCL-2 positive B-cells in germinal centers of morphologically inconspicuous lymph nodes. **Prevalence** and biological and clinical significance of this lesion are still not clear.

Methodology: All 1.294 reactive lymph nodes from unselected consecutive surgical specimens of 132 patients in a 3 months period were stained for BCL-2 protein. The t(14;18) translocation was investigated by FISH analysis.

Results: Follicular lymphoma “in situ” was identified in 22 lymph nodes in 3/132 patients (2.3%) without evidence or history of malignant lymphoma and confirmed by detection of the t(14;18) by FISH. Interestingly, in one patient, a lymph node excised two years before also contained follicular lymphoma “in situ”.

Conclusion: We found a **prevalence** of 2.3% for “FL in situ” lesions in an unselected series of lymph nodes, as a surrogate for the normal population. Taking into account the incidence of manifest follicular lymphoma the progression risk of this lesion is probably limited. It can be speculated that a part of the follicular lymphoma “in situ” lesions indeed represent an early step in the lymphomagenesis, whereas others persist without further progression to overt follicular lymphoma. The underlying mechanisms, however, remain to be elucidated.

Introduction

Follicular lymphoma (FL) is one of the most common non-Hodgkin lymphomas in adults and is usually characterized by an indolent clinical course¹. This is due to the underlying mechanism of tumor growth, based on the slow expansion of long-lived neoplastic cells resistant against apoptosis. FL is characterized by the chromosomal translocation t(14;18)(q32;q21) resulting in the constitutive expression of the BCL2 protein². This genetic aberration is found in up to 90% of FL³.

Interestingly, B-cells carrying the t(14;18) translocation can also be found in the peripheral blood of healthy individuals^{4,5}. In a study by Liu et al.,⁶ the translocation was detected in peripheral B-lymphocytes of 55% of healthy individuals with a frequency of between less than 1 up to 853 translocations per million cells. The frequency of t(14;18)-positive cells significantly increased with age, paralleling the increasing incidence of follicular lymphoma. Average translocation frequency was 13 times greater in the peripheral blood in the oldest individuals (61 yr and older) compared to the youngest age group (20 yr or younger). Particular t(14;18)-bearing clones persisted over a period of 5 months in two individuals. These findings demonstrate that clones harbouring the oncogenic t(14;18) chromosomal translocation are commonly present in healthy individuals, may be long-lived, and that they rise in frequency with age.

A possibly related finding is the occurrence of groups of strongly BCL2-expressing, t(14;18) positive B-cells in germinal centers of reactive lymph nodes without morphological evidence for involvement by FL, which has been designated "FL in situ"⁷. Some patients with "FL in situ" had either other lymph nodes involved by conventional FL or were diagnosed with overt FL later on. But more than half of the patients did not develop any evidence of a manifest FL during the follow-up time. Therefore, "FL in situ" might represent either the earliest stage of FL development, or

alternatively a pre-neoplastic state similar to monoclonal gammopathy of uncertain significance, requiring further genetic alterations or immunologic events for neoplastic transformation. The clinical significance of FL in situ is not clear, partially because the true prevalence of this finding in the general population is not known. For these reasons, we wanted to know how frequent germinal centers involved by FL in situ might be identified in reactive lymph nodes submitted for histopathologic examination from patients without evidence of lymphoma, as a surrogate for the prevalence in healthy individuals, who cannot be screened.

Material und Methods

A total of 1294 unselected lymph nodes from 132 patients (78 male, 54 female, mean age: 61 years, range 18 – 91 years; median 5 lymph nodes per patient) consecutively submitted in a three month period, from January to March 2009, to the Institute of Pathology of the University of Tübingen, Germany, were included in the study. All lymph nodes underwent routine histological examination, and were stained for the BCL2 protein. For inclusion in the study, lymph nodes had to show preserved architecture and at least one reactive germinal center on routine H&E stained slides. Identified cases of “FL in situ” were further analyzed by immunohistochemical staining for CD10, MIB1, IgM and immunoglobulin light chains and fluorescence in situ hybridization with a break-apart probe flanking the *BCL2* gene locus (Vysis LSI BCL2 Dual Color Break Apart Rearrangement Probe, Abbott Molecular, Wiesbaden, Germany). None of the patients had a history of FL, or a FL manifestation at another site. The study was approved by the local ethics committee.

Lymph nodes of 113 of the 132 patients had been removed for the purpose of oncological staging of solid tumors. The remainder had a diagnosis of inflammatory diseases (e.g. diverticulitis) or non-specific lymphadenopathy.

For calculation of the confidence interval the Clopper-Pearson method was used.

Results

In 22 of the 1294 lymph nodes (1.7%) corresponding to 3 of the 132 patients (2.3%, confidence interval [0.005;0.065], confidence niveau 0.95) strong BCL2 positive cells were identified in morphologically reactive germinal centers (see Table 1). Of interest, in the three patients more than one germinal center per node, and several lymph nodes per patient (range 2-16) were involved by FL in situ.

Pat.	Age/ sex	Specimen	Primary disease	Associated Lymphoma	LN	LN with FLIS
1	71/m	Whipple resection	Intraductal papillary mucinous neoplasm of the pancreas with invasive adenocarcinoma	No	7	4
2	69/m	Lobectomy	Lung cancer	No	27	16
3	42/m	Lymphadenectomy	Lymphadenitis (relapse)	No	4 (2007=1)	2 (2007=1)

Legend:

Pat.= Patient, LN= lymph nodes, m= male, FLIS= Follicular lymphoma in situ

Table 1: Clinical data of the three patients with "FL in situ".

None of the nodes showed extension of these cells outside the germinal centers; therefore, there was no evidence of a partial lymph node involvement by FL. The intensity of BCL2 expression was significantly stronger than that of reactive T-cells or marginal-zone B-cells, and also stronger than the usual intensity observed in overt FL. Proliferation rate - as evidenced by Mib-1 staining - was very low (below 10%), when compared to the adjacent reactive germinal centers. The extent of infiltration within individual follicles varied from some strongly BCL2 positive cells to a complete replacement of the germinal center (Figure 1).

Immunohistochemical staining for CD10 revealed a significantly stronger reactivity in the BCL2 positive germinal centers as compared to reactive follicles. Stainings for immunoglobulin light chains and IgM did not reveal a secretory differentiation of the strongly BCL2 expressing cells nor an IgM expression.

Fluorescence in situ hybridization with a break-apart probe (Vysis LSI BCL2 Dual Color Break Apart Rearrangement Probe, Abbott Molecular, Wiesbaden, Germany) confirmed in the three patients the presence of a break in the *BCL2* gene locus, indicative for the chromosomal translocation t(14;18).

Discussion

Taking into account the incidence of manifest FL being about 1 in 10,000 inhabitants per year, our study shows that "FL in situ" is encountered with a significantly higher frequency than would have been expected if transformation to clinically evident lymphoma would be the rule. The true prevalence of FL in situ in the examined age group can be assumed to be even higher than the 2.3% found in our study, given that even for patients undergoing resection of multiple nodes for staging purposes, these represent only a fraction of all lymph nodes of an individual. Although our study cohort, for practical purposes, does not represent healthy individuals, we consider it to be a relatively good surrogate group, based on the age and sex distribution, which is similar to patients with FL.

Patient 3 is of particular interest because in a lapse of 2 years he underwent two cervical lymph node biopsies with the clinical diagnosis of lymphadenitis. In the first biopsy a non-specific lymphadenitis with follicular hyperplasia was diagnosed. The same morphological features were seen in the subsequent biopsy, two years later, where FL in situ was found in two of the four lymph nodes analyzed with BCL2. Retrospectively, the first biopsy was also stained for BCL2, and surprisingly a single

germinal centre was found to be strongly BCL2 positive. This observation further supports that “FL in situ” is only a potential first step in the development of FL, and requires further genetic or immunologic events for the expansion of the malignant clone.

In summary, we found a prevalence of 2.3% for “FL in situ” lesions in an unselected series of lymph nodes, as a surrogate for the normal population. Because this prevalence is in between the frequency in which t(14;18) positive cells are encountered in the peripheral blood of healthy individuals and the incidence of FL, it can be speculated that a part of the FL in situ lesions indeed represent an early step in FL lymphomagenesis, whereas others persist without further progression to overt FL. The underlying mechanisms resulting in progression from FL in situ to full-blown FL, however, remain to be elucidated.

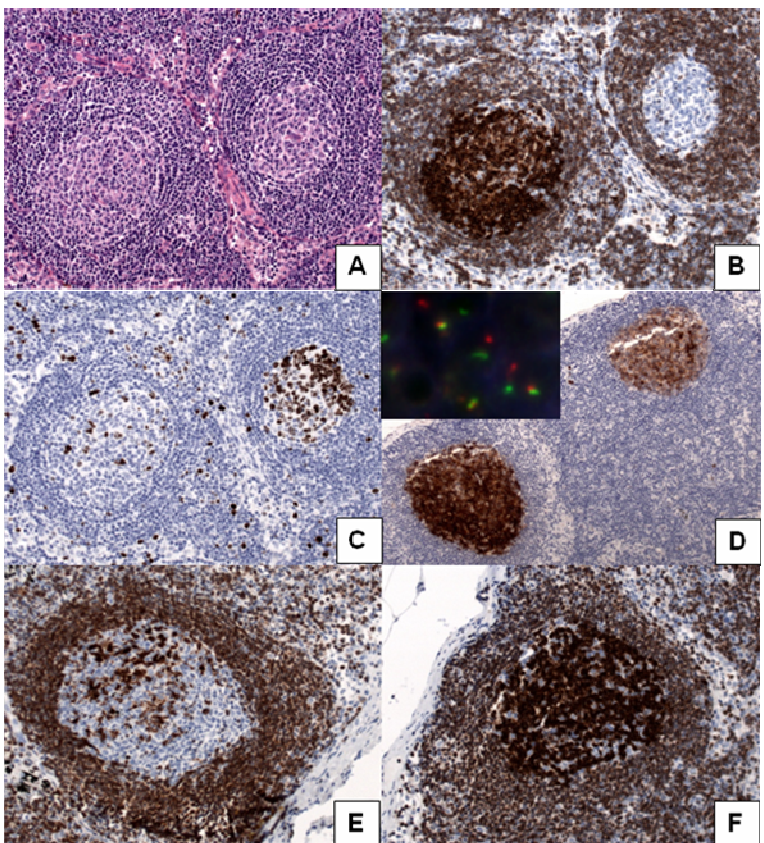
The authors declare no conflict of interest.

References

1. Swerdlow S.H. CE, Harris N.L., Jaffe E.S., Pileri S.A., Stein H., Thiele J., Vardiman J.W. (Eds.). *World Health Organization Classification of Tumours. WHO Classification of Tumours of Haematopoietic and Lymphoid Tissues*. Lyon: IARC Press, 2008.
2. Hockenbery D, Nunez G, Milliman C, Schreiber RD, Korsmeyer SJ. Bcl-2 is an inner mitochondrial membrane protein that blocks programmed cell death. *Nature* 1990;**348**:334-336.
3. Horsman DE, Gascoyne RD, Coupland RW, Coldman AJ, Adomat SA. Comparison of cytogenetic analysis, southern analysis, and polymerase chain reaction for the detection of t(14; 18) in follicular lymphoma. *Am J Clin Pathol* 1995;**103**:472-478.
4. Dolken G, Illerhaus G, Hirt C, Mertelsmann R. BCL-2/JH rearrangements in circulating B cells of healthy blood donors and patients with nonmalignant diseases. *J Clin Oncol* 1996;**14**:1333-1344.
5. Schuler F, Hirt C, Dolken G. Chromosomal translocation t(14;18) in healthy individuals. *Semin Cancer Biol* 2003;**13**:203-209.
6. Liu Y, Hernandez AM, Shibata D, Cortopassi GA. BCL2 translocation frequency rises with age in humans. *Proc Natl Acad Sci U S A* 1994;**91**:8910-8914.
7. Cong P, Raffeld M, Teruya-Feldstein J, Sorbara L, Pittaluga S, Jaffe ES. In situ localization of follicular lymphoma: description and analysis by laser capture microdissection. *Blood* 2002;**99**:3376-3382.

Legends

Figure 1: **Follicular lymphoma in situ:** **A)** In conventional histological examination the lymph nodes showed a preserved architecture with germinal centers of inconspicuous morphology (H&E, original magnification 200x). **B)** Immunohistochemical analysis for BCL2 revealed strong BCL2 expression in B-cells restricted to some germinal centers (left), while others were totally spared (right) (BCL2 immunoperoxidase, original magnification 200x). **C)** Ki67 immunohistochemical analysis demonstrated an inverse pattern of expression when compared to BCL2: “FL in situ” lesions featured a very low proliferation rate (left), when compared to the reactive germinal centers (right) (Ki67 immunoperoxidase, original magnification 200x). **D)** Immunohistochemical analysis for CD10 revealed strong CD10 expression in BCL2 positive germinal centers (left) as compared to reactive ones (right) (CD10 immunoperoxidase, original magnification 200x). FISH analysis in a case of “FL in situ” showed a break in the *BCL2* gene locus, indicative of the chromosomal translocation t(14;18)(q32;q21) (Insert). **E, F)** The extent of germinal center infiltration varied between some strongly BCL2 positive cells (**E**) to a complete obliteration of the respective germinal center (**F**) (BCL2 immunoperoxidase, original magnification 200x).



Peer Review