



HAL
open science

RIDGE ALTERATIONS FOLLOWING FLAPLESS IMMEDIATE IMPLANT PLACEMENT WITH OR WITHOUT IMMEDIATE LOADING. Part II. A HISTOMETRIC STUDY IN THE BEAGLE DOG.

Juan Blanco, Antonio Linares, Javier Perez, Fernando Muñoz

► **To cite this version:**

Juan Blanco, Antonio Linares, Javier Perez, Fernando Muñoz. RIDGE ALTERATIONS FOLLOWING FLAPLESS IMMEDIATE IMPLANT PLACEMENT WITH OR WITHOUT IMMEDIATE LOADING. Part II. A HISTOMETRIC STUDY IN THE BEAGLE DOG.. *Journal of Clinical Periodontology*, 2011, 38 (8), pp.762. 10.1111/j.1600-051X.2011.01747.x . hal-00659531

HAL Id: hal-00659531

<https://hal.science/hal-00659531>

Submitted on 13 Jan 2012

HAL is a multi-disciplinary open access archive for the deposit and dissemination of scientific research documents, whether they are published or not. The documents may come from teaching and research institutions in France or abroad, or from public or private research centers.

L'archive ouverte pluridisciplinaire **HAL**, est destinée au dépôt et à la diffusion de documents scientifiques de niveau recherche, publiés ou non, émanant des établissements d'enseignement et de recherche français ou étrangers, des laboratoires publics ou privés.



RIDGE ALTERATIONS FOLLOWING FLAPLESS IMMEDIATE IMPLANT PLACEMENT WITH OR WITHOUT IMMEDIATE LOADING. Part II. A HISTOMETRIC STUDY IN THE BEAGLE DOG.

Journal:	<i>Journal of Clinical Periodontology</i>
Manuscript ID:	CPE-12-10-3009.R2
Manuscript Type:	Original Article Pre-Clinical Sciences
Date Submitted by the Author:	12-Apr-2011
Complete List of Authors:	Blanco, Juan; School of Medicine and Dentistry, Stomatology Linares, Antonio; School of Medicine and Dentistry, Stomatology Perez, Javier; Lab technician Muñoz, Fernando; University of Santiago de Compostela, Veterinary Clinical Sciences
Topic:	Implantology
Keywords:	extraction, immediate implant, immediate loading, ridge alterations
Main Methodology:	Animal Model

SCHOLARONE™
Manuscripts

1
2 **RIDGE ALTERATIONS FOLLOWING FLAPLESS IMMEDIATE IMPLANT**
3 **PLACEMENT WITH OR WITHOUT IMMEDIATE LOADING. Part II. A**
4 **HISTOMETRIC STUDY IN THE BEAGLE DOG.**
5
6

7 **Running title:** Flapless immediate implants and loading
8

9 **KEY WORDS:** Immediate implants, immediate loading, ridge alterations, flapless
10 surgery.
11
12

13
14
15 **Juan Blanco ***, **Antonio Liñares ***, **Javier Pérez#**, **Fernando Muñoz μ**
16

17
18 *: Department of Stomatology, University of Santiago de Compostela, Spain.
19

20 #: Dental Technician. Lugo, Spain
21

22 μ: School of Veterinary of Lugo, University of Santiago de Compostela, Spain.
23
24

25
26
27 Reprint requests to:

28 Dr Juan Blanco
29

30 Department of Stomatology.
31

32 School of Medicine and Odontology
33

34 University of Santiago de Compostela
35

36 C/ Entreríos s/n.
37

38 15705. Santiago de Compostela
39

40 SPAIN
41

42 Phone: 34-981571826
43

44 Fax: 34-981571620
45

46 E-mail: jblanco@blancoramos.net
47
48
49
50
51
52
53
54
55
56
57
58
59
60

1
2 **Conflict of interest and sources of funding statement**
3
4

5 This study was supported by Straumann Company (Straumann, Basel, Switzerland).
6

Deleted: that there are

7 The authors declare no conflicts of interest in this study.
8
9

Deleted: s

10
11
12
13
14
15
16
17
18
19
20
21
22
23
24
25
26
27
28
29
30
31
32
33
34
35
36
37
38
39
40
41
42
43
44
45
46
47
48
49
50
51
52
53
54
55
56
57
58
59
60

For Peer Review

Abstract

Objective: To assess the effect of immediate loading on ridge alterations following implants placed into fresh extraction sockets in a dog model.

Material and Methods: Six Beagle dogs were used. Four implants were placed into post-extraction sockets in the lower jaw immediately after removal of premolar 3 and 4. In the control side, two implants remained without occlusal loading, and in the test side received an immediate prosthesis with occlusal contacts (involved implant sites). Extraction sockets without implants were used as test in non-involved implant sites. Three months later the dogs were sacrificed.

Results: Vertical distance from implant shoulder to Bone Crest (BC) was similar for both groups. BC at the buccal aspect was located 3.66 mm apical to the shoulder in the test group and 4.11 mm in the control group. This difference was not statistically significant. Buccal bone resorption was more pronounced in the premolar 3 area than in the premolar 4 area. In edentulous sites the buccal bone crest was located 0.97 mm apical to the lingual counterpart.

Conclusion: Immediate implant placement with or without immediate loading does not prevent the amount of bone resorption that occurs following tooth extraction without immediate implant placement.

- Deleted: assess
- Deleted:
- Deleted: dimensional changes of the alveolar ridge after
- Deleted: tooth extraction alone and immediate implant placement with or without immediate loading.
- Deleted: To assess the healing process after flapless immediate implant placement with or without immediate loading in terms of ridge alterations
- Deleted: .
- Deleted: in this study
- Deleted: (two per side)
- Deleted: tooth
- Deleted: the two implants
- Deleted: that remained
- Deleted: throughout the experimental period
- Deleted: sites
- Deleted: also
- Deleted: controls
- Deleted: , and histological parameters were analysed.
- Deleted: Four implants were placed in the lower jaw (two per side) in 6 beagle dogs, immediately after tooth extraction (Pm3, Pm4). Flapless immediate implant placement was performed in one hemimandible (control). The same procedure was done in the contralateral side and immediate prosthesis was connected with occlusal contacts (test). After 3 months the dogs were sacrificed, and samples were processed to assess ridge alterations with histometric
- Deleted: analysis
- Deleted: .
- Deleted: The
- Deleted: v
- Deleted: the
- Deleted: the
- Deleted: The
- Deleted: The amount of
- Deleted: b
- Deleted: The distance from the shoulder to the first bone-to-implant contact was similar in both groups. The mean first bone-implant contact at the buccal aspect was located in relation to the SLA level at 1.2 mm for the test group and 1.7mm for the unloaded group. This difference was not statistically significant. The amount of buccal bone resorption was more pronounced i... [1]
- Deleted: Buccal bone resorption ... [2]
- Deleted: Buccal bone resorption ... [3]

Clinical relevance

Scientific rationale for study: There is an increasing interest in immediate implant placement and immediate loading protocols. From a biological point of view, ridge alterations and alveolar bone resorption must be clarified before recommending such technique in daily practice. The present study shows the results in terms of ridge alterations following flapless immediate implant placement with or without immediate loading.

Deleted: ,
Deleted: but
Deleted: f
Deleted: aspects as

Principal findings: In this animal model, ridge alterations did always occur irrespective of the loading protocol applied to the immediately placed implants.

Deleted: There is an increasing interest in immediate implant placement and immediate loading protocols, but from a biological point of view there are some aspects (osseointegration process, bone resorption, etc.) that are necessary to be clarified before recommending such technique in a daily practice. We present the results of an experimental study in the beagle dog, where we have compared flapless immediate implant placement and immediate loading versus no loading.

Practical implications: Buccal bone resorption did always occur and this may compromise the aesthetic outcome of post-extraction implant placement in the anterior area.

Deleted: ¶
¶
¶
¶
¶
¶
¶
¶

Deleted: and Practical implications:

Deleted: study

Deleted: The resorption process may be more pronounced in implant sites than in extraction sites.

Formatted: Font: Not Bold

Deleted: at different degrees

Deleted: ¶

Introduction

Several experimental and human studies have shown that alveolar bone dimensions are reduced following tooth extraction (Araújo & Lindhe 2005, Johnson 1963, 1969, Pietrokovski & Massler 1967, Schropp et al. 2003).

Schropp et al. (2003), in a prospective clinical study, showed that about 50% of the bucco-lingual width of the alveolar bone was lost 12 months following single tooth extraction. An important finding was that two-thirds of this loss occurred within the first 3 months.

Paolantonio et al. (2001) suggested that the placement of implants into post-extraction sockets could maintain the original shape of the alveolar ridge. Moreover, the survival rates of implants placed into post-extraction sites are similar to those implants placed in healed sites (Chen & Buser 2009).

However, experimental models have shown that following immediate implant placement a process of bone resorption occurs, mainly on the buccal aspect (Araújo et al. 2005, Araújo et al. 2006, Blanco et al. 2008). The amount of resorption in the pre-clinical models of immediate implants is inconsistent, and it may be affected by implant location (Caneva et al. 2010a), implant diameter (Caneva et al. 2010b), implant surface (Vignoletti et al. 2009), socket dimension and thickness of the buccal bone plate (Araújo et al. 2006), and the surgical approach (Blanco et al. 2008, Caneva et al. 2010c).

On the other hand, experimental studies evaluating the hard tissue healing of immediate implants in humans (Botticelli et al. 2004, Sanz et al. 2010) have shown a similar amount of horizontal bone resorption to that observed at sockets that heal spontaneously after tooth extraction (Schropp et al. 2003).

Deleted: ¶

¶
¶
¶
¶
¶
¶
¶

Deleted: Following tooth extraction a process of bone resorption occurs in the alveolar ridge leading to dimensional alterations that may affect treatment strategy to restore the missing teeth. Clinical and radiographic studies (Johnson 1963, 1969, Pietrokovski & Massler 1967, Camargo et al. 2000, Schropp et al. 2003) have shown important reductions in the height and width of the alveolar crest following tooth extraction (single or multiple).

Deleted: I

Deleted: prospective

Deleted: ridge in posterior sites

Deleted: lost

Deleted: s

Deleted: after a healing period of

Deleted: (

Deleted: Schropp et al. 2003)

Deleted: .

Deleted: remarkable observation

Deleted: the observation

Deleted: occurred

Deleted: and co-workers

Deleted: Paolantonio et al. (2001) suggested that the placement of immediate implants could prevent the remodeling and could maintain the original shape of the alveolar ridge.

Deleted: clinical

Deleted: the size of the implant

Deleted: size of the socket

Some authors have suggested that certain loads may increase the amount of mineralized bone at the bone-to-implant interface and in the peri-implant bone area (Wehrbein et al. 1998, Gottfredsen et al. 2001). Immediate implant loading may stimulate bone formation and thus may influence early stages of osseointegration (Romanos et al. 2002, 2003).

Deleted: in humans have shown that the amount of horizontal resorption is similar in immediate implant placement (Botticelli et al. 2004, Sanz et al. 2010) and sockets that heal spontaneously after tooth extraction (Schropp et al. 2003). ¶

Moreover, immediately loaded implants present similar survival rates to implants loaded in a delayed protocol (Esposito et al. 2009).

Deleted: with

The combination of immediate implant placement and loading shows slightly lower survival rates to those of immediate loading of implants placed in healed sites. However, the bimodal approach showed favorable marginal bone changes after 1 year (Atieh et al. 2009).

A recently published minipig study showed that the amount of bone resorption was similar in immediate implants with immediate loading as immediate implants with delayed loading, in non-splinted implants (Liñares et al. 2011).

Deleted: *in press*

Formatted: Font: Not Italic

The objective of the present investigation was to assess the effect of immediate loading on ridge alterations following implants placed into fresh extraction sockets in a dog model.

Formatted: Adjust space between Latin and Asian text, Adjust space between Asian text and numbers

Deleted: to assess dimensional changes of the alveolar ridge after tooth extraction alone and immediate implant placement with or without immediate loading.

Deleted: The objective of this study was to assess in the beagle dog model the influence of flapless immediate implant placement and loading on ridge alterations of the alveolar bone

Material and methods

Deleted: .

Once approval from the Ethics Committee of the University of Santiago had been given, this research was carried out using 6 beagle dogs. They were provided by the School of Veterinary Studies at the University of Cordoba, and were installed in the Animal Experimentation Service facility at the Veterinary Teaching Hospital Rof Codina of Lugo. The animals were maintained in individual kennels in a 12:12 light/dark cycle (lights on at 07:00 h) and $22 \pm 2^\circ\text{C}$, with regular chow and tap water. All experiments

1
2 were performed according to the Spanish Government Guide and the European
3
4 Community Guide for animal care.
5
6
7
8
9

10 Experimental study

11 Surgical procedure

12
13
14 The experimental model used in this study was recently reported (Blanco et al. 2010).
15
16 Six beagle dogs, about 2 years old and 20 kg of weight, were enrolled in the study.
17
18 During surgical procedures, the animals were premedicated with acepromazine (0.05
19 mg/Kg intramuscularly) and morphine (0.2 mg/Kg intravenously). Immediately after,
20 they were induced general anesthesia by injection of propofol (2 mg/Kg intravenously).
21
22 Isoflurane (1.5-2%) and O₂ (100%) were used as inhaled anaesthetics.
23
24
25

26
27 In total, 24 implants were placed in 6 dogs. All implants were 8 mm long, 3.3 mm
28 in diameter with Standard neck height (2.8 mm), Straumann Dental Implant System
29
30 (Institute Straumann, Basel, Switzerland). All the implants had a sand-blasted and acid
31
32 etched surface (SLA). The implants were placed into fresh extraction sockets, and bone
33
34 augmentation procedures were not attempted
35
36

37
38 The lower premolars 3 and 4 were carefully removed, separating the roots by means of
39
40 tooth hemisectioning with the use of a fissure bur, and extracting them individually with
41
42 elevators and forceps (Fig. 1 a & b). After the extraction, immediate implants were
43
44 placed into the center of the distal socket of each tooth (Fig. 1 d-g). Four implants were
45
46 placed in each dog (2 in each hemimandible) according to the manufacturer protocol
47
48 (Straumann® Dental Implant System, Basel, Switzerland). The implants were placed so
49
50 that the marginal level of the sand blasted and acid etched (SLA) - coated surface was
51
52
53
54
55
56
57
58
59
60

Deleted: -

Deleted: -

Deleted: -

Deleted: -

Deleted: 3rd and 4th premolars

Deleted: s

flush with the buccal bone crest. In order to achieve this, the buccal soft tissue height was measured with a periodontal probe immediately before implant installation and having in mind that the smooth surface of the implant had a height of 2.8 mm (Fig. 1c).

Before implant placement, the socket diameter was measured with a periodontal probe.

Deleted: The implant was positioned in the center of the socket.

The mean bucco-lingual width was 3.5 ± 0.3 mm and $3.9 \text{ mm} \pm 0.3$ for the premolar 3 and 4 respectively. Thus, after implant placement a small gap < 1 mm was present between the inner part of the socket and the implant surface. No grafting procedures nor suturing were performed.

Deleted: and

After implant installation the experimental groups were randomly selected. Two implants of one side (test group) received an immediate loading restoration by means of provisional abutments for bridges (Straumann® Dental Implant System, Basel, Switzerland). The provisional prosthesis splinted the implants by an acrylic stent that remained with occlusal contacts with the antagonist teeth. The occlusion was checked again at sacrifice. Short healing caps (1.5 mm height) were connected to the the implants in the contralateral side (control group) aiming a non-submerged healing approach without loading (Fig. 1 h & i).

Deleted: One

Deleted: hemimandible

Deleted: that were

Deleted: T

Deleted: hemimandible

Deleted: received short healing caps (1.5 mm height)

Deleted: submerged

The mesial sockets of premolar 3 and 4 were left to heal without implant placement and served as test in non-involved implant sites. The second mandibular premolars in both quadrants were not involved in the surgical procedures and were used as controls in non-involved implant sites.

Deleted: alveolus

Deleted: any grafting procedure

Deleted: mandibular

Deleted: (2P2)

During the first week after surgery, the animals received Amoxicillin (500 mg, twice daily) orally and Meloxicam (0.1 mg/Kg, once a day) orally. Throughout the experiment, the animals were fed a pellet diet. They were placed on a plaque control

1
2 regimen that included tooth and implant cleaning three times per week with the use of
3
4 toothbrush and dentifrice.
5

6
7 After three months of healing, the animals were euthanized with an overdose of sodium
8
9 pentobarbital through the cephalic veins and a histometric analysis was performed to
10
11 evaluate the main variables on each group:
12

13 14 15 16 **Histological preparation**

17
18
19 The mandibles were removed and block biopsies of each implant were dissected using
20
21 an oscillating saw (Donath 1993). The samples were fixed 1 week in 10% formol. Next,
22
23 the samples were dehydrated in different graded ethanol series (70-100%), and
24
25 infiltrated with 4 different graded mixtures of ethanol and infiltrating resine,
26
27 glicometacrilate (Technovit 7200®, VLC – Heraus Kulzer GMBH, Werheim, Germany)
28
29 with 1% of Benzoyl Peroxide (BPO®: Heraus Kulzer GMBH, Werheim, Germany).
30
31 The last infiltration was performed with pure infiltrating resine under vacuum. The
32
33 samples were then polymerized, first under low intensity UV light for 4 h, followed by a
34
35 polymerization under high intensity UV light for 12 h and finally by keeping the
36
37 samples heated for 24 h to assure complete polymerization.
38

39
40 The samples were glued to a sample holder. Longitudinal sections in bucco-lingual
41
42 direction of 200 microns were cut with a band saw and mechanically polished (Exakt
43
44 Apparatebau, Norderstedt, Germany) using 1200 and 4000 grit silicon carbide papers
45
46 (Struers, Copenhagen, Denmark) until a samples thickness of 70 µm was obtained and
47
48 all sections were stained with Levai Laczko tintion for histometric analysis.
49

50
51 **Histometric analysis.**
52
53
54
55
56
57
58
59
60

Deleted: both histological examination and histomorphometric

Formatted: Font: Bold

The samples on the permanent ports were observed using the Olympus® SZX9 microscope (Olympus, Tokyo, Japan). By means of the Olympus® DP12 digital camera (Olympus, Tokyo, Japan), the images were captured and transferred to the computer. With the Microimage® program, the points of interest were identified from the digital histological images in order to measure the distances, which were expressed in millimeters.

Implant site

A line was traced along the digital image parallel to the implants longitudinal axis. The following marks were then marked on both the vestibular and lingual side of each implant: (Fig. 2 a)

- S: Implant shoulder
- PM: Peri-implant mucosa margin
- IC: Most coronal contact point of the bone with the implant
- BC: Bone crest

From each point, a perpendicular line was traced towards a parallel line along the implants longitudinal axis and the following measures (expressed in millimeters) were taken:

- S – BC: Distance from the implant shoulder to the bone crest.
- S – IC: Distance from the implant shoulder to the most coronal bone implant contact.
- BCB-BCI: Vertical distance between buccal and lingual bone crest.

Tooth site

Deleted: ¶

Formatted: Font: Italic

Deleted: subsequently

Formatted: Space Before: 6 pt

Formatted: Font: Italic, English (U.K.)

Deleted: made

Deleted: <#>SLA: Marginal border of the SLA-coated surface that was located 2.8 mm. apical of S.¶

Deleted: I

Deleted: BIC

Deleted: First

Deleted: BIC

Deleted: first

Deleted: <#>PM – BIC: Distance from the peri-implant margin mucosa to the first bone to-implant contact, that is, the length of the biologic width. ¶

Formatted: Indent: Left: 36 pt, No bullets or numbering

Formatted: Font: Italic

Formatted: No bullets or numbering

At tooth sites (premolar 2), the following marks were identified at the buccal and
lingual side (Fig. 2b):

- CEJ: cemento-enamel junction
- BC: bone crest (buccal/lingual)
- GM: gingival margin

From each point, a perpendicular line was traced towards a parallel line along the tooth
longitudinal axis and the following measurements (expressed in millimeters) were
taken:

- GM-BC: distance from the gingival margin to bone crest
- GM-CEJ: distance from the gingival margin to cemento-enamel junction
- CEJ-BC: distance from the cemento-enamel junction to the bone crest.

Edentulous site

At the edentulous sites, the height of the cortical bone walls was determined in the
following way, according to Araujo & Lindhe (2005) (Fig. 2c): a line parallel to the
long axis of the center of the socket was drawn (C-C) to separate the buccal and
lingual compartments. Subsequently, horizontal lines (LC and BC) perpendicular to
C-C were drawn to connect the most coronal portions of the buccal and lingual
bone crest to C-C. The vertical distance between the buccal and lingual
intersections with C-C was measured and expressed in mm (LC-BC).

Statistical analysis

Deleted: on

Deleted: vestibular

Deleted: s

Formatted: Font: (Default) Times New Roman, 12 pt

Deleted: ¶

Formatted: Font: Italic

Formatted: No bullets or numbering

Deleted: In

Formatted: Indent: Left: 18 pt, Space After: 10 pt, No bullets or numbering

Formatted: Font: (Default) Times New Roman, 12 pt, English (U.S.)

Formatted: Font: (Default) Times New Roman, 12 pt, English (U.S.)

Formatted: Font: (Default) Times New Roman, 12 pt

Formatted: Font: (Default) Times New Roman, 12 pt, English (U.S.)

Formatted ... [4]

Formatted ... [5]

Deleted: root

Formatted ... [6]

Deleted: in the center of the socket

Formatted ... [7]

Formatted ... [8]

Formatted ... [9]

Formatted ... [10]

Formatted ... [11]

Formatted ... [12]

Formatted ... [13]

Formatted ... [14]

Formatted ... [15]

Formatted ... [16]

Formatted ... [17]

Formatted ... [18]

Formatted ... [19]

Formatted ... [20]

Formatted ... [21]

Formatted ... [22]

Formatted ... [23]

Formatted ... [24]

Formatted ... [25]

Deleted: .

Formatted: English (U.S.)

Formatted ... [26]

Deleted: In the edentulous site ... [27]

1
2 The statistical analysis was performed using the Sigma-Stat® statistics program.
3

4
5 Descriptive statistics were taken for each of the variables and groups (mean values and
6
7 standard deviation).
8

9
10 To compare the implant groups in each variable for test and control and implant
11
12 position (premolar 3 or 4), the Student's t-test for paired observations was used.
13

14 The dog was used as unit for analysis (n=6), using average results across similarly
15
16 treated implants in the same dog and then compared. *P*-values <0.05 were considered
17
18 statistically significant.
19

20 21 **Results**

22 23 **Clinical observations**

24
25 In total 24 implants were immediately placed following tooth extraction, 12 of them
26
27 were immediately loaded and the other 12 remained without loading in a non-
28
29 submerged healing approach. At the end of the experimental period, none of the
30
31 implants and prosthesis was lost. At the time of sacrifice all restorations were still in
32
33 service and the occlusal contacts remained in the provisional bridge, however, all
34
35 restorations showed abrasion of the occlusal aspects.
36
37
38
39
40
41

Deleted: animal

Deleted: the

42 43 **Histological observations**

44 45 **Implant sites**

46
47 The histological study showed that the buccal and lingual mucosa in each implant of
48
49 both groups was covered by a keratinized oral epithelium that continued from the peri-
50
51 implant marginal mucosa with the barrier epithelium facing to the implants. Apical to
52
53
54
55
56
57
58
59
60

1
2 this epithelium was an area of fibre rich connective tissue, with fibres orientated parallel
3
4 to the implant surface.
5

6 7 **Tooth sites**

8
9
10 The GM was located coronal to the CEJ at the buccal and lingual aspect of each tooth.

Deleted: on

11 The bone wall was markedly wider at the lingual than at the buccal aspect of the teeth.

12
13 The buccal BC was located at a longer distance from the CEJ than the corresponding
14
15 lingual BC.
16

17 18 **Edentulous sites**

19
20 The mucosa covering the healed socket was lined by an oral epithelium that harboured a
21
22 well-keratinized surface layer. The underlying, connective tissue was characterized by
23
24 its densely packed collagen fibres and lack of infiltrates of inflammatory cells. A newly
25
26 formed hard-tissue bridge covered the entrance of the extraction socket. This marginal
27
28 ridge was mainly made up of woven bone, although small areas of lamellar bone could
29
30 also be observed. The newly formed hard-tissue bridge extended a varying distance into
31
32 the extraction socket. Apical of the bridge, the edentulous region was comprised of
33
34 cancellous bone dominated by its bone marrow. The marginal termination of the
35
36 original buccal bone wall was located apical of its lingual counterpart.
37

Deleted: In the immediate loading group, this was 3.66 ± 0.44 mm (buccal) and 2.28 ± 0.55 mm (lingual). In the unloaded group this was 4.11 ± 1.04 mm (buccal) and 2.77 ± 0.72 mm (lingual).

Deleted: in terms of S-BC distance.

Deleted: .

Deleted: ¶

Deleted: If

Deleted: length

Deleted: (2.8 mm) is eliminated,

Deleted: This

Deleted:

Deleted: implies that in the immediate loading group,

Deleted: on

Deleted: at the buccal aspect

41 42 **Histometric results.**

43 44 **Implant sites (Table 1) (Fig. 3 & 4)**

45 46 *Distance between S and BC*

47
48
49 No significant differences were found between groups. Considering that the implant
50
51 neck is 2.8 mm long, the bone crest was at the buccal aspect roughly 0.86 mm apical to
52
53

the SLA border and 0.50 mm coronal at the lingual one in the test group. In the control group the bone crest was located 1.3 mm apical to the SLA border at the buccal and at the same level of the SLA border on the lingual aspect.

Deleted: border,

Deleted: on

Deleted: aspect

Deleted: unloaded

Deleted: on

Deleted: BIC

Distance between S and IC

No significant differences were found between groups. The most coronal bone-to-implant contact was located 1.27 mm apical to the SLA surface, and 0.30 mm at the lingual aspect. Again, these distances were similar in the unloaded group, 1.70 mm at the buccal and 0.37 mm at the lingual aspect.

Deleted: in terms of S-IC distance

Deleted: In the immediate loading group, this was 4.07 ± 0.67 mm (buccal) and 3.10 ± 0.29 mm (lingual). In the unloaded group this was 4.50 ± 0.78 mm (buccal) and 3.17 ± 0.33 mm (lingual). This implies that in the immediate loading group, on the buccal aspect,

Deleted: the first

Deleted: on

Deleted: on

Deleted: on

Vertical distance between buccal and lingual bone plate at implant sites.

The mean vertical distance between buccal and lingual bone crest was similar in both groups. The difference was not statistically significant. The buccal bone crest was always located apical to the lingual counterpart.

Deleted: No significant differences were found between groups.¶

¶
Distance between PM and BIC (biologic width) ¶In the immediate loading group, this was 3.93 ± 0.64 mm at the buccal and 2.95 ± 0.37 mm at the lingual aspect. In the unloaded group, this was 4.01 ± 0.65 mm at the buccal and 2.64 ± 0.53 mm at the lingual aspect, with no significant differences between groups.¶

Deleted: the

Deleted: bone crest

Deleted: the

Deleted: e

Deleted: 1.38 ± 0.51 mm in the test group and 1.34 ± 0.87 mm in the control. This difference

Deleted: first

Deleted: BIC

Deleted: BIC

Distance from the implant shoulder (S) to the most coronal bone-to-implant contact (S-IC) and to the bone crest (S-BC) comparing implants from premolar 3 region with implants from premolar4 region. (Table 2 & Fig. 5)

The mean S-IC (buccal) distance in all implants of the premolar 3 region was 4.67 ± 0.83 mm and 3.87 ± 0.34 mm in the premolar 4. This difference was statistically significant ($p=0.026$). In the lingual aspect the difference was not significant. The mean S-BC (buccal) distance in the premolar 3 region was 4.4 ± 0.82 mm and 3.33 ± 0.33 mm in the premolar 4. This difference was statistically significant ($p=0.004$). Again there was no difference between premolar 3 and 4 in the lingual aspect.

Tooth sites (Table 3)

1
2 The mean distance between the GM and the BC was 3.02 ± 0.38 mm (buccal) and 2.57
3
4 ± 0.34 mm (lingual), while the corresponding distance between GM and CEJ was $2.24 \pm$
5
6 0.34 mm (buccal) and 1.98 ± 0.39 mm (lingual). The BC was located on the average of
7
8 0.77 ± 0.19 (buccal) and 0.53 ± 0.07 mm (lingual) apical to the CEJ.
9

10 Edentulous sites

11
12 The mean vertical distance between the buccal and lingual bone crest was 0.97 ± 0.63
13
14 mm. The buccal bone crest always remained apical to the lingual counterpart.
15
16

Deleted:

17 Discussion

18
19 The present investigation was designed to assess the impact of immediate implant
20
21 placement and loading in terms of ridge alterations in the beagle dog model. This
22
23 experimental model confirms the results shown in similar animal models of immediate
24
25 implant placement (Araújo et al. 2005, 2006b, Blanco et al. 2008, Vignoletti et al. 2009,
26
27 Caneva et al. 2010a & b, Liñares et al. 2011). This means that a process of bone
28
29 resorption occurs after tooth extraction, even when an implant is placed immediately in
30
31 a post-extraction socket. The present study has also evaluated the potential effect of
32
33 immediate loading in immediate implant placement. No differences were found between
34
35 the immediate loading group and the unloaded group. These means that the immediate
36
37 loading protocol did not affect the process of ridge alterations of implants placed
38
39 immediately after tooth extraction, and this is in agreement with a recently published
40
41 minipig study (Liñares et al. 2011). The amount of buccal bone resorption showed in
42
43 that study (0.7 mm test and 0.8 mm control) is similar to the results of the present
44
45 investigation (0.8 mm test and 1.3 mm control). Several preclinical investigations have
46
47 shown higher amounts of buccal bone resorption. Araújo et al. (2005) in a similar model
48
49 but without loading showed 2.6 mm of buccal bone resorption after 3 months of healing
50
51
52
53
54
55
56
57
58
59
60

Deleted: in press

Formatted: Font: Not Italic

Deleted: after removing the teeth

Deleted: In

Deleted: t

Deleted: .

Deleted: it

Deleted: been

Deleted: assessed

Deleted: Any difference could not be

Deleted: in press

Formatted: Font: Not Italic

Deleted: n

Deleted: paper

1
2
3
4
5
6
7
8
9
10
11
12
13
14
15
16
17
18
19
20
21
22
23
24
25
26
27
28
29
30
31
32
33
34
35
36
37
38
39
40
41
42
43
44
45
46
47
48
49
50
51
52
53
54
55
56
57
58
59
60

of immediately placed implants. In another study, the same group showed at 2 months of healing, 2.1 mm of buccal bone resorption (Araújo et al. 2006b). This difference may be due to the fact of raising a flap in those studies, but probably more to the size of the implant, since they used a 4.1 mm Straumann implant and the present study a 3.3 mm implant with the same characteristics. In fact, a recently published study in the Labrador dog showed almost double bone resorption with a 5 mm implant compared to a 3.3 mm implant (Caneva et al. 2010b). In the present study, the resorption process was more pronounced at the buccal aspect and in the premolar 3 area. The mean distance from SLA border to bone crest at buccal in the premolar 3 area was three times longer than in the premolar 4 region. The bone crest in premolar 3 was located 1.6 mm apical to the coronal level of the rough surface, and in the premolar 4 area the bone crest was situated 0.5 mm apical to the same landmark. This is in agreement with the results of a similar study by Vignoletti et al. (2009), who showed that with a 3.25 mm diameter implant the amount of buccal bone resorption was significantly higher in the premolar 3 area in comparison with the premolar 4 area. Moreover, Araújo et al. 2006a in a similar model but using 2 different socket sizes found more bone resorption in the socket of reduced diameter in comparison with the bigger one. In the premolar area the mean distance from shoulder to first bone-to-implant contact was 2 mm, however in the molar area was 0.8 mm. This may be due not only to the size of the socket but also to the thickness of the buccal bone plate. The authors stated that the thinner a bone wall, and the closer the implant is placed to this wall, the higher the risk of compromised healing and occurrence of bone dehiscence. However, it should be considered that the presence of an adjacent tooth to an implant may counteract the bone resorption process following tooth extraction. The implant in the premolar 4 area had an adjacent tooth (molar 1), but

Deleted: paper

Deleted: p

Deleted: the surgical approach

Deleted: in the Labrador dog

Deleted: twice

Deleted: more

Deleted: than

Deleted: that

Deleted: investigation

Deleted: affected

Deleted: mainly on

Deleted: shoulder

Deleted: 1.1 mm

Deleted: and co-workers

Deleted: to

Deleted: the

Deleted: should be taken into account, since it

Deleted: the

1
2
3
4
5
6
7
8
9
10
11
12
13
14
15
16
17
18
19
20
21
22
23
24
25
26
27
28
29
30
31
32
33
34
35
36
37
38
39
40
41
42
43
44
45
46
47
48
49
50
51
52
53
54
55
56
57
58
59
60

the implant in the premolar 3 area did not. Therefore this situation could have an impact on the final results.

Thus from this study and previous animal models it seems that the size of the socket, thickness of the buccal bone plate and implant diameter may play an important role in terms of buccal bone resorption after immediate implant placement.

Deleted: have an adjacent tooth.

Deleted: ¶

A small intrabony defect was detected in most of the implants at the end of the experiment, since the distance from implant shoulder to bone crest was shorter than the distance from shoulder to the first bone-to-implant contact. It is unclear if after longer healing periods these defects tend to disappear after a process of bone remodelling.

Deleted: that

On the other hand, the present investigation found that the mean vertical distance between the buccal and lingual bone crest was 0.97 mm at edentulous sites. At implant sites, this distance was longer, 1.38 mm in the test group and 1.34 mm in the control.

Deleted: showed

Deleted: more buccal

Deleted: bone resorption was more pronounced at the buccal than at lingual

Deleted: occurred

Deleted: in the extraction sites without implants.

Deleted: T

Deleted: higher

Thus, almost 0.5 mm more buccal bone resorption was found in the implant sites than in the edentulous sites. Araújo et al. (2005) showed in a similar study the amount of bone resorption following extraction of premolars 3 and 4 with or without immediate implant

Deleted: 3rd and 4th

placement. After 3 months of healing, the amount of buccal bone height reduction (in comparison with lingual bone alteration) was similar at implant sites and edentulous sites. The vertical distance between the buccal and lingual bone crest was 2.2 mm in

Deleted: s

edentulous sites and 2.4 mm in implant sites. Thus, the amount of buccal bone resorption in the edentulous sites showed by Araújo was more than double to the observed in the present investigation. This could be explained by the surgical approach performed in the Araújo study (raising a flap) in comparison to this study (flapless approach). It must be emphasized that this surgical trauma (flap elevation), implying the separation of the periostium and its disconnection from the underlying bone surface,

1
2
3
4
5
6
7
8
9
10
11
12
13
14
15
16
17
18
19
20
21
22
23
24
25
26
27
28
29
30
31
32
33
34
35
36
37
38
39
40
41
42
43
44
45
46
47
48
49
50
51
52
53
54
55
56
57
58
59
60

will cause vascular damage and an acute inflammatory response, which in turn will mediate the resorption of the exposed bone surface (Wilderman 1963, Staffileno et al. 1966, Wood et al. 1972). Recently, two experimental studies in the beagle dog have evaluated the impact of elevating a flap for tooth extraction on the dimensional alterations of the ridge. Fickl et al. (2008) compared alveolar bone healing following tooth extraction with or without flap elevation. Plaster casts were taken before, 2 and 4 months after the extractions. Volumetric bone changes were analyzed with specially designed software. The results showed an increase of 0.7 mm of volumetric shrinkage of both hard and soft tissues in the flap with respect to the flapless group. Later, Araújo & Lindhe (2009) in a similar experimental model but with longer follow-up (6 months), showed that the resorption of the alveolar crest was not influenced by the technique for tooth extraction (flap or flapless). Recently, an experimental study in the Labrador dog (Caneva et al. 2010c), showed no difference in terms of bone resorption for post-extraction implants with flapless or flap approach. Thus, it seems that in shorter healing periods the impact of flap elevation may have an effect on early bone resorption, but in longer healing periods the amount of resorption may be equal when performing tooth extraction with or without flap elevation.

Deleted: buccal vertical bone resorption in both groups but in the flap group 0.7 mm more bone loss was found than in the flapless group.

The use of a bone graft, filling the buccal void that may result after implant installation into fresh extraction sockets, could prevent bone resorption, however conflicting data exists on this issue (Araújo et al. 2011, Hsu et al. in press).

In summary, it can be concluded due to the results of the present study that immediately loaded implants placed into fresh extraction sockets, do not prevent bone resorption that mainly occurs at the buccal bone plate in the normal remodelling process.

Deleted: with

Deleted:

Deleted: following tooth extraction ridge alterations do always occur in the same manner with or without immediate implant placement and with or without immediate implant loading and placement. Buccal bone resorption does always occur

Deleted: red

Deleted: at different degrees and this may compromise the aesthetic outcome when placing immediate implants in the aesthetic zone.

Deleted: ¶

References

Araújo, M. G. & Lindhe, J. (2005) Dimensional ridge alterations following tooth extraction. An experimental study in the dog. *Journal of Clinical Periodontology* **32**, 212–218.

Araújo, M. G., Sukekava, F., Wennstrom, J. L. & Lindhe, J. (2005) Ridge alterations following implant placement in fresh extraction sockets: an experimental study in the dog. *Journal of Clinical Periodontology* **32**, 645–652.

Araújo, M. G., Wennstrom, J. L. & Lindhe, J. (2006a) Modeling of the buccal and lingual bone walls of fresh extraction sites following implant installation. *Clinical Oral Implants Research* **17**, 606–614.

Araújo, M. G., Sukekava, F., Wennstrom, J. L. & Lindhe, J. (2006b) Tissue modeling following implant placement in fresh extraction sockets. *Clinical Oral Implants Research* **17**, 615–624.

Araújo, M. G. & Lindhe, J. (2009) Ridge alterations following tooth extraction with and without flap elevation: an experimental study in the dog. *Clinical Oral Implants Research* **20**, 545–549.

Araújo, M. G., Linder, E. & Lindhe, J. (2011) Bio-Oss collagen in the buccal gap at immediate implants: a 6-month study in the dog. *Clinical Oral Implants Research* **22**, 1-8.

Atieh, M. A., Payne, A. G., Duncan, W. J. & Cullinan, M. P. (2009) Immediate restoration/loading of immediately placed single implants: is it an effective bimodal approach? *Clinical Oral Implants Research* **20**, 645–659.

Blanco, J., Nuñez, V., Aracil, L., Muñoz, F. & Ramos, I. (2008) Ridge alterations following immediate implant placement in the dog: flap versus flapless surgery *Journal of Clinical Periodontology* **35**, 640–648.

Blanco, J., Liñares, A., Villaverde, G., Pérez, J. & Muñoz, F. (2010) Flapless immediate implant placement with or without immediate loading. A histomorphometric study in beagle dog. *Journal of Clinical Periodontology* **37**, 937–942.

Botticelli, D., Beglundh, T. & Lindhe, J. (2004) Hard tissue alterations following immediate implant placement in extraction sites. *Journal of Clinical Periodontology* **31**, 820–828.

Camargo, P. M., Lekovic, V., Weinlaender, M., Klokkevoold, P. R., Kenney, E. B., Dimitrijevic, B., Nedic, M., Jancovic, S. & Orsini, M. (2000) Influence of bioactive glass on changes in alveolar process dimensions after exodontias. *Oral Surgery, Oral Medicine, Oral Pathology, Oral Radiology and Endodontology* **90**, 581–586.

Caneva, M., Salata, L. A., de Souza, S. S., Baffone, G., Lang, N. P. & Botticelli, D. (2010a) Influence of implant positioning in extraction sockets on osseointegration: histomorphometric analyses in dogs. *Clinical Oral Implants Research* **21**, 43–49.

Deleted: ¶
¶

Formatted: English (U.S.)

Formatted: English (U.S.)

Formatted: English (U.S.)

Formatted: English (U.S.)

Formatted: English (U.S.)

Formatted: English (U.S.)

Formatted: English (U.S.)

Formatted: English (U.S.)

Deleted: ¶

Deleted: ¶

Caneva, M., Salata, L. A., de Souza, S. S., Bressan, E., Botticelli, D. & Lang, N. P. (2010b) Hard tissue formation adjacent to implants of various size and configuration immediately placed into extraction sockets: an experimental study in dogs. *Clinical Oral Implants Research* **21**, 885-890.

Deleted:

Caneva, M., Botticelli, D., Salata, L. A., Souza, S. L., Bressan, E. & Lang, N. P. (2010c) Flap vs. "flapless" surgical approach at immediate implants: a histomorphometric study in dogs. *Clinical Oral Implants Research* **21**, 1314-1319.

Deleted: ¶

Formatted: English (U.S.)

Formatted: English (U.S.)

Formatted: English (U.S.)

Formatted: English (U.S.)

Formatted: English (U.S.)

Formatted: English (U.S.)

Deleted: ¶

Formatted: Line spacing: single

Chen, S. T. & Buser, D. (2009) Clinical and esthetic outcomes of implants places in postextraction sites. *The International Journal of Oral & Maxillofacial Implants* **24** (Suppl.), 186-217.

Donath, K. (1993) Preparation of Histological Sections (by the Cutting-Grinding Technique for Hard Tissue and other Material not Suitable to be Sectioned by Routine Methods) – Equipment and Methodological Performance. Norderstedt: EXAKT – Kulzer Publication.

Esposito, M., Grusovin, M. G., Achille H., Coulthard, P. & Worthington, H. V. (2009) Interventions for replacing missing teeth: different times for loading dental implants. *Cochrane Database of Systematic Reviews* **21**, CD003878.

Fickl, S., Zuhr, O., Wachtel, H., Bolz, W. & Huerzeler, M. (2008) Tissue alterations after tooth extraction with and without surgical trauma: a volumetric study in the beagle dog. *Journal of Clinical Periodontology* **35**, 356-363.

Gotfredsen, K., Berglundh, T. & Lindhe, J. (2001) Bone reactions adjacent to titanium implants subjected to static load of different duration. A study in the dog (III). *Clinical Oral Implants Research* **12**, 552-558.

Hsu, K. M., Choi, B. H., Ko, C. Y., Kim, H. S., Xuan, F. & Jeong, S. M. Ridge Alterations following Immediate Implant Placement and the Treatment of Bone Defects with Bio-Oss in an Animal Model. *Clinical Implants Dental Related Research* (in press).

Formatted: Font: Italic

Formatted: Font: Italic

Formatted: English (U.S.)

Johnson, K. (1963) A study of the dimensional changes occurring in the maxilla after tooth extraction. Part I. Normal healing. *Australian Dental Journal* **8**, 428-433.

Johnson, K. (1969) A study of the dimensional changes occurring in the maxilla following tooth extraction. *Australian Dental Journal* **14**, 241-244.

Liñares, A., Mardas, N., Dard, M. & Donos, N. (2011) Effect of immediate or delayed loading following immediate placement of implants with a modified surface. *Clinical Oral Implants Research* **22**, 38-46.

Deleted: in press

Deleted: doi: 10.1111/j.1600-0501.2010.01988.x.

Formatted: Font: Bold

Paolantonio, M., Dolci, M., Scarano, A., d'Archivio, D., Placido, G., Tumini, V. & Piatelli, A. (2001) Immediate implantation in fresh extraction sockets. A controlled clinical and histological study in man. *Journal of Periodontology* **72**, 1560-1571.

1
2 Pietrokovski, J. & Massler, M. (1967) Alveolar ridge resorption following tooth
3 extraction. *The Journal of Prosthetic Dentistry* **17**, 21–27.

4
5 Romanos, G. E., Toh, C. G., Siar, C. H. & Swaminathan, D. (2002) Histologic and
6 histomorphometric evaluation of peri-implant bone subjected to immediate loading: an
7 experimental study with *Macaca fascicularis*. *The International Journal of Oral and*
8 *Maxillofacial Implants* **17**, 44-51.

9
10 Romanos, G. E., Toh, C. G., Siar, C. H., Wicht, H., Yacoob, H. & Nentwig, G. H.
11 (2003) Bone-implant interface around titanium implants under different loading
12 conditions: a histomorphometrical analysis in the *Macaca fascicularis* monkey. *Journal*
13 *of Periodontology* **74**, 1483-1490.

14
15 Sanz, M., Cecchinato, D., Ferrus, J., Pjetursson, E. B., Lang, N. P. & Lindhe, J. (2010)
16 A prospective, randomized-controlled clinical trial to evaluate bone preservation using
17 implants with different geometry placed into extraction sockets in the maxilla. *Clinical*
18 *Oral Implants Research* **21**, 13-21.

19
20 Schropp, L., Wenzel, A., Kostopoulos, L. & Karring, T. (2003) Bone healing and soft
21 tissue contour changes following single-tooth extraction: a clinical and radiographic 12-
22 month prospective study. *The International Journal of Periodontics & Restorative*
23 *Dentistry* **23**, 313–323.

24
25 Staffileno, H., Levy, S. & Gargiulo, A. (1966) Histologic study of cellular mobilization
26 and repair following a periosteal retention operation via split thickness mucogingival
27 flap surgery. *Journal of Periodontology* **37**, 117–131.

28
29 Vignoletti, F., de Sanctis, M., Berglundh, T., Abrahamsson, I. & Sanz, M. (2009) Early
30 healing of implants placed into fresh extraction sockets: an experimental study in the
31 beagle dog. II: ridge alterations. *Journal of Clinical Periodontology* **36**, 688-697.

32
33 Wehrbein, H., Merz, B. R., Hämmerle, C. H. & Lang, N. P. (1998) Bone-to-implant
34 contact of orthodontic implants in humans subjected to horizontal loading. *Clinical Oral*
35 *Implants Research* **9**, 348-353

36
37 Wilderman, M. N. (1963) Repair after a periosteal retention procedure. *Journal of*
38 *Periodontology* **34**, 487–503.

39
40
41 Wood, D. L., Hoag, P. M., Donnenfeld, O. W. & Rosenberg, D. L. (1972) Alveolar
42 crest reduction following full and partial thickness flaps. *Journal of Periodontology* **43**,
43 141–144.
44
45
46
47
48
49
50
51
52
53
54
55
56
57
58
59
60

1
2
3
4
5
6
7
8
9
10
11
12
13
14
15
16
17
18
19
20
21
22
23
24
25
26
27
28
29
30
31
32
33
34
35
36
37
38
39
40
41
42
43
44
45
46
47
48
49
50
51
52
53
54
55
56
57
58
59
60

	S-IC		S-BC		BC-LC
	Buccal	Lingual	Buccal	Lingual	
Immediate loading (N=6)	4.07±0.67	3.10±0.29	3.66±0.44	2.28±0.55	1.38±0.51
No loading (N=6)	4.50±0.78	3.17±0.33	4.11±1.04	2.77±0.72	1.34±0.87
<i>p-value</i>	NS	NS	NS	NS	NS

Table 1. Results of histometric measurements in mm (mean and SD) describing the distance between landmarks in the implant sites.

the implant sites.

S-IC, distance from implant shoulder to first bone-to-implant contact. S-BC, distance from implant shoulder to bone crest. BC-LC, vertical distance between buccal and lingual bone crest.

Deleted: ¶

Deleted: ¶

Deleted: ¶

Deleted: ¶
¶
¶
¶
¶

Deleted:

Deleted: ¶

Deleted: ¶

Formatted Table

Deleted: BIC

Deleted: ¶

Deleted: ¶
¶
¶
¶

Deleted: BIC

Deleted: PM-BIC, distance from peri-implant margin mucosa to first bone-to-implant contact.

Table 2. Results of histometric measurements in mm (mean and SD) describing the distance between landmarks in the premolar 3 and premolar 4 region comparing all implants.

	S-IC		S-BC	
	Buccal	Lingual	Buccal	Lingual
Premolar 3 (N=6)	4.67±0.83	3.18±0.34	4.4±0.82	2.67±0.76
Premolar 4 (N=6)	3.87±0.34	3.08±0.26	3.33±0.33	2.33±0.53
<i>p-value</i>	0.026	NS	0.004	NS

Deleted: BIC

S-IC, distance from implant shoulder to first bone-to-implant contact. S-BC, distance from implant shoulder to bone crest.

Deleted: BIC

Deleted: ¶
¶
¶
¶
¶
¶

<u>GM-CEJ</u>		<u>CEJ-BC</u>		<u>GM-BC</u>	
<u>Buccal</u>	<u>Lingual</u>	<u>Buccal</u>	<u>Lingual</u>	<u>Buccal</u>	<u>Lingual</u>
<u>2.24±0.34</u>	<u>1.98±0.39</u>	<u>0.77±0.19</u>	<u>0.53±0.07</u>	<u>3.02±0.38</u>	<u>2.57±0.34</u>

Table

Formatted Table

3.

Results of histometric measurements in mm (mean and SD) describing the distance between landmarks in tooth sites.

Deleted: the

Deleted: h sites.

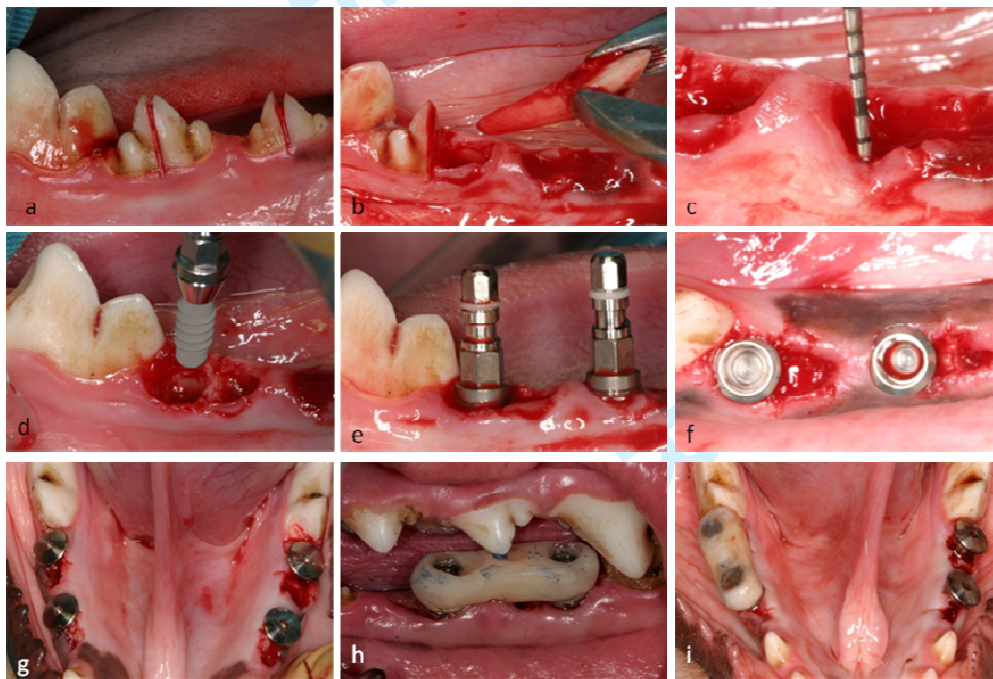
¶
¶
¶

GM-CEJ, distance from the gingival margin to cemento-enamel junction. CEJ-BC, distance from the cemento-enamel junction to the bone crest. GM-BC, distance from the gingival margin to bone crest.

Deleted: ¶

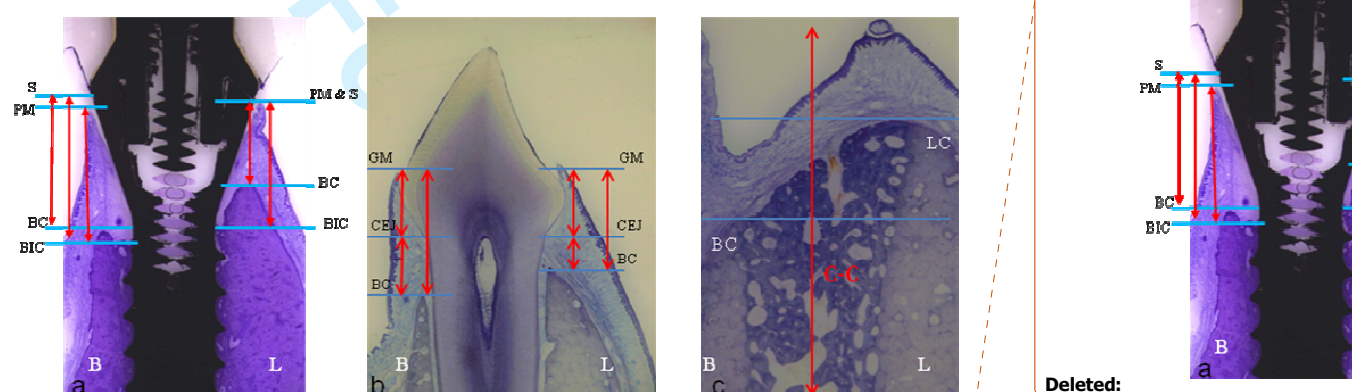
¶
¶
¶
¶
¶
¶

Figure 1.



Clinical photographs illustrating the experimental surgery. (a) hemisectioning premolar 3 and 4. (b) tooth extraction. (c) buccal bone sounding to locate the top of the buccal alveolar crest. (d-g) flapless immediate implant placement in distal sockets. (h) immediate loading with a resin provisional screw-retained bridge in the test group. (i) photograph illustrating the experimental groups.

Figure 2.



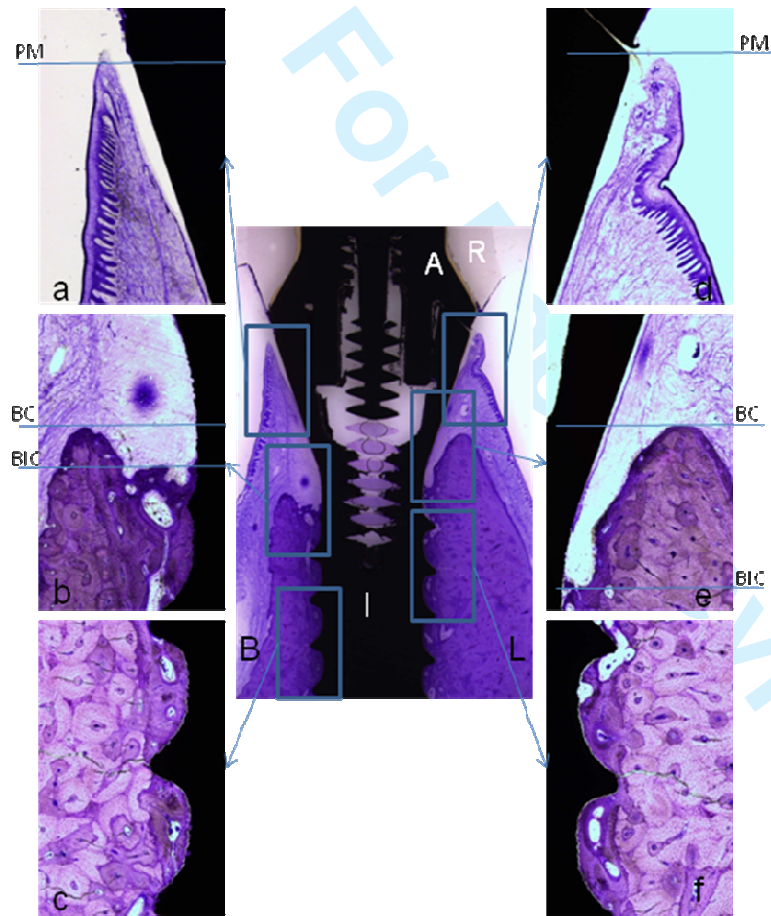
Landmarks used for histometric measurements. a. Implant site; PM, peri-implant mucosa margin; S, implant shoulder; BC, marginal bone crest; IC, most coronal bone to implant contact. b. Tooth site; GM gingival margin; CEJ, cement-enamel junction; BC, bone crest. c. Edentulous site; BC, buccal crest, LC, lingual crest. Levai Laczko staining method. Original magnification x 1.6.

Deleted: BIC

Deleted: ¶

Deleted: ¶
¶
¶
¶
¶

Figure 3.



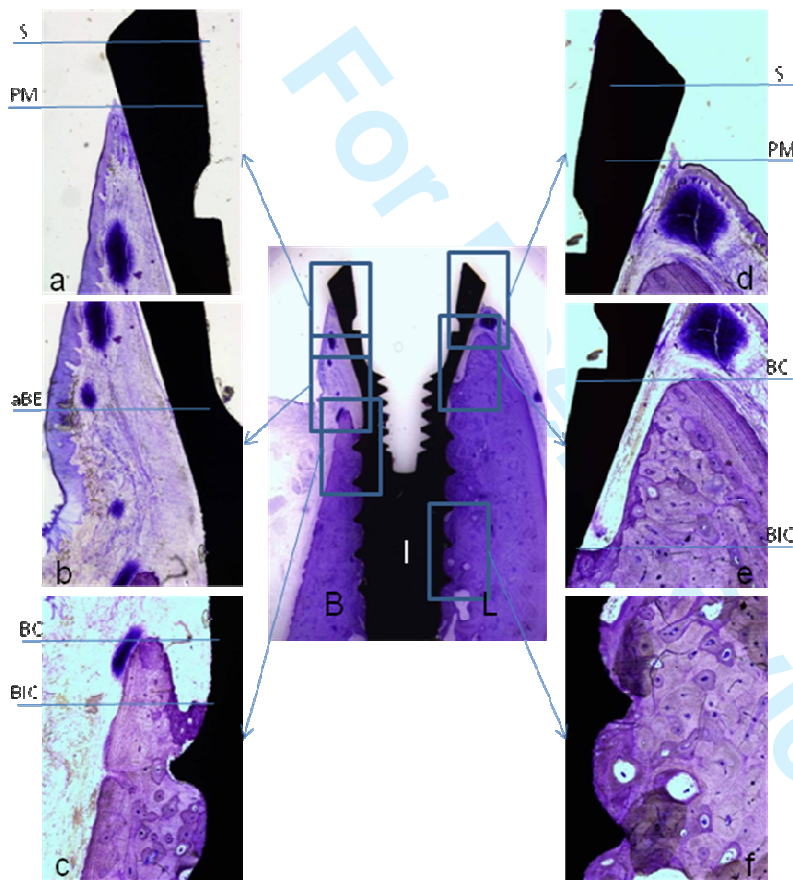
Buccal-lingual section representing one test implant site after 3 months of healing and loading. B, buccal aspect; L, lingual aspect; I, implant; A, abutment. (a) Note the location of the margin of the PM, peri-implant mucosa apical to the implant shoulder, S.

(b) Note the presence of a intrabony defect due to the bone crest (BC) is coronal to first bone-to-implant contact (IC). (c) Osseointegration at the mid part of the implant in the buccal aspect. (d) Location of the margin of the PM, peri-implant mucosa at the same level of implant shoulder. (e) presence of a bigger intrabony defect as compared with the buccal due to the bone crest (BC) is coronal to first bone-to-implant contact (IC). (f) Osseointegration at the mid part of the implant in the lingual aspect. Levai Laczko staining method. Original magnification x 1.6.and insets x 16.

Deleted: BIC

Deleted: BIC

Figure 4.



Buccal-lingual section representing one control implant site after 3 months of healing without loading. B, buccal aspect; L, lingual aspect; I, implant. Note that the level of the buccal bone crest is far apical in comparison with the lingual plate. (a & d) Note the location of the margin of the PM, peri-implant mucosa apical to the implant shoulder, S.

(b) Note the apical termination of the barrier epithelium, aBE, and well keratinized oral mucosa. (c) bone crest (BC) is coronal to first bone-to-implant contact (IC) forming an intrabony defect which is more pronounced in lingual (e). (f) Excellent level of bone-to-implant contact. Levai Laczko staining method. Original magnification x 1.6. and insets x 16.

Deleted: BIC

Figure 5.



Buccal-lingual section representing specimens of implant groups at premolar 3 and 4 region after 3 months of healing. (a-d) 4 implants of one animal. (a) control implant in the premolar 3 region. (b) control implant of the premolar 4 region. Note the difference in buccal bone resorption comparing a and b. (c) test implant of the premolar 3 region and (d) test implant of the premolar 4 region. Again the amount of bone loss of the buccal bone plate is more pronounced in the premolar 3 implant than in the 4 area. (e-h) 4 implants of another animal. (e) control implant in premolar 3. (f) control implant in premolar 4. (g) test implant in premolar 3. (h) test implant in premolar 4. Note that the amount of bone loss is more pronounced in the buccal aspect and in the premolar 3. Levai Laczko staining method. Original magnification x 1.6.

1
2
3
4
5
6
7
8
9
10
11
12
13
14
15
16
17
18
19
20
21
22
23
24
25
26
27
28
29
30
31
32
33
34
35
36
37
38
39
40
41
42
43
44
45
46
47
48
49
50
51
52
53
54
55
56
57
58
59
60

For Peer Review

1
2
3 **Page 3: [1] Deleted** **Usuario de Windows** **1/31/2011 4:31:00 PM**

4 The distance from the shoulder to the first bone-to-implant contact was similar in both
5
6 groups. The mean first bone-implant contact at the buccal aspect was located in relation
7
8 to the SLA level at 1.2 mm for the test group and 1.7mm for the unloaded group. This
9
10 difference was not statistically significant. The amount of buccal bone resorption was
11
12 more pronounced in the premolar 3 area than in the premolar 4 area. In edentulous sites
13
14 the buccal bone crest was located 0.97 mm apical to the lingual counterpart.
15
16
17
18
19

20 **Page 3: [2] Deleted** **Juan Blanco** **2/1/2011 12:13:00 PM**

21 Buccal bone resorption do always occur following tooth extraction.
22
23
24
25

26 **Page 3: [3] Deleted** **Usuario de Windows** **1/31/2011 4:32:00 PM**

27 Buccal bone resorption do always occur following tooth extraction with or without
28
29 immediate implant placement and with or without immediate loading to those implants.
30
31
32

33 **Page 11: [4] Formatted** **Usuario de Windows** **1/31/2011 6:42:00 PM**

34 Font: (Default) Times New Roman, 12 pt, English (U.S.)
35
36

37 **Page 11: [5] Formatted** **Usuario de Windows** **1/31/2011 6:42:00 PM**

38 Font: (Default) Times New Roman, 12 pt, English (U.S.)
39
40
41

42 **Page 11: [6] Formatted** **Usuario de Windows** **1/31/2011 6:42:00 PM**

43 Font: (Default) Times New Roman, 12 pt, English (U.S.)
44
45

46 **Page 11: [7] Formatted** **Usuario de Windows** **1/31/2011 6:42:00 PM**

47 Font: (Default) Times New Roman, 12 pt
48
49
50

51 **Page 11: [8] Formatted** **Usuario de Windows** **1/31/2011 6:42:00 PM**

52 Font: (Default) Times New Roman, 12 pt
53
54

55 **Page 11: [9] Formatted** **Usuario de Windows** **1/31/2011 6:42:00 PM**

56 Font: (Default) Times New Roman, 12 pt, English (U.S.)
57
58
59
60

1
2
3
4
5 **Page 11: [10] Formatted** **Usuario de Windows** **1/31/2011 6:42:00 PM**

6 Font: (Default) Times New Roman, 12 pt

7
8
9 **Page 11: [11] Formatted** **Usuario de Windows** **1/31/2011 6:42:00 PM**

10 Font: (Default) Times New Roman, 12 pt, English (U.S.)

11
12
13
14 **Page 11: [12] Formatted** **Usuario de Windows** **1/31/2011 6:42:00 PM**

15 Font: (Default) Times New Roman, 12 pt, English (U.S.)

16
17
18 **Page 11: [13] Formatted** **Usuario de Windows** **1/31/2011 6:42:00 PM**

19 Font: (Default) Times New Roman, 12 pt, English (U.S.)

20
21
22
23 **Page 11: [14] Formatted** **Usuario de Windows** **1/31/2011 6:42:00 PM**

24 Font: (Default) Times New Roman, 12 pt

25
26
27 **Page 11: [15] Formatted** **Usuario de Windows** **1/31/2011 6:42:00 PM**

28 Font: (Default) Times New Roman, 12 pt, English (U.S.)

29
30
31
32 **Page 11: [16] Formatted** **Usuario de Windows** **1/31/2011 6:42:00 PM**

33 Font: (Default) Times New Roman, 12 pt

34
35
36
37 **Page 11: [17] Formatted** **Usuario de Windows** **1/31/2011 6:42:00 PM**

38 Font: (Default) Times New Roman, 12 pt, English (U.S.)

39
40
41
42 **Page 11: [18] Formatted** **Usuario de Windows** **1/31/2011 6:42:00 PM**

43 Font: (Default) Times New Roman, 12 pt

44
45
46
47 **Page 11: [19] Formatted** **Usuario de Windows** **1/31/2011 6:42:00 PM**

48 Font: (Default) Times New Roman, 12 pt, English (U.S.)

49
50
51
52 **Page 11: [20] Formatted** **Usuario de Windows** **1/31/2011 6:42:00 PM**

53 Font: (Default) Times New Roman, 12 pt

54
55
56
57 **Page 11: [21] Formatted** **Usuario de Windows** **1/31/2011 6:42:00 PM**

58 Font: (Default) Times New Roman, 12 pt, English (U.S.)

Page 11: [22] Formatted Usuario de Windows 1/31/2011 6:42:00 PM

Font: (Default) Times New Roman, 12 pt

Page 11: [23] Formatted Usuario de Windows 1/31/2011 6:42:00 PM

GM-CEJ		CEJ-BC		GM-BC		Font: (Default) Times New Roman , 12 pt, English (U.S.)
Buccal	Lingual	Buccal	Lingual	Buccal	Lingual	
2.24±0.34	1.98±0.39	0.77±0.19	0.53±0.07	3.02±0.38	2.57±0.34	

Page 11: [24] Formatted Usuario de Windows 1/31/2011 6:42:00 PM

Font: (Default) Times New Roman, 12 pt

Page 11: [25] Formatted Usuario de Windows 1/31/2011 6:42:00 PM

Font: (Default) Times New Roman, 12 pt, English (U.S.)

Page 11: [26] Formatted Usuario de Windows 1/31/2011 6:42:00 PM

Font: (Default) AdvMacT_R, 9.5 pt, English (U.S.)

Page 11: [27] Deleted Usuario de Windows 1/31/2011 6:11:00 PM

In the edentulous sites, it was indentified the most coronal part of the buccal (BCb) and lingual (BCl) alveolar crest. A vertical line was traced along the center of the ridge and 2 horizontal lines from each crest to the vertical line (Fig.2 c).

BCb-BCl: vertical distance between the buccal bone crest and the lingual.

Page 25: [28] Deleted Juan Blanco 2/22/2011 1:34:00 PM