HAL
open science

Modified UroVysion scoring criteria increase the urothelial carcinoma detection rate in case of equivocal urinary cytology

Clément J.R. Huysentruyt, Marcella Baldewijns, Andrea Rüland, Ronald Tonk, Peter Vervoort, Kim Smits, Cees van De Beek, Ernst-Jan M Speel

To cite this version:

Clément J.R. Huysentruyt, Marcella Baldewijns, Andrea Rüland, Ronald Tonk, Peter Vervoort, et al.. Modified UroVysion scoring criteria increase the urothelial carcinoma detection rate in case of equivocal urinary cytology. Histopathology, 2011, 58 (7), pp.1048. 10.1111/j.1365-2559.2011.03859.x . hal-00655188

HAL Id: hal-00655188

https://hal.science/hal-00655188v1

Submitted on 27 Dec 2011

HAL is a multi-disciplinary open access archive for the deposit and dissemination of scientific research documents, whether they are published or not. The documents may come from teaching and research institutions in France or abroad, or from public or private research centers.

L'archive ouverte pluridisciplinaire **HAL**, est destinée au dépôt et à la diffusion de documents scientifiques de niveau recherche, publiés ou non, émanant des établissements d'enseignement et de recherche français ou étrangers, des laboratoires publics ou privés.

Histopathology

Modified UroVysion scoring criteria increase the urothelial carcinoma detection rate in case of equivocal urinary cytology

Journal:	*Histopathology*
Manuscript ID:	HISTOP-08-10-0444.R1
Wiley - Manuscript type:	Original Article
Date Submitted by the Author:	31-Oct-2010
Complete List of Authors:	Huysentruyt, Clément; Maastricht University Hospital, Dept of Pathology Baldewijns, Marcella; Maastricht University Hospital, Dept of Pathology Rüland, Andrea; Maastricht University Hospital, Dept of Pathology Tonk, Ronald; Maastricht University Hospital, Dept of Pathology Vervoort, Peter; Maastricht University Hospital, Dept of Pathology Smits, Kim; Maastricht University Hospital, Dept of Pathology Beek, Cees; Maastricht University Hospital, Dept of Urology Speel, Ernst-Jan; Maastricht University Hospital, Molecular Cell Biology
Keywords:	cystoscopy, cytology, FISH, urothelial carcinoma, UroVysion

SCHOLARONE™
Manuscripts

TITLE

Modified UroVysion scoring criteria increase the urothelial carcinoma detection rate in case of equivocal urinary cytology

AUTHORS

Clément J. R. Huysentruyt[a], Marcella M. Baldewijns[a], Andrea M. Rüland[a], Ronald J. W. Tonk[a], Peter S. A. M. Vervoort[a], Kim M. Smits[a], Cees van de Beek[b] and Ernst-Jan M. Speel[a,c]

AFFILIATIONS

[a] Department of Pathology, Maastricht University Medical Center, The Netherlands

[b] Department of Urology, Maastricht University Medical Center, The Netherlands

[c] Department of Molecular Cell Biology, GROW - School for Oncology & Developmental Biology, Maastricht University Medical Center, The Netherlands

For Peer Review

CONTACT INFORMATION

Marcella M. Baldewijns

Maastricht University Medical Center

Department of Pathology

PO Box 5800

6202 AZ Maastricht

The Netherlands

Email: m.baldewijns@mumc.nl

Tel: ++31/43/3874612

Fax: ++31/43/3876613

RUNNING TITLE

UroVysion and equivocal cytology

KEYWORDS

Cystoscopy; cytology; FISH; urothelial carcinoma; UroVysion

For Peer Review

ABSTRACT

Aim

UroVysion® is a four-target fluorescence in situ hybridisation (FISH) technique to detect urothelial carcinoma (UC) in urinary cytology. The aim of this retrospective study is to investigate the UC detection rate of a modified UroVysion test in patients with equivocal urinary cytology. The modification comprised the addition of a cytological pre-screening technique and different evaluation criteria.

Methods & results

A thin layer slide was prepared of the residual urine sample of 82 patients with equivocal urinary cytology, pre-stained and pre-screened to confirm the presence of atypical urothelial cells. The same slide was used for the UroVysion test and scored according to different evaluation criteria. Results were compared with the outcome of cystoscopic and histologic findings.

UroVysion detected 68% of the UCs when the manufacturer's evaluation criteria were applied. In case of altered evaluation criteria, the sensitivity increased to 81% when at least one copy number change of a probe target was considered as a positive test. The specificity only decreased from 84% to 82%.

Conclusions

Our data suggest that the sensitivity of the UroVysion test can be increased with the addition of a cytological pre-screening technique prior to the UroVysion test and a modification of the UroVysion evaluation criteria.

For Peer Review

TEXT

INTRODUCTION

Bladder cancer is the seventh most common cancer worldwide. It accounts for about 3.2% of all cancers, mostly urothelial carcinomas (UC). The highest prevalence of bladder cancer is observed in countries of the European Union and North America [1].

Bladder cancer is mostly detected by cystoscopy combined with urinary cytology. Cystoscopy is very successful in detecting low-grade and high-grade papillary tumours but may fail to identify carcinoma in situ (CIS) [2]. Cytology is a sensitive and specific examination for both high-grade papillary and flat lesions, but is less sensitive for detecting low-grade papillary lesions. Both techniques are thus complementary. Because cystoscopy is an invasive procedure and urinary cytology has a low sensitivity for low-grade tumours, additional tests emerged for the diagnosis of urothelial carcinoma (UC) on urine samples [3].

UroVysion® (UV (Abbott Molecular, Des Plaines, IL, USA)) is one of the most common used commercial UC markers [3]. It is a multi-target, multi-colour fluorescence in situ hybridisation (FISH) assay that detects aneusomy of chromosomes 3, 7 and 17, and loss of 9p21. UV has an overall sensitivity of 72% and specificity of 83% [4], moreover, it remains sensitive in the follow-up of patients under Bacillus Calmette-Guérin (BCG) treatment [3, 5-7]. Recent studies suggested the use of more flexible evaluation criteria for the UV test leading to an increase of the sensitivity of the UV test.[8-9].

When the UV test was introduced at our department, we added a pre-screening technique to the test. A FISH test is normally performed on another slide than the original slide used for cytological screening. This second slide may not always contain the atypical cells present in the previous cytological slide. In order to prevent false negative results and to confirm the presence of atypical cells also in the second slide, the UV test was preceded by a pre-staining and cytological screening of this slide (figure 1).

For Peer Review

In the current study we retrospectively investigated the sensitivity of the UV test in combination with the pre-screening method for the detection of UCs in patients with equivocal urinary cytology. Additionally, the impact of different evaluation criteria [8-9] on the sensitivity of the UV test was examined.

MATERIAL AND METHODS

Patient population

In this study we retrospectively included patients with equivocal urinary cytology for which UV tests and follow up examinations were performed. Data were collected from December 2005 till May 2009 (Table 1). Equivocal cytology was defined as cytology with a diagnosis that was neither clearly negative nor clearly positive for malignancy. The study group contained patients in the follow-up for UC, who all received intravesical chemotherapy or BCG, as well as patients without a history of UC. Cystoscopy and histology were used as 'gold standards' to evaluate the presence of UC. The histology was evaluated and graded in accordance with the 1999 World Health Organization classification. The tumour stage was assigned according to the TNM classification, 6th edition. Cystoscopy was regarded as positive in case of an unequivocal tumour mass. In this study patients without information about a consecutive cystoscopy or biopsy, as well as patients with FISH specimens lacking the atypical cells were not included.

Urinary cytology

The urine samples were fresh voided (n=63), obtained through bladder washings (n=8), bladder (n=7) or ureter (n=4) catheterizations and collected in 50% ethanol. They were poured in a 50 ml conical centrifuge tube and centrifuged at 1000 rpm during 10 min. The cell pellet was added to 5 ml Cytorich® Blue (BD Diagnostics TriPath, Burlington, NC, USA). Slides for

For Peer Review

cytologic evaluation were made using the thin layer technique (BD Diagnostics Prepstain® slide processor, Burlington, NC, USA) and stained with the Papanicolaou stain.

UroVysion FISH

Pre-screening technique

A second thin layer preparation was stained with haematoxylin for cytological pre-screening. Atypical cells were scored using a Leica DM5000B microscope in bright field mode and their location annotated by coordinates. Cases with slides that contained no or a too low number of atypical cells to successfully score the UV evaluation criteria (see further) were not included in the study. The pre-screening technique was tested prior to the study and resulted in good quality of hybridization on the pre-stained specimens.

FISH

After cytological pre-screening, the slides were heated at 65ºC for 30 min and immersed in a pepsin solution (500 mg/l, 10mM HCl), for 7 min. After washing in phosphate-buffered saline (PBS) cells were postfixed in 1% formaldehyde with 20mM MgCl2 in PBS for 5 min, dehydrated in 70%, 96% and 2 X 100% ethanol and air dried. Six µl UroVysion probe mixture, containing probes for the chromosome 3, 7 and 17 centromeric regions and the 9p21 locus labelled with SpectrumRed, SpectrumGreen, SpectrumAqua and SpectrumGold respectively, was administered under a coverslip of 18 x 18 mm. Cellular and probe DNA were denatured at 73ºC for 2 min in a ThermoBrite® system (Abbott Molecular, Des Plaines, IL, USA). Posthybridisation washings were made in 0.4x SSC/0.3% 4-nonylphenolpolyethyleneglycol (NP-40, Abbott Molecular, Des Plaines, IL, USA) for 2 min at 73°C. The slides were rinsed in 2x SSC/0.1% NP-40 at room temperature for 2 min, air dried , and counterstained with 4,6-diamidine,2-phenylindole dihydrocholoride (DAPI) solution. Next, the slides were examined using the Leica DM5000B microscope with

For Peer Review

appropriate fluorochrome filter sets and evaluation included the atypical cells at the annotated coordinates. The UV test was considered positive if 1) four or more cells out of a minimum of 25 morphologically abnormal cells demonstrated polysomy in two or more chromosomes (3, 7 and 17) in the same cell and/or if at least 12 morphologically abnormal cells demonstrated homozygous loss of 9p21 (= UV1 criteria, according to Abbott Molecular); or 2) at least one chromosomal gain (3, 7 or 17) was detected in four or more cells out of a minimum of 25 morphologically abnormal cells and/or if at least 12 morphologically abnormal cells demonstrated heterozygous or homozygous loss of 9p21 (= UV2 criteria).

Statistics

The chi-square test was used to evaluate the relation between the test results (UV and cystoscopy) and the presence of UC. All tests were 2-tailed with $p<0.05$ considered statistically significant. Statistical analysis was performed with SPSS® for Windows, version 15.0.

RESULTS

Table 1 shows the patient characteristics including the number of the cystoscopic examinations, performed simultaneously with or within three months after the urine collection, and histologic evaluations, executed within an average of four months. Thirty-one out of the 82 patients revealed a UC on histology and / or cystoscopy. In seven out of 31 patients with UC no biopsy was taken because of clearly presence of tumour on cystoscopy. In six of these patients, there was already a prior history of UC.

The application of the UV1 criteria resulted in an overall sensitivity of 68% . Using the UV2 criteria the sensitivity increased to 81%, while the specificity only decreased from 84% to 82%. Very high sensitivity scores were realised when combining UV and cystoscopy (Table

For Peer Review

2).

Sensitivity and specificity of the UV test in follow-up patients, who all received intravesical chemotherapy or BCG, were 75% and 84%, respectively, using the UV1 criteria, in contrast with 88% and 81%, applying the UV2 criteria. For patients without a history of UC, UV1 criteria resulted in a sensitivity and specificity of 60% and 84%, respectively, compared to 73% and 84% in case of applying UV2 criteria.

Cystoscopic evaluation alone had a sensitivity of 65%: 11 out of 62 patients with negative cystoscopies revealed a UC on biopsy. In 7/11 cases the UC was located in the upper urinary tract (UUT). The other four cases were three CIS lesions and one grade 3 UC of the bladder. Out of 20 UCs detected on cystoscopy, the UV test was negative in six or seven cases, depending on using the UV2 or UV1 criteria.

When applying the UV1 criteria, UV detected 0/3 grade 1 UCs and only 1/5 grade 2 UCs, while cystoscopy was positive in 3/3 grade 1 UCs and 3/5 grade 2 UCs (Table 3). For grade 3 lesions and carcinoma in situ (CIS) UV was positive in respectively 10/12 and 4/4 lesions, while cystoscopy detected six grade 3 lesions and only one CIS. It is important to mention that of the cystoscopically missed malignancies, all two grade 2 lesions and 5/6 grade 3 lesions were located in the UUT. Regarding the relationship between tumour stage, UV and cystoscopy, there are no significant differences between the detection rates of UV and cystoscopy (Table 3). Exceptions are T3 tumours where none of the lesions were detected by cystoscopy, however these tumours were UUT tumours.

Of the 31 patients with a proven UC, chromosomal alterations were found in 25 cases. Gain of chromosome 3 (18/31), 7 (19/31) and/or 17 (15/31) was noted more frequently than heterozygous (4/31) or homozygous (9/31) deletions of locus 9p21. Interestingly, all CIS lesions had a gain of chromosome 3, 7 and 17. Five patients had chromosomal alterations that did not fit the UV1 criteria: one patient with an isolated gain of chromosome 7, three patients

For Peer Review

with an isolated heterozygous deletion of 9p21 and one patient with an isolated heterozygous deletion of 9p21 combined with a solitary gain of chromosome 3.

In the patients with UUT tumours, the UV test was positive in 5/7 cases with the UV1 criteria and in 7/7 cases with the UV2 criteria. Chromosomal alterations in the UUT tumours were not significantly different from the bladder UCs.

DISCUSSION

Currently, cystoscopy and urinary cytology are routinely used for the detection of tumours in the urinary tract. However, on cytology, it is sometimes difficult to discriminate between reactive and malignant atypical urothelial cells. Urothelial cells can show reactive atypia due to instrumentation, inflammation, infection, calculi, radiotherapy and intravesical BCG or chemotherapy [10-14]. Atypical findings are problematic because they raise concerns with the patient and physician about the possible presence or recurrence of cancer [15]. The UV test, however, can be a helpful additional tool in those cases [16, 17].

The present study evaluates the combination of the UV test with a cytological pre-screening on the same slide. This method allows us to link cytological observed cellular atypia with chromosomal alterations. It can be difficult to select the atypical cells in a FISH specimen in the case of equivocal urine cytology. The pre-screening technique however can facilitate this. When gain of at least one chromosome (3, 7 or 17) and/or heterozygous or homozygous deletion of 9p21 (UV2 criteria) were interpreted as a positive UV test, 81% of the malignancies were detected compared to 68% when applying the manufacturer's criteria (UV1 criteria) with only a slight decrease in specificity (2%). Our data indicate that in case of equivocal urinary cytology the use of more flexible criteria for UV positivity substantially increases the number of detected UCs. This suggests that the current scoring criteria may be too restrictive since some urothelial carcinomas have chromosomal abnormalities (gains of

For Peer Review

single chromosomes or heterozygous 9p21 deletions) that are undetected by the manufacturer's criteria.

Until now, no study has compared the current manufacturer's UV criteria with more flexible criteria in urine specimens of patients with equivocal cytology by using a cytological pre-screening technique in combination with the UV test. Ferra et al [9] also compared more flexible evaluation criteria, i.e. any cytogenetic abnormality regardless of the number of cells is a positive result, with the manufacturer's criteria in equivocal urinary cytology cases. With a sensitivity of 68% and 83% by using respectively the manufacturer's criteria and the flexible criteria, their results are almost identical to ours. Nevertheless, their specificity dropped from 40% to 22%, while we maintained a specificity of more than 80%. This difference might be explained by the pre-screening technique we used, as it allows us to better allocate the exact location of the atypical cells before application of the UV test, thereby excluding that tetrasomic cells, such as umbrella cells or dividing cells, are scored positive [8, 18]. Also the number of the present atypical cells and cells with cytogenetic abnormalities needs to be high enough to maintain a high specificity.

Furthermore, in a recently published analysis of 14 studies involving 2477 UV tests (using UV1 criteria) the pooled sensitivity and specificity was 72% and 83% [4]. The overall prevalence of UCs in the examined patient groups was 35%, almost identical to the 36% in our study. In these studies the UV test was not only performed on equivocal urine specimens, but also on cytologic clear negative or positive cases. The fact that the sensitivity and specificity scores of these studies are comparable with our UV1 data, indicates that the pre-screening technique we use to trace atypical cells, leads to a more effective application of the UV test.

The UV test in our series detected 7 UUT tumours, most of them in spontaneously voided urine specimens. This finding suggests that the UV test can be helpful in cases of equivocal

For Peer Review

cytology and negative findings on cystoscopy, which is in agreement with other studies [19-21].

Furthermore, our results show that the UV test and cystoscopy are complementary techniques, achieving extremely high sensitivity rates when both are executed (Table 2).

In accordance with other reports [3, 5-7] this study also confirms that the UV test can be performed on urine specimens of follow-up patients, who received intravesical therapy. Sensitivity scores in our study are even higher in this population than in those without a tumour history.

There are some hypotheses for the false negative UV cases we encountered. Firstly, UCs in these cases may have other chromosomal alterations than those detectable by UV. Secondly, it is also known that low grade UCs are mostly diploid tumours [22, 23] and this may explain the false negative results, since most of our false negative UV cases were low grade tumours.

What to do with a positive UV test without detectable UC? In this regard, a positive UV test has been shown to be predictive of a future recurrence [8, 24-25] as it may be an indicator of unstable urothelium capable of or primed for malignant transformation, thus detecting patients at significant risk [26]. However, tetrasomic cells, mostly umbrella cells or dividing cells, can be present in urine samples and should not be interpreted as FISH-positive, malignant cells [8, 18].

In summary, our results suggest that a modification of the standard UV evaluation criteria on pre-screened preparations can result in a higher detection rate of UCs in patients with equivocal urinary cytology. Future prospective, blinded studies may help to validate our results in a higher number of patients and on a diversity of specimens (voided urine specimens, bladder washings, bladder and ureter catheterizations).

For Peer Review

REFERENCES

[1]Eble J, Sauter G, Epstein J and Sesterhenn I. WHO Classification of Tumors. Pathology and genetics of tumors of the urinary system and male genital organs. Lyon, France: IARC Press; 2004. p. 93.

[2]Schmidbauer J, Witjes F, Schmeller N, Donat R, Susani M, Merberger M. Improved detection of urothelial carcinoma in situ with hexaminolevulinate fluorescence cystoscopy. J Urol 2004;171:135-8.

[3] Têtu B. Diagnosis of urothelial carcinoma from urine. Mod Pathol 2009;22:S53-9.

[4] Hajdinjak T. Urovysion FISH test for detecting urothelial cancers: meta-analysis of diagnostic accuracy and comparison with urinary cytology testing. Urol Oncol 2008;26:646-51.

[5] Kipp B, Karnes R, Brankley S, et al. Monitoring intravesical therapy for superficial bladder cancer using fluorescence in situ hybridization. J Urol 2005;173:401-4.

[6] Mian C, Lodde M, Comploj E, et al. The value of the ImmunoCyt/uCyt+ test in the detection and follow-up of carcinoma in situ of the urinary bladder. Anticancer Res 2005;25:3641-4.

[7] Savic S, Zlobec I, Thalmann G, et al. The prognostic value of cytology and fluorescence in situ hybridization in the follow-up of nonmuscle – invasive bladder cancer after intravesical Bacillus Calmette-Guérin therapy. Int J Cancer 2009;124:2899-904.

[8] Bubendorf L, Grilli B, Sauter G, Mihatsch M, Gasser T, Dalquen P. Multiprobe FISH for enhanced detection of bladder cancer in voided urine specimens and bladder washings. Am J Clin Pathol 2001;116:79-86.

[9] Ferra S, Denley R, Herr H, Dalbagni G, Jhanwar S, Lin O. Reflex UroVysion testing in suspicious urine cytology cases. Cancer Cytopathol 2009;117:7-14.

[10] Desphande V, McKee GT. Analysis of atypical urine cytology in a tertiary care center. Cancer Cytopathol 2005;105:468-75.

[11] Garbar C, Mascaux C, Wespes E. Is urinary tract cytology still useful for diagnosis of bladder carcinomas? A large series of 592 bladder washings using a 5-category classification of different cytological diagnoses. Cytopathology 2007;18:79-83.

[12] Highman W, Wison E. Urine cytology in patients with calculi. J Clin Pathol 1982;35:350-6.

[13] Kannan V, Gupta D. Calculus artifact. A challenge in urinary cytology. Acta Cytol 1999;43:794-800.

[14] McVey RJ, Persad RV, Brown CWS, Robinson E, Payne SR. How long is urinary cytology abnormal after flexible cystoscopy. BJU Int 2004;94:548-51.

[15] Nabi G, Greene DR, O'Donnell M. How important is urinary cytology in the diagnosis of urological malignancies? Eur Urol 2003;43:632.

[16] Kipp B, Halling K, Campion B. Assessing the value of reflex fluorescence in situ hybridization testing in the diagnosis of bladder cancer when routine cytological examination is equivocal. J Urol 2008;179:1296-1301.

[17] Lotan Y, Bensalah K, Ruddell T, Shariat S, Sagalowsky A, Ashfaq R. Prospective evaluation of the clinical usefulness of reflex fluorescence in situ hybridization assay in patients with atypical cytology for the detection of urothelial carcinoma of the bladder. J Urol 2008;179:2164-9.

[18] Halling K, Kipp B. Bladder cancer detection using FISH (UroVysion assay). Adv Anat Pathol 2008;15:279-86.

[19] Akkad T, Brunner A, Pallwein L, et al. Fluorescence in situ hybridization for detecting upper urinary tract tumors – a preliminary report. Urology 2007;70:753-7.

[20] Luo B, Li W, Deng CH, et al. Utility of fluorescence in situ hybridization in the diagnosis of upper urinary tract urothelial carcinoma. Cancer Genet Cytogenet 2009;189:93-7.

[21] Marin-Aguilera M, Mengual L, Ribal MJ, et al. Utility of fluorescence in situ hybridization as a non-invasive technique in the diagnosis of upper urinary tract urothelial carcinoma. Eur Urol 2007;51:409-15.

[22] Kipp B, Tanasescu M, Else T, et al. Quantitative fluorescence in situ hybridization and its ability to predict bladder cancer recurrence and progression to muscle-invasive bladder cancer. J Mol Diagn 2009;11:148-54.

[23] Richter J, Jiang F, Gorog JP, et al. Marked genetic differences between stage pTa and stage pT1 papillary bladder cancer detected by comparative genomic hybridization. Cancer Res 1997;57:2860-64.

[24] Skacel M, Fahmy M, Brainard J, et al. Multitarget fluorescence in situ hybridization assay detects transitional cell carcinoma in the majority of patients with bladder cancer and atypical or negative urine cytology. J Urol 2003;169:2101-5.

[25] Yoder B, Skacel M, Hedgepeth R, et al. Reflex UroVysion testing of bladder cancer surveillance patients with equivocal or negative urine cytology: a prospective study with focus on the natural history of anticipatory positive findings. Am J Clin Pathol 2007;127:295-301.

[26] Veeramachaneni R, Nordberg M, Shi R, Herrera G, Turbat-Herrera E. Evaluation of fluorescence in situ hybridization as an ancillary tool to urine cytology in diagnosing urothelial carcinoma. Diagn Cytopathol 2003;28:301-7.

For Peer Review

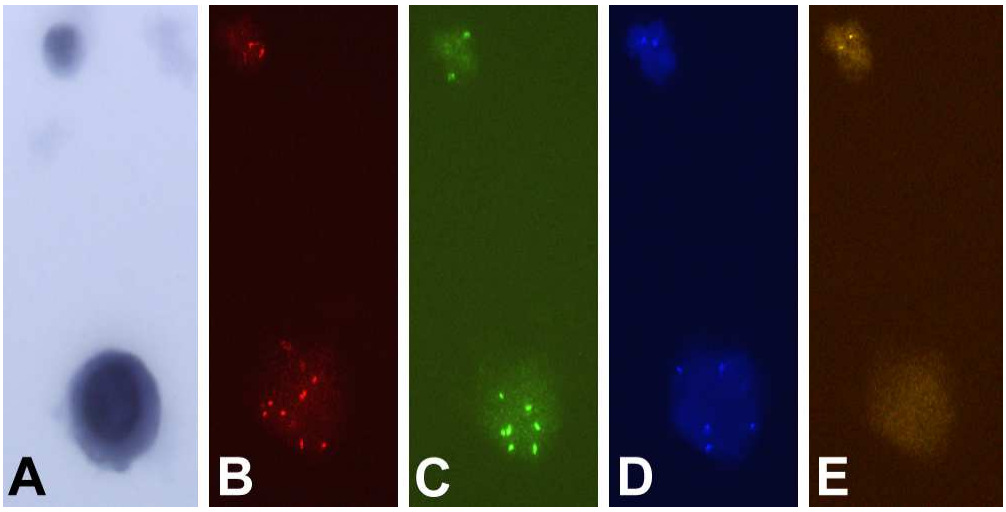

84x42mm (300 x 300 DPI)

eer Review

Figure 1. The coordinates of the atypical urothelial cell (A, under) on a haematoxylin pre-stained preparation are annotated during prescreening. Note the neutrophilic granulocyte (A, above). After fluorescence in situ hybridization the same atypical urothelial cell shows 7 copies of the centromeric region of chromosome 3 labeled with the fluorophore SpectrumRed (B), 7 copies of the centromeric region of chromosome 7 labeled with SpectrumGreen (C), 5 copies of the centromeric region of chromosome 17 labeled with SpectrumAqua (D) and homozygous loss of 9p21 labeled with SpectrumGold (E), while the neutrophilic granulocyte keeps 2 copies of each locus.

For Peer Review

Table 1: Patient characteristics

Number of patients	82
• No history of UC	• 34
• History of UC	• 48
○ Bladder UC	○ 45
○ Ureter UC	○ 1
○ Bladder + ureter UC	○ 2
Patients with cystoscopic evaluation	82
Patients with histologic evaluation	36
Male/female	4.1/1
Median ± SD patient age (years)	70 ± 11.4

UC: urothelial carcinoma

For Peer Review

Table 2: Cystoscopy and UV test performance characteristics for UC detection in patients with equivocal cytology specimens (n = 82 patients)

Examination	Sens	Spec	PPV	NPV	p
Cystoscopy	65% (20/31)	NA	NA	82% (51/62)	p<0.0001
UV1	68% (21/31)	84% (43/51)	72% (21/29)	81% (43/53)	p<0.0001
UV2	81% (25/31)	82% (42/51)	74% (25/34)	88% (42/48)	p<0.0001
UV1/cysto+	90% (28/31)	84% (43/51)	78% (28/36)	94% (43/46)	p<0.0001
UV2/cysto+	100% (31/31)	82% (42/51)	78% (31/40)	100% (42/42)	p<0.0001

UV: UroVysion® / UC: urothelial carcinoma

Sens: sensitivity / Spec: specificity

PPV: positive predictive value / NPV: negative predictive value

UV1: UV test positive according to the strict manufacturer's criteria

UV2: UV test positive when polysomy in at least one chromosome (3, 7 or 17) and/or heterozygous or homozygous deletion of 9p21

UV1/cysto+: UV test positive according to the strict manufacturer's criteria and/or cystoscopy positive

UV2/cysto+: UV test positive when polysomy in at least one chromosome (3, 7 or 17) and/or heterozygous or homozygous deletion of 9p21 and/or cystoscopy positive

NA: not applicable, since cystoscopy was used as gold standard in case of no histology control

For Peer Review

Table 3: Relationship between tumour grade, stage, cystoscopy and UV test

Patients with equivocal cytology and histology-proven UC (n = 24 patients)								
	G1 (n=3)	G2 (n=5)	G3 (n=12)	CIS (n=4)	Ta (n=15)	T1 (n=3)	T2 (n=1)	T3 (n=5)
Cysto-	0	2[a]	6[b]	3	5[c]	1[d]	0	5[e]
Cysto+	3	3	6	1	10	2	1	0
UV-	3	1	1	0	5	0	0	0
UV1	0	1	10[b]	4	8[c]	3[d]	1	3[f]
UV2	0	4[a]	11[b]	4	10[c]	3[d]	1	5[e]
UV1/cysto+	3	3	11[b]	4	14[c]	3[d]	1	3[f]
UV2/cysto+	3	5[a]	12[b]	4	15[c]	3[d]	1	5[e]

UC: urothelial cell carcinoma / CIS: carcinoma in situ

[a]: incl 2 pyelum UCs / [b]: incl 2 ureter UCs and 3 pyelum UCs / [c]: incl 1 pyelum UC / [d]: incl 1 ureter UC / [e]: incl 1 ureter UC and 4 pyelum UCs / [f]: incl 1 ureter UC and 2 pyelum UCs

Cysto-: cystoscopy negative / Cysto+: cystoscopy positive

UV-: UV test without chromosomal alterations

UV1: UV test positive according to the strict manufacturer's criteria

UV2: UV test positive when polysomy in at least one chromosome (3, 7 or 17) and/or heterozygous or homozygous deletion of 9p21

UV1/cysto+: UV test positive according to the strict manufacturer's criteria and/or cystoscopy positive

UV2/cysto+: UV test positive when polysomy in at least one chromosome (3, 7 or 17) and/or heterozygous or homozygous deletion of 9p21 and/or cystoscopy positive

For Peer

COPYRIGHT TRANSFER AGREEMENT

WILEY-BLACKWELL

Date: 31 ST October 2010 Contributor name: Clément Huysentruyt

Contributor address: Kwademeerslaan 13 8531 Hulste BELGIUM

Manuscript number (if known): HISTOP-08-10-0444

Re: Manuscript entitled Modified Urovysion scoring criteria increase the urothelial carcinoma detection rate in case of equivocal urinary cytology (the "Contribution")

for publication in Histopathology (the "Journal")

published by Wiley-Blackwell ("Wiley-Blackwell").

Dear Contributor(s):
Thank you for submitting your Contribution for publication. In order to expedite the editing and publishing process and enable Wiley-Blackwell to disseminate your Contribution to the fullest extent, we need to have this Copyright Transfer Agreement signed and returned as directed in the Journal's instructions for authors as soon as possible. If the Contribution is not accepted for publication, or if the Contribution is subsequently rejected, this Agreement shall be null and void. **Publication cannot proceed without a signed copy of this Agreement.**

A. COPYRIGHT

1. The Contributor assigns to Wiley-Blackwell, during the full term of copyright and any extensions or renewals, all copyright in and to the Contribution, and all rights therein, including but not limited to the right to publish, republish, transmit, sell, distribute and otherwise use the Contribution in whole or in part in electronic and print editions of the Journal and in derivative works throughout the world, in all languages and in all media of expression now known or later developed, and to license or permit others to do so.

2. Reproduction, posting, transmission or other distribution or use of the final Contribution in whole or in part in any medium by the Contributor as permitted by this Agreement requires a citation to the Journal and an appropriate credit to Wiley-Blackwell as Publisher, and/or the Society if applicable, suitable in form and content as follows: (Title of Article, Author, Journal Title and Volume/Issue, Copyright © [year], copyright owner as specified in the Journal). Links to the final article on Wiley-Blackwell's website are encouraged where appropriate.

B. RETAINED RIGHTS

Notwithstanding the above, the Contributor or, if applicable, the Contributor's Employer, retains all proprietary rights other than copyright, such as patent rights, in any process, procedure or article of manufacture described in the Contribution.

C. PERMITTED USES BY CONTRIBUTOR

1. Submitted Version. Wiley-Blackwell licenses back the following rights to the Contributor in the version of the Contribution as originally submitted for publication:

a. After publication of the final article, the right to self-archive on the Contributor's personal website or in the Contributor's institution's/employer's institutional repository or archive. This right extends to both intranets and the Internet. The Contributor may not update the submission version or replace it with the published Contribution. The version posted must contain a legend as follows: This is the pre-peer reviewed version of the following article: FULL CITE, which has been published in final form at [Link to final article].

b. The right to transmit, print and share copies with colleagues.

2. Accepted Version. Re-use of the accepted and peer-reviewed (but not final) version of the Contribution shall be by separate agreement with Wiley-Blackwell. Wiley-Blackwell has agreements with certain funding agencies governing reuse of this version. The details of those relationships, and other offerings allowing open web use, are set forth at the following website: http://www.wiley.com/go/funderstatement. NIH grantees should check the box at the bottom of this document.

3. Final Published Version. Wiley-Blackwell hereby licenses back to the Contributor the following rights with respect to the final published version of the Contribution:

a. Copies for colleagues. The personal right of the Contributor only to send or transmit individual copies of the final published version in any format to colleagues upon their specific request provided no fee is charged, and further-provided that there is no systematic distribution of the Contribution, e.g. posting on a listserve, website or automated delivery.

b. Re-use in other publications. The right to re-use the final Contribution or parts thereof for any publication authored or edited by the Contributor (excluding journal articles) where such re-used material constitutes less than half of the total material in such publication. In such case, any modifications should be accurately noted.

c. Teaching duties. The right to include the Contribution in teaching or training duties at the Contributor's institution/place of employment including in course packs, e-reserves, presentation at professional conferences, in-house training, or distance learning. The Contribution may not be used in seminars outside of normal teaching obligations (e.g. commercial seminars). Electronic posting of the final published version in connection with teaching/training at the Contributor's institution/place of employment is permitted subject to the implementation of reasonable access control mechanisms, such as user name and password. Posting the final published version on the open Internet is not permitted.

d. Oral presentations. The right to make oral presentations based on the Contribution.

4. Article Abstracts, Figures, Tables, Data Sets, Artwork and Selected Text (up to 250 words).

a. Contributors may re-use unmodified abstracts for any non-commercial purpose. For on-line uses of the abstracts, Wiley-Blackwell encourages but does not require linking back to the final published versions.

b. Contributors may re-use figures, tables, data sets, artwork, and selected text up to 250 words from their Contributions, provided the following conditions are met:

(i) Full and accurate credit must be given to the Contribution.
(ii) Modifications to the figures, tables and data must be noted. Otherwise, no changes may be made.
(iii) The reuse may not be made for direct commercial purposes, or for financial consideration to the Contributor.
(iv) Nothing herein shall permit dual publication in violation of journal ethical practices.

CTA-A

215x296mm (300 x 300 DPI)

D. CONTRIBUTIONS OWNED BY EMPLOYER

1. If the Contribution was written by the Contributor in the course of the Contributor's employment (as a "work-made-for-hire" in the course of employment), the Contribution is owned by the company/employer which must sign this Agreement (in addition to the Contributor's signature) in the space provided below. In such case, the company/employer hereby assigns to Wiley-Blackwell, during the full term of copyright, all copyright in and to the Contribution for the full term of copyright throughout the world as specified in paragraph A above.

2. In addition to the rights specified as retained in paragraph B above and the rights granted back to the Contributor pursuant to paragraph C above, Wiley-Blackwell hereby grants back, without charge, to such company/employer, its subsidiaries and divisions, the right to make copies of and distribute the final published Contribution internally in print format or electronically on the Company's internal network. Copies so used may not be resold or distributed externally. However the company/employer may include information and text from the Contribution as part of an information package included with software or other products offered for sale or license or included in patent applications. Posting of the final published Contribution by the institution on a public access website may only be done with Wiley-Blackwell's written permission, and payment of any applicable fee(s). Also, upon payment of Wiley-Blackwell's reprint fee, the institution may distribute print copies of the published Contribution externally.

E. GOVERNMENT CONTRACTS

In the case of a Contribution prepared under U.S. Government contract or grant, the U.S. Government may reproduce, without charge, all or portions of the Contribution and may authorize others to do so, for official U.S. Government purposes only, if the U.S. Government contract or grant so requires. (U.S. Government, U.K. Government, and other government employees: see notes at end)

F. COPYRIGHT NOTICE

The Contributor and the company/employer agree that any and all copies of the final published version of the Contribution or any part thereof distributed or posted by them in print or electronic format as permitted herein will include the notice of copyright as stipulated in the Journal and a full citation to the Journal as published by Wiley-Blackwell.

G. CONTRIBUTOR'S REPRESENTATIONS

The Contributor represents that the Contribution is the Contributor's original work, all individuals identified as Contributors actually contributed to the Contribution, and all individuals who contributed are included. If the Contribution was prepared jointly, the Contributor agrees to inform the co-Contributors of the terms of this Agreement and to obtain their signature to this Agreement or their written permission to sign on their behalf. The Contribution is submitted only to this Journal and has not been published before. (If excerpts from copyrighted works owned by third parties are included, the Contributor will obtain written permission from the copyright owners for all uses as set forth in Wiley-Blackwell's permissions form or in the Journal's Instructions for Contributors, and show credit to the sources in the Contribution.) The Contributor also warrants that the Contribution contains no libelous or unlawful statements, does not infringe upon the rights (including without limitation the copyright, patent or trademark rights) or the privacy of others, or contain material or instructions that might cause harm or injury.

CHECK ONE BOX:

☒ Contributor-owned work
ATTACH ADDITIONAL SIGNATURE PAGES AS NECESSARY

Contributor's signature [signature] Date 31st October 2010

Type or print name and title Clément Huysentruyt, MD

Co-contributor's signature _____ Date _____

Type or print name and title _____

☐ Company/Institution-owned work (made-for-hire in the course of employment)

Company or Institution (Employer-for-Hire) _____ Date _____

Authorized signature of Employer _____ Date _____

☐ U.S. Government work

Note to U.S. Government Employees
A contribution prepared by a U.S. federal government employee as part of the employee's official duties, or which is an official U.S. Government publication, is called a "U.S. Government work," and is in the public domain in the United States. In such case, the employee may cross out Paragraph A.1 but must sign (in the Contributor's signature line) and return this Agreement. If the Contribution was not prepared as part of the employee's duties or is not an official U.S. Government publication, it is not a U.S. Government work.

☐ U.K. Government work (Crown Copyright)

Note to U.K. Government Employees
The rights in a Contribution prepared by an employee of a U.K. government department, agency or other Crown body as part of his/her official duties, or which is an official government publication, belong to the Crown. U.K. government authors should submit a signed declaration form together with this Agreement. The form can be obtained via http://www.opsi.gov.uk/advice/crown-copyright/copyright-guidance/publication-of-articles-written-by-ministers-and-civil-servants.htm

☐ Other Government work

Note to Non-U.S., Non-U.K. Government Employees
If your status as a government employee legally prevents you from signing this Agreement, please contact the editorial office.

☐ NIH Grantees

Note to NIH Grantees
Pursuant to NIH mandate, Wiley-Blackwell will post the accepted version of Contributions authored by NIH grant-holders to PubMed Central upon acceptance. This accepted version will be made publicly available 12 months after publication. For further information, see www.wiley.com/go/nihmandate.

CTA-A

215x296mm (300 x 300 DPI)