



**HAL**  
open science

## Desbuquois dysplasia type I and fetal hydrops due to novel mutations in the CANT1 gene.

Franco Laccone, Katharina Schoner, Birgit Krabichler, Britta Kluge, Robin Schwerdtfeger, Bernt Schulze, Johannes Zschocke, Helga Rehder

► **To cite this version:**

Franco Laccone, Katharina Schoner, Birgit Krabichler, Britta Kluge, Robin Schwerdtfeger, et al.. Desbuquois dysplasia type I and fetal hydrops due to novel mutations in the CANT1 gene.. European Journal of Human Genetics, 2011, 10.1038/ejhg.2011.101 . hal-00649451

**HAL Id: hal-00649451**

**<https://hal.science/hal-00649451>**

Submitted on 8 Dec 2011

**HAL** is a multi-disciplinary open access archive for the deposit and dissemination of scientific research documents, whether they are published or not. The documents may come from teaching and research institutions in France or abroad, or from public or private research centers.

L'archive ouverte pluridisciplinaire **HAL**, est destinée au dépôt et à la diffusion de documents scientifiques de niveau recherche, publiés ou non, émanant des établissements d'enseignement et de recherche français ou étrangers, des laboratoires publics ou privés.

1 Title:

2 Desbuquois dysplasia type I and fetal hydrops due to novel mutations in the *CANT1*  
3 gene.

4 Franco Laccone<sup>1</sup>, Katharina Schoner<sup>2</sup>, Birgit Krabichler<sup>3</sup>, Britta Kluge<sup>1</sup>,  
5 Robin Schwerdtfeger<sup>4</sup>, Bernt Schulze<sup>4</sup>, Johannes Zschocke<sup>3,5</sup>, Helga Rehder<sup>1,2</sup>.

6

7 <sup>1)</sup> Institute of Medical Genetics, Medical University Vienna, Austria

8 <sup>2)</sup> Institute of Pathology, Philipps-University Marburg, Germany

9 <sup>3)</sup> Division of Human Genetics, Medical University Innsbruck, Austria

10 <sup>4)</sup> Center of Prenatal Diagnosis and Human Genetics, Hannover, Germany

11 <sup>5)</sup> Institute of Human Genetics, University Heidelberg, Germany

12

13

14 Address for correspondence: Ass. Prof. Dr. med. Franco Laccone

15 Institute of Medical Genetics,

16 Medical University Vienna

17 Waehringer Strasse 10

18 A-1090 Vienna

19 Tel: +43-(0)1-4277 60614

20 Fax: +43-(0)1-4277 9606

21 Email: [franco.laccone@meduniwien.ac.at](mailto:franco.laccone@meduniwien.ac.at)

22 Key Words: Skeletal dysplasia, Desbuquois syndrome, *CANT1* gene mutations,

23 haplotype analysis, fetal hydrops

24 Conflict of interest: none

1 **Abstract:**

2 We report on three hydropic fetuses of 17, 22 and 25 gestational weeks from three  
3 distinct families presenting with Desbuquois dysplasia type 1. All fetuses showed  
4 brachymelia and characteristic dysmorphic features. X-ray studies revealed delta-shaped  
5 extraphalangeal bones and disease-specific prominence of the lesser trochanter, varying  
6 in severity with fetal age. Early lethal manifestation of the disorder was reflected in lung  
7 hypoplasia and in early death of similarly affected siblings in cases 1 and 2. All families  
8 were German Caucasians by descent. Sequence analysis of the *CANTI* gene revealed  
9 two frameshift mutations, c.228\_229insC and c.277\_278delCT, in homozygous and  
10 compound heterozygous configuration respectively and a homozygously novel missense  
11 mutation, c.336C>A (p.D112E) located within a highly conserved region of exon 2.  
12 Haplotype analyses by high-resolution single nucleotide polymorphism array showed  
13 that the haplotype associated with c.228\_229insC may be traced to a single founder in  
14 the German population.

15

16

17 Key Words: Skeletal dysplasia, Desbuquois syndrome, *CANTI* gene mutations,

18 haplotype analysis, fetal hydrops, extra phalanx

19

20

21

## 1 **Introduction:**

2 Autosomal recessive Desbuquois dysplasia (DBQD, OMIM 251450) is a skeletal  
3 disorder defined by pre- and postnatal growth failure, short limbs, spondylometaphyseal  
4 abnormalities, osteopenia, advanced carpotarsal ossification and ligamentous joint  
5 laxity. It is associated with characteristic dysmorphic features, including a flat round  
6 face, midface hypoplasia, short nose, microstomia, and microretrognathia, often  
7 resulting in a Pierre Robin anomaly. Characteristic radiologic features are a small delta-  
8 shaped extraphalangeal bone distal to the second metacarpal, leading to radial deviation  
9 of the index fingers, metaphyseal flaring with prominent lesser trochanter causing a  
10 monkey wrench appearance of the proximal femora, horizontal acetabular roofs with  
11 dislocation of femoral heads, narrow thorax, and coronal or sagittal clefting of the  
12 vertebrae <sup>1-6</sup>. There are cases with mild clinical features that show no prenatal growth  
13 failure, normal hands, and only minor facial dysmorphism and joint problems. Thus, the  
14 disorder has been divided into two distinct groups with normal hands (type 2) and with  
15 abnormal hands (type 1) <sup>7,8</sup>. The latter condition displays a high lethality rate of >33%  
16 due to respiratory failure <sup>9</sup>. Sex distribution in 20 documented cases of DBQD type 1 is  
17 3:2 male:female <sup>3</sup>. Recently a new clinical subtype of DBQD has been described <sup>10</sup>.

18

19 The disease gene was localized to 17q25.3 <sup>11</sup>. In 2009, mutations in the *calcium-*  
20 *activated nucleotidase (CANT1)* gene were identified to be responsible for DBQD type  
21 1 in 10 affected patients from nine mostly non-European families. Early (perinatal)  
22 lethality in four of these patients was associated with nonsense mutations <sup>12</sup>. Very  
23 recently mutations in the CANT1-gene have also been found associated with the DBQD  
24 type 2 as well as with the so called “Kim variant” of DBQD <sup>13</sup>.

25

1 **Case descriptions:**

2

3 **Case 1:**

4 The first son of a 26 year-old woman died a few days after delivery from respiratory  
5 failure. He was affected by a skeletal dysplasia that, due to the presence of an atrioseptal  
6 defect, triphalangeal thumbs and supernumerary ossicles in both hands, was classified  
7 as Ellis-van Creveld (EvC) syndrome. Ten years later, recurrence of EvC syndrome was  
8 diagnosed in the second pregnancy by prenatal ultrasound. The pregnancy was  
9 terminated at 25 gestational weeks (g.w.). The healthy parents were consanguineous by  
10 an uncle-niece relationship and of German Caucasians descent (supplementary Fig. s1  
11 a)

12

13 **Case 2**

14 A male fetus resulted from the third pregnancy of non-consanguineous, healthy, 30  
15 year-old parents of German Caucasians descent. No information were available about  
16 common ancestors. Their first born girl had been affected by an unclassified  
17 chondrodysplasia and had died at the age of five months from respiratory problems. The  
18 second born son as also a fourth born daughter are healthy. Prenatal ultrasound during  
19 the third pregnancy revealed a recurrence of chondrodysplasia. The pregnancy was  
20 terminated at 21 g.w. (supplementary Fig. s1 b)

21 .

22 **Case 3:**

23 Prenatal ultrasound during the third pregnancy of a healthy 29-year-old nullipara with  
24 two previous early abortions revealed fetal hydrops with hygroma colli and short long

1 bones. The pregnancy was terminated at 17+1 g.w. Both non-consanguineous parents  
2 were German Caucasians by descent and no information were available about common  
3 ancestors (supplementary Fig. s1 c)

4 .

5

6 ***At autopsy*** the three hydropic male fetuses weighed 600/360/111 g, were 17.5/15/10 cm  
7 crown-rump length and 23.5/22.5/13.8 cm crown-heel length. They displayed almost  
8 identical characteristics, namely, brachymelic dwarfism, short neck and trunk, distended  
9 abdomen and a large cranium with high forehead (Fig. 1a and 1b). The faces were round  
10 and flat with short midfaces, very short, flat and broad noses with anteverted nares,  
11 microstomia, and microretrognathia, associated with a Pierre-Robin anomaly in cases 1  
12 and 2. The eyes were upslanting with proptosis and epicanthic folds and the ears were  
13 dorsally rotated and overfolded. In addition, case 3 had cystic hygroma of the neck (fig1  
14 c). The hands of each case showed radial deviation and clinodactyly of index fingers  
15 and low inserting broad thumbs with dysplastic nails. The feet were club feet with low  
16 inserting and short big toes. X-ray examination revealed mild shortening and bowing of  
17 long bones with slightly flared metaphyses and a protuberant lesser trochanter, in case  
18 1, giving a monkey wrench appearance of the proximal femora. There was pronounced  
19 shortening of the first metatarsals and of the first and second metacarpals, duplication or  
20 splitting of the distal phalanx of the thumbs, and a small laterally displaced extra  
21 phalangeal bone at the base of both index fingers (Fig. 2a-c). The femoral heads  
22 appeared dislocated, with narrow horizontal acetabular roofs (Fig. 3a-c). Other joints  
23 were fixed by the hydropic surrounding tissues, prohibiting an assessment of joint laxity  
24 in the three fetuses. The thorax was narrow and bell shaped and the ribs were thin. The

1 vertebral bodies showed sagittal clefts in the lumbar and thoracic regions of spine in  
2 cases 1 and 2 and more severe ossification defects of the spine in case 3 (supplementary  
3 Fig. s2). Histological examination of the long bones revealed crowding of enlarged  
4 resting chondrocytes and short, irregular columns with ovoid groupings of  
5 chondrocytes, as described by Shohat et al.<sup>6</sup>. In addition there were distinctly  
6 hypoplastic lungs, laryngeal stenosis, and dilatation of ureters and renal pelvices in case  
7 1, ASD in the affected sib of case 1, horseshoe kidneys in case 2, laryngo-  
8 tracheomalacia in the affected sib of case 2 and subaortic septal hypertrophy in case 3.  
9 Considering the characteristic findings and the affected sibs, (recurrent) DBQD type 1  
10 was diagnosed in all three hydropic fetuses (supplementary table s1).

11

## 12 **Molecular studies**

13 DNA was extracted from deep frozen fetal tissues in cases 2 and 3, using standard  
14 procedures. For the only available paraffin embedded tissues in case 1 (lung and  
15 kidney), the DNA was isolated using the EZ1 DNA Tissue Kit from Qiagen (Hilden,  
16 Germany). The four exons of the *CANT1* gene (transcript ENST00000302345) and  
17 adjacent intronic sequences were PCR amplified with newly designed primers  
18 (supplementary table s2) and sequenced using a fluorescent automated sequencer  
19 (Applied Biosystems 3130xl Genetic Analyzer). The fetus in case 1 was homozygous  
20 for a novel missense mutation c.336C>A in exon 2 of the *CANT1* gene, predicted to  
21 result in the replacement of aspartate with glutamate at residue 112 (p.D112E)  
22 (supplementary Fig. s3a-b). Case 2 displayed compound heterozygosity for two  
23 frameshift mutations in exon 2: c.277\_278delCT (p.L93VfsX89), which is novel, and  
24 c.228\_229insC (p.W77LfsX13) (supplementary Fig. s4 and s5). The latter mutation

1 c.228\_229insC was also found to be homozygous in case 3. Analysis of parental DNA  
2 in cases 2 and 3 confirmed Mendelian inheritance of the mutations. Parental DNA in  
3 case 1 was unavailable, but homozygosity was in line with the reported consanguinity  
4 of the parents. The presence of the mutations c.336C>A and c.228\_229insC has  
5 been also confirmed by RFLPs analysis (data not shown). In case of the  
6 c.277\_278delCT mutation no suitable restriction site was available for an RFLP  
7 analysis. In order to determine whether the mutation c.228\_229insC can be traced to a  
8 single founder, we carried out haplotype analyses on genomic DNA of the parents and  
9 fetuses of case 2 and 3 using a high-resolution single nucleotide polymorphism (SNP)  
10 array analysis (Illumina Omni1-quad Beadchips according to the Infinum HD Assay  
11 Protocol, Illumina, San Diego, Ca). Case 3 carried a rare haplotype in homozygous form  
12 for an 865 kb region on chromosome 17 that includes the *CANTI* gene. Haplotype  
13 retracing confirmed that the (maternally inherited) mutation c.228\_229insC in case 2  
14 was associated with the same SNP haplotype. This joint haplotype was limited by SNPs  
15 rs9910295 and rs2703549 on chromosome 17, an area that represents a known  
16 haplotype block. SNP alleles in the narrow, stable haplotype block containing the  
17 *CANTI* gene did not correspond to one of the predicted HapMap haplotypes<sup>14</sup>, but in  
18 6/8 positions resembled a HapMap haplotype with an allele frequency of 0.132. Our  
19 examination of published SNP frequency data and our own data confirmed an allele  
20 frequency of the haplotype associated with c.228\_229insC of at most 12%. The data  
21 thus indicate that mutation c.228\_229insC may be traced to a single founder in the  
22 German population. Molecular analysis of 200 chromosomes of in a panel of 200  
23 unrelated German Caucasians healthy controls excluded the presence of both c.336C>A  
24 and c.228\_229insC mutations.



1

## 2 **Discussion**

3 All three hydropic fetuses were affected by DBQD type 1, as confirmed by mutations in  
4 the *CANTI* gene. Independent of fetal age, they all displayed short limb dwarfism,  
5 radial deviation of index fingers due to a small delta-shaped extraphalangeal bone,  
6 duplicated, partly synostotic (split) distal phalangeal bones of the thumbs, horizontal  
7 acetabular roofs, underossification of vertebrae and characteristic craniofacial features,  
8 associated with a Pierre-Robin anomaly in cases 1 and 2 (Figs 1a-b and 2a-c). However,  
9 the syndrome-specific “monkey wrench appearance” of the proximal femora, caused by  
10 a prominent lesser trochanter, was convincingly demonstrated only in case 1, at 25 g.w..  
11 This abnormality was less evident in case 2, at 21 g.w., and not apparent in case 3, at 17  
12 g.w. and thus represents an evolutive feature (Fig. 3a-c).

13

14 As in other skeletal dysplasias, fetal hydrops implies a severe, lethal variant of the  
15 disorder. It has been mentioned in two sib fetuses of 12 and 19 g.w. that had shown  
16 similarities to Desbuquois dysplasia. However, molecular studies for confirmation of  
17 the suspected diagnosis had not been performed<sup>15</sup>. Hydrops was most marked in case 3  
18 with cystic hygroma of the neck that has not been described before. In the absence of a  
19 previous sib with skeletal dysplasia this Hydrops triggered a more thorough fetal  
20 ultrasound examination. In cases 1 and 2, diagnosis of DBQD allowed correction of the  
21 diagnoses in the previously born sibs. Failure to classify a skeletal dysplasia as DBQD  
22 type 1 in a prenatal ultrasound is well documented in the literature. As discussed by  
23 Baynam et al. (2010), an “upsilon sign” illustrating the widely splayed digits 2 and 3 as  
24 caused by the extraphalangeal bones may be used as a specific clue in prenatal

1 ultrasound and a molecular analysis may provide diagnostic certainty. In addition to the  
2 characteristic features of Desbuquois dysplasia, our cases presented with an atrial septal  
3 defect in the affected sib of case 1, with subaortic septal hypertrophy in case 3 and with  
4 renal anomalies, such as uretero-pelvic dilatation, horseshoe kidney and single renals  
5 cysts in cases 1, 2 and 3. While structural heart defects had been described before <sup>2,12</sup>  
6 renal anomalies have not yet been observed in DBQD. According to the Electronic  
7 Northern Expression as well as to the Microarray Expression for *CANT1*, the gene is  
8 expressed in both heart and kidney ([http://bioinfo2.weizmann.ac.il/cgi-](http://bioinfo2.weizmann.ac.il/cgi-bin/genenote/home_page.pl)  
9 [bin/genenote/home\\_page.pl](http://bioinfo2.weizmann.ac.il/cgi-bin/genenote/home_page.pl)) and may play a role during the embryonic developmental  
10 of both organs.

11 DBQD must be differentiated clinically from Catel-Manzke and from Larsen  
12 syndromes. An intermediate phenotype of DBQD, diastrophic dysplasia, and recessive  
13 multiple epiphyseal dysplasia, including the monkey wrench appearance of the proximal  
14 femora have been identified with compound heterozygote *DTDST* gene mutations <sup>16,17</sup>.

15

16 We identified three novel *CANT1* gene mutations in our patients, all located within exon  
17 2 of the gene. Two were frameshift mutations with predicted stop codons after 89 and  
18 13 missense amino acid residues, respectively, and were expected to cause complete  
19 loss of protein function probably through non-sense mediated RNA decay as disease-  
20 causing mechanism. The two frameshift mutations were found in compound  
21 heterozygous form in case 2 and the c.228\_229insC mutation in homozygous form in  
22 the severely hydropic fetus of case 3. The third mutation, found homozygously in the  
23 case with parental consanguinity, involves Asp<sup>112</sup>, an amino acid that is highly  
24 conserved up to maize (supplementary Fig. 3c). Yang and Kirley <sup>18</sup> demonstrated that

1 hSCAN-1, a protein of the apyrase family, binds poorly to the Cibacron blue nucleotide  
2 analogue affinity matrix in the presence of calcium if aspartic acid at position 84 is  
3 mutated (p.D84A); Asp<sup>84</sup> of hSCAN-1 corresponds to Asp<sup>114</sup> of the CANT1 protein.  
4 The homologous amino acids Asp<sup>112</sup> and Asp<sup>114</sup> are located in a highly conserved  
5 “nucleotide conserved region” (NCR1 b) of the apyrase gene family. This domain may  
6 have a crucial role in the binding of nucleotides or may be important for calcium-  
7 dependent conformational changes of the protein. Hamasaki et al.,<sup>19</sup> show that the D112  
8 is indeed a key residue for nucleotide binding by mutagenic experiments. This missense  
9 mutation was also predicted to be probably damaging with a score of 1.000 (sensitivity:  
10 0.00; specificity: 1.00) by an in silico analysis using the PolyPhen-2 software  
11 (v2.0.23r349)<sup>20</sup>. The mutation p.D112E is thus very likely to cause a complete loss of  
12 protein function in line with early lethality in our case 1.

13

14 Fifteen out of the seventeen previously described families with DBQD were from  
15 different non-European ethnicities, one was from France and a second from an  
16 Australia/Caucasian family<sup>12,13,21</sup>. Sixteen different mutations were identified in these  
17 families; (Table 1). Here we report the first mutations found in patients of German  
18 descent. Interestingly, three out of five independent DBQD alleles carried the same  
19 novel frameshift insertion, c.228\_229insC. Haplotype analysis confirmed that this  
20 mutation most likely traces back to a single founder. It is possible that this mutation  
21 represents a relatively common mutation in the German population; prenatal lethality  
22 associated with this mutation may explain why this mutation has not been reported  
23 before in the German population. Notably, Furuichi et al. reported this mutation in an  
24 Australian Caucasian patient<sup>13</sup>. According to our results, it may be plausible that this

1 patient has German ancestors. The identification in this patient of a common haplotype  
2 would reinforce our findings of a single founder for the c.228\_229insC mutation. We  
3 are not able to reliably determine the age of this mutation since the common haplotype  
4 encompasses a haplotype block, and there are only three independent alleles. The  
5 observations that 3 out of 5 independent chromosomes from our German patients  
6 carried this mutation may indicate that it is an old mutation, which may be expected  
7 also in other families.

8 The present report, in conjunction with the previously reported cases, confirms that  
9 complete functional loss of the CANT1 protein due to homozygous or compound  
10 heterozygous early frameshift mutations or missense mutations in critically functional  
11 regions of the protein is responsible for the early lethal form of DBQD. By contrast,  
12 missense mutations causing partial loss of protein function (e.g., the recurrent p.R300C  
13 and R300H mutations in exon 4) are associated with the classical form of DBQD. It is  
14 also possible that some missense mutations may cause intermediate or abortive forms of  
15 DBQD. Furthermore, we unveiled a founder mutation (c.228\_229insC) as demonstrated  
16 by the haplotype analysis in the German population.

17

18 Of our three fetal DBQD cases and the two affected sibs, four were male. This is  
19 consistent with previous reports that suggest a male preponderance of 2:3 F/M in  
20 DBQD type 1<sup>3</sup> and of 1:4 (4:17) F/M in 'early lethal DBQD'<sup>1,3,6,9,12,21,22</sup>. A good  
21 explanation for a male preponderance is still lacking; one possibility would be a better  
22 prenatal survival of male fetuses<sup>15</sup>.

23

1 Acknowledgements: We are grateful to Dr. Ute Moog, Institute of Human Genetics,  
2 University Heidelberg, for additional information concerning case 1 and to Dr Jürgen  
3 W. Spranger for clinical advice in case 1.

4

5 **References:**

6

- 7 **1 Beemer FA, Kramer PP, van der Harten HJ, Gerards LJ: A new syndrome**  
8 **of dwarfism, neonatal death, narrow chest, spondylometaphyseal**  
9 **abnormalities, and advanced bone age. *Am J Med Genet* 1985; 20: 555-558.**
- 10 **2 Desbuquois G, Grenier B, Michel J, Rossignol C: Nanisme**  
11 **chondrodystrophique avec ossification anarchic et polymalformations chez**  
12 **deux soeurs. *Arch Franc Pediatr* 1966; 23: 573-587.**
- 13 **3 Gillessen-Kaesbach G, Meinecke P, Ausems MG et al: Desbuquois**  
14 **syndrome: three further cases and review of the literature. *Clin Dysmorphol***  
15 **1995; 4: 136-144.**
- 16 **4 Le Merrer M, Young ID, Stanescu V, Maroteaux P: Desbuquois syndrome.**  
17 ***Eur J Pediatr* 1991; 150: 793-796.**
- 18 **5 Meinecke P, Spranger J, Schaefer E, Maroteaux P: Micromelic dwarfism**  
19 **with vertebral and metaphyseal abnormalities and advanced carpotarsal**  
20 **ossification: another observation. *Am J Med Genet* 1989; 32: 432-434.**
- 21 **6 Shohat M, Lachman R, Gruber HE et al: Desbuquois syndrome: clinical,**  
22 **radiographic, and morphologic characterization. *Am J Med Genet* 1994; 52:**  
23 **9-18.**

- 1 7 Faivre L, Cormier-Daire V, Elliott AM *et al*: Desbuquois dysplasia, a  
2 reevaluation with abnormal and "normal" hands: radiographic  
3 manifestations. *Am J Med Genet A* 2004; 124A: 48-53.
- 4 8 Nishimura G, Hong HS, Kawame H, Sato S, Cai G, Ozono K: A mild  
5 variant of Desbuquois dysplasia. *Eur J Pediatr* 1999; 158: 479-483.
- 6 9 Hall BD: Lethality in Desbuquois dysplasia: three new cases. *Pediatr Radiol*  
7 2001; 31: 43-47.
- 8 10 Kim OH, Nishimura G, Song HR *et al*: A variant of Desbuquois dysplasia  
9 characterized by advanced carpal bone age, short metacarpals, and  
10 elongated phalanges: report of seven cases. *Am J Med Genet A* 2010; 152A:  
11 875-885.
- 12 11 Faivre L, Le Merrer M, Al-Gazali LI *et al*: Homozygosity mapping of a  
13 Desbuquois dysplasia locus to chromosome 17q25.3. *J Med Genet* 2003; 40:  
14 282-284.
- 15 12 Huber C, Oules B, Bertoli M *et al*: Identification of CANT1 mutations in  
16 Desbuquois dysplasia. *Am J Hum Genet* 2009; 85: 706-710.
- 17 13 Furuichi T, Dai J, Cho TJ *et al*: CANT1 mutation is also responsible for  
18 Desbuquois dysplasia, type 2 and Kim variant. *J Med Genet* 2010.
- 19 14 Frazer KA, Ballinger DG, Cox DR *et al*: A second generation human  
20 haplotype map of over 3.1 million SNPs. *Nature* 2007; 449: 851-861.
- 21 15 Baynam G, Kiraly-Borri C, Goldblatt J, Dickinson JE, Jevon GP, Overkov  
22 A: A recurrence of a hydrop lethal skeletal dysplasia showing similarity to  
23 Desbuquois dysplasia and a proposed new sign: the Upsilon sign. *Am J Med*  
24 *Genet A* 2010; 152A: 966-969.

- 1   **16**   Miyake A, Nishimura G, Futami T *et al*: A compound heterozygote of novel  
2           and recurrent DTDST mutations results in a novel intermediate phenotype  
3           of Desbuquois dysplasia, diastrophic dysplasia, and recessive form of  
4           multiple epiphyseal dysplasia. *J Hum Genet* 2008; 53: 764-768.
- 5   **17**   Panzer KM, Lachman R, Modaff P, Pauli RM: A phenotype intermediate  
6           between Desbuquois dysplasia and diastrophic dysplasia secondary to  
7           mutations in DTDST. *Am J Med Genet A* 2008; 146A: 2920-2924.
- 8   **18**   Yang M, Kirley TL: Site-directed mutagenesis of human soluble calcium-  
9           activated nucleotidase 1 (hSCAN-1): identification of residues essential for  
10          enzyme activity and the Ca(2+)-induced conformational change.  
11         *Biochemistry* 2004; 43: 9185-9194.
- 12   **19**   Hamasaki R, Kato H, Terayama Y, Iwata H, Valenzuela JG: Functional  
13          characterization of a salivary apyrase from the sand fly, *Phlebotomus*  
14          duboscqi, a vector of *Leishmania major*. *J Insect Physiol* 2009; 55: 1044-  
15          1049.
- 16   **20**   Adzhubei IA, Schmidt S, Peshkin L *et al*: A method and server for  
17          predicting damaging missense mutations. *Nat Methods*; 7: 248-249.
- 18   **21**   Faden M, Al-Zahrani F, Arafah D, Alkuraya FS: Mutation of CANT1  
19          causes Desbuquois dysplasia. *Am J Med Genet A* 2010; 152A: 1157-1160.
- 20   **22**   al-Gazeli LI, Aziz SA, Bakalinova D: Desbuquois syndrome in an Arab  
21          Bedouin family. *Clin Genet* 1996; 50: 255-259.

22

23

1           **Figures legends:**

2

3 Fig. 1: Fetal aspect of case 1, 2 and 3 showing short limbs and trunk, hydrops, large  
4           cranium with flat round face, severe microretrognathia, and brachydaktyly, with  
5           short broad thumbs and radial deviation of index fingers. (a) case 1 - male, 25  
6           g.w.; (b) case 2 – male, 21 g.w., (c) case 3 – male, 17 g.w.

7

8 Fig. 2: X-ray of hands demonstrating short phalanges, short first and second  
9           metacarpals, duplicated or splitted distal phalanges of the thumbs and radial  
10          deviation of index fingers due to an extraphalangeal bone at the base of the  
11          proximal phalanges (arrows). (a) right hand of case 1, (b) left hand of case 3, (c)  
12          right hand of case 3.

13

14 Fig. 3: X-ray of femora and hips displaying narrow and horizontal acetabular roofs,  
15          mild shortening and bowing of femora, slight flaring of femoral metaphyses and  
16          protuberance of the lesser trochanter, giving a distinct monkey wrench  
17          appearance only in case 1 (a, arrows). (b) case 2 and (c) case 3.

18

19



Table 1: Reported mutations leading to different Desbuquois Dysplasia Types and geographic distribution.

consanguinity	Ethnicity	location	mutation at genomic level	effect on protein	lethality	subtype	ref
yes	Sri lanka	5'UTR + exon 1	del2703 bp/del 2703 bp	p.—/ p.—	yes	DD1	Huber et al. 2009
yes	Turkish	exon 3	c.734delC/ c.734delC	p.P245RfsX3/p.P245RfsX3	yes	DD1	„
yes	Turkish	exon 4	c.898C>T/c.898C>T	p.R300C/p.R300C	no	DD1	„
yes	Turkish	exon 4	c.898C>T/c.898C>T	p.R300C/p.R300C	no	DD1	„
yes	Iranian	exon 4	c.898C>T/c.898C>T	p.R300C/p.R300C	no	DD1	„
yes	French	exon 4	c.899G>A/c.899G>A	p.R300H/p.R300H	no	DD1	„
yes	Saudi	exon 4	c.899G>A/c.899G>A	p.R300H/p.R300H	no	DD1	„
yes	Moroccan	exon 4	c.907_911insGCGCC/ c.907_911insGCGCC	p.S303AfsX20/p.S303AfsX20	yes	DD1	„
no	Brasilian	exon 2/exon4	c.374G>A/ c.896C>T	p.W125X/p.P299L	no	DD1	„
yes	Saudi	exon 4	c.893_897insGCCGC/ c.893_897insGCCGC	p.325fsX/p.325fsX	yes	DD1	Faden et al. 2010 Furuichi et al. 2010
no	Australian Caucasian	exon 2	c.228_229insC/c.617T>C	p.W77LfsX13/p.L224P	no	DD1	„
yes	Turkish	exon 2	c.375G>C/c.375G>C	p.W125C/p.W125C	no	DD2	„
yes	Japanese	exon 3	c.676G>A/c.676G>A	p.V226M/p.V226M	no	DDKV	„
no	Japanese	exon 3/exon 4	c.676G>A/c.861C>A	p.V226M/p.C287X	no	DDKV	„
no	Japanese	exon 2/exon 3	c.494T>C/c.676G>A	p.M165T/p.V226M	no	DDKV	„
no	Korean	exon 3/exon 4	c.676G>A/c.1079C>A	p.V226M/p.A360D	no	DDKV	„
no	Korean	intron 2/exon 3	IVS2-9G>A/c.676G>A	p.G279VfsX8/p.V226M	no	DDKV	„
yes	German	exon 2	c.336C>A/c.336C>A	p.D112E/p.D112E	yes	DD1	present case 1

no	German	exon 2	c.277_278delCT/ c.228_229insC	p.L93VfsX89/p.W77LfsX13	yes	DD1	present case 2
no	German	exon 2	c.228_229insC/ c.228_229insC	p.W77LfsX13/p.W77LfsX13	yes	DD1	present case 3

DD1 = Desbuquois Dysplasya Typ I

DD2 = Desbuquois Dysplasya Typ II

DDKV = Desqubois Dysplasia "Kim Variant"

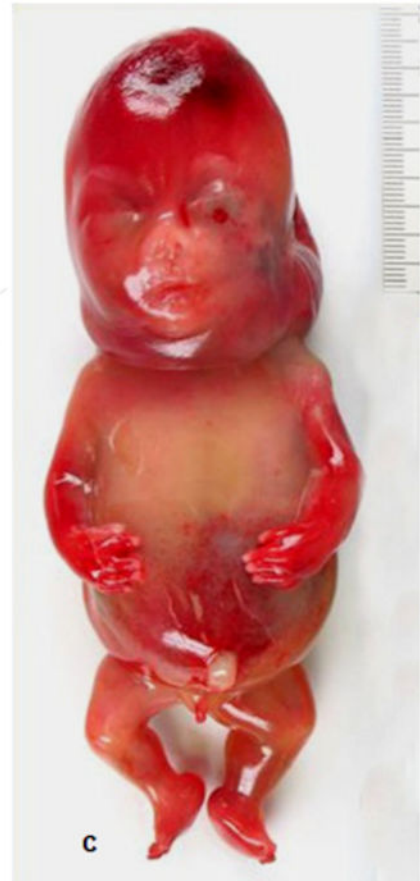
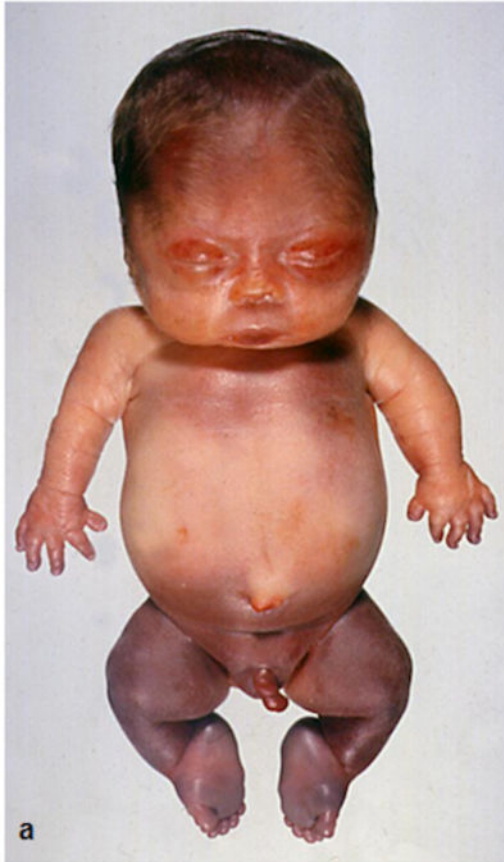
figure 1

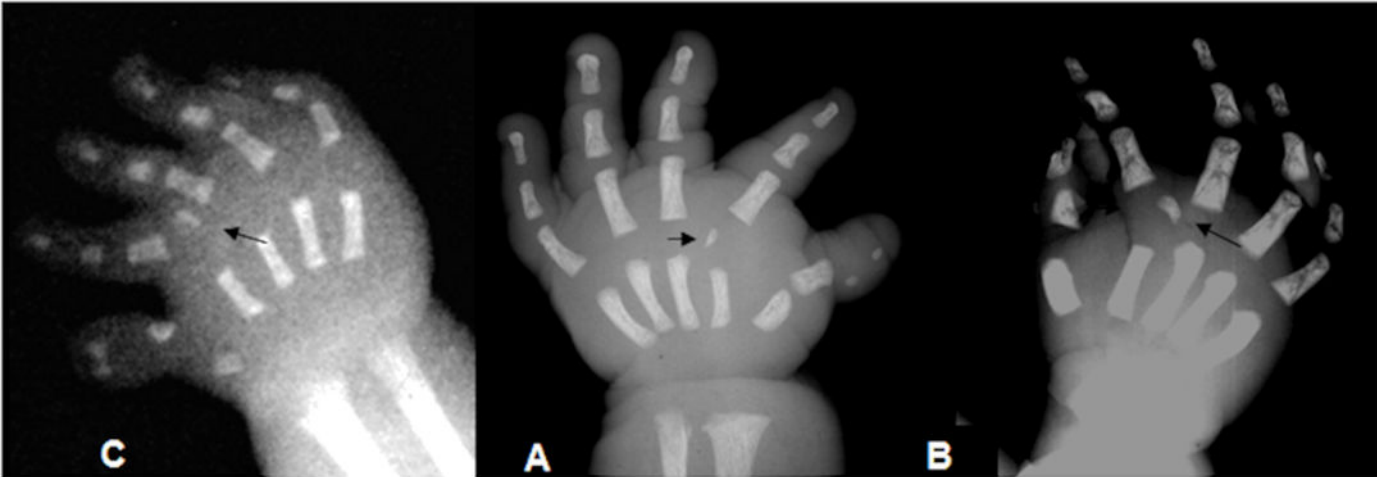


figure 2

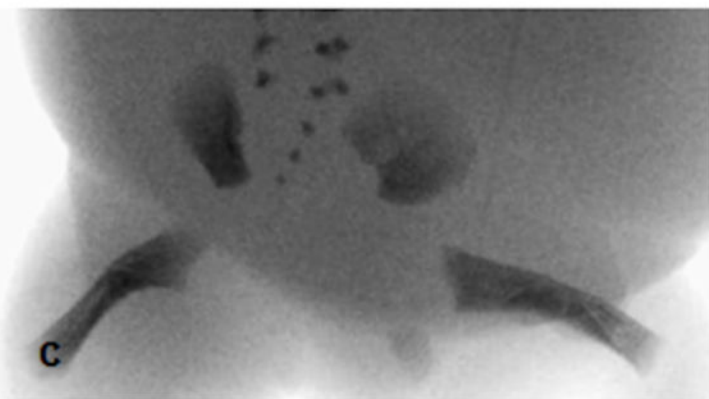
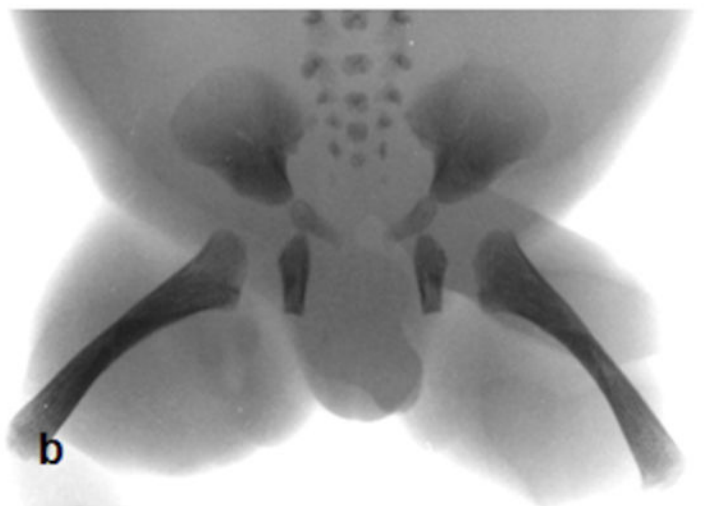
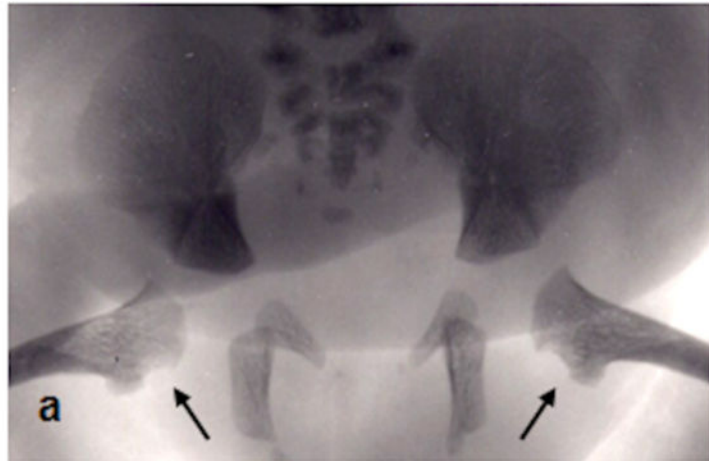


figure 3