



HAL
open science

Imaging technologies applied to chronic wounds: a survey

Leslie Casas, Castaneda Benjamin, Sylvie Treuillet

► **To cite this version:**

Leslie Casas, Castaneda Benjamin, Sylvie Treuillet. Imaging technologies applied to chronic wounds: a survey. ISABEL 2011, 4th International Symposium on Applied Sciences in Biomedical and Communication Technologies, Oct 2011, Barcelona, Spain. p1-5. hal-00647913v2

HAL Id: hal-00647913

<https://hal.science/hal-00647913v2>

Submitted on 5 Dec 2011

HAL is a multi-disciplinary open access archive for the deposit and dissemination of scientific research documents, whether they are published or not. The documents may come from teaching and research institutions in France or abroad, or from public or private research centers.

L'archive ouverte pluridisciplinaire **HAL**, est destinée au dépôt et à la diffusion de documents scientifiques de niveau recherche, publiés ou non, émanant des établissements d'enseignement et de recherche français ou étrangers, des laboratoires publics ou privés.

Imaging technologies applied to chronic wounds: a survey

Leslie Casas
Laboratorio de Imágenes Médicas
Departamento de Ingeniería
Pontificia Universidad Católica del
Perú
+51 1 6262000
casas.el@pucp.edu.pe

Benjamin Castaneda
Laboratorio de Imágenes Médicas
Departamento de Ingeniería
Pontificia Universidad Católica del
Perú
+51 999096966
castanda.b@pucp.edu.pe

Sylvie Treuillet
Laboratoire PRISME
Université d'Orléans
12 rue de Blois
F 45067 Orléans cedex
+33 238494565
Sylvie.Treuillet@univ-orleans.fr

ABSTRACT

Chronic wounds are a major problem in healthcare worldwide. The assessment and treatment of chronic wounds include monitoring color and size (area or volume) at regular intervals by an expert. This evaluation is often based on qualitative observation and manual measurements of the wound (using a caliper or tracing methods). Over the last two decades, several researchers have focused on developing technologies to assess the clinical improvement of chronic wounds. This article aims to provide a survey on imaging technologies applied to chronic wounds. Their accuracy, precision, reliability, ergonomics and usage are compared. In general terms, the survey aggregates the different methods into 3 groups: planimetric techniques, volumetric techniques and color classification. Finally, a discussion is provided on open topics and what progress needs to be done in this area of research. Among other key points, vision-based technologies for wound assessment should emphasize clinical validation, correlation of clinical findings with quantitative metrics and application to tele-dermatology.

General Terms

Measurement

Keywords

Chronic wounds, measure, imaging, tele-dermatology

1. INTRODUCTION

Chronic wounds are a major problem in the healthcare worldwide. The most typical chronic wounds are pressure, venous and diabetic ulcers, which mainly affect geriatric population, or patients who have lost totally or partially their capability of mobility [18].

Pressure applied to a particular area for a long period of time causes decomposition and necrosis of subcutaneous tissue, fat and muscle [19,30]. In Europe, it is estimated that over 2 millions of patients suffer from pressure ulcers [30]. In Peru, it was reported that between 11.4% and 16% of hospitalized geriatric patients developed pressure ulcers [26]. On the other hand, diabetic ulcers occur mainly due to two chronic complications: neuropathy and

"Permission to make digital or hard copies of all or part of this work for personal or classroom use is granted without fee provided that copies are not made or distributed for profit or commercial advantage and that copies bear this notice and the full citation on the first page. To copy otherwise, to republish, to post on servers or to redistribute to lists, requires prior specific permission and/or a fee.

ISABEL '11, October 26-29, Barcelona, Spain

Copyright © 2011 ACM ISBN 978-1-4503-0913-4/11/10... \$10.00"

vasculopathy. In particular, diabetic foot is the main cause for amputation of lower limbs. It has been reported that 85% of the patients with amputation of the limbs have suffered of a wound previously [10,34]. In USA, 47% of amputations require the removal of the lower limb, whereas in Peru, the percentage lies between 33% and 77% [1]. Finally, venous ulcers usually appear in the lower limbs due to chronic venous insufficiency. Between 54% and 78% of the cases reported re-occurrences even after a long period of treatment [14].

Chronic wounds may also appear as the clinical manifestation of a disease. Cutaneous Leishmaniasis is one example mostly found in tropical and subtropical areas around the world. According to the World Health Organization, it is considered as one of the six most important tropical diseases for research [20]. This is critical in countries like Peru, where this disease is endemic in 75% of the nation.

Chronic wounds directly affect the patient's quality of life causing social isolation, depression, decrease in productivity, and high costs for treatment [11,22]. In USA, a 2008 report from the National Institute of General Medical Sciences showed that chronic wounds treatment cost over 20 million dollars annually [33]. In Europe, it affects more than 2 billions people and the related cost is about 8 billions of Euros per year.

In this context, the assessment and monitoring of chronic wounds is a critical task to perform an accurate diagnosis and to select a suitable treatment. Clinical studies have shown that the reduction of a wound size is a good indicator of healing in most chronic wounds [11,28]. Additionally, color may provide relevant information about tissue type and inflammation [20]. Therefore, monitoring the size and aspect of the wound at regular intervals is part of the standard clinical practice. Nevertheless, this evaluation is mostly based on qualitative observation and manual measurements.

In this paper, a survey on imaging technologies applied to chronic wounds is presented. Their reliability, precision, ergonomics and usage are compared. Finally, a discussion is provided on remaining open topics and what progress needs to be done in this area of research.

2. COMMON PRACTICES FOR WOUND ASSESSMENT

In this section, the most common methods used by the clinicians are described. They are mainly based on manual, low-cost approaches for estimation of the area of the wound and, therefore, they suffer from high variability. These methods may be divided into techniques that measure area and perimeter, and techniques that measure volumetric information.

The first method uses a ruler (or a caliper) to measure the major and minor axes of the lesion. Based on these two measurements, the area of the wound is estimated as a rectangle [16] or as an ellipse [4]. When the model is a rectangle, the area may be overestimated by 10% to 45% with less accuracy for smaller wounds [16]. When the model is an ellipse, it was reported an error between 16% and 40% of the real area [4]. In either model, the decision of the major axes is subjective and has an impact on the variability of the method [28].

The second approach is performed by placing a transparent film over the wound and tracing the outline with a permanent marker [7]. Afterwards, the film is placed on a metric grid and the area is calculated by counting the number of squared millimeters contained within the outline. This process is time consuming and prone to human error. Alternatively, the outline could be traced directly into a digital pad [13,16,28]. Several studies have shown that the most important factor in error measurement is the correct and consistent identification of the border of the wound due to its poor definition or the subjectivity of the process [7]. Also, the number of partial squares of the grid inside the outline and the thickness of the marker may introduce some inaccuracy [4].

All the described techniques require direct contact with the wound to measure or estimate its area. Some other techniques have been evaluated to estimate the volume of the wound by filling it with liquid [35], or measuring it by using a cast model. These methods are highly invasive and are not commonly used clinically.

Under these circumstances, several research efforts have been focused to establish a more accurate, more precise, and less invasive method to estimate the dimensions of a wound over time. In the next section, techniques based on imaging technologies are reviewed.

3. IMAGING TECHNOLOGIES APPLIED TO WOUNDS

3.1 Historical review

Since 1986, there has been an increasing interest in the computer-aided diagnosis of skin lesions. First stereophotogrammetry was carried on pictures of wounds before digital cameras appeared. After taking stereo photographs and developing the film, the images were projected with a specialized mechanical device connected to a computer and observed in three dimensions through polarizing spectacles. The boundary was manually traced by the operator and the computer then calculated the area and the volume between the bottom of the wound and the original healthy surface extrapolated by third-order curves. The method was really innovative for the time and reported to be extremely accurate (2% error). However, it could not be used in clinical settings due to the amount of equipment required. During the 1990's, most of the work used digital images of wounds to find a reliable difference between injured and non-injured skin using color image processing and active contour models. Between 1998 and 2005, several prototypes attempted to monitor 3D characteristics of a wound: structured light techniques [18, 24], photogrammetry [19], an industrial 3-D digitizer [7] or a hand-held scanner [14]. All these prototypes were cumbersome and too expensive for routine care in clinics. Since 2005, a new generation of hand-held devices has been designed based on commercially available digital cameras or scanners. The state-of-art of these measurement devices may be divided in two approaches. A first group considers only planimetric measurement, whereas the second one allows volume calculation by reconstructing 3D models of wounds.

3.2 Planimetric tools

Pictzar (BioVisual Technologies LLC, NJ, USA) is an imaging software that allows the clinician to outline manually the border of the wound to calculate the area. For that purpose, a ruler or other accurate scale is included in the photo near the wound. Previous studies have reported that the accuracy error of this tool is 12% of the real area for wounds between 1 to 40 cm² [33].

Other approach is the tool AWAMS (Savant Imaging, Washington, USA) that includes a touch pad compatible with video cameras. The software calculates not only the area of the wound but also the percentages of tissue types. The selection of the wound border and the tissue types is manual. One downside of this tool is the requirement for specialized hardware. Both, Pictzar and AWAMS, need a suitable touch pad with the corresponding increase in cost. Moreover, these tools are highly dependent on the relative position of the tablet with respect to the wound when acquiring the image.

The wound measurement device presented in [21] estimated the area based on a smartphone camera and four laser diodes arranged to form a square for distance calibration and skew correction. Like the methods previously described, the wound border is traced manually in the smartphone to compute the area. The accuracy test showed that the average error was 1.96%, 1.76%, and 4.28% when the skew was 0, 5, and 10 degrees, respectively. It reported a good intra-observer and inter-observer reliability of 0.975 and 0.978, respectively. In spite of the good statistics shown, there were some issues reported by the users. Ambient lighting conditions or glare on the skin could cause acquisition problems. In addition, some injuries lied outside the geometric designated area to geometric layout for the lasers. Also a higher error of 7.5% was observed when the wound was placed in high curvature surfaces like heels, ankles or elbows.

Silhouette Mobile (Aranz Medical, Christchurch, New Zealand) provides also area measurements using a PDA equipped with a camera and two laser fan beams used for skew correction. The image is acquired within the projected laser beam fields and then the perimeter is traced manually for area calculation.

Other methods for correcting skew and scale have been developed. VeV MD (Unit 3, 55 Henlow Bay, Winnipeg, Canada) is a software that calculates the area of a wound from a digital picture acquired with a squared-shaped target plate placed in the same plane as the wound. They reported an accuracy of 22% for large wounds (100-336 cm²) and 5% for small ones (25-37.5%) [13].

3.3 Volumetric methods

In order to assess the dimensions of a wound more accurately, some researchers have focused on obtaining three dimensional models to measure not only area but volume. Metrics obtained from these models and their rate of change in time may provide clinicians with useful diagnostic information. Current 3D methods have been developed to obtain more accurate measurements without the constraint of the view-angle of a device. In that context, researchers have explored two methods for three dimensional reconstructions, active or passive scanning.

A new generation of portable and user-friendly 3D laser scanners is now available. For example, NextEngine Inc. (CA, USA) provides a low cost portable laser scanner which has been used for the assessment of cutaneous Leishmaniasis wounds [35]. This scanner has two arrays of four laser beams and two CMOS sensors to be used with small (<12 inch) and large (24 inch)

objects. The accuracy, according to the manufacturer, is 0.127 mm. In [35], only small wounds (<8cm²) were acquired. The 3D mesh of these wounds is processed off-line to provide several types of metrics (axes, perimeter, area and volume). The reported accuracy and precision were 0.63% and 1.26%, respectively. The main advantage of this method is that it outlines the contour of the wound automatically. This process is not only performed based on color, but on the height of the wound. The disadvantage of this method is the need of specialized equipment which is probably not available in hospitals. Figure 1 shows an example of a reconstructed Leishmaniasis wound.

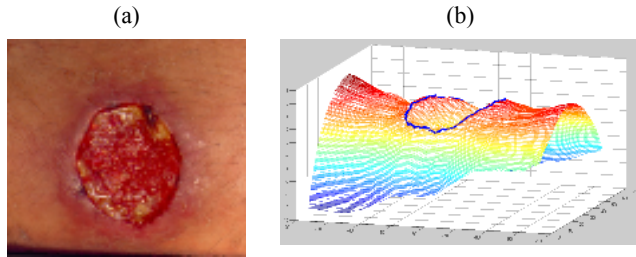


Figure 1. Image (a) and 3D reconstruction (b) of a cutaneous Leishmaniasis wound. (a) is a courtesy of Drs. Llanos and Valencia from the Instituto de Medicina Tropical Alexander von Humboldt, Universidad Peruana Cayetano Heredia, and (b) was provided by the Laboratorio de Imágenes Médicas, Pontificia Universidad Católica del Perú.

The second prototype of the project MAVIS [25] is based on idea of stereo vision and uses an array of mirrors and lenses in order to obtain two laterally displaced images. Then, it performs a 3D reconstruction of the object. In this method, the contour is traced manually with an error in area estimation of 1.5% for large wounds (>5 cm²) and 5% for small ones (<5cm²). The precision error is 8% and 5% for small and large wounds, respectively. The error in volume estimation is between 2% and 6% depending on the size of the wound. This system was improved by introducing markers for the reconstruction process and utilizing an automatic outline system. This method is portable and user-friendly.

In addition, a new approach was developed by Treuillet et al [30] using only a standard camera for stereo vision. They performed a 3D reconstruction based on two images. Robust algorithms for image matching and self-camera calibration were used to address the unknown constraints like accurate position of the cameras, illumination, view-angle and skew. This work reported a variability of 5% and a relative error of 0.43% with a standard deviation of 3.17 %. This system has the advantage that it only requires a digital camera to perform the acquisition and, therefore, it could be used easily in hospitals and clinics. Moreover the images could be taken and sent via internet for processing (See figure 2).

The disadvantages of the previous work, Mavis II and probably other systems based of photos are the constraints related to the acquisition process. In spite of the corrections applied to the images, these constraints may produce a less accurate 3D model. Image matching is affected by irregular illumination and contrast, which may result in less control points producing a poor representation of the wound.

Tables 1 and 2 provide a quick overview of the performance of all the vision-based technologies reviewed in this article.

3.4 Color Classification of wounds

Besides size measurement, another important focus on assessing wounds is the evaluation of skin-tissue injury. The assessment of the healing progress of these chronic wounds relies still commonly on visual inspection based on a red-yellow-black ruler corresponding respectively to the dominant color of three types of tissues: granulation, slough and necrosis. Color image analysis may be pertinent for assessing skin tissues injury, and providing quantitative measurement without contact.

Table 1. Overview of volumetric technologies

	Derma	Next Engine	MED-PHOS	Mavis-II	Stereo
Principle	Laser	Laser	Photos + Laser	Photos	Photos
Accuracy	✓✓	✓✓✓	✓✓✓✓	✓✓	✓✓
Repeatability	✓✓	✓✓✓	✓✓✓	✓✓	✓✓
Ergonomics	✓	✓✓	✓	✓✓✓	✓✓✓
Training time	✓✓✓	✓✓	✓✓	✓	✓
Cost	✓✓✓	✓✓	✓✓✓	✓✓	✓

Table 2. Overview of planimetric technologies

	Pictzar	AWAMS	WMD	VeV MD
Principle	Photo	Photo+ Touch pad	Laser + photo	Photo
Accuracy	✓✓	(*)	✓✓	✓✓
Inter-Repeatability	✓✓	(*)	✓✓	✓✓
Intra-Repeatability	✓✓✓	(*)	✓✓	✓✓✓
Ergonomics	✓✓✓	✓	✓✓	✓✓✓
Training time	✓	✓✓	✓✓✓	✓✓
Cost	✓	✓✓✓	✓✓	✓

✓: Poor, ✓✓:Medium, ✓✓✓:High (*) Information not available

First works proposed a simple correlation between healing evolution and dominant color [3]. More advanced algorithms used splines [23] and SVM classifier [17] to automatically find the border of the wound without convincing results. Since color texture inside the wound is highly variable, complete tissue classification gives a more reliable border definition of the wound than two-state segmentation (injured vs. healthy skin). Applying threshold techniques for partitioning the wound area in several regions relative to tissue types is not efficient because of the biological variability and inhomogeneity of tissue texture properties [2,27]. To overcome this problem, binary morphology and active contours were used to improve the final outline of the lesion [9]. A more robust approach consisted on using pattern recognition techniques based on learning processes. In several studies, tissue samples for learning were manually extracted [12,27] without considering a large image database. Recent works proposed to apply an unsupervised region segmentation on the color image of the wound, before classifying the regions in different tissues categories [6,31]. Classifying regions against individual pixels is preferable since the segmentation process groups homogeneous pixels considering spatial continuity. The color features extracted from homogeneous regions are statistically more robust and texture features may also be computed. Several descriptors have been tested to find the best tissue characterization such as mean, dominant color, histograms,

gabor coefficients, local binary pattern, co-occurrence matrix for texture contrast and anisotropy. Nevertheless, a critical problem relative to a large database collected in several care centers is color correction as lighting conditions are not controlled. Color constancy can be improved by including a color checker pattern in the field of view of the camera [31]. In comparison with expert labeling, best results of tissue classification into granulation-slough-necrosis were obtained by coupling color and texture descriptors in a SVM classifier, with a success rate of 84%, specificity of 92%, sensitivity of 77% and overall accuracy of 88%. Once tissue classification was done, size measurement or surface area could be computed. However, results remained dependent to the image acquisition process (scale factor and point of view). A solution may consist in coupling color classification with 3D vision modeling by combining several images captured with a hand held camera in different viewpoints [32]. This multi-view strategy improves the repeatability and robustness of the classification and gives access to real area values considering body curvature (see figure 2).

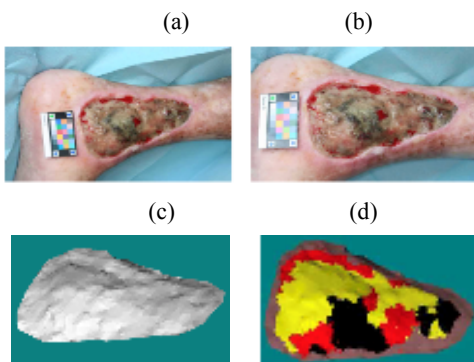


Figure 2. Example of automatic color classification applied on the 3D model of wound: (a-b) Stereo pairs, (c) 3D model, and (d) Automatic color classification of tissues. Courtesy of Laboratoire PRISME, Université d'Orléans.

4. DISCUSSION

Within clinical standards, wound assessment is still an operator dependent endeavor with high variability based on manual measurements. Therefore, it is a qualitative procedure which relies on the experience of the dermatologist to produce a good diagnosis or evaluation. As reviewed in the last section, over the last couple of decades, there have been several prototypes and even products which address how wound assessment can be ameliorated. Although, these new techniques reported very promising results on increasing accuracy in size measurements while reducing inter and intra-observer variability, they have not been adopted in clinical standards. Most of the newly developed devices, even low-cost and user-friendly ones, seem to stay at the test stage. There is clearly a lack of clinical results to support their use. Therefore, research on their clinical relevance should be emphasized.

Vision-based technologies may have an impact on wound assessment at several stages. First, let's consider the improvement just based on the accurate representation of the wound for remote evaluation and diagnosis. Recent advances on information and communication technologies, such as smart mobile phones and wireless networks, have made possible to capture, process and transmit high resolution images. These advances enable the dermatological evaluation of population in remote areas. Direct usage of digital images can help to obtain a remote diagnostic. Recently, Tran et al [29] have found encouraging results on the

diagnostic value of pictures taken from a mobile phone and sent wirelessly to a remote specialist. Moreover, current 3D representation of the wounds and remote manipulation by the expert could give a further impulse to the field of tele-dermatology.

Another impact which is yet to be evaluated is the change from qualitative to quantitative diagnosis. From the previous section, several metrics regarding size, texture and color can now be provided with enough precision as to evaluate its clinical usefulness. From the medical point of view, there is still a question on which ones of these are convenient metrics for assessment of wound healing. Furthermore, this evaluation could include their evolution over time. In this aspect, a large clinical validation for a reliable statistical analysis of these indexes or biomarkers is missing in the literature.

In the previous section, 2D and 3D techniques were described. Although the former ones are easier to implement and even to manipulate by healthcare technicians, there are important points in favor of the latter ones. Measurements from 2D techniques are influenced by lighting conditions, camera position and angle of acquisition. Also, there is an intrinsic loss of information on the representation of 3D real world information on an image. On the other hand, 3D techniques could produce more metrics from the wound such as perimeter, depth, area and volume. It is true that these techniques require more specialized equipment; however, customized low-cost hardware could be developed if the clinical gain justifies the effort. Furthermore, there are already some 3D methods which only require a digital camera.

A critical aspect on the definition of the abovementioned metrics is the accurate delineation of the border of the wound. This important task is currently made manually with the consequent increase on variability. Although some efforts have been done to use color information to automate this process, it is still a challenge. Recent work [21] suggests that combining 3D surface and color information could improve this task. Finally, it is also worth to highlight that volumetric metrics are less sensitive to border delineation than planar metrics.

Finally, vision-based technologies can be combined with other technologies such as multi-spectral, hyper-spectral and ultrasonic imaging for more accurate and reliable tissue characterization.

5. REFERENCES

- [1] Alcántara, W., Flores, R., Garmendia, F. 1999. Prevalence and risk factors for amputations in patients with diabetic foot. *Anales de la Facultad de Medicina*, Vol. 60 No. 3. Universidad Mayor de San Marcos, 159-164.
- [2] Berris, W.P., Sanwine, S.J., 1988. Color histogram clustering technique for tissue analysis of healing skin wound. *Proc. Of 6th Int Conf on Image Processing and its applications*, Dublin (July 1988), 693-699.
- [3] Bon, G., Briand E., Guichard, S., Couturaud, B., et al, 2000. Quantitative and kinetic evolution of wound healing through image analysis. *IEEE Trans. Med. Imag.*, Vol. 19, No. 7, (Jul. 2000) 767-772.
- [4] Bowling, F., King, L., Fadavit, H. et al. 2008. An assessment of the accuracy and usability of a novel optical wound measurement system. *Diabetic Medicine*, Vol. No. 26 (January 2009), 93-96.
- [5] Callieri, M., Cignoni, P., Scopigno, R. 2003. DERMA: monitoring the evolution of skin lesions with a 3D system.

- Vision, Model, Visualization, Munchen Germany (Nov. 2003) 167–174.
- [6] Celebi, M., Aslandogan, Y., Bergstresser, P., 2005. Unsupervised border detection of skin lesion images. in Proc. Int. Conf. Inf. Technol.: Coding Comput. (ITCC05), Vol. 2, 123–128
- [7] Chang, A., Dearman, B., Greenwood, J., 2011. A Comparison of Wound Area Measurement Techniques: Visitrak Versus Photography. Open Access Journal of Plastic Surgery, (April 2011) 158-166
- [8] Convington, J., Griffin, J., Mendius, R., Tooms, R., Clift, J. Measurement of pressure ulcer volume using dental impression materials: Suggestion from the field. Physical Therapy. Vol. 69 No. 8 (Aug 1989).
- [9] Diaz, K., Castaneda, B., Miranda, C. et al. 2008. Development of an acquisition protocol and a segmentation algorithm for wounds of cutaneous leishmaniasis in digital images. SPIE, 2010.
- [10] Elguera, F., Villanueva, J., Neyra, L. 2006. Bacteriologic study of diabetic foot infected at Arzobispo Loayza Hospital. Revista de la Sociedad Peruana de Medicina Interna 19. 5-9
- [11] Gethin, G. 2006. The importance of continuous wound measuring. Wounds UK, Vol.2, No. 2, 60-68
- [12] Galushka, M., Zheng, H., Patterson, D., Bradley, L., 2005. Case-based tissue classification for monitoring leg ulcer healing. Proc. 18th IEEE Symp. Computer-Based Med. Syst., 353–358.
- [13] Haghpahan, S., Bogie, K., DPhil, Wang, X. 2006. Reliability of Electronic Versus Manual Wound Measurement Techniques. Arch Phys Med Rehabil., 1396-1402.
- [14] Harrisona, J., Nixon, M., Fright, W. Snapea, L. 2004. Use of hand-held laser scanning in the assessment of facial swelling: a preliminary study. British Journal of Oral and Maxillofacial Surgery, Vol. 42. 8-17.
- [15] Keast, D., Bowering, C., Wayne, A. et al. 2004. MEASURE: A proposed assessment framework for developing best practice recommendations for wound assessment. Wound Repair and Regeneration 12. (May-June 2004), S1-S17
- [16] Kecelj-Leskovec, N., Jezersek, M., Mozina, J., et al. 2007. Measurement of venous leg ulcers with a laser-based three dimensional method: Comparison to computer planimetry with photography. Wound Repair and Regeneration 15, (May 2007) 767-771.
- [17] Kolesnik, M., Fexa, A., 2005. Multi-dimensional color histograms for segmentation of wounds in images. Lecture Notes in Computer Science, Vol. 3656, 1014–1022.
- [18] Krouskop, T., Baker, R., Wilson, M. 2002. A non contact wound measurement system. Journal of Rehabilitation Research and Development Vol. 39, No. 3 (June 2002)
- [19] Malian, A. Azizi, A., Heuvel Van Den, F. A., Zolfaghari, M. 2005. Development of a robust photogrammetric metrology system for monitoring the healing of bedsores. *Photogrammetric Record* 20 (September 2005) 241-273.
- [20] Ministerio de Salud. Oficina General de Epidemiología. Módulos Técnicos. Serie de Monografías. Leishmaniasis. Lima, Perú. 2000:08-83.
- [21] Nemeth, M., Springler, S., Gajjala, A., et al., 2010. Clinical Usability of a Wound Measurement Device 36th Annual American Spinal Injury Conference. (Nashville, Tennessee, USA).
- [22] Newton, H. 2010. Assessment of a venous ulcer. Wound Essential. Vol. 5, 69-78.
- [23] Oduncu, H., Hoppe, A., Clark, M. et al., 2004. Analysis of skin wound images using digital color image processing: A preliminary communication. Int. J. Low Extremity Wounds, Vol. 3, No. 3 (Sep. 2004), 151–156.
- [24] Plassman, P., Jones, T.D. 1998. MAVIS: a non-invasive instrument to measure area and volume of wounds. Medical Engineering & Physics, 20 (1998), p.325-331
- [25] Plassmann P, Jones CD., 2007. Accuracy and Precision of the Hand-Held MAVIS Wound Measurement Device. The International Journal of Lower Extremity Wounds. Vol. 6. No. 3 (Sep 2007) 176-190.
- [26] Peralta, C., Varela, L., Gálvez, M., 2009. Frequency of pressure ulcers and its related factors in elderly patients admitted to the Medicine wards at a general hospital. Revista Médica Herediana 20 (2009)
- [27] Perez, A., Gonzaga, A., and Alves, J., 2001. Segmentation and analysis of leg ulcers color images. Proc. Int. Workshop Med. Imag. Augmented Reality (June 2001), 262–266.
- [28] Thawer, H., Houghton, P., Woodbury, G. 2002. A comparison of computer-assisted and manual wound size measurement. Ostomy Wound Management. Vol. 48, No. 10, 46-53.
- [29] Tran, K. Ayad, M., Weinverg, J. et al, 2011. Mobile teledermatology in the developing world: Implications of a feasibility study on 30 Egyptian patients with common skin diseases. Journal of the American Academy of Dermatology, Vol. 64, No. 2 (Feb 2011), 302-309.
- [30] Treuillet, S., Albouy, B., Lucas, Y. 2009. Three-Dimensional Assessment of Skin Wounds Using a Standard Digital Camera. IEEE Transactions on Medical Imaging, Vol. 28, No. 5 (May 2009)
- [31] Wannous, H., Treuillet, S., Lucas, Y., 2010. Robust tissue classification for reproducible wound assessment in telemedicine environments. J. Electron. Imag., Vol. 19, No. 2, (Apr-Jun 2010) 1-9
- [32] Wannous, H., Treuillet, S., Lucas, Y., 2011. Enhanced Assessment of the Wound-Healing Process by Accurate Multiview Tissue Classification. IEEE Transactions on Medical Imaging, Vol. 30, No. 2, (Feb. 2011), 315-326.
- [33] Wendelken, M., Berg, W., Lichtenstein, P. 2011. Wounds Measured From Digital Photographs Using Photodigital Planimetry Software: Validation and Rater Reliability. Wounds Vol. 23, No. 9 (September 2011) 267-275.
- [34] Woolcott, K., Pachas, C. 2008. Risks for pressure ulcers according Scale Norton in aged patient at an institution of a domiciliary service of Lima. Revista de Enfermería Herediana 01, (Marzo 2008) 26-32.
- [35] Zvietsovich, F. 2011. Estimación de volume de lesiones producidas por leishmaniasis cutánea utilizando un escáner laser de triangulación. BS Thesis. Pontificia Universidad Católica del Perú.