



HAL
open science

14-Year Outcomes of Coronally Advanced Flap for Root Coverage: Follow-up from a Randomized Trial

Giovanpaolo Pini Prato, Roberto Rotundo, Debora Franceschi, Francesco Cairo, Pierpaolo Cortellini, Michele Nieri

► **To cite this version:**

Giovanpaolo Pini Prato, Roberto Rotundo, Debora Franceschi, Francesco Cairo, Pierpaolo Cortellini, et al.. 14-Year Outcomes of Coronally Advanced Flap for Root Coverage: Follow-up from a Randomized Trial. *Journal of Clinical Periodontology*, 2011, 38 (8), pp.715. 10.1111/j.1600-051X.2011.01744.x . hal-00647406

HAL Id: hal-00647406

<https://hal.science/hal-00647406v1>

Submitted on 2 Dec 2011

HAL is a multi-disciplinary open access archive for the deposit and dissemination of scientific research documents, whether they are published or not. The documents may come from teaching and research institutions in France or abroad, or from public or private research centers.

L'archive ouverte pluridisciplinaire **HAL**, est destinée au dépôt et à la diffusion de documents scientifiques de niveau recherche, publiés ou non, émanant des établissements d'enseignement et de recherche français ou étrangers, des laboratoires publics ou privés.



14-Year Outcomes of Coronally Advanced Flap for Root Coverage: Follow-up from a Randomized Trial

Journal:	<i>Journal of Clinical Periodontology</i>
Manuscript ID:	CPE-12-10-3025.R2
Manuscript Type:	Original Article Clinical Periodontology
Date Submitted by the Author:	09-Apr-2011
Complete List of Authors:	Pini Prato, Giovanpaolo; university of florence, periodontology Rotundo, Roberto; University of Florence, Florence, Italy, 1Department of Periodontology Franceschi, Debora; University of Florence, Florence, italy, 1Department of Periodontology Cairo, Francesco; University of Florence, Florence, Italy, 1Department of Periodontology Cortellini, Pierpaolo; 2Accademia Toscana di Ricerca Odontostomatologica (ATRO) Nieri, Michele; University of Florence, Periodontology
Topic:	Treatment
Keywords:	gingival recession, coronally advanced flap, randomized controlled trial, long term, statistical interaction
Main Methodology:	Clinical Trial

SCHOLARONE™
Manuscripts

1
2
3 **14-Year Outcomes of Coronally Advanced Flap for Root Coverage:**
4
5

6 **Follow-up from a Randomized Trial**
7
8
9

10
11
12
13 Pini Prato Giovanpaolo¹, Rotundo Roberto¹, Franceschi Debora¹, Cairo Francesco¹, Cortellini
14
15 Pierpaolo², Nieri Michele¹
16
17

18
19
20
21
22 ¹Department of Periodontology, University of Florence, Florence, Italy
23

24
25 ²Accademia Toscana di Ricerca Odontostomatologica (ATRO)
26
27
28
29
30

31 **Running title:** Long-term root coverage
32
33

34 **Key words:** gingival recession, coronally advanced flap, randomized controlled trial, long term,
35
36 statistical interaction
37
38
39
40
41
42

43 **Address for correspondence:** Pini Prato Giovanpaolo
44

45
46 viale Matteotti,11 - 50121 - Florence, Italy
47

48 e-mail: gpinipr@tin.it
49
50

51 **Conflict of interest:** The authors declare that there are no conflicts of interest in this study.
52
53

54 **Source of funding:** No external funding, apart from the support of the authors' institutions, was
55
56 available for this study.
57
58
59
60

ABSTRACT

Trial design: This long-term 14-year-randomized split-mouth study aimed at evaluating (1) the outcomes of two different methods of root surface modifications (root surface polishing vs. root-planing) used in combination with coronally advanced flap (CAF) and (2) the long-term results of CAF performed for the treatment of single gingival recessions.

Methods: Ten patients with similar bilateral recessions ≥ 2 mm were selected for a split-mouth randomized design study. Exposed root surfaces were assigned to receive polishing (test sites) or root planing (control sites). A multilevel model was used to analyze data at 3 months, 1, 5 and 14 years.

Results: One patient dropped-out after 1 year. At 14 years recession depth was 0.9 (1.2) mm for test sites and 0.9 (0.9) mm for control sites. The interaction between treatment and keratinized tissue (KT) was significant ($p=0.0035$). Recession depths increased slightly over time ($p=0.0006$) in both groups.

Conclusions: This study shows that during a long-term follow-up, gingival recession recurred in 39% of the treated sites following CAF procedure.

CLINICAL RELEVANCE

Rationale for the study: To verify the long-term outcomes of root planing versus root surface polishing used in combination with coronally advanced flap procedure for the treatment of single gingival recessions

1
2
3
4
5
6
7
8
9
10
11
12
13
14
15
16
17
18
19
20
21
22
23
24
25
26
27
28
29
30
31
32
33
34
35
36
37
38
39
40
41
42
43
44
45
46
47
48
49
50
51
52
53
54
55
56
57
58
59
60

Principal findings: Gingival recession depths tend to increase following coronally advanced flap during a 14 year follow-up period. Interaction was found between treatment and baseline Keratinized Tissue (KT).

Practical implications: The amount of baseline KT could influence the choice of treatment. An apical shift of the gingival margin occurs in the long term follow-up period.

For Peer Review

INTRODUCTION

Coronally advanced flap (CAF) is one of the most reliable techniques for the treatment of single gingival recessions and different surgical flap designs have been proposed over time increasing the possibility of achieving complete root coverage (Cairo et al. 2008; Chambrone et al. 2010).

A prerequisite for root coverage is the treatment/modification of the exposed root surface using different mechanical and/or chemical approaches. Root planing is still being used to remove the microbial biofilm minimizing cementum toxicity (Bertrand & Dunlap 1988), to smoothe irregularities and grooves on exposed root surface (Wennstrom 1996) and to remove root caries lesions (Fourel et al. 1982; Miller et al. 1983). Vigorous planing has also been suggested to reduce the convexity of the root and the mesio-distal distance between periodontal spaces (Holbrook & Ochsenbein 1983) thus improving the possibility of obtaining a greater reduction of the recession. However, Saletta et al. (2005) have demonstrated that while strong root planning (40 strokes) does not modify root curvature it does minimally reduce (3%) the mesio-distal dimensions of the root surface and slightly flattens (6%) the root surface. It should be also considered that most of Miller Class I and II gingival recessions are associated with tooth brushing trauma in patients with high levels of oral hygiene, clinically healthy gingiva and clean root surfaces. The role of mechanical instrumentation of the exposed root seems questionable in these patients, (Wennström 1996) and a more conservative approach could be considered. A previous randomized controlled clinical study (RCT) (Pini Prato et al. 1999) compared two mechanical treatments of shallow (<3 mm) gingival recessions associated with CAF: root-planing with curettes versus polishing with rubber cup and prophylaxis paste. At the 3 months re-evaluation the difference in terms of recession reduction between the test and control sites was not statistically different and residual dental hypersensitivity was present in two sites treated with root planing. More recently, a RCT (Zucchelli et al. 2009) was conducted to compare the efficacy of hand and

1
2
3
4
5
6
7
8
9
10
11
12
13
14
15
16
17
18
19
20
21
22
23
24
25
26
27
28
29
30
31
32
33
34
35
36
37
38
39
40
41
42
43
44
45
46
47
48
49
50
51
52
53
54
55
56
57
58
59
60

ultrasonic instrumentation of the root associated with the CAF approach. The results showed that both treatments were equally effective in terms of root coverage and clinical attachment level (CAL) gain 6 months after surgery.

In the past, chemical conditioning of the exposed cementum (citric acid, tetracycline HCL, etc.) was suggested to improve the clinical and histological outcomes of the treatment of gingival recessions. Chemical agents were used to remove the smear layer produced by root instrumentation (Liu & Solt 1980), to expose the collagen fibrils of the dental matrix facilitating the formation of a new connective attachment (Selvig et al. 1981; Polson & Proye 1982) and to eliminate cytopathic material on the exposed root that could inhibit fibroblast growth (Olson et al. 1985). However, systematic reviews (Roccuzzo et al. 2002; Oates et al. 2003) have shown that sites treated with root planing alone or with combined chemical/mechanical treatment do not show significant differences in terms of root coverage.

Although a large number of clinical trials have been published on the treatment of localized gingival recessions, few data are available on the long-term results of these procedures. Leknes et al. (2005) in a long-term RCT reports that CAF is a reliable technique for the treatment of recessions in terms of root coverage, probing depth and CAL gain. In particular, the results are stable at short follow-up (6-12 months) but long-term (6 years) stability seems to be critically dependent on the recall visits and re-instruction in the use of non-traumatic brushing practices.

Using the same population of a previous study (Pini Prato et al. 1999), this long-term 14-year-randomized split-mouth study aimed at evaluating (1) the outcomes of two different methods of root surface modifications (root-planing vs. root surface polishing) used in combination with CAF and (2) the long-term results of CAF performed for the treatment of single gingival recessions.

METHODS

Study Population

The study population comprised the group published in a previous short-term split-mouth randomized clinical trial conducted to investigate the potential benefit of root instrumentation or root polishing in the treatment of single gingival recessions with the Coronally Advanced Flap (CAF) procedure 3 months after surgery (Pini Prato et al. 1999). Ten patients were selected among individuals referred to the Department of Periodontology of University of Siena Dental School. An *a priori* sample size calculation was not performed.

Information on this study is summarized below.

The entry criteria used were: 1) non-compromised systemic health and no contraindications for periodontal surgery; 2) presence of maxillary bilateral buccal recessions ≥ 2 mm classified as Miller's Class I or II; 3) difference in depth of the gingival recession between right and left site ≤ 1 mm and difference in clinical attachment level ≤ 2 mm; 4) identifiable cement-enamel junction (CEJ); 5) tooth vitality and absence of grooves, irregularities, caries, or restorations in the area to be treated; 6) no periodontal surgical treatment during the previous 24 months on the involved sites; 7) full-mouth plaque score (FMPS) $< 20\%$ and full mouth bleeding score (FMBS) $< 20\%$; and 8) absence of plaque and bleeding on probing at the selected sites.

The ten patients enrolled in this study received oral hygiene instructions to eliminate habits related to the etiology of the recessions.

Clinical measurements

The following measurements were taken by one investigator (GPP) using a PCP UNC 15 periodontal probe at baseline:

Recession depth (REC) on the mid-buccal site

Probing Depth (PD) on the mid-buccal site

Clinical Attachment Level (CAL) calculated as PD + Rec

1
2
3
4
5
6
7
8
9
10
11
12
13
14
15
16
17
18
19
20
21
22
23
24
25
26
27
28
29
30
31
32
33
34
35
36
37
38
39
40
41
42
43
44
45
46
47
48
49
50
51
52
53
54
55
56
57
58
59
60

Keratinized Tissue (KT) width: distance between gingival margin (GM) and mucogingival junction (MGJ)

Anatomical crown length (IM-CEJ): distance between incisal margin (IM) and cement-enamel junction (CEJ)

Dentin hypersensitivity (DH): present or absent.

Randomization

A split-mouth design was used. The sites were randomly assigned to 2 treatment groups (test and control) by tossing a coin (PC) immediately prior to surgery. In the test group, exposed root surfaces were treated by polishing before flap elevation, using a rubber cup and a prophylaxis paste for 60 seconds under local anesthesia. Polishing was also performed in the intrasulcular area. Immediately after polishing, the root surface was washed with water spray for 60 seconds. In the control group exposed root surfaces were treated by means of root planing, using curettes under local anesthesia. Root planing was also performed in the intrasulcular area. Immediately after instrumentation the treated root surfaces were washed for 60 seconds with water spray.

Surgical procedures

Both groups underwent CAF procedure performed by the same operator (GPP). In 9 patients homologous contralateral teeth were treated while a canine and a contralateral lateral incisor were treated in patient number 4. A trapezoidal flap was designed using one intrasulcular and two oblique releasing incisions. The full-split thickness pedicle flap was then elevated. Care was taken to reduce flap tension and facilitate the passive coronal displacement of the gingival margin. The

1
2
3 papillae adjacent to the gingival recession were carefully de-epithelialized and the flap was then
4
5 coronally displaced and sutured.
6
7
8
9

10 **Post-surgical protocol**

11
12 Patients were instructed to avoid any mechanical trauma and tooth brushing for 3 weeks in the
13
14 surgical area. Chlorhexidine rinses were prescribed twice daily for 1 minute. Sutures were removed
15
16 seven days after surgery and prophylaxis was performed. About 3 weeks after surgery, all patients
17
18 were instructed to resume mechanical tooth cleaning. The patients were recalled 3 months after
19
20 surgery and periodontal measurements were repeated.
21
22
23
24
25
26
27
28
29

30 **Follow up 3 months-14 years**

31
32 The 10 patients of the previous article were enrolled in the present study and followed for a long
33
34 period of time.
35
36

37
38 During the 14 year observation period, patients were recalled for 1, 5 and 14 year follow up visits
39
40 and they complied with the program of supporting periodontal care. They were also re-called
41
42 every 6 months for professional re-instruction and prophylaxis.
43
44

45
46 The same baseline and 3-month periodontal measurements (Rec, PD, CAL, IM-GM, IM-MGJ, and
47
48 GM-MGJ) were repeated by the same investigator (GPP) who was not blinded to the treatment
49
50 and who always used the same periodontal probes.
51
52
53
54

55 **Statistical analysis**

56
57 Quantitative data were summarized as means (standard deviation) and qualitative data were
58
59 summarized as frequency (percentage).
60

1
2
3 Differences in recession depth between the two treatment groups were analyzed using a
4
5 multilevel model at three levels: Patient, Site and Occasion. Occasion refers to the measurements
6
7 performed at 3 months, 1, 5 and 14 years. Explicative variables were: treatment (Polishing vs. Root
8
9 Planing), baseline recession depth, baseline Keratinized Tissue width, Time (3 months, 1 year, 5
10
11 years and 14 years). Interactions Treatment x Time, Treatment x Recession depth and Treatment x
12
13 KT were tested. Non-significant interactions were excluded from the model. Time was used as a
14
15 continuous variable. The software was MLwiN version 2.02 © Multilevel Models Project Institute
16
17 of Education, University of Bristol. The algorithm used to fit the model was the IGLS (Iterative
18
19 Generalised Least Square).
20
21
22
23
24

25
26 Differences in hypersensitivity (DH) and CRC at 14 years between the treatment groups were
27
28 analyzed using the McNemar test.
29
30
31
32

33 RESULTS

34
35
36 Out of 10 patients, one patient dropped out 1 year later because she moved to another country. In
37
38 the test group (Polishing) recession depth was 0.6 (0.7) mm at 1 year (in 1997), 0.9 (1.1) mm at 5
39
40 years (in 2001) and 0.9 (1.2) mm at 14 years (in 2010). In the control group (Root planing)
41
42 recession depth was 0.5 (0.6) mm at 1 year, 0.7 (0.8) mm at 5 years and 0.9 (0.9) mm at 14 years.
43
44
45

46
47 CRC was quite stable over time in both sides. Eight sites, 5 in the test and 3 in the control group
48
49 showed complete root coverage at 14 years. On the other hand, one site (root planing) showing
50
51 CRC at 3 months developed a new recession at 14 years while one site (Polishing) and one site
52
53 (Root Planing) that showed a recession at 3 months developed a CRC at 14 years.
54
55

56
57 The amount of KT decreased slightly over time in both sides.

58
59 Dental hypersensitivity disappeared in both sides one year after treatment, while it recurred in 3
60
sites of each group at the 14 year follow up. (Table 1).

1
2
3 No side effects occurred during the follow-up period.
4

5
6 Inferential statistics
7

8
9 The multilevel model for recession depth is shown in Table 2. The interaction between treatment
10 and KT is significant ($p=0.0035$). In fact, in cases of 3 mm of baseline KT, the 2 treated groups
11 showed no difference in terms of recession depth during the follow-up observations.
12 Nevertheless, comparing the two treatments, the greater the baseline amount of KT, the lower
13 the final recession depth in the test group (polishing), while in the control sites (root planing) the
14 lower the baseline amount of KT, the lower the final recession depth (Fig. 1).
15
16
17
18
19
20
21
22
23

24 Taking into consideration 3 mm of baseline KT as the point of indifference between the two
25 treatments, figures 2 and 3 show the trend of gingival recession depth variation within the 2
26 groups over time, for sites with $KT < 3$ mm and sites with $KT \geq 3$ mm.
27
28
29
30

31 Recession depth increased slightly over time ($p=0.0006$) in both the test and control sites. Seven
32 sites (4 in the Polishing group and 3 in the Root Planing group) showed an increased recession
33 depth from 3 months to 14 years.
34
35
36
37

38 At 14 years there was no difference in dental hypersensitivity or CRC between the two groups ($p=1$
39 and $p=0.8308$, respectively).
40
41
42

43 One treated case is reported in figures 4-8.
44
45
46
47
48

49 **DISCUSSION**
50

51
52 Using the same patients of the previous study (Pini Prato et al. 1999), the present 14-year long-
53 term randomized clinical study aimed at evaluating: 1) the outcomes of two different methods of
54 root surface treatments (root planing vs. root surface polishing) used in combination with CAF;
55 and 2) the long term results of CAF performed for the treatment of single gingival recessions.
56
57
58
59
60

1. Outcomes of root surface treatment: root planing versus root surface polishing

1
2
3 Only a few studies discuss different approaches for treating exposed root surfaces associated with
4 gingival recession for root coverage procedures. Oles et al. (1988) compared the efficacy of
5 scaling/polishing, root planing, and sodium hypochlorite root conditioning associated with a
6 laterally positioned flap. Three months later, the results of that study did not show any statistical
7 difference in the clinical outcomes among the 3 treated groups.
8
9

10
11 More recently, another randomized controlled split-mouth clinical study (Zucchelli et al. 2009)
12 was conducted to compare the efficacy of hand and ultrasonic instrumentation in combination
13 with CAF in 11 patients with bilateral Miller class I and II single recessions. The control root
14 surfaces were planed with curescopes while the test group roots were instrumented with ultrasonic
15 piezoelectric devices. Hand and ultrasonic root instrumentation proved equally effective in terms
16 of root coverage and CAL gain at 6 months post-surgery.
17
18

19
20 In the present study, a multilevel statistical model was set up considering baseline recession
21 depth, baseline keratinized tissue width, treatment, and occasions as explicative variables;
22 recession depth was the outcome variable. Interaction effects were considered in the model.
23 Interaction is defined as “a process in which the combined effects of two or more variables are
24 greater than the sum of their individual effects” (Lang & Secic 2006). In this study, treatment “per
25 se” (polishing versus root planing) did not show differences in terms of final recession depth; on
26 the other hand the treatment combined with the baseline amount of KT showed a significant
27 effect. In fact, the two approaches showed different trends: polishing (test group) resulted in a
28 greater recession reduction in the presence of a greater KT width, while root planing (control
29 group) showed a greater recession reduction in sites with a smaller amount of KT. However, these
30 observed clinical outcomes following the 2 root surface therapies appear difficult to explain and
31 therefore further studies are needed.
32
33
34
35
36
37
38
39
40
41
42
43
44
45
46
47
48
49
50
51
52
53
54
55
56
57
58
59
60

1
2
3 A post-hoc power calculation was reported in the previous short term study publication (Pini-Prato
4 et al. 1999). The power to detect a difference in change of 0.5 mm at a significant level of $\alpha=0.05$
5
6 was 67%. In this long term study a significant difference in interaction terms was found, Therefore,
7
8 the study has sufficient power to detect this difference. Anyway it is possible that the interaction
9
10 result is due to chance and in this case a statistical type I error is made.
11
12
13
14

15 16 *2. Long-term results of CAF procedure.*

17
18

19 The present study was also useful in evaluating the long-term outcomes of the coronally advanced
20 flap technique for the treatment of gingival recession defects. Few data are available in the
21 periodontal literature. Leknes et al. (2005) reported a severe recurrence of gingival recession in a
22 6-year long-term study in sites treated either with CAF alone or with CAF and a bio-resorbable
23 barrier. At 6 years, out of 11 bilateral single recessions only 2 sites treated with barriers and 1 site
24 treated with CAF were still completely covered.
25
26
27
28
29
30
31
32

33 A 3-year case series study (De Sanctis & Zucchelli 2007) reported an increased amount of
34 keratinized tissue associated with 97% average root coverage following a modified CAF procedure
35 performed on single-recession defects .
36
37
38
39

40 In a 5 year long term evaluation of a case series treated with the envelope type of CAF approach
41 on multiple recessions, Zucchelli & De Sanctis (2005) reported a slight shift of the gingival margin
42 as compared to 1-year data. In fact, complete root coverage was observed in 88% of the cases at 1
43 year, while it decreased to 85% at 5 years.
44
45
46
47
48
49

50 Another 5 year long-term comparative study (Pini Prato et al. 2010) on multiple recessions
51 treated with CAF alone or with CAF + Connective tissue graft (CTG) showed a similar trend toward
52 a consistent shift of the gingival margin in the CAF treated sites, while the CAF+CTG treated sites
53 showed a tendency to a coronal shift of the gingival margin.
54
55
56
57
58
59
60

1
2
3 The present long-term study performed on single gingival recessions revealed an apical shift of the
4
5 gingival margin in about 39% of the treated sites showing a progressive worsening of the gingival
6
7 recessions during the 14-year follow-up period. The estimated apical shift was 0.024 mm per year,
8
9 on average. This result was statistically significant even if it might not appear relevant from a
10
11 clinical standpoint. However, a small increase in gingival recession may cause the recurrence of
12
13 dental hypersensitivity. The observed relapse of the soft tissue defects could be due to a
14
15 resumption of traumatic tooth brushing habits in patients with high levels of oral hygiene even if
16
17 they were included in a stringent maintenance protocol with recalls every 4 to 6 months. At each
18
19 recall visit, the oral hygiene procedures were checked and the patients were re-motivated and re-
20
21 instructed, if needed. As a consequence of the apical shift of the gingival margin, the dental
22
23 hypersensitivity that had disappeared in all the treated sites after 1 year, reappeared after 14
24
25 years in 6 sites (3 patients) that did not show complete root coverage.
26
27

28
29 Regarding the KT width, the results of this study showed that it tends to decrease over time. These
30
31 outcomes differ from those reported in other studies where an increased amount of KT occurred
32
33 after 1 and 5 years (Zucchelli et al. 2005, 2009).
34
35

36
37 This randomized trial does have some methodological limitations, such as the lack of sample size
38
39 calculation and blindness. However, it should be considered that this study was conducted back in
40
41 1995-1996; CONSORT statements to improve the quality of randomized controlled trials were not
42
43 available at that time.
44
45

46
47 In conclusion, root planing and polishing treatments of the exposed root surface used in
48
49 combination with CAF showed similar outcomes in terms of recession reduction after 14 years.
50
51 However, considering the baseline amount of KT, polishing seems to be more indicated than root
52
53 planing in cases of KT widths greater than 3 mm, while root planing appears to be more
54
55 appropriate in cases of baseline KT widths of less than 3 mm. In addition, at 14 years, an apical
56
57
58
59
60

1
2
3 shift of the gingival margin (recession relapse) was found in 39% of the sites treated with the
4
5
6 coronally advanced flap procedure.
7
8
9
10
11
12
13
14
15
16
17
18
19
20
21
22
23
24
25
26
27
28
29
30
31
32
33
34
35
36
37
38
39
40
41
42
43
44
45
46
47
48
49
50
51
52
53
54
55
56
57
58
59
60

For Peer Review

REFERENCES

- Bertrand, P.M., Dunlap, R.M. (1988) Coverage of deep, wide gingival clefts with free gingival autografts: root planing with and without citric acid demineralization. *International Journal of Periodontics and Restorative Dentistry* **8**, 64-77.
- Cairo, F., Pagliaro, U., Nieri, M. (2008) Treatment of gingival recession with coronally advanced flap procedures: a systematic review. *Journal of Clinical Periodontology* **35**: 136-162.
- Chambrone, L., Sukekava, F., Araújo, M.G., Pustiglioni, F.E., Chambrone, L.A., Lima, L.A. (2010) Root-coverage procedures for the treatment of localized recession-type defects: a Cochrane systematic review. *Journal of Periodontology* **81**: 452-478.
- DeSanctis, M., Zucchelli, G. (2007) Coronally advanced flap: a modified surgical approach for isolated recession-type defects: three-year results. *Journal of Periodontology*, **34**, 262-268.
- Fourel, J. (1982) Gingival reattachment on carious tooth surfaces. A 4-year follow-up. *Journal of Clinical Periodontology* **9**: 285-289.
- Holbrook, T., Ochsenbein, C. (1983) Complete coverage of the denuded root surface with a One-stage gingival graft. *International Journal of Periodontics and Restorative Dentistry* **3**: 9-27.
- Lang, T.A., Secic, M. (2007) *How to report statistics in medicine*. American College of Physicians. Philadelphia, Second Edition p. 413
- Leknes, K.N., Amarante, E.S., Price, D.E., Boe, O.E., Skavland, R.J., Lie, T. (2005) Coronally positioned flap procedures with or without a biodegradable membrane in the treatment of human gingival recession. A 6-year follow-up study. *Journal of Clinical Periodontology* **32**: 518-529.

- 1
2
3 Liu, W.J.L., Solt C.W. (1980) A surgical procedure for the treatment of localized gingival
4 recession in conjunction with root surface citric acid conditioning. *Journal of Periodontology*
5
6 51, 505-509
7
8
9
10
11 Miller, P.D. (1983) Root coverage using a free soft tissue autograft following citric acid
12 application. Part II. Treatment of the carious root. *International Journal of Periodontics and*
13
14 *Restorative Dentistry* 3: 38-51.
15
16
17
18 Oates, T.W., Robinson, M., Gunsolley, J.C. (2003) Surgical therapies for the treatment of
19 gingival recession. A systematic review. *Ann Periodontol* 8: 303-320
20
21
22
23 Oles, R.D., Ibbott, C.G., Laverty, W.H. (1988) Effect of root curettage and sodium hypochlorite
24 treatment on pedicle flap coverage of localized recession. *Journal of Canadian Dental*
25
26 *Association* 54: 515-517.
27
28
29
30 Olson, R.H., Adams, D.F., Layman, D.L. Inhibitory effect of periodontally diseased root extracts
31 on the growth of human gingival fibroblasts. *Journal of Periodontology* 1985;56:592-596
32
33
34
35 Pini Prato, G.P., Baldi, C., Pagliaro, U., Nieri, M., Saletta, D., Rotundo, R., Cortellini, P. (1999)
36 Coronally advanced flap procedure for root coverage. Treatment of root surface: root planing
37 versus polishing. *Journal of Periodontology* 70: 1064-1076.
38
39
40
41
42 Pini Prato, G.P., Cairo, F., Nieri, M., Franceschi, D., Rotundo, R., Cortellini, P. (2010) Coronally
43 advanced flap versus connective tissue graft in the treatment of multiple gingival recessions: a
44 split-mouth study with a 5-year follow-up. *Journal of Clinical Periodontology* 37: 644-650.
45
46
47
48
49 Polson, A.M. & Proye, M.P. (1982) Effects of root surface alterations on periodontal healing. II.
50 Citric acid treatment of the denuded root. *Journal of Clinical Periodontology* 9:441-454
51
52
53
54 Rocuzzo, M., Bunino, M., Needleman, I. & Sanz, M. (2002) Periodontal plastic surgery for
55 treatment of localized gingival recessions: a systematic review. *Journal of Clinical*
56
57 *Periodontology* 29: 178-194.
58
59
60

1
2
3 Saletta, D., Baldi, C., Nieri, M., Ceppatelli, P., Franceschi, D., Rotundo, R., Cairo, F., Pini Prato,
4
5 G.P. (2005) Root curvature: differences among dental morphotypes and modifications after
6
7 mechanical instrumentation. *Journal of Periodontology*. **76**:723-730.
8
9

10 Selvig, K.A., Ririe, C.M., Nilveus, R., Egelberg, J. (1981) Fine structure of new connective
11
12 tissue attachment following acid treatment of experimental furcation pockets in dogs. *Journal*
13
14 *of Periodontal Research* **16**:123-129
15
16

17 Wennström, J.L. (1996) Mucogingival therapy. World Workshop in Periodontics. *Annals of*
18
19 *Periodontology* **1**: 671-701.
20
21

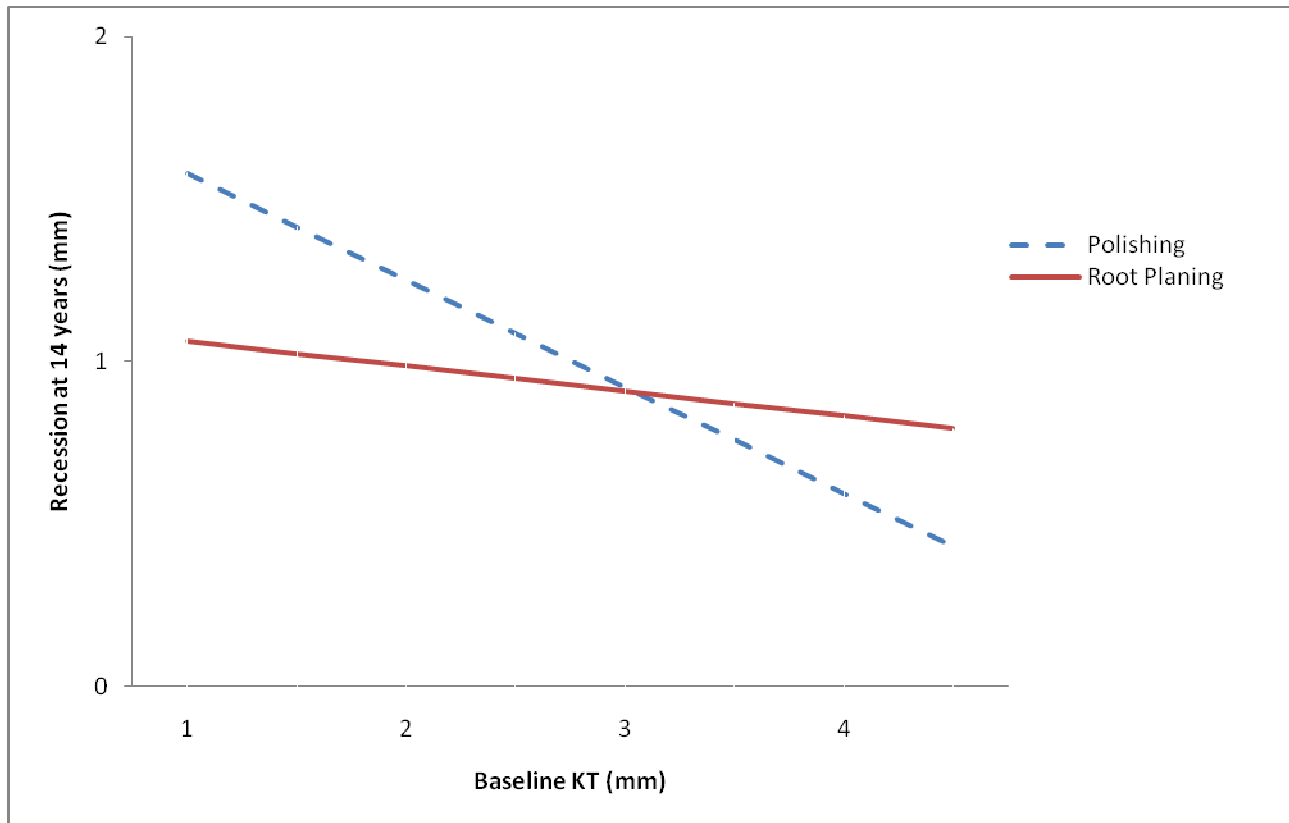
22 Zucchelli, G., De Sanctis, M. (2005) Long-term outcome following treatment of multiple Miller
23
24 class I and II recession defects in esthetic areas of the mouth. *Journal of Periodontology* **76**:
25
26 2286-2292.
27
28

29 Zucchelli, G., Mounssif, I., Stefanini, M., Mele, M., Montebugnoli, L., Sforza, N.M. Hand and
30
31 ultrasonic instrumentation in combination with root-coverage surgery: a comparative
32
33 controlled randomized clinical trial. *J Periodontol* 2009; **80**: 577-585
34
35
36

37 Zucchelli, G., Mele, M., Mazzotti, C., Marzadori, M., Montebugnoli, L., De Sanctis, M. Coronally
38
39 advanced flap with and without vertical releasing incisions for the treatment of multiple
40
41 gingival recessions: a comparative controlled randomized clinical trial. *J Periodontol*.
42
43 2009;80:1083-94
44
45
46
47
48
49
50
51
52
53
54
55
56
57
58
59
60

FIGURES AND TABLES

Figure 1. Interaction between treatment and baseline Keratinized Tissue, considering a baseline recession depth of 3 mm.



1
2
3
4
5
6
7
8
9
10
11
12
13
14
15
16
17
18
19
20
21
22
23
24
25
26
27
28
29
30
31
32
33
34
35
36
37
38
39
40
41
42
43
44
45
46
47
48
49
50
51
52
53
54
55
56
57
58
59
60

Figure 2. Trend of gingival recession depth in sites with KT<3mm during the 14-year follow-up.

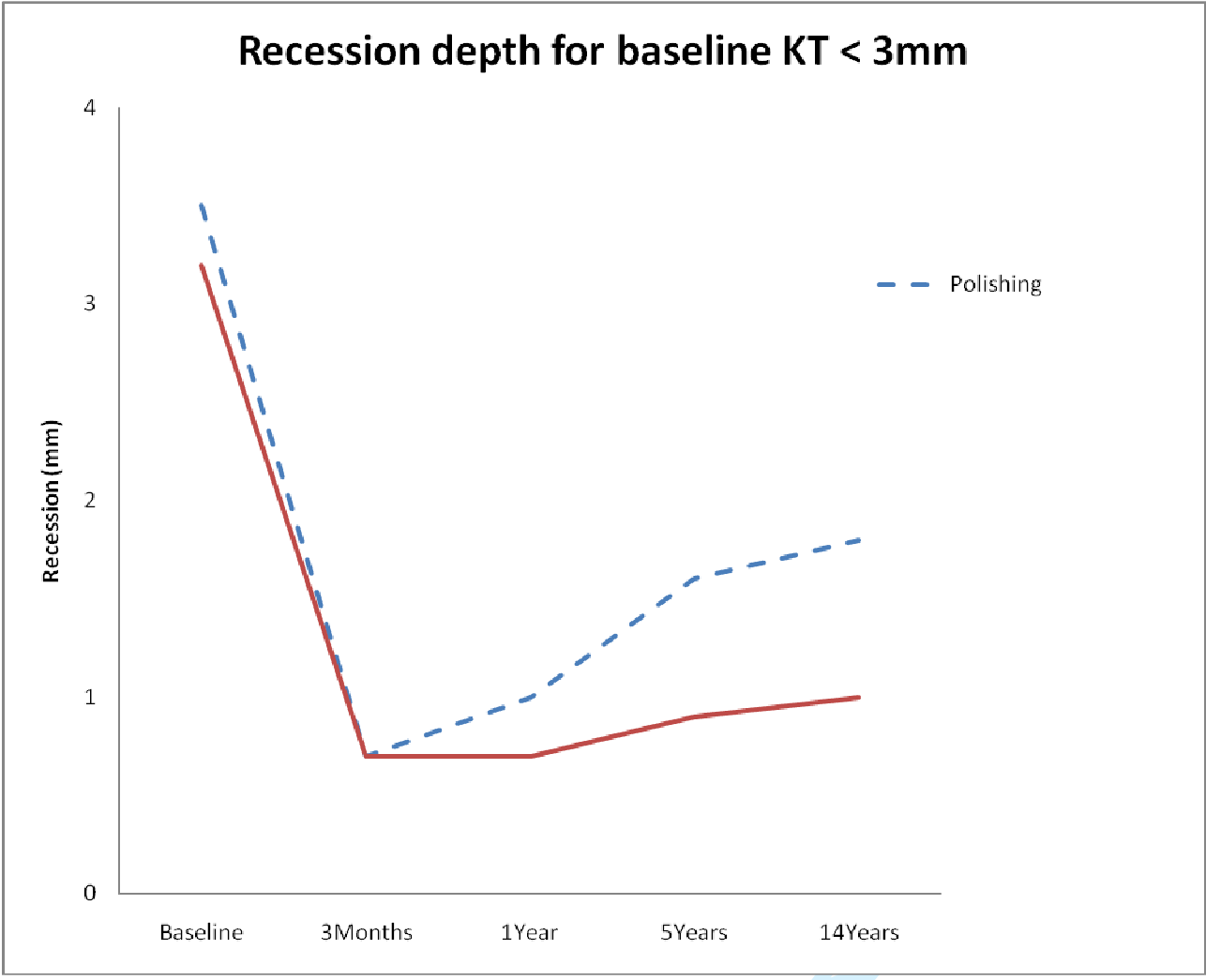
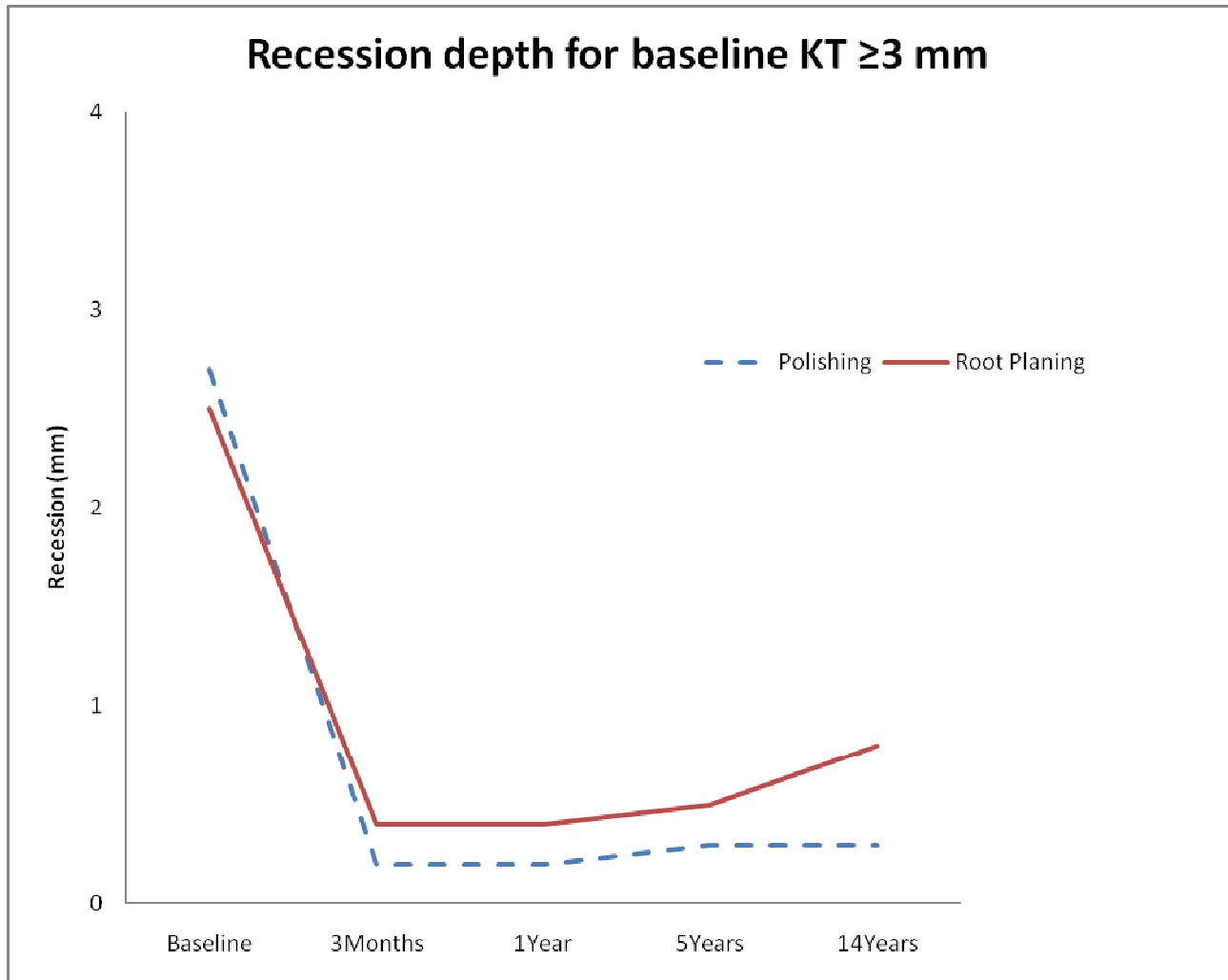


Figure 3. Trend of gingival recession depth in sites with $KT \geq 3$ mm during the 14-year follow-up.



1
2
3
4
5
6
7
8
9
10
11
12
13
14
15
16
17
18
19
20
21
22
23
24
25
26
27
28
29
30
31
32
33
34
35
36
37
38
39
40
41
42
43
44
45
46
47
48
49
50
51
52
53
54
55
56
57
58
59
60

Figure 4. Bilateral recessions on maxillary canines

Figure 5. The exposed roots were randomly treated by rubber cup and prophylaxis paste (left side-test group) and by sharp curette (right side-control group)

Figure 6. Coronally advanced flaps were performed on both test and control sites in the same surgical session.

Figure 7. Results 1 year after surgery. Complete root coverage was obtained in both the test and control sites.

Figure 8. Results 14 years after surgery. Recession of gingival margin occurred in both sites.

Table 1. Descriptive statistics.

	Baseline (10 patients)		3 months (10 patients)		1 year (10 patients)		5 years (9 patients)		14 years (9 patients)	
	Polishing	Root planing	Polishing	Root planing	Polishing	Root planing	Polishing	Root planing	Polishing	Root planing
Rec (mm)	3.1 (1.1)	2.9 (1.0)	0.4 (0.6)	0.5 (0.6)	0.6 (0.7)	0.5 (0.6)	0.9 (1.1)	0.7 (0.8)	0.9 (1.2)	0.9 (0.9)
KT (mm)	3.1 (1.3)	2.7 (1.2)	2.5 (1.3)	2.5 (1.0)	2.4 (1.3)	2.6 (0.8)	2.3 (1.7)	2.4 (1.0)	2.4 (1.8)	2.3 (1.3)
PD (mm)	1.3 (0.5)	1.3 (0.5)	0.7 (0.4)	0.7 (0.4)	0.7 (0.4)	1.0 (0.4)	0.8 (0.5)	1.0 (0.4)	1.0 (0.6)	1.0 (0.5)
CRC	-	-	5 (50%)	4 (40%)	4 (40%)	4 (40%)	5 (56%)	4 (44%)	5 (56%)	3 (33%)
Hypersensitivity	5 (50%)	4 (40%)	0 (0%)	2 (20%)	0 (0%)	0 (0%)	3 (33%)	2 (22%)	3 (33%)	3 (33%)

Test=Polishing; Control=Root Planing. Mean (Standard Deviation) for quantitative variables and Frequency (Percentage) for qualitative variables.

1
2
3
4
5
6
7
8
9
10
11
12
13
14
15
16
17
18
19
20
21
22
23
24
25
26
27
28
29
30
31
32
33
34
35
36
37
38
39
40
41
42
43
44
45
46
47
48
49
50
51
52
53
54
55
56
57
58
59
60**Table 2.** Multilevel model for Recession Depth.

$$Rec_{ijk} = b_{0ijk} + b_1Treatment_{jk} + b_2baseline_recession_{jk} + b_3baseline_KT_{jk} + b_4Treatment \times baseline_KT_{jk} + b_5Time_{ijk} + v_k + u_j + e_i$$

Term	Estimate	Std Error	p-value
Intercept	-0.608	0.443	
Treatment (Test=1) _{jk}	0.766	0.272	0.0049
Baseline Recession _{jk}	0.463	0.093	<0.0001
Baseline KT _{jk}	-0.077	0.093	0.4077
Treatment x Baseline KT _{jk}	-0.251	0.086	0.0035
Time _{ijk}	0.024	0.007	0.0006
$\sigma^2_{Patient}$	0.072	0.044	
σ^2_{Site}	0.016	0.022	
$\sigma^2_{Occasion}$	0.118	0.022	

σ^2 =Variance; i, j, k refer to occasion, site, patient. Treatment is a binary variable with value 1 if test and 0 if control side. Time is a continuous variable in years. Recession and KT are measured in mm.

1
2
3
4
5
6
7
8
9
10
11
12
13
14
15
16
17
18
19
20
21
22
23
24
25
26
27
28
29
30
31
32
33
34
35
36
37
38
39
40
41
42
43
44
45
46
47
48
49
50
51
52
53
54
55
56
57
58
59
60

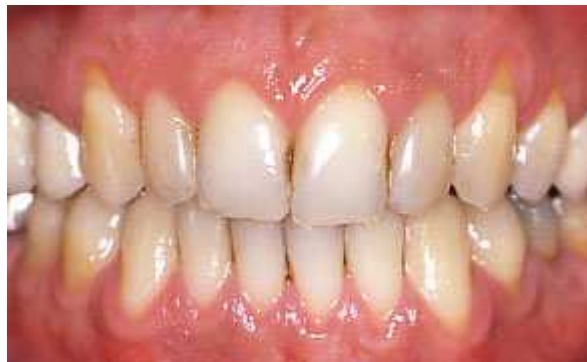

Figure 4. Bilateral recessions on maxillary canines
24x15mm (300 x 300 DPI)

Peer Review

1
2
3
4
5
6
7
8
9
10
11
12
13
14
15
16
17
18
19
20
21
22
23
24
25
26
27
28
29
30
31
32
33
34
35
36
37
38
39
40
41
42
43
44
45
46
47
48
49
50
51
52
53
54
55
56
57
58
59
60

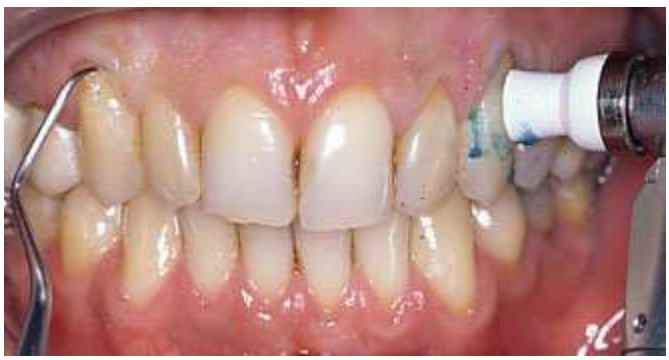

Figure 5. The exposed roots were randomly treated by rubber cup and prophylaxis paste (left side-test group) and by sharp curette (right side-control group)
28x14mm (300 x 300 DPI)

Peer Review

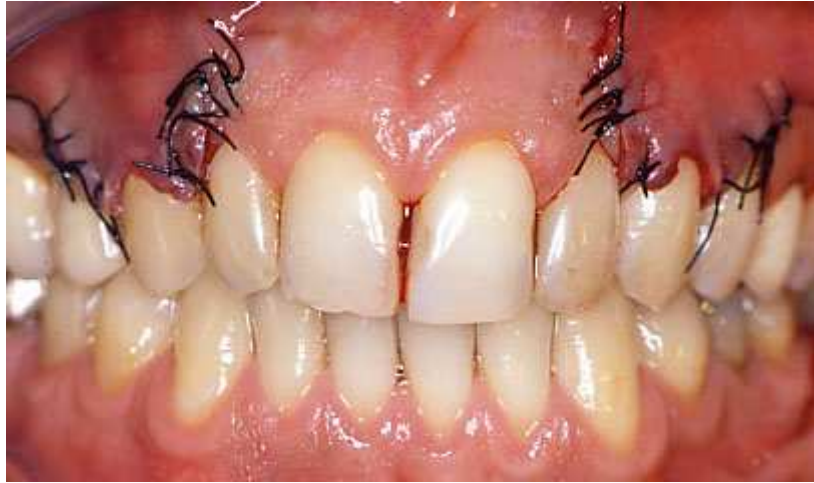

Figure 6. Coronally advanced flaps were performed on both test and control sites in the same surgical session.

34x20mm (300 x 300 DPI)

Peer Review

1
2
3
4
5
6
7
8
9
10
11
12
13
14
15
16
17
18
19
20
21
22
23
24
25
26
27
28
29
30
31
32
33
34
35
36
37
38
39
40
41
42
43
44
45
46
47
48
49
50
51
52
53
54
55
56
57
58
59
60

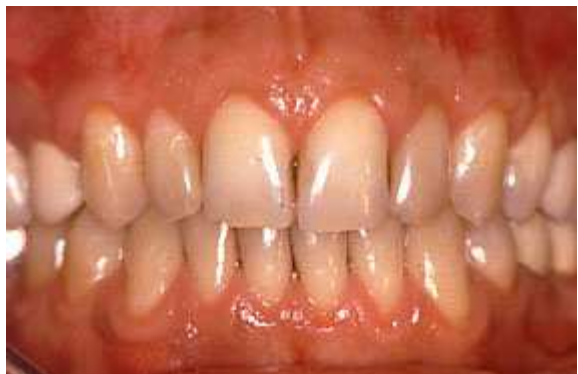

Figure 7. Results 1 year after surgery. Complete root coverage was obtained in both the test and control sites.
24x15mm (300 x 300 DPI)

Peer Review

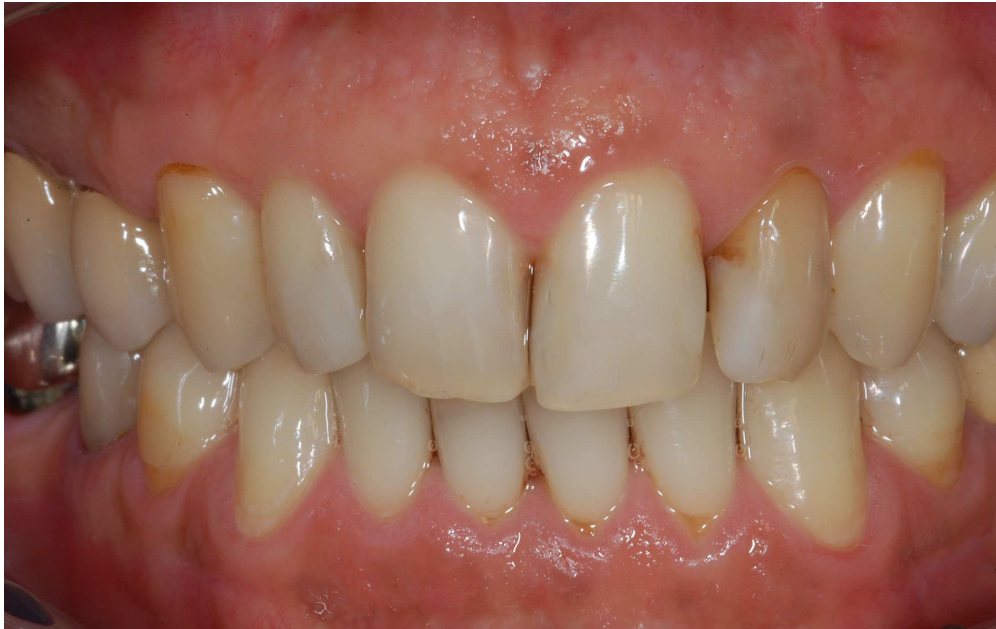

Figure 8. Results 15 years after surgery. Recession of gingival margin occurred in both sites.
186x116mm (300 x 300 DPI)