



**HAL**  
open science

## **Surgical therapy of peri-implantitis lesions by means of bovine-derived xenograft. Comparative results of a prospective study on two different implant surfaces.**

Mario Rocuzzo, Francesca Bonino, Luca Bonino, Paola Dalmaso

### ► **To cite this version:**

Mario Rocuzzo, Francesca Bonino, Luca Bonino, Paola Dalmaso. Surgical therapy of peri-implantitis lesions by means of bovine-derived xenograft. Comparative results of a prospective study on two different implant surfaces.. *Journal of Clinical Periodontology*, 2011, 38 (8), pp.738. 10.1111/j.1600-051X.2011.01742.x . hal-00647405

**HAL Id: hal-00647405**

**<https://hal.science/hal-00647405>**

Submitted on 2 Dec 2011

**HAL** is a multi-disciplinary open access archive for the deposit and dissemination of scientific research documents, whether they are published or not. The documents may come from teaching and research institutions in France or abroad, or from public or private research centers.

L'archive ouverte pluridisciplinaire **HAL**, est destinée au dépôt et à la diffusion de documents scientifiques de niveau recherche, publiés ou non, émanant des établissements d'enseignement et de recherche français ou étrangers, des laboratoires publics ou privés.



**Surgical therapy of peri-implantitis lesions by means of bovine-derived xenograft. Comparative results of a prospective study on two different implant surfaces.**

Journal:	<i>Journal of Clinical Periodontology</i>
Manuscript ID:	CPE-12-10-3012.R2
Manuscript Type:	Original Article Implant Dentistry
Date Submitted by the Author:	02-Apr-2011
Complete List of Authors:	Rocuzzo, Mario; Private Practice Bonino, Francesca; Private Practice Bonino, Luca; Private Practice Dalmaso, Paola; University of Torino, Public Health and Microbiology
Topic:	Implantology
Keywords:	per-implantitis, surgical treatment, defect fill, bone substitute, surface decontamination
Main Methodology:	Clinical Trial

SCHOLARONE™  
Manuscripts

1  
2  
3 **Surgical therapy of peri-implantitis lesions by means of bovine-derived xenograft.**  
4  
5 **Comparative results of a prospective study on two different implant surfaces.**  
6  
7  
8  
9

10  
11 **Authors:**

12  
13  
14 Mario Rocuzzo: Private practice, Torino; University of Torino, Department of Maxillo-facial  
15  
16 Surgery.  
17

18  
19 Francesca Bonino: Private practice, Torino.

20  
21 Luca Bonino: Private practice, Torino.

22  
23 Paola Dalmaso; University of Torino, Department of Public Health and Microbiology.  
24  
25  
26  
27

28 **Running header of the manuscript:** Surgical treatment of peri-implantitis  
29  
30  
31

32  
33 **Corresponding author:**

34  
35 Mario Rocuzzo, D.D.S.

36  
37 Corso Tassoni, 14  
38

39  
40 10143 Torino

41  
42 Italy

43  
44 mroccuzzo@iol.it  
45  
46  
47  
48  
49  
50  
51

52 **Key words:**

53  
54 Bone substitute; Biomaterial; Peri-implantitis; Defect fill; Surgical treatment.  
55  
56  
57  
58  
59  
60

## Abstract

**Objectives:** The aim of this prospective study was to evaluate a regenerative surgical treatment modality for peri-implantitis lesions on two different implant surfaces.

**Material and Methods:** Twenty-six patients with one crater-like defect, around either TPS (Control) or SLA (Test) dental implants, with a probing depth  $\geq 6$ mm and no implant mobility, were included. Implant surface was mechanically debrided and treated using 24 % EDTA gel and 1% Chlorhexidine gel. The bone defect was filled with bovine-derived xenograft (BDX) and the flap was sutured around the non-submerged implant.

**Results:** One-year follow-up demonstrated clinical and radiographic improvements. Probing depth were significantly reduced by  $2.1 \pm 1.2$  mm in Control and by  $3.4 \pm 1.7$  mm in Test. Complete defect fill was never found around Controls, while occurred in 3 out of 12 Test implants. Bleeding on probing decreased from  $91.1 \pm 12.4\%$  (Control) and  $75.0 \pm 30.2\%$  (Test) to  $57.1 \pm 38.5\%$  ( $p=0.004$ ) and  $14.6 \pm 16.7\%$  ( $p=0.003$ ) respectively. Several deep pockets ( $\geq 6$ mm) were still present after surgical therapy around Controls.

**Conclusions:** Surface characteristics may have an impact on the clinical outcome following surgical debridement, disinfection of the contaminated surfaces and grafting with BDX. Complete fill of the bony defect seems not to be a predictable result

## Conflict of interest and source of funding statement

The authors declare that they have no conflict of interests in this study. The study was self-funded; no external funding was available for this research.

Mario Rocuzzo received grants and travel funds from Institut Straumann AG and Geistlich Pharma AG

## Clinical Relevance

**Scientific rationale for the study:** In animal studies the treatment of peri-implantitis is influenced by the surface characteristics of the implants. Limited information on the regenerative possibilities in peri-implantitis lesions around implants of different surfaces is available on humans. The objective of this clinical trial is to test the efficiency of a surgical protocol in defects around TPS and SLA implants.

**Principal findings:** Surgical regenerative treatment by means of BDX resulted in clinical and radiographic significant improvements after 1 year, particularly around SLA implants. Complete fill of the bony defect seems not to be a predictable outcome.

### **Practical implications:**

Surface characteristics might be considered as a clinical parameter potentially influencing the outcome following surgical regenerative therapy of peri-implantitis lesions after decontamination of implants and grafting with BDX. These preliminary results provide an ethical base to perform randomized controlled clinical studies to investigate various methods for the decontamination of implant surfaces and grafting materials. In the meantime, the clinical decision on whether implants should be removed or treated by means of decontamination and regenerative procedure may be based on several factors, including surface characteristics.

## INTRODUCTION

During the last years, biological complications around dental implants have become a frequent finding in patients (Berglundh et al. 2002, Roos-Jansåker et al. 2006, Lindhe & Meyle 2008, Fransson et al. 2009, Koldslund et al. 2010, Rocuzzo et al. 2010, Lang & Berglundh 2011). According to Zitzmann & Berglundh (2008) peri-implantitis is characterized by inflammatory lesions in peri-implant tissues and an associated loss of supporting bone.

Various protocols have been suggested in the treatment of peri-implantitis. Non-surgical procedures alone, however, appear to be insufficient to resolve peri-implantitis lesions (Renvert et al. 2008), while surgical procedures may promote access for removal of bacteria on the implant surface. Nevertheless, Claffey et al. (2008), reported that data obtained from case series and animal experiments indicate that no single cleaning method including chemical agents used during surgical treatment of peri-implantitis was proven to be superior.

The outcome of surgical treatment of peri-implantitis at implants with different types of surfaces has been evaluated in animal experiments. Persson et al. (2001) reported that resolution occurred following surgical treatment at implants with both smooth and SLA surfaces. Parlar et al. (2009), showed that treatment of peri-implantitis with decontamination method resulted in considerable more bone fill around an SLA implant than TPS. More recently, Albouy et al. (2011) demonstrated that resolution of peri-implantitis following surgical treatment is possible but the outcome of treatment is influenced by implant surface characteristics.

Surgical treatment of peri-implantitis lesions has been evaluated in several clinical studies (Behneke et al. 2000, Khoury & Buchmann 2001, Leonhardt et al. 2003, Romeo et al. 2005, 2007, Schwarz et al. 2006, 2009, 2010, Roos-Jansåker et al. 2007a, 2007b, Wiltfang et al.

1  
2  
3 2010). Two systematic reviews based on RCTs (Kotsovilis et al. 2008, Esposito et al. 2010)  
4  
5 failed, however, to determine which is the most effective way to treat peri-implantitis.  
6  
7

8 Apart from surface decontamination, it seems useful, in crater-formed defects, to correct the  
9  
10 anatomical conditions for improving plaque control and for eliminating the favourable  
11  
12 environment for anaerobic bacteria by means of bone regenerative procedures (Schwarz et  
13  
14 al. 2010). The most recent literature research on the matter, to the best of our knowledge,  
15  
16 (Sahrman et al. 2011) aimed to assess available literature for regenerative treatment using  
17  
18 bone-graft substitutes and membranes. A large heterogeneity concerning disinfection  
19  
20 protocols and regenerative materials used and the high percentage of low-quality studies  
21  
22 rendered a meta-analysis impossible. Well-controlled trials are needed to determine  
23  
24 predictable protocols for the successful treatment of peri-implantitis using GBR technique.  
25  
26

27  
28 The aim of this prospective study was to evaluate and compare the healing, following  
29  
30 regenerative surgery, after decontamination of implants, by means of bovine-derived  
31  
32 xenograft, in defects around implants of 2 different surfaces.  
33  
34  
35  
36  
37

## 38 **MATERIALS AND METHODS**

### 39 **Patient Population**

40  
41 From January 2008 to June 2009, twenty-six patients (10 males and 16 females; mean age:  
42  
43  $60 \pm 7.9$  years; 4 smokers), who presented a peri-implantitis crater-like lesion with a probing  
44  
45 depth (PD) of  $\geq 6$ mm and no implant mobility, were consecutively enrolled from those  
46  
47 attending the principle investigator's private practice. The specialist practice receives referrals  
48  
49 from general dental practitioners, specialists in orthodontics, specialists in maxillo-facial  
50  
51 surgery and physicians, mainly located in the North-west of Italy.  
52  
53  
54  
55

56  
57 Patients had been treated, in the previous years, for periodontitis and subsequently had  
58  
59  
60

1  
2  
3 received therapy by means of dental implants of 2 different surfaces, i.e.: Titanium Plasma-  
4 sprayed Surface (TPS) and Sand blasted Large grit and Acid etched surface (SLA)  
5  
6  
7 (Straumann Dental Implant System, Straumann AG, Basel, Switzerland). All implants  
8 supported cemented fixed dental prostheses only. Patients had been recalled at various  
9 intervals, depending on the initial diagnosis and the results of the therapy, for supporting  
10 periodontal therapy (SPT). Motivation, reinstruction, instrumentation and treatment of re-  
11 infected sites were performed as needed. Patients had been placed on an individually  
12 tailored maintenance care program, including continuous evaluation of the occurrence and  
13 the risk of disease progression.  
14

15  
16  
17 All patients had complied with the recall program until evaluation of the peri-implantitis. Hollow  
18 cylinder and hollow screws implants were not included in the study. Only one implant defect  
19 per patient was included in the study (Table 1). The baseline demographic and clinical  
20 characteristics of the patients, divided in 2 groups according to the implant surface, are  
21 represented in Table 2. Each patient was given a detailed description of the procedure. They  
22 were also informed that their data would be used for statistical analysis and gave their  
23 informed consent to the treatment. No ethical committee approval was sought to start up this  
24 observational study, as it was not required by national law or by ordinance of local inspective  
25 authority. The prospective study was performed in accordance with the principles stated in the  
26 Declaration of Helsinki and the Good Clinical Practice Guidelines.  
27  
28  
29  
30  
31  
32  
33  
34  
35  
36  
37  
38  
39  
40  
41  
42  
43  
44  
45  
46  
47  
48  
49

### 50 **Surgical procedures.**

51  
52 Each patient underwent scaling and root planing and professional implant cleaning after  
53 receiving personalized oral hygiene instructions. No surgery was performed before the re-  
54 assurance of good motivation and compliance from each single patient, Full-mouth plaque  
55  
56  
57  
58  
59  
60



1  
2  
3 score (FMPS) < 20% and Full-mouth bleeding score (FMBS) < 20%.

4  
5 All surgeries were performed by one surgeon (MR) with 20 year of experience in periodontal  
6  
7 surgery. The area selected for surgery was anesthetized with mepivacaine plus epinephrine  
8  
9 1:100,000. Full-thickness, mucoperiosteal flaps were raised by means of intracrevicular  
10  
11 incisions. Subsequently, all granulation tissue was completely removed from the defect area  
12  
13 and the implant surfaces were thoroughly debrided using plastic curettes (Straumann AG,  
14  
15 Basel, Switzerland). Following cleaning, the exposed implant was covered with EDTA 24%  
16  
17 (Prefgel Straumann AG, Basel, Switzerland) for 2 minutes and Chlorhexidine 1% gel  
18  
19 (Corsodyl dental gel, GlaxoSmithKline, Baranzate, Italy) for 2 minutes. Then the implant and  
20  
21 bony surfaces were thoroughly rinsed with sterile physiologic saline. Bovine-derived xenograft  
22  
23 (BDX) (BioOss® Collagen, Geistlich, Wolhusen, Switzerland) was applied in a way as to  
24  
25 homogeneously fill the intrabony defect component. Before its application, the graft material  
26  
27 was moistened in sterile saline. If the area was with no keratinized tissue, following grafting, a  
28  
29 connective tissue graft was trimmed and adapted over the entire defect so as to cover 2–3  
30  
31 mm of the surrounding alveolar bone and to ensure stability of the graft material. Finally, the  
32  
33 flap was repositioned coronally and fixed with sutures to ensure a non-submerged healing  
34  
35 procedure.  
36  
37  
38  
39  
40  
41  
42  
43  
44

#### 45 **Postsurgical Care**

46  
47 Patients were instructed to take 1 g of Amoxicillin and Clavulanic acid twice a day for 6 days,  
48  
49 starting at least 1 hour prior to surgery, and non-steroidal analgesics, as needed. Immediately  
50  
51 after surgery, the patients applied ice packs at the treated area, and it was recommended that  
52  
53 these be kept in place for at least 4 hours. Patients were advised to discontinue tooth  
54  
55 brushing and to avoid trauma at the site of surgery for 3 weeks. They were also instructed to  
56  
57  
58  
59  
60

1  
2  
3 use 0.2% chlorhexidine digluconate rinse for 1 minute 3 times a day for the same period of  
4  
5 time. Patients were seen after 7 days and then weekly for the first month to monitor healing.  
6  
7  
8 The sutures were removed after 14 days. After the healing phase, patients were placed on an  
9  
10 individually tailored maintenance care program. Motivation, reinstruction, supragingival  
11  
12 instrumentation and antiseptic therapy were performed as needed.  
13  
14  
15  
16

### 17 **Clinical Assessments**

18  
19 The outcome variables for this study were probing depth reduction (PD), bleeding on probing  
20  
21 (BOP) reduction, and bone defect (BD) fill.  
22  
23

24 Immediately before surgery and 12 months postoperatively, a calibrated examiner (FB),  
25  
26 blinded to the initial classification of the patients, collected the following parameters by means  
27  
28 of a periodontal probe (XP23/UNC 15, Hu-Friedy, Chicago, IL): Probing depth (PD) according  
29  
30 to Fiorellini and Weber (1994) at the mesial, distal, buccal, and palatal/lingual aspects of each  
31  
32 implant. At the same time and sites the presence of dental plaque (PI), of bleeding on probing  
33  
34 (BOP) and of pus were recorded. Figures were rounded off to the nearest millimeter. At the  
35  
36 same time, the distance between the base of the implant shoulder and the most coronal  
37  
38 visible bone-to-implant contact (BL) measured in millimetres, both at the mesial and the distal  
39  
40 aspect of each implant, was collected using standardized periapical intraoral films with a long  
41  
42 cone technique (Roccuzzo et al. 2001; Bornstein et al. 2005). The 12-month BL values were  
43  
44 compared with the baseline values according to the technique previously described by  
45  
46 Roccuzzo et al. (2008) and the radiographic bone-defect (BD) fill was calculated.  
47  
48  
49  
50  
51  
52  
53  
54

### 55 **Statistical Analysis**

56  
57 Each patient contributed with one peri-implantitis lesion and was, therefore, regarded as the  
58  
59  
60

1  
2  
3 statistical unit. Data were expressed as mean  $\pm$  SD or percentages. The statistical distribution  
4  
5 of the quantitative measures was found to be non-gaussian (Shapiro-Wilk test) and non  
6  
7 parametric tests were used. Comparison between the 2 groups was performed by means of  
8  
9 Fisher's exact test for qualitative variables, and the Mann-Whitney rank-sum tests for  
10  
11 quantitative variables. Pre- and post-surgery recordings were conducted using exact  
12  
13 McNemar test or Wilcoxon matched-pairs signed-rank test. All the tests were two tailed. The  
14  
15 level of significance was set at 5%.  
16  
17  
18  
19

## 20 21 22 **RESULTS**

23  
24 In all patients, surgery and immediate healing proceeded without complications and with  
25  
26 minimal postoperative discomfort. No patient dropout and no implant removal were registered  
27  
28 during the first 12 months of observation. The clinical parameters in both groups at baseline  
29  
30 and at 1-year evaluation are summarized in Table 2-4.  
31  
32

33  
34 In control group, PD decreased from  $7.2 \pm 1.5$  mm to  $5.1 \pm 2.0$  mm, corresponding to a  
35  
36 statistically significant reduction of  $2.1 \pm 1.2$  mm ( $p=0.001$ ). In test group, PD decreased from  
37  
38  $6.8 \pm 1.2$  mm to  $3.4 \pm 1.0$  mm, corresponding to a statistically significant reduction of  $3.4 \pm 1.7$   
39  
40 mm ( $p=0.003$ ). A statistically significant difference in PD reduction was found between the 2  
41  
42 groups ( $p=0.04$ )  
43  
44

45  
46 Controls presented on average  $3.1 \pm 1.1$  sites per patient with  $PD \geq 6$ mm at baseline and  $1.2$   
47  
48  $\pm 1.7$  sites at 1 year ( $p=0.002$ ). Test implants presented  $2.8 \pm 1.1$  mean sites per patient with  
49  
50  $PD \geq 6$  mm at baseline, which all disappeared at 1-year evaluation ( $p=0.002$ ). Even though  
51  
52 the reduction was greater in Test, the difference between the 2 groups did not reach the  
53  
54 statistically significant level.  
55  
56  
57  
58  
59  
60

1  
2  
3 At baseline BOP was present around  $91.1 \pm 12.4\%$  of the control and  $75.0 \pm 30.2\%$  of test  
4  
5  
6  
7  
8  
9  
10  
11  
12 implant sites. At 1-year examination, the values significantly decreased to  $57.1 \pm 38.5\%$   
13  
14  
15  
16  
17  
18  
19  
20  
21  
22  
23  
24  
25  
26  
27  
28  
29  
30  
31  
32  
33  
34  
35  
36  
37  
38  
39  
40  
41  
42  
43  
44  
45  
46  
47  
48  
49  
50  
51  
52  
53  
54  
55  
56  
57  
58  
59  
60  
( $p=0.004$ ) and to  $14.6 \pm 16.7\%$  ( $p=0.003$ ), respectively. The difference between the 2 groups  
was statistically significant ( $p=0.007$ ).

In control, mean BL decreased from  $3.9 \pm 1.6$  mm to  $2.2 \pm 1.3$  mm, corresponding to a  
reduction of  $1.6 \pm 0.7$  mm ( $p=0.001$ ). In test, BL decreased from  $3.0 \pm 0.9$  mm to  $1.1 \pm 0.8$   
mm, corresponding to a reduction of  $1.9 \pm 1.3$  mm ( $p=0.002$ ). Both reductions were  
statistically significant, but the difference between the 2 groups were not statistically  
significant. Complete bone defect fill was never found in control, while occurred in 3 out of 12  
in test. However, no statistical significant difference between the two groups was detected.

At baseline, plaque was found around  $64.3 \pm 25.4\%$  of control and  $45.8\% \pm 25.7\%$  of test  
implants. At 1-year examination plaque was present around  $30.4 \pm 24.4\%$  ( $p=0.003$ ) and  $16.7$   
 $\pm 16.3\%$  ( $p=0.01$ ), respectively. The reduction was statistically significant in both groups. The  
difference between test and control, however, did not reach a statistically significant level.

Before treatment, pus was present around 10 implants of Control and 4 of Test. At the end of  
the observation period, all test implants healed, while 4 of control did not. After the 1 year  
examination, 2 of these 4 TPS implants presented deep pockets with pus and were  
subsequently removed.

## DISCUSSION

The aim of this prospective study was to evaluate the results of regenerative surgery by  
means of BDX in peri-implant defects around implants of 2 different surfaces. The outcome  
variables were probing depth reduction (PD), bleeding on probing (BOP) reduction, and bone  
defect (BD) fill.

1  
2  
3 The proposed treatment was effective in reducing the mean pocket depth, even though it  
4 produced better results in the test group. In particular, mean PD decrease was  $2.1 \pm 1.2$  mm  
5 in control and  $3.4 \pm 1.7$  mm in test, with a statistically significant difference between the  
6 groups ( $p=0.04$ ). No deep pockets ( $PD \geq 6$ mm) were detected in test at the end of the  
7 observation period, while  $1.2 \pm 1.7$  mean sites were still present in control. From a clinical  
8 point of view, this result seem quite interesting, even though the difference did not reach a  
9 statistically significant level, probably due to the small sample size of the two groups. It is not  
10 possible to draw definitive conclusions, but these positive preliminary results encourage  
11 further investigation with a similar protocol.  
12  
13  
14  
15  
16  
17  
18  
19  
20  
21  
22  
23

24 The surgical therapy was also effective in reducing the proximal bone defects, especially in  
25 Test. In particular, complete defect fill occurred around 25% of the SLA implants while it was  
26 never found around TPS implants. The mean defect fill (measured mesially and distally at  
27 each implant) was  $1.6 \pm 0.7$  mm in control and  $1.9 \pm 1.3$  mm in test, with a difference which  
28 did not reach a significant level. Two TPS implants out of 14 were removed, at the end of the  
29 follow-up period, as a consequence of the persistence of deep pockets.  
30  
31  
32  
33  
34  
35  
36  
37

38 Behneke et al. (2000) presented a report on 25 ITI screw implants in 17 patients, with air-  
39 polishing of the surface, and corticocancellous bone grafts or particulate bone placed into the  
40 peri-implant osseous defects, allowing transmucosal healing. Two of the 25 cases resulted in  
41 a negative outcome of the procedure. The results of this study suggested that the use of  
42 autogenous bone grafts appears to be an efficacious treatment approach for restoring the  
43 bone loss caused by peri-implantitis. The success of the treatment was attributed to the use of  
44 autogenous bone as an augmentation material with the possibility of maintenance of cellular  
45 viability and rapid revascularization. It must be said, however, that the possibility of placement  
46 of a block into a defect depends on the morphology of the defect and may be quite difficult in  
47  
48  
49  
50  
51  
52  
53  
54  
55  
56  
57  
58  
59  
60

1  
2  
3 some anatomic circumstances. On the other hand, the spongy consistency of BDX Collagen,  
4  
5 used in the present study after moistening in sterile saline, allowed simple trimming and easy  
6  
7 adaptation of the material to the peri-implant defects.  
8  
9

10 Khoury & Buchmann (2001) concluded that submerged healing of autogenous bone grafts,  
11  
12 with and without the application of barriers, in advanced peri-implant disease represents an  
13  
14 appropriate treatment regimen to augment the open creater-deformed defects, and is  
15  
16 significantly associated with a long-tem stability of peri-implant health. The advantages of the  
17  
18 technique presented in the present study is that healing seems to be present without the need  
19  
20 of the removal of the prosthetic restoration in order to submerge the implant reducing time  
21  
22 and cost of treatment. It must be said, however, that a minimal amount of keratinized tissue  
23  
24 was considered necessary for a successful application of the technique. Therefore, in areas  
25  
26 with no keratinized mucosa, a connective tissue graft was trimmed and adapted to ensure  
27  
28 stability of the graft material. Test and Control were, with the adopted technique, similar in all  
29  
30 aspects, except for implant surface. This was particularly interesting from a statistical point of  
31  
32 view, as bias and variability were reduced to minimal levels. It would be useful in the future, to  
33  
34 assess if the quality of the soft tissue, i.e. keratinized tissue vs. alveolar mucosa, may  
35  
36 influence the treatment outcomes of peri-implantitis, as previous studies have not taken this  
37  
38 parameter into careful consideration.  
39  
40  
41  
42  
43  
44

45 Leonhardt et al. (2003) treated 26 implants demonstrating peri-implantitis in 9 periodontally  
46  
47 compromised partially dentate individuals (5 smokers) by means of surgical exposure of the  
48  
49 lesions and cleaning using hydrogen peroxide. No attempt to regenerate the bone defect was  
50  
51 pursued, while antibiotic regimen was started according to a susceptibility test of target  
52  
53 bacteria. The treatment was successful in 58% of the implants treated during the 5-year  
54  
55 follow-up period. Smoking seemed to be a negative factor for treatment success. On the  
56  
57  
58  
59  
60

1  
2  
3 contrary Serino & Turri (2011) found no difference in the mean number of implants with peri-  
4  
5  
6 implantitis at the 2-year examination between smokers and non-smokers. In the present study  
7  
8 the number of smokers was so limited (4 out of 26) to draw any conclusions.

9  
10 The question if submerged healing and/or the application of a membrane may have resulted  
11  
12 in more pronounced bone defect fill is still open. Roos-Jansåker (2007b) presented one study  
13  
14 on regenerative surgical treatment modality for peri-implantitis employing submerged healing  
15  
16 in 12 patients. After surgical exposure of the defect the implant surface was treated using 3%  
17  
18 hydrogen peroxide. The bone defects were filled with a bone substitute and a resorbable  
19  
20 membrane was placed over the grafted defect. The implant was then covered by flaps and  
21  
22 submerged healing was allowed for 6 months. Probing depth was reduced by 4.2 mm and a  
23  
24 mean defect fill of 2.3 mm was obtained. In the same year, the same author Roos-Jansåker  
25  
26 (2007a) presented a prospective cohort study using a bone substitute with or without  
27  
28 resorbable membranes punched and fixed over the implant by the abutment. There was no  
29  
30 significant difference between the 2 groups. No sufficient data are present to leap to definitive  
31  
32 conclusions on this matter. In the present study it was decided not to use the membrane in  
33  
34 order to keep the procedure as simple as possible in agreement with data showing that the  
35  
36 placement of Bio-Oss Collagen alone in fresh extraction sockets may counteract  
37  
38 postextraction ridge reductions (Araújo & Lindhe 2009). More recently, Araújo et al. (2011)  
39  
40 demonstrated that the placement of Bio-Oss Collagen in the void between the implant and the  
41  
42 buccal-approximal bone walls of fresh extraction sockets provided additional amounts of hard  
43  
44 tissue at the entrance of the previous socket and improved the level of marginal bone-to-  
45  
46 implant contact.

47  
48 A similar protocol, without the use of a membrane, was recently described by Wiltfang et al.  
49  
50 (2010), who presented the results in 36 cases of peri-implantitis-induced bone loss (depth > 4  
51  
52  
53  
54  
55  
56  
57  
58  
59  
60

1  
2  
3 mm) that were followed for 1 year. The implants were decontaminated with etching gel and  
4  
5 the defects were filled with autologous bone mixed 1:1 with a xenogenic bone graft. The  
6  
7 bone defects after treatment revealed a mean reduction of 3.5 mm comparing the values from  
8  
9 5.1 mm prior to surgery to 1.6 mm 1 year after treatment. Average reduction of the probing  
10  
11 depth was 4 mm. Probing depths of more than 4 mm were present in seven implants.  
12  
13

14  
15 Regarding BOP, at baseline, bleeding was found at  $91.1 \pm 12.4\%$  of the sites compared with  
16  
17  $57.1 \pm 38.5\%$  after treatment ( $p=0.004$ ), in control and at  $75.0 \pm 30.2\%$  of the sites  
18  
19 compared with  $14.6 \pm 16.7\%$  after treatment ( $p=0.003$ ), in test. The improved bleeding  
20  
21 scores for both groups indicate a clinically healthier situation after therapy in accordance with  
22  
23 Lang et al. (1990) and Roos-Jansåker et al. (2007a, 2007b).  
24  
25

26  
27 It is interesting to note that at 1-year evaluation, both FMPS ( $21.0 \pm 6.8\%$  vs.  $19.5 \pm 5.2\%$ )  
28  
29 and FMBS ( $20.6 \pm 6.0\%$  vs.  $18.6 \pm 6.1\%$ ) were reduced to an acceptable level with no  
30  
31 statistical difference between the two groups. This may indeed suggest that the study  
32  
33 outcome is not related to oral hygiene but somehow to implant surface characteristics.  
34  
35

36  
37 The question about the ideal protocol for bactericidal effect against adhering bacteria is still  
38  
39 open. Schou et al. (2003) indicated that the simplest method involving chlorhexidine and saline  
40  
41 should be the preferred implant surface preparation method. A recent paper by Gosau et al.  
42  
43 (2010) revealed that several antiseptics seemed to be able to reduce the total amount of  
44  
45 microorganisms accumulating on titanium surfaces supporting the additional use of  
46  
47 antibacterial agents in peri-implant therapy. Similarly, Schwarz et al. (2011) failed to  
48  
49 demonstrate a significant impact of the method of surface decontamination on the clinical  
50  
51 outcome following combined surgical therapy of advanced peri-implantitis lesions. The two  
52  
53 step procedure (EDTA + chlorhexidine gel) employed in this research has never been  
54  
55  
56  
57  
58  
59  
60



1  
2  
3 described before and has been selected because it presents the advantage of low-cost and  
4  
5 easy use. Its real efficacy, however, can be confirmed only by controlled bacterial studies.  
6  
7

8 Unlike the studies of Schwarz et al. (2006, 2009) where several implant types and implant  
9  
10 surfaces were investigated, this research evaluated the outcome of the same surgical  
11  
12 protocol on implants that differ by only one variable of interest, i.e. surface characteristics.  
13  
14

15 While the TPS surface has  $S_a$  values of approximately 3.1  $\mu\text{m}$ , SLA has  $S_a$  values of  
16  
17 approximately 2.0  $\mu\text{m}$  (Buser et al. 1999). In a recent systematic review, prepared for the  
18  
19 Seventh European Workshop on Periodontology, Renvert et al. (2011) revealed that only a  
20  
21 few studies provided data on how implant surfaces influence peri-implant disease, with no  
22  
23 evidence that implant surface characteristics can have a significant effect on the initiation of  
24  
25 peri-implantitis. In animals, it is demonstrated (Albouy et al. 2011) that resolution of peri-  
26  
27 implantitis following surgery is possible and that the outcome of treatment is influenced by  
28  
29 implant surface characteristics, but no comparative clinical research has confirmed this  
30  
31 difference in humans. The preliminary results of this study seem to confirm data from a recent  
32  
33 research on mandibles of dogs (Parlar et al. 2009), where the treatment of peri-implantitis  
34  
35 with decontamination method resulted in considerable more bone fill around an SLA implant  
36  
37 than TPS. In the clinical practice, of course, the amount of re-osseointegration on previously  
38  
39 plaque contaminated surface cannot be evaluated.  
40  
41  
42  
43  
44  
45

46 In conclusion, the antimicrobial and surgical technique described resulted in a clinical  
47  
48 healthier situation around many of the treated implants so that their function could be fully  
49  
50 maintained. Moreover, the treatment around SLA implants presented better final results, even  
51  
52 though the reason for this is not fully understood. The time in function of the implants varied  
53  
54 considerably from 14 to 120 months. The impact of this variable is also completely unknown.  
55  
56  
57  
58 Nevertheless, these preliminary results seems to suggest that the clinical decision on whether  
59  
60

1  
2  
3 implants should be removed or treated may also be based on the surface characteristics.  
4  
5 Ideally, this should be established on large well-designed RCTs with long follow-up. Practical  
6  
7 and ethical reasons, however, make RCTs possible only after preliminary information, from  
8  
9 lower quality studies, are available. Within its limits, mainly the lack of classification of the  
10  
11 defects (Schwarz et al. 2010) and the relatively small sample size, the present pilot study  
12  
13 represents a step in the definition of the ideal protocol for the treatment of peri-implant defect.  
14  
15 Finally, more years of observation are necessary to verify whether an osseous defect fill with  
16  
17 incomplete “re-osseointegration” is sufficient to ensure favorable long-term maintenance of  
18  
19 the implants.  
20  
21  
22  
23  
24  
25  
26  
27  
28  
29  
30  
31  
32  
33  
34  
35  
36  
37  
38  
39  
40  
41  
42  
43  
44  
45  
46  
47  
48  
49  
50  
51  
52  
53  
54  
55  
56  
57  
58  
59  
60

1  
2  
3 **REFERENCES**  
4  
5  
6

- 7 Albouy, J.P., Abrahamsson, I., Persson, L.G. & Berglundh, T. (2011) Implant surface  
8 characteristics influence the outcome of treatment of peri-implantitis: an experimental study in  
9 dogs. *Journal of Clinical Periodontology* **38**, 58-64.
- 10 Araújo, M.G. & Lindhe J. (2009) Ridge preservation with the use of Bio-Oss collagen. A 6  
11 month study in the dog. *Clinical Oral Implants Research* **20**, 433–440.
- 12 Araújo, M.G., Linder, E. & Lindhe, J. (2011) Bio-Oss Collagen in the buccal gap at immediate  
13 implants: a 6-month study in the dog. *Clinical Oral Implants Research* **22**, 1–8.
- 14 Behneke, A., Behneke, N. & d'Hoedt, B. (2000) Treatment of peri-implantitis defects with  
15 autogenous bone grafts: six-month to 3-year results of a prospective study in 17 patients.  
16 *International Journal of Oral & Maxillofacial Implants* **15**, 125-138.
- 17 Berglundh, T., Persson, L. & Klinge, B. (2002) A systematic review of the incidence of  
18 biological and technical complications in implant dentistry reported in prospective longitudinal  
19 studies of at least 5 years. *Journal of Clinical Periodontology* **29** (Suppl. 3), 197-212.
- 20 Bornstein, M.M., Schmid, B., Belser, U.C., Lussi, A. & Buser, D. (2005) Early loading of non-  
21 submerged titanium implants with a sandblasted and acid-etched surface. 5-year results of a  
22 prospective study in partially edentulous patients. *Clinical Oral Implants Research* **16**, 631–  
23 638.
- 24 Buser, D., Nydegger, T., Oxland, T., Cochran, D.L., Schenk, R.K., Hirt, H.P., Snétivy, D. &  
25 Nolte, L.P. (1999) Interface shear strength of titanium implants with a sandblasted and acid-  
26 etched surface: a biomechanical study in the maxilla of miniature pigs. *Journal of Biomedical*  
27 *Materials Research* **45**, 75-83.
- 28 Claffey, N., Clarke, E., Polyzois, I. & Renvert, S. (2008) Surgical treatment of peri-implantitis.  
29 *Journal of Clinical Periodontology* **35** (Suppl. 8), 316-332.
- 30 Esposito, M., Grusovin, M.G., Tzanetia, E., Piattelli, A. & Worthington, H.V. (2010)  
31 Interventions for replacing missing teeth: treatment of perimplantitis. *Cochrane Database of*  
32 *Systematic Reviews* **6**: CD004970.
- 33 Fiorellini, J.P. & Weber, H.P. (1994) Clinical trials on the prognosis of dental implants.  
34 *Periodontology 2000* **4**, 98-108.
- 35 Fransson, C., Wennström, J., Tomasi, C. & Berglundh, T. (2009) Extent of peri-implantitis-  
36 associated bone loss. *Journal of Clinical Periodontology* **36**, 357-363.
- 37  
38  
39  
40  
41  
42  
43  
44  
45  
46  
47  
48  
49  
50  
51  
52  
53  
54  
55  
56  
57  
58  
59  
60

- 1  
2  
3 Gosau, M., Hahnel, M., Schwarz, F., Gerlach, T., Reichert, T.E. & Bürgers, R. (2010) Effect of  
4 six different peri-implantitis disinfection methods on *in vivo* human oral biofilm. *Clinical Oral*  
5 *Implants Research* **21**, 866-872.  
6  
7  
8 Heitz-Mayfield, L.J. (2008) Peri-implant diseases: diagnosis and risk indicators. *Journal of*  
9 *Clinical Periodontology* **35** (Suppl. 8), 292-304.  
10  
11 Heitz-Mayfield, L.J. & Lang, N.P. (2010) Comparative biology of chronic and aggressive  
12 periodontitis vs. peri-implantitis. *Periodontology 2000* **53**, 167-181.  
13  
14 Khoury, F. & Buchmann, R. (2001) Surgical therapy of peri-implant disease: a 3-year follow-  
15 up study of cases treated with 3 different techniques of bone regeneration. *Journal of*  
16 *Periodontology* **72**, 1498-1508.  
17  
18  
19 Koldslund, O.C., Scheie, A.A. & Aass, A.A. (2010) Prevalence of peri-implantitis related to  
20 severity of the disease with different degrees of bone loss. *Journal of Periodontology* **81**, 231-  
21 238.  
22  
23  
24  
25  
26 Kotsovilis, S., Karoussis, I.K., Trianti, M. & Fourmouis I. (2008) Therapy of peri-implantitis: a  
27 systematic review. *Journal of Clinical Periodontology* **35**, 621-629.  
28  
29  
30 Lang, NP., Adler, R., Joss, A. & Nyman, S. (1990) Absence of bleeding on probing. An  
31 indicator of periodontal stability. *Journal of Clinical Periodontology* **17**, 714-721.  
32  
33  
34 Lang, N.P. & Berglundh, T. (2011) Working Group 4 of Seventh European Workshop on  
35 Periodontology. Periimplant diseases: where are we now?--Consensus of the Seventh  
36 European Workshop on Periodontology. *Journal of Clinical Periodontology* **38** (Suppl. 11),  
37 178-181.  
38  
39  
40 Leonhardt, A., Dahlén, G. & Renvert, S. (2003) Five-year clinical, microbiological, and  
41 radiological outcome of treatment of peri-implantitis in man. *Journal of Periodontology* **74**,  
42 1415-1422.  
43  
44  
45 Lindhe, J. & Meyle, J. (2008) Peri-implant diseases: Consensus Report of the Sixth European  
46 Workshop on Periodontology. *Journal of Clinical Periodontology* **35** (Suppl. 8), 282-285.  
47  
48  
49 Moher, D., Hopewell, S., Schulz, K.F., Montori, V., Gøtzsche, P.C., Devereaux, P.J.,  
50 Elbourne, D., Egger, M. & Altman, D.G. for the CONSORT group (2010) CONSORT 2010  
51 explanation and elaboration: updated guidelines for reporting parallel group randomised trial.  
52 *British Medical Journal* **340**, c869.  
53  
54  
55  
56 Mombelli, A. & Lang, N.P. (1998) The diagnosis and treatment of peri-implantitis.  
57 *Periodontology 2000* **17**, 63-76.  
58  
59  
60

1  
2  
3 Parlar, A., Bosshardt, D.D., Cetiner, D., Schafroth, D., Unsal, B., Haytac, C. & Lang, N.P.  
4 (2009) Effects of decontamination and implant surface characteristics on re-osseointegration  
5 following treatment of peri-implantitis. *Clinical Oral Implants Research* **20**, 391–399.

6  
7  
8 Persson, L.G., Berglundh, T., Lindhe, J. & Sennerby, L. (2001) Re-osseointegration after  
9 treatment of peri-implantitis at different implant surfaces. An experimental study in the dog.  
10  
11 *Clinical Oral Implants Research* **16**, 595-603.

12  
13  
14 Renvert, S., Roos-Jansåker, A.M. & Claffey, N. (2008) Non-surgical treatment of peri-implant  
15 mucositis and peri-implantitis: a literature review. *Journal of Clinical Periodontology* **35**, 305-  
16  
17 315.

18  
19 Renvert, S., Polyzois, I. & Claffey, N. (2011) How do implant surface characteristics influence  
20 peri-implant disease? *Journal of Clinical Periodontology* 38 (Suppl. 11), 214-222.

21  
22 Renvert, S., Polyzois, I. & Maguire, R. (2009) Re-osseointegration on previously  
23 contaminated surfaces: a systematic review. *Clinical Oral Implants Research* **20** (Suppl. 4),  
24  
25 216-227.

26  
27  
28 Roccuzzo, M., Bunino, M., Prioglio, F. & Bianchi, S.D. (2001) Early loading of sandblasted  
29 and acid-etched (SLA) implants: a prospective split-mouth comparative study. *Clinical Oral*  
30  
31 *Implants Research* **12**, 572-578.

32  
33 Roccuzzo, M., Aglietta, M., Bunino, M. & Bonino, L. (2008) Early loading of sandblasted and  
34 acid-etched implants: a randomized controlled double-blind split-mouth study. Five-year  
35  
36 results. *Clinical Oral Implants Research* **19**, 148–152.

37  
38 Roccuzzo, M., De Angelis, N., Bonino, L. & Aglietta, M. (2010) Ten-year results of a three-arm  
39  
40 prospective cohort study on implants in periodontally compromised patients. Part I: implant  
41  
42 loss and radiographic bone loss. *Clinical Oral Implants Research* **21**, 490-496.

43  
44 Romeo, E., Ghisolfi, M., Murgolo, N., Chiapasco, M., Lops, D. & Vogel, G. (2005) Therapy of  
45  
46 peri-implantitis with resective surgery. A 3-year clinical trial on rough screw-shaped oral  
47  
48 implants. Part I: clinical outcome. *Clinical Oral Implants Research* **16**, 9-18.

49  
50 Romeo, E., Lops, D., Chiapasco, M., Ghisolfi, M. & Vogel, G. (2007) Therapy of peri-  
51  
52 implantitis with resective surgery. A 3-year clinical trial on rough screw-shaped oral implants.  
53  
54 Part II: radiographic outcome. *Clinical Oral Implants Research* **18**, 179-187.

55  
56 Roos-Jansåker, A.M., Lindahl, C., Renvert, H. & Renvert, S. (2006) Nine- to fourteen-year  
57  
58 follow-up of implant treatment. Part II: presence of peri-implant lesions. *Journal of Clinical*  
59  
60 *Periodontology* **33**, 290-295.

1  
2  
3 Roos-Jansåker, A.M., Renvert, H., Lindhal, C. & Renvert, S. (2007a) Surgical treatment of  
4 peri-implantitis using a bone substitute with or without a resorbable membrane: a prospective  
5 cohort study. *Journal of Clinical Periodontology* **34**, 625-632.

6  
7  
8 Roos-Jansåker, A.M., Renvert, H., Lindhal, C. & Renvert, S. (2007b) Submerged healing  
9 following surgical treatment of peri-implantitis: a case series. *Journal of Clinical*  
10 *Periodontology* **34**, 723-727.

11  
12  
13 Sahrman, P., Attin, T. & Schmidlin, P.R. (2011) Regenerative treatment of peri-implantitis  
14 using bone substitutes and membrane: a systematic review. *Clinical Implant Dentistry and*  
15 *Related Research* **13**, 46-57.

16  
17  
18 Schou, S., Holmstrup, P., Jørgensen, T., Skovgaard, L.T., Stoltze, K., Hjørting-Hansen, E. &  
19 Wenzel, A. (2003) Implant surface preparation in the surgical treatment of experimental peri-  
20 implantitis with autogenous bone graft and ePTFE membrane in cynomolgus monkeys.  
21 *Clinical Oral Implants Research* **14**, 412-22.

22  
23  
24 Schulz, K.F., Altman, D.G. & Moher, D. for the CONSORT group (2010) CONSORT 2010  
25 statement: updated guidelines for reporting parallel group randomized trials. *British Medical*  
26 *Journal* **340**, c332.

27  
28  
29 Schwarz, F., Bieling, K., Bonsmann, M., Latz, T. & Becker, J. (2006) Nonsurgical treatment of  
30 moderate and advanced periimplantitis lesions: a controlled clinical study. *Clinical Oral*  
31 *Investigations* **10**, 279-288.

32  
33  
34 Schwarz, F., Sahm, N., Bieling, K. & Becker, J. (2009) Surgical regenerative treatment of peri-  
35 implantitis lesions using a nanocrystalline hydroxyapatite or a natural bone mineral in  
36 combination with a collagen membrane: a four-year clinical follow-up report. *Journal of*  
37 *Clinical Periodontology* **36**, 807-814.

38  
39  
40 Schwarz, F., Sahm, N., Iglhaut, G. & Becker, J. (2011) Impact of the method of surface  
41 debridement and decontamination on the clinical outcome following combined surgical  
42 therapy of peri-implantitis: a randomized controlled clinical study. *Journal of Clinical*  
43 *Periodontology* **38**, 276-284.

44  
45  
46 Schwarz, F., Sahm, N., Schwarz, K. & Becker, J. (2010) Impact of defect configuration on the  
47 clinical outcome following surgical regenerative therapy of peri-implantitis. *Journal of Clinical*  
48 *Periodontology* **37**, 449-455.

49  
50  
51 Serino, G. & Strom, C. (2009) Peri-implantitis in partially edentulous patients: association with  
52 inadequate plaque control. *Clinical Oral Implants Research* **20**, 169-174.

1  
2  
3 Serino, G. & Turri, A. (2011) Outcome of surgical treatment of peri-implantitis: results from a  
4 2-year prospective clinical study in humans. *Clinical Oral Implants Research* XX [Epub].

5  
6 Wiltfang, J., Zernial, O., Behrens, E., Schlegel, A., Warnke, P.H. & Becker, S.T. (2010)  
7 Regenerative Treatment of Peri-Implantitis Bone Defects with a Combination of Autologous  
8 Bone and a Demineralized Xenogenic Bone Graft: A Series of 36 Defects. *Clinical Implants*  
9 *Dentistry and Related Research* XX [Epub].

10  
11 Zitzmann, N. U. & Berglundh, T. (2008) Definition and prevalence of peri-implant diseases.  
12  
13  
14  
15  
16  
17  
18  
19  
20  
21  
22  
23  
24  
25  
26  
27  
28  
29  
30  
31  
32  
33  
34  
35  
36  
37  
38  
39  
40  
41  
42  
43  
44  
45  
46  
47  
48  
49  
50  
51  
52  
53  
54  
55  
56  
57  
58  
59  
60  
*Journal of Clinical Periodontology* 35, 286–291.

For Peer Review

Table 1. Data on patients, defect location, implant type, months in function

n	SEX	AGE	SMOKING	SITE	IMPLANT TYPE	Months in function
1	M	56		25	∅ 4.1 x 10 mm TPS	80
2	F	53		31	∅ 3.3 x 12 mm TPS	63
3	M	68		21	∅ 4.1 x 10 mm SLA	22
4	F	66		35	∅ 4.1 x 10 mm TPS	98
5	M	55		46	∅ 4.1 x 08 mm SLA	14
6	F	55		14	∅ 4.1 x 10 mm TPS	20
7	F	60		24	∅ 4.1 x 10 mm SLA	58
8	M	68		27	∅ 4.8 x 08 mm SLA	44
9	F	67		26	∅ 4.1 x 10 mm TPS	114
10	M	58	Yes	13	∅ 4.1 x 10 mm SLA	54
11	F	70		23	∅ 4.1 x 08 mm TPS	96
12	F	56		37	∅ 4.8 x 08 mm SLA	69
13	F	79		35	∅ 4.1 x 10 mm TPS	60
14	M	60		26	∅ 4.1 x 10 mm TPS	24
15	F	54		26	∅ 4.1 x 10 mm TPS	58
16	F	63		31	∅ 4.1 x 10 mm TPS	90
17	F	46	Yes	17	∅ 4.8 x 10 mm SLA	34
18	M	51	Yes	46	∅ 4.1 x 12 mm TPS	49
19	F	71		17	∅ 4.8 x 10 mm SLA	78
20	M	64	Yes	35	∅ 4.1 x 12 mm TPS	84
21	F	57		36	∅ 4.1 x 08 mm TPS	92
22	F	56		27	∅ 4.1 x 08 mm SLA	54
23	F	56		14	∅ 4.1 x 10 mm SLA	49
24	F	63		46	∅ 4.1 x 10 mm SLA	24
25	M	45		36	∅ 4.1 x 12 mm TPS	120
26	M	62		36	∅ 4.8 x 10 mm SLA	52



Table 2. Baseline demographic and clinical parameters in Control (TPS) N= 14 and in Test (SLA) N=12. Means  $\pm$  SD; Numbers (%).

	Control	Test	<i>p</i>
Female (%)	9 (64.3)	7 (58.3)	0.99
Age	59.9 $\pm$ 7.0	60 $\pm$ 8.8	0.98
Smoke (%)	2 (14.3)	2 (16.7)	0.99
FMPS (%)*	30.5 $\pm$ 9.1	27.5 $\pm$ 7.5	0.33
FMBS (%)†	29.4 $\pm$ 7.6	26.8 $\pm$ 10.4	0.21

\* Full-mouth plaque score

† Full-mouth bleeding score

Table 3. Clinical parameters around the implants at baseline and 1 year after treatment in both groups. Means  $\pm$  SD; Numbers (%).

	Baseline	Post-op	P value
Probing depth (mm)			
Control	7.2 $\pm$ 1.5	5.1 $\pm$ 2.0	0.001
Test	6.8 $\pm$ 1.2	3.4 $\pm$ 1.0	0.003
Number of sites per patient with PD $\geq$ 6 mm			
Control	3.1 $\pm$ 1.1	1.2 $\pm$ 1.7	0.002
Test	2.8 $\pm$ 1.1	0	0.002
Bone level (mm)			
Control	3.9 $\pm$ 1.6	2.2 $\pm$ 1.3	0.001
Test	3.0 $\pm$ 0.9	1.1 $\pm$ 0.8	0.002
Bleeding on probing at implant site (%)			
Control	91.1 $\pm$ 12.4	57.1 $\pm$ 38.5	0.004
Test	75 $\pm$ 30.2	14.6 $\pm$ 16.7	0.003
Plaque at implant site (%)			
Control	64.3 $\pm$ 25.4	30.4 $\pm$ 24.4	0.003
Test	45.8 $\pm$ 25.7	16.7 $\pm$ 16.3	0.01
Pus			
Control	10 (71.4%)	4 (28.6%)	0.01
Test	4 (33.3%)	0 (0%)	0.04

Table 4. Results of treatment in both groups. Means  $\pm$  SD; Numbers (%).

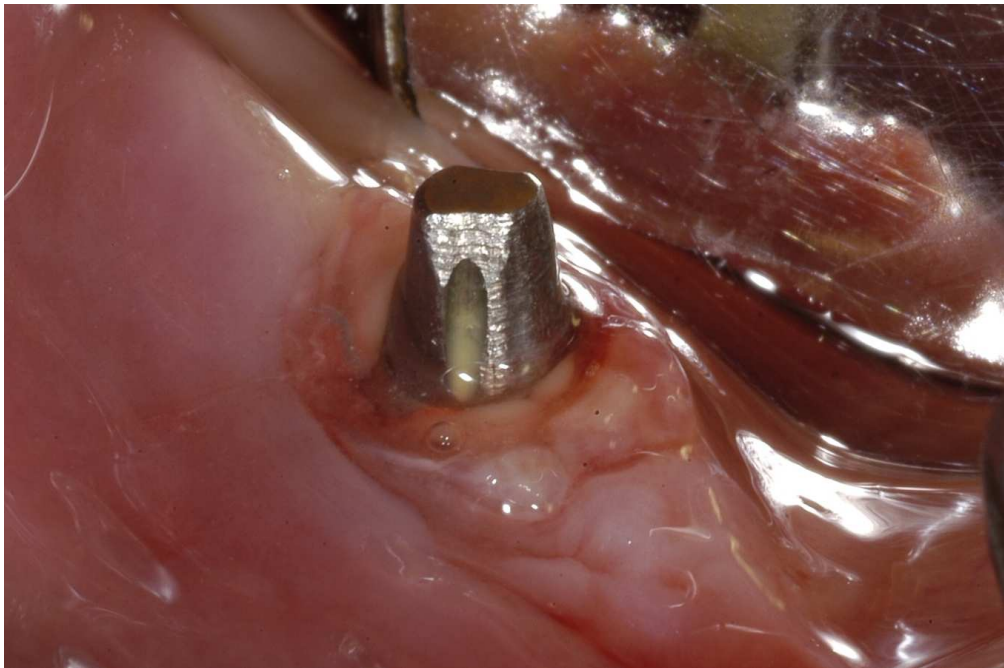	Control	Test	<i>p</i>
Probing Depth Reduction (mm)	2.1 $\pm$ 1.2	3.4 $\pm$ 1.7	0.04
Reduction of number of sites per patient with PD $\geq$ 6 mm	1.9 $\pm$ 1.6	2.8 $\pm$ 1.1	0.10
Bone defect fill (mm)	1.6 $\pm$ 0.7	1.9 $\pm$ 1.3	0.99
Complete bone defect fill	0 /14 (0%)	3/12 (25%)	0.09
BOP* reduction	19/56 (33.9%)	29/48 (60.4%)	0.007
Plaque reduction	19/56 (33.9%)	14/48 (29.1%)	0.59
Pus elimination	6/10 (60%)	4/4 (100%)	0.25

\*Bleeding on Probing

1  
2  
3  
4  
5  
6  
7 **Figure legends:**  
8  
9

- 10 1) Inflammation and pus around the implant, at baseline.  
11  
12 2) Peri-implantitis lesion after removal of granulation tissue and before decontamination of the  
13 implant surface.  
14  
15 3) Bovine-derived xenograft applied around the peri-implantitis defect.  
16  
17 4) Non-submerged suture of the flap.  
18  
19 5) Clinical situation and probing around the implant at 1-year follow-up.  
20  
21  
22  
23  
24  
25  
26  
27  
28  
29  
30  
31  
32  
33  
34  
35  
36  
37  
38  
39  
40  
41  
42  
43  
44  
45  
46  
47  
48  
49  
50  
51  
52  
53  
54  
55  
56  
57  
58  
59  
60

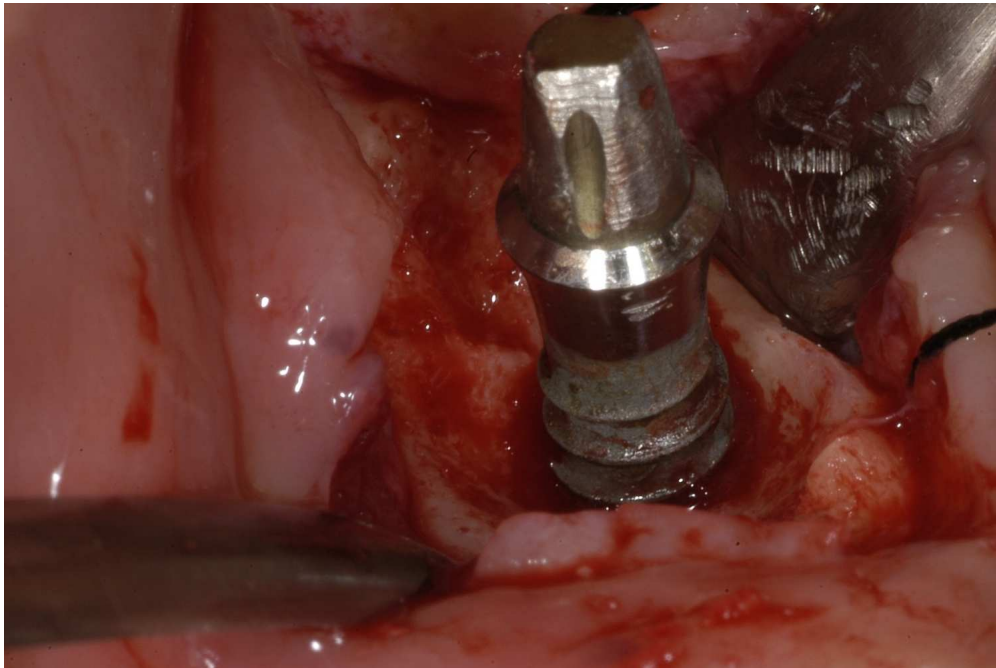
1  
2  
3  
4  
5  
6  
7  
8  
9  
10  
11  
12  
13  
14  
15  
16  
17  
18  
19  
20  
21  
22  
23  
24  
25  
26  
27  
28  
29  
30  
31  
32  
33  
34  
35  
36  
37  
38  
39  
40  
41  
42  
43  
44  
45  
46  
47  
48  
49  
50  
51  
52  
53  
54  
55  
56  
57  
58  
59  
60



Inflammation and pus around the implant, at baseline.  
114x76mm (300 x 300 DPI)

Review

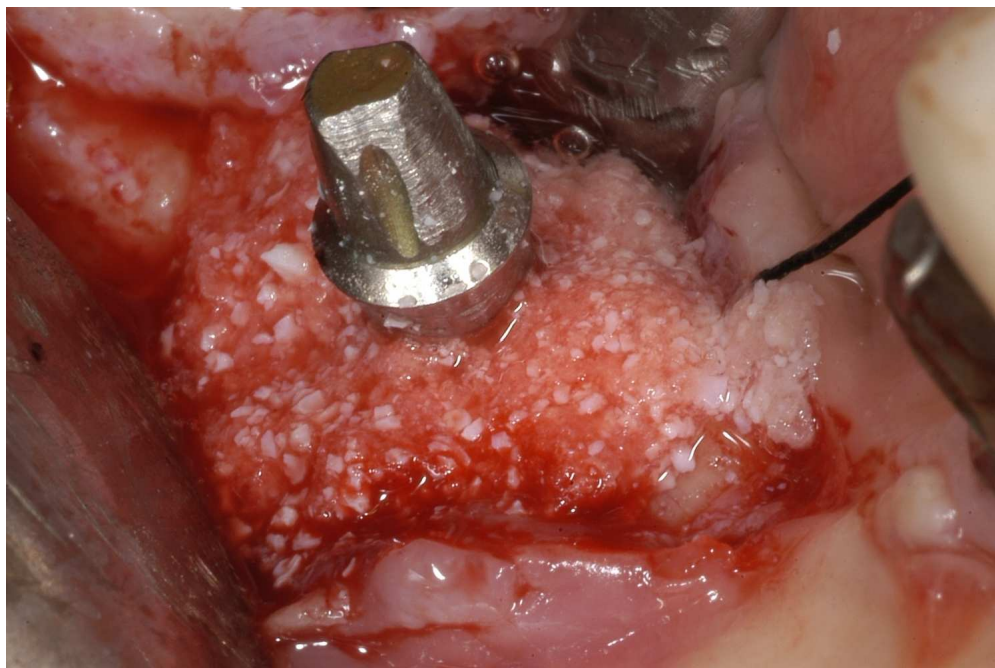1  
2  
3  
4  
5  
6  
7  
8  
9  
10  
11  
12  
13  
14  
15  
16  
17  
18  
19  
20  
21  
22  
23  
24  
25  
26  
27  
28  
29  
30  
31  
32  
33  
34  
35  
36  
37  
38  
39  
40  
41  
42  
43  
44  
45  
46  
47  
48  
49  
50  
51  
52  
53  
54  
55  
56  
57  
58  
59  
60



127x84mm (300 x 300 DPI)

Review

1  
2  
3  
4  
5  
6  
7  
8  
9  
10  
11  
12  
13  
14  
15  
16  
17  
18  
19  
20  
21  
22  
23  
24  
25  
26  
27  
28  
29  
30  
31  
32  
33  
34  
35  
36  
37  
38  
39  
40  
41  
42  
43  
44  
45  
46  
47  
48  
49  
50  
51  
52  
53  
54  
55  
56  
57  
58  
59  
60

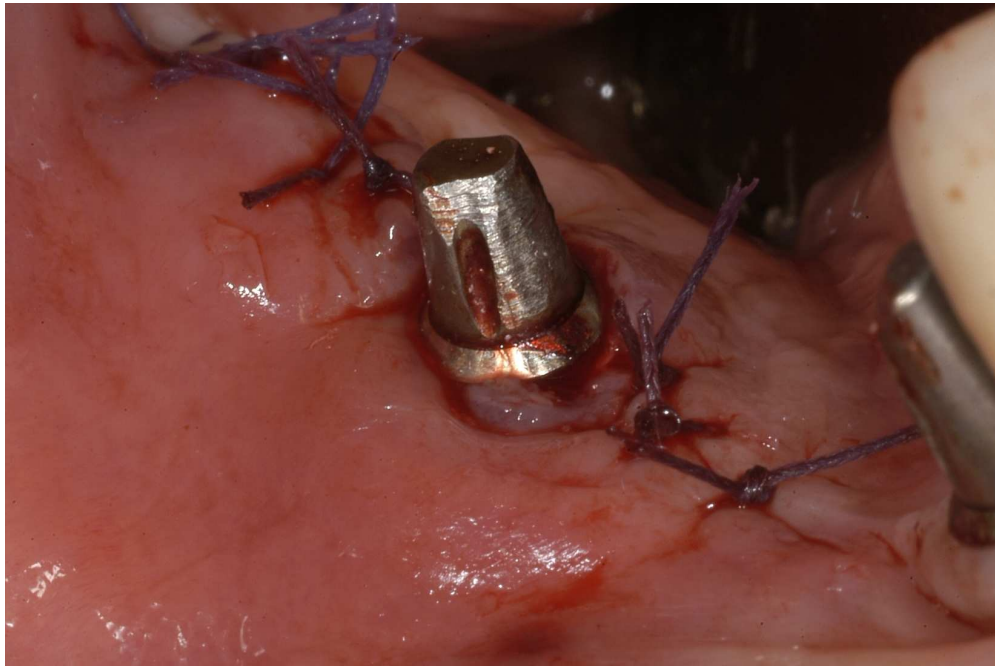


Bovine-derived xenograft applied around the peri-implant defect.

126x84mm (300 x 300 DPI)

Review

1  
2  
3  
4  
5  
6  
7  
8  
9  
10  
11  
12  
13  
14  
15  
16  
17  
18  
19  
20  
21  
22  
23  
24  
25  
26  
27  
28  
29  
30  
31  
32  
33  
34  
35  
36  
37  
38  
39  
40  
41  
42  
43  
44  
45  
46  
47  
48  
49  
50  
51  
52  
53  
54  
55  
56  
57  
58  
59  
60

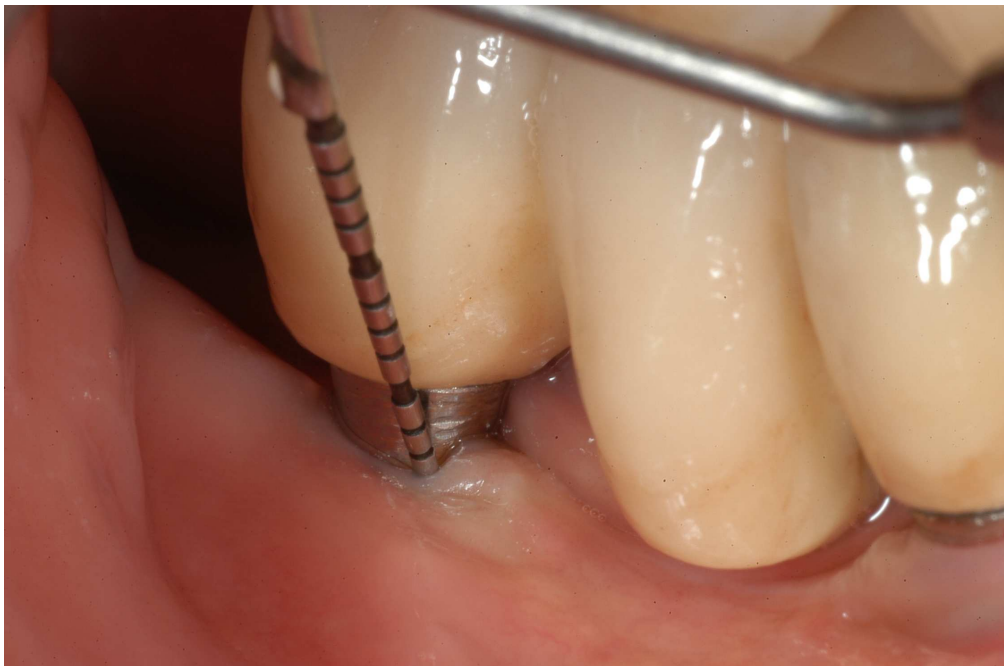

Non-submerged suture of the flap.  
139x93mm (300 x 300 DPI)

Review



1  
2  
3  
4  
5  
6  
7  
8  
9  
10  
11  
12  
13  
14  
15  
16  
17  
18  
19  
20  
21  
22  
23  
24  
25  
26  
27  
28  
29  
30  
31  
32  
33  
34  
35  
36  
37  
38  
39  
40  
41  
42  
43  
44  
45  
46  
47  
48  
49  
50  
51  
52  
53  
54  
55  
56  
57  
58  
59  
60



Clinical situation and probing around the implant at 1-year follow-up.  
189x125mm (300 x 300 DPI)

Review