HAL
open science

# Systematic review: Use of ultrasonography, computed tomography and magnetic resonance imaging for the diagnosis, assessment of activity and abdominal complications of Crohn's disease

Julian Panes, Rosa Bouzas, Valle García-Sánchez, María Chaparro, Javier Pérez-Gisbert, Blanca Martínez de Guereñu, Juan Luis Mendoza, José María Paredes, Sergi Quiroga, Tomás Ripollés, et al.

## To cite this version:

Julian Panes, Rosa Bouzas, Valle García-Sánchez, María Chaparro, Javier Pérez-Gisbert, et al.. Systematic review: Use of ultrasonography, computed tomography and magnetic resonance imaging for the diagnosis, assessment of activity and abdominal complications of Crohn's disease. Alimentary Pharmacology and Therapeutics, 2011, 34 (2), pp.125. 10.1111/j.1365-2036.2011.04710.x . hal-00644724

**HAL Id: hal-00644724**

**https://hal.science/hal-00644724v1**

Submitted on 25 Nov 2011

**HAL** is a multi-disciplinary open access archive for the deposit and dissemination of scientific research documents, whether they are published or not. The documents may come from teaching and research institutions in France or abroad, or from public or private research centers.

L'archive ouverte pluridisciplinaire **HAL**, est destinée au dépôt et à la diffusion de documents scientifiques de niveau recherche, publiés ou non, émanant des établissements d'enseignement et de recherche français ou étrangers, des laboratoires publics ou privés.

Alimentary Pharmacology & Therapeutics

# Systematic review: Use of ultrasonography, computed tomography and magnetic resonance imaging for the diagnosis, assessment of activity and abdominal complications of Crohn's disease

| | |
|---|---|
| Journal: | *Alimentary Pharmacology & Therapeutics* |
| Manuscript ID: | APT-1112-2010.R1 |
| Wiley - Manuscript type: | Systematic Review |
| Date Submitted by the Author: | 01-May-2011 |
| Complete List of Authors: | Panes, Julian; Hospital Clinic, Vailarroel 170, Gastroenterology Dept.<br>Bouzas, Rosa; Complejo Hospitalario Xeral-Cies, Radiology<br>García-Sánchez, Valle; Hospital Reina Sofía, Gastroenterology<br>Chaparro, María; Hospital La Princesa, Gastroenterology<br>Pérez-Gisbert, Javier; University Hospital La Princesa, Gastroenterology and Hepatology<br>Martínez de Guereñu, Blanca; Osatek Vitoria, Radiology<br>Mendoza, Juan; Hospital Clínico San Carlos, Aparato Digestivo<br>Paredes, José; Hospital Uniersitari Dr Peset, Aparato Digestivo<br>Quiroga, Sergi; Hospital Vall d'Hebron, Radiology<br>Ripollés, Tomás; Hospital Universitari Dr Peset, Radiology<br>Rimola, Jordi; Hospital Clínic, Radiology |
| Keywords: | Crohn's disease < Disease-based, Inflammatory bowel disease < Disease-based, Large intestine < Organ-based, Small intestine < Organ-based, Radiology/imaging < Topics, Inflammation < Topics, Diagnostic tests < Topics |
| | |

SCHOLARONE™
Manuscripts

# Systematic review: Use of ultrasonography, computed tomography and magnetic resonance imaging for the diagnosis, assessment of activity and abdominal complications of Crohn's disease

**Running head: Cross-Sectional imaging in Crohn's disease**

Julián Panés[1,2], Rosa Bouzas[3], María Chaparro[2,4], Valle García-Sánchez[5], Javier P Gisbert[2,4], Blanca Martínez de Guereñu[6], Juan-Luís Mendoza[7], José María Paredes[8], Sergi Quiroga[9], Tomás Ripollés[8], Jordi Rimola[1].

Affiliations: [1]Hospital Clínic Barcelona,[2]CIBERehd Instituto Salud Carlos III, [3]Complejo Hospitalario Xeral-Cíes Vigo, [4] Hospital Universitario de La Princesa e Instituto de Investigación Sanitaria Princesa, [5] Hospital Reina Sofía Córdoba, [6]Osatek Vitoria, [7] Hospital Clínico San Carlos Madrid, [8] Hospital Universitario Dr. Peset Valencia, [9] Hospital Vall d'Hebron Barcelona, Spain

**Address for correspondence:**

Julián Panés, M.D.
Department of Gastroenterology
Hospital Clínic of Barcelona
Villarroel 170
08036 Barcelona
Spain
Tel: +34 932275418
Fax: + 34 932279387
e-mail: jpanes@clinic.ub.es

**Keywords**: Crohn's disease, imaging techniques, ultrasonography, computed tomography, magnetic resonance imaging, cross-sectional imaging, endoscopy.

For Peer Review

**Summary**

**Backgroud**: Cross-sectional imaging techniques, including ultrasonography (US), computed tomography (CT), and magnetic resonance imaging (MRI), are increasingly used for evaluation of Crohn's disease (CD).

**Aim**: To perform an assessment of the diagnostic accuracy of cross-sectional imaging techniques for diagnosis of CD, evaluation of disease extension and activity, and diagnosis of complications, and to provide recommendations for their optimal use.

**Methods**: Relevant publications were identified by literature search, and selected based on predefined quality parameters, including a prospective design, sample size and reference standard. 68 publications were chosen.

**Results**: US is an accurate technique for diagnosis of suspected CD and for evaluation of disease activity (sensitivity 0.84, specificity 0.92), is widely available and non-invasive, but its accuracy is lower for disease proximal to the terminal ileum. MRI has a high diagnostic accuracy for the diagnosis of suspected CD, and for evaluation of disease extension and activity (Sensitivity 0.93, specificity 0.90), and is less dependent on the examiner and disease location compared with US. CT has a similar accuracy to MRI for assessment of disease extension and activity. The three techniques have a high accuracy for identification of fistulas, abscesses and stenosis (sensitivities and specificities>0.80), although US has false positive results for abscesses. Due to the lack of radiation, US or MRI should be preferred over CT, particularly in young patients.

**Conclusion**: Cross sectional imaging techniques have a high accuracy for evaluation of suspected and established CD, reliably measure disease severity and complications, and may offer the possibility to monitor disease progression.


For Peer Review

## INTRODUCTION

Assessment of intestinal inflammatory lesions by imaging techniques is essential for management of patients with Crohn's disease (CD). Characterization of disease location and extension at the time of diagnosis is required to establish a proper management plan. Imaging techniques are also the accepted reference for detection of complications including strictures and penetrating lesions such as fistulas and abscesses. Recently, awareness of the shortcomings of mere clinical evaluation for assessment of disease activity has grown. Some patients with an established diagnosis of CD and symptoms compatible with a disease flare do not have evidence of active CD by laboratory, endoscopic, and radiologic criteria. In two large clinical trials, 18% of patients with CD and moderate-to-severe clinical symptoms had no evidence of ulceration at ileocolonoscopy [1, 2]. On the other hand, a sizable proportion of patients with established CD may have persistent severe lesions in the absence of symptoms [3] and persistence of lesions is associated with higher requirements for hospitalization and surgeries [4]. Therefore, objective assessment of inflammatory lesions is required for guiding therapeutic interventions and for assessing the efficacy of these interventions.

Ileocolonoscopy has been the gold standard for evaluation of lesions in the colon and terminal ileum. However, ileocolonoscopy cannot always be complete, and there are several drawbacks related to the invasiveness, procedure-related discomfort, risk of bowel perforation, and relatively poor patient acceptance. Over the last few years, cross-sectional imaging techniques, including ultrasonography (US), computed tomography (CT), and magnetic resonance imaging (MRI), have been increasingly used for evaluation of patients with CD. The choice between imaging techniques is often determined by local availability and expertise, and technical details of these examinations are also subject to considerable variation, which may affect accuracy.

The purpose of the present review was to provide an objective assessment of the diagnostic accuracy of cross-sectional imaging techniques in three different scenarios: 1) for diagnosis of

For Peer Review

CD; 2) for assessment of disease extension and activity; and 3) for diagnosis of complications. Recommendations on the use of imaging techniques provided in this review are based on an analysis of published evidence selected according to quality criteria, performed by six gastroenterologists with experience in inflammatory bowel disease (IBD) and five radiologists with experience in the use of US, CT, and MRI in CD.

**SEARCH STRATEGY AND STUDY SELECTION**

A comprehensive literature search was undertaken to identify all relevant citations. The electronic search strategy involved keyword searches of MEDLINE and EMBASE. The electronic search was supplemented by manually reviewing the reference lists of included studies as well as relevant review articles. Literature search comprised the period from January 1994 to December2010 and the following search criteria were used (all fields): ("Crohn Disease" OR "Crohn's" OR "inflammatory bowel disease") AND ("ultrasound" OR "ultrasonography" OR "sonography" OR "computed tomography" OR "CT scan", OR "Helical CT", OR "CT enterography" OR "magnetic resonance" OR "magnetic resonance imaging" OR "MRI" OR "MR"). References from the articles so selected were also examined in search of additional studies meeting inclusion criteria.

Five reviewers (BM, TR, RB, SQ, and JR) independently assessed the eligibility of the articles for inclusion. The search yielded a total of 1408 articles, of which 169 were found to be eligible and retrieved as full-text articles for conspicuous analysis (Figure 1).

The final selection of the articles was performed according to the following criteria: 1) 15 or more patients were included; 2) US and/or CT and/or MRI were used to diagnose CD, for assessment of disease extension and/or activity, or for assessing CD-related complications; 3) Adequate reference standard, including ileocolonoscopy, capsule endoscopy, enteroscopy, or surgical or pathological findings for evaluating small and large bowel, 4) Prospective design;

For Peer Review

and 5) Data reported to allow calculation of sensitivity, specificity, accuracy, or correlation values (in the case of disease severity). Articles published in any language were included. All studies fulfilling the selection criteria were included in the systematic review, without performing any additional formal quality assessment[5-9]. Disagreements between the reviewers regarding study inclusion were resolved by consensus of all authors. Following those criteria, 68 articles fulfilling all inclusion criteria were finally included in the analysis. For each of these studies, the following variables were extracted in a predefined data extraction form: author, publication year, number of patients included, population (adult or children), open or blinded design, gold standard (ileocolonoscopy, small-bowel capsule endoscopy [SBCE], or surgery), number of patients positive and negative for the variable examined, sensitivity, and specificity. The mean sensitivity and specificity was calculated and expressed as weighted mean (and corresponding 95% confidence interval [CI]) to make allowances for the number of patients included in each study. Sensitivity and specificity estimates were calculated on per-patient and per-bowel-segment bases (when available), because information about the capability of a given test in localizing disease and determining the extent of disease, in addition to its capability in diagnosing disease, can be obtained from segmental data. This separate calculation is relevant, as analysis on a per-patient basis probably leads to overestimation of sensitivity values, because any patient with disease is considered to have true-positive findings without considering whether the localization of disease is correct or not [10].

The evidence level (EL) and grade of recommendation (GR) were graded according to the Oxford Centre for Evidence-Based Medicine (http://www.cebm.net/index.aspx?o=1025).

**ACCURACY OF IMAGING TECHNIQUES IN THE DIAGNOSIS OF CD**

For this section studies were considered only if they included patients with suspected CD; when both suspected and established CD were reported, the studies were only selected if

For Peer Review

accuracy results were available for suspected CD alone. Studies including only patients with established CD were excluded. A summary of the studies included in this section and its main characteristics is provided in table 1.

**STATEMENT-1**

-US is an accurate technique for the initial diagnostic workout of patients with suspected CD, with the advantages of being widely available, non- invasive and free of ionizing radiation. [EL 2b, GR B]

-As the accuracy of US is highly dependent on factors such as experience level of the examining physician and location and severity of the disease, in patients with high suspicion of CD negative US findings should be confirmed with other diagnostic techniques. [EL2b GR C]

-Accuracy of CT for diagnosing of CD in patients with a suspected diagnosis has not been properly evaluated in prospective studies.

- MRI is an accurate technique for the diagnosis of suspected CD, with the advantage over US of being less dependent on the examinator and disease location. [EL2b GR B]

-The accuracy of cross-sectional imaging techniques for the diagnosis of CD is dependent on disease severity, and is inferior to endoscopy for detection of mild lesions. Cross-sectional imaging techniques allow identification of transmural CD and extraluminal lesions, which cannot be assessed by endoscopic methods. [EL 2b GR B]

**Accuracy of US in the diagnosis of CD**

Five studies including a total of 1029 patients with suspected CD were identified[11-15]. The overall per-patient sensitivity of US for the diagnosis of CD calculated from all studies included (Table 1) was 85% (95% CI 83% - 87%). Overall per patient specificity derived from studies reporting this data was 98% (95% CI 95% - 99%)[13, 15].

Diagnosis of CD was based mainly on the measurement of bowel wall thickness in all studies. Most studies considered a bowel wall thickness of 4 mm or higher to be a pathologic finding[11, 12, 14, 15]. Other US findings considered to be significantly associated with a diagnosis of CD by the majority of authors include decreased compressibility of thickened bowel walls, narrowing

of the lumen, conglomeration of loops, and extramural lesions such as fistulas or abscesses[12, 14, 16].

Disease location and disease activity are the main factors influencing the accuracy of US for the diagnosis of CD[11-14]. When sensitivity was estimated based on disease location, the highest values were found for anatomic areas easily accessible by US, such as the terminal ileum and left colon, whereas the accuracy was fairly low for less accessible locations, such as the rectum and upper small bowel[14]. Moderate heterogeneity was found among the sensitivities reported by the studies included[11-15]. Differences in the resolution of ultrasonic units, the cut-off value for bowel wall thickness, and the experience of sonographers may explain, at least in part, the differences in terms of accuracy between these studies.

Overall, the results show that US is an accurate technique to detect bowel wall abnormalities as an initial approach in patients with suspected CD, with the advantages of being a widely available, minimally invasive, and a ionizing radiation-free tool.

**Accuracy of CT in the diagnosis of CD**

No studies fulfilling all inclusion criteria were identified evaluating the accuracy of CT in the diagnosis of patients with suspected CD.

**Accuracy of MRI in the diagnosis of CD**

The accuracy of MRI in the diagnostic workout of patients with suscepted CD was evaluated in four studies fulfilling the inclusion criteria (Table 1).[11, 17-19] Overall per-patient sensitivity and specificity of MRI for the diagnosis of CD, calculated from included studies, which are detailed in Table 1, were 78% (95% CI 67% - 84%) and 85% (95% CI 76% - 90%), respectively.

As with US, in addition to wall thickness, consideration of other changes that are associated with disease activity such as wall enhancement after injection of MRI contrast, and presence of edema, increase the sensitivity of MRI for diagnosing CD[17-19]. Some technical aspects, in

For Peer Review

particular distension of the bowel and use of a luminal contrast, may affect the accuracy of MRI for assessing changes associated with active disease such as wall thickening and enhancement of bowel wall after MRI contrast administration[20].

Some prospective studies have shown that SBCE may be more sensitive than MRI for establishing a diagnosis of small bowel CD[17]. Comparisons of the diagnostic yield of SBCE and MRI enteroclysis in the detection of small bowel lesions show that in patients with CD, SBCE is able to detect significantly more inflammatory lesions in the proximal and middle part of the small bowel in comparison to MR enteroclysis[21]. Nevertheless, SBCE and MRI could be complementary methods for diagnosing small bowel CD; some lesions missed by SBCE can be captured by MRI and vice-versa.[22]

**Comparison of US, CT, and MRI in the diagnosis of CD**

The only direct comparison of the diagnostic accuracy of cross-sectional imaging techniques including a reference standard was performed by Borthne et al. [11]. In this study, US and MRI were compared using ileocolonoscopy as reference standard in pediatric patients with suspected IBD. US showed higher sensitivity than MRI (93.3% vs. 81.8%), but the sample size was very small and most importantly, only the terminal ileum, the location with the highest accuracy for US, was examined. No studies were found comparing CT enteroclysis or enterography with US specifically in patients with suspected CD.

Horsthuis et al. assessed the accuracy of US, MRI, and CT in the diagnosis of IBD, as compared with a predefined reference standard in a meta-analysis including 33 studies[10]. Mean sensitivity estimates for the diagnosis of IBD (both CD and/or ulcerative colitis) on a per-patient basis were high and not significantly different between the three imaging modalities (89.7%, 93.0%, and 84.3% for US, MRI, and CT, respectively). Mean per-patient specificity estimates were 95.6% for US, 92.8% for MRI, and 95.1% for CT. Mean per-bowel-segment sensitivity estimates were lower: 73.5% for US, 70.4% for MRI, and 67.4% for CT. Mean per-

For Peer Review

bowel-segment specificity estimates were also similar: 92.9% for US, 94.0% for MRI, and 90.2% for CT. CT proved to be significantly less sensitive and specific compared with MRI, which in conjunction with the need to minimize radiation exposure makes the use of US or MRI preferable.

## ASSESSMENT OF DISEASE EXTENSION

**STATEMENT 2**

-Assessment of disease extension in the small bowel should be based on radiological imaging techniques. MRI and US have a high diagnostic accuracy for assessment of disease extension. Selection between MRI and US should be based on the anatomical location to be explored, local expertise, and availability. [EL 1b, RG A]

-For the assessment of jejunal and ileal lesions MRI is preferred over US for its higher sensitivity particularly for jejunal lesions. [EL 2b, RG B]

-Assessment of disease extension in the colon and terminal ileum should be based on endoscopy, and completed with imaging techniques in cases of incomplete procedures. [EL 1b, RG A]

-US and MRI can be used as imaging methods for disease extension in the terminal ileum and colon. Higher availability and tolerance may render US a preferred technique. [EL 1b, RG A].

-Indirect evidence suggests a similar diagnostic accuracy for CT, but radiation exposure is a limitation for repeated use of this technique. [EL 5, RG D]

### Location and extension of active CD with US

Eight studies compared the accuracy of US with other imaging techniques and/or endoscopy and/or surgery in localizing CD lesions (Table 2)[14, 23-29]. The sensitivity of US for diagnosis of

location ranged from 74% to 96%, with specificity ranging between 80% and 100%. Pooled results of these studies show a sensitivity of 86%(95% CI 83% - 88%) and specificity of 94% (95% CI 93% -, 95%).

The addition of an oral non-absorbable solution (bowel hydrosonography) results in an increase in the sensitivity of US for the detection of segments with active disease [26]. Also, the use of a luminal contrast in the colon (hydrocolonic sonography) provides a high accuracy for assessing colonic CD lesions [23].

**Location and extension of active CD with CT**

The accuracy of CT for assessment of CD extension has been evaluated in only one prospective study with adequate reference standard, showing a high sensitivity (88%) and specificity (88%). However, the sensitivity for detection of lesions in colonic segments, particularly in the ascending colon (38%) was significantly lower than for the ileum (81%), which may be related to the lack of endoluminal contrast.[30]

**Location and extension of active CD with MRI**

Three studies assessed disease extension in the colon and ileum[27, 30, 31] obtaining a sensitivity of 38-88% and specificity of 88-90%. In two other studies evaluating the accuracy of MRI only in the proximal small bowel, the technique correctly categorized disease extension in most patients[17, 22]. The sensitivity of MRI for evaluating the extent of CD lesions in the small bowel was 74% (95% CI 768% - 80%) and the specificity 91% (95% CI 86% - 95%)[17, 22](Table 2).

**Comparison of different cross-sectional imaging techniques for assessment of disease extension in CD**

US seems to have a superior overall accuracy for the detection of disease localized in the terminal ileum and colon, except for the rectum, and MRI has superior accuracy compared with US for the detection of lesions in the jejunum and more proximal ileum (89% versus

For Peer Review

73%)[27]. Direct comparison of CT and MRI for assessment of location and extension of inflammatory lesions demonstrated a similar diagnostic accuracy.[30]

## ASSESSMENT OF DISEASE ACTIVITY AND SEVERITY

**STATEMENT 3**

-US has a high diagnostic accuracy for assessment of disease activity in the terminal ileum and colon [EL 1b, RG A]. MRI may achieve a similar sensitivity if adequate luminal distension is achieved. [EL 1b, RG A]

-CT can also be used to assess activity in the terminal ileum as accuracy is similar to other diagnostic techniques for this location [EL 1b, RG A]. Information is insufficient for determining accuracy of CT for colonic disease.

-US, MRI and CT have a higher accuracy for assessing disease activity in terminal ileum than barium contrast studies. [EL 1b, RG A]

-Due to lack of radiation US or MRI should be preferred over CT for evaluation of disease activity and severity, particularly in young patients. [EL 5, RG D]

### Assessment of disease activity

*Assessment of disease activity with US*

Six studies assessed the presence of active disease in a total of 207 CD patients (Table 3)[23, 28, 32-35].The sensitivity of US for the detection of disease activity ranged from 63% to 100%, with specificity in the range of 77% to 100%. Overall sensitivity was 85% (95% CI 79% - 89%) and specificity 91% (95% CI 87% - 95%).

Three studies used Doppler US for the detection of active disease, showing that wall thickness and the angiographic vascularization pattern (Figure 2) are useful for the detection of active disease[16, 25, 34]. To date, one study evaluated the accuracy of contrast-enhanced US for

assessment of activity in CD, showing that the technique has a high sensitivity (93%, [95% CI 88% - 97%]) and specificity (94%, [95% CI 88% - 97%]) [34]. The comparison of the diagnostic accuracy of conventional US, Doppler US and contrast-enhanced US for assessment of disease activity, showed that the sensitivity of the three modalities of examination (93.7%, 93.7% and 93.7%) and specificity (96.5%, 96.5% and 96.6%) were virtually identical [34].

*Assessment of disease activity with CT*

The diagnostic value of CT for distinguishing quiescent from active CD affecting only the terminal ileum was determined in eight studies (Table 3)[30, 36-42], including a total of 216 patients with CD. The sensitivity of CT for the detection of disease activity in the terminal ileum ranged from 60% to 95%, with specificity ranging from 50% to 100%. Overall sensitivity was 81% (95% CI 77% - 86%) and specificity 88% (95% CI 82% - 91%). The lowest sensitivity for the detection of colonic lesions was obtained in the study not using luminal contrast[30].

*Assessment of disease activity with MRI*

Sixteen studies have evaluated the accuracy of MRI in the assessment of activity in the terminal ileum and/or the colon (Table 3)[18, 30, 33, 37, 40, 42-52]. Six of these studies [18, 30, 33, 45, 48, 49] provide results on a per patient basis including a total of 217 patients, 11 studies provide results on a per segment basis[37, 40, 42-47, 50-52], in three of these only one segment, the terminal ileum, was studied[37, 40, 43]; a total of 1629 segments were assessed in all these studies. Pooled results of studies determining accuracy of MRI for assessment of disease activity on a per patient basis show a sensitivity of 80% (95% CI 77% - 83%), and specificity of 82% (95% CI 78% - 85%) whereas pooled results of studies reporting on a per segment basis showed a sensitivity of 70% (95% CI 67% - 73%) and specificity of 89% (95% CI 93% - 96%). In general studies using luminal negative contrast show a higher accuracy for assessment of disease activity (Figure 3), and one study assessing the value of diffusion weighted sequences showed also a low sensitivity for the detection of colonic CD lesions in the absence of luminal contrast.[50]

For Peer Review

*Comparison of different imaging techniques for detection of activity in CD*

Four studies compared the sensitivities and specificities for CT and MRI [30, 37, 40, 42]. Three studies found a similar diagnostic accuracy for both techniques, and one study using helical CT (the other three studies used multidetector CT) showed a higher sensitivity and specificity for MRI [42]. Two studies compared the diagnostic accuracy of US and MRI to assess the presence of activity in the colon and terminal ileum[27, 33]. In these studies, the diagnostic accuracy of US was higher than that of MRI. Again, studies reporting low sensitivity for MRI are those that did not use luminal distension producing more false negative results.

**Assessment of disease severity**

**STATEMENT 4**

-A high correlation exists between the severity of intestinal lesions assessed by endoscopy and the intensity of US, MRI or CT changes. [EL 2b, RG B]

-A weak correlation exists between findings of cross-sectional imaging techniques and clinical activity indexes or biomarkers. [EL 1b, RG A]

-US, MRI or CT can be used in clinical practice for the assessment of disease severity. [EL 1b, RG A]

*Assessment of disease severity with US*

Twelve studies evaluated the relationship between US findings and disease severity assessed byendoscopy, small bowel enterography, clinical indexes of disease activity (Van Hess and CDAI), and biomarkers (C-reactive protein, platelet count, erythrocyte sedimentation rate) (Table 4)[14, 16, 23-25, 27, 29, 32, 34, 53-55]. Two studies found that bowel wall thickening was related to the severity of inflammation, as assessed by endoscopic examination and histopathologic analysis[32, 55]. Contrast-enhanced US could classify severity significantly better than Doppler-US signal and measurement of mural thickening ($P < 0.001$)[53]. In general, the magnitude of US

changes have a high correlation with endoscopic and histologic magnitude of alterations[16, 27, 53-55] and a weak correlation with indexes of clinical activity and biomarkers [14, 23-25, 27, 29, 32, 54].

*Assessment of disease severity with CT*

Two studies evaluated the value of CT for assessment of disease severity[36, 41]. One study found a significant correlation between the degree of enhancement and the severity of CD assessed by CDAI[36] that was not confirmed in the other study[41]. In the latter, significant correlations were observed between the intensity of various CT changes including wall thickening, enhancement, and presence lymphadenopathy and the severity of endoscopic lesions (Table 4).

*Assessment of disease severity with MRI*

Nine studies evaluated the accuracy of MRI in the assessment of disease severity in the colon and distal ileum [22, 27, 46-52], showing a good correlation with endoscopic findings, that was lower when the intestinal lumen was not distended[50, 51] (Table 4). Three studies derived an index of activity, one based on a qualitative evaluation of MRI findings including contrast enhancement, edema, wall thickening, ulceration (Figure4), presence of layered pattern, and diffusion hyperintensity[50], and two others by the same group of investigators calculating a quantitative index based on the first four variables [46, 52]. The later studies showed a higher correlation with the severity of CDEIS (r=0.80 and r=0.84) than the first one (r=0.54) although in addition to differences in derivation methodology, technical aspects may have influenced also the results. A formal validation study of a radiological-based index of severity has only been performed for MRI [52]

One study evaluated the diagnostic accuracy of MRI for assessing the severity of small bowel CD using SBCE as reference standard for evaluation of a total of 52 segments. MRI underestimated severity in 14% and revealed more severe pathology in 11.5%; in the

For Peer Review

remaining segments (75.5%) there was agreement between the two techniques[22]. The high accuracy of MRI for assessment of upper small bowel lesions is confirmed in a study using double balloon enteroscopy showing a correlation of 0.88 between an endoscopic and a MRI index of activity based on the same parameters used in the above mentioned studies.[51] The majority of studies found no correlation between MRI findings and indices of clinical activity or biomarkers [18, 27, 43, 44, 48, 49], and in three studies this correlation was weak [46, 50, 56].

*Comparison of different imaging techniques for assessment of severity in CD*

One single study compared the accuracy of MRI without luminal contrast and US in the evaluation of disease severity in the colon and terminal ileum using ileocolonoscopy as reference standard [27]. US showed a better correlation with endoscopic findings, ($r > 0.8$) than MRI ($r > 0.50$).

**Assessment of postsurgical recurrence**

**STATEMENT 5**

-US, CT and MRI are valid alternatives to ileocolonoscopy for assessing disease recurrence in patients who have undergone ileocolic resection. The degree of alterations in radiologic findings parallels the severity of endoscopic lesions.[EL 2b, RG B]

The summary of studies assessing the value of US, CT and MRI for assessment of postoperative disease recurrence is shown in Table 5. Four studies evaluated the accuracy of US for assessment of postsurgical recurrence[57-60], two using oral contrast [57, 59]; all used endoscopy as reference standard and the Rutgeerts' score to categorize severity. All studies showed a high accuracy of US for the diagnosis of postsurgical recurrence in CD, detecting almost all cases of severe or complicated recurrence, as well as a high sensitivity and specificity in differentiating mild from severe recurrence[57-60]. In one study, a direct comparison between US with and

For Peer Review

without oral contrast was performed, showing a mild increase in the sensitivity after giving oral contrast while specificity remained unchanged [59]

One study evaluated CT for detecting anastomotic recurrence, showing high sensitivity, specificity, and accuracy in the evaluation of relapse of ileocolic anastomosis[61].

Five published studies assessing the accuracy of MRI included operated patients [33, 45, 48, 62, 63], but only one allowed objective analysis of the results in this subgroup [63]. The correlation for the assessment of activity between endoscopy (Rutgeerts' score) and MRI and differentiation between mild and severe lesions was considered very high (k coefficient >0.8).(Table 5).

**Limitations of selected studies on disease extension, activity, and severity**

The main limitation for the assessment of the diagnostic accuracy of imaging techniques in the diagnosis of small bowel CD is the lack of an established reference standard. SBCE is currently the only technique that allows direct visualization of the whole small bowel. However, SBCE also has a series of limitations including the risk of retention due to strictures[17], the lack of validated diagnostic criteria for interpretation of the significance and severity of the lesions detected in the small bowel, and the fact that evaluation is limited to the surface of the intestinal mucosa, which may explain an apparent "over-rating" of disease activity/severity by MRI in some patients [22].

Another important limitation is the small sample size in the majority of studies and that most studies evaluated only the presence of active disease, without attempting to differentiate between mild and severe lesions, which is crucial for therapeutic decision-making.

In studies evaluating MRI, heterogeneous results may be related to the type of units (3 T vs. 1.5 T) and most importantly the use of luminal distension. Reporting the results on a per-patient or per-segment basis also has a significant effect in the assessment of diagnostic

For Peer Review

accuracy, which is always lower in the latter.

None of the studies analyzed the influence of concomitant medications as a covariate in the models to correlate radiologic findings and disease activity [8]. This omission may be of some importance, as, for example, steroids have been shown to reduce the diagnostic accuracy of scintigraphy[64].

**DIAGNOSIS OF COMPLICATIONS**

Colonoscopy and barium administration have been the principal means of evaluating CD patients due to their ability to depict bowel mucosa alterations and stenosis. However, these techniques are unable to show either the transmural inflammation or extraluminal complications that are characteristic of CD. The ability to demonstrate directly the bowel wall, the adjacent abdominal organs, mesentery, and retroperitoneum makes cross-sectional imaging techniques important diagnostic modalities for assessment of complications in CD.

**Detection of intraabdominal fistulas**

**STATEMENT6**

US, CT and MRI have a high sensitivity and specificity for the diagnosis of intraabdominal fistulas, with similar diagnostic accuracies. [EL 2b, GR B]

Diagnostic accuracy of cross sectional imaging techniques (US, CT and MR) for diagnosis of fistulas is higher than that of SBFT, and should be preferred over the latter. [EL 2b, GR B]

Combinations SBFT with a cross sectional imaging modality may increase the diagnostic accuracy over either technique alone. [EL 2b, GR B]

Due to lack of radiation US or MR should be the preferred over CT for the detection of complications. Selection between MR and US will depend on local expertise and availability. [EL 5 GR D]

The diagnostic accuracy of US for the detection of fistulas (Figure 5) was assessed in four studies that included a total of 99 lesions affecting the small intestine or colon in 216 patients

For Peer Review

(Table 6)[25, 65-67]. The sensitivity of US for the diagnosis of fistulizing lesions ranged from 67% to 87%, with specificity in the range of 90% to 100%. Pooled results of the three studies showed a sensitivity of 74% (95% CI 67% - 79%), and specificity of 95% (95% CI 91% - 97%).

The diagnostic value of CT for diagnosing fistulas (Figure 6) was determined in seven studies that included a total of 79 lesions in 233 patients (Table 6)[30, 36, 37, 39, 65, 68, 69]. Five of these studies provided an appropriate reference standard for evaluation of extraenteric lesions such as surgery[30, 37, 39, 65, 69]. Sensitivity ranged from 20% to 100%, and specificity from 91% to 100%. Pooled results of the five studies with adequate reference standard, showed a sensitivity of CT for the diagnosis of fistulas of 70% (95% CI 64%, 76%), and specificity of 97% (95% CI 94% - 99%).

The diagnostic value of MRI for diagnosing intraabdominal fistulas was determined in five studies that included a total of 51 lesions in 210 patients (Table 6)[18, 25, 30, 37, 56]. As in US and CT studies, the majority of lesions corresponded to enteroenteric fistulas. Four studies used a combination of diagnostic techniques, physical examination (enterocutaneous fistulas), and surgery as reference standard. In one study, no reference standard was provided[49]. The sensitivity of MRI for fistulizing lesions ranged from 40% to 100%, and specificity from 93% to 100%. Pooled results of the studies with adequate reference standard, showed a sensitivity of MRI for the diagnosis of fistulas of 76% (95% CI 71% - 82%), and specificity of 96% (95% CI 92% - 98%).

Various studies have compared the performance of different cross-sectional imaging modalities and small bowel enteroclysis. The accuracy of small bowel enteroclysis and US for the diagnosis of internal fistulas and abscesses complicating CD was compared in a study using surgery as reference standard, demonstrating that both techniques have the same accuracy for the detection of internal fistulas (85%)[65]. In the same study, CT was carried out in a subgroup of patients with suspicion of septic complications. In these patients, CT showed a

For Peer Review

sensitivity of 68% and a specificity of 91%. US had a sensitivity and specificity of 87% and 91%, whereas SBFT had a sensitivity of 74% and a specificity of 91%.

For the detection of internal fistulas, the combination of small bowel enteroclysis and US significantly improved diagnostic accuracy (small bowel enteroclysis 84%, US 85%, combination 91%). In the group of patients also undergoing CT examinations, the combination of US with small bowel enteroclysis and CT significantly improved sensitivity relative to CT or SBFT alone (97%, 68%, and 73% respectively), as well as overall accuracy [65].

In another study using a combination of endoscopy, barium studies, CT, and surgery as reference standard, 17 cases with enteroenteric fistulas were identified[25]. US and MRI detected 14 (82%) and 12 (70%) fistulas, respectively. The specificity and accuracy were 100% and 90%f or US and 92% and 80% for MRI.

A number of studies fulfilling the selection criteria of the current consensus have compared the diagnostic accuracy of CT and MRI for the detection of extraenteric complications. The study by Lee et al.[37] showed that CT and MRI enterography have a higher accuracy than SBFT to identify extraenteric complications of CD, including fistulas, sinus tracts, and abscesses; sensitivity values for the detection of extraenteric complications were significantly higher for CT and MR enterography (100% for both) than for SBFT (32%-37%). CT and MR enterography were equally accurate for the identification of extraenteric complications (sensitivity 100% for both). Another study by Fiorino et al. observed also a similar accuracy of CT and MRI for the detection of fistulas, although this particular study reported the lowest sensitivity of both techniques for this type of lesions[30].

A feasibility study to evaluate two CT enterography protocols (enterography and enteroclysis) in comparison with SBFT, terminal ileoscopy, and surgery (in selected cases), showed a higher sensitivity of CT for the detection of extraenteric findings of CD (fistulas and sinus tracts, in addition to abscesses or phlegmons) compared to SBFT[39].

For Peer Review

**Detection of abscesses**

**STATEMENT 7**

US, CT and MRI have a high sensitivity for the diagnosis of intraabdominal abscesses. Diagnostic accuracy of US is slightly lower than that of CT and MRI due to false positive cases. [EL 2b, GR B]

Systematic combination of cross sectional diagnostic modalities does not significantly improve the diagnostic accuracy for the detection of intraabdominal abscesses complicating CD, but CT or MRI may be used to confirm doubtful US lesions. [EL 5, GR D]

Cross sectional techniques have a lower sensitivity for the detection of deep abscesses (e.g. retrogastric, deep pelvis). [EL 2b, GR B]

For Peer Review

The value of US for the detection of abscesses has been assessed in three studies using surgery as reference standard, which included a total of 42lesions in 242patients (Table 6)[65, 66, 70]. The sensitivity of US for the diagnosis of abscesses ranged from 81% to 100%, with specificity in the range of 92% to 94%. Pooling the results of the three studies, the sensitivity was 84% (95% CI 79% - 88%), and specificity 93% (95% CI 89% - 95%). In the study by Gasche et al., intra-abdominal abscesses were correctly detected in 9/9 patients and excluded in 22/24 patients (sensitivity 100%, specificity 92%)[66]. Nevertheless, the apparently higher accuracy compared with other studies may be due, at least in part, to patient selection. It is widely recognized that certain anatomic areas are difficult to assess by US, in particular the stomach, the deep pelvic part of the sigmoid, and the rectum. Accordingly, in this study, the authors did not attempt to detect complications in these areas. However, one of the three unrecognized fistulas was an ileosigmoid tract. This finding indicates that not only the distal sigmoid, but also the deep pelvic part of the ileum, may not be visualized by US.

The diagnostic value of CT for diagnosing intraabdominal abscesses was determined in five studies that included a total of 39 lesions in 172 patients (Table 6)[36, 37, 39, 65, 69]. Four of these studies provided an appropriate reference standard for evaluation of extraenteric lesions [37, 39, 65, 69], and the other study used only endoscopy as reference standard [36]. The sensitivity ranged

from 87% to 100%, and specificity from 95% to 100%. Pooling the results of the four studies with adequate reference standard, the sensitivity of CT for the diagnosis of abscesses was 84% (95 CI 78% - 90%), and specificity 97% (95% CI 94% - 99%).

Four studies using MRI reported on the presence of intraabdominal abscesses, identifying 10 lesions in 109 cases (Table 6)[37, 48, 56, 71]. One study did not use an appropriate reference standard for the identification of extraenteric lesions [48]; in the remaining studies, lesions were confirmed at surgery in the majority of cases (8/10). The results of studies with adequate reference standard show a sensitivity of MRI for the detection of abscesses of 86% (95% CI79% - 91%), and a specificity of 93% (95% CI 88% - 97%).

A comparison of US and CT for the identification of abscesses in the study by Maconi et al. [65] shows that abscesses were correctly detected in a high and similar proportion of cases by means of US (90.9%) and CT (86.4%), although accuracy was higher for CT (92%) than for US (87%) because of false positive results in US studies. Both methods missed only deep abscesses: five by US in the entire series of patients (three interloop, one mesenteric, and one appendicular) and three by CT (two interloop and one mesenteric). The combination of CT and US did not significantly improve the diagnostic accuracy for detection of intraabdominal abscesses complicating CD. Wold et al. demonstrated that CT was more sensitive in the detection of abscesses or phlegmons than SBFT[39]. Among the four abscesses confirmed at surgery in 23 patients, three of the lesions were only demonstrated by CT.

**Detection of stenosis**

**STATEMENT 8**

US, CT and MRI have a high sensitivity and specificity for the diagnosis of stenosis affecting the large or small bowel. [EL 2b, GR B]

For US routine use of endoluminal contrast is not necessary. [EL 2b, GR C]

Diagnostic accuracy of MRI and CT is based on the use of luminal contrast. In partially obstructing stenosis enteroclysis may provide higher sensitivity than enterography for

For Peer Review

detection of lesions in the small bowel. [EL 2b, GR C]

Examination with a cross sectional imaging modality is necessary before SBCE to rule out significant stenotic lesions. [EL 2b, GR C]

US has demonstrated a high diagnostic accuracy for the detection of small bowel stenosis in three studies, all using surgery as reference standard, identifying 78 stenotic lesions in 156 patients[66, 67, 70](Table 6). The sensitivity of US for the diagnosis of stenosis ranged from 74% to 100%, with specificity in the range of 89% to 93%. Pooling the results of the three studies, the sensitivity was 79% (95% CI 71% - 84%), and specificity 92% (95% CI 87% - 96%)[66].

CT enterography or enteroclysis has been shown to have a high diagnostic accuracy for the diagnosis of small bowel stenosis in five studies evaluating 79 stenoses of the small or large bowel in 199 patients (Table 6)[30, 36, 38, 69, 72] In the four studies with adequate reference standard, the sensitivity of CT ranged from 85% to 93%, and the specificity was 100% [30, 38, 69, 72]. Pooling the results of the two studies, sensitivity was 89% (95% CI 83% - 94%), and specificity 99% (95% CI 97% - 100%).

Data derived from one of the CT studies suggest that use of a peroral contrast agent may have some limitations compared with nasojejunal intubation in the detection of small-bowel strictures, especially for partially obstructing strictures [73]. Therefore, direct volume challenge via nasojejunal catheter is probably a preferred method for the diagnosis of strictures of the small bowel in patients with CD.

Eight studies report on the value of MRI for the detection of stenosis in CD, identifying 89 lesions, the majority in the small bowel, in 239 patients (Table 6)[18, 22, 30, 48, 49, 56, 71, 74]. One study identified 7 patients with colonic stenoses at endoscopy, which were not assessed by MRI because this examination was applied only for assessment of the small bowel [37]. MRI sensitivity for detection of stenoses ranged from 75% to 100%, and specificity from 91% to 100%. Pooling the results of the seven studies with adequate reference standard, the

For Peer Review

sensitivity of MRI for diagnosis of stenosis was 89% (95% CI 84% - 92%), and specificity 94% (95% CI 90% - 96%).

One study comparing two methodologies of distension of the small bowel, enterography and enteroclysis, showed that bowel distension was also superior with enteroclysis, and that the latter had a higher sensitivity (86% vs. 100%) and specificity (93% vs. 100%) for the detection of stenoses [74]. The direct comparison of CT and MRI for diagnosis of stenosis in the study by Fiorino at al. showed also a similar sensitivity (85%vs 92%) and specificity (100% vs. 90%) for both techniques [30].

Three studies [22, 38, 72] indicate that small-bowel radiologic imaging, preferably CT enterography of MR enterography, is needed prior to SBCE in suspected or known CD patients due to the high frequency of asymptomatic stenoses, and because these techniques can also detect extraenteric complications.

**Limitations of selected studies on extraenteric CD complications**

The high prevalence of intestinal complications in studies using surgery as the reference standard incorporates a selection bias. Fistulas, strictures, and abscesses are present in a higher proportion of operated patients than in the general CD population. This may lead to overestimation of the specificity.

Comparisons of the diagnostic accuracy of various techniques across studies are also limited by factors related to the different definitions of lesions used. The definition of strictures has varied and includes the presence of severe luminal narrowing in regions of bowel wall thickening with or without prestenotic dilatation [66], identification of small bowel narrowing accompanied by prestenotic dilatation [30, 38], or a lesion causing narrowing of <1 cm[72]. The definition of fistulas also varies between studies[65, 66, 69].

It is important to establish a standard definition for each complication from a radiologic point

For Peer Review

of view and for each of the available techniques. Such a definition would make it possible to reach more accurate overall conclusions from various studies, since we could then be confident that all the investigators assessed the same type of complication. In this sense, the most recent literature allows for these definitions for lesions detected with US and CT; however, standard definitions are more difficult to find for MRI.

For Peer Review

**ACKNOWLEDGEMENT**

Medical writing assistance was provided by Juliane Weber and Anna Mett, of *in*Science Communications, a WoltersKluwer business. This assistance and logistics for development of this consensus was supported by Abbott Laboratories.

For Peer Review

**References**:

1. Colombel JF, Sandborn WJ, Reinisch W, et al. Infliximab, azathioprine, or combination therapy for Crohn's disease. *N Engl J Med* 2010;**362**(15):1383-1395.
2. Hanauer SB, Feagan BG, Lichtenstein GR, et al. Maintenance infliximab for Crohn's disease: the ACCENT I randomised trial. *Lancet* 2002;**359**(9317):1541-1549.
3. Lemann M, Mary JY, Colombel JF, et al. A randomized, double-blind, controlled withdrawal trial in Crohn's disease patients in long-term remission on azathioprine. *Gastroenterology* 2005;**128**(7):1812-1818.
4. Allez M, Lemann M, Bonnet J, Cattan P, Jian R, Modigliani R. Long term outcome of patients with active Crohn's disease exhibiting extensive and deep ulcerations at colonoscopy. *Am J Gastroenterol* 2002;**97**(4):947-53.
5. Baker ME, Walter J, Obuchowski NA, et al. Mural attenuation in normal small bowel and active inflammatory Crohn's disease on CT enterography: location, absolute attenuation, relative attenuation, and the effect of wall thickness. *AJR Am J Roentgenol* 2009;**192**(2):417-423.
6. Bodily KD, Fletcher JG, Solem CA, et al. Crohn Disease: mural attenuation and thickness at contrast-enhanced CT Enterography--correlation with endoscopic and histologic findings of inflammation. *Radiology* 2006;**238**(2):505-516.
7. Booya F, Fletcher JG, Huprich JE, et al. Active Crohn disease: CT findings and interobserver agreement for enteric phase CT enterography. *Radiology* 2006;**241**(3):787-795.
8. Colombel JF, Solem CA, Sandborn WJ, et al. Quantitative measurement and visual assessment of ileal Crohn's disease activity by computed tomography enterography: correlation with endoscopic severity and C reactive protein. *Gut* 2006;**55**(11):1561-1567.
9. Hara AK, Alam S, Heigh RI, Gurudu SR, Hentz JG, Leighton JA. Using CT enterography to monitor Crohn's disease activity: a preliminary study. *AJR Am J Roentgenol* 2008;**190**(6):1512-1516.
10. Horsthuis K, Bipat S, Bennink RJ, Stoker J. Inflammatory bowel disease diagnosed with US, MR, scintigraphy, and CT: meta-analysis of prospective studies. *Radiology* 2008;**247**(1):64-79.
11. Borthne AS, Abdelnoor M, Rugtveit J, Perminow G, Reiseter T, Klow NE. Bowel magnetic resonance imaging of pediatric patients with oral mannitol MRI compared to endoscopy and intestinal ultrasound. *Eur Radiol* 2006;**16**(1):207-214.
12. Hollerbach S, Geissler A, Schiegl H, et al. The accuracy of abdominal ultrasound in the assessment of bowel disorders. *Scand J Gastroenterol* 1998;**33**(11):1201-1208.
13. Astegiano M, Bresso F, Cammarota T, et al. Abdominal pain and bowel dysfunction: diagnostic role of intestinal ultrasound. *Eur J Gastroenterol Hepatol* 2001;**13**(8):927-931.
14. Parente F, Greco S, Molteni M, et al. Role of early ultrasound in detecting inflammatory intestinal disorders and identifying their anatomical location within the bowel. *Aliment Pharmacol Ther* 2003;**18**(10):1009-1016.
15. Bozkurt T, Richter F, Lux G. Ultrasonography as a primary diagnostic tool in patients with inflammatory disease and tumors of the small intestine and large bowel.

For Peer Review

*J Clin Ultrasound* 1994;**22**(2):85-91.
16. Neye H, Voderholzer W, Rickes S, Weber J, Wermke W, Lochs H. Evaluation of criteria for the activity of Crohn's disease by power Doppler sonography. *Dig Dis* 2004;**22**(1):67-72.
17. Albert JG, Martiny F, Krummenerl A, et al. Diagnosis of small bowel Crohn's disease: a prospective comparison of capsule endoscopy with magnetic resonance imaging and fluoroscopic enteroclysis. *Gut* 2005;**54**(12):1721-1727.
18. Pilleul F, Godefroy C, Yzebe-Beziat D, Dugougeat-Pilleul F, Lachaux A, Valette PJ. Magnetic resonance imaging in Crohn's disease. *Gastroenterol Clin Biol* 2005;**29**(8-9):803-808.
19. Horsthuis K, de Ridder L, Smets AM, et al. Magnetic resonance enterography for suspected inflammatory bowel disease in a pediatric population. *J Pediatr Gastroenterol Nutr* 2010;**51**(5):603-9.
20. Gourtsoyiannis NC, Papanikolaou N, Karantanas A. Magnetic resonance imaging evaluation of small intestinal Crohn's disease. *Best Pract Res Clin Gastroenterol* 2006;**20**(1):137-156.
21. Golder SK, Schreyer AG, Endlicher E, et al. Comparison of capsule endoscopy and magnetic resonance (MR) enteroclysis in suspected small bowel disease. *Int J Colorectal Dis* 2006;**21**(2):97-104.
22. Tillack C, Seiderer J, Brand S, et al. Correlation of magnetic resonance enteroclysis (MRE) and wireless capsule endoscopy (CE) in the diagnosis of small bowel lesions in Crohn's disease. *Inflamm Bowel Dis* 2008;**14**(9):1219-1228.
23. Bru C, Sans M, Defelitto MM, et al. Hydrocolonic sonography for evaluating inflammatory bowel disease. *AJR Am J Roentgenol* 2001;**177**(1):99-105.
24. Maconi G, Parente F, Bollani S, Cesana B, Bianchi Porro G. Abdominal ultrasound in the assessment of extent and activity of Crohn's disease: clinical significance and implication of bowel wall thickening. *Am J Gastroenterol* 1996;**91**(8):1604-1609.
25. Martinez MJ, Ripolles T, Paredes JM, Blanc E, Marti-Bonmati L. Assessment of the extension and the inflammatory activity in Crohn's disease: comparison of ultrasound and MRI. *Abdom Imaging* 2009;**34**(2):141-148.
26. Parente F, Greco S, Molteni M, et al. Oral contrast enhanced bowel ultrasonography in the assessment of small intestine Crohn's disease. A prospective comparison with conventional ultrasound, x ray studies, and ileocolonoscopy. *Gut* 2004;**53**(11):1652-1657.
27. Pascu M, Roznowski AB, Muller HP, Adler A, Wiedenmann B, Dignass AU. Clinical relevance of transabdominal ultrasonography and magnetic resonance imaging in patients with inflammatory bowel disease of the terminal ileum and large bowel. *Inflamm Bowel Dis* 2004;**10**(4):373-382.
28. Reimund JM, Jung-Chaigneau E, Chamouard P, Wittersheim C, Duclos B, Baumann R. [Diagnostic value of high resolution sonography in Crohn's disease and ulcerative colitis]. *Gastroenterol Clin Biol* 1999;**23**(6-7):740-746.
29. Parente F, Maconi G, Bollani S, et al. Bowel ultrasound in assessment of Crohn's disease and detection of related small bowel strictures: a prospective comparative study versus x ray and intraoperative findings. *Gut* 2002;**50**(4):490-495.
30. Fiorino G, Bonifacio C, Peyrin-Biroulet L, et al. Prospective comparison of

For Peer Review

computed tomography enterography and magnetic resonance enterography for assessment of disease activity and complications in ileocolonic Crohn's disease. *Inflamm Bowel Dis* 2010.

31. Low RN, Sebrechts CP, Politoske DA, et al. Crohn disease with endoscopic correlation: single-shot fast spin-echo and gadolinium-enhanced fat-suppressed spoiled gradient-echo MR imaging. *Radiology* 2002;**222**(3):652-660.

32. Bremner AR, Griffiths M, Argent JD, Fairhurst JJ, Beattie RM. Sonographic evaluation of inflammatory bowel disease: a prospective, blinded, comparative study. *Pediatr Radiol* 2006;**36**(9):947-953.

33. Miao YM, Koh DM, Amin Z, et al. Ultrasound and magnetic resonance imaging assessmentof active bowel segments in Crohn's disease. *Clin Radiol* 2002;**57**(10):913-918.

34. Migaleddu V, Scanu AM, Quaia E, et al. Contrast-enhanced ultrasonographic evaluation of inflammatory activity in Crohn's disease. *Gastroenterology* 2009;**137**(1):43-52.

35. Pradel JA, David XR, Taourel P, Djafari M, Veyrac M, Bruel JM. Sonographic assessment of the normal and abnormal bowel wall in nondiverticular ileitis and colitis. *Abdom Imaging* 1997;**22**(2):167-172.

36. Hassan C, Cerro P, Zullo A, Spina C, Morini S. Computed tomography enteroclysis in comparison with ileoscopy in patients with Crohn's disease. *Int J Colorectal Dis* 2003;**18**(2):121-125.

37. Lee SS, Kim AY, Yang SK, et al. Crohn disease of the small bowel: comparison of CT enterography, MR enterography, and small-bowel follow-through as diagnostic techniques. *Radiology* 2009;**251**(3):751-761.

38. Solem CA, Loftus EV, Jr., Fletcher JG, et al. Small-bowel imaging in Crohn's disease: a prospective, blinded, 4-way comparison trial. *Gastrointest Endosc* 2008;**68**(2):255-266.

39. Wold PB, Fletcher JG, Johnson CD, Sandborn WJ. Assessment of small bowel Crohn disease: noninvasive peroral CT enterography compared with other imaging methods and endoscopy--feasibility study. *Radiology* 2003;**229**(1):275-281.

40. Siddiki HA, Fidler JL, Fletcher JG, et al. Prospective comparison of state-of-the-art MR enterography and CT enterography in small-bowel Crohn's disease. *AJR Am J Roentgenol* 2009;**193**(1):113-121.

41. Andersen K, Vogt C, Blondin D, et al. Multi-detector CT-colonography in inflammatory bowel disease: prospective analysis of CT-findings to high-resolution video colonoscopy. *Eur J Radiol* 2006;**58**(1):140-6.

42. Low RN, Francis IR, Politoske D, Bennett M. Crohn's disease evaluation: comparison of contrast-enhanced MR imaging and single-phase helical CT scanning. *J Magn Reson Imaging* 2000;**11**(2):127-35.

43. Ochsenkuhn T, Herrmann K, Schoenberg SO, Reiser MF, Goke B, Sackmann M. Crohn disease of the small bowel proximal to the terminal ileum: detection by MR-enteroclysis. *Scand J Gastroenterol* 2004;**39**(10):953-960.

44. Neurath MF, Vehling D, Schunk K, et al. Noninvasive assessment of Crohn's disease activity: a comparison of 18F-fluorodeoxyglucose positron emission tomography, hydromagnetic resonance imaging, and granulocyte scintigraphy with labeled antibodies. *Am J Gastroenterol* 2002;**97**(8):1978-1985.

For Peer Review

45. Koh DM, Miao Y, Chinn RJ, et al. MR imaging evaluation of the activity of Crohn's disease. *AJR Am J Roentgenol* 2001;**177**(6):1325-1332.
46. Rimola J, Rodriguez S, Garcia-Bosch O, et al. Magnetic resonance for assessment of disease activity and severity in ileocolonic Crohn's disease. *Gut* 2009;**58**(8):1113-1120.
47. Schreyer AG, Golder S, Scheibl K, et al. Dark lumen magnetic resonance enteroclysis in combination with MRI colonography for whole bowel assessment in patients with Crohn's disease: first clinical experience. *Inflamm Bowel Dis* 2005;**11**(4):388-394.
48. Florie J, Horsthuis K, Hommes DW, et al. Magnetic resonance imaging compared with ileocolonoscopy in evaluating disease severity in Crohn's disease. *Clin Gastroenterol Hepatol* 2005;**3**(12):1221-1228.
49. van Gemert-Horsthuis K, Florie J, Hommes DW, et al. Feasibility of evaluating Crohn's disease activity at 3.0 Tesla. *J Magn Reson Imaging* 2006;**24**(2):340-348.
50. Oussalah A, Laurent V, Bruot O, et al. Diffusion-weighted magnetic resonance without bowel preparation for detecting colonic inflammation in inflammatory bowel disease. *Gut* 2010;**59**(8):1056-1065.
51. Hyun SB, Kitazume Y, Nagahori M, et al. Magnetic resonance enterocolonography is useful for simultaneous evaluation of small and large intestinal lesions in Crohn's disease. *Inflamm Bowel Dis* 2010.
52. Rimola J, Ordas I, Rodriguez S, et al. Magnetic resonance imaging for evaluation of Crohn's disease: Validation of parameters of severity and quantitative index of activity. *Inflamm Bowel Dis* 2010.
53. Ripolles T, Martinez MJ, Paredes JM, Blanc E, Flors L, Delgado F. Crohn disease: correlation of findings at contrast-enhanced US with severity at endoscopy. *Radiology* 2009;**253**(1):241-248.
54. Futagami Y, Haruma K, Hata J, et al. Development and validation of an ultrasonographic activity index of Crohn's disease. *Eur J Gastroenterol Hepatol* 1999;**11**(9):1007-1012.
55. Haber HP, Busch A, Ziebach R, Dette S, Ruck P, Stern M. Ultrasonographic findings correspond to clinical, endoscopic, and histologic findings in inflammatory bowel disease and other enterocolitides. *J Ultrasound Med* 2002;**21**(4):375-382.
56. Maccioni F, Bruni A, Viscido A, et al. MR imaging in patients with Crohn disease: value of T2- versus T1-weighted gadolinium-enhanced MR sequences with use of an oral superparamagnetic contrast agent. *Radiology* 2006;**238**(2):517-530.
57. Calabrese E, Petruzziello C, Onali S, et al. Severity of postoperative recurrence in Crohn's disease: correlation between endoscopic and sonographic findings. *Inflamm Bowel Dis* 2009;**15**(11):1635-1642.
58. Rispo A, Bucci L, Pesce G, et al. Bowel sonography for the diagnosis and grading of postsurgical recurrence of Crohn's disease. *Inflamm Bowel Dis* 2006;**12**(6):486-490.
59. Castiglione F, Bucci L, Pesce G, et al. Oral contrast-enhanced sonography for the diagnosis and grading of postsurgical recurrence of Crohn's disease. *Inflamm Bowel Dis* 2008;**14**(9):1240-5.
60. Paredes JM, Ripolles T, Cortes X, et al. Non-invasive diagnosis and grading of postsurgical endoscopic recurrence in Crohn's disease: usefulness of abdominal ultrasonography and (99m)Tc-hexamethylpropylene amineoxime-labelled leucocyte

For Peer Review

scintigraphy. *J Crohns Colitis* 2010;**4**(5):537-45.
61. Minordi LM, Vecchioli A, Poloni G, Guidi L, De Vitis I, Bonomo L. Enteroclysis CT and PEG-CT in patients with previous small-bowel surgical resection for Crohn's disease: CT findings and correlation with endoscopy. *Eur Radiol* 2009;**19**(10):2432-2440.
62. Girometti R, Zuiani C, Toso F, et al. MRI scoring system including dynamic motility evaluation in assessing the activity of Crohn's disease of the terminal ileum. *Acad Radiol* 2008;**15**(2):153-164.
63. Sailer J, Peloschek P, Reinisch W, Vogelsang H, Turetschek K, Schima W. Anastomotic recurrence of Crohn's disease after ileocolic resection: comparison of MR enteroclysis with endoscopy. *Eur Radiol* 2008;**18**(11):2512-2521.
64. Sans M, Fuster D, Llach J, et al. Optimization of technetium-99m-HMPAO leukocyte scintigraphy in evaluation of active inflammatory bowel disease. *Dig Dis Sci* 2000;**45**(9):1828-1835.
65. Maconi G, Sampietro GM, Parente F, et al. Contrast radiology, computed tomography and ultrasonography in detecting internal fistulas and intra-abdominal abscesses in Crohn's disease: a prospective comparative study. *Am J Gastroenterol* 2003;**98**(7):1545-1555.
66. Gasche C, Moser G, Turetschek K, Schober E, Moeschl P, Oberhuber G. Transabdominal bowel sonography for the detection of intestinal complications in Crohn's disease. *Gut* 1999;**44**(1):112-117.
67. Kohn A, Cerro P, Milite G, De Angelis E, Prantera C. Prospective evaluation of transabdominal bowel sonography in the diagnosis of intestinal obstruction in Crohn's disease: comparison with plain abdominal film and small bowel enteroclysis. *Inflamm Bowel Dis* 1999;**5**(3):153-7.
68. Hara AK, Leighton JA, Heigh RI, et al. Crohn disease of the small bowel: preliminary comparison among CT enterography, capsule endoscopy, small-bowel follow-through, and ileoscopy. *Radiology* 2006;**238**(1):128-134.
69. Turetschek K, Schober E, Wunderbaldinger P, et al. Findings at helical CT-enteroclysis in symptomatic patients with crohn disease: correlation with endoscopic and surgical findings. *J Comput Assist Tomogr* 2002;**26**(4):488-92.
70. Maconi G, Bollani S, Bianchi Porro G. Ultrasonographic detection of intestinal complications in Crohn's disease. *Dig Dis Sci* 1996;**41**(8):1643-8.
71. Magnano G, Granata C, Barabino A, et al. Polyethylene glycol and contrast-enhanced MRI of Crohn's disease in children: preliminary experience. *Pediatr Radiol* 2003;**33**(6):385-391.
72. Voderholzer WA, Beinhoelzl J, Rogalla P, et al. Small bowel involvement in Crohn's disease: a prospective comparison of wireless capsule endoscopy and computed tomography enteroclysis. *Gut* 2005;**54**(3):369-373.
73. Maglinte DD, Sandrasegaran K, Lappas JC, Chiorean M. CT Enteroclysis. *Radiology* 2007;**245**(3):661-671.
74. Negaard A, Paulsen V, Sandvik L, et al. A prospective randomized comparison between two MRI studies of the small bowel in Crohn's disease, the oral contrast method and MR enteroclysis. *Eur Radiol* 2007;**17**(9):2294-2301.

For Peer Review

## TABLES

**Table 1. Accuracy of cross sectional imaging in the diagnosis of Crohn's disease (CD) compared with endoscopy or surgical findings on a per-patient basis**

| Author | Patients n included/n confirmed | Population | Reference standard | Location evaluated | Sensitivity (%) | Specificity (%) |
|---|---|---|---|---|---|---|
| **Ultrasonography** | | | | | | |
| Bozkurt et al. 1994[15] | 46/31 | Adults | Endoscopy, barium, surgery | Small and large bowel | 75 | 100 |
| Hollerbach et al. 1998 [12] | 168/69 | Adults | Endoscopy (ileocolonoscopy, gastroscopy), enteroclysis, barium enema, CT, surgery | Small and large bowel | 84 | NA |
| Astergiano et al. 2001[13] | 313/61 | Adults | Endoscopy, radiologic procedures | Small and large bowel | 84 | 98 |
| Parente et al. 2003[14] | 487/NA | Adults | Endoscopy (ileocolonoscopy, gastroscopy, push-enteroscopy), SBE, barium enema, CT, surgery | Small and large bowel | 88 | NA |
| Borthne et al.2006 [11] | 15/NA | Children | Colonoscopy | Small and large bowel | 93 | NA |
| **Magnetic resonance imaging** | | | | | | |
| Albert et al. 2005 [17] | 25/14 | Adults | Ileocolonoscopy, WCE | Small bowel | 77 | 80 |
| Pilleul et al.2005 [18] | 15/6 | Children | Ileocolonoscopy | Small and large bowel | 83 | 100 |
| Borthne et al. 2006 [11] | 20/NA | Children | Colonoscopy | Small and large bowel | 82 | 100 |
| Horsthuis et al 2010[19] | 33/15 | Children | Endoscopy (ileocolonoscopy, gastroscopy), enteroclysis, clinic | Small and large bowel | 61-91%* | 60-90%* |

CT = computed tomography; SBE = small bowel enteroclysis; WCE = wireless-capsule endoscopy; NA not available; * Calculated by two observers.

For Peer Review

**Table 2. Accuracy of ultrasonography, computed tomography and magnetic resonance imaging in the assessment of disease extension in Crohn's disease**

| Author | Patients with CD n total / n active | Population | Reference standard | Location evaluated | Sensitivity (%) | Specificity (%) |
|---|---|---|---|---|---|---|
| **Ultrasonography** | | | | | | |
| Maconi et al. 1996 [24] | 115/NA | Adults | Ileocolonoscopy, barium contrast studies | Terminal ileum and colon | 89 | 94 |
| Reimund et al. 1999 [28] | 48/47 | Adults | Ileocolonoscopy, barium contrast studies | Terminal ileum and colon | 83 | 67 |
| Bru et al. 2001 [23] | 38/NA | Adults | Ileocolonoscopy | Terminal ileum and colon | 83 | 87 |
| Parente et al. 2002 [29] | 296/NA | Adults | Ileocolonoscopy, barium contrast studies (small bowel and barium enema) | Terminal ileum and colon | 93 | 97 |
| Parente et al. 2003 [14] | 273/NA | Adults | Endoscopy, barium contrast studies (small bowel and barium enema), CT, surgery | Terminal ileum and colon | 77 | 95 |
| Pascu et al. 2004 [27] | 37/NA | Adults | Ileocolonoscopy | Terminal ileum and colon | 74 | 97 |
| Parente et al. 2004 [26] | 102/NA | Adults | Ileocolonoscopy, barium enteroclysis | Small bowel | 96 | 98 |
| Martinez et al. 2009 [25] | 30 (segments 119/53) | Adults | Endoscopy, barium contrast studies (small bowel and barium enema), CT | Small bowel and colon | 91 | 98 |
| **Computed Tomography** | | | | | | |
| Fiorino et al. 2010 [30] | 44/28 | Adults | Ileocolonoscopy, surgery | Small bowel and colon | 88 | 88 |
| **Magnetic resonance imaging** | | | | | | |
| Low et al. 2002 [31] | 28/25 | Adults | Barium studies, high resolution endoscopy, surgery | Small bowel and colon | 86 | NA |

For Peer Review

| | | | | | | |
|---|---|---|---|---|---|---|
| Pascu et al. 2004 [27] | 37/NA | Adults | Ileocolonoscopy | Colon and terminal ileum | 38 | 90 |
| Albert et al. 2005 [17] | 52/30 | Adults | Capsule endoscopy | Small bowel | 85 | 100 |
| Tillack et al. 2008 [22] | 19/18 | Adults | Capsule endoscopy | Small bowel | 78 | 91 |
| Fiorino et al. 2010 [30] | 44/28 | Adults | Ileocolonoscopy, surgery | Small bowel and colon | 88 | 88 |

CT = computed tomography ; NA = not available

For Peer Review

**Table 3. Accuracy of ultrasonography, computed tomography, and magnetic resonance imaging in the assessment of disease activity in Crohn's disease**

| Author | Patients with CD n total / n active | Population | Reference standard | Location evaluated | Sensitivity (%) | Specificity (%) |
|---|---|---|---|---|---|---|
| **Ultrasonography** | | | | | | |
| Pradel et al. 1997 [35] | 19/18 | Adults | Ileocolonoscopy, barium contrast studies | Terminal ileum and colon | 63 | 90 |
| Reimund et al. 1999 [28] | 48/47 | Adults | Ileocolonoscopy, barium contrast studies | Terminal ileum and colon | 96 | NA |
| Bru et al. 2001 [23] | 38/NA | Adults | Ileocolonoscopy | Terminal ileum and colon | 100 | 82 |
| Miao et al. 2002 [33] | 30/23 | Adults | Ileocolonoscopy, barium contrast studies, surgery | Terminal ileum and colon | 87 | 100 |
| Bremner et al. 2006 [32] | 25/NA | Children | Ileocolonoscopy, barium contrast studies | Terminal ileum and colon | 48 | 98 |
| Migaleddu et al. 2009 [34] | 47/31 | Adults | Ileocolonoscopy, histology | Terminal ileum and colon | 90 (wall thickness)<br>90 (color Doppler)<br>93 (contrast-enhanced US) | 93 (wall thickness)<br>93 (color Doppler)<br>94 (contrast-enhanced US) |
| **Computed tomography** | | | | | | |
| Low et al. 2000[42] | 26/NA (segments 128/65) | Adults | Endoscopy (ileocolonoscopy, gastroscopy), enteroclysis, barium enema, surgery | Small and large bowel | 60-65 | 90-92 |
| Hassan et al. 2003 [36] | 30/30 | Adults | Ileocolonoscopy | Terminal ileum | 87 | 100 |
| Wold et al.2003 [39] | 23/13 | Adults | Ileoscolonoscopy | Terminal ileum | 77 | 90 |
| Andersen et al. 2006; [41] | 15/NA | Adults | Colonoscopy | Colon | 75 | 50 |
| Solem et al. 2008 [38] | 41/21 | Adults | Consensus panel | Small bowel | 82 | 89 |
| Lee et al. 2009 [37] | 30/18 | Adults | Ileoscolonoscopy | Terminal ileum | 89 | 80 |
| Siddiki et al.2009 [40] | 33/22 | Adults | Ileocolonoscopy | Terminal ileum | 95 | 88 |
| Fiorino et al. 2010 [30] | 44/28 | Adults | Ileocolonoscopy, surgery | Small bowel and colon | 86-90 | 91-100 |

For Peer Review

| | | | | | | |
|---|---|---|---|---|---|---|
| **Magnetic resonance imaging** | | | | | | |
| Low et al. 2000[42] | 26/NA (segments 193/65) | Adults | Endoscopy (ileocolonoscopy, gastroscopy), enteroclysis, barium enema, surgery | Small and large bowel | 80-85 | 91 |
| Koh et al. 2001 [45] | 30/7 (segments 124/30) | Adults | Ileocolonoscopy | Colon and terminal ileum | 91<br>59 | 71<br>93 |
| Miao et al. 2002 [33] | 30/23 | Adults | Ileocolonoscopy | Colon and terminal ileum | 87 | 71 |
| Neurath et al. 2002 [44] | 51/51 (segments 139/42) | Adults | Ileocolonoscopy, PET | Colon and terminal ileum | 67 | 93 |
| Ochsenkühn et al. 2004[43] | 25/18 | Adults | Ileocolonoscopy | Terminal Ileum | 88 | 85 |
| Pilleul et al. 2005 [18] | 62/23 | Children | Ileocolonoscopy | Colon and terminal ileum | 78 | 46 |
| Schreyer et al. 2005 [47] | 30/29 (segments 161/49) | Adults | Ileocolonoscopy | Colon and terminal ileum | 55 | 98 |
| Florie et al. 2005 [48] | 31/21 | Adults | Ileocolonoscopy | Colon and terminal ileum | 93 | 55 |
| vanGemert-Horsthuis et al. 2006 [49] | 20/16 | Adults | Ileocolonoscopy | Colon and terminal ileum | 100 | 100 |
| Lee et al. 2009 [37] | 30/18 | Adults | Ileocolonoscopy | Terminal ileum | 83 | 100 |
| Rimola et al. 2009 [46] | 50/35 (segments 218/83) | Adults | Ileocolonoscopy | Colon and terminal ileum | 81 | 89 |
| Siddiki et al. 2009 [40] | 30/21 | Adults | Ileocolonoscopy | Terminal ileum | 91 | 67 |
| Fiorino et al. 2010 [30] | 44/28 | Adults | Ileocolonoscopy, surgery | Small bowel and colon | 81-90 | 91-95 |
| Oussalah et al. 2010 [50] | 61/NA (segments 221/NA) | Adults | Ileocolonoscopy | Colon and terminal ileum | 58 | 84 |
| Hyun et al. 2010 [51] | 30 /20<br>230/64 | Adults | Ileocolonoscopy, capsule endoscopy | Small bowel<br>Colon | 86<br>62 | 93<br>95 |
| Rimola et al. 2010 [52] | 48/29 | Adults | Ileocolonoscopy | Small bowel<br>Colon | 87 | 87 |

For Peer Review

| | | |
|---|---|---|
| | (segments 258/115) | 36 |

NA: not available, PET: positron emission tomography

For Peer Review

**Table 4. Efficacy of ultrasonography, computed tomography, and magnetic resonance imaging in the assessment of disease severity in Crohn's disease**

| Author | Patients with CD n total / n active | Population | Reference standard | Location evaluated | Results |
|---|---|---|---|---|---|
| **Ultrasonography** | | | | | |
| Maconi et al. 1996 [24] | 115/NA | Adults | Ileocolonoscopy, barium contrast studies | Terminal ileum and colon | Low correlation between US and CDAI or biological markers |
| Futagami et al. 1999 [54] | 55/NA | Adults | Ileocolonoscopy, barium contrast studies | Small bowel and colon | Correlation between ultrasonographic activity index and endoscopic or barium contrast studies r=0.62<br>Correlation with CDAI r = 0.2 and biomarkers r=0.08 |
| Bru et al. 2001 [23] | 38/NA | Adults | Ileocolonoscopy | Terminal ileum and colon | Correlations between hydrocolonic sonographic activity index and Van Hess r = 0.72<br>Correlation with biomarkers r = 0.44 and r=0.55 |
| Haber et al. 2001 [55] | 26/NA (segments 164/104) | Children | Ileocolonoscopy, histology | Terminal ileum and colon | Correlations between US and endoscopic and histologic findings ($P < 0.0001$) |
| Parente et al. 2002 [29] | 296/NA | | Ileocolonoscopy, barium contrast studies (small bowel and barium enema) | Terminal ileum and colon | No significant correlation between US and CDAI (r < 0.6) |
| Parente et al. 2003 [14] | 487/NA | | Endoscopy, barium contrast studies (small bowel and barium enema), CT, surgery | Terminal ileum and colon | No correlation between US and CDAI r = 0.29 or CRP r = 0.17 |
| Pascu et al. 2004 [27] | 37/NA | | Ileocolonoscopy | Terminal ileum and colon | Correlations between US and endoscopic activity index r = 0.83<br>No significant correlation with CDAI or CRP |
| Neye et al. 2004 [16] | 22/NA (segments 126/70) | | Ileocolonoscopy, barium contrast studies, surgery | Terminal ileum and colon | High concordance of power Doppler US and endoscopy; K coefficient 0.91–0.71 |
| Bremner et al. 2006 [32] | 25/NA | Children | Ileocolonoscopy, barium contrast studies | Terminal ileum and colon | No significant correlation with superior mesenteric artery Doppler and disease severity |

For Peer Review

| | | | | | |
|---|---|---|---|---|---|
| Ripolles et al. 2009 [53] | 61/53 | Adults | Ileocolonoscopy | Terminal ileum and colon | Correlation between US (contrast-enhanced) and endoscopic severity *P* < 0.001 |
| Martinez et al. 2009 [25] | 30/NA (segments 119/53) | Adults | Endoscopy, barium contrast studies (small bowel and barium enema), CT | Small bowel and colon | Significant correlation between bowel wall thickness and CDAI and CRP (p<0.01) |
| Migaleddu et al. 2009 [34] | 47/31 | Adults | Ileocolonoscopy, histology | Terminal ileum and colon | Linear correlation coefficient for contrast-enhanced US, baseline US, and color Doppler US versus CDAI 0.74, 0.68, and 0.73, respectively |
| **Computed tomography** | | | | | |
| Hassan et al. 2003 [36] | 30/30 | Adults | Ileocolonoscopy | Terminal ileum | Correlation with CDAI (r = 0.81) |
| Andersen et al. 2006 [41] | 15/NA | Adults | Ileocolonoscopy, | Colon | Correlation enhancement – endoscopic inflammation (r=0.72) |
| **Magnetic resonance imaging** | | | | | |
| Pascu et al. 2004 [27] | 37/NA | Adults | Ileocolonoscopy | Colon and terminal ileum | Correlation between MRI index and endoscopic activity index r=0.344 (p=0.007) |
| Florie et al. 2005 [48] | 31/21 (segments 141/NA) | Adults | Ileocolonoscopy | Colon and terminal ileum | Correlation between MRI and endoscopic severity: 0.59 (observer 1) - 0.53 (observer 2) (p<0.001). |
| Schreyer et al. 2005 [47] | 30/29 | Adults | Ileocolonoscopy | Colon and terminal ileum | Distinction between mild-moderate and severe Sensitivity 69%, Specificity 99% |
| van Gemert-Horsthuis et al. 2006 [49] | 20/15 | Adults y | Ileocolonoscop | Colon and terminal ileum | Lack of correlation between MRI severity and endoscopic severity: r=0.4 (p=0.09) |
| Tillack et al. 2008 [22] | 19/18 (segments 40/NA) | Adults | Capsule endoscopy | Small bowel | Distinction between mild-moderate and severe: Sensitivity 58%, Specificity 77% |
| Rimola et al. 2009 [46] | 29/48 (segments 115/258) | Adults | Ileocolonoscopy | Colon and terminal ileum | Distinction between mild-moderate and severe Sensitivity 91%, Specificity 95% |

For Peer Review

| | | | | | |
|---|---|---|---|---|---|
| Oussalah et al. 2010 [50] | 61/NA (segments211/ NA) | Adults | Ileocolonoscopy | Colon and terminal ileum | Correlation between MRI index and endoscopic severity index r=0.659 (p<0.001) |
| Rimola et al. 2010 [52] | 48/NA (segments 158/115) | Adults | Ileocolonoscopy | Colon and terminal ileum | Distinction between mild-moderate and severe Sensitivity 92%, Specificity 92% Correlation between MRI index and endoscopic severity index r=0.84 (p<0.001) |
| Hyun et al. 2010 [51] | 30/20 | Adults | Ileocolonoscopy, double balloon enteroscopy | Small bowel and colon | Correlation between MRI index and endoscopic severity index r=0.85 (p<0.001) |

CDAI = CD Activity Index; CRP = C-reactive protein; CT = computed tomography; NA = not available.

For Peer Review

**Table 5. Accuracy of ultrasonography, computed tomography and Magnetic Resonance in the assessment of post-surgical recurrence in Crohn's disease (CD)**

| Author | Patients with CD n total / n active | Population | Radiologic technique | Reference standard | Sensitivity (%) | Specificity (%) |
|---|---|---|---|---|---|---|
| Rispo et al. 2006 [58] | 45/24 | Adults | Transabdominal US | Ileocolonoscopy | 79<br>Severe disease: 94 | 95<br>Severe disease: 100 |
| Sailer et al. 2008 [63] | 30/27 | Adults | MR enteroclysis | Ileo-colonic anastomosis | NA<br>Correlation with endoscopic severity r=0.67 (p<0.01) | NA |
| Castiglione et al. 2008[59] | 22/24 | Adults | Transabdominal US<br>Oral contrast Abdominal US | Ileocolonoscopy | 77<br>82 | 94<br>94 |
| Minordi et al. 2009 [61] | 34/32 | Adults | CT Enteroclysis | Ileocolonoscopy | 97 | 100 |
| Calabrese et al. 2009 [57] | 72/63 | Adults | Small intestine oral contrast US | Ileocolonoscopy | 92 | 20 |
| Paredes et al 2010 [60] | 26/33 | Adults | Transabdominal US:<br>- wall thickness<br>- Doppler US<br>- 1 or 2 of the above | Ileocolonoscopy | <br>80<br>80<br>86 | <br>77<br>67<br>67 |

NA = not available.

For Peer Review

**Table 6. Accuracy of ultrasonography, computed tomography, and magnetic resonance imaging in the assessment of complications in Crohn's disease (CD)**

| Author | Patients with CD | Reference standard | Complication (n) | Sensitivity (%) | Specificity (%) |
|---|---|---|---|---|---|
| **Ultrasonography** | | | | | |
| Maconi et al. 1996 [65] | 128 | Surgery | Fistula (56) | 71 | 96 |
| | | | Abscess (26) | 80 | 93 |
| Maconi et al. 1996; [70] | 98 | Endoscopy, barium radiology, computed tomography, surgery | Stenosis (40)<br>Abscess (6) | 75<br>83 | 93<br>94 |
| Gasche et al. 1999 [66] | 33 | Surgery | Stenosis (22)<br>Fístula (23)<br>Abscess (9) | 100<br>87<br>100 | 901<br>90<br>92 |
| Kohn et al. 1999; [67] | 25 | Surgery | Stenosis (16)<br>Fistula (3) | 75<br>67 | 89<br>95 |
| Martínez et al. 2009 [25] | 30 | Endoscopy, barium radiology, surgery | Fístula (17) | 82 | 100 |
| **Computed tomography** | | | | | |
| Turetschek et al. 2002 [69] | 28 | Endoscopy, surgery | Stenosis (21)<br>Fistula (14)<br>Abscess (3) | 90<br>100<br>100 | 100<br>100<br>100 |
| Maconi et al. al. 2003 [65] | 61 | Surgery | Fistula (38)<br>Abscess (22) | 68<br>86 | 91<br>95 |
| Hassan et al. 2003 [36] | 30 | Endoscopy | Stenosis (20)<br>Fistula (3)<br>Abscess (5) | NA | NA |
| Wold et al. 2003 [39] | 23 | Surgery, clinical examination | Fistula (6)<br>Abscess (4) | 100<br>100 | 100<br>100 |
| Voderholzer et al. 2005 [72] | 56 | Capsuleendoscopy, endoscopy | Stenosis (16) | 94 | 100 |
| Hara et al. 2006 [68] | 17 | Ileoscopy, capsule endoscopy, SBFT | Fistula (2) | NA | NA |
| Solem et al. 2008 [38] | 41 | Use of a consensus clinical diagnosis as the criterion standard | Stenosis (8) | 88 | 100 |

For Peer Review

| | | | | | |
|---|---|---|---|---|---|
| Lee et al. 2009 [37] | 30 | Endoscopy, SBFT, surgery | Fistula (11)<br>Abscess (5) | 100<br>100 | 100<br>100 |
| Fiorino et al. 2010 [30] | 44 | Endoscopy, surgery | Stenosis (14)<br>Fistula (5) | 85<br>20 | 100<br>100 |
| | | | | | |
| **Magnetic resonance imaging** | | | | | |
| Magnano et al. 2003 [71] | 22 | Endoscopy | Stenosis (8)<br>Abscess (1) | 87<br>NA | 92<br>NA |
| van Gemert-Horsthuis et al. 2005 [49] | 20 | Endoscopy | Stenosis (7) | 86 | 85 |
| Pilleul et al. 2005 [18] | 47 | US, surgery | Stenosis (8)<br>Fistula (9) | 100<br>100 | 100<br>100 |
| Florie et al. 2005 [48] | 31 | Endoscopy | Stenosis, fistula, abscess (8) | 75 | 90.9 |
| Maccioni et al. 2006 [56] | 59 | Endoscopy, CT, US, barium radiology, surgery | Stenosis (22)<br>Fistula (9)<br>Abscess (4) | 91<br>78<br>86 | 100<br>100<br>93 |
| Negaard et al. 2007 [74] | 35 | Endoscopy | Stenosis (9) | 86 | 93 |
| Tillack et al. 2008 [22] | 19 pacients (52segments) | Capsule endoscopy, endoscopy | Stenosis (22) | 82 | 93 |
| Martínez et al. 2009 [25] | 30 | Endoscopy, barium radiology, surgery | Fistula (17) | 71 | 92 |
| Lee et al. 2009 [37] | 30 | Endoscopy, barium radiology, surgery | Fistula (11)<br>Abscess (5) | 100<br>100 | 100<br>100 |
| Fiorino et al. 2010 [30] | 44 | Endoscopy, surgery | Stenosis (14)<br>Fistula (5) | 92<br>40 | 90<br>94 |

NA = not available.

For Peer Review

**FIGURE LEGENDS**

Figure 1: Flow chart for the selection of the studies included in this systematic revision.

Figure 2: Inflammatory changes in active Crohn's disease assessed by US. Abdominal US shows bowel wall thickening with moderate positive vascularity on Doppler. Surrounding perienteric fat has an increased echogenicity due to inflammatory changes.

Figure 3: Active Crohn's disease in the terminal ileum evaluated by MRI. Coronal T1 with fat-suppressed MR image obtained after intravenous contrast injection shows mural hyperenhancement and mural thickening on the distal ileum (arrow). Prominent engorged vasa recta in the mesentery (comb sign) is also identified (arrowheads).

Figure 4. Ulcerative lesions of large bowel in a patient with Crohn's disease. Ulcers appear at MRI (arrowheads in Figure a) as a deep depressions on the mucosal surface of the thickened bowel wall. Colonoscopy (Figure b) revealed deep ulcers in the colon surrounded by a markedly inflamed mucosa.

Figure 5. Fistulizing Crohn's disease. Abdominal ultrasonography shows a lineal communication between two thickened small bowel loops (SB) which contains air (arrow), corresponding to an entero-enteric fistula.

Figure 6. Fistulizing Crohn's disease. Abdominal CT scan in axial plane after iv contrast administration depicts a thickened ileal loop with ileo-cecal fistula and surrounding perientiec inflammatory changes (arrow). Posterior to the fistula a small abscess is observed (arrowhead).

For Peer Review

**TECHNICAL RECOMMENDATIONS ON THE USE OF CROSS SECTIONAL IMAGING FOR ASSESSMENT OF CROHN'S DISEASE**

**US for evaluation of CD**

Technical considerations

Evaluation of the bowel with US is a time-consuming procedure and should be done meticulously in order to examine all intestinal segments. Patients are submitted to an overnight fasting period to diminish peristaltic movements and the amount of intraluminal air.

US is a highly operator-dependent technique with a learning curve that demands training. It requires a relatively high skill level, as well as expertise, to achieve results comparable to those published in the literature.

An intestinal sonographic exam should include an initial grey-scale assessment of the following parameters: the location of the involved intestinal segment or segments on the basis of the measurement of wall thickness, wall stratification, creeping fat, mesenteric lymph nodes, and complications (strictures and penetrating lesions).

Except for particular cases, sonography of the intestinal tract does not require any specific preparation. A general survey of the abdomen should be performed with a 3–5 MHz convex array transducer, but in most cases high-resolution convex or linear probes (>5MHz) are indispensable for detailed examination of the bowel wall and surrounding mesentery. The graded compression technique is used to displace adjacent bowel loops and isolate involved loops [75].

For color Doppler studies, technical parameters must be adjusted for maximum sensitivity, using a special preset designed for the detection of low-velocity flow in the bowel wall. Using

For Peer Review

color Doppler, the vascularity of the bowel wall can be assessed according to semiquantitative measurements of the intensity of color signals. In cases of uncertain interpretation, pulsed Doppler may be used to confirm that signals originated from blood vessels and not from motion artifacts. The use of color Doppler may provide additional information on the severity of the disease[16].

Oral contrast

Higher accuracy is obtained when enteral contrast medium is administered (hydrosonography), because it facilitates the detection of jejunal lesions, particularly mild lesions [26]. Polyethilenglicol solution at a dose ranging from 500 to 800mL has been proposed as an oral contrast medium for the study of the small bowel. Although the use of oral contrast increases the accuracy for detection of small bowel lesions by less experienced ultrasonographers[76], it is only recommended in cases of inconclusive examinations by conventional US due to its long preparation time. For colonic disease, the instillation of a water enema also increases accuracy [23].

Intravenous contrast

Contrast-enhanced US needs dedicated contrast-specific software on the US equipment to enable visualization of microbubble signals without fundamental grey-scale echoes. Contrast-enhanced US has several advantages over color Doppler sonography: curves of brightness-time analysis are more reproducible than semiquantitative measurements of the number of vessels, and motion artifacts produced by peristalsis or intestinal contents do not interfere with contrast-enhanced US, unlike color Doppler.

Quantitative measurements with contrast-enhanced US correlate with the severity of inflammatory activity shown at endoscopy[34, 53]. Contrast administration may be useful in distinguishing between phlegmons and abscesses [77].

For Peer Review

**CT for evaluation of CD**

Technical considerations

The improved resolution of multidetector CT (MDCT), combined with the use of enteric contrast agents to distend the bowel and intravenous contrast to highlight the bowel wall, has rendered CT an accepted method for the assessment of CD.

Currently, the maximum section thickness reconstruction recommended should be 3 mm [5, 9, 37, 68], although narrower thicknesses of 1.5 to 2.5 mm [6-8, 38-40, 61, 78-80] can be used.

Oral contrast

*CT enteroclysis and CT enterography*

Two main methods to achieve small bowel distention are used: CT enteroclysis and CT enterography. The purpose of both is to maximize small bowel distension, since subtle mucosal abnormalities may be missed in a collapsed loop, and inadequate distention may simulate wall thickening or abnormal enhancement [81].CT enteroclysis employs fluoroscopic placement of an 8- to 16-F nasojejunal tube, and the contrast material is administered through the catheter, whereas CT enterography uses the oral route to deliver large amounts of contrast (1500–2000 mL). Superior intestinal distension is achieved with CT enteroclysis, but this degree of distension may not be required to adequately assess the small bowel in most cases of CD [61, 73, 80, 82].CT enterography is often preferred due to its noninvasive nature and has gained acceptance as a first-line technique for studying the small bowel [6, 80, 81].

*Type of luminal contrast*

Patients should fast for at least 3 hours prior to the examination. The oral contrast medium should have minimal mucosal absorption and a high and homogeneous distension capability. The contrast medium of choice should be neutral (i.e., an attenuation value near to that of water), since it allows optimal distinction between luminal fluid and the contiguous enhanced

For Peer Review

bowel wall and increases the conspicuity of segmental mural hyperenhancement and mural stratification [78, 80]. The most commonly used luminal solutions for small bowel distension are osmotic sugars (such as mannitol and sorbitol), a combination of sorbitol and low-concentration barium solutions, and polyethilenglycol electrolyte solution. Water, although widely used, is not recommended, since it has a slow transit time and can be reabsorbed over the length of the small bowel. Solutions containing sorbitol or polyethyleneglycol can produce self-limited diarrhea, and it is necessary to advise patients of this adverse event [78]. Patients drink aliquots starting 45 or 60 minutes before CT, to achieve maximum ileal distension at the time of examination [78, 80].

Positive oral contrast agents should be used when patients cannot ingest large amounts of fluid or if there is a contraindication to the use of intravenous contrast (renal failure, iodine allergy, poor intravenous access) [81]. Some authors recommend an additional colonic enema with water immediately prior to CT data acquisition, thus improving the detection of disease in the colon [83].

<u>Intravenous contrast</u>

CT studies should be performed with non-ionic intravenous contrast administration using an automatic power injector. The minimum iodine concentration is 300 mg/mL[5-8, 38, 39, 80], although higher concentrations (up to 370 mg I/mL) can also be used [37, 68, 79, 84]. A total of 150 mL of contrast medium at rate of 3-5 mL/s should be administered [5, 6, 36, 37, 39, 61, 68], although the total volume should be tailored according to patient weight, iodine concentration and injection rate.

There is no ample agreement on the acquisition time: some authors carry out a biphasic study with enteric and portal venous phases [37, 39, 85] and others use a single enteric [7-9, 40, 61, 68, 79] or single portal venous phase [5, 6, 8, 38], with acquisition initiated 40–50s or 70s after initiating contrast injection. From a practical point of view, a single phase acquisition can be enough to evaluate the intestine, since a recent study showed no significant differences between enteric

For Peer Review

and portal venous phases regarding the identification of CD lesions [84].

Antispasmodic drugs

Prokinetic agents such as metoclopramide (usually 10 mg orally) to increase gastric and small bowel peristalsis can be used before CT enterography to favor progression of oral contrast and increase patient tolerance[6-8, 38, 39, 86].Antiperistaltic drugs can be administered intravenously during image acquisition to obtain homogeneous small-bowel distension and to reduce abdominal discomfort. The most commonly used drugs are N-butylhjoscine bromide (10–20 mg intravenously) [61] or glucagon (0.1–1 mg intravenously) [6-8, 38-40, 82, 85-87]. These agents are commonly used in CT enteroclysis[36, 61], although their use is not standard in CT enterography[37, 85].

Radiation dose

Concern has been raised about the associated risk of radiation-induced cancer from repeated CT and in particular about exposure in young patients.[88, 8990] The magnitude of these risks has been estimated indirectly by extrapolating from existing long-term studies of the effects of radiation exposure assuming a linear no-threshold model of risk from radiation exposure.[91] These models have been used to estimate the lifetime increased risk of cancer from one-time and repeated medical radiation exposure. While the linear no threshold model is the predominant theory, there is debate in the medical physics literature as to whether application of these studies to patients receiving diagnostic radiation, in particular of its application to radiation doses of less than 10 mSv, is appropriate.[92, 93]

It has been shown that patients with CD have many imaging studies over their lifetime, such as small bowel follow-through and CT scans of the abdomen and pelvis.[89] Patients diagnosed at an early age, those with upper gastrointestinal disease, penetrating disease, history of intravenous corticosteroid or infliximab use, and patients with multiple surgeries are at risk for

For Peer Review

higher doses of radiation accumulating over their lifetime.[88] The potential risk of CT-induced cancer related to cumulative low-dose radiation is a consideration in the choice of imaging modality for the diagnosis and monitoring of CD activity. Therefore, it has been suggested that techniques that eliminate or reduce radiation exposure should be favored.[89, 91]

**MRI for evaluation of CD**

Technical considerations

MRI studies of the small and large bowel should be performed in high-field MRI units. Phase array body coils should cover the total abdominopelvic area to ensure good visualization of the whole intestine. Several different pulse sequences are available for imaging the bowel. Currently 1.5 Tesla and 3 Tesla MRI equipments are available for clinical use. No formal comparison of the diagnostic accuracy of these two equipments for diagnosis of IBD has been performed, although the higher resolution of 3 Tesla equipments may increase the accuracy for detection of ulcers. Protocols for the study of CD most frequently include breath-hold T1- and T2-weighted imaging at least in two planes (axial and coronal).

T2-weighted sequences provide high contrast between the bowel wall and lumen and include fundamentally turbo spin-echo T2/single-shot turbo spin echo-sequences (HASTE) [37] and balanced gradient echo sequences (such as true fast imaging with steady-state precession [TrueFISP], fasting imaging employing steady-state acquisition [FIESTA], and fast-field echo [FFE]) [94]. The former provides information relative to the presence of mural edema and thickening of the bowel wall, and the latter better depict mesenteric vessels and lymph nodes. A fat suppression technique is strongly recommended for evaluation of edema and perienteric inflammatory changes.

T1-weighted gradient echo sequences with 3D acquisition allow thinner collimation and multiplanar reconstruction, but are more prone to artifact production and a decreased signal to noise ratio in comparison with 2D sequences. Fat saturation is also highly recommended to

For Peer Review

better assess bowel enhancement. Diffusion-weighted imaging MRI sequence has been proposed as an alternative to contrast enhanced MRI for assessment of inflammatory bowel disease providing a similar accuracy [50, 95]. Further studies are needed to test the accuracy of this sequence.

Oral contrast

Optimal distension is essential for the correct evaluation of inflammatory lesions of the bowel wall to avoid false positive or false negative interpretations. To that end, administration of luminal contrast with a non-absorbable agent is necessary. Two main methods to distend the small bowel are used: enteroclysis and enterography. MR enteroclysis is an invasive and time-consuming technique that requires intubation of the duodenum or proximal small bowel under fluoroscopy and the administration of enteric contrast agents. MR enterography techniques require the ingestion of a large amount of fluid. MR enterography is better tolerated than MR enteroclysis[96]. Some studies have shown that both modalities have equal sensitivity [74, 97] and specificity [10], suggesting that MR enterography can be used as a diagnostic and follow-up method in patients with CD.

Commonly used luminal solutions include osmotic sugars (such as mannitol or sorbitol) and polyethilenglycol electrolyte solution in case of enterography[11, 17, 71, 98]. Administration of water as a contrast agent is currently not recommended, because it is rapidly absorbed and does not achieve adequate distension of distal segments [99].

The volume of luminal oral contrast administered in case of enterography ranges between 1 and 1.5 L within 45–60 minutes prior to the examination and more than 2 L in case of enteroclysis[18, 46, 63].

Instillation of a rectal enema is the best choice to reach an adequate distension of the colon. Oral luminal contrast administration alone does not reach an optimal homogeneous distension of the whole colon. MR colonography with previous bowel cleansing is probably the current

For Peer Review

best choice to evaluate inflammatory changes in the colon using this imaging modality [46, 99, 100]. Administration of oral and rectal luminal contrast simultaneously allows for the evaluation of the small and large bowel in a single examination [47, 101].

Intravenous contrast

The use of intravenous contrast is essential, since hyperenhancement of the bowel wall improves the detection of segments with active inflammation in CD [31, 56]. Several acquisitions can be performed, with scanning beginning after a 45 s delay, although there is no consensus regarding the best time to acquire the images in dynamic sequences [31, 102].

Antispasmodic drugs

The reduction of peristalsis contributes to prevent motion artifacts and improve image quality. The most commonly used antispasmodic drugs are intravenous hyoscine-butylbromide (20 or 40 mg) or glucagon (1mg), which can be administered by intramuscular or intravenous routes. Because of the short-acting nature, some authors administer a split injection of an antispasmodic agent, one part immediately before the initial sequences to reduce intraluminal flow voids and a second part immediately before the injection of intravenous contrast[103].

For Peer Review

**Supplementary references**:

75. Puylaert JB. Acute appendicitis: US evaluation using graded compression. *Radiology* 1986;**158**(2):355-360.
76. Calabrese E, La Seta F, Buccellato A, et al. Crohn's disease: a comparative prospective study of transabdominal ultrasonography, small intestine contrast ultrasonography, and small bowel enema. *Inflamm Bowel Dis* 2005;**11**(2):139-145.
77. Esteban JM, Aleixandre A, Hurtado MJ, Maldonado L, Mora FJ, Nogues E. Contrast-enhanced power Doppler ultrasound in the diagnosis and follow-up of inflammatory abdominal masses in Crohn's disease. *Eur J Gastroenterol Hepatol* 2003;**15**(3):253-259.
78. Fletcher JG. CT enterography technique: theme and variations. *Abdom Imaging* 2009;**34**(3):283-288.
79. Hara AK, Swartz PG. CT enterography of Crohn's disease. *Abdom Imaging* 2009;**34**(3):289-295.

80. Paulsen SR, Huprich JE, Fletcher JG, et al. CT enterography as a diagnostic tool in evaluating small bowel disorders: review of clinical experience with over 700 cases. *Radiographics* 2006;**26**(3):641-657.
81. Tochetto S, Yaghmai V. CT enterography: concept, technique, and interpretation. *Radiol Clin North Am* 2009;**47**(1):117-132.
82. Macari M, Megibow AJ, Balthazar EJ. A pattern approach to the abnormal small bowel: observations at MDCT and CT enterography. *AJR Am J Roentgenol* 2007;**188**(5):1344-1355.
83. Schmidt S, Felley C, Meuwly JY, Schnyder P, Denys A. CT enteroclysis: technique and clinical applications. *Eur Radiol* 2006;**16**(3):648-660.
84. Vandenbroucke F, Mortele KJ, Tatli S, et al. Noninvasive Multidetector Computed Tomography Enterography in Patients with Small-Bowel Crohn's Disease: Is a 40-Second Delay Better than 70 Seconds? *Acta Radiol* 2007:1-9.
85. Megibow AJ, Babb JS, Hecht EM, et al. Evaluation of bowel distention and bowel wall appearance by using neutral oral contrast agent for multi-detector row CT. *Radiology* 2006;**238**(1):87-95.
86. Booya F, Akram S, Fletcher JG, et al. CT enterography and fistulizing Crohn's disease: clinical benefit and radiographic findings. *Abdom Imaging* 2009;**34**(4):467-475.
87. Schindera ST, Nelson RC, DeLong DM, et al. Multi-detector row CT of the small bowel: peak enhancement temporal window--initial experience. *Radiology* 2007;**243**(2):438-444.
88. Desmond AN, O'Regan K, Curran C, et al. Crohn's disease: factors associated with exposure to high levels of diagnostic radiation. *Gut* 2008;**57**(11):1524-1529.
89. Peloquin JM, Pardi DS, Sandborn WJ, et al. Diagnostic ionizing radiation exposure in a population-based cohort of patients with inflammatory bowel disease. *Am J Gastroenterol* 2008;**103**(8):2015-2022.
90. Hall EJ, Brenner DJ. Cancer risks from diagnostic radiology. *Br J Radiol* 2008;**81**(965):362-78.
91. Brenner DJ, Doll R, Goodhead DT, et al. Cancer risks attributable to low doses of ionizing radiation: assessing what we really know. *Proc Natl Acad Sci U S A* 2003;**100**(24):13761-6.
92. Tubiana M, Feinendegen LE, Yang C, Kaminski JM. The linear no-threshold relationship is inconsistent with radiation biologic and experimental data. *Radiology* 2009;**251**(1):13-22.
93. Jaffe TA, Gaca AM, Delaney S, et al. Radiation doses from small-bowel follow-through and abdominopelvic MDCT in Crohn's disease. *AJR Am J Roentgenol* 2007;**189**(5):1015-22.
94. Hohl C, Haage P, Krombach GA, et al. [Diagnostic evaluation of chronic inflammatory intestinal diseases in children and adolescents: MRI with true-FISP as new gold standard?]. *Rofo* 2005;**177**(6):856-863.
95. Kiryu S, Dodanuki K, Takao H, et al. Free-breathing diffusion-weighted imaging for the assessment of inflammatory activity in Crohn's disease. *J Magn Reson Imaging* 2009;**29**(4):880-886.
96. Negaard A, Sandvik L, Berstad AE, et al. MRI of the small bowel with oral contrast or nasojejunal intubation in Crohn's disease: randomized comparison of patient acceptance. *Scand J Gastroenterol* 2008;**43**(1):44-51.
97. Schreyer AG, Geissler A, Albrich H, et al. Abdominal MRI after enteroclysis or

For Peer Review

with oral contrast in patients with suspected or proven Crohn's disease. *Clin Gastroenterol Hepatol* 2004;**2**(6):491-497.
98. Lauenstein TC, Schneemann H, Vogt FM, Herborn CU, Ruhm SG, Debatin JF. Optimization of oral contrast agents for MR imaging of the small bowel. *Radiology* 2003;**228**(1):279-283.
99. Ajaj W, Goyen M, Schneemann H, et al. Oral contrast agents for small bowel distension in MRI: influence of the osmolarity for small bowel distention. *Eur Radiol* 2005;**15**(7):1400-1406.
100. Dinter DJ, Chakraborty A, Brade J, et al. Endoscopy and magnetic resonance imaging in patients with Crohn's disease: a retrospective single-centre comparative study. *Scand J Gastroenterol* 2008;**43**(2):207-216.
101. Narin B, Ajaj W, Gohde S, et al. Combined small and large bowel MR imaging in patients with Crohn's disease: a feasibility study. *Eur Radiol* 2004;**14**(9):1535-1542.
102. Florie J, Wasser MN, Arts-Cieslik K, Akkerman EM, Siersema PD, Stoker J. Dynamic contrast-enhanced MRI of the bowel wall for assessment of disease activity in Crohn's disease. *AJR Am J Roentgenol* 2006;**186**(5):1384-1392.
103. Fidler J. MR imaging of the small bowel. *Radiol Clin North Am* 2007;**45**(2):317-331.

For Peer Review

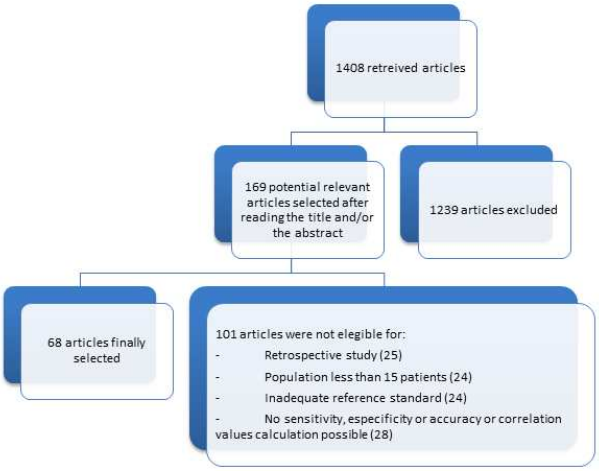


Flow chart for the selection of the studies included in this systematic revision.
254x190mm (96 x 96 DPI)

Review

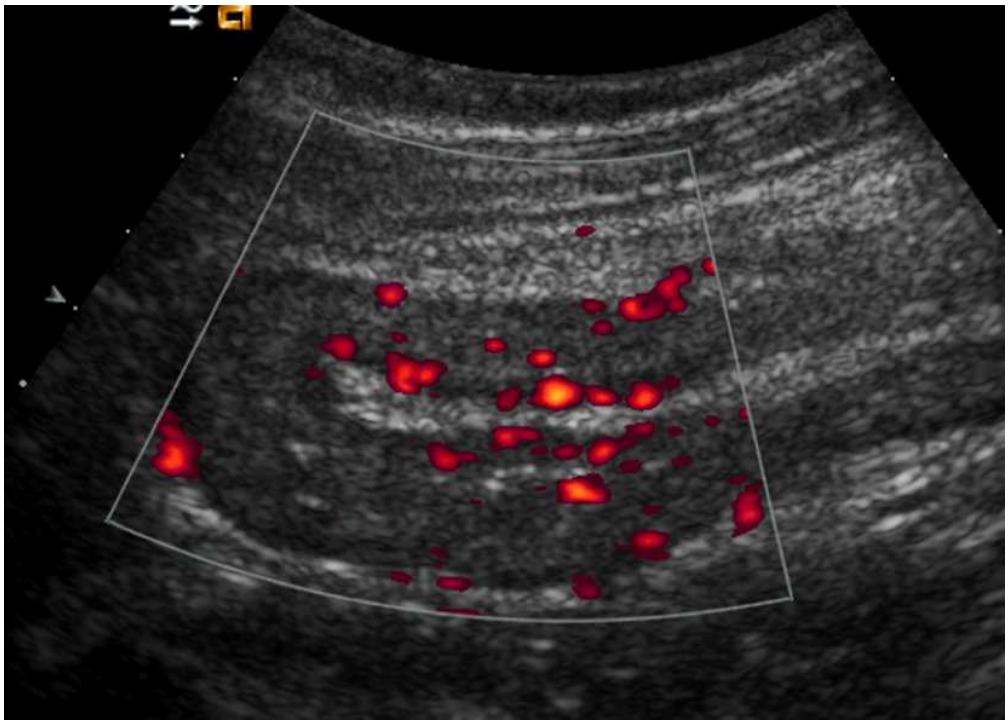

Inflammatory changes in active Crohn's disease assessed by US. Abdominal US shows bowel wall thickening with moderate positive vascularity on Doppler. Surrounding perienteric fat has an increased echogenicity due to inflammatory changes.
70x50mm (300 x 300 DPI)

Review

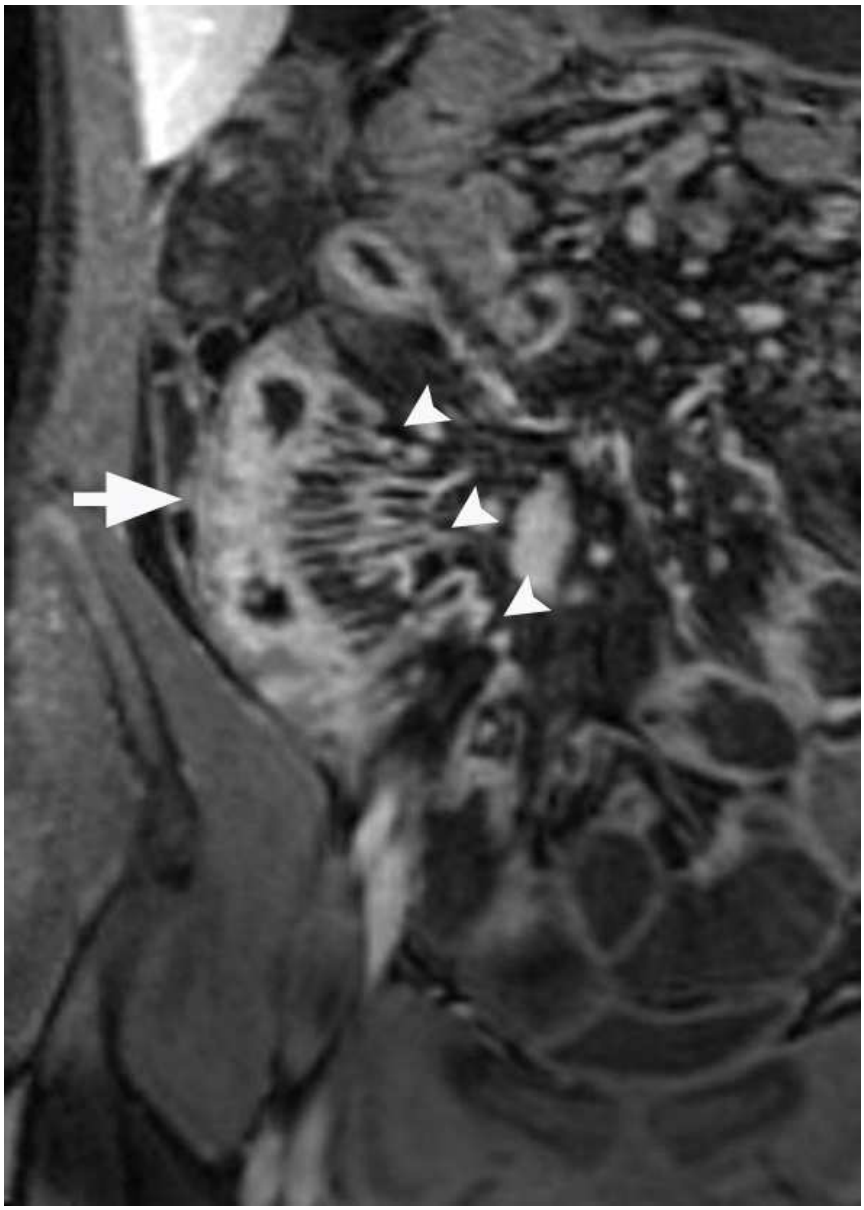

Active Crohn's disease in the terminal ileum evaluated by MRI. Coronal T1 with fat-suppressed MR image obtained after intravenous contrast injection shows mural hyperenhancement and mural thickening on the distal ileum (arrow). Prominent engorged vasa recta in the mesentery (comb sign) is also identified (arrowheads).
50x70mm (300 x 300 DPI)

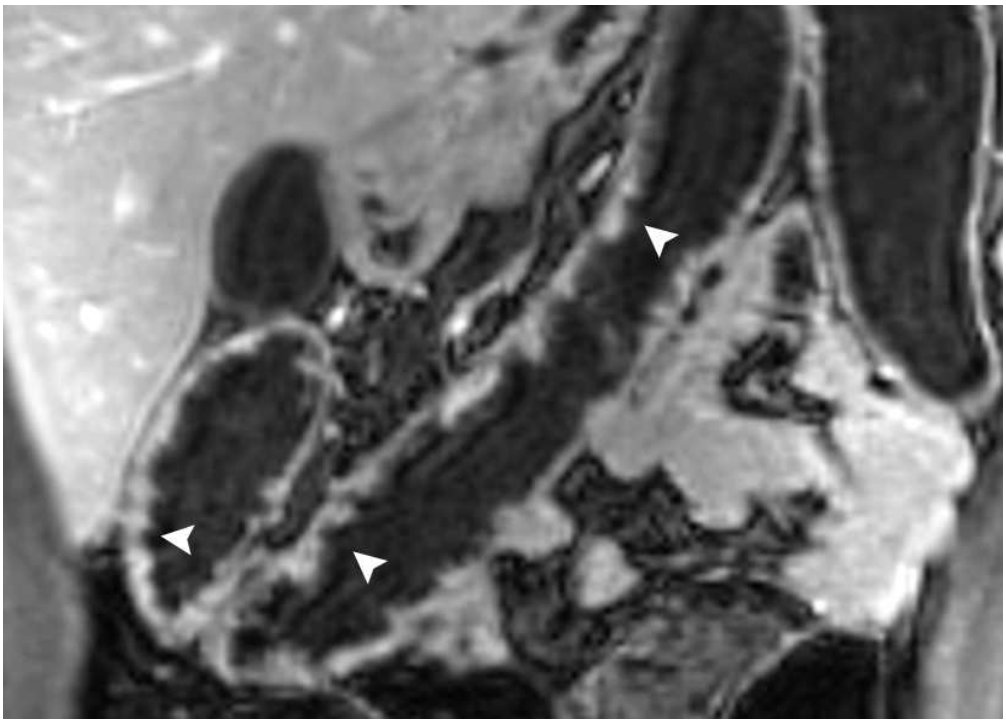

Ulcerative lesions of large bowel in a patient with Crohn's disease. Ulcers appear at MRI (arrowheads in Figure a) as a deep depressions on the mucosal surface of the thickened bowel wall. Colonoscopy (Figure b) revealed deep ulcers in the colon surrounded by a markedly inflamed mucosa.
70x50mm (300 x 300 DPI)

Review

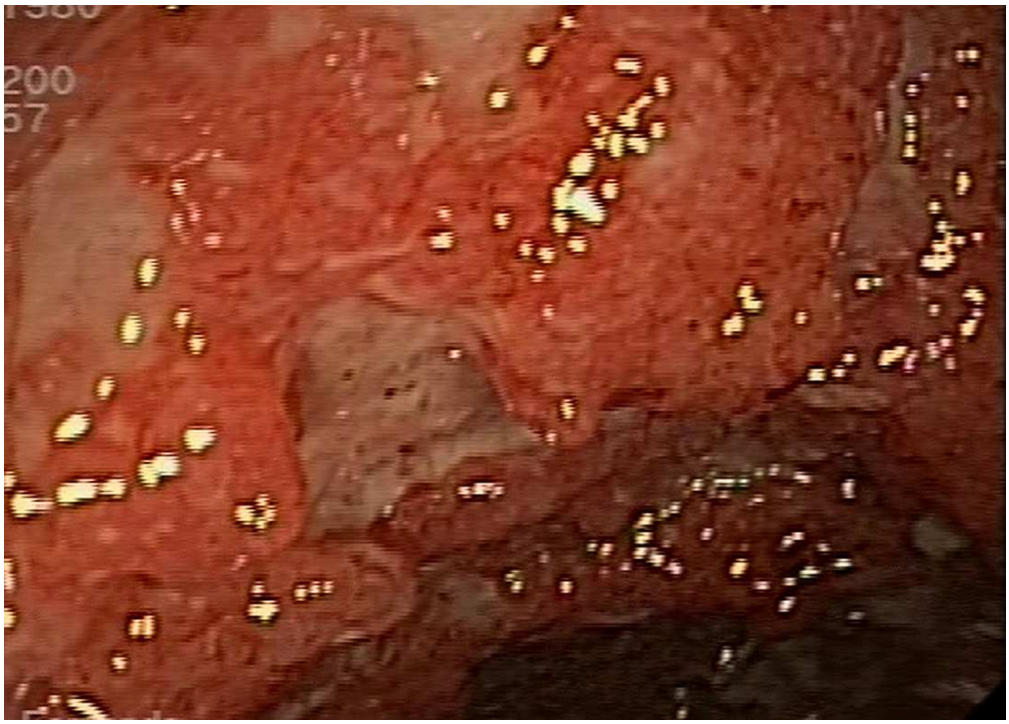


Ulcerative lesions of large bowel in a patient with Crohn's disease. Ulcers appear at MRI (arrowheads in Figure a) as a deep depressions on the mucosal surface of the thickened bowel wall. Colonoscopy (Figure b) revealed deep ulcers in the colon surrounded by a markedly inflamed mucosa.
69x49mm (400 x 400 DPI)

Review

Fistulizing Crohn's disease. Abdominal ultrasonography shows a lineal communication between two thickened small bowel loops (SB) which contains air (arrow), corresponding to an entero-enteric fistula.
50x70mm (300 x 300 DPI)

Fistulizing Crohn's disease. Abdominal CT scan in axial plane after iv contrast administration depicts a thickened ileal loop with ileo-cecal fistula and surrounding perientiec inflammatory changes (arrow). Posterior to the fistula a small abscess is observed (arrowhead).
177x120mm (72 x 72 DPI)

Review

# PRISMA 2009 Checklist

| Section/topic | # | Checklist item | Reported on page # |
|---|---|---|---|
| **TITLE** | | | |
| Title | 1 | Identify the report as a systematic review, meta-analysis, or both. | 1, 2, 4-5 |
| **ABSTRACT** | | | |
| Structured summary | 2 | Provide a structured summary including, as applicable: background; objectives; data sources; study eligibility criteria, participants, and interventions; study appraisal and synthesis methods; results; limitations; conclusions and implications of key findings; systematic review registration number. | 2 |
| **INTRODUCTION** | | | |
| Rationale | 3 | Describe the rationale for the review in the context of what is already known. | 3 - 5 |
| Objectives | 4 | Provide an explicit statement of questions being addressed with reference to participants, interventions, comparisons, outcomes, and study design (PICOS). | 3 - 5 |
| **METHODS** | | | |
| Protocol and registration | 5 | Indicate if a review protocol exists, if and where it can be accessed (e.g., Web address), and, if available, provide registration information including registration number. | no |
| Eligibility criteria | 6 | Specify study characteristics (e.g., PICOS, length of follow-up) and report characteristics (e.g., years considered, language, publication status) used as criteria for eligibility, giving rationale. | 3 - 5 |
| Information sources | 7 | Describe all information sources (e.g., databases with dates of coverage, contact with study authors to identify additional studies) in the search and date last searched. | 4 - 5 |
| Search | 8 | Present full electronic search strategy for at least one database, including any limits used, such that it could be repeated. | 4 |
| Study selection | 9 | State the process for selecting studies (i.e., screening, eligibility, included in systematic review, and, if applicable, included in the meta-analysis). | 4 - 5 |
| Data collection process | 10 | Describe method of data extraction from reports (e.g., piloted forms, independently, in duplicate) and any processes for obtaining and confirming data from investigators. | 4 - 5 |
| Data items | 11 | List and define all variables for which data were sought (e.g., PICOS, funding sources) and any assumptions and simplifications made. | 4 - 5 |
| Risk of bias in individual studies | 12 | Describe methods used for assessing risk of bias of individual studies (including specification of whether this was done at the study or outcome level), and how this information is to be used in any data synthesis. | 4 - 5 |
| Summary measures | 13 | State the principal summary measures (e.g., risk ratio, difference in means). | 5 |
| Synthesis of results | 14 | Describe the methods of handling data and combining results of studies, if done, including measures of consistency (e.g., $I^2$) for each meta-analysis. | 5 |

For Peer Review

# PRISMA 2009 Checklist

| Section/topic | # | Checklist item | Reported on page # |
|---|---|---|---|
| Risk of bias across studies | 15 | Specify any assessment of risk of bias that may affect the cumulative evidence (e.g., publication bias, selective reporting within studies). | No |
| Additional analyses | 16 | Describe methods of additional analyses (e.g., sensitivity or subgroup analyses, meta-regression), if done, indicating which were pre-specified. | No |
| **RESULTS** | | | |
| Study selection | 17 | Give numbers of studies screened, assessed for eligibility, and included in the review, with reasons for exclusions at each stage, ideally with a flow diagram. | 4 - 5 |
| Study characteristics | 18 | For each study, present characteristics for which data were extracted (e.g., study size, PICOS, follow-up period) and provide the citations. | Tables 1 - 6 |
| Risk of bias within studies | 19 | Present data on risk of bias of each study and, if available, any outcome level assessment (see item 12). | No |
| Results of individual studies | 20 | For all outcomes considered (benefits or harms), present, for each study: (a) simple summary data for each intervention group (b) effect estimates and confidence intervals, ideally with a forest plot. | Tables 1 - 6 |
| Synthesis of results | 21 | Present results of each meta-analysis done, including confidence intervals and measures of consistency. | No meta-analyses |
| Risk of bias across studies | 22 | Present results of any assessment of risk of bias across studies (see Item 15). | No |
| Additional analysis | 23 | Give results of additional analyses, if done (e.g., sensitivity or subgroup analyses, meta-regression [see Item 16]). | No |
| **DISCUSSION** | | | |
| Summary of evidence | 24 | Summarize the main findings including the strength of evidence for each main outcome; consider their relevance to key groups (e.g., healthcare providers, users, and policy makers). | 5 - 24 |
| Limitations | 25 | Discuss limitations at study and outcomelevel (e.g., risk of bias), and at review-level (e.g., incomplete retrieval of identified research, reporting bias). | 5 - 24 |
| Conclusions | 26 | Provide a general interpretation of the results in the context of other evidence, and implications for future research. | 5- 24 + Tables 1 - 6 |
| **FUNDING** | | | |
| Funding | 27 | Describe sources of funding for the systematic review and other support (e.g., supply of data); role of funders for the systematic review. | 24 |

*From:* Moher D, Liberati A, Tetzlaff J, Altman DG, The PRISMA Group (2009). Preferred Reporting Items for Systematic Reviews and Meta-Analyses: The PRISMA Statement.PLoS Med 6(6): e1000097. doi:10.1371/journal.pmed1000097

For more information, visit:**www.prisma-statement.org**.



For Peer Review