



**HAL**  
open science

## **Heparanase Expression in HNSCC Are Associated With Reduced Proliferation And Improved Survival**

Carolin Mogler, Christel Herold-Mende, Gerhard Dyckhoff, Ekkehart  
Jenetzky, Philipp Beckhove, Burkhard M Helmke

► **To cite this version:**

Carolin Mogler, Christel Herold-Mende, Gerhard Dyckhoff, Ekkehart Jenetzky, Philipp Beckhove, et al.. Heparanase Expression in HNSCC Are Associated With Reduced Proliferation And Improved Survival. *Histopathology*, 2011, 58 (6), pp.944. 10.1111/j.1365-2559.2011.03834.x . hal-00642393

**HAL Id: hal-00642393**

**<https://hal.science/hal-00642393>**

Submitted on 18 Nov 2011

**HAL** is a multi-disciplinary open access archive for the deposit and dissemination of scientific research documents, whether they are published or not. The documents may come from teaching and research institutions in France or abroad, or from public or private research centers.

L'archive ouverte pluridisciplinaire **HAL**, est destinée au dépôt et à la diffusion de documents scientifiques de niveau recherche, publiés ou non, émanant des établissements d'enseignement et de recherche français ou étrangers, des laboratoires publics ou privés.



## Heparanase Expression in HNSCC Are Associated With Reduced Proliferation And Improved Survival

Journal:	<i>Histopathology</i>
Manuscript ID:	HISTOP-03-10-0158.R1
Wiley - Manuscript type:	Original Article
Date Submitted by the Author:	19-Jul-2010
Complete List of Authors:	Mogler, Carolin; University Heidelberg, Pathology Herold-Mende, Christel; Division of Neurosurgical Research, Department of Neurosurgery, Dyckhoff, Gerhard; Head and Neck Surgery Jenetzky, Ekkehart; German Cancer Research Center Beckhove, Philipp; German Cancer Research Center Helmke, Burkhard; Elbe Klinikum Stade, Institute of Pathology
Keywords:	HNSCC, Heparanase, Proliferation, Survival

SCHOLARONE™  
Manuscripts

**Heparanase expression in HNSCC Is Associated With Reduced Proliferation And Improved Survival**

Carolin Mogler<sup>1\*</sup>, Christel Herold-Mende<sup>2,3\*</sup>, Gerhard Dyckhoff<sup>3</sup>, Ekkehart Jenetzky<sup>4</sup>, Philipp Beckhove<sup>4</sup>, Burkhard M. Helmke<sup>1,5</sup>

**Author affiliations:** **1** Institute of Pathology, University of Heidelberg. **2** Division of Neurosurgical Research, Department of Neurosurgery, University of Heidelberg **3** Head and Neck Surgery, University of Heidelberg. **4** German Cancer Research Center, Heidelberg. **5** Institute of Pathology, Elbeklinikum Stade

\* These authors contributed equally to the work

**Short title:** Heparanase expression in HNSCC

**Corresponding author:**

Carolin Mogler, MD

Institute of Pathology, Heidelberg

INF 220/21

D-69120 Heidelberg

Fon: + 49-6221-5638175 fax: + 49-6221-565251

**Key words:** HNSCC, Heparanase, Proliferation, Survival

## Abstract

**Aims:** Head and neck squamous cell carcinomas (HNSCC) are characterized by a poor prognosis. Cellular expression of heparanase, a degrading enzyme of the extracellular matrix (ECM), was associated with poorer prognosis in several cancers. In the present analysis we aimed to analyze its role for tumor growth and patient outcome in HNSCC.

**Methods & Results:** We analyzed cellular expression of the active form of heparanase in 71 human HNSCC using immunohistochemistry. Results were compared with corresponding clinicopathological data. Additionally, 65 cases of the study samples were stained against the proliferation marker MIB1.

Cellular heparanase expression was detected in 41 of 71 (57.74%) cases, especially UICC IV-staged tumors showed high heparanase levels. Heparanase was localized mainly in the cytoplasm and to a lesser extent at the cell membrane. High levels of heparanase were significantly correlated with an almost 4-fold decrease of MIB1 labeling ( $p = 0.006$ ). Comparison with clinical outcome by multivariate analysis revealed that patients with a high heparanase expression showed prolonged overall survival ( $p = 0.029$ ).

**Conclusions:** Although heparanase was mainly found in late stage HNSCCs, cellular heparanase expression in HNSCC significantly prolonged overall survival. We assume that the proliferation-reducing effect of high heparanase levels might outweigh tumor-promoting effects of heparanase, especially in advanced tumors.

## Introduction

Head and neck cancer is a major cause of cancer morbidity worldwide with >500,000 new cases reported annually [1]. Despite progress in surgical techniques and improved application of radiotherapy and chemotherapy, the mortality of these tumors is still high [2]. Head and neck cancers are characterized by local aggressiveness due to invasion of single tumor cells or tumor lobules into adjacent tissues and a marked propensity for dissemination to cervical lymph nodes [3]. The hydrolase heparanase has been described recently to be involved in tumor invasion and metastasis [4]. Heparanase is an endo-beta-D-glucuronidase, which is predominantly involved in cleavage of heparansulfate residues and hence participates in extracellular matrix degradation and remodelling [5]. Heparansulfate proteoglycans are ubiquitous macromolecules associated with the cell surface and the main constituents of the extracellular matrix of a wide range of tissues [6]. In the process of metastasis, the penetration of the basement membranes in blood or lymphatic vessels is an essential step required for the intravasation and extravasation of cancer cells [7]. In addition, heparanase also supports angiogenesis by releasing heparansulfate-bound growth factors, such as basic fibroblast growth factor (bFGF) and vascular endothelial growth factor (VEGF) [7]. A single heparanase gene encodes for a 65-kDa protein that undergoes a proteolytic cleavage, yielding a 50-kDa polypeptide, which is 100-fold more active than the 65-kDa form [8-9]. Heparanase is directly involved in cell adhesion independent of its enzymatic activity provided that the enzyme is expressed on the cell surface [10]. Heparanase activity has been identified in a variety of cells from normal tissues, primarily the placenta and lymphoid organs [11-13], among which endothelial cells, platelets, mast cells, neutrophils, macrophages, T and B lymphocytes, ganglion cells, and nerves mostly

express heparanase, with little or no staining in connective tissue cells and most normal epithelia [14-15]. Whereas no or weak heparanase expression was detected in normal epithelial cells, heparanase expression is increased in human carcinomas of the breast, lung, prostate, ovary, cervix, bladder, pancreas, liver, esophagus, colon, and stomach compared to corresponding normal tissues [14,16-25]. Thus far, studies published on heparanase expression in head and neck cancers [26-27] focussed on heparanase expression pattern and potential association with survival rates. However, knowledge on the influence of heparanase expression levels on tumor growth is still poor. Therefore we analyzed expression of the active form of heparanase and of the proliferation marker Ki-67 in 71 HNSCCs and related the observed staining patterns with patient outcome.

## Materials and Methods

### Immunohistochemistry

71 samples of patients with HNSCC have been collected. Written informed consent of all patients and permission of the local ethics committee was obtained before. Samples included large biopsies (**n= 7; size >1cm**) and surgical samples (**n= 64**) of paraffine-embedded tumors. **Biopsies were only used if of sufficient size and before neoadjuvant radio-/chemotherapy in order to analyze untreated tumor samples.**

After a pretreatment of 30 min in 97°C citrate buffer and overnight storage at 37°C, 3 µm sections have been routinely stained with Hematoxylin eosine and immunohistochemically with a monoclonal mouse antibody (clone HP 130; InSight Biotechnology Ltd., Wembley, UK) against the active 50 kD fragment of heparanase (1:300) and the proliferation marker MIB1 (clone Ki-67;1:200; Dako, Hamburg, Germany) using the Dako TecMate<sup>R</sup> with antibody incubation at room temperature for 1 hour. Isotype antibodies (IgG; Dako, Hamburg, Germany) served as negative controls.

Stainings were evaluated by two different experienced pathologists. For heparanase, intensity of staining was classified as 0 none, 1 weak, 2 moderate, 3 strong. Heparanase extent was divided into five groups: 0 no heparanase expression detected; 1: >0-25 % of tumor cells positive, 2: >25-50%, 3: >50-75%, 4: >75-100%.

For MIB1 staining proliferation was measured by assessing the ratio of MIB1-positive tumor cell nuclei related to all tumor cell nuclei shown in the sample. Results were classified as followed: < 10% low proliferation, 10-25% moderate, > 25% high proliferation.

## Clinical data

Clinical data were extracted from patients' files from the Department of Head and Neck Surgery. Emphasis was laid on age at first diagnosis, sex, tumor size, tumor site, grading, lymph node stage, hematogenous metastasis (TNM), UICC stage, treatment & **margin status**, relapses, tumor and non-tumor related death and overall survival.

**Most patients (64 patients) underwent surgical resection. In cases of heightened risk for an in situ relapse (e.g. R1 resection, infiltration of cervical lymph node capsule, advanced tumor stage), patients additionally underwent post-operative radiotherapy as proposed in the international guidelines. In total, 45 patients received post-operative radiation, the other 18 patients who did not receive post-operative radiation, were all staged as UICC stage I or II. One patient was planned to receive radiation (pT4pN2cpMx) but died before. Patients who were not addressable by surgical intervention or rejected surgical resection underwent primary radio-/chemotherapy.**

For main clinical data, see table 1: the majority of patients were male (61 cases), mean age at first diagnosis was 57.5 years for male and 58.3 years for female patients. At first diagnosis, most patients were staged pT2 or higher, 40 patients had lymph node metastasis. 68 patients had no detectable hematogenous metastasis, in the course of disease 5 patients developed pulmonary and cerebral metastasis. However, the majority of cases were staged UICC III (16 cases) or IV (29 cases: (22 cases IVa, 2 cases IVb and 5 cases IVc). 64 patients (55 male and 9 female) underwent surgical therapy, the other seven had combined radio-/chemotherapy. The mean follow up for the entire group was 56.8 months ( $\pm$  24.2 months), for patients who are still alive 96.4 months ( $\pm$  28.0 months). 35 patients experienced tumor-related death, 5 died due to other reasons (car accident e.g.).



### Statistical analysis

For statistical analysis we examined the association of heparanase expression in HNSCC with patients' overall survival applying univariate and multivariate analysis by using the software programme SPSS. Initially, Kaplan-Meier plot and log-rank test were performed, followed by Cox regression to adjust for other prognostic indicators, including UICC stage and therapy. To investigate potential relations between heparanase expression and tumor cell proliferation, Spearman's rank order correlation test for equidistant variables was calculated. A  $p$ -Value of  $< 0.05$  was considered to be statistically significant.

## Results

### Heparanase is heterogeneously distributed in HNSCCs

In a panel of 71 HNSCC tissues expression of the 50 kDa heparanase subunit was analyzed by immunohistochemistry. As summarized in table 2, 57.7% (41/71) of the specimen stained positive for heparanase. Among those, only about half of the cases (20/41) showed a moderate to strong staining intensity. With regard to the extent of heparanase expression, in the majority of cases (33/41) more than 25% positive tumor cells were found. The intratumoral heparanase distribution was highly heterogenous: 18 of 41 positive cases (43.9%) showed a strong heparanase expression in nearly all parts of the tumor (fig. 1A), while the majority of cases (23/41; 56.1%) displayed a predominant heparanase accumulation at the invasion front with predominant heparanase localization in the outer tumor cell layers (fig. 1B).

Contemplating the cellular distribution of heparanase, different staining patterns could be detected. Predominantly (29/41), heparanase was localized in the cytoplasm with small granulae (fig. 1C). In 5 cases heparanase was exclusively restricted to the cell membrane (fig. 1D). The remaining 7 cases showed features of both patterns.

Additionally, heparanase expression was also found in non-neoplastic tissue. Smooth muscle cells of vessels and pharyngeal skeletal muscles were brightly illuminated with a fine cytoplasmatic pattern in all cases where vessels or skeletal muscles were engaged in the slides (fig. 1E, F).

### High heparanase expression is associated with advanced tumor stages

Especially advanced tumors showed a strong and extended heparanase expression. 77.8% of tumors (14/18) with more than 50% heparanase-positive tumor cells were staged UICC IV (Fig. 2A). When analyzing metastasized primary tumors in more

detail, about half (19/37) of primary tumors were heparanase positive. **Among the heparanase positive cases, the majority of tumors (68.4%)** showed a heparanase expression in more than 50% of the tumor cells (Fig 2B). Altogether these data indicate that advanced tumors predominantly express high heparanase levels.

### **High heparanase expression is associated with low tumor proliferation**

65 samples from the study sample were additionally stained against MIB1, among those 38 were positive for heparanase (58.5%). In all samples a bright distinct nuclear staining for MIB1 in a subgroup of tumor cells was detected (Fig. 3). According to the graduation mentioned earlier, 30 cases showed a moderate to high proliferation rate (Fig. 3 A, B) and 35 cases showed a low proliferation rate. Distribution of MIB1 positive nuclei was more homogenous than that of heparanase. Comparing these cases with corresponding heparanase levels, most heparanase positive tumors showed a similar distribution of MIB1 and heparanase (Fig. 3 A, arrowheads), while in a subgroup of 16 cases a more opposite expression pattern was observed (Fig. 3B, arrowheads). Interestingly, increasing heparanase levels turned out to be associated with an almost 4-fold decrease in the proliferation rate (Fig. 4).

Finally, we performed statistical analysis to investigate the influence heparanase expression on tumor proliferation by Spearman rank order correlation test. Analysis confirmed that HNSCCs with high heparanase expression had significant lower tumor cell proliferation rates compared to cases with low heparanase expression ( $-0.335$ ;  $p=0.006$ ). Thus, our data proved an inverse correlation between increased heparanase expression and reduced tumor cell proliferation.

**Heparanase expression is associated with favorable overall survival**

When comparing heparanase expression levels with clinical parameters we found a beneficial influence on overall survival ( $p=0.026$ ), which is a surprising result and has not been shown yet for HNSCC or any other tumor entity (Fig. 5). **Interestingly, choosing a higher cut-off, heparanase proved to be a stable significant parameter for 15% cut-off ( $p= 0.0261$ ) and a borderline significant parameter for a cut-off at <25% ( $p= 0.062$ ).** No correlation was found for the subcellular localization of heparanase ( $p = 0.193$ ), staining intensity or intratumoral heparanase distribution (data not shown). Focussing on advanced tumor stages (UICC stage IV), again a trend to a better overall survival for patients with heparanase-positive tumor cells was seen, but we did not achieve statistical significance ( $p=0.09$ ), most probably due to small number of cases ( $n=29$ ). However, when dividing heparanase positive UICC IV staged tumors into subgroups with less than 50% and  $\geq 50\%$  heparanase positive tumor cells, tumors with more heparanase showed a trend towards a worse survival compared to tumors with low heparanase ( $p=0.29$ ).

Subsequent multivariate analysis revealed that heparanase expression and UICC stage were the only factors with significant influence on overall survival ( $p=0.003$ ). Neither epidemiological factors (age, gender) nor heparanase specific parameters (staining intensity, intratumoral heparanase distribution, predominant subcellular heparanase expression) nor tumor specific parameters (anatomical tumor site, proliferation rate, intratumoral distribution, grading, **margin status**) affected overall survival significantly (data not shown). **Interestingly, also the choice of therapy (surgical intervention vs. primary radio-/chemotherapy) did not lead to significant differences in the overall survival (data not shown).**

## Discussion

Heparanase, a beta- d- endo- glucuronidase, is capable of degrading heparansulfates. Over the last three decades heparanase has been shown to be involved in many physiological and pathological processes, including especially tumor cell invasion and migration for the latter [5,28-31]. Its appearance in different tumors has been proven to reduce patients' overall survival and could be associated with poorer prognosis in many different tumor entities [17,32-35]. Nevertheless, not much is known about heparanase expression in squamous cell carcinomas of the head and neck, especially whether heparanase expression is related to tumor cell proliferation.

According to our results, in more than half of the cases active heparanase was detected in HNSCCs. Interestingly, heparanase extent increased with advanced tumor stages. Additionally, tumors in UICC stage IV displayed more lymph node metastasis when high levels of heparanase were detectable, suggesting an association of heparanase expression with a more aggressive tumor phenotype. Comparable results have been described elsewhere [4]. Different cellular expression patterns of active heparanase have been described to be related to various functions [36-37]. For example, cytoplasmatic or membrane-bound heparanase can interact with the extracellular matrix (ECM) and promote tumor angiogenesis, tumor progression and metastasis through the release of heparansulfate bound angiogenic and growth factors in the ECM [29,38]. In contrast, heparanase detected in the nucleus is supposed to influence complex intracellular processes such as cell differentiation [39-40]

With regard to head and neck cancer, different subcellular localizations have been recorded. A distinct nuclear expression of heparanase has been described [27] as well as a cytoplasmatic accumulation [26]. Interestingly, both could be correlated with

a poor survival. Although in this larger study sample we showed a predominant cytoplasmatic expression, unlike in previous studies we were not able to correlate high heparanase levels with poor survival rate. In contrast, we could prove a significantly better overall survival in patients with higher frequencies of heparanase positive tumor cells, an association that has not been described in literature yet and which is pretty surprising at first glance. However, we could substantiate these contradictory results by the observation that increasing numbers of heparanase positive tumor cells were inversely correlated with a 4-fold decrease of tumor cell proliferation. **A common finding by others was that heparanase can enzymatically influence cell migration and invasiveness but not proliferation [41-43], e.g. in a stable heparanase knock down model in gastric cancer only migration and invasiveness were reduced but not tumor cell proliferation [44]. Further studies also clearly showed that heparanase expressing cells were able to activate neighboring tumor and non tumor cells (such as endothelial cells) with subsequent improved cell migration and invasiveness while no increase in proliferation was notable [45]. However, strong support comes from Zetser and colleagues [46] demonstrating that stably transfected glioblastoma cells overexpressing heparanase significantly reduced tumor cell proliferation in vitro and vivo.** It can be therefore speculated that the local proliferation-reducing effect of heparanase seems to outweigh the heparanase-associated promotion of a more aggressive tumor behavior and a more frequent formation of lymph node metastasis and might thus provide an explanation for the better overall survival seen in our study sample.

To sum up, for the first time we present heparanase to be a prognostic marker for prolonged overall survival in patients with head and neck squamous cell carcinomas most due to a significant decrease of tumor cell proliferation specifically occurring in

the presence of high heparanase levels. Based on these findings and in light of the current literature, future studies are warranted to learn more about the functional role of heparanase in advanced HNSCC.

### **Acknowledgements**

We thank Prof. Vlodaysky (Haifa, Israel) for providing the Heparanase antibody.

For Peer Review

## References

1. Simizu S, Ishida K, Wierzba MK *et al.* Expression of heparanase in human tumor cell lines and human head and neck tumors. *Cancer Lett.* 2003; **193**; 83-89.
2. Ferlay J, Autier P, Boniol M *et al.* Estimates of the cancer incidence and mortality in Europe in 2006. *Ann Oncol.* 2007; **18**; 581-592.
3. Dunne AA, Muller HH, Eisele DW *et al.* Meta-analysis of the prognostic significance of perinodal spread in head and neck squamous cell carcinomas (HNSCC) patients. *Eur J Cancer.* 2006; **42**; 1863-1868.
4. Vlodavsky I, Michaeli RI, Bar-Ner M *et al.* Involvement of heparanase in tumor metastasis and angiogenesis. *Isr J Med Sci.* 1988; **24**; 464-470.
5. Vlodavsky I, Friedmann Y Molecular properties and involvement of heparanase in cancer metastasis and angiogenesis. *J Clin Invest.* 2001; **108**; 341-347.
6. Wight TN, Kinsella MG, Qwarnstrom EE The role of proteoglycans in cell adhesion, migration and proliferation. *Curr Opin Cell Biol.* 1992; **4**; 793-801.
7. Vlodavsky I, Goldshmidt O, Zcharia E *et al.* Mammalian heparanase: involvement in cancer metastasis, angiogenesis and normal development. *Semin Cancer Biol.* 2002; **12**; 121-129.
8. Vlodavsky I, Goldshmidt O Properties and function of heparanase in cancer metastasis and angiogenesis. *Haemostasis.* 2001; **31 Suppl 1**; 60-63.
9. Vlodavsky I, Goldshmidt O, Zcharia E *et al.* Molecular properties and involvement of heparanase in cancer progression and normal development. *Biochimie.* 2001; **83**; 831-839.
10. Goldshmidt O, Zcharia E, Cohen M *et al.* Heparanase mediates cell adhesion independent of its enzymatic activity. *Faseb J.* 2003; **17**; 1015-1025.
11. Bar-Ner M, Mayer M, Schirmacher V *et al.* Involvement of both heparanase and plasminogen activator in lymphoma cell-mediated degradation of heparan sulfate in the subendothelial extracellular matrix. *J Cell Physiol.* 1986; **128**; 299-306.
12. Hulett MD, Freeman C, Hamdorf BJ *et al.* Cloning of mammalian heparanase, an important enzyme in tumor invasion and metastasis. *Nat Med.* 1999; **5**; 803-809.
13. McKenzie E, Tyson K, Stamps A *et al.* Cloning and expression profiling of Hpa2, a novel mammalian heparanase family member. *Biochem Biophys Res Commun.* 2000; **276**; 1170-1177.
14. Friedmann Y, Vlodavsky I, Aingorn H *et al.* Expression of heparanase in normal, dysplastic, and neoplastic human colonic mucosa and stroma. Evidence for its role in colonic tumorigenesis. *Am J Pathol.* 2000; **157**; 1167-1175.
15. Ginath S, Menczer J, Friedmann Y *et al.* Expression of heparanase, Mdm2, and erbB2 in ovarian cancer. *Int J Oncol.* 2001; **18**; 1133-1144.
16. Gohji K, Okamoto M, Kitazawa S *et al.* Heparanase protein and gene expression in bladder cancer. *J Urol.* 2001; **166**; 1286-1290.
17. Shinyo Y, Kodama J, Hongo A *et al.* Heparanase expression is an independent prognostic factor in patients with invasive cervical cancer. *Ann Oncol.* 2003; **14**; 1505-1510.
18. Maxhimer JB, Quiros RM, Stewart R *et al.* Heparanase-1 expression is associated with the metastatic potential of breast cancer. *Surgery.* 2002; **132**; 326-333.
19. Kosir MA, Quinn CC, Zukowski KL *et al.* Human prostate carcinoma cells produce extracellular heparanase. *J Surg Res.* 1997; **67**; 98-105.
20. Davidson B, Shafat I, Risberg B *et al.* Heparanase expression correlates with poor survival in metastatic ovarian carcinoma. *Gynecol Oncol.* 2007; **104**; 311-319.
21. Kim AW, Xu X, Hollinger EF *et al.* Human heparanase-1 gene expression in pancreatic adenocarcinoma. *J Gastrointest Surg.* 2002; **6**; 167-172.
22. Koliopanos A, Friess H, Kleeff J *et al.* Heparanase expression in primary and metastatic pancreatic cancer. *Cancer Res.* 2001; **61**; 4655-4659.
23. Chen XP, Liu YB, Rui J *et al.* Heparanase mRNA expression and point mutation in hepatocellular carcinoma. *World J Gastroenterol.* 2004; **10**; 2795-2799.
24. Okawa T, Naomoto Y, Nobuhisa T *et al.* Heparanase is involved in angiogenesis in esophageal cancer through induction of cyclooxygenase-2. *Clin Cancer Res.* 2005; **11**; 7995-8005.
25. Tang W, Nakamura Y, Tsujimoto M *et al.* Heparanase: a key enzyme in invasion and metastasis of gastric carcinoma. *Mod Pathol.* 2002; **15**; 593-598.
26. Beckhove P, Helmke BM, Ziouta Y *et al.* Heparanase expression at the invasion front of human head and neck cancers and correlation with poor prognosis. *Clin Cancer Res.* 2005; **11**; 2899-2906.
27. Doweck I, Kaplan-Cohen V, Naroditsky I *et al.* Heparanase localization and expression by head and neck cancer: correlation with tumor progression and patient survival. *Neoplasia.* 2006; **8**; 1055-1061.



28. Dempsey LA, Brunn GJ, Platt JL Heparanase, a potential regulator of cell-matrix interactions. *Trends Biochem Sci.* 2000; **25**; 349-351.
29. Goldshmidt O, Zcharia E, Abramovitch R *et al.* Cell surface expression and secretion of heparanase markedly promote tumor angiogenesis and metastasis. *Proc Natl Acad Sci U S A.* 2002; **99**; 10031-10036.
30. Parish CR, Freeman C, Hulett MD Heparanase: a key enzyme involved in cell invasion. *Biochim Biophys Acta.* 2001; **1471**; M99-108.
31. Vlodaysky I, Friedmann Y, Elkin M *et al.* Mammalian heparanase: gene cloning, expression and function in tumor progression and metastasis. *Nat Med.* 1999; **5**; 793-802.
32. Dutta U, Poornachandra KS Heparanase and gallbladder cancer: new insights into understanding tumor growth and invasion. *J Gastroenterol Hepatol.* 2008; **23**; 343-344.
33. Bar-Sela G, Kaplan-Cohen V, Ilan N *et al.* Heparanase expression in nasopharyngeal carcinoma inversely correlates with patient survival. *Histopathology.* 2006; **49**; 188-193.
34. Quiros RM, Rao G, Plate J *et al.* Elevated serum heparanase-1 levels in patients with pancreatic carcinoma are associated with poor survival. *Cancer.* 2006; **106**; 532-540.
35. Rohloff J, Zinke J, Schoppmeyer K *et al.* Heparanase expression is a prognostic indicator for postoperative survival in pancreatic adenocarcinoma. *Br J Cancer.* 2002; **86**; 1270-1275.
36. Fux L, Ilan N, Sanderson RD *et al.* Heparanase: busy at the cell surface. *Trends Biochem Sci.* 2009; **34**; 511-519.
37. Schubert SY, Ilan N, Shushy M *et al.* Human heparanase nuclear localization and enzymatic activity. *Lab Invest.* 2004; **84**; 535-544.
38. Benhamron S, Nechushtan H, Verbovetski I *et al.* Translocation of active heparanase to cell surface regulates degradation of extracellular matrix heparan sulfate upon transmigration of mature monocyte-derived dendritic cells. *J Immunol.* 2006; **176**; 6417-6424.
39. Nobuhisa T, Naomoto Y, Okawa T *et al.* Translocation of heparanase into nucleus results in cell differentiation. *Cancer Sci.* 2007; **98**; 535-540.
40. Nobuhisa T, Naomoto Y, Takaoka M *et al.* Emergence of nuclear heparanase induces differentiation of human mammary cancer cells. *Biochem Biophys Res Commun.* 2005; **331**; 175-180.
41. Wang Z, Xu H, Jiang L *et al.* Positive association of heparanase expression with tumor invasion and lymphatic metastasis in gastric carcinoma. *Mod Pathol.* 2005; **18**; 205-211.
42. Zhang YL, Fu ZR, Zhang J *et al.* [Inhibition of invasiveness of human mammary carcinoma cell line MDA435 by heparanase antisense oligodeoxynucleotide]. *Zhonghua Yi Xue Za Zhi.* 2003; **83**; 204-207.
43. Zhou Y, Song B, Qin WJ *et al.* Heparanase promotes bone destruction and invasiveness in prostate cancer. *Cancer Lett.* 2008; **268**; 252-259.
44. Zheng LD, Jiang GS, Pu JR *et al.* Stable knockdown of heparanase expression in gastric cancer cells in vitro. *World J Gastroenterol.* 2009; **15**; 5442-5448.
45. Gingis-Velitski S, Zetser A, Flugelman MY *et al.* Heparanase induces endothelial cell migration via protein kinase B/Akt activation. *J Biol Chem.* 2004; **279**; 23536-23541.
46. Zetser A, Bashenko Y, Miao HQ *et al.* Heparanase affects adhesive and tumorigenic potential of human glioma cells. *Cancer Res.* 2003; **63**; 7733-7741.

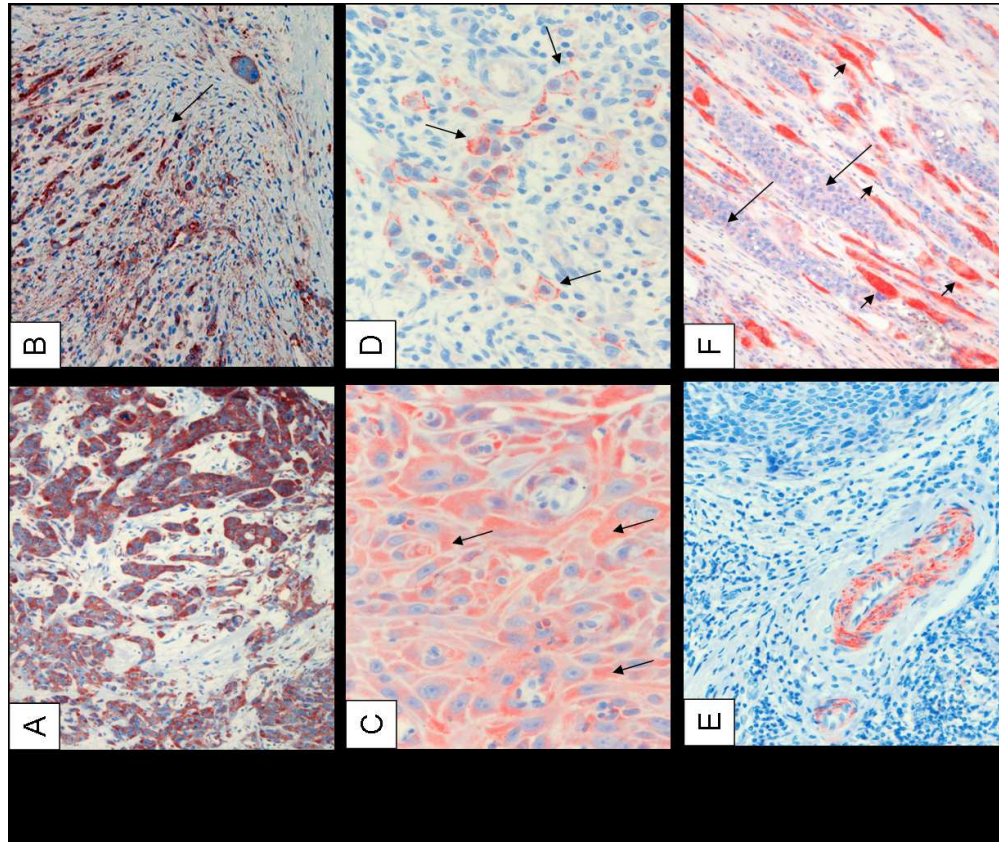


Figure 1 Detection of heparanase by immunohistochemistry  
 A Bright heparanase expression in HNSCC (100x); B heparanase at the invasion front (arrows) of a HNSCC (100x) C cytoplasmatic pattern (arrows, 200x) D membranous pattern (arrows, 200x); E heparanase positive smooth muscle cells within the vessel wall (100x); F heparanase positive pharyngeal muscle cells (arrow heads) invaded by HNSCC tumor cells with weaker but detectable heparanase expression (arrows,100x).

207x173mm (150 x 150 DPI)

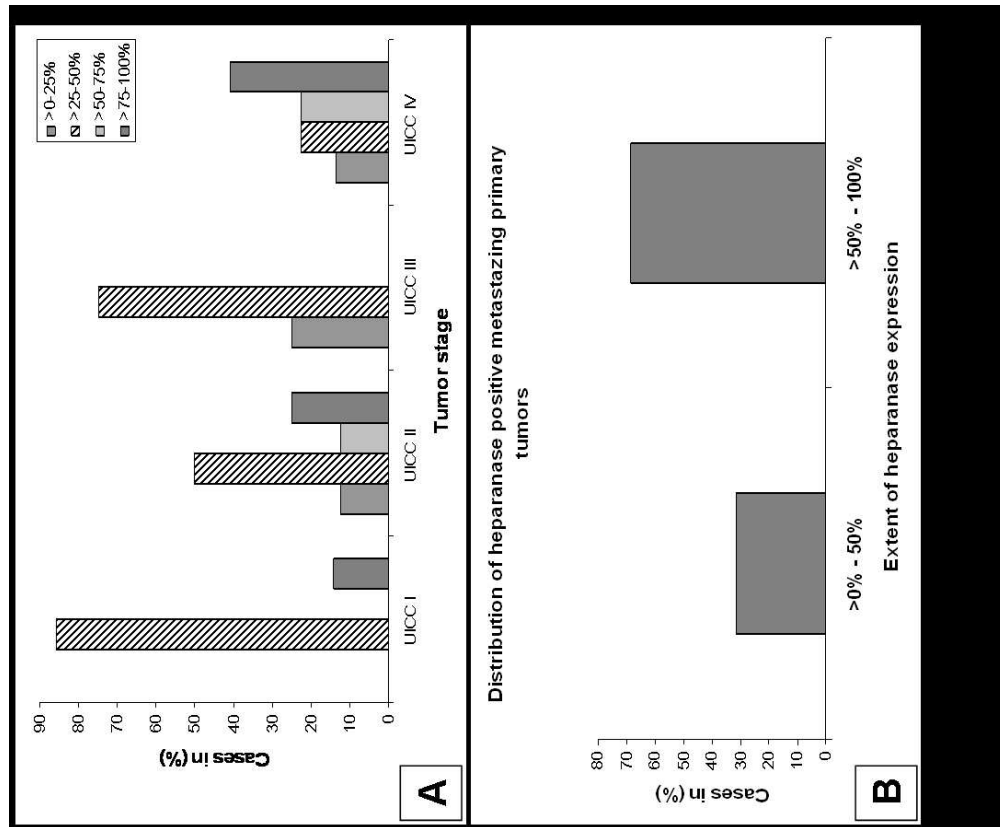


Figure 2 Distribution of heparanase expression  
A Distribution of UICC-staged tumors according to heparanase levels: significantly more UICC IV tumors showed higher heparanase levels (dark grey bars).  
B Distribution of heparanase positive metastizing primary tumors: most tumors presented with high levels of heparanase (>50% of positive tumor cells).

184x151mm (150 x 150 DPI)

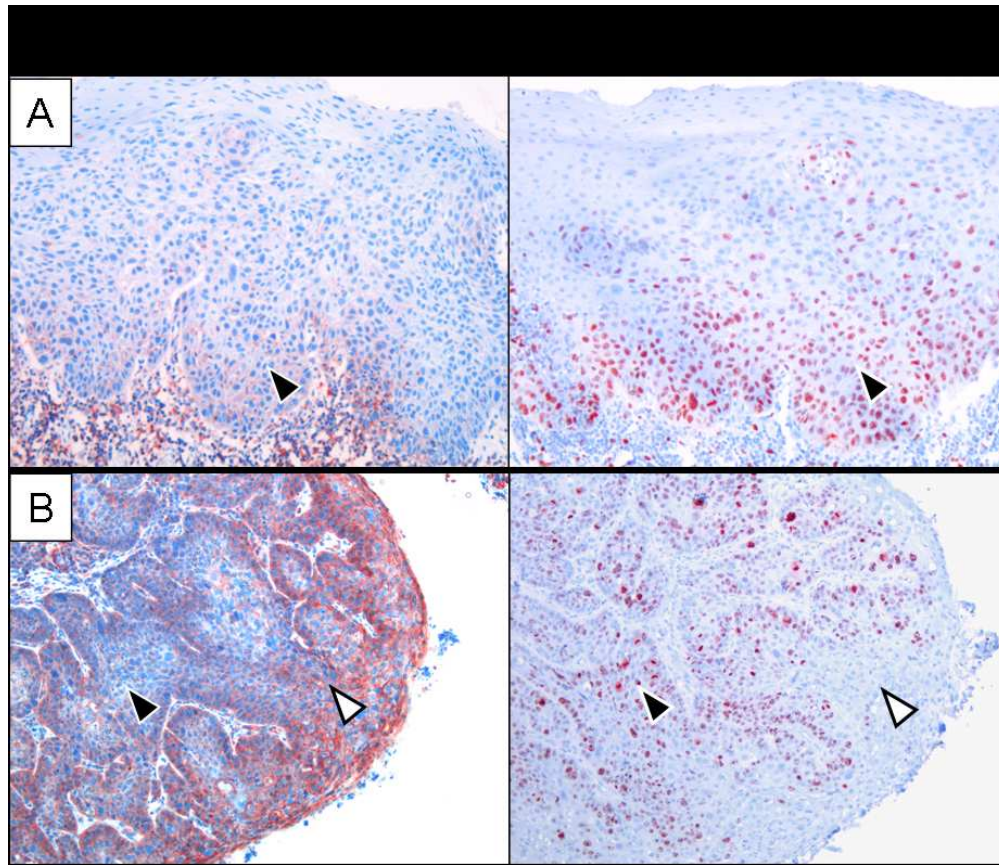


Figure 3 Intratumoral distribution of heparanase and MIB 1-staining patterns  
While in A high proliferation is associated with low heparanase, in B high proliferation and heparanase expression are seen but with almost no intratumoral overlap. Magnification: 100x

156x134mm (150 x 150 DPI)



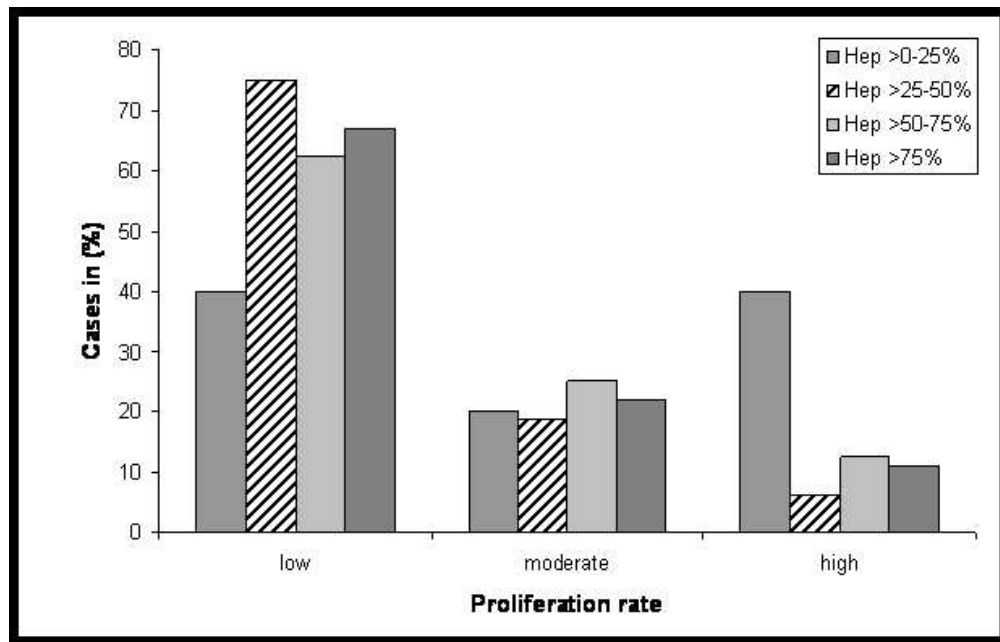


Figure 4 Increasing heparanase levels correlate with a decrease in tumor proliferation. Interestingly, an almost 4-fold decrease of proliferation was found in tumors with high heparanase levels compared to tumors with only low or no heparanase expressing tumor cells.

163x104mm (96 x 96 DPI)

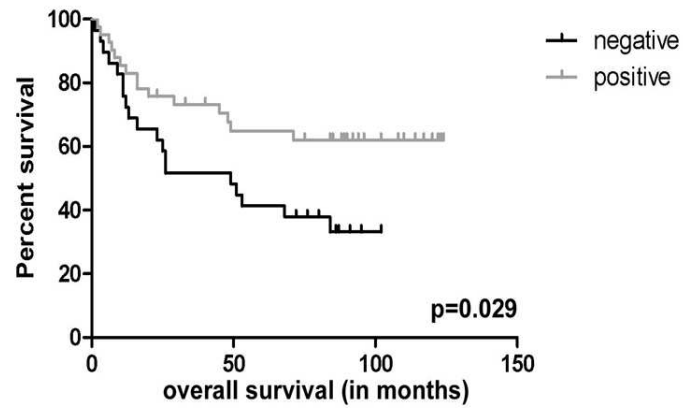


Figure 5 Heparanase expression and patient survival  
Patients with heparanase (Hep) positive tumors show better survival rates compared to patients with heparanase negative tumors.  
( $p=0.029$ )

181x99mm (150 x 150 DPI)

Review

## Tables

**Table 1: Main clinical data**

	total (n)
<b>Gender</b>	
male	61
female	10
<b>Tumor size</b>	
pTis	1
pT1	16
pT2	21
pT3	13
pT4	20
<b>Lymph node metastasis</b>	
pN1	7
pN2a	1
pN2b	15
pN2c	16
pN3	1
<b>UICC stage</b>	
0	1
I	13
II	12
III	16
IV	29
<b>Margin status</b>	
R0	51
R1	5
R2	4
Rx	4
none (primary RCHT)	7
<b>Tumor site</b>	
pharynx	33
- epipharynx	2
- oropharynx	18
- hypopharynx	13
larynx	33
Oral cavity& air sinus	5
<b>Overall survival (in months)</b>	
Entire group	56.8 (±24.2)
Patietents still alive (n=31)	96.4 (±28.0)

RCHT: radio-/chemotherapy

**Table 2: Main Heparanase parameters**

	total (n)(%)
<b>Heparanase intensity</b>	
0	30 (42.25%)
1	21 (29.56%)
2	15 (21.12%)
3	5 (7.04%)
<b>Heparanase extent</b>	
no heparanase staining	30 (42.25%)
>0-25%	6 (8.45%)
>25-50%	17 (23.94%)
>50%	18 (25.35%)
<b>Heparanase localization</b>	
cytoplasmatic	29 (40.85%)
membranous	5 (7.04%)
both	7 (9.86%)



# Colour Work Agreement Form



Form No: SN\_Upw2000\_P\_CoW\_F2

**If you have any problems or queries please contact the Production Editor for guidance (details can be found in the Instructions for Authors)**

If you have submitted a manuscript that contains colour figures, it is the policy of the journal for authors to meet the full cost of colour reproduction. Blackwell Publishing require you to complete this form. Please fill in your contact details and then complete the table as instructed.

**Note:** this form must be filled in for **all** manuscripts that have been submitted with colour work, even if you subsequently choose not to publish either in print or online in colour.

**We are unable to process your manuscript until we receive your instructions so please return this form as quickly as possible!**

Journal name: HISTOPATHOLOGY

Corresponding Author: MOGLER, CAROLIN MD

Manuscript No/Title: HISTOP-03-10-0158.R1

Your Name: MOGLER, CAROLIN

Address: Institute of Pathology, INF 220/21  
D - 69120 Heidelberg

Fax: +49-6221-565251 Tel: +49-6221-56-38175

e-mail: Carolin.Mogler@med.uni-heidelberg.de

## WHAT YOU NEED TO DO

Please complete the table on page 2, placing an 'X' in the relevant column for each figure. The costs are shown at the top of each column. Please calculate the total cost for each category at the foot of the table, and then add VAT if applicable (see below).

**All customers MUST quote their VAT numbers**

**Customers in the UK:** add VAT at 17.5%.

**Customers elsewhere in the EU:**

- *Customers registered for VAT:* No VAT (please complete details below)

VAT registration number: DE 143 293 939

Name of organisation: \_\_\_\_\_

- *Customers NOT registered for VAT:* Add VAT at 17.5%.

**Customers outside the EU:** No VAT

PAGE 1

<<<For internal use ONLY>>>				
JPCMS No	Journal acronym	Volume	Issue	Print run

Please now complete this table (Remember: only one 'X' per figure).

Figure Number	Column 1 Colour in print and online*	Column 2 Colour online ONLY	Column 3 Black & white in print and online
Costs	1st and 2nd figures = Free Subsequent figures = £60 each	£50 each	Free
1	X		
2			X
3	X		
4			X
5			X
6			
7			
8			
9			
10			
Total number of figures of each type	2	1	3

No. of colour figs	Cost	No. of colour figs	Cost
1	Free	6	£240
2	Free	7	£300
3	£60	8	£360
4	£120	9	£420
5	£180	10	£480

Column 1 total £ 0  
 Column 2 total £ 0  
 VAT (if applicable) £ 0  
**Total: £** 0

**Payment by Credit Card (MasterCard/VISA/American Express)**

Blackwell Publishing accepts payment in three major currencies: Pounds Sterling, United States Dollars and the Euro. Please indicate which currency you would like to pay in: Pounds Sterling (£)  / United States Dollars\* (US\$)  / Euros\* (€)  (tick one)  
 \*Conversions from US\$ or € will be made at our monthly rate.

Please debit my credit card number: 4 1 5 9 7 4 0 0 8 7 9 3 6 0 1 1

Verification ID Number: 5 1 3 This can be found on your credit card (Visa/MasterCard have 3 numbers and Amex has 4)

Name on card Carolin Mogler Expiry Date 06 / 14

With the sum of 0€

Signature Carolin Mogler Date 21<sup>th</sup> July 2010

**Note:** payment by credit card can only be accepted if **all** sections are completed. Please use BLOCK CAPITALS where possible.

**Payment by Purchase Order**

If you are asking your university or institution to pay we require purchase order details

I attach order number \_\_\_\_\_ dated \_\_\_\_\_

**Please now return all pages of your completed form as a scanned electronic file (preferred option), or by fax or post to the production editor for your journal. Contact details can be found in the instructions for authors.**