



HAL
open science

A multicentre randomized controlled clinical trial on the treatment of intrabony defects with enamel matrix derivatives/synthetic bone graft or enamel matrix derivatives alone-Results after 12 months

Joerg Meyle, Thomas Hoffmann, Heinz Topoll, Bernd Heinz, Eli Al-Machot, Pia-Merete Jervøe-Storm, Søren Jepsen, Peter Eickholz, Christian Meiss

► To cite this version:

Joerg Meyle, Thomas Hoffmann, Heinz Topoll, Bernd Heinz, Eli Al-Machot, et al.. A multicentre randomized controlled clinical trial on the treatment of intrabony defects with enamel matrix derivatives/synthetic bone graft or enamel matrix derivatives alone-Results after 12 months. *Journal of Clinical Periodontology*, 2011, 38 (7), pp.652. 10.1111/j.1600-051X.2011.01726.x . hal-00640460

HAL Id: hal-00640460

<https://hal.science/hal-00640460>

Submitted on 12 Nov 2011

HAL is a multi-disciplinary open access archive for the deposit and dissemination of scientific research documents, whether they are published or not. The documents may come from teaching and research institutions in France or abroad, or from public or private research centers.

L'archive ouverte pluridisciplinaire **HAL**, est destinée au dépôt et à la diffusion de documents scientifiques de niveau recherche, publiés ou non, émanant des établissements d'enseignement et de recherche français ou étrangers, des laboratoires publics ou privés.



A multicentre randomized controlled clinical trial on the treatment of intrabony defects with enamel matrix derivatives/synthetic bone graft or enamel matrix derivatives alone—Results after 12 months

| | |
|-------------------------------|--|
| Journal: | <i>Journal of Clinical Periodontology</i> |
| Manuscript ID: | CPE-09-10-2844.R1 |
| Manuscript Type: | Original Article Clinical Periodontology |
| Date Submitted by the Author: | 06-Feb-2011 |
| Complete List of Authors: | Meyle, Joerg; University of Giessen, Periodontology Hoffmann, Thomas; University of Technology, Faculty of Medicine, Department of Periodontology Topoll, Heinz Heinz, Bernd Al-Machot, Eli; University of Technology, Faculty of Medicine, Department of Periodontology Jervøe-Storm, Pia-Merete; University of Bonn, Periodontology Jepsen, Søren; Bonn University, Periodontology Eickholz, Peter; Centre for Dental, Oral, and Maxillofacial Medicine (Carolinum), Johann Wolfgang Goethe-University, Periodontology; home Meiss, Christian; University of Frankfurt, Periodontology |
| Topic: | Treatment |
| Keywords: | periodontitis, bone replacement graft, enamel matrix derivative, intrabony defects, periodontal regeneration |
| Main Methodology: | Clinical Trial |
| | |

SCHOLARONE™
Manuscripts

1
2
3 **A multicentre randomized controlled clinical trial on the treatment of intrabony**
4 **defects with enamel matrix derivatives/synthetic bone graft or enamel matrix**
5 **derivatives alone—Results after 12 months**
6
7
8
9

10
11 J. Meyle¹, T. Hoffmann², H. Topoll³, B. Heinz⁴, E. Al-Machot², P.-M. Jervøe-Storm⁵,
12
13 C. Meiß⁶, P. Eickholz⁶, S. Jepsen⁵
14
15
16
17

18 ¹Department of Periodontology, University of Giessen, Germany

19 ²Department of Conservative Dentistry, University of Dresden, Germany

20 ³Private Practice, Münster, Germany

21 ⁴Private Practice, Hamburg, Germany

22 ⁵Department of Periodontology, Operative and Preventive Dentistry, University of
23 Bonn, Germany
24

25 ⁶Department of Periodontology, University of Frankfurt am Main, Germany
26
27
28
29
30
31
32

33 Key words: bone replacement graft; enamel matrix derivative; intrabony defects;
34 periodontal regeneration; randomized clinical trial; radiographic evaluation
35
36
37
38
39
40
41
42

43 Running title: EMD/bone graft vs. EMD
44

45 Corresponding author:
46

47 Dr. Joerg Meyle
48

49 Department of Periodontology,
50

51 University of Giessen
52

53 Schlangenzahl 14
54

55 35392 Giessen, Germany
56

57 FAX.: 0049 – 0641 – 9946189
58

59 E-Mail: joerg.meyle@dentist.med.uni-giessen.de
60

Abstract

Objectives: Comparison of the clinical and radiographic outcomes of a combination of enamel matrix derivatives (EMD) and a synthetic bone graft (EMD/SBG) with EMD alone in wide (≥ 2 mm) and deep (≥ 4 mm) 1- and 2- wall intrabony defects 12 months after treatment.

Method: Seventy-three patients with chronic periodontitis and one wide (≥ 2 mm) and deep (≥ 4 mm) intrabony defect were recruited in 5 centers in Germany. During surgery, defects were randomly assigned to EMD/SBG (test) or EMD (control). Assessments at baseline, after 6 and 12 months included bone sounding, attachment levels, probing pocket depths, bleeding on probing, and recessions. Changes in defect fill were recorded radiographically.

Results: Both treatment modalities led to significant clinical improvements. In the EMD/SBG group a mean defect fill of 2.7 ± 1.9 mm was calculated, in the EMD group the defect fill was 2.8 ± 1.6 mm. A mean gain in clinical attachment of 1.7 ± 2.1 mm in the test group and 1.9 ± 1.7 mm in the control group after 1 year was observed. Radiographic analysis confirmed for both groups that deeper defects were associated with greater defect fill.

Conclusion: The results show comparable clinical and radiographic outcomes following both treatment modalities 12 months after treatment.

Clinical relevance

Scientific rationale for the study: Clinical and in particular radiographic comparison of a combination of an enamel matrix derivative and a synthetic bone graft (EMD/SBG) with EMD alone in wide and deep uncontained intrabony defects 12 months after treatment.

1
2
3 **Principal findings:** The follow-up data reported 12 months after the use of EMD
4 alone and a combination of EMD with a synthetic bone graft in wide and deep
5 intrabony defects demonstrate significant clinical and radiographic improvements,
6 compared to baseline as well as minor insignificant improvements (stability)
7 compared to the 6-month results.
8
9

10 **Practical implications:** Local defect characteristics have an impact on treatment
11 outcome irrespective of the mode of regenerative treatment, i.e. if EMD is combined
12 with a synthetic bone graft or not.
13
14
15
16
17
18
19
20
21
22
23
24
25
26
27
28
29
30
31
32
33
34
35
36
37
38
39
40
41
42
43
44
45
46
47
48
49
50
51
52
53
54
55
56
57
58
59
60

1
2
3 During the past decades different approaches and techniques have been employed
4
5 to regenerate lost periodontal structures (for review see (Becker & Becker 1999,
6
7 Bosshardt 2008, Caton 1997, Esposito et al. 2005, Froum et al. 2002, Gestrelus et
8
9 al. 2000, Jepsen et al. 2002, Murphy & Gunsolley 2003, Needleman et al. 2005,
10
11 Needleman et al. 2001, Needleman et al. 2006, Reddy & Jeffcoat 1999, Schallhorn &
12
13 McClain 1993, Sculean et al. 2008b).

14
15
16
17 In numerous studies it has been demonstrated that enamel matrix derivatives (EMD)
18
19 modulate the behavior of cells in stimulating proliferation, inducing production of
20
21 transforming growth factor β as well as interleukin-6 and differentiation of immature
22
23 cells *in vitro* (Foster et al. 2006, Foster et al. 2008, Giannobile & Somerman 2003,
24
25 Hakki et al. 2001, Lyngstadaas et al. 2001, Okubo et al. 2003, Sato et al. 2008,
26
27 Schwartz et al. 2000, Swanson et al. 2006, Tokiyasu et al. 2000, Van der Pauw et al.
28
29 2000)

30
31
32
33 EMD favor the formation of a new attachment apparatus *In vivo*, characterized by the
34
35 presence of acellular and cellular cementum with inserting collagen fibres and new
36
37 alveolar bone (Hammarstrom 1997, Hammarstrom et al. 1997, Heijl et al. 1997,
38
39 Jepsen et al. 2004, Meyle et al. 2004, Sculean et al. 2000, Sculean et al. 2001)

40
41
42
43 In several controlled clinical trials treatment of intrabony defects with EMD resulted in
44
45 significantly more attachment gain and bone fill than open flap debridement (Esposito
46
47 et al. 2005, Froum et al. 2001a, Froum et al. 2001b, Sanz et al. 2004, Tonetti et al.
48
49 2004a, Tonetti et al. 2004b, Tonetti et al. 2002). EMD was also successfully used in
50
51 class II furcation defects.. Compared with guided tissue regeneration EMD treatment
52
53 resulted in reduced postoperative swelling and pain (Jepsen et al. 2004, Meyle et al.
54
55 2004, Hoffmann et al. 2006).

56
57
58
59 In wider defects the viscous nature of EMD doesn't prevent the collapse of the soft
60
tissue flap into the defect. Therefore EMD have been combined with different space-

1
2
3 maintaining products (e.g. membranes or bone substitutes) in order to enhance the
4 space for periodontal regeneration (Donos et al. 2006, Dori et al. 2005, Pietruska
5
6
7
8
9
10
11 al. 2008b, Sculean et al. 2001, Trombelli & Farina 2008, Trombelli et al. 2002,
12
13 Zucchelli et al. 2003). Controlled clinical studies indicate that a combination of EMD
14
15 and bovine derived xenograft may enhance gain of clinical attachment (Lekovic et al.
16
17
18
19
20
21
22
23
24
25
26
27
28
29
30
31
32
33
34
35
36
37
38
39
40
41
42
43
44
45
46
47
48
49
50
51
52
53
54
55
56
57
58
59
60

maintaining products (e.g. membranes or bone substitutes) in order to enhance the space for periodontal regeneration (Donos et al. 2006, Dori et al. 2005, Pietruska 2001, Rosen & Reynolds 2002, Sculean et al. 2002, Sculean et al. 2003, Sculean et al. 2008b, Sculean et al. 2001, Trombelli & Farina 2008, Trombelli et al. 2002, Zucchelli et al. 2003). Controlled clinical studies indicate that a combination of EMD and bovine derived xenograft may enhance gain of clinical attachment (Lekovic et al. 2001, Zucchelli et al. 2002). It is still questionable, if graft materials are substituted by newly formed bone (Sculean et al. 2008c). Recently the combination of EMD with autogenous bone indicated that , this combined approach led to less recession as compared with EMD alone (Guida et al. 2007). Similar results were reported when EMD was compared with a bovine derived xenograft (Mellonig 2006, Velasquez-Plata et al. 2002). In a recent review it was concluded that the additional use of a graft (autogenous bone, DFDBA, BPBM, bioactive glass) seems to enhance the clinical outcome of EMD over EMD alone (Trombelli & Farina 2008).

Biphasic calcium phosphates have been used as bone substitutes in orthopedic, cranio/maxillofacial, oral and periodontal surgery and have been shown to be biocompatible, safe, and effective scaffolds for the formation of new bone (Daculsi et al. 1999, Nery et al. 1992, Piattelli et al. 1996). Preclinical evidence suggests that a biphasic calcium phosphate (BCP) with >99% cristallinity, consisting of 60% hydroxyapatite (HA) and 40% β -tri-calcium-phosphate (TCP) in particulate preparation may accelerate new bone formation (Nery et al. 1992).

In this study we compared the clinical and radiographic outcomes of EMD in combination with synthetic bone substitute or EMD alone in the treatment of wide intrabony defects after 12 months.

Materials and Methods

Experimental design

The amount of defect fill 6 and 12 months following two different regenerative treatments of 1- and 2- wall intrabony periodontal defects was studied in a randomized, prospective, multi-centre controlled clinical trial. Details of the study protocol, statistical analysis and clinical results after 6 months have been reported previously (Jepsen et al. 2008).

Briefly an access flap was prepared with papilla preservation (Cortellini et al. 1995, 1999). After debridement, removal of granulation tissue and remaining subgingival calculus, enamel matrix derivatives were applied (Straumann® Emdogain, Straumann, Basel, Switzerland) (EMD). Subsequently in the test group the defects were filled with a synthetic bone graft (Straumann® BoneCeramic, Straumann, Basel, Switzerland) (SBG), which had been mixed with EMD. In the controls EMD was used alone. The flap was repositioned and closed with monofilament synthetic non – resorbable 5-0 and 6-0 suturing material (Ethicon Prolene, Ethicon Products, Norderstedt, Germany). All patients were controlled after 3, 6, 9 and 12 months . No subgingival instrumentation was performed at the surgical site.

Five centers participated involving a total of five operators and five masked examiners connected with and supervised by a central monitoring facility at the Institut Straumann AG, Basel, Switzerland.

Subject population

For a detailed description see (Jepsen et al. 2008). The study was performed in compliance with Good Clinical Practice and the Declaration of Helsinki lastly revised in Edinburgh 2000; the study protocol was approved by the International Ethics Committee in Freiburg, Germany.

1
2
3 Only patients with a diagnosis of severe periodontitis and a radiographic intrabony
4 defect of at least 4 mm depth, and 2 mm width without furcation involvement were
5 included. Inclusion criteria were confirmed during surgery. Patients with uncontrolled
6 or poorly controlled diabetes, unstable or life-threatening conditions, current
7 pregnancy at the time of recruitment and smokers were not admitted. Only
8 occasional smoking (1 - 30 cigarettes/month) was allowed.
9

10 All patients went through initial treatment including repeated oral hygiene
11 instructions, professional tooth cleaning, and subgingival scaling and root planing.
12 Patients had to demonstrate a full mouth plaque index $\leq 25\%$ (O'Leary et al. 1972) at
13 least one time out of 2 examinations before inclusion. At least 2 sessions of oral
14 hygiene control were conducted.
15

16
17
18
19
20
21
22
23
24
25
26
27
28
29
30
31
32
33
34
35
36
37
38
39
40
41
42
43
44
45
46
47
48
49
50
51
52
53
54
55
56
57
58
59
60

75 patients gave informed consent and were enrolled. A randomization list was generated by an independent statistician based on 1 surgical site per patient for a total of 75 surgical sites. To conceal assignment the investigator was instructed to assign a previously supplied sealed envelope containing the treatment assignment to the specific patient. The original randomization allocation could not be used for a replacement patient.

Clinical measurements

Clinical outcomes were evaluated after 6 and 12 months. The 6 month results have been reported previously (Jepsen et al. 2008). All measurements were carried out using a customized acrylic stent with markings. Each of the centers had its own blinded and calibrated examiner. Full mouth plaque scores (O'Leary et al. 1972) were recorded as the percentage of total surfaces (six aspects per tooth) that revealed plaque. The primary outcome variable was the change in bone fill after 6 months as measured by bone sounding. Secondary outcomes, i.e. probing pocket depths

1
2
3 (PPD), relative attachment level (RAL) and gingival recessions (GR) were recorded
4
5 with a computerized constant force probe (Florida Probe[®], Gainesville, FL, USA) at
6
7 six sites per tooth. Bleeding on probing was recorded concomitantly with PPD, RAL,
8
9 and GR. All pocket depth and attachment measurements were adjusted to the
10
11 nearest 0.2 mm. Following local anesthesia, vertical defect fill, as determined by
12
13 bone sounding, was measured at the same six sites from the acrylic stent with a
14
15 manual probe (PCP-UNC 15, Hu-Friedy, Leimen, Germany).
16
17

18
19 During surgery width and depth of the intrabony defect was assessed with a manual
20
21 probe (PCP-UNC 15, Hu-Friedy, Leimen, Germany). The following assessments
22
23 were performed: 1) bone level (distance from stent to bottom of the defect); 2) defect
24
25 depth (distance bone crest to bottom of bone defect); 3) defect width (horizontally
26
27 from the bone crest at the experimental site in a direction towards the center of the
28
29 tooth) and; 4) determination of the defect type (1-wall, 2-wall, combined 1- and 2-wall
30
31 or circumferential). Any adverse effect or post-surgical complications were recorded
32
33 using a questionnaire.
34
35
36
37
38
39
40

41 **Radiographic examination**

42
43 75 pairs of intraoral periapical radiographs were obtained using XCP film holders
44
45 (Kentzler & Kaschner, Ellwangen, Germany) . The position of the film holder in
46
47 relation to the teeth was fixed by an impression of elastic silicone. Film size (0 or 2)
48
49 and exposure time were chosen according to tooth type. The radiographs were
50
51 obtained immediately prior to and 12 months after surgery using F-speed films
52
53 (Insight, Kodac, Rochester, CT, USA).
54
55
56
57
58
59

60 **Radiographic evaluation**

1
2
3 All radiographs were sorted in random order and numbered from 1 to 150 by the
4 investigator of the radiographic analysis (P.E.), who also determined the coronal
5 landmark (CEJ or restoration margin: RM). All radiographs where the anatomical
6 landmarks or the defects could not be properly identified were excluded.
7

8
9
10 Radiographs were digitized using a computer program (SIDEXIS nextGeneration
11 1.51, Sirona, Bensheim, Germany) and a flatbed scanner (Microtek ScanMaker 4,
12 Microtek, Hsinchu, Taiwan) with 600dpi resolution and 8 bit grey values. The data
13 were stored as TIFF files and analysed by the examiner using the computer program
14 SIDEXIS and a 19" flat screen (Totoku CCL 192 plus, Totoku Electric, Ueda, Japan)
15 in a dark room.
16
17

18
19
20 Analysis started with number 1 in the order given by one examiner (C.M.) who was
21 blinded to the clinical results and to the time point the particular radiographs had
22 been taken (baseline, 12 months) (Eickholz et al. 2004a, Eickholz et al. 2004b, Klein
23 et al. 2001). Each radiograph was identified by its number.
24
25

26
27 For evaluation the analysing tool of the program SIDEXIS was used. The images
28 were magnified once using the "zoom" function. Then the distances CEJ/RM to
29 alveolar crest (AC), CEJ/RM to DB, the depth of the intrabony component (INTRA),
30 and the angle between root surface and lateral bone wall were measured (Figure 1
31 and 2). If radiographs were too dark or had too low contrast to identify landmarks the
32 examiner was allowed to adjust brightness and contrast. If basic image enhancement
33 functions (brightness, contrast) were insufficient to make landmarks visible the
34 examiner was instructed to exclude these images from analysis.
35
36
37
38
39
40
41
42
43
44
45
46
47
48
49
50
51
52
53

54 55 56 57 **Definition of radiographic landmarks**

58
59 The radiographic landmarks were defined as follows: if the CEJ was destroyed by
60 restorative treatment it was replaced by the margin of the restoration (RM) (Fig. 2a).

1
2
3 BD was defined as most coronal point where the periodontal ligament space showed
4 a continuous width (Fig. 1). If no periodontal ligament space could be identified, the
5 point where the projection of the AC crossed the root surface was used (Benn 1992).
6
7
8 If both structures could be identified, the point defined by the periodontal ligament
9 was used as BD and the crossing of the silhouette of the alveolar crest with the root
10 surface was defined as AC. If several bony contours could be identified, the most
11 apical one that crossed the root was defined as the BD and the most coronal one as
12 AC (Eickholz et al. 1996). For all intrabony defects the distances CEJ/RM to AC and
13 CEJ/RM to BD were measured using the measurement tool (Fig. 2a, b), also a first
14 auxiliary line (AUX1) was drawn to represent the tooth axis (Fig. 2c). Then using the
15 angle function a 90° angle was drawn with AUX1 as one leg. This angle was moved
16 along AUX1 until the other leg (AUX2) ran through the most coronal margin of the
17 intrabony defect (M3) (Fig. 1a, 2c). The depth of the intrabony defect (INTRA) was
18 measured as distance between BD and the crossing of the silhouette of the root
19 surface and AUX 2 (Fig. 2c). Using the function "angle" the width of the intrabony
20 defect was assessed as an angle. One leg of this angle ran through BD and M3, the
21 other through BD and CEJ/RM (Klein et al. 2001, Eickholz et al. 2004a,b, Pretzl et al.
22 2009) (Fig. 2d).

23
24
25
26
27
28
29
30
31
32
33
34
35
36
37
38
39
40
41
42
43
44
45 To assess intraindividual reproducibility measurements were repeated in 20
46 radiographs (approximately each 10th radiograph) after all radiographs had been
47 evaluated once.

48
49
50
51
52 Both (investigator and examiner of the radiographic analysis) were blinded for the
53 clinical parameters and treatment assignment as well as the time point the
54 radiographs had been taken (baseline, 12 months). Using 20 radiographs of
55 intrabony defects unrelated to this study the examiner was calibrated prior to
56 evaluation by the investigator of the radiographic analysis in finding the anatomical
57
58
59
60

1
2
3 landmarks and measurement of respective distances. Both evaluated the 20
4 radiographs (measurement of CEJ/RM-BD, CEJ/RM-AC, INTRA, angle) and
5
6
7 repeated all measurements approximately 2 weeks later.
8
9

13 **Data management and statistical analysis of clinical data**

14
15 Statistical management of data for the 6 months results has been reported previously
16
17 (Jepsen et al. 2008). Statistical analysis after 12 months was mostly of descriptive
18
19 nature. Based on the study protocol testing the hypothesis of non-inferiority of
20
21 EMD/SBG compared with EMD had been performed after 6 months. Two patients -
22
23 one in each group – dropped out prematurely. As no data for the efficacy variable
24
25 was available after baseline (surgery), these two could not be considered for analysis
26
27 according to the intention-to-treat-principle. Hence, the data analysis had to be
28
29 limited to 73 subjects. For data processing and statistical evaluation, appropriate
30
31 validated software was used (SPSS software package, version 13, SPSS, Chicago,
32
33 IL, USA).
34
35
36
37

38
39 The primary outcome variable was the change in defect fill recorded by bone
40
41 sounding 6 months after surgery. Bone sounding values at baseline and after 12
42
43 months were compared by t-test in both treatment groups. Mean changes and 95%
44
45 confidence intervals were computed.
46
47

48
49 Secondary variables included RAL, PPD 12 months after surgery, which were
50
51 compared descriptively between the treatment groups. Secondary variables were
52
53 also the differences between the distances from the cemento enamel junction (CEJ)
54
55 to the most apical extension of the bony defect (BD) on radiographs obtained prior to
56
57 and 12 months after surgery. All radiographic measurements were entered in a
58
59 database (MS Excel 2000, Microsoft Co., Redmond, WA, USA) and transferred to an
60
independent statistician. Intraindividual reproducibility was calculated for both

1
2
3 examiners as standard deviation of single measurements (Cohen & Ralls 1988). For
4
5 the distances CEJ/RM-BD, CEJ/RM-AC, and INTRA the interindividual reproducibility
6
7 was assessed as amount of differences > 1.0 mm.
8
9

10 The patient was looked upon as statistical unit. The outcome variable of the
11
12 radiographic evaluation was the difference between the distance CEJ/RM to BD at
13
14 baseline and 12 month after surgery (absolute defect fill). Baseline and 12 months
15
16 results were compared using the Wilcoxon test. Between groups differences (EMD
17
18 vs. EMD/SBG) were tested using the Mann Whitney U test. Factors influencing
19
20 defect fill (change of distance CEJ/RM-BD from baseline to 12 months after therapy)
21
22 were identified using multiple linear regression analysis including the following
23
24 independent variables: therapy (EMD vs. EMD/SBG), baseline INTRA, baseline
25
26 defect angle. The full analysis was described in detail in a specific statistical analysis
27
28 plan before unblinding data. The significance level was set at $p < 0.05$.
29
30
31
32
33
34
35
36
37
38
39
40
41
42
43
44
45
46
47
48
49
50
51
52
53
54
55
56
57
58
59
60

Results

Patient and defect characteristics

This study was conducted in five study centres comprising 73 patients. No center effects could be demonstrated. The per protocol population consisted of 23 men and 50 women, with a mean age of 46.9 years (median 48.2; range 21.1 to 66.7 years), 12 of the patients were occasional smokers. The six month data have been reported previously (Jepsen et al. 2008).

Clinical outcomes

Both treatment modalities led to significant improvements measured by bone sounding. The mean defect fill in the EMD/SBG group was 2.7 mm [95%CI (2.03 – 3.26), $p < 0.001$, t-test), and 2.8 mm [95%CI (2.26 – 3.36), $p < 0.001$, t-test) in the EMD group (Table 1). Bone gain in the combined treatment group showed a higher variability as indicated by a higher standard deviation. A reduction of PPD was found after the combined treatment (2.8 ± 2.1 mm; $p < 0.001$, t-test) as well as after EMD alone (2.9 ± 1.8 mm; $p < 0.001$, t-test). In the test group a mean gain of attachment of 1.7 ± 2.1 mm ($p < 0.001$, t-test) was observed and in the control group of 1.9 ± 1.7 mm ($p < 0.001$, t-test). In the EMD/SBG treated group mean gingival recessions increased by 1.1 ± 1.3 mm and in the control group (EMD) by 1.0 ± 1.1 mm (Table 1). Both therapies resulted in significant reductions of PPD and gain of attachment. Between groups no differences were found for any of the variables as well as for the changes of each variable. As compared with the 6-month data a slight (insignificant) increase in attachment gain (EMD: 1.8 to 1.9 mm and EMD/SBG 1.3 to 1.7 mm) and pocket reduction (EMD: 2.6 to 2.9 mm and EMD/SBG 1.9 to 2.8 mm) was observed. Full mouth plaque scores ranged between 12.2% and 14.5% at all time points with no significant differences between groups (Table 2). At baseline local plaque scores at

1
2
3 the experimental sites were 10 of 37 (27.0%) in the EMD/SBG group and 4 of 35
4 sites (11.4 %) in the EMD group. Twelve months after surgery the respective values
5 were 7 of 37 (18.9%; EMD/SBG) and 5 of 35 (14.3%; EMD). These differences were
6 not statistically significant (Fisher's exact test (two-sided)).
7
8
9

10
11
12 As regards patient-centered outcomes and evaluation of adverse effects of
13 regenerative treatment, favourable results have been reported previously (Jepsen et
14 al. 2008).
15
16
17
18
19

20 21 **Radiographic outcomes**

22 During radiographic analysis 3 pairs of radiographs were excluded because of
23 excentric projection and overlapping of crowns. One pair of radiographs was not
24 evaluated, because the 12 months radiograph exhibited a bending mark within the
25 defect and another pair could not be evaluated because the 12 months radiograph
26 was lost. Finally a total of 136 radiographs (68 pairs) were analysed.
27
28
29

30 Intraindividual reproducibility of calibration measurements assessed as standard
31 deviations of single measurements was 0.27 mm (CEJ/RM-BD), 0.49 mm (CEJ/RM-
32 AC), 0.25 mm (INTRA), and 1.22° (angle), respectively. Intraindividual reproducibility
33 for the investigational radiographs was 0.46 mm (CEJ/RM-BD), 0.34 mm (CEJ/RM-
34 AC), 0.44 mm (INTRA), and 4.21° (angle), respectively.
35
36
37

38 Some minor differences in defect fill were observed depending upon the topography
39 (Figure 3a, b). In circumferential defects the variation was higher than in others
40 without reaching statistical significance. Both treatment modalities resulted in
41 significant defect fill. This led to a significant ($p < 0.001$) reduction of CEJ/RM-BD
42 (EMD/SBG: 1.77 ± 1.92 mm; EMD: 1.40 ± 1.93 mm) and INTRA (EMD/SBG: 2.19 ± 2.21
43 mm; EMD: 1.49 ± 1.89 mm), which was also reflected in a significant ($p < 0.01$)
44 increase of the defect angle (EMD/SBG: $9.0 \pm 14.4^\circ$; EMD: $6.7 \pm 13.0^\circ$). However,
45
46
47
48
49
50
51
52
53
54
55
56
57
58
59
60

1
2
3 statistical analysis failed to reveal differences between both treatment modalities
4
5 (Tab. 3). Multiple linear regression analysis identified only baseline INTRA to
6
7 influence bone fill, i.e. the deeper the defect the more defect fill may be expected
8
9 (Tab. 4).
10
11

12 13 14 15 **Discussion**

16 17 ***Clinical results***

18
19 The results of the present, randomized–controlled trial demonstrate favourable
20
21 outcomes after 12 months.
22
23

24 Both treatment modalities resulted in statistically significant defect fill with significant
25
26 reductions of the distance from apical to coronal radiological landmarks as well as
27
28 the intraosseous depth of defect, which was also reflected in an increase of the
29
30 defect angle.. No differences were found between treatment modalities.
31
32
33

34
35
36 The results of the present investigation are confirmed by several other studies and
37
38 systematic reviews (Esposito et al. 2005, Francetti et al. 2005, Froum et al. 2001b,
39
40 Pontoriero et al. 1999, Sculean et al. 2008a, Tonetti et al. 2002, Wachtel et al. 2003).
41
42 In 2008 Sculean demonstrated that the treatment of intrabony defects with enamel
43
44 matrix proteins may result in a reduction of pocket probing depth and gain of clinical
45
46 attachment, which could be maintained over a period of 10 years. The present results
47
48 confirm that after 12 months significant improvements in clinical parameters can be
49
50 obtained in 1- and 2-wall intrabony defects after treatment with enamel matrix
51
52 proteins and a bone replacement graft. Since hard tissue fill is the only component of
53
54 regenerated peridontium which can be assessed clinically, bone sounding was
55
56 performed and served as primary outcome variable (Machtei 1997).
57
58
59
60

1
2
3 Osseous regeneration after treatment with EMD in combination with a biphasic
4 calcium phosphate in humans requires more than 9 months as outlined in a human
5 histological analysis by (Sculean et al. 2008c).
6
7

8
9
10 Lekovic (2000) reported about significant improvements if EMD were combined with
11 bovine porous bone mineral. The improvements were observed on the buccal and
12 lingual sites despite the fact that interproximal defects were treated (Lekovic et al.
13 2000). In 2003 Zucchelli et al. reported about significantly greater attachment gain
14 and bone gain with a combination of EMD and bone mineral (Zucchelli et al. 2003). It
15 is obvious that the defect characteristics were different from our study. The authors
16 reported about a mean intrabony defect depth of 6.8 mm whereas in our study this
17 was 5.9 and 5.6 mm respectively. In other trials only slight differences between the 2
18 treatment groups (EMD versus EMD+SBG) were observed (Bokan et al. 2006) A
19 systematic review has shown that clinical parameters are improved when intrabony
20 defects are treated with bone fillers (Reynolds et al. 2003). Similar results were
21 described by Yilmaz et al. (2010), who compared EMD combined with/without
22 autogenous bone in two to three wall intrabony defects (Yilmaz et al. 2010). They
23 reported about a small but significantly higher gain of relative attachment level. In
24 general it appears that the combination of EMD with bone grafts or autogenous bone
25 seems to be more favourable than a combination of EMD with barrier membranes if
26 intrabony lesions are treated (Tu et al. 2010).
27
28
29
30
31
32
33
34
35
36
37
38
39
40
41
42
43
44
45
46
47
48
49

50 According to our data in wide 1-wall and 2-wall defects the effect of EMD can not be
51 improved by adding a SBG. After 12 months there was no substantial improvement
52 as compared with 6 month data (Jepsen et al. 2008).
53
54
55
56

57 ***Radiographic results***

58 For calibration the radiographic examiner achieved better reproducibility than during
59 evaluation of the investigational radiographs. The radiographs chosen for training
60

1
2
3 and calibration were of optimal and in some cases better quality than the
4
5 investigational radiographs regarding projection, brightness, and contrast. This may
6
7 explain the differences.
8

9
10 However, the intraindividual reproducibility of the measurement of the distance
11
12 CEJ/RM-AC with a standard deviation of single measurements of 0.34 mm was
13
14 comparable or better than measurement errors reported by other authors (Hausmann
15
16 et al. 1989, Benn 1992, Wolf et al. 2001: 0.35-0.56 mm). For the assessment of the
17
18 distance CEJ/RM-BD only within intrabony defects the measurement error was also
19
20 comparable or better (Wolf et al. 2001: 0.70-0.82 mm). The computer-assisted
21
22 method has been used before for the evaluation of regenerative therapy (Pretzl et al.
23
24 2009) and demonstrated good validity as compared to the gold standard of
25
26 intrasurgical assessments (Tihanyi et al. 2011).
27
28
29

30
31 Radiographic defect fill as evidenced by reduction of the distances CEJ/RM-BD
32
33 (EMD/SBG: 1.77 mm, EMD: 1.40 mm) and INTRA (EMD/SBG: 2.19±2.21 mm; EMD:
34
35 1.49±1.89 mm) 12 months after therapy corresponds well to results reported 12
36
37 months after GTR therapy of intrabony defects with non-resorbable barriers
38
39 (CEJ/RM-BD: ePTFE: 1.9 mm [Eickholz et al. 1998]) as well as with resorbable
40
41 membranes (CEJ/RM-BD: Polyglactin 910: 1.4 mm [Eickholz et al. 1998].
42
43
44

45
46 Eight and 16 months after use of EMD in 1- and 2-walled intrabony defects
47
48 radiographic bone gain of 0.9 mm and 2.2 mm was reported (Heijl et al. 1997). Better
49
50 radiographic defect fill was observed 12 months after therapy of 3-wall intrabony
51
52 defects with non-resorbable barriers or EMD (ePTFE: 2.9 mm, EMD: 2.4 mm [Crea et
53
54 al. 2009]). Comparison of these results is difficult. Reduction of the distance CEJ/RM-
55
56 BD represents exclusively defect fill, whereas reduction of INTRA represents levelling
57
58 of the defect due to a combination of apical defect fill and marginal resorption. From
59
60 a technical point of view radiographic changes are more trustworthy if they were

1
2
3 obtained with individual stent film holders as in this study (Eickholz et al. 1998, Pretzl
4 et al. 2009, Crea et al. 2009).

5
6
7
8 Not only after 6 but also after 12 months the data support the effectiveness and
9 safety of regenerative procedures based on EMD application..The differences in
10 attachment gain between our study and previous investigations can easily be
11 explained by defect topography: in our study wide (≥ 2 mm) non contained (1- and 2-
12 walled) intrabony defects were treated.
13
14
15
16
17
18

21 22 **Source of funding**

23
24 This study was supported by the Institut Straumann AG, Basel, Switzerland. Study
25 design and development of protocol were performed in teamwork between the
26 investigators of the five participating centers and an independent statistician. Authors
27 had full control of the data and analyses and received no commercial input in the
28 preparation of the paper.
29
30
31
32
33
34
35

36 37 **Acknowledgements**

38 The authors wish to thank Mrs. Daniela Michel for her professional study monitoring,
39 Dr. Michael Hotze for his effective study management and Dr. Manfred Klasser for
40 his expert statistical support.
41
42
43
44
45
46
47
48
49
50
51
52
53
54
55
56
57
58
59
60

Legends

Figure 1a: Maxillary left second premolar at baseline (cemento enamel junction: CEJ; alveolar crest: AC; most apical extension of bony defect: BD; most coronal extension of bone wall: M3).

Figure 1b: The same tooth 12 months after surgery: complete defect fill of defect

Figure 2: Identification of landmarks for the evaluation of defect healing, **Fig. 2a:** Distance restoration margin (RM) to AC; **2b:** Distance RM to BD **2c:** definition of "INTRA"; **2d:** definition and assessment of defect angle (for details see text)

Figure 3: Defect fill (measured as differences in bone sounding) in millimeters at the test sites after 12 months Tuckey plots (25% and 75% percentiles and standard deviations).

1-w: predominantly 1-wall defect (>2/3); 2-w: predominantly 2-wall defect (>2/3); comb: combined 1-wall and 2-wall defect; circum: circumferential defect; number of defects in parentheses.

3a: Regenerative treatment with Emdogain (EMD)

3b: Regenerative treatment with Emdogain and synthetic bone ceramics (EMD/SBG)

References

- 1
2
3
4
5
6
7
8
9
10
11
12
13
14
15
16
17
18
19
20
21
22
23
24
25
26
27
28
29
30
31
32
33
34
35
36
37
38
39
40
41
42
43
44
45
46
47
48
49
50
51
52
53
54
55
56
57
58
59
60
- Becker, W. & Becker, B.E. (1999) Periodontal regeneration: a contemporary re-evaluation. *Periodontol* 2000 19, 104-114.
- Bokan, I., Bill, J.S. & Schlagenhauf, U. (2006) Primary flap closure combined with Emdogain alone or Emdogain and Cerasorb in the treatment of intra-bony defects. *J Clin Periodontol* 33, 885-893.
- Bosshardt, D.D. (2008) Biological mediators and periodontal regeneration: a review of enamel matrix proteins at the cellular and molecular levels. *J Clin Periodontol* 35, 87-105.
- Caton, J.G. (1997) Overview of clinical trials on periodontal regeneration. *Ann Periodontol* 2, 215-222.
- Cohen, M.E. & Ralls, S.A. (1988) False positive rates in the determination of changes in probing depth-related periodontal measurements. *J Periodontal Res* 23, 161-165.
- Cortellini, P., Prato, G.P. & Tonetti, M.S. (1995) The modified papilla preservation technique. A new surgical approach for interproximal regenerative procedures. *Journal of Periodontology* 66, 261-266.
- Cortellini, P., Prato, G.P. & Tonetti, M.S. (1999) The simplified papilla preservation flap. A novel surgical approach for the management of soft tissues in regenerative procedures. *Int.J.Periodontics.Restorative.Dent.* 19, 589-599.
- Daculsi, G., Weiss, P., Bouler, J.M., Gauthier, O., Millot, F. & Aguado, E. (1999) Biphasic calcium phosphate/hydrosoluble polymer composites: a new concept for bone and dental substitution biomaterials. *Bone* 25, 59S-61S.
- Donos, N., Kostopoulos, L., Tonetti, M., Karring, T. & Lang, N.P. (2006) The effect of enamel matrix proteins and deproteinized bovine bone mineral on heterotopic bone formation. *Clin Oral Implants Res* 17, 434-438.
- Dori, F., Arweiler, N., Gera, I. & Sculean, A. (2005) Clinical evaluation of an enamel matrix protein derivative combined with either a natural bone mineral or beta-tricalcium phosphate. *J Periodontol* 76, 2236-2243.
- Eickholz, P., Benn, D.K. & Staehle, H.J. (1996) Radiographic evaluation of bone regeneration following periodontal surgery with or without expanded polytetrafluoroethylene barriers. *J Periodontol* 67, 379-385.
- Eickholz, P., Horr, T., Klein, F., Hassfeld, S. & Kim, T.S. (2004a) Radiographic parameters for prognosis of periodontal healing of infrabony defects: two different definitions of defect depth. *J Periodontol* 75, 399-407.
- Eickholz, P., Krigar, D.M., Pretzl, B., Steinbrenner, H., Dorfer, C. & Kim, T.S. (2004b) Guided tissue regeneration with bioabsorbable barriers. II. Long-term results in infrabony defects. *J Periodontol* 75, 957-965.
- Esposito, M., Grusovin, M.G., Coulthard, P. & Worthington, H.V. (2005) Enamel matrix derivative (Emdogain) for periodontal tissue regeneration in intrabony defects. *Cochrane Database Syst Rev*, CD003875.
- Foster, B.L., Nociti, F.H., Jr., Swanson, E.C., Matsa-Dunn, D., Berry, J.E., Cupp, C.J., Zhang, P. & Somerman, M.J. (2006) Regulation of cementoblast gene expression by inorganic phosphate in vitro. *Calcif Tissue Int* 78, 103-112.
- Foster, B.L., Tompkins, K.A., Rutherford, R.B., Zhang, H., Chu, E.Y., Fong, H. & Somerman, M.J. (2008) Phosphate: known and potential roles during development and regeneration of teeth and supporting structures. *Birth Defects Res C Embryo Today* 84, 281-314.
- Francetti, L., Trombelli, L., Lombardo, G., Guida, L., Cafiero, C., Rocuzzo, M., Carusi, G. & Del Fabbro, M. (2005) Evaluation of efficacy of enamel matrix

- 1
2
3 derivative in the treatment of intrabony defects: a 24-month multicenter study.
4 Int J Periodontics Restorative Dent 25, 461-473.
- 5 Froum, S., Lemler, J., Horowitz, R. & Davidson, B. (2001a) The use of enamel matrix
6 derivative in the treatment of periodontal osseous defects: a clinical decision
7 tree based on biologic principles of regeneration.
8 Int.J.Periodontics.Restorative.Dent. 21, 437-449.
- 9 Froum, S.J., Gomez, C. & Breault, M.R. (2002) Current concepts of periodontal
10 regeneration. A review of the literature. N Y State Dent J 68, 14-22.
- 11 Froum, S.J., Weinberg, M.A., Rosenberg, E. & Tarnow, D. (2001b) A comparative
12 study utilizing open flap debridement with and without enamel matrix
13 derivative in the treatment of periodontal intrabony defects: a 12-month re-
14 entry study. Journal of Periodontology 72, 25-34.
- 15 Gestrelus, S., Lyngstadaas, S.P. & Hammarstrom, L. (2000) Emdogain--periodontal
16 regeneration based on biomimicry. Clin.Oral Investig. 4, 120-125.
- 17 Giannobile, W.V. & Somerman, M.J. (2003) Growth and amelogenin-like factors in
18 periodontal wound healing. A systematic review. Ann Periodontol 8, 193-204.
- 19 Guida, L., Annunziata, M., Belardo, S., Farina, R., Scabbia, A. & Trombelli, L. (2007)
20 Effect of autogenous cortical bone particulate in conjunction with enamel
21 matrix derivative in the treatment of periodontal intraosseous defects. J
22 Periodontol 78, 231-238.
- 23 Hakki, S.S., Berry, J.E. & Somerman, M.J. (2001) The effect of enamel matrix protein
24 derivative on follicle cells in vitro. Journal of Periodontology 72, 679-687.
- 25 Hammarstrom, L. (1997) Enamel matrix, cementum development and regeneration. J
26 Clin Periodontol 24, 658-668.
- 27 Hammarstrom, L., Heijl, L. & Gestrelus, S. (1997) Periodontal regeneration in a
28 buccal dehiscence model in monkeys after application of enamel matrix
29 proteins. J Clin Periodontol 24, 669-677.
- 30 Heijl, L., Heden, G., Svardstrom, G. & Ostgren, A. (1997) Enamel matrix derivative
31 (EMDOGAIN) in the treatment of intrabony periodontal defects. Journal of
32 Clinical Periodontology 24, 705-714.
- 33 Jepsen, S., Eberhard, J., Herrera, D. & Needleman, I. (2002) A systematic review of
34 guided tissue regeneration for periodontal furcation defects. What is the effect
35 of guided tissue regeneration compared with surgical debridement in the
36 treatment of furcation defects? J Clin Periodontol 29 Suppl 3, 103-116;
37 discussion 160-102.
- 38 Jepsen, S., Heinz, B., Jepsen, K., Arjomand, M., Hoffmann, T., Richter, S., Reich, E.,
39 Sculean, A., Gonzales, J.R., Bodeker, R.H. & Meyle, J. (2004) A randomized
40 clinical trial comparing enamel matrix derivative and membrane treatment of
41 buccal Class II furcation involvement in mandibular molars. Part I: Study
42 design and results for primary outcomes. J Periodontol. 75, 1150-1160.
- 43 Jepsen, S., Topoll, H., Rengers, H., Heinz, B., Teich, M., Hoffmann, T., Al-Machot,
44 E., Meyle, J. & Jervoe-Storm, P.M. (2008) Clinical outcomes after treatment of
45 intra-bony defects with an EMD/synthetic bone graft or EMD alone: a
46 multicentre randomized-controlled clinical trial. J Clin Periodontol 35, 420-428.
- 47 Klein, F., Kim, T.S., Hassfeld, S., Staehle, H.J., Reitmeir, P., Holle, R. & Eickholz, P.
48 (2001) Radiographic defect depth and width for prognosis and description of
49 periodontal healing of infrabony defects. J Periodontol 72, 1639-1646.
- 50 Lekovic, V., Camargo, P.M., Weinlaender, M., Nedic, M., Aleksic, Z. & Kenney, E.B.
51 (2000) A comparison between enamel matrix proteins used alone or in
52 combination with bovine porous bone mineral in the treatment of intrabony
53 periodontal defects in humans. J Periodontol 71, 1110-1116.
- 54
55
56
57
58
59
60

- 1
2
3 Lekovic, V., Camargo, P.M., Weinlaender, M., Vasilic, N., Djordjevic, M. & Kenney,
4 E.B. (2001) The use of bovine porous bone mineral in combination with
5 enamel matrix proteins or with an autologous fibrinogen/fibronectin system in
6 the treatment of intrabony periodontal defects in humans. *Journal of*
7 *Periodontology* 72, 1157-1163.
- 9 Lyngstadaas, S.P., Lundberg, E., Ekdahl, H., Andersson, C. & Gestrelus, S. (2001)
10 Autocrine growth factors in human periodontal ligament cells cultured on
11 enamel matrix derivative. *Journal of Clinical Periodontology* 28, 181-188.
- 13 Machtei, E.E. (1997) Outcome variables for the study of periodontal regeneration.
14 *Annals of Periodontology* 2, 229-239.
- 15 Mellonig, J.T. (2006) Histologic and clinical evaluation of an allogeneic bone matrix
16 for the treatment of periodontal osseous defects. *Int J Periodontics Restorative*
17 *Dent* 26, 561-569.
- 18 Meyle, J., Gonzales, J.R., Bodeker, R.H., Hoffmann, T., Richter, S., Heinz, B.,
19 Arjomand, M., Reich, E., Sculean, A., Jepsen, K. & Jepsen, S. (2004) A
20 randomized clinical trial comparing enamel matrix derivative and membrane
21 treatment of buccal class II furcation involvement in mandibular molars. Part II:
22 secondary outcomes. *J Periodontol.* 75, 1188-1195.
- 24 Murphy, K.G. & Gunsolley, J.C. (2003) Guided tissue regeneration for the treatment
25 of periodontal intrabony and furcation defects. A systematic review. *Ann*
26 *Periodontol* 8, 266-302.
- 28 Needleman, I., Tucker, R., Giedrys-Leeper, E. & Worthington, H. (2005) Guided
29 tissue regeneration for periodontal intrabony defects--a Cochrane Systematic
30 Review. *Periodontol* 2000 37, 106-123.
- 32 Needleman, I.G., Giedrys-Leeper, E., Tucker, R.J. & Worthington, H.V. (2001)
33 Guided tissue regeneration for periodontal infra-bony defects. *Cochrane*
34 *Database Syst Rev*, CD001724.
- 35 Needleman, I.G., Worthington, H.V., Giedrys-Leeper, E. & Tucker, R.J. (2006)
36 Guided tissue regeneration for periodontal infra-bony defects. *Cochrane*
37 *Database Syst Rev*, CD001724.
- 39 Nery, E.B., LeGeros, R.Z., Lynch, K.L. & Lee, K. (1992) Tissue response to biphasic
40 calcium phosphate ceramic with different ratios of HA/beta TCP in periodontal
41 osseous defects. *J Periodontol* 63, 729-735.
- 43 O'Leary, T.J., Drake, R.B. & Naylor, J.E. (1972) The plaque control record. *Journal of*
44 *Periodontology* 43, 38.
- 45 Okubo, K., Kobayashi, M., Takiguchi, T., Takada, T., Ohazama, A., Okamatsu, Y. &
46 Hasegawa, K. (2003) Participation of endogenous IGF-I and TGF-beta 1 with
47 enamel matrix derivative-stimulated cell growth in human periodontal ligament
48 cells. *Journal of Periodontal Research* 38, 1-9.
- 49 Piattelli, A., Scarano, A. & Mangano, C. (1996) Clinical and histologic aspects of
50 biphasic calcium phosphate ceramic (BCP) used in connection with implant
51 placement. *Biomaterials* 17, 1767-1770.
- 53 Pietruska, M.D. (2001) A comparative study on the use of Bio-Oss and enamel matrix
54 derivative (Emdogain) in the treatment of periodontal bone defects. *Eur.J.Oral*
55 *Sci.* 109, 178-181.
- 56 Pontoriero, R., Wennstrom, J.L. & Lindhe, J. (1999) The use of barrier membranes
57 and enamel matrix proteins in the treatment of angular bone defects. A
58 prospective controlled clinical study. *Journal of Clinical Periodontology* 26,
59 833-840.
- 60 Reddy, M.S. & Jeffcoat, M.K. (1999) Methods of assessing periodontal regeneration.
Periodontol 2000 19, 87-103.

- 1
2
3 Reynolds, M.A., Aichelmann-Reidy, M.E., Branch-Mays, G.L. & Gunsolley, J.C.
4 (2003) The efficacy of bone replacement grafts in the treatment of periodontal
5 osseous defects. A systematic review. *Ann Periodontol* 8, 227-265.
- 6
7 Rosen, P.S. & Reynolds, M.A. (2002) A retrospective case series comparing the use
8 of demineralized freeze-dried bone allograft and freeze-dried bone allograft
9 combined with enamel matrix derivative for the treatment of advanced
10 osseous lesions. *Journal of Periodontology* 73, 942-949.
- 11
12 Sanz, M., Tonetti, M.S., Zabalegui, I., Sicilia, A., Blanco, J., Rebelo, H., Rasperini,
13 G., Merli, M., Cortellini, P. & Suvan, J.E. (2004) Treatment of intrabony defects
14 with enamel matrix proteins or barrier membranes: results from a multicenter
15 practice-based clinical trial. *J Periodontol* 75, 726-733.
- 16
17 Sato, S., Kitagawa, M., Sakamoto, K., Iizuka, S., Kudo, Y., Ogawa, I., Miyauchi, M.,
18 Chu, E.Y., Foster, B.L., Somerman, M.J. & Takata, T. (2008) Enamel matrix
19 derivative exhibits anti-inflammatory properties in monocytes. *J Periodontol*
20 79, 535-540.
- 21
22 Schallhorn, R.G. & McClain, P.K. (1993) Periodontal regeneration using combined
23 techniques. *Periodontol* 2000 1, 109-117.
- 24
25 Schwartz, Z., Carnes, D.L., Jr., Pulliam, R., Lohmann, C.H., Sylvia, V.L., Liu, Y.,
26 Dean, D.D., Cochran, D.L. & Boyan, B.D. (2000) Porcine fetal enamel matrix
27 derivative stimulates proliferation but not differentiation of pre-osteoblastic 2T9
28 cells, inhibits proliferation and stimulates differentiation of osteoblast-like
29 MG63 cells, and increases proliferation and differentiation of normal human
30 osteoblast NHOst cells. *Journal of Periodontology* 71, 1287-1296.
- 31
32 Sculean, A., Barbe, G., Chiantella, G.C., Arweiler, N.B., Berakdar, M. & Brex, M.
33 (2002) Clinical evaluation of an enamel matrix protein derivative combined
34 with a bioactive glass for the treatment of intrabony periodontal defects in
35 humans. *Journal of Periodontology* 73, 401-408.
- 36
37 Sculean, A., Berakdar, M., Chiantella, G.C., Donos, N., Arweiler, N.B. & Brex, M.
38 (2003) Healing of intrabony defects following treatment with a bovine-derived
39 xenograft and collagen membrane. A controlled clinical study. *J Clin*
40 *Periodontol* 30, 73-80.
- 41
42 Sculean, A., Donos, N., Brex, M., Reich, E. & Karring, T. (2000) Treatment of
43 intrabony defects with guided tissue regeneration and enamel-matrix-proteins.
44 An experimental study in monkeys. *Journal of Clinical Periodontology* 27, 466-
45 472.
- 46
47 Sculean, A., Kiss, A., Miliauskaite, A., Schwarz, F., Arweiler, N.B. & Hannig, M.
48 (2008a) Ten-year results following treatment of intra-bony defects with enamel
49 matrix proteins and guided tissue regeneration. *J Clin Periodontol* 35, 817-
50 824.
- 51
52 Sculean, A., Nikolidakis, D. & Schwarz, F. (2008b) Regeneration of periodontal
53 tissues: combinations of barrier membranes and grafting materials - biological
54 foundation and preclinical evidence: a systematic review. *J Clin Periodontol*
55 35, 106-116.
- 56
57 Sculean, A., Windisch, P., Chiantella, G.C., Donos, N., Brex, M. & Reich, E. (2001)
58 Treatment of intrabony defects with enamel matrix proteins and guided tissue
59 regeneration. A prospective controlled clinical study. *Journal of Clinical*
60 *Periodontology* 28, 397-403.
- Sculean, A., Windisch, P., Szendroi-Kiss, D., Horvath, A., Rosta, P., Becker, J., Gera,
I. & Schwarz, F. (2008c) Clinical and histologic evaluation of an enamel matrix
derivative combined with a biphasic calcium phosphate for the treatment of
human intrabony periodontal defects. *J Periodontol* 79, 1991-1999.

- 1
2
3 Swanson, E.C., Fong, H.K., Foster, B.L., Paine, M.L., Gibson, C.W., Snead, M.L. &
4 Somerman, M.J. (2006) Amelogenins regulate expression of genes associated
5 with cementoblasts in vitro. *Eur J Oral Sci* 114 Suppl 1, 239-243; discussion
6 254-236, 381-232.
- 7
8 Tokiyasu, Y., Takata, T., Saygin, E. & Somerman, M. (2000) Enamel factors regulate
9 expression of genes associated with cementoblasts. *Journal of Periodontology*
10 71, 1829-1839.
- 11 Tonetti, M.S., Cortellini, P., Lang, N.P., Suvan, J.E., Adriaens, P., Dubravec, D.,
12 Fonzar, A., Fourmoussis, I., Rasperini, G., Rossi, R., Silvestri, M., Topoll, H.,
13 Walkkamm, B. & Zybutz, M. (2004a) Clinical outcomes following treatment of
14 human intrabony defects with GTR/bone replacement material or access flap
15 alone. A multicenter randomized controlled clinical trial. *J Clin Periodontol* 31,
16 770-776.
- 17
18 Tonetti, M.S., Fourmoussis, I., Suvan, J., Cortellini, P., Bragger, U. & Lang, N.P.
19 (2004b) Healing, post-operative morbidity and patient perception of outcomes
20 following regenerative therapy of deep intrabony defects. *J Clin Periodontol*
21 31, 1092-1098.
- 22
23 Tonetti, M.S., Lang, N.P., Cortellini, P., Suvan, J.E., Adriaens, P., Dubravec, D.,
24 Fonzar, A., Fourmoussis, I., Mayfield, L., Rossi, R., Silvestri, M., Tiedemann,
25 C., Topoll, H., Vangsted, T. & Walkkamm, B. (2002) Enamel matrix proteins in
26 the regenerative therapy of deep intrabony defects. *J Clin Periodontol* 29, 317-
27 325.
- 28
29 Trombelli, L. & Farina, R. (2008) Clinical outcomes with bioactive agents alone or in
30 combination with grafting or guided tissue regeneration. *J Clin Periodontol* 35,
31 117-135.
- 32
33 Trombelli, L., Heitz-Mayfield, L.J., Needleman, I., Moles, D. & Scabbia, A. (2002) A
34 systematic review of graft materials and biological agents for periodontal
35 intraosseous defects. *Journal of Clinical Periodontology* 29 Suppl 3, 117-135.
- 36 Tu, Y.K., Woolston, A. & Faggion, C.M., Jr. (2010) Do bone grafts or barrier
37 membranes provide additional treatment effects for infrabony lesions treated
38 with enamel matrix derivatives? A network meta-analysis of randomized-
39 controlled trials. *J Clin Periodontol* 37, 59-79.
- 40
41 Van der Pauw, M.T., Van den Bos, T., Everts, V. & Beertsen, W. (2000) Enamel
42 matrix-derived protein stimulates attachment of periodontal ligament
43 fibroblasts and enhances alkaline phosphatase activity and transforming
44 growth factor beta1 release of periodontal ligament and gingival fibroblasts. *J*
45 *Periodontol* 71, 31-43.
- 46
47 Velasquez-Plata, D., Scheyer, E.T. & Mellonig, J.T. (2002) Clinical comparison of an
48 enamel matrix derivative used alone or in combination with a bovine-derived
49 xenograft for the treatment of periodontal osseous defects in humans. *J*
50 *Periodontol* 73, 433-440.
- 51
52 Wachtel, H., Schenk, G., Bohm, S., Weng, D., Zuhr, O. & Hurzeler, M.B. (2003)
53 Microsurgical access flap and enamel matrix derivative for the treatment of
54 periodontal intrabony defects: a controlled clinical study. *Journal of Clinical*
55 *Periodontology* 30, 496-504.
- 56
57 Yilmaz, S., Cakar, G., Yildirim, B. & Sculean, A. (2010) Healing of two and three wall
58 intrabony periodontal defects following treatment with an enamel matrix
59 derivative combined with autogenous bone. *J Clin Periodontol* 37, 544-550.
- 60
Zucchelli, G., Amore, C., Montebugnoli, L. & De Sanctis, M. (2003) Enamel matrix
proteins and bovine porous bone mineral in the treatment of intrabony defects:
a comparative controlled clinical trial. *J Periodontol* 74, 1725-1735.

Zucchelli, G., Bernardi, F., Montebugnoli, L. & De, S.M. (2002) Enamel matrix proteins and guided tissue regeneration with titanium-reinforced expanded polytetrafluoroethylene membranes in the treatment of infrabony defects: a comparative controlled clinical trial. J Periodontol 73, 3-12.

For Peer Review

Table 1. Clinical outcomes at 12 months; mean differences are calculated as baseline – 6 months respectively baseline – 12 months

| Variable | Treatment | | | | | |
|--------------------------|---------------------------|-----------|-----------|---------------------------|------------|-----------|
| | Test (EMD / SBC), n = 38 | | | Control (EMD), n = 35 | | |
| Baseline – 6 / 12 months | Baseline | 6 months | 12 months | Baseline | 6 months | 12 months |
| Bone sounding (mm) | 12.0 ± 2.1 | 9.9 ± 2.4 | 9.3 ± 2.2 | 12.2 ± 2.0 | 10.2 ± 2.5 | 9.4 ± 2.3 |
| Mean difference ± SD | 2.01 ± 2.1 / 2.65 ± 1.9 | | | 2.07 ± 1.2 / 2.81 ± 1.6 | | |
| RAL (mm) | 9.3 ± 2.1 | 8.0 ± 2.2 | 7.6 ± 2.3 | 10.1 ± 2.2 | 8.3 ± 2.5 | 8.2 ± 2.5 |
| Mean difference ± SD | 1.31 ± 1.8 / 1.69 ± 2.1 | | | 1.83 ± 1.6 / 1.93 ± 1.7 | | |
| PPD (mm) | 6.9 ± 1.8 | 5.0 ± 1.7 | 4.1 ± 1.7 | 7.1 ± 1.5 | 4.5 ± 1.9 | 4.2 ± 1.9 |
| Mean difference ± SD | 1.93 ± 1.8 / 2.80 ± 2.1 | | | 2.55 ± 1.8 / 2.90 ± 1.8 | | |
| GR (mm) | 2.4 ± 1.3 | 3.0 ± 1.7 | 3.5 ± 1.7 | 3.0 ± 1.6 | 3.8 ± 1.7 | 4.0 ± 1.8 |
| Mean difference ± SD | -0.62 ± 1.1 / -1.11 ± 1.3 | | | -0.72 ± 1.1 / -0.97 ± 1.1 | | |

PPD: probing pocket depths. RAL: relative attachment level. GR: gingival recessions.

EMD: enamel matrix derivative. SBC: synthetic bone graft.

Table 2. Full mouth plaque scores (mean \pm SD)

| Time | Treatment | |
|-----------|------------------|------------------|
| | Test (EMD / SBC) | Control (EMD) |
| 2 weeks | 12.7 \pm 9.2% | 12.7 \pm 9.5% |
| 6 weeks | 14.5 \pm 8.6% | 13.9 \pm 10.0% |
| 3 months | 13.2 \pm 7.7% | 14.5 \pm 10.6% |
| 6 months | 13.6 \pm 7.0% | 13.7 \pm 9.3% |
| 9 months | 12.2 \pm 7.0% | 12.8 \pm 7.7% |
| 12 months | 13.9 \pm 11.0% | 13.2 \pm 11.3% |

Table 3. Change of intrabony defects by therapy as evaluated on intraoral radiographs

| Variable | Treatment | | | |
|----------------------|--------------------------|-------------|-----------------------|-------------|
| | Test (EMD / SBG), n = 35 | | Control (EMD), n = 33 | |
| Baseline – 12 months | Baseline | 12 months | Baseline | 12 months |
| CEJ/RM - BD (mm) | 9.8 ± 3.2 | 8.0 ± 2.8 | 10.1 ± 2.5 | 8.7 ± 2.6 |
| Mean difference ± SD | 1.77 ± 1.9 | | 1.40 ± 1.9 | |
| CEJ/RM – AC (mm) | 6.1 ± 2.7 | 5.3 ± 2.3 | 6.4 ± 2.5 | 6.0 ± 2.6 |
| Mean difference ± SD | 0.73 ± 2.0 | | 0.37 ± 1.7 | |
| INTRA (mm) | 5.9 ± 2.6 | 3.7 ± 2.3 | 5.6 ± 2.1 | 4.2 ± 2.2 |
| Mean difference ± SD | 2.19 ± 2.2 | | 1.49 ± 1.9 | |
| Defect angle (°) | 25.8 ± 9.9 | 34.8 ± 14.4 | 28.0 ± 10.2 | 34.8 ± 16.0 |
| Mean difference ± SD | -9.0 ± 14.4 | | -6.7 ± 13.0 | |

CEJ: cemento - enamel junction. RM: restoration margin. BD: most apical extent of bony defect.

AC: alveolar crest. INTRA: depth of the intrabony component of bony defects.

EMD: enamel matrix derivative. SBG: synthetic bone graft.

Table 4: Multiple linear regression analysis: (DF: degrees of freedom; MSQ: mean of squares).

| | | | | | |
|---|----------------|------------------|--------|----------|----------|
| Dependent variable: change of distance CEJ/RM-BM; n=68; R ² =0.125; R ² _{adjusted} =0.112; standard error of estimate=1.809 | | | | | |
| | <i>b</i> | s.e.(<i>b</i>) | T | <i>P</i> | |
| Constant | -0.094 | 0.591 | -0.159 | 0.874 | |
| INTRA at baseline | 0.202 | 0.095 | 3.068 | 0.003 | |
| Analysis of variance | | | | | |
| Model | Sum of squares | DF | MSQ | <i>F</i> | <i>P</i> |
| Regression | 30.801 | 1 | 30.801 | 9.410 | 0.003 |
| Residual | 216.033 | 66 | 3.273 | | |

Figures and Graphs

Fig. No. 1a




Fig. No. 1b

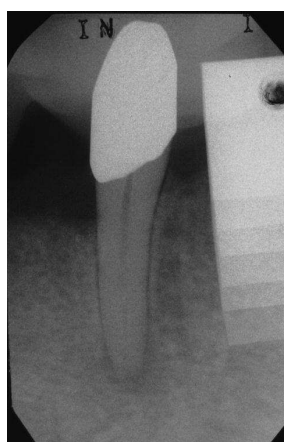


Fig. No. 2a

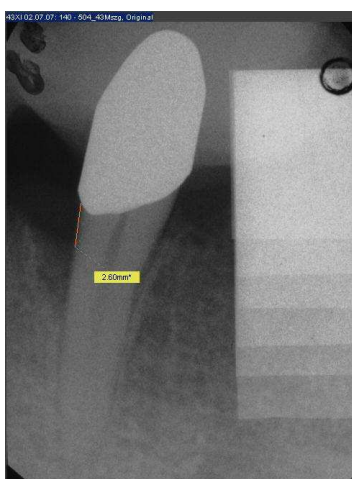


Fig. No. 2b

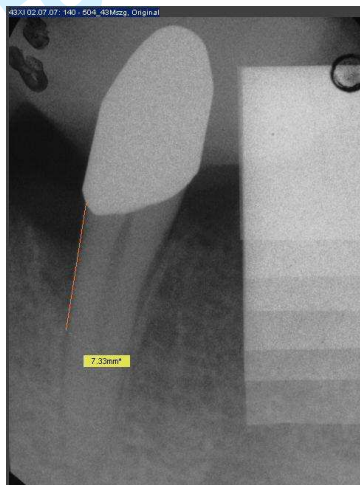


Fig. No. 2c

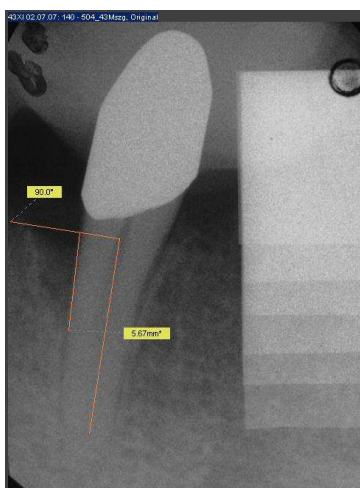


Fig. No. 2d

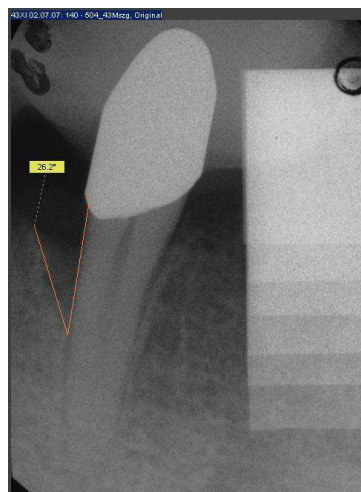


Fig. 3a

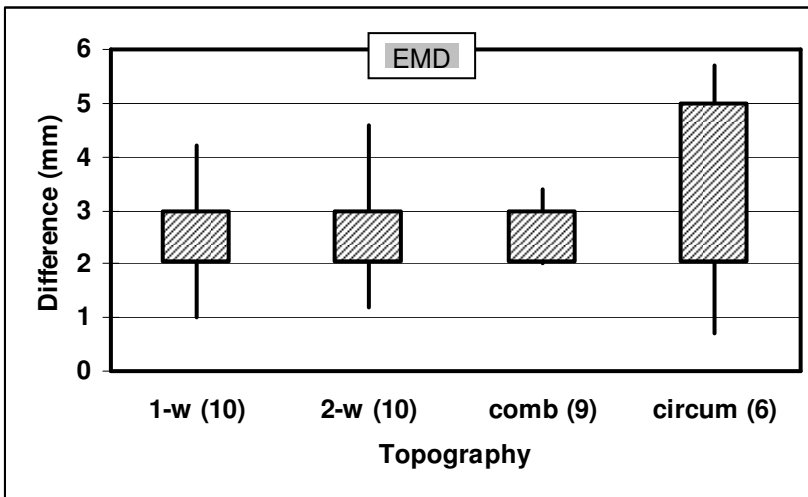


Fig. 3b

