



**HAL**  
open science

## Randomized controlled trial on lateral augmentation using two collagen membranes. Morphometric results on mineralized tissue compound.

Anton Friedmann, Kirsten Gissel, Mouaz Soudan, Bernd-Michael Kleber, Sandu Pitaru, Thomas Dietrich

### ► To cite this version:

Anton Friedmann, Kirsten Gissel, Mouaz Soudan, Bernd-Michael Kleber, Sandu Pitaru, et al.. Randomized controlled trial on lateral augmentation using two collagen membranes. Morphometric results on mineralized tissue compound.. *Journal of Clinical Periodontology*, 2011, 38 (7), pp.677. 10.1111/j.1600-051X.2011.01738.x . hal-00639787

**HAL Id: hal-00639787**

**<https://hal.science/hal-00639787>**

Submitted on 10 Nov 2011

**HAL** is a multi-disciplinary open access archive for the deposit and dissemination of scientific research documents, whether they are published or not. The documents may come from teaching and research institutions in France or abroad, or from public or private research centers.

L'archive ouverte pluridisciplinaire **HAL**, est destinée au dépôt et à la diffusion de documents scientifiques de niveau recherche, publiés ou non, émanant des établissements d'enseignement et de recherche français ou étrangers, des laboratoires publics ou privés.



**Randomized controlled trial on lateral augmentation using two collagen membranes. Morphometric results on mineralized tissue compound.**



Journal:	<i>Journal of Clinical Periodontology</i>
Manuscript ID:	CPE-06-10-2701.R2
Manuscript Type:	Original Article Implant Dentistry
Date Submitted by the Author:	30-Mar-2011
Complete List of Authors:	Friedmann, Anton; CharitéCentrum 3, Operative Dentistry and Periodontology Gissel, Kirsten; CharitéCentrum 3, Periodontology and Synoptic Dentistry Soudan, Mouaz; CharitéCentrum 3, Periodontology and Synoptic Dentistry Kleber, Bernd-Michael; CharitéCentrum 3, Periodontology and Synoptic Dentistry Pitaru, Sandu; Tel Aviv University, Oral Biology, School of Dental Medicine Dietrich, Thomas; University of Birmingham, Oral Surgery, School of Dental Medicine
Topic:	Implantology
Keywords:	GBR, collagen membrane, implants, bone augmentation, morphometry
Main Methodology:	Clinical Trial

SCHOLARONE™  
Manuscripts

1  
2  
3 **Randomized controlled trial on lateral augmentation using two collagen**  
4 **membranes. Morphometric results on mineralized tissue compound.**  
5  
6

7  
8 Anton Friedmann<sup>1</sup>, Kirsten Gissel<sup>2</sup>, Mouaz Soudan<sup>2</sup>, Bernd-Michael Kleber<sup>2</sup>, Sandu  
9 Pitaru<sup>3</sup>, Thomas Dietrich<sup>4</sup>  
10  
11

12 <sup>1</sup>Department of Periodontology, School of Dentistry, Faculty of Health, University of  
13 Witten, Germany  
14  
15

16  
17 <sup>2</sup>Department of Periodontology, CharitéCentrum 3, Campus Virchow-Klinikum,  
18 Charité Universitätsmedizin Berlin, Berlin, Germany  
19  
20

21  
22 <sup>3</sup>Department of Oral Biology, School of Dental Medicine, Tel Aviv University, Israel  
23

24  
25 <sup>4</sup>Department of Oral Surgery, School of Dental Medicine, University of Birmingham,  
26 UK  
27  
28

29 Running title: Collagen membranes in GBR  
30

31 Key words: lateral augmentation, non-cross linked collagen, ribose cross linked  
32 collagen, morphometry, randomized trial  
33  
34

35  
36 **Corresponding author:**  
37

38 Prof. Dr. Anton Friedmann  
39

40 Department of Periodontology  
41

42 School of Dentistry  
43

44 Faculty of Health  
45

46 University of Witten  
47

48 Alfred-Herrhausen-Str. 50  
49

50 58448 Witten  
51

52 Germany  
53  
54

55 Phone: +492302 926666  
56  
57

58 Email: [anton.friedmann@uni-wh.de](mailto:anton.friedmann@uni-wh.de)  
59  
60

### Conflict of interest and source of funding statement

The authors declare that they have no conflict of interest.

The study was funded in parts by *Biomet 3i* (Palm Beach; FL, USA) as unrestricted research grant to Department of Periodontology and Synoptic Dentistry, Charité, Berlin, Germany and by material donations from Institute Straumann AG (Basel, Switzerland). Originally, *Biomet 3i* was the study initiator proposing the initial steps for the protocol and providing the membranes as study material. After the company lost the rights of distribution for the OSSIX membrane, it was no longer part of this investigation. The final protocol, as described in the manuscript and approved by the Ethic Committee of the Charité University was designed by the principal investigator (AF). The data processing and preparation of the manuscript were completed by the co-authors all named on the cover page. Dr. Pitaru is one of the two inventors of Ossix and holds a patent on this invention together with Dr. M. Noff. Dr. Pitaru is one of the two co-founders of Colbar Life Sciences, held equities in this Company until 2005 and served as Chief Scientist Officer until 2003.

## Abstract

Background: GBR is considered an effective tool for gaining mineralized tissue either at exposed implant surface or in deficient alveolar ridge areas prior to implant placement.

Material & Methods: Customized casts obtained following impression taking at surgery and re-entry allowed for morphometric assessment of alveolar ridge alterations 6 months after one-stage augmentation of bone dehiscences. In a randomized pilot study using biphasic calcium phosphate tests (n=17) received treatment with ribose cross linked collagen membranes whereas controls (n=20) received non-cross linked membranes. The primary endpoint was to quantify the effect of membrane type on dimensional changes in bone margins at crestal level of endosseous implants.

Results: Soft tissue dehiscencies occurred at 70.5% and 55% frequency for tests and controls, respectively. Gain in clinically hard newly mineralized tissue at the crestal level was significantly higher in test group in lateral (1.8mm vs. 0.7mm;  $p=.046$ ) and in vertical dimensions (1.1mm vs. 0.2mm;  $p=.035$ ) compared to controls. Second measurement obtained at the border of reflected flap revealed none-significant difference between groups (3.0mm vs. 2.1mm;  $p=0.57$ ) for lateral dimension.

Conclusions: both collagen devices were effective in bone augmentation. RCLMs supported mineralization process and remodeling even in sites showing compromised healing as indicated by morphometric outcome.

1  
2  
3 Clinical relevance  
4

5 *Scientific rationale for the study:* Limited data are available regarding morphometric outcome  
6  
7 in terms of mineralized tissue gain if either cross linked or non-cross linked collagen  
8  
9 membranes were used in lateral augmentation.  
10

11  
12 *Principial findings:* Results indicate both membranes having potential to effectively support  
13  
14 GBR in dehiscence type of defect. Dehiscence of the soft tissue occurred in 70.5% of test  
15  
16 and in 55% of control sites. However, significantly higher amount of newly mineralized tissue  
17  
18 in a most critical zone argues for the use of cross linked collagen membranes although more  
19  
20 exposures occurred in test sites.  
21  
22

23  
24 *Practical implications:* Cross linked membranes combined with biphasic calcium phosphate  
25  
26 are suitable for GBR and likely to support formation of significant amount of newly  
27  
28 mineralized tissue under unlikely clinical conditions.  
29  
30  
31  
32  
33  
34  
35  
36  
37  
38  
39  
40  
41  
42  
43  
44  
45  
46  
47  
48  
49  
50  
51  
52  
53  
54  
55  
56  
57  
58  
59  
60

## Introduction

Guided bone regeneration (GBR) is one of several well documented, evidence based augmentation techniques (Hammerle & Karring, 1998; McAllister & Haghghat, 2007). Several animal and clinical studies showed gain in marginal bone, using resorbable membranes in combination with an underlying, osteoconductive membrane-supporting material (Hammerle & Lang, 2001; Hockers, et al., 1999; Strietzel, et al., 2006; Zitzmann et al., 2001). Collagen membranes, as the most frequently used type of degradable membranes, lack enough stiffness for space maintenance and tend to collapse (Strietzel et al., 2006). Therefore, titanium re-inforced non-degradable e-PTFE membranes are still favored by some clinicians. Early exposure of barrier membranes to the oral environment jeopardizes the outcome due to infection, mostly manifested around non-resorbable membranes, or due to rapid disintegration in case of resorbable membrane (De Sanctis et al., 1996; Mayrand & Grenier, 1985; Nowzari & Slots, 1995; Sela, et al., 2003; Simion, et al., 1994; Tempro & Nalbandian, 1993).

Collagen cross-linking contributes to prolonged membrane barrier function (Bornstein et al., 2007; von Arx, et al., 2005). Barriers with high degradation rates could have a shorter-than-indicated effect (Moses, et al., 2008). Membrane degradation starts shortly after implantation (von Arx et al., 2005). The integration pattern of various collagen membranes into soft tissues were analyzed in recently published animal studies (Rothamel, et al., 2005; Schwarz, et al., 2006). A larger membrane porosity (less collagen contents per area) would allow for cell ingrowths within the membrane, resulting in better tissue (Rothamel et al., 2005; Schwarz et al., 2006), but may result in reduced barrier function (Rothamel, et al., 2004). Importantly, nutrient diffusion for cell proliferation and differentiation was not affected by collagen cross linking vs. non-cross linking in an in-vitro study (Friedmann, et al., 2008). Significantly more new

1  
2  
3 bone formation in animal defects augmented with biphasic calcium phosphate (BCP)  
4 together with either a non-degradable (e-PTFE) or a newly introduced slowly  
5 degrading polyethylene glycol membranes vs. controls grafted without membranes  
6 was recently confirmed by Jung, et al. (Jung, et al., 2006). Nevertheless, the  
7 discussion upon the benefits and disadvantages of cross-linked collagen material as  
8 slowly degradable vs. membranes from native collagen, a rapidly degrading type is  
9 still ongoing. In this respect, there is no data regarding the efficiency of resorbable  
10 membranes to support bone gain in cases in which bone augmentation is performed  
11 with simultaneous installation of implants with transgingival surgical elements.  
12  
13  
14  
15  
16  
17  
18  
19  
20  
21  
22  
23  
24

25 Morphometric assessment of outcomes in bone augmentation in terms of volume  
26 gain has been the topic for in vitro and clinical studies (Kohles, et al., 2000; Llambes  
27 et al., 2007; Proussaefs & Lozada 2005; Proussaefs, et al., 2002; Studer, et al.,  
28 1997; Tai et al., 2000; Windisch, et al., 2007). Our group introduced a method to  
29 perform morphometric measurements on casts obtained from impressions of the  
30 residual alveolar ridge taken during surgery and of the post-augmented ridge taken  
31 during re-entry (Pitaru, et al., 2006).  
32  
33  
34  
35  
36  
37  
38  
39  
40  
41  
42

43 The aim of the present randomized clinical trial was to test the efficiency of  
44 supporting bone gain and promoting soft tissue healing of a ribose cross-linked  
45 collagen membrane (RCLM) vs. a non-cross-linked collagen membrane (NCLM)  
46 during augmentation of bone dehiscences and fenestrations with biphasic calcium  
47 phosphate and concomitant implant placement using a new morphometric approach  
48 for human clinical trials.  
49  
50  
51  
52  
53  
54  
55  
56  
57  
58  
59  
60



## Material and Methods

This study was a randomised controlled, single-blinded pilot clinical trial with an observation period of six months. All participants signed a written consent prior to the beginning of surgical procedures. The study was conducted in accordance with the guidelines of Good Clinical Practice (GCP-ICH) and the principles of the Declaration of Helsinki. The study was approved by the Ethics Committee of the Universitätsmedizin Charité, Berlin, Germany, under protocol number EA2/054/05 and registered at ClinicalTrials.gov under ID: NCT00835432. Patients were recruited from the pool of recall patients at the Department of Periodontology and Synoptic Dentistry or from referring dentists during the years 2005-2006. Included were partially edentulous patients in good general health with one or more teeth missing and requiring bone augmentation with placement of implants. There were no restrictions with regard to the location of the edentulous area, i.e. anterior and posterior regions of the maxilla and/or mandible were included. The study used a block randomization to randomize patients to either the cross-linked test (OSSIX, 3i, Palm Beach, FL, USA) or the non-cross-linked control (BioGide, Geistlich, Wohlhusen, Switzerland) membranes in a 1:1 ratio. This was a pilot study and no sample size calculation was performed. At the beginning of the study, treatment allocation for each patient was placed in a sealed envelope to be opened during the surgery. In patients who had two surgical sites that met the inclusion criteria, both sites were treated concomitantly and the first site received the membrane as per treatment allocation while the second site received the alternative treatment, facilitating comparisons within patients with two surgical sites.

Smokers consuming 10 or more cigarettes per day were excluded. All treatments were performed between November 2005 and May 2007. All surgeries were carried

1  
2  
3 out under local anaesthesia (Ultracain DS forte, Aventis, Germany) by a single  
4  
5 surgeon (AF). All patients received a one-stage procedure including implant  
6  
7 placement, concomitant augmentation, and primary wound closure. Defect  
8  
9 extensions were recorded using periodontal probe (PCP 15, Hu-Friedy, Leimen,  
10  
11 Germany) during surgery. While in vivo measurements were performed by the  
12  
13 surgeon, morphometric analyses on the casts obtained were carried out by the  
14  
15 Clinical Investigator (KG), who was blinded to the randomized patient assignment. In  
16  
17 addition, impressions were taken for ex-vivo measurements by a blinded investigator  
18  
19 (KG) using individualised plastic trays and a sterile A-silicone material (Elite®  
20  
21 Implant, Zhermack, Germany). These impressions were taken before and after  
22  
23 reflection of a muco-periosteal flap exposing the defect area. Straumann Soft Tissue  
24  
25 Level implants with 4.1 mm in diameter and varying from 8 to 12mm in length  
26  
27 (Institute Straumann AG, Basel, Switzerland) were used in accordance with  
28  
29 established guidelines. In brief, recipient site was prepared for placing implant with it  
30  
31 rough SLA surface at the crestal level of alveolar bone leaving the machined part of  
32  
33 the implant neck above the bone level. Standard Plus (SP) implants with a machined  
34  
35 neck of 1.8 mm were used. Biphasic calcium phosphate (BoneCeramic, Institute  
36  
37 Straumann AG, Basel, Switzerland) was used for grafting dehiscences and  
38  
39 fenestrations in alveolar bone in exposed implant areas. No autogenous bone was  
40  
41 used. For easier application, a coagulum was formed by the calcium phosphate  
42  
43 grafting material with 1 to 2 ml of the patients' own blood collected in the wound area  
44  
45 after the incisions were carried out (Artzi, et al., 2005; Friedmann, et al., 2002);  
46  
47 Friedman, et al., 2009). The composite grafting material was placed in the defect up  
48  
49 to the level of the machined surface of the implant, in the vertical direction and up to  
50  
51 the completion of the bony envelop in the lateral direction. After application of the  
52  
53 augmentation material, envelopes containing the randomization code were opened  
54  
55  
56  
57  
58  
59  
60

1  
2  
3 and membrane placement was performed as assigned. Each membrane was applied  
4  
5 in a monolayer. All flaps were coronally advanced by periosteal release to achieve a  
6  
7 tension free adaptation of soft tissue margins for complete closure of the wound. The  
8  
9 post-operative regimen included twice daily mouth rinses with Chlorhexidine 0.2%  
10  
11 (Chlorhexamed, Glaxo Smith Kline, Bühl, Germany). Systemic antibiotics, either  
12  
13 amoxicillin 750mg 3xdaily (Amoxicillin-Ratiopharm, Ratiopharm, Germany) or  
14  
15 clindamycine 300 mg 4xdaily (Clindamycin-Ratiopharm, Ratiopharm, Germany) were  
16  
17 administered for 1 week; and ibuprofen (Ibuprofen-Ratiopharm 600mg, Ratiopharm,  
18  
19 Germany) as necessary for postoperative analgesia. Sutures were removed after 14  
20  
21 days. Fixed partial dentures or semi-permanent splinting were used as temporary  
22  
23 prosthetic devices only. In edentulous posterior regions, no dentures were applied  
24  
25 during the study.  
26  
27  
28  
29  
30  
31

32  
33 At re-entry after 6 months, an impression was taken to document tissue dimensions  
34  
35 and full thickness flaps were then raised using similar incision extensions as during  
36  
37 the first surgery, with the exception for lingual flaps which were not raised if the area  
38  
39 augmented was sufficiently exposed (Fig. 2a-f). Following thorough removal of any  
40  
41 remaining non-mineralized tissue with sterile curettes another impression was taken  
42  
43 to document hard-tissue dimensions. In nine cases requiring additional  
44  
45 augmentation, BCP and RCLM were used. All implants received gingival formers  
46  
47 (Straumann AG, Basel, Switzerland) and the flap was sutured back by single sutures  
48  
49 using Monocryl 6.0 suture (Ethicon, Hamburg, Germany).  
50  
51  
52  
53

#### 54 *Morphometric procedure*

55  
56  
57 The primary objective of the study was to quantify the effect of the type of collagen  
58  
59 membrane on the level of bone augmentation at the crestal level of endosseous  
60  
implants. To do this the following morphometric procedure was undertaken. All

1  
2  
3 impressions were cast in stone rock plaster (Octa Stone CN, Hereus – Kulzer,  
4 Bensheim, Germany). Casts of impressions obtained at initial surgery and at re-entry  
5 (post-augmentation) are designated as casts-0 and casts-1, respectively. Negative  
6 templates of casts-1 were obtained by taking silicon (C-silicon, Silaplast®, Detax,  
7 Germany) impressions. Using landmarks as teeth adjacent to the augmented site and  
8 the implant neck the negative templates were adjusted upon the casts-1 (Fig. 3a+b).  
9  
10 To determine reference points and to ascertain reproducibility in positioning one and  
11 the same template on casts obtained at both surgeries, the top aspects of the  
12 templates were trimmed parallel with the basis of cast 1; furthermore the side walls of  
13 templates were trimmed perpendicular to top and bottom aspect of the templates  
14 (Fig. 4a-d). While kept together, the casts-1 and their negative silicon templates were  
15 sectioned through bucco-lingual plans that mid-crossed in mesio-distal dimension of  
16 implants around which augmentation was performed. A perpendicular was dropped  
17 from the edge of template to the middle of the cover screw of a cross-sectioned  
18 implant to label central implant axis (Fig. 4a). To assess vertical dimension a parallel  
19 perpendicular was marked on the template at the crossing point of alveolar crest and  
20 implant surface and the distance between this point and the top plan of the silicon  
21 template was measured with a digitized calliper and termed - H1/1 (Fig. 3a; 4a). A  
22 perpendicular to H1/1 passing through the crossing point of alveolar crest and  
23 implant surface was drawn. The distance between the implant middle axis and the  
24 buccal aspect of the alveolar crest was measured on this perpendicular and termed -  
25 W1/1 (Fig. 3a; 4a). A second perpendicular, parallel to H1/1 was drawn at the level of  
26 most pronounced buccal aspect of augmented area and the distance from the middle  
27 of implant to this aspect was recorded and termed - W2/1 (Fig. 4a; 4b). The distance  
28 from this point to the top plan of the silicon template was measured with a digitized  
29 caliper and termed - H2/1 (Fig. 4a). Then, the cross sectioned silicon templates were  
30  
31  
32  
33  
34  
35  
36  
37  
38  
39  
40  
41  
42  
43  
44  
45  
46  
47  
48  
49  
50  
51  
52  
53  
54  
55  
56  
57  
58  
59  
60

1  
2  
3 adapted to the casts-0 obtained during the augmentation procedure using the  
4 reference marks mentioned above (Fig. 4c+d). Using the templates as landmarks the  
5 casts-0 were sectioned in the same plan as described above for the casts-1. Using  
6 the landmark lines drawn on the silicon templates, now adapted to casts-0, the  
7 distances measured on casts-1 were measured for casts-0 and termed W1/0; H1/0;  
8 W2/0; and H2/0. This methodology ensured that casts-0 and casts-1 were sectioned  
9 in the same plans and exactly at the same site, that is a bucco-lingual plan crossing  
10 the central axis of the implants (Fig. 4b). Bone gain in width and height was  
11 calculated by:  
12  
13  
14  
15  
16  
17  
18  
19  
20  
21  
22  
23  
24

- 25 • Crestal (coronal) width gain:  $\Delta W1 = W1/1 - W1/0$
- 26
- 27 • Crestal (coronal) vertical gain:  $\Delta H1 = H1/0 - H1/1$
- 28
- 29 • Apical width gain:  $\Delta W2 = W2/1 - W2/0$
- 30
- 31 • Apical vertical gain:  $\Delta H2 = H2/0 - H2/1$
- 32
- 33
- 34
- 35
- 36
- 37

### 38 *Statistical analysis*

39  
40  
41 Changes in hard and soft-tissue dimensions between baseline and re-entry were  
42 outcomes of interest. Data were analyzed in two different ways. Firstly, data of all 37  
43 patients were analyzed using one randomly selected site of those patients with two  
44 surgical sites. Comparisons between groups and between baseline and re-entry  
45 within groups were made using t-tests and paired t-tests as appropriate. Further  
46 analyses used multiple linear regression adjusting for maxillary vs. mandibular  
47 defects, anterior and posterior sites, smoking, membrane exposure. Secondly,  
48 comparisons between groups were made limited to data of those patients who had  
49 two surgical sites (split-mouth comparison) using non-parametric Wilcoxon sign rank  
50  
51  
52  
53  
54  
55  
56  
57  
58  
59  
60

1  
2  
3 tests. All statistical tests were two-sided at  $\alpha=0.05$  and performed using statistical  
4  
5  
6 software (STATA 11, Stata Corp, College Station, TX, USA).  
7  
8  
9  
10  
11  
12  
13  
14  
15  
16  
17  
18  
19  
20  
21  
22  
23  
24  
25  
26  
27  
28  
29  
30  
31  
32  
33  
34  
35  
36  
37  
38  
39  
40  
41  
42  
43  
44  
45  
46  
47  
48  
49  
50  
51  
52  
53  
54  
55  
56  
57  
58  
59  
60

For Peer Review

## Results

Patient recruitment involved 40 patients; three of them were excluded due to the extensive loss of alveolar bone making therefore the implant placement at one stage with augmentation not feasible (Fig. 1). All patients included completed the study, resulting in a total of 37 patients with 46 defect sites. All implants inserted (in total: 73) were well integrated after 6 months of healing. All implants received gingival formers for 4 to 6 weeks being loaded subsequently by single crowns or fixed partial dentures. There were 37 implants placed in 17 defect sites in the test group and 36 implants in 20 sites in the control group (Table 1). The overall survival rate at time point of loading was 100%.

Albeit patient assignment to the test and control groups was performed randomly, groups matched well in regard to patient's age, proportions between females and males and distribution of sites between maxilla and mandible (Table 1). In both groups not-smoking patients and smoking <10 cigarettes/day were represented in similar frequency. A group of nine patients formed a split mouth group and were treated at 2 sites each site with a different membrane. Analysis of the morphometric results within this group indicated not-statistically significant differences between the sites treated with the RCLM and those treated with NCLM. Therefore, only one site per patient has been chosen by secondary randomization assigning one study site and implant per patient, either to tests or to controls. Thus, Table 2 represents 37 patient data sets and the distribution among test and control group for 37 study sites randomly selected for analysis. The age ranged from 24 to 69 years with a median of 53 years (Table 2).

1  
2  
3 No adverse events were recorded but one participant in the control group showed  
4 hypersensitive reaction to Amoxicillin, which then was exchanged by Zithromax  
5  
6 (Azithromycine, Pfizer, Germany).  
7  
8  
9

### 10 *Morphometric results*

11  
12 Statistical outcomes for all 37 sites including randomly selected one site per patient  
13  
14 out of former split mouth randomization are given by Table 3. At reference point 1  
15  
16 (W1 / H1), indicating the most crestal bone-to-implant contact the median gain of  
17  
18 mineralized tissue in the vertical dimension (vertical gain;  $\Delta H1$ ) was 1.1mm in the test  
19  
20 sites compared to 0.2 mm in the control sites ( $p = .0463$ ). The median gain in the  
21  
22 horizontal dimension (width gain;  $\Delta W1$ ) was 1.8 mm in the test sites vs. 0.7 mm in the  
23  
24 control sites ( $p = .0359$ ). There were no statistically significant associations between  
25  
26 the primary outcome and membrane exposure ( $p = .6845$  for  $\Delta H1$  and  $p = .2809$  for  
27  
28  $\Delta W1$ , respectively).  
29  
30  
31  
32  
33  
34  
35

36 At the second reference point ( $\Delta W2 / \Delta H2$ ), the most apically accessible point for  
37  
38 measurement, the median vertical gains were 2.5 mm and 2.7 mm for the test and  
39  
40 control sites, respectively ( $p = 0.5674$ ). The median width gains at this reference  
41  
42 point were 3.0 mm and 2.1 mm for test and control sites, respectively ( $p = .1189$ ).  
43  
44  
45  
46

47 In both groups of patients, test and control sites which exhibited soft tissue  
48  
49 dehiscence required additional augmentation at exposed implant surface. There were  
50  
51 4 sites in the test group and 5 sites in the control group (23.5% vs. 20%, respectively)  
52  
53 requiring additional treatment; implants involved received secondary application of  
54  
55 BCP plus RCLM membranes at re-entry.  
56  
57  
58  
59  
60



## Discussion

The aim of the present randomized clinical trial was to test the effectivity of ribose-cross linked (RCLM; test) membrane vs. a non-cross linked (NCLM; control) membrane in GBR treatment using a new method for morphometric analysis. Generally, the results indicate that both membranes improved the bone volume and predictably supported GBR procedures at dehiscence-type and fenestration-type defects.

The rate of soft tissue dehiscences during healing was almost equally distributed for both groups. Over 50% of sites were exposed and underwent secondary epithelization. The figures are high compared to the data presented for the group of dehiscence-type defects within the review by Jensen & Terheyden. They found rates of soft tissue dehiscences up to 14.5% for sites with resorbable and of 26.3% for those with non-resorbable membranes (Jensen & Terheyden, 2009). Similar observations in regard to RCLM samples were reported previously by our group (Friedmann et al., 2001). Moses et al. found the RCLM membrane demonstrating a higher reduction of the bony defect area in cases of premature membrane exposure (Moses, et al., 2005). The history of premature membrane exposure may have a negative effect on new bone formation even if soft tissue dehiscence recovers by secondary epithelization. Although ribose-cross linked membranes might be associated with a higher incidence rate of soft tissue dehiscences (Moses et al., 2005; Tal, et al., 2008), the frequency of concomitant inflammatory reactions reported is almost zero (Friedmann et al., 2001). On the opposite, the histological report by Zubery et al. demonstrated nicely the ossification of ribose cross linked collagen membrane remnants facing underlying newly mineralized tissues. These observations support the idea that slow degradation of ribose-cross linked collagen

1  
2  
3 membranes is beneficial for mineralization process (Zubery, et al., 2007; Zubery et  
4  
5 al., 2008).  
6  
7

8  
9 In our study Soft Tissue Level Straumann implants were inserted in accordance with  
10  
11 the ITI surgical protocol resulting in a position of the machined part of implant neck  
12  
13 supracrestally. However, all implants and augmentation sites were planned to heal in  
14  
15 the submerged mode according to the study protocol. Therefore complete flap  
16  
17 closure required mobilization and coronal advancing of the flap to achieve tension  
18  
19 free primary wound closure over the implant neck exceeding almost 2mm coronally to  
20  
21 the crest. No grafting material was applied in the supracrestal area of bone  
22  
23 dehiscencies laterally and therefore it is conceivable that flap stabilization was under  
24  
25 optimal in this study. This lack of membrane support by grafting material might  
26  
27 explain the unexpected high frequency of soft tissue dehiscence and premature  
28  
29 membrane exposure. In a recent study by Burkhard and Lang tensions exceeding  
30  
31 0.1N determined before suturing the flap resulted in a wound dehiscence rate over  
32  
33 40% (Burkhardt & Lang, 2010). The high prevalence of dehiscences in our study may  
34  
35 be a result of mechanical challenges due to masticatory movements as a  
36  
37 complementary factor to membrane properties. According to the implant design  
38  
39 secondary epithelialisation in this study did not always result in complete soft tissue  
40  
41 closure over the cover screw. However, the difference in frequency of dehiscence  
42  
43 onset following augmentation and the need of additional augmentation at re-entry  
44  
45 was obvious.  
46  
47  
48  
49  
50  
51  
52

53  
54 The method used to assess bone gain was originally introduced by Pitaru et al.  
55  
56 2006 at Europerio in Madrid, Spain (Pitaru et al., 2006). Customizing each defect  
57  
58 site before and after augmentation in plaster of paris allowed for determining  
59  
60 identically positioned reference points on boths. A silikon template transfered the

1  
2  
3 reference points from one cast to the other. Implants inserted concomitantly with  
4  
5 augmentation of dehiscence bone defects served as reference points. Albeit the  
6  
7 implant necks were positioned supracrestally the equicrestal level of roughened  
8  
9 sand blasted and acid-etched (SLA) surface on casts obtained at re-entry was  
10  
11 clearly indicated. Therefore, measurements across alveolar crest perpendicular to  
12  
13 the most coronal bony margin performed in this study can be considered  
14  
15 standardized. In a previous publication our group demonstrated the degree of  
16  
17 mineralization in newly formed tissues exceeding 40% in the area grafted laterally  
18  
19 with BCP (Friedmann, et al., 2009). Since in this study biopsies for the  
20  
21 histomorphometric analysis were harvested during re-entry surgeries from sites  
22  
23 augmented in the present study, histologic outcome indicates an effective  
24  
25 denudation of bony crest (Friedmann et al., 2009). Taking these observations into  
26  
27 account and furthermore by removing all non-mineralized tissue from underneath  
28  
29 the flap prior to impression we payed maximum attention to establish accuracy of  
30  
31 the impressions. Since all surgeries were performed by one co-worker (AF) we  
32  
33 consider the approach standardized for all sites. Our study presents for first time  
34  
35 an accurate method for quantifying vertical and horizontal changes of the alveolar  
36  
37 ridge in GBR. Furthermore this is first prospective report on efficacy of collagen  
38  
39 membranes in one stage GBR with one stage Soft Tissue Level Straumann  
40  
41 implants. Lang et al. reported successful implementation of Gore Tex membranes  
42  
43 placing them around necks of Straumann implants which, however, healed in  
44  
45 transmucosal mode (1994) (Lang, et al., 1994). The methods for tracking defect  
46  
47 changes introduced in periodontal regeneration as standardized probing from the  
48  
49 cemento-enamel junction (CEJ) to the deepest defect extension at baseline and at  
50  
51 re-entry surgery (Yukna et al., 2000; Lekovic et al., 2002) are not applicable for  
52  
53 purposes outlined in this study. Even in a situation illustrated by Fig. 2a – 2f  
54  
55  
56  
57  
58  
59  
60

1  
2  
3 probing across the ridge would result in significant variation in positioning any  
4  
5 measuring device at baseline and the re-entry surgeries.  
6  
7

8  
9 Retrospective analyses presented by Jensen and Terheyden at ITI consensus  
10 conference 2008 revealed an average fill of 85.5% together with 68.5% completely  
11 regenerated defects, respectively, calculated for the group of dehiscence-type of  
12 defects if a resorbable membrane was used. The rate of infectious complications was  
13  
14  
15  
16  
17  
18 13.75%. These data are based on a review of 20 studies (Jensen & Terheyden,  
19  
20 2009).  
21  
22

23  
24 Our results did not evaluate the level of defect fill, but rather the change in the bone  
25 dimensions in the defect. Nevertheless, sites requiring additional augmentation can  
26 be considered showing incomplete regeneration. Implants exposed in the area to be  
27 grafted are generally considered seeking new bone formation. A failure in apposition  
28 of new bone results therefore in an unlikely contact of the implant surface with soft  
29 tissues bearing odds for onsetting peri-implantitis. Therefore, the gain in mineralized  
30 tissue at the crestal level of implant roughened surface is the crucial parameter in  
31 testing the efficacy of GBR procedure. The statistically significant differences in gain  
32 of clinically hard mineralized tissues at the crestal border of previously exposed SLA-  
33 surface (H1/W1) favors the use of the ribose-cross linked collagen test membrane.  
34  
35 Clinically viable amounts of mineralized tissue was gained in the test group as  
36 indicated by without exception positive values for the difference between baseline  
37 and 6 months results in height and width parameters ( $\Delta H1$ ;  $\Delta W1$ ) of the bone  
38 covering previously exposed implant areas (Tab. 3). There was none additional gain  
39 and even a slight loss of bone occurred obviously in some controls as expressed by  
40 negative differences in crestal height and width for this group. Taking into account  
41 similar frequencies of dehiscence onset in both groups, we had to assume that cases  
42  
43  
44  
45  
46  
47  
48  
49  
50  
51  
52  
53  
54  
55  
56  
57  
58  
59  
60

1  
2  
3 treated with RCLM (tests) had a greater benefit in regard to primary outcome than  
4 those treated with NCLM (controls). This interpretation is supported by results of an  
5 animal study, which showed significantly greater membrane stability for the RCLM  
6 than for NCLM sutured onto oral mucosa in rats, both materials being exactly same  
7 as used in our study (Rothamel et al., 2005). The unpublished in vitro data by Pitaru  
8 et al. showed greater resistance of RCLM vs. NCLM against bacterial collagenases  
9 (personal communication, October 14, 2010). Evaluating at re-entry the degradation  
10 status of both collagen membranes histologically Tal et al. found that among 26  
11 initially applied RCLMs 13 were prematurely exposed (50%). Five out of them  
12 appeared interrupted and four were completely degraded 6 months following  
13 placement, whereas all devices from non-exposed sites remained intact. On the  
14 contrary, none of 18 NCLM devices initially applied was detectible at re-entry  
15 histologically. The authors concluded RCLM being more resistant against tissue  
16 degradation and retaining its integrity for a longer period of time compared to NCLM  
17 (Tal et al., 2008).  
18  
19  
20  
21  
22  
23  
24  
25  
26  
27  
28  
29  
30  
31  
32  
33  
34  
35  
36  
37  
38

39 Although none significant differences between both groups existed in regard to  
40 measurements at the second level addressed as  $\Delta H2 / \Delta W2$ , we conclude that the  
41 results are clearly superior for the use of RCLM material in lateral augmentation if  
42 compared to native collagen membranes, especially in regard to alterations in soft  
43 tissue healing.  
44  
45  
46  
47  
48  
49  
50  
51  
52  
53  
54  
55  
56  
57  
58  
59  
60

## References:

- 1  
2  
3  
4  
5  
6  
7  
8  
9  
10  
11  
12  
13  
14  
15  
16  
17  
18  
19  
20  
21  
22  
23  
24  
25  
26  
27  
28  
29  
30  
31  
32  
33  
34  
35  
36  
37  
38  
39  
40  
41  
42  
43  
44  
45  
46  
47  
48  
49  
50  
51  
52  
53  
54  
55  
56  
57  
58  
59  
60
- Artzi, Z., Kozlovsky, A., Nemcovsky, C. E. & Weinreb, M. (2005). The amount of newly formed bone in sinus grafting procedures depends on tissue depth as well as the type and residual amount of the grafted material. *J Clin Periodontol*, **32**, 193-199.
- Bornstein, M. M., Bosshardt, D. & Buser, D. (2007). Effect of two different bioabsorbable collagen membranes on guided bone regeneration: a comparative histomorphometric study in the dog mandible. *J Periodontol*, **78**, 1943-1953.
- Burkhardt, R. & Lang, N. P. Role of flap tension in primary wound closure of mucoperiosteal flaps: a prospective cohort study. *Clin Oral Implants Res*, **21**, 50-54.
- De Sanctis, M., Zucchelli, G. & Clauser, C. (1996). Bacterial colonization of barrier material and periodontal regeneration. *J Clin Periodontol*, **23**, 1039-1046.
- Friedmann, A., Dard, M., Kleber, B. M., Bernimoulin, J. P. & Bosshardt, D. D. (2009). Ridge augmentation and maxillary sinus grafting with a biphasic calcium phosphate: histologic and histomorphometric observations. *Clin Oral Implants Res*, **20**, 708-714.
- Friedmann, A., Dehnhardt, J., Kleber, B. M. & Bernimoulin, J. P. (2008). Cytobiocompatibility of collagen and ePTFE membranes on osteoblast-like cells in vitro. *J Biomed Mater Res A*, **86**, 935-941.
- Friedmann, A., Strietzel, F. P., Marezki, B., Pitaru, S. & Bernimoulin, J.-P. (2001). Observations on a new collagen barrier membrane in 16 consecutively treated patients. Clinical and histological findings. *J Periodontol*, **72**, 1616-1624.
- Friedmann, A., Strietzel, F. P., Marezki, B., Pitaru, S. & Bernimoulin, J. P. (2002). Histological assessment of augmented jaw bone utilizing a new collagen barrier membrane compared to a standard barrier membrane to protect a granular bone substitute material. *Clin Oral Implants Res*, **13**, 587-594.
- Hammerle, C. H. & Karring, T. (1998). Guided bone regeneration at oral implant sites. *Periodontol 2000*, **17**, 151-175.
- Hammerle, C. H. & Lang, N. P. (2001). Single stage surgery combining transmucosal implant placement with guided bone regeneration and bioresorbable materials. *Clin Oral Implants Res*, **12**, 9-18.
- Hockers, T., Abensur, D., Valentini, P., Legrand, R. & Hammerle, C. H. (1999). The combined use of bioresorbable membranes and xenografts or autografts in the treatment of bone defects around implants. A study in beagle dogs. *Clin Oral Implants Res*, **10**, 487-498.
- Jensen, S. S. & Terheyden, H. (2009). Bone augmentation procedures in localized defects in the alveolar ridge: clinical results with different bone grafts and bone-substitute materials. *Int J Oral Maxillofac Implants*, **24 Suppl**, 218-236.
- Jung, R. E., Zwahlen, R., Weber, F. E., Molenberg, A., van Lenthe, G. H. & Hammerle, C. H. (2006). Evaluation of an in situ formed synthetic hydrogel as a biodegradable membrane for guided bone regeneration. *Clin Oral Implants Res*, **17**, 426-433.
- Kohles, S. S., Vernino, A. R., Clagett, J. A., Yang, J. C., Severson, S. & Holt, R. A. (2000). A morphometric evaluation of allograft matrix combinations in the treatment of osseous defects in a baboon model. *Calcif Tissue Int*, **67**, 156-162.
- Lang, N. P., Bragger, U., Hammerle, C. H. & Sutter, F. (1994). Immediate transmucosal implants using the principle of guided tissue regeneration. I.

- 1  
2  
3 Rationale, clinical procedures and 30-month results. *Clin Oral Implants Res*, **5**,  
4 154-163.
- 5 Llambes, F., Silvestre, F. J. & Caffesse, R. (2007). Vertical guided bone regeneration  
6 with bioabsorbable barriers. *J Periodontol*, **78**, 2036-2042.
- 7 Mayrand, D. & Grenier, D. (1985). Detection of collagenase activity in oral bacteria.  
8 *Can J Microbiol*, **31**, 134-138.
- 9 McAllister, B. S. & Haghghat, K. (2007). Bone augmentation techniques. *J*  
10 *Periodontol*, **78**, 377-396.
- 11 Moses, O., Pitaru, S., Artzi, Z. & Nemcovsky, C. E. (2005). Healing of dehiscence-  
12 type defects in implants placed together with different barrier membranes: a  
13 comparative clinical study. *Clin Oral Implants Res*, **16**, 210-219.
- 14 Moses, O., Vitrial, D., Aboodi, G., Sculean, A., Tal, H., Kozlovsky, A., Artzi, Z.,  
15 Weinreb, M. & Nemcovsky, C. E. (2008). Biodegradation of three different  
16 collagen membranes in the rat calvarium: a comparative study. *J Periodontol*,  
17 **79**, 905-911.
- 18 Lekovic, V., Camargo, P. M., Weinlaender, M., Vasilic, N., Kenney, E. B. (2002).  
19 Comparison of platelet-rich plasma, bovine porous bone mineral, and guided  
20 tissue regeneration versus platelet-rich plasma and bovine porous bone  
21 mineral in the treatment of intrabony defects: a reentry study. *J Periodontol*,  
22 **73**, 198-205.
- 23 Nowzari, H. & Slots, J. (1995). Microbiologic and clinical study of  
24 polytetrafluoroethylene membranes for guided bone regeneration around  
25 implants. *Int J Oral Maxillofac Implants*, **10**, 67-73.
- 26 Pitaru, S., Friedmann, A., Meidan, L. & Bernimoulin, J. P. (2006). Ribose-crosslinked  
27 collagen membranes are more effective than ePTFE membranes in supporting  
28 bone augmentation in humans: a morphometric study. *J Clin Periodontol*, **33**,  
29 53 Abstract.
- 30 Proussaefs, P. & Lozada, J. (2005). The use of intraorally harvested autogenous  
31 block grafts for vertical alveolar ridge augmentation: a human study. *Int J*  
32 *Periodontics Restorative Dent*, **25**, 351-363.
- 33 Proussaefs, P. T., Valencia, G., Lozada, J. & Tatakis, D. N. (2002). A method to  
34 assess the clinical outcome of ridge augmentation procedures. *J Periodontol*,  
35 **73**, 302-306.
- 36 Rothamel, D., Schwarz, F., Sager, M., Herten, M., Sculean, A. & Becker, J. (2005).  
37 Biodegradation of differently cross-linked collagen membranes: an  
38 experimental study in the rat. *Clin Oral Implants Res*, **16**, 369-378.
- 39 Rothamel, D., Schwarz, F., Sculean, A., Herten, M., Scherbaum, W. & Becker, J.  
40 (2004). Biocompatibility of various collagen membranes in cultures of human  
41 PDL fibroblasts and human osteoblast-like cells. *Clin Oral Implants Res*, **15**,  
42 443-449.
- 43 Schwarz, F., Rothamel, D., Herten, M., Sager, M. & Becker, J. (2006). Angiogenesis  
44 pattern of native and cross-linked collagen membranes: an  
45 immunohistochemical study in the rat. *Clin Oral Implants Res*, **17**, 403-409.
- 46 Sela, M. N., Kohavi, D., Krausz, E., Steinberg, D. & Rosen, G. (2003). Enzymatic  
47 degradation of collagen-guided tissue regeneration membranes by periodontal  
48 bacteria. *Clin Oral Implants Res*, **14**, 263-268.
- 49 Simion, M., Baldoni, M., Rossi, P. & Zaffe, D. (1994). A comparative study of the  
50 effectiveness of e-PTFE membranes with and without early exposure during  
51 the healing period. *Int J Periodontics Restorative Dent*, **14**, 166-180.
- 52 Strietzel, F. P., Khongkhunthian, P., Khattiya, R., Patchanee, P. & Reichart, P. A.  
53 (2006). Healing pattern of bone defects covered by different membrane types--  
54  
55  
56  
57  
58  
59  
60

- 1  
2  
3 a histologic study in the porcine mandible. *J Biomed Mater Res B Appl*  
4 *Biomater*, **78**, 35-46.
- 5 Studer, S. P., Sourlier, D., Wegmann, U., Scharer, P. & Rees, T. D. (1997).  
6 Quantitative measurement of volume changes induced by oral plastic surgery:  
7 validation of an optical method using different geometrically-formed  
8 specimens. *J Periodontol*, **68**, 950-962.
- 9  
10 Tai, C. C., Sutherland, I. S. & McFadden, L. (2000). Prospective analysis of  
11 secondary alveolar bone grafting using computed tomography. *J Oral*  
12 *Maxillofac Surg*, **58**, 1241-1249; discussion 1250.
- 13  
14 Tal, H., Kozlovsky, A., Artzi, Z., Nemcovsky, C. E. & Moses, O. (2008). Long-term  
15 bio-degradation of cross-linked and non-cross-linked collagen barriers in  
16 human guided bone regeneration. *Clin Oral Implants Res*, **19**, 295-302.
- 17  
18 Tempro, P. J. & Nalbandian, J. (1993). Colonization of retrieved  
19 polytetrafluoroethylene membranes: morphological and microbiological  
20 observations. *J Periodontol*, **64**, 162-168.
- 21  
22 von Arx, T., Brogini, N., Jensen, S. S., Bornstein, M. M., Schenk, R. K. & Buser, D.  
23 (2005). Membrane durability and tissue response of different bioresorbable  
24 barrier membranes: a histologic study in the rabbit calvarium. *Int J Oral*  
25 *Maxillofac Implants*, **20**, 843-853.
- 26  
27 Windisch, S. I., Jung, R. E., Sailer, I., Studer, S. P., Ender, A. & Hammerle, C. H.  
28 (2007). A new optical method to evaluate three-dimensional volume changes  
29 of alveolar contours: a methodological in vitro study. *Clin Oral Implants Res*,  
30 **18**, 545-551.
- 31  
32 Yukna, R. A., Krauser, J. T., Callan, D. P., Evans, G. H., Cruz, R., Martin, M. (2000).  
33 Multi-center clinical comparison of combination anorganic bovine-derived  
34 hydroxyapatite matrix (ABM)/cell binding peptide (P-15) and ABM in human  
35 periodontal osseous defects. 6-month results. *J Periodontol* **71**, 1671-9.
- 36  
37 Zitzmann, N. U., Scharer, P. & Marinello, C. P. (2001). Long-term results of implants  
38 treated with guided bone regeneration: a 5-year prospective study. *Int J Oral*  
39 *Maxillofac Implants*, **16**, 355-366.
- 40  
41 Zubery, Y., Goldlust, A., Alves, A. & Nir, E. (2007). Ossification of a novel cross-  
42 linked porcine collagen barrier in guided bone regeneration in dogs. *J*  
43 *Periodontol*, **78**, 112-121.
- 44  
45 Zubery, Y., Nir, E. & Goldlust, A. (2008). Ossification of a collagen membrane cross-  
46 linked by sugar: a human case series. *J Periodontol*, **79**, 1101-1107.
- 47  
48  
49  
50  
51  
52  
53  
54  
55  
56  
57  
58  
59  
60



**Acknowledgements:**

We are grateful for initiation of the study by 3i Implant Innovations and their support with study materials. We also highly appreciate the contribution made by Institute Straumann AG supplying this study with additional materials such as BCP, Tissue Level Implants and gingival formers. We are deeply indebted to Asisa Saidowa for providing our group with schematic drawings of the principle used for assessments. Our gratitude goes also to Mr. Bodenstein and Mr. Schnitzer, who both supported the laboratory part of study providing clinical investigator with lab equipment and facilities.

1  
2  
3  
4  
5  
6  
7  
8  
9  
10  
11  
12  
13  
14  
15  
16  
17  
18  
19  
20  
21  
22  
23  
24  
25  
26  
27  
28  
29  
30  
31  
32  
33  
34  
35  
36  
37  
38  
39  
40  
41  
42  
43  
44  
45  
46  
47  
48  
49  
50  
51  
52  
53  
54  
55  
56  
57  
58  
59  
60

Legends:

Fig. 1: Flow diagram of study outline.

Fig. 2: clinical images of surgical procedure.

Fig. 2a: two Straumann Soft Tissue Level implants are placed displaying a dehiscence and a fenestration bone defects on the buccal aspect of the ridge. The necks of both implants are positioned supracrestally according to the protocol of use.

Fig. 2b: augmentation with biphasic calcium phosphate (BCP) is performed; the randomization assigned this site for test group (ribose cross-linked membrane).

Fig. 2c: primary closure by coronally advancing the flap tissue for submerged healing is achieved.

Fig. 2d: the site 6 months later prior to re-entry shows sufficient gain in width indicated by a perio probe.

Fig. 2e: re-opening demonstrates a complete fill of the defect extension by newly organized hard tissue in both, the area of former dehiscence and fenestration.

Fig. 2f: an example of intra surgical impression taking with sterile silicon and an individual tray.

Fig. 3: Schematic drawing of the principle for assessment of the parameters Width (W) and Height (H) at most crestal extension of augmented area on casts out of stone. The reflected portions of buccal flaps were reduced in stone for easier adaptation of the silicon template on both, cast 1 and cast 0.

Fig. 3a: mid-crestal section across alveolar ridge casted in plaster together with negative silicon template mounted on top shows position of implant neck and crestal extension of newly organized bone (cast 1). Perpendicular is marked on the

1  
2  
3 silicon template indicating the middle axis of the implant. A perpendicular to this one  
4  
5 at the crestal level indicates width of the ridge in buccal direction termed as W1/1.  
6  
7 H1/1 is the distance from the edge of silicon template down to the crossing point with  
8  
9 the buccal proximity of the crest.  
10  
11

12  
13 Fig 3b: mid-crestal section of the cast obtained at baseline surgery prior to  
14  
15 implant positioning (cast 0) with the template mounted according to references  
16  
17 determined by teeth adjacent to the gap thus reproducing the position previously  
18  
19 achieved on cast 1. The perpendicular indicating the middle axis of the implant is the  
20  
21 reference for assessment of Width 1/0 along the second perpendicular at the crestal  
22  
23 level again. Assessment of the distance H1/0 repeats the measurement H1/1,  
24  
25 however, the crossing point with alveolar crest is supposed to be more apical.  
26  
27  
28  
29

30  
31 Fig. 4: illustration of morphometric steps performed on casts under laboratory  
32  
33 conditions.  
34

35  
36 Fig. 4a: mid-crestal section of cast 1 (obtained after augmentation at re-entry) with  
37  
38 mounted silicon template shows the implant neck casted in plaster and the  
39  
40 perpendicular dropped from the edge of the template at the middle of cover screw  
41  
42 indicating the middle axis of the implant. According to the scheme in the Fig. 3 H1/1  
43  
44 marks the distance from the edge of the template to the first crestal contact with the  
45  
46 bone; W1/1 determines the distance from the mid-implant axis to the same crossing  
47  
48 point, respectively. H2/1 and W2/1 reflect the distances in the same manner more  
49  
50 apically.  
51  
52  
53

54  
55 Fig. 4b: mid-section of the cast 0 with the template transferred from cast 1 displaying  
56  
57 the reference lines obtained from cast 1 post augmentation for assessment of  
58  
59 baseline dimensions of the ridge. The gap between the ridge casted in plaster and  
60

1  
2  
3 the edge of the template indicates bone deficiency in buccal–lingual direction. The  
4  
5 labeled landmarks repeat those schematically drawn in Fig. 3.  
6  
7

8  
9 Fig. 4c: silicon template shows parallel walls and perpendicularly arranged top plan  
10  
11 and bottom for exact positioning transferring the template from cast 1 to cast 0.  
12  
13

14  
15 Fig. 4d: the image shows the tooth next to the area of interest from the opposite to  
16  
17 the edentulous area site with the template being exactly adapted.  
18  
19

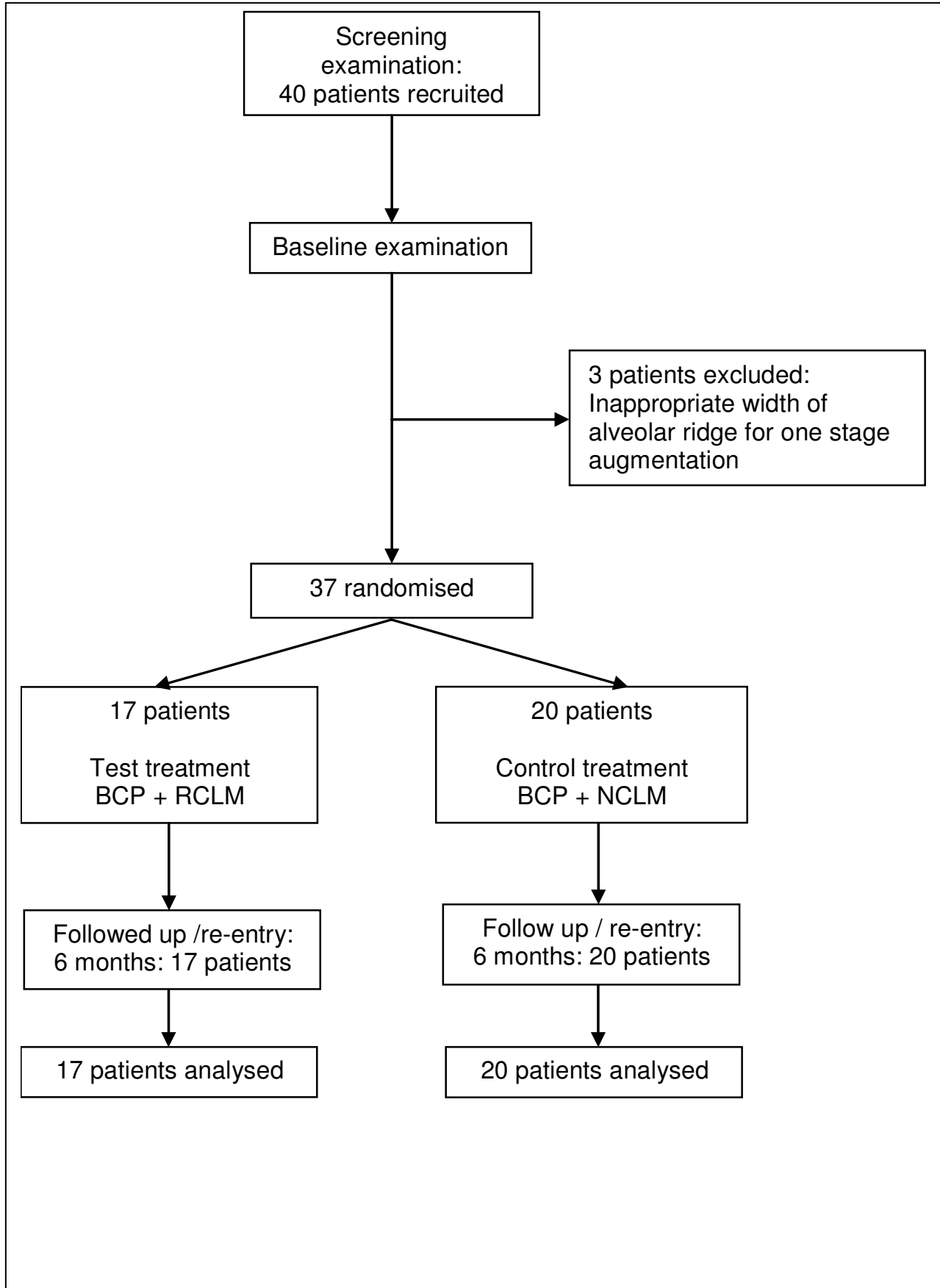
20  
21 Table 1: Comprehensive patient data (n = 37). Patient\*\*\* indicates sites excluded  
22  
23 from statistical analysis by secondary randomization.  
24

25  
26 Table 2: Baseline characteristics for patients and sites randomly selected for statistical  
27  
28 analysis (n = 37).  
29

30  
31 Table 3: Median values and ranges of morphometric outcome (\* p < 0.05).  
32  
33  
34  
35  
36  
37  
38  
39  
40  
41  
42  
43  
44  
45  
46  
47  
48  
49  
50  
51  
52  
53  
54  
55  
56  
57  
58  
59  
60

1  
2  
3  
4  
5  
6  
7  
8  
9  
10  
11  
12  
13  
14  
15  
16  
17  
18  
19  
20  
21  
22  
23  
24  
25  
26  
27  
28  
29  
30  
31  
32  
33  
34  
35  
36  
37  
38  
39  
40  
41  
42  
43  
44  
45  
46  
47  
48  
49  
50  
51  
52  
53  
54  
55  
56  
57  
58  
59  
60

Fig. 1



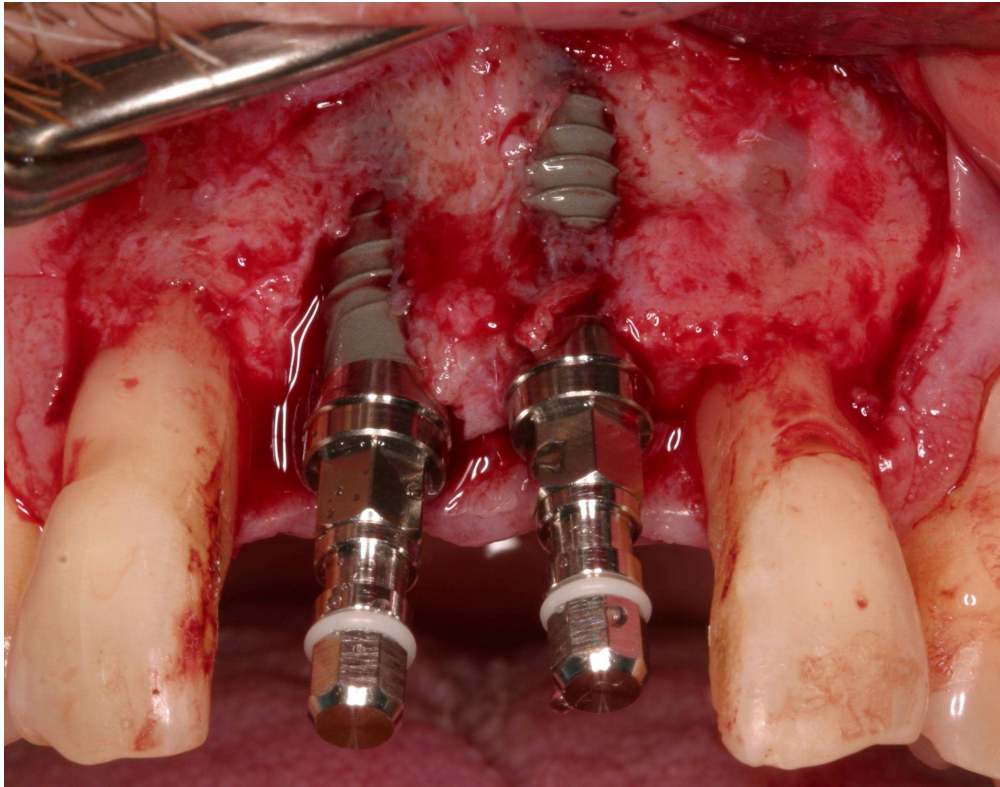


Fig. 2a: Two Straumann Soft Tissue Level implants are placed displaying a dehiscence and a fenestration bone defects on the buccal aspect of the ridge. The necks of both implants are positioned supracrestally according to the protocol of use.  
316x249mm (180 x 180 DPI)

1  
2  
3  
4  
5  
6  
7  
8  
9  
10  
11  
12  
13  
14  
15  
16  
17  
18  
19  
20  
21  
22  
23  
24  
25  
26  
27  
28  
29  
30  
31  
32  
33  
34  
35  
36  
37  
38  
39  
40  
41  
42  
43  
44  
45  
46  
47  
48  
49  
50  
51  
52  
53  
54  
55  
56  
57  
58  
59  
60

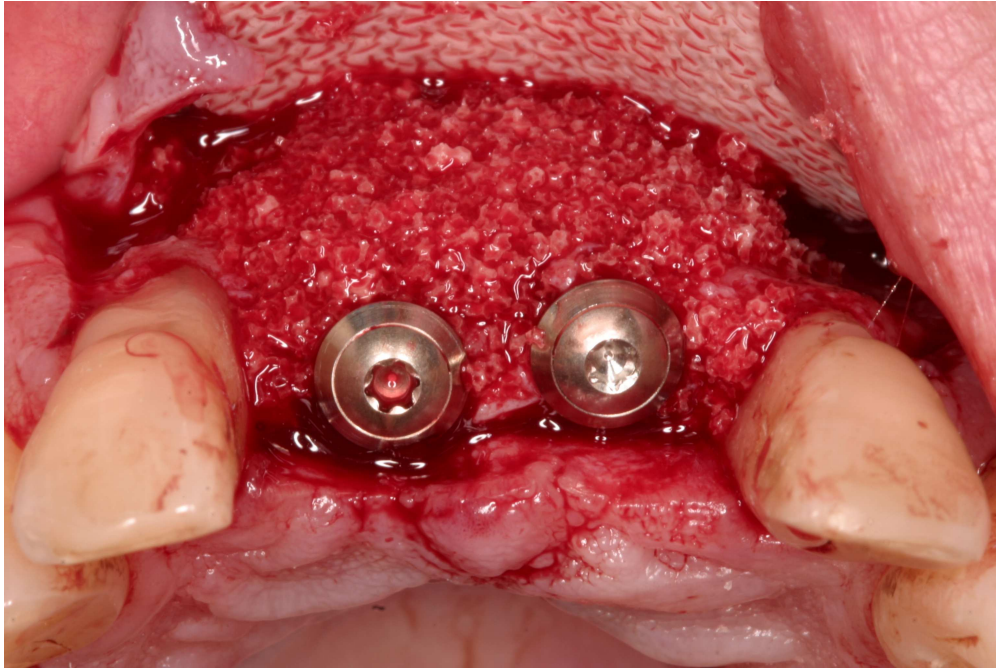


Fig. 2b: Augmentation with biphasic calcium phosphate (BCP) is performed; the randomization assigned this site for test group (ribose cross-linked membrane).  
433x288mm (180 x 180 DPI)

Review

1  
2  
3  
4  
5  
6  
7  
8  
9  
10  
11  
12  
13  
14  
15  
16  
17  
18  
19  
20  
21  
22  
23  
24  
25  
26  
27  
28  
29  
30  
31  
32  
33  
34  
35  
36  
37  
38  
39  
40  
41  
42  
43  
44  
45  
46  
47  
48  
49  
50  
51  
52  
53  
54  
55  
56  
57  
58  
59  
60

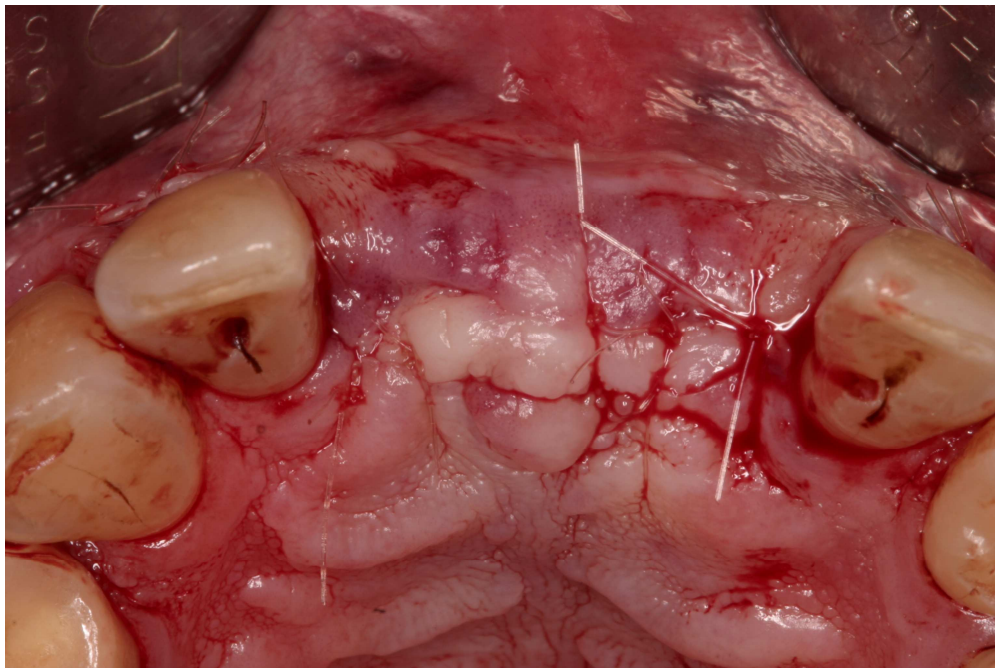

Fig. 2c: Primary closure by coronally advancing the flap tissue for submerged healing is achieved.  
433x288mm (180 x 180 DPI)

Review



1  
2  
3  
4  
5  
6  
7  
8  
9  
10  
11  
12  
13  
14  
15  
16  
17  
18  
19  
20  
21  
22  
23  
24  
25  
26  
27  
28  
29  
30  
31  
32  
33  
34  
35  
36  
37  
38  
39  
40  
41  
42  
43  
44  
45  
46  
47  
48  
49  
50  
51  
52  
53  
54  
55  
56  
57  
58  
59  
60

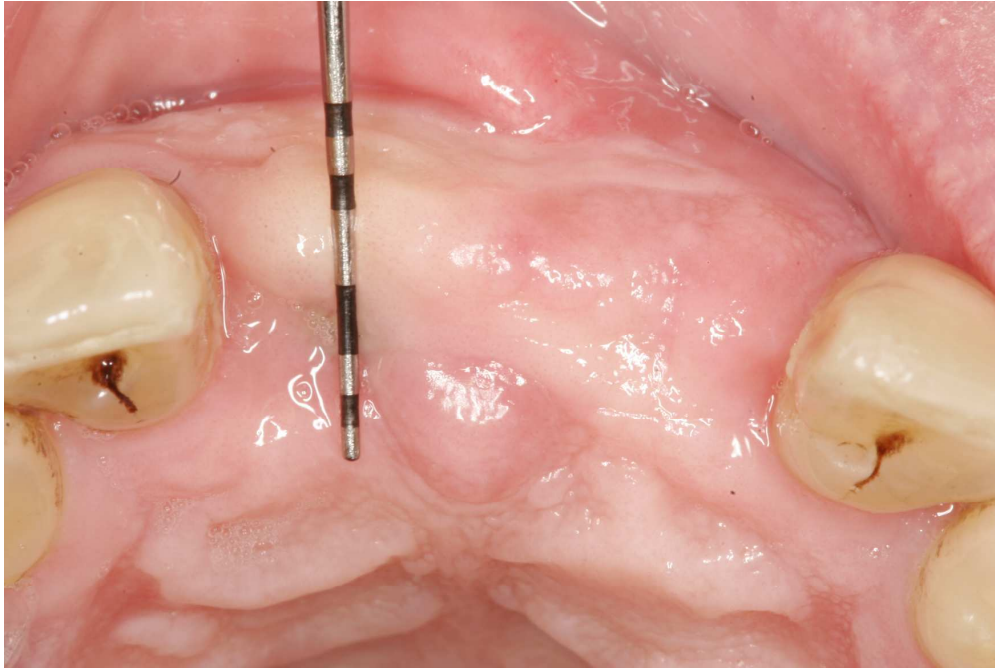

Fig. 2d: The site 6 months later prior to re-entry shows sufficient gain in width indicated by a perio probe.

1236x824mm (72 x 72 DPI)

Review

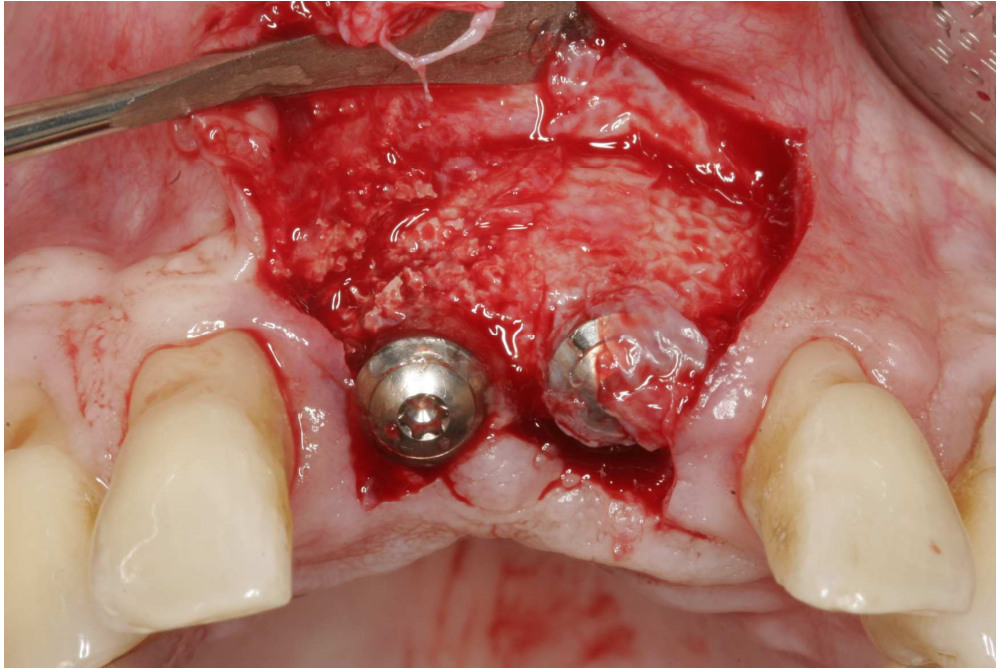


Fig. 2e: Re-opening demonstrates a complete fill of the defect extension by newly organized hard tissue in both, the area of former dehiscence and fenestration.  
1236x824mm (72 x 72 DPI)

Review

1  
2  
3  
4  
5  
6  
7  
8  
9  
10  
11  
12  
13  
14  
15  
16  
17  
18  
19  
20  
21  
22  
23  
24  
25  
26  
27  
28  
29  
30  
31  
32  
33  
34  
35  
36  
37  
38  
39  
40  
41  
42  
43  
44  
45  
46  
47  
48  
49  
50  
51  
52  
53  
54  
55  
56  
57  
58  
59  
60

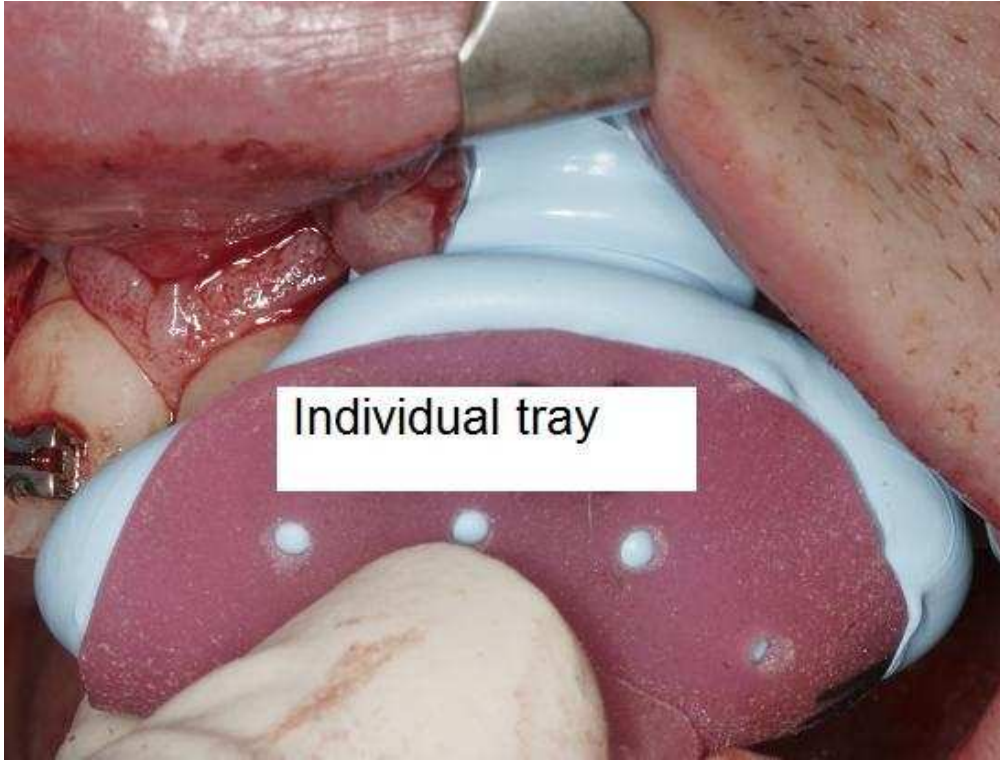


Fig. 2f: An example of intra surgical impression taking with sterile silicon and an individual tray.  
192x146mm (72 x 72 DPI)

Review

Fig. 3a

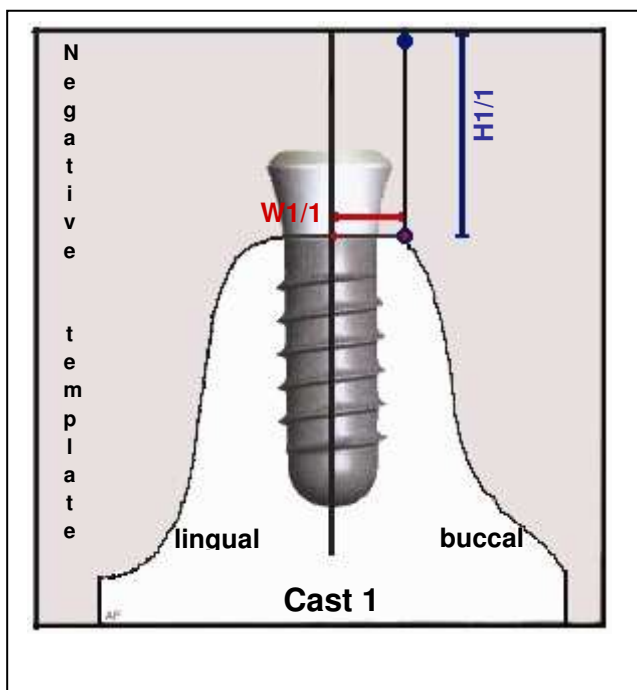
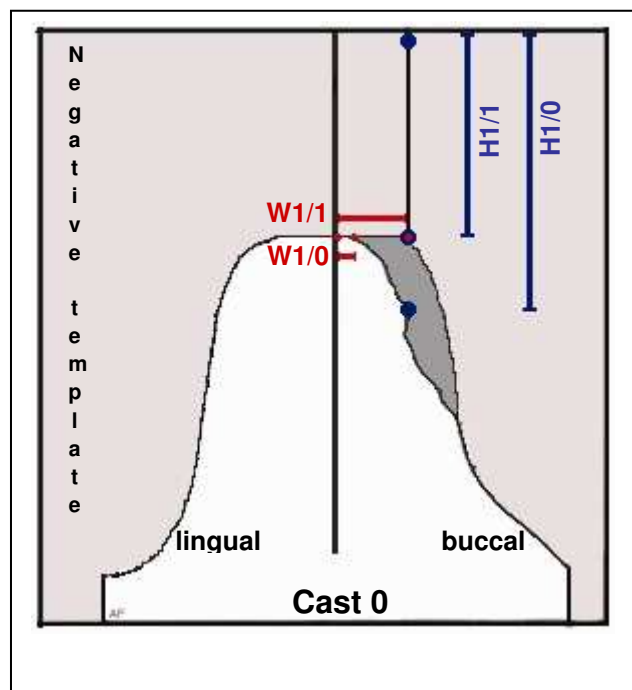


Fig. 3b



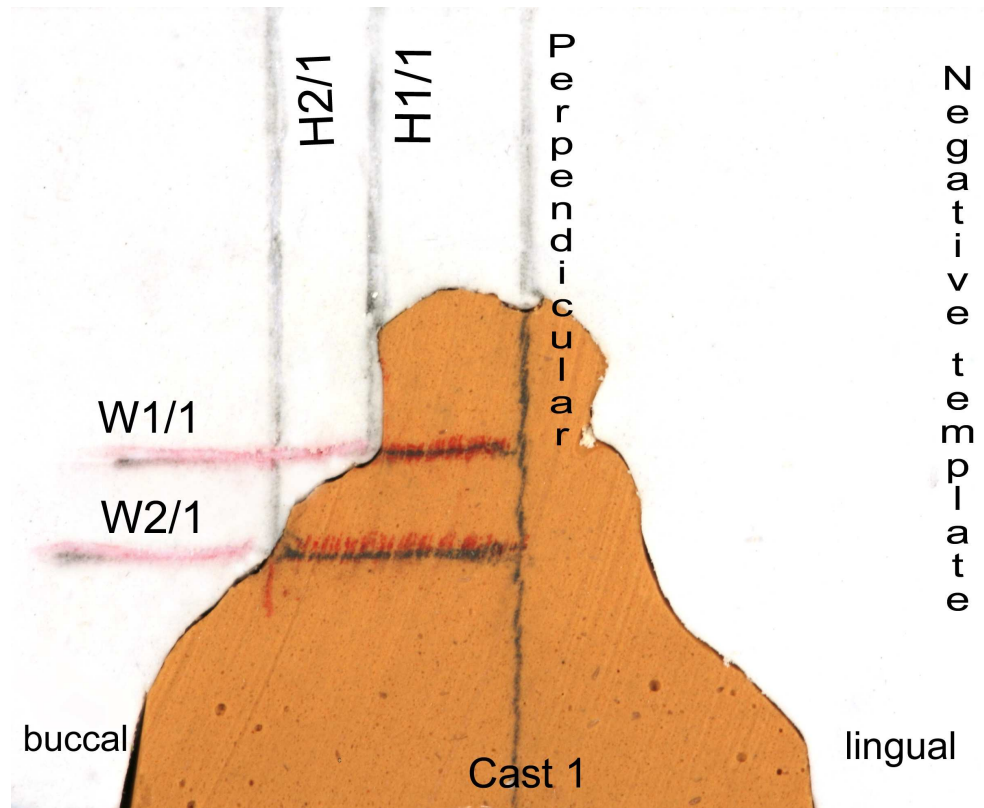


Fig. 4a: Mid-crestal section of cast 1 (obtained after augmentation at re-entry) with mounted silicon template shows the implant neck casted in plaster and the perpendicular dropped from the edge of the template at the middle of cover screw indicating the middle axis of the implant. According to the scheme in the Fig. 3 H1/1 marks the distance from the edge of the template to the first crestal contact with the bone; W1/1 determines the distance from the mid-implant axis to the same crossing point, respectively. H2/1 and W2/1 reflect the distances in the same manner more apically.

868x698mm (72 x 72 DPI)

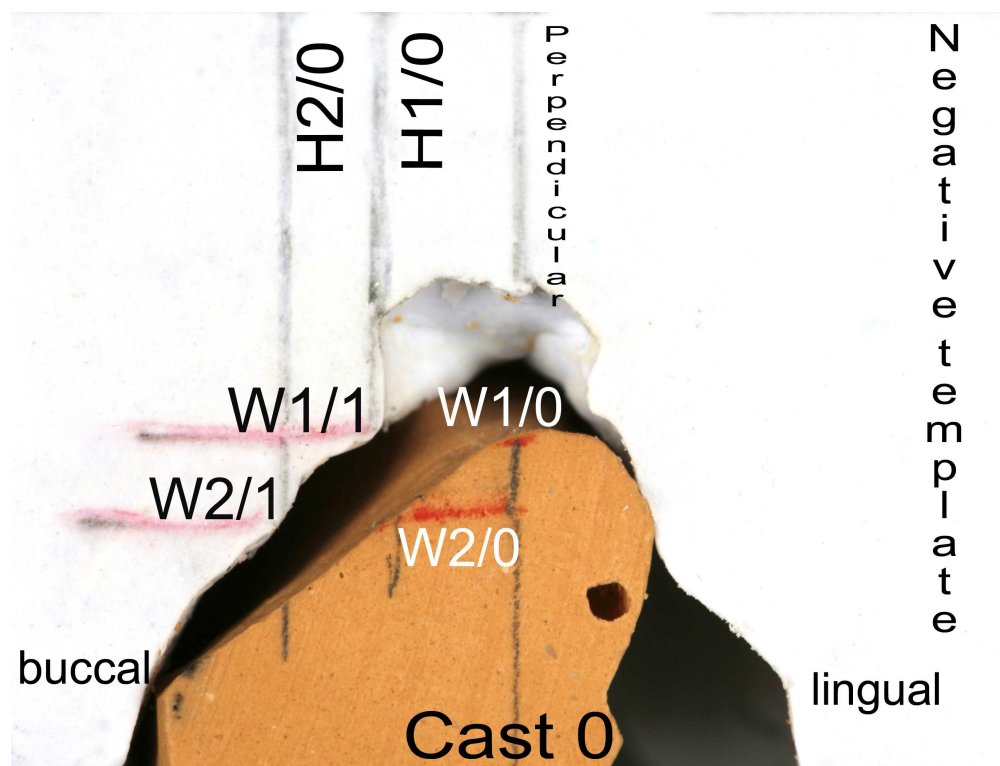


Fig. 4b: Mid-section of the cast 0 with the template transferred from cast 1 displaying the reference lines obtained from cast 1 post augmentation for assessment of baseline dimensions of the ridge. The gap between the ridge casted in plaster and the edge of the template indicates bone deficiency in buccal-lingual direction. The labeled landmarks repeat those schematically drawn in Fig. 3.

970x735mm (72 x 72 DPI)

1  
2  
3  
4  
5  
6  
7  
8  
9  
10  
11  
12  
13  
14  
15  
16  
17  
18  
19  
20  
21  
22  
23  
24  
25  
26  
27  
28  
29  
30  
31  
32  
33  
34  
35  
36  
37  
38  
39  
40  
41  
42  
43  
44  
45  
46  
47  
48  
49  
50  
51  
52  
53  
54  
55  
56  
57  
58  
59  
60




Fig. 4c: Silicon template shows parallel walls and perpendicularly arranged top plan and bottom for exact positioning transferring the template from cast 1 to cast 0.  
750x820mm (72 x 72 DPI)



Fig. 4d: The image shows the tooth next to the area of interest from the opposite to the edentulous area site with the template being exactly adapted.  
518x1027mm (72 x 72 DPI)



Tab. 1

Patient	Age	Sex F / M	Regio: 1=max.posterior 2=mand.posterior 3=max.anterior 4=mand.anterior	Defect size		N implants total	Test/Control 1 / 0	Exposure Yes/no 1 / 0
				Baseline (mm)	Depth / Width			
1	58	F	2	4	3	3	1	0
2	68	F	2	5	5	2	1	0
3	64	M	3	6	5	2	1	1
4	67	F	2	5	5	2	0	1
5	61	M	3	7	5	2	1	1
6***	47	F	2	4	5	1	1	1
6			2	4	8	1	0	1
7	59	F	2	5	4	1	0	1
7***			2	5	4	2	1	1
8	37	M	2	7	6	1	1	1
9	62	F	2	5	4	2	1	1
10***	52	F	2	8	4	2	0	1
10			2	5	4	2	1	1
11	64	F	3	8	6	1	0	1
12	44	F	2	2	4	1	0	0
13***	49	F	2	4	4	2	0	1
13			2	6	5	2	1	0
14	49	F	2	5	4	1	0	0
14***			2	5	5	1	1	1
15	40	M	2	5	6	1	0	0
16	69	M	3	10	6	1	1	1
17***	65	M	1	7	5	1	1	0
17			1	10	15	1	0	1

Patient	Age	Sex	Regio:	Depth	Width	N	Test/Control	Exposure
18	68	F	2	6	6	2	0	0
19	33	M	3	10	6	1	1	1
20	63	F	4	8	5	2	0	1
21	64	F	2	5	5	2	0	1
22	55	F	2	4	6	2	1	1
23	40	M	2	7	6	1	0	1
24	58	F	3	8	4	1	0	1
25	65	F	2	7	4	2	0	0
26	56	F	2	3	5	2	1	1
27	67	F	2	4	3	2	1	1
28	30	M	3	10	6	1	0	1
29***	67	M	2	4	4	1	0	1
29			2	3	3	2	1	0
30	69	F	2	5	4	2	1	1
31***	64	F	2	4	3	2	0	0
31			2	3	3	2	1	0
32	69	F	2	6	4	2	0	0
33***	24	M	3	7	4	1	1	0
33			3	6	4	1	0	1
34	44	F	1	8	10	1	1	1
35	49	F	2	5	7	2	0	0
36	62	F	2	7	5	2	0	0
37	59	F	1	1	1	2	0	0

Tab. 2

	<b>Test (N = 17)</b>	<b>Control (N = 20)</b>
Age: median (range)	61 years (33 – 69)	59 years (24 – 69)
Gender: <b>F</b> : <b>M</b>	11 : 6	15 : 5
Smoking: - : +	16 : 1	18 : 2
Soft tissue dehiscence: - : + (%)	5 : 12 (70.5)	9 : 11 (55.0)

For Peer Review

Tab. 3

	<b>Test (N = 17)</b>	<b>Control (N = 20)</b>
	<b>(mm)</b>	<b>(mm)</b>
$\Delta H1 (= H1/1 - H1/0)$	1.1 (0.8 – 1.9)	0.2 (-0.2 – 1.8)
P =	0.0463*	
$\Delta W1 (= W1/1 - W1/0)$	1.8 (1.0 – 3.0)	0.7 (-0.0 – 2.3)
P =	0.0359*	
$\Delta H2 (= H2/1 - H2/0)$	2.5 (1.4 – 3.7)	2.7 (0.2 – +4.3)
P =	0.5674	
$\Delta W2 (= W2/1 - W2/0)$	3.0 (2.2 – 3.3)	2.1 (0.8 – 3.0)
P =	0.1189	