



HAL
open science

HEALING OF PERI-IMPLANT TISSUES AFTER FLAPLESS AND FLAPPED IMPLANT INSTALLATION

Abeer Bayounis, Hamad Alzoman, John Jansen, Nadir Babay

► **To cite this version:**

Abeer Bayounis, Hamad Alzoman, John Jansen, Nadir Babay. HEALING OF PERI-IMPLANT TISSUES AFTER FLAPLESS AND FLAPPED IMPLANT INSTALLATION. *Journal of Clinical Periodontology*, 2011, 38 (8), pp.754. 10.1111/j.1600-051X.2011.01735.x . hal-00639786

HAL Id: hal-00639786

<https://hal.science/hal-00639786>

Submitted on 10 Nov 2011

HAL is a multi-disciplinary open access archive for the deposit and dissemination of scientific research documents, whether they are published or not. The documents may come from teaching and research institutions in France or abroad, or from public or private research centers.

L'archive ouverte pluridisciplinaire **HAL**, est destinée au dépôt et à la diffusion de documents scientifiques de niveau recherche, publiés ou non, émanant des établissements d'enseignement et de recherche français ou étrangers, des laboratoires publics ou privés.



HEALING OF PERI-IMPLANT TISSUES AFTER FLAPLESS AND FLAPPED IMPLANT INSTALLATION

Journal:	<i>Journal of Clinical Periodontology</i>
Manuscript ID:	CPE-06-10-2693.R3
Manuscript Type:	Original Article Implant Dentistry
Date Submitted by the Author:	17-Mar-2011
Complete List of Authors:	Bayounis, Abeer; College of Dentistry, King Saud University, Department of Peridontics and Community Dentistry Alzoman, Hamad; College of Dentistry, King Saud University, Department of Periodontics and Community Dentistry Jansen, John; Radboud University Nijmegen Medical Center, Biomaterials; College of Dentistry, King Saud University, Dental Implant and Osseointegration Research Chair Babay, Nadir; College of Dentistry, King Saud University, Department of Periodontics and Community Dentistry
Topic:	Implantology
Keywords:	extraction
Main Methodology:	Animal Model

SCHOLARONE™
Manuscripts

1
2 **HEALING OF PERI-IMPLANT TISSUES AFTER FLAPLESS AND FLAPPED**
3
4 **IMPLANT INSTALLATION**

5
6
7
8 **Abeer M.A. Bayounis¹, Hamad A. Alzoman^{1, 2}, John A.Jansen^{2, 3}, Nadir Babay¹**
9

- 10
11
12 1. Department of Periodontics and Community Dentistry, College of Dentistry, King
13 Saud University, Riyadh, Kingdom of Saudi Arabia
14
15 2. Dental Implant and Osseointegration Research Chair (DIORC), College of Dentistry,
16 King Saud University, Riyadh, Saudi Arabia.
17
18 3. Department of Biomaterials, Radboud University Nijmegen Medical Center,
19 Nijmegen, The Netherlands
20
21
22
23
24
25
26
27

28 Corresponding author:

29 John A.Jansen, DDS, PhD

30 Department of Biomaterials

31 Radboud University Nijmegen Medical Center

32 PO Box 9101, 6500 HB Nijmegen

33 The Netherlands

34 j.jansen@dent.umcn.nl
35
36
37
38
39
40
41
42
43
44
45
46
47
48
49
50
51
52
53
54
55
56
57
58
59
60

ABSTRACT

Aim: The aim of this study was to investigate the consequences of different flapless procedures for the installation of dental implants on peri-implant bone response

Materials and methods: After bilateral extraction of the mandibular second and third premolars and a three-month healing period, 30 SLActive ® implants were installed for three months in 10 Beagle dogs according to three different surgical approaches, i.e.: (1) flapped (F), (2) tissue punch flapless (P), and (3) direct flapless (DF).

Results: At harvesting, 29 implants were analyzed. Micro-CT and histomorphometrical evaluation (which included also the mobile implants) showed comparable results in bone volume ($F=55\pm 9$, $P=51\pm 4$, $DF=54\pm 5$) and crestal bone level ($F=3420\pm 762$, $P=5358\pm 1681$, $DF=3843\pm 433$). However, the implants inserted with the punch approach revealed a significantly lower 1st bone contact ($F=3420\pm 762$, $P=5358\pm 1681$, $DF=3843\pm 433$) and bone-to-implant contact percentage ($F=70\pm 12$, $P=48\pm 23$, $DF=73\pm 12$). Considering the gingival response, the barrier epithelium was also significantly deeper around the implants installed with the punch approach ($F=1383\pm 332$, $P=2278\pm 1154$, $DF=1107\pm 300$).

Conclusions: The results indicate that a flapless surgical technique can be used for the installation of oral implants. In addition using a tissue punch wider than the implant diameter should be avoided, as it can jeopardize the outcome of the implantation procedure.

Deleted: 6

Clinical Relevance

Scientific rationale for the study: There is a tendency to install dental implants without elevating a mucoperiosteal flap. However, there is a lack of histological data dealing with the effect of flapless surgery on implant healing.

Principal findings: Direct drilling through the gingival mucosa does not jeopardize the crestal bone level, bone-to-implant contact and implant stability.

Practical implications: Flapless surgery can be used for the installation of oral implants.

Nevertheless, the use of a tissue punch, which is much wider than the implant diameter, has to be avoided.

Deleted: d

Deleted: flapless technique is very important for the final per-implant tissue response

Source of Funding

The study was self-funded by the authors and their institution.

INTRODUCTION

Currently, the installation of dental implants can be considered as a routine method in the rehabilitation of partially and completely edentulous patients. Initially, dental implants were installed using a surgical protocol, which involved the elevation of a mucoperiosteal flap. The rationale for this approach was to prevent infection and ingrowth of gingival tissue in between the implant and the bone margins of the implant bed.

However, it is known from periodontal surgery that any flap reflection always results in bone resorption and changes of the crestal bone level (Nobuto et al. 2005, Wood et al. 1972). In view of this problem, a flapless surgical approach was already introduced in the late 1970s by Ledermann (1977). In this procedure a motor-driven circular tissue punch, or a circumferential incision utilizing a surgical blade was used to remove the soft tissue at the implant site without any surgical flap elevation (Sclar 2007). Another approach of flapless implant surgery is penetrating with a round bur directly through the mucosa into the alveolar bone.

Besides the suggested reduced crestal bone resorption, flapless surgery is associated with several other advantages, like: (1) a reduced surgical time and less traumatic surgery, which results in minimal bleeding and an accelerated postsurgical healing as well as allows the patient to resume normal oral hygiene procedures immediately after surgery (Becker et al. 2005, Fortin et al. 2006), and (2) better maintenance of the soft tissue profiles, including the gingival margins of adjacent teeth and the interdental papilla (Ramfjord et al. 1968, Wood et al. 1972, Jeong et al. 2007, Cairo et al. 2008).

Despite these evident advantages, the major drawback of flapless implant surgery is that it is a 'blind' surgical technique. As a consequence, thermal damage can occur due to reduced access

1
2 for external irrigation during the implant bed preparation. Also, the surgeon cannot
3
4 manipulate the soft tissues to achieve a proper adaptation of keratinized gingiva (Sclar, 2007).

5
6 In addition to these advantages and disadvantages, there are also some strict anatomical
7
8 requirements formulated to allow the performance of a flapless procedure. These include the
9
10 availability of: (1) a sufficient bone width and height because the lack of a direct view of the
11
12 bone topography, (2) adequate keratinized tissue due to the inevitable sacrifice of some
13
14 keratinized tissue, and (3) the absence of significant tissue undercuts to prevent dehiscence
15
16 and fenestrations (Hahn 2000, Campelo et al. 2002, Kan et al. 2000).

17
18 A lot of literature is already available to support the reliability and safety of flapless implant
19
20 surgery (Campelo & Camara 2002, Rocci et al. 2003, Blanco et al. 2008, Becker et al. 2009,
21
22 de Bruyn et al. 2009). Most of these studies deal with retrospective and prospective studies, in
23
24 which frequently image-guided templates are used for the installation of the implants (Azari
25
26 & Nikzad 2008, D'haese et al. 2009, Komiyama et al. 2009, Lindeboom & van Wijk 2010).
27
28 Evaluation of the efficacy of the procedure is based on pocket depth measurements as well as
29
30 marginal bone loss using radiographs. However, it has been reported before that the use of
31
32 these clinical parameters overrate the histological marginal bone level (Caulier et al. 1997).
33
34 Besides the limited diagnostic value of these evaluation techniques, only two studies are
35
36 available which provide histological data about the effect of flapless surgery on peri-implant
37
38 bone loss (Becker et al. 2006, Lee et al. 2010). Unfortunately, the data, as presented in these
39
40 studies, do not corroborate with each other. Becker et al. (2006), who installed the implants by
41
42 direct drilling to the mucosa, found favorable histological data. In contrast, Lee et al. (2010),
43
44 who used tissue punches with various sizes in their flapless approach, reported a possible
45
46 negative effect on the junctional epithelial as well as crestal bone response, which was found
47
48 to be depending on the diameter of the used tissue punch.
49
50
51
52
53
54
55
56
57
58
59
60

1
2 In view of the apparent lack of histological data dealing with the effect of flapless surgery on
3
4 implant healing, the present dog study was done to investigate the consequences of different
5
6 flapless surgical procedures (i.e., tissue punch and direct approach) on peri-implant response
7
8 tissue changes.

9
10 The null hypothesis was that there are no significant differences in the histological outcome of
11
12 bone-to-implant response, crestal bone level, barrier epithelium and connective tissue
13
14 thickness when utilizing different surgical approaches.

15
16 The alternative hypothesis was that the used surgical approach in dental implant placement
17
18 will affect bone-to-implant response, crestal bone level alterations, barrier epithelium and
19
20 connective tissue thickness.
21
22
23
24
25
26
27
28
29
30
31
32
33
34
35
36
37
38
39
40
41
42
43
44
45
46
47
48
49
50
51
52
53
54
55
56
57
58
59
60

MATERIALS AND METHODS

Animals

The study was performed at the Animal Research Center at the affiliated King Khalid University Hospital. Ten healthy adult Beagle dogs, 1-2 years of age, with an average weight of 8 to 15 kg, were used. All dogs were housed in single cages. After tooth extractions and dental implant installation, the dogs were fed with soft food. The study protocol was approved by the Animals Ethical Committee of King Saud University and performed according institutional regulations.

Surgical Procedures

Anesthesia

Before surgery, the dogs were premedicated using atropine (Neozine, Rhodia, Brazil) 0.5mg/kg intramuscularly (IM) to prevent against salivation and vomiting. Anesthesia was induced by injection of Ketamine HCl® (ketamine 10%: 8-10 mg/kg; Tekam Al Hikam Pharmaceuticals, Amman, Jordan) and Rompun® xylazine (Seton 2%: 1-3 mg/kg; Laboratorios Calier, Barcelona, Spain) IM. Local anesthesia with xylocaine® (30 mg of 2% lidocaine with 1:80,000 epinephrine; Astra, Sodertalje, Sweden) was used at the site of tooth extraction to control bleeding.

Also, Duphaphen strep B.P® (injectable preparation of streptomycin, 2 ml/kg; Solvay, Massa, Italy) was given during surgery and post-operatively.

Tooth Extraction

Bilateral mandibular second and third premolars (PM2 and PM3) were extracted in each dog. Therefore, the premolars were hemisectioned using a high speed hand piece and extracted

1
2 using an appropriately sized dental elevator as well as forceps. Following tooth extraction, the
3
4 extraction wounds were approximated and closed with 4/0 Vicryl resorbable sutures.
5
6
7

8 Oral implant installation

9
10 After a healing period of three months, dental implants were installed. Bone fill of the
11
12 extraction sockets was confirmed by radiography. The same protocol for anesthesia and
13
14 antibiotics was used as for tooth extraction. In total 30 dental implants were installed with a
15
16 length of 8 mm, a diameter of 3.3 mm, a 2.8 mm high smooth neck), and a 3.5 mm shoulder
17
18 diameter (Straumann® Dental Implant System, SLActive® surface, Basel, Switzerland).
19

20 The implants were placed following one of three surgical approaches:

- 21
22 A. Flapped surgical approach; A full thickness flap was reflected by using a crestal
23
24 incision connected to two vertical incisions. After exposure of the alveolar ridge,
25
26 implants sites were prepared using a low-speed drill with copious external cooling
27
28 with saline solution. A graded series of drills was used for the implant bed
29
30 preparation. The final drill had a diameter of 2.8 mm, which was followed by implant
31
32 installation. After implant placement, the flaps were sutured back with 4/0 Vicryl®
33
34 resorbable sutures.
35
36 B. Flapless surgical approach;
- 37 1. Circular soft tissue punch; The soft tissue preparation of the implant site was done
38
39 using a motor-driven 5-mm-wide circular tissue punch at the center of the implant
40
41 placement site. Subsequently, the implant bed was prepared following the same
42
43 sequence as used for the flapped surgical approach.
44
 - 45 2. Direct round bur; No soft tissue preparation was done at all, but the same implant
46
47 bed preparation steps were followed, starting with a round bur (diameter 1.4 mm),
48
49 which was used to penetrate the soft tissue directly into the bone .
50
- 51
52
53
54
55
56
57
58
59
60

1
2 The implants in all of the groups were installed in a non-submerged position with their
3
4 “smooth” per mucosal part penetrating through the mucosa. Care was taken to place all
5
6 implants at the same height and to avoid perforation of the buccal or lingual cortical plates. It
7
8 was attempted to place the implants in such a way that the marginal level of the sand-blasted
9
10 and acid-etched (SLA) – coated surface was leveled with the alveolar bone crest. In order to
11
12 achieve this in the flapless group, bone probing was performed immediately before implant
13
14 installation, taking into consideration that the smooth surface of the implant had a height of
15
16 2.8 mm.

17
18 Each dog received a total of three oral implants, two at one side of the mandible and one at
19
20 the other side. Implant installation and randomization was done according the schedule as
21
22 listed in Table 1.
23
24
25

26 **Specimen preparation**

27
28 Three months after implant installation, all dogs were euthanized by an overdose of ketamine
29
30 10% (8-10mg/kg) and xylazine 2% (1-3 mg/kg) IM. Subsequently, the mandibles were
31
32 harvested and IsoMet precision saw (Buehler, Düsseldorf, Germany) was used to cut the
33
34 specimens in separate bone blocks containing one implant each. Each specimen was kept
35
36 individually in 5% formalin and the containers were labeled according to the dog number, the
37
38 quadrant and the surgical technique used for each implant.
39
40

41 **Micro CT**

42
43 After fixation in phosphate-buffered formaldehyde solution (pH=7.4) and dehydration in
44
45 ethanol 70%, three-dimensional micro-computed tomography (μ CT) images were made to
46
47 analyze the bone mineral density and bone volume of the implant surrounding bone mass. The
48
49 specimens were wrapped in Parafilm M[®] (Pechiney Plastic Packaging, Chicago, USA) to
50
51

1
2 prevent drying during scanning. Then, all samples were scanned at an energy of 101 kV and
3
4 an intensity of 96 μ A with a resolution of 37.41 μ m pixel using an aluminum filter (1mm)
5
6 (Skyscan-1072 X-ray microtomograph, TomoNT version 3N.5, Skyscan[®], Kontich Belgium).
7

8 In addition, calibration rods with standardized bone mineral density were scanned as
9
10 reference. Cone-Beam reconstruction (version 2.15, Skyscan[®]) was performed. All scan and
11
12 reconstruction parameters applied were identical for all specimens and calibration rods.
13

14 The data were analyzed by CT Analyser (version 1.4, Skyscan[®]). The region of interest (ROI)
15
16 was specified as an annular area with a diameter of 1.5 mm surrounding the implants over an
17
18 area from the first thread to the last thread. In this area bone volume (BV) was determined.
19
20 Bone volume (mm^3) was expressed as a percentage of the total ROI volume, using the
21
22 equation:

$$\text{Bone volume/Total ROI tissue volume} \times 100\%$$

23 24 25 26 27 **Histological procedures and histomorphometrical evaluation**

28
29 After micro-CT analysis, the specimens were prepared for histological and
30
31 histomorphometrical evaluation. First, the specimens were dehydrated in ethanol and
32
33 embedded in methylmethacrylate (MMA). After polymerization in MMA, three thin (10 μ m)
34
35 non-decalcified sections in bucco-lingual direction were prepared parallel to the long axis of
36
37 the implant with a modified diamond blade sawing microtome technique (Leica, SP1600,
38
39 Nussboch, Germany). All sections were stained with basic fuchsin and methylene blue and
40
41 were examined with a light microscope (Zeiss - Axio Imager Z1 automated microscope with
42
43 AxioCam MRc5 digital camera and AxioVision V6.3.2. acquisition software, Göttingen,
44
45 Germany). In addition, digital image analysis software (Leica Qwin Pro, Leica Microsystems
46
47 Imaging Solutions, Cambridge, UK) was used for histomorphometrical measurements.
48

49 The following parameters were assessed (Figure 1):
50

- 1
2
3
4
5
6
7
8
9
10
11
12
13
14
15
16
17
18
19
20
21
22
23
24
25
26
27
- A. Barrier epithelium length (BEL): The barrier epithelium length was measured by drawing a line over the top of the gingival epithelium perpendicular on the implant surface. Subsequently, the length of the barrier epithelium was measured from this line to the boundary of the junctional epithelium.
- B. Connective tissue thickness (CTT): The thickness of the connective tissue from the apical limitation of the gingival epithelium to the first bone-to-implant contact.
- C. Bone level (BL): The distance from the top of the implant to the bone crest in contact with the implant surface.
- D. Percentage of bone contact at the interface (BIC): The amount of bone contact was defined as the percentage of implant length at which there was direct bone-to-implant contact without intervening soft tissue layers. Measurements for bone-to-implant contact were performed along the implant interface from the most coronal bone contact till the apex of the implant.

28 All histomorphometric procedures were performed on three representative sections of each
29 implant and done blindly by two different experienced operators (VC and LH).
30
31
32

33 **Statistical analysis**

34
35 All measurements were statistically evaluated using commercial available software program
36 (SPSS 16.0, SPSS Inc., Chicago, USA) . Data were analyzed using paired t-testing. A
37
38 Shapiro-Wilk test was done to determine that all data were from a normal distribution.
39
40
41 Differences were considered statistically significant when the P-value was less than 0.05.
42
43
44
45
46
47
48
49
50
51
52

RESULTS

Clinical observations

A total of 30 dental implants were placed, which showed all primary stability at the moment of installation. All implants were inserted in an undersized mode in the high density bone of the dog mandible. The implants were always surrounded by an attached gingiva. At the time of euthanasia, clinical examination showed uneventful healing for 26 implants, without any sign of clinical mobility. No complications, as swelling, inflammation or exudation of the pergingival tissues was observed. Three dental implants, as placed with the tissue punch technique, appeared clinically to be mobile (dog 6 – right/distal implant, dog 7 – right implant, dog 10 - right implant) and one implant (dog 7 – left/mesial implant) placed, using the direct round bur technique, was found to be lost.

Micro-CT Measurements

Analysis of the micro-CT images indicated a bone volume percentage of 55 ± 9 for the flapped surgical approach group, while the tissue punch and direct approach groups had a bone volume percentage of 51 ± 4 and 54 ± 5 , respectively. Statistical testing revealed that no significant differences existed in bone volume percentages between the groups ($P = 0.4475$).

Histological analysis

Flapped approach

The bone tissue, as present around the implants installed using the flapped approach, appeared to be mature and was characterized by the presence of osteocytes and Haversian systems (Figure 2). High remodeling activity was observed only occasionally. Such areas of high remodeling activity were always seen at some distance of the implant interface. The bone was always in close contact with the implant surface and no intervening fibrous tissue layer was

1
2 present (Figure 2B). Remodeling lacunae were observed at the implant-bone interface. Only
3
4 one implant showed significant loss of crestal bone. The two most coronal screw-threads of
5
6 this implant became exposed. Further around three implants, crestal bone loss was seen till the
7
8 first coronal screw thread. For all the other implants, the bone made its first contact with the
9
10 implant surface above the first screw-thread.

11 Junctional epithelium was in contact with the implant surface (Figure 2A). Some
12
13 inflammatory response was always present in the connective tissue. This inflammatory
14
15 response was characterized by the presence of plasma cells.
16
17

18 19 20 Direct flapless approach

21 The bone as well as gingival (junctional epithelium and connective tissue) response to the
22
23 implants, as installed with the direct flapless approach, was very similar to the flapped
24
25 installed implants. The bone was again mature with very limited remodeling activity and in
26
27 tight contact with the implant surface (Figure 3). Four implants showed crestal bone loss till
28
29 the first coronal screw-thread, while the first implant-bone contact for the other implants was
30
31 always above the first screw-thread (Figure 3).
32

33 A junctional epithelium with some inflammatory response in the connective tissue was seen
34
35 around all implants (Figure 3).
36
37

38 39 Punch flapless approach

40 The peri-implant tissue response around the implants installed with the punch flapless
41
42 approach was not always consistent and differed from the implants installed with the two
43
44 other approaches. The three implants, which were found to be clinically mobile, showed a
45
46 very significant bone loss and the four most coronal screw-threads became exposed (Figure
47
48 5). The apical region of these implants (including the remaining 2 screw-threads) were
49
50

1 covered with bone, which was in intimate contact with the implant surface (Figure 4). Three
2 other implants showed crestal bone loss till the second coronal screw-thread. For the other
3
4 other implants, the first implant-bone contact was above the first screw-thread. The implants
5
6 four implants, the first implant-bone contact was above the first screw-thread. The implants
7
8 that showed crestal bone loss were also surrounded by a thick sub-epithelial connective tissue
9
10 layer, which was slightly inflamed. Around these implants a long junctional epithelium with a
11
12 deeper sulcus was seen compared with the implants, which showed no crestal bone loss.
13

16 **Histomorphometrical Measurements**

17
18 The results of the histomorphometrical measurements for the crestal bone level, bone-to-
19
20 implant contact%, connective tissue thickness and barrier epithelium length are listed in Table
21
22 2. Further analysis of the data revealed that the crestal bone level with the implant surface for
23
24 the punch method was at a significantly lower level than for the implants installed with the
25
26 two other procedures (Table 3).

27
28 Statistical testing of the bone-to-implant contact measurements indicated that the bone-to-
29
30 implant contact varied significantly between the three surgical approaches. The implants
31
32 inserted with the punch technique revealed a significantly lower amount of bone-implant
33
34 contact compared with the direct and flap technique, while no significant difference existed
35
36 between the flap vs. direct technique (Table 3).

37
38 While the soft tissue measurements also seem to imply that the punch technique results in a
39
40 thicker connective tissue layer as well as deeper gingival sulcus, this was not completely
41
42 confirmed by the statistical analysis. Statistical analysis of the connective tissue thickness data
43
44 showed that the barrier epithelium length varied significantly between the three groups (Table
45
46 3). A deeper sulcus was found around the dental implants installed with the punch vs. direct
47
48 as well as flap vs. punch approach.
49
50
51
52
53
54
55
56
57
58
59
60

Deleted: Testing

Deleted: Table 3),

Deleted: but

DISCUSSION

1
2
3
4
5
6 The aim of the current study was to investigate the consequences of different flapless (i.e.,
7 tissue punch and direct approach) as well as flapped surgical procedures on bone and gingiva
8 response. It has to be noticed that in our study design a tissue punch with a diameter of 5 mm
9 was used in the flapless surgical approach. The use of this punch created a gingival defect,
10 which was wider than the implant shoulder diameter (3.5 mm). This was done to avoid any
11 contact between the implant surface and gingival tissues during implant installation in order to
12 prevent the displacement of epithelial cells and/or fibroblasts into the bone bed. On the other
13 hand, it cannot be excluded that the mismatch in diameter has supported the enhanced
14 ingrowth of the gingival epithelium. Also, no oral hygiene regime was done after implant
15 installation. Although, an effect of this omission on the final study results cannot be
16 completely excluded, it has to be emphasized that such a hygiene procedure was excluded for
17 all surgical approaches. Therefore, we assume that the wound healing conditions were similar
18 for all dogs and did not interfere with the outcome.

Deleted: to

Deleted: excuded

19
20
21
22
23
24
25
26
27
28
29
30
31 At the end of the three month implantation period, three of the implants installed with the
32 punch method appeared to be clinically mobile, one of the implants inserted with the direct
33 approach was found to be lost, while no complications were observed for the flapped placed
34 implants. This makes the survival rate for the three surgical methods: 7/10 (punch), 9/10
35 (direct) and 10/10 (flapped) respectively. These data corroborate with a study as performed by
36 Rocci et al. (2003), who used flapless surgery to place implants in the maxilla of 46 patients.
37 On the other hand, in the studies of e.g. Becker et al. (2005), Erakat et al. (2008), de Bruyn et
38 al. (2009), Lindeboom & van Wijk (2010) and Nikzad & Azari (2010) survival rates in
39 between 98-100% were reported for a flapless procedure. A clear explanation for this
40 discrepancy is difficult to give, but it has to be realized that of course careful instruction about
41
42
43
44
45
46
47
48
49
50

1
2 the initial use and care for their implants can be given to patients in order to prevent
3
4 overloading during the initial healing stage, while in dogs overloading can only be prevented
5
6 by feeding them with soft dog chow.
7

8 The parameters as selected for the evaluation of the tissue response were: bone volume (by
9
10 micro-CT), crestal bone level (BL), bone-to-implant (BIC) contact%, connective tissue
11
12 thickness and barrier epithelium length (all measured by light microscopy). The light
13
14 microscopical assessment was done to obtain more information about the hard and soft tissue
15
16 response in the very close vicinity of the implant, while micro-CT was used to obtain more
17
18 information about bone density and quality of the implant site and its effect on the final
19
20 interfacial bone response. Both the BIC and marginal bone loss affect the overall success of a
21

22 dental implant. BIC is providing information about the bone integrative capacity of an implant
23
24 material and is considered as a major determinant of implant stability after initial healing,
25
26 since a higher BIC results in a higher resistance to shear strength (Buser 1999). The BIC%
27
28 measurement in the histomorphometrical procedure, as used in the current experimental
29
30 design, was done form the first implant-to-bone contact till the apex of the implant. In
31
32 addition, the bone level distance from the top of the implant till the first implant-to-bone
33
34 contact was determined, which represented the marginal bone loss. This was done, because
35
36 BIC% data are assuming an uniform distribution of bone contact over the complete length of
37
38 the implant surface, while this has not to be the case. Marginal bone level changes, as
39
40 characterized by first implant bone-contact will influence the BIC, but can also affect the soft
41
42 tissue level (Chang et al. 1999) as well as the overall success of the implant. As a
43
44 consequence, it has to be recommended that always several different histomorphometrical
45
46 parameters are assessed, which describe the interfacial tissue response as accurate as possible.
47
48 Subsequently, these parameters can be related to each other as was done in the current study
49
50 for BIC and marginal bone loss. Further, to allow the crestal bone level measurements, it was
51
52
53
54
55
56
57
58
59
60

Deleted: can result in lower

Deleted: T

1
2 attempted to install all implants with the marginal level of roughened surface leveled with the
3
4 alveolar bone crest. Despite the bone probing, it has to be emphasized that it cannot be
5
6 excluded that in the flapless group not a completely perfect fit was achieved. Still, it is
7
8 supposed that the obtained data are valid, as the final goal was not to observe significant
9
10 changes in crestal bone level, which is still feasible in the current approach. The degree of
11
12 bone trabecularity, also known as bone density or bone quality (and histomorphometrically
13
14 expressed as bone volume), represents the amount of bone matrix as present in a particular
15
16 area of the jaws. It is supposed that a relation exists between the amount of bone trabeculae
17
18 and their thickness, i.e. the bone volume, and the BIC as obtained at the end of the implant
19
20 healing period. More numerous and thicker trabeculae will result in a higher BIC (Ichikawa et
21
22 al. 2000, Trisi et al. 2002). An appropriate technique for determining bone volume around
23
24 implants is by making use of micro-CT (Schouten et al. 2009). The micro-CT measurements
25
26 in the current study showed that there was no significant difference in bone volume in an area
27
28 of 1.5 mm surrounding the dental implant for the three surgical techniques. This indicates that
29
30 there was no difference in the degree of bone trabecularity or bone quality between the
31
32 various implant sites and that all observed effects are due to the used surgical conditions.

33
34 The histological evaluation and histomorphometrical measurements indicated that the
35
36 punched surgical approach resulted in more crestal bone loss, less BIC and increased barrier
37
38 epithelium length. of the occurrence of statistical significant difference can be enhanced due
39
40 to the fact that the three “punched” implants, which appeared to be mobile after three months
41
42 of implantation, were included in the histomorphometrical analysis. Although clinical testing
43
44 before harvesting suggested the presence of mobility, these implants showed still a close bone
45
46 contact at their apical part with a BIC of resp. 10%, 20% and 27%. This limited apical BIC
47
48 also influenced the first bone contact and barrier epithelium length. If these implants had been
49
50 removed from the analysis, only a significant difference in BIC between the punch vs. direct

Deleted: s

1
2 approach would have been found. Nevertheless, it was decided to maintain these data, as the
3
4 implants were still present at the end of the experimental time and an outlier test did not
5
6 support the exclusion of these data.
7

8 Our histological and histomorphometrical evaluation corroborates with the studies of Becker
9
10 et al. (2006) as well as Lee et al. (2010). Becker et al. used the direct and flapped approach
11
12 and found no significant differences in BIC% and crestal bone level between these two
13
14 techniques. Lee et al. compared the effect of three different punch diameters on the bone and
15
16 gingival healing. The diameter of the installed implants was 4 mm and they observed that an
17
18 increased junctional epithelium length, probing dept as well as marginal bone level occurred
19
20 when the mucosa was punched with a 5 mm punch compared with the use of a 3 and 4 mm
21
22 punch. Lee suggested that for the 5 mm tissue punch a too wide gap was created between the
23
24 implant neck and mucosa, which delayed the healing of the peri-implant mucosa. This
25
26 explanation is based on the interrupted vascularization theory, which hypothesizes that
27
28 separation and detachment of the periosteum from the underlying bone surface causes
29
30 vascular damage and an acute inflammatory response. This will result in resorption of the
31
32 exposed bone surface (Brägger et al. 1988). The periosteum will be removed when the tissue
33
34 punch is used. In our study design, such an effect will even be enhanced due the larger
35
36 discrepancy in diameter between tissue punch and implant (5 mm vs. 3.3 mm). This can
37
38 explain why three of our “punched” implants became mobile, while mobility or implant loss
39
40 was not reported by Lee et al. [Recently, also de Sanctis et al \(2010\) reported about the](#)
41
42 [installation of implants in the mandible of dogs immediately following tooth extraction. They](#)
43
44 [observed a tendency towards a longer length of the epithelium and concluded that this](#)
45
46 [occurred independent of buccal/lingual bone resorption after extraction. It is conceivable that](#)
47
48 [their observation is due to similar factors as in the current study where a wider punch was](#)
49
50 [used before implant placement.](#)
51

1
2 The comparable histomorphometrical data between the direct flapless and flapped approach
3 suggests that the direct drilling of the implant bed through the mucosa does not force soft
4 tissue into the bone, as the BL, BIC% and implant stability were not found to be jeopardized.
5
6 Although, the soft tissue height was measured using a periodontal probe prior to the
7 installation of the implants of the direct flapless group to assure the position of the implant,
8 one of the implants as installed by the direct technique was still lost. This can be due to the
9 inevitable lack of visibility in relation to the anatomy of the alveolar ridge as well as a
10 reduced access for external irrigation during the drilling of the implant bed (Sclar 2007).
11
12 Perhaps, a solution as observed for the currently observed failures with the flapless
13 techniques, is the use of a recently suggested mini-incision approach (Jeong et al. 2009). This
14 technique allows a submerged positioning of the dental implant, which can support the bone
15 healing response.
16
17
18
19
20
21
22
23
24
25
26
27

28 CONCLUSIONS

29
30
31
32 The results, as obtained in the current dog study, indicate that a flapless surgical technique can
33 be used for the installation of oral implants. However, but caution should be exercised,
34 because in our study design the healing of both bone and gingival tissue around implants
35 installed with a punched flapless technique was hampered. Therefore, the use of a tissue
36 punch, which is much wider than the implant diameter, has to be avoided as it endangers the
37 outcome of the implantation procedure.
38
39
40
41
42
43
44
45
46
47
48
49
50
51
52
53
54
55
56
57
58
59
60

ACKNOWLEDGEMENT

1
2 The authors thank Natasja van Dijk for her help in the histological preparation of the
3
4 specimen as well as Vincent Cuijpers and Liao Hongbing for their assistance in the micro-CT
5
6 and histomorphometrical analysis. Further, we thank dr.Ewald Bronkhorst for his assistance
7
8 in the statistical analysis of the data. The implants were kindly provided by Straumann
9
10 company, Switzerland.
11
12
13
14
15
16
17
18
19
20
21
22
23
24
25
26
27
28
29
30
31
32
33
34
35
36
37
38
39
40
41
42
43
44
45
46
47
48
49
50
51
52
53
54
55
56
57
58
59
60

For Peer Review

REFERENCES

1
2
3
4
5
6
7
8 Azari, A. & Nikzad, S. (2008) Flapless implant surgery: Review of the literature and report of
9
10 2 cases with computer-guided surgical approach. *Journal of Oral and Maxillofacial Surgery*
11
12 **66**, 1015-1021.

13
14
15
16 Becker, W., Goldstein, M., Becker, B.E. & Sennerby L. (2005) Minimally invasive flapless
17
18 implant surgery: A prospective multicenter study. *Clinical Implant and Dentistry Related*
19
20 *Research* **7** (Suppl 1), 21-27.

21
22
23 Becker, W., Goldstein, M., Becker, B.E., Sennerby, L., Kois, D. & Hujoel, P. (2009)
24
25 Minimally invasive flapless implant placement: follow-up results from a multicenter study.
26
27 *Journal of Periodontology* **80**, 347-352.

28
29
30 Becker, W., Wikesjö, U.M., Sennerby, L., Qahash, M., Hujoel, P., Goldstein, M. &
31
32 Turkyilmaz, I. (2006) Histologic evaluation of implants following flapless and flapped
33
34 surgery: A study in canines. *Journal of Periodontology* **77**, 1717-1722.

35
36
37
38 Brägger, U., Pasqualli, L. & Kornman, K.S. (1988) Remodeling of interdental alveolar bone
39
40 after periodontal flap procedure assessed by means of computer-assisted densitometer image
41
42 analysis. *Journal of Clinical Periodontology* **15**, 558-564.

43
44
45
46 Blanco, J. Nuñez, V., Aracil, L., Muñoz, F. & Ramos, I. (2008) Ridge alterations following
47
48 immediate implant placement in the dog: flap *versus* flapless surgery. *Journal of Clinical*
49
50 *Periodontology* **7**, 640-648.

1
2
3
4 Buser D. (1999) Effect of various titanium surface configurations on osseointegration and
5
6 clinical implant stability. In: Lang NP, Karring T, Lindhe J (eds). Proceedings of the Third
7
8 European Workshop on Periodontology Implant Dentistry. Berlin: Quintessence, 88–101.
9

10
11
12 Cairo, F., Pagliaro, U. & Nieri, M. (2008) Soft tissue management at implant sites. *Journal of*
13
14 *Clinical Periodontology* **35 (8 suppl)**, 163–167.
15

16
17
18 Campelo, L.D. & Camara, J.R. (2002) Flapless implant surgery: A 10-year clinical
19
20 retrospective analysis. *International Journal of Oral and Maxillofacial Implants* **17**, 271-276.
21

22
23
24 Caulier, H., Naert, I., Kalk, W. & Jansen, J.A. (1997) The relationship of some histologic
25
26 parameters, radiographic evaluations, and periosteal measurements of oral implants: An
27
28 experimental animal study. *International Journal of Oral and Maxillofacial Implants* **12**, 380-
29
30 386.
31

32
33
34 Chang, M., Wennström, J.L., Odman, P. & Anderson B. (1999) Implant supported single-
35
36 tooth replacements compared to contralateral natural teeth, crown and soft tissue dimensions.
37
38 *Clinical Oral Implants Research* **10**, 185-194.
39

40
41
42 De Bruyn, H., Atashkadeh, M., Cosyn, J. & van de Velde, T. (2009) Clinical outcome and
43
44 bone preservation of single TiUnite™ implants installed with flapless or flap surgery. *Clinical*
45
46 *Implant Dentistry and Related Research* Epub ahead.
47
48
49
50

1
2 [De Sanctis, M., Vignoletti, F., Discepoli, N., Muñoz, F., Sanz, M. \(2010\) Immediate implants](#)
3 [at fresh extraction sockets: an experimental study in the beagle dog comparing four different](#)
4 [implant systems. Soft tissue findings. *Journal of Clinical Periodontology* **37**, 769-777.](#)
5
6
7

8
9
10 D'hease, J., van de Velde, T., Elaut, L. & de Bruyn H. (2009) A prospective study on the
11 accuracy of mucosally supported stereolithographic surgical guides in fully edentulous
12 maxillae. *Clinical Implant Dentistry and Related Research* Epub ahead.
13
14

15
16
17 Erakat, M., Chuang, S., Yoo, R., Weed, M. & Dodson, T. (2008) Immediate loading of
18 splinted locking-taper implants: 1 – year survival estimates and risk factors for failure.
19
20 *International Journal of Oral and Maxillofacial Implants* **23**, 105-110.
21
22

23
24
25 Fortin, T., Bosson, J.L., Isidori, M. & Blacher, E. Effect of flapless surgery on pain
26 experienced in implant placement using an image guided system. *International Journal of*
27 *Oral and Maxillofacial Surgery* **24**, 300-303.
28
29
30

31
32
33 Hahn J. (2000) Single-stage, immediate loading and flapless surgery. *Journal of Oral*
34 *Implantology* **26**, 193-198.
35
36
37

38
39 Ichikawa, T., Hanawa, T., Ukai, H. & Murakami, K. (2000) Three-dimensional bone response
40 to commercially pure titanium, hydroxyapatite, and calcium-ion-mixing titanium in rabbits.
41
42 *International Journal of Oral and Maxillofacial Implants* **15**, 231–238.
43
44
45
46
47
48
49
50
51
52

1
2 Jeong, S.M., Choi, B.H., Li, J., Kim, H.S., Ko, C.Y., Jung, J.H., Lee, H.J., Lee, S.H. &
3
4 Engelke, W. (2007) Flapless implant surgery: an experimental study. *Oral Surgery Oral*
5
6 *Medicine Oral Pathology Oral Radiology and Endodontology* **104**, 24-28.
7
8

9
10 Jeong, S.M., Choi, B.H., Xuan, F., Kim, H.R. (2009) Flapless implant surgery using a mini-
11
12 incision. *Clinical Implant Dentistry and Related Research* Epub ahead.
13
14

15
16 Kan, J.Y.K., Rungcharassaeng, K., Ojano, M. & Goodacre, C.J. (2000) Flapless anterior
17
18 implant surgery: A surgical and prosthodontic rationale. *Practical Periodontics and Aesthetic*
19
20 *Dentistry* **12**, 467-474.
21
22

23
24 Komiyama, A., Hulti, M., Näsström, K., Benchimol, D. & Klinge, B. (2009) Soft tissue
25
26 conditions and marginal bone changes around immediately loaded implants inserted in
27
28 edentate jaws following computer guided treatment planning and flapless surgery: A \geq 1-year
29
30 clinical follow-up study. *Clinical Implant Dentistry and Related Research*, Epub ahead.
31
32

33
34 Ledermann, P.D. (1977) Vollprothetische versorgung des atrophierten problem -unterkiefers
35
36 mit hilfe von CBS implantaten. *Quintessenz* **12**, 21-26.
37
38

39
40 Lee, D., Choi, B., Jeong, S., Xuan, F., Kim, H. & Mo, D. (2010) Effects of soft tissue punch
41
42 size on the healing of peri-implant tissue in flapless implant surgery. *Oral Surgery Oral*
43
44 *Medicine Oral Pathology Oral Radiology and Endodontology* **109**, 525-530.
45
46
47
48
49
50
51

1
2 Lindeboom, J.A. & van Wijk, A.J. (2010) A comparison of two implant techniques on
3 patient-based outcome measures: a report of flapless vs. conventional flapped implant
4 placement. *Clinical Oral Implants Research* **21**, 366-370.
5
6
7

8
9
10 Nikzad, A. & Azari, A. (2010) Custom-made radiographic template, computed tomography,
11 and computer-assisted flapless surgery for treatment planning in partial edentulous patients: a
12 prospective 12-month study. *Journal of Oral and Maxillofacial Surgery* Epub ahead.
13
14
15

16
17
18 Nobuto, T., Suwa, F., Kono, T., Taguchi, Y., Takahashi, T., Kanemura, N., Terada, S. & Imai,
19 H. (2005) Microvascular response in the periosteum following mucoperiosteal flap surgery in
20 dogs: Angiogenesis and bone resorption and formation. *Journal of Periodontology* **76**, 1346-
21 1353.
22
23
24
25

26
27
28 Ramfjord S.P. & Costich, E.R. (1968) Healing after exposure of periosteum on the alveolar
29 process. *Journal of Periodontology* **38**, 199-207.
30
31
32

33
34 Rocci, A., Martignoni, M. & Gottlow, J. (2003) Immediate loading in the maxilla using
35 flapless surgery, implants placed in predetermined positions, and prefabricated provisional
36 restorations: A retrospective 3-year clinical study. *Clinical Implant Dentistry and Related*
37 *Research* **5**(Suppl. 1), 29-36.
38
39
40
41

42
43
44 Schouten, C., Meijer, G., van den Beucken, J., Spauwen, P. & Jansen J. (2009) The
45 quantitative assessment of peri-implant bone responses using histomorphometry and micro-
46 computed tomography. *Biomaterials* **30**, 4539-4549.
47
48
49
50

1
2 Sclar, A.G. (2007) Guidelines for Flapless Surgery. *Journal of Oral and Maxillofacial*
3
4 *Surgery* **65** (Suppl 1), 20-32.
5

6
7
8 Stoppie, N., van der Waerden, J.P., Jansen, J.A., Duyck, J., Wevers, M. & Naert, I.E. (2005)
9
10 Validation of microfocus computed tomography in the evaluation of bone implant specimens.
11
12 *Clinical Implant Dentistry and Related Research* **7**, 87-94.
13

14
15
16 Trisi, P., Lazarra, R., Rao, W. & Rebaudi, A. (2002) Bone-implant contact and bone quality:
17
18 evaluation of expected and actual bone contact on machined and osseotite implant surfaces.
19
20 *International Journal of Periodontics and Restorative Dentistry* **22**, 535-545.
21

22
23
24 Wood, D.L., Hoag, P.M., Donnenfeld, O.W. & Rosenfeld, L.D. (1972) Alveolar crest
25
26 reduction following full and partial thickness flaps. *Journal of Periodontology* **42**, 141-144.
27
28
29
30
31
32
33
34
35
36
37
38
39
40
41
42
43
44
45
46
47
48
49
50
51
52
53
54
55
56
57
58
59
60

Table 1: Oral implant location for the different surgical approaches.

	Flap	Tissue punch	Direct approach
Dog #1	Left-distal	Left-mesial	Right
Dog #2	Right	Left-mesial	Left-distal
Dog #3	Right-distal	Left	Right-mesial
Dog #4	Left-mesial	Left-distal	Right
Dog #5	Left-mesial	Right	Left-distal
Dog #6	Right-mesial	Right-distal	Left
Dog #7	Left-distal	Right	Left-mesial
Dog #8	Right-mesial	Right-distal	Left
Dog #9	Left	Right-mesial	Right-distal
Dog #10	Left-distal	Right	Left-mesial

Table 2: Histomorphometrical measurements.

Surgical technique	1 st Bone Contact (in μm)	Bone-implant-contact (%)	Connective tissue thickness (in μm)	Barrier epithelium length (in μm)
Flap	3420 \pm 762	70 \pm 13	1498 \pm 559	1383 \pm 350
Punch	5358 \pm 1681	48 \pm 24	2047 \pm 1227	2278 \pm 1217
Direct	3843 \pm 433	73 \pm 13	1476 \pm 375	1107 \pm 318

Table 3: Statistical comparisons for the various implant installation techniques (P-value and 95% Confidence Interval).

Deleted: tial

Surgical technique	1 st Bone Contact		Bone-implant-contact		Connective tissue thickness		Barrier epithelium length	
	P-value	95% CI	P-value	95% CI	P-value	95% CI	P-value	95% CI
Flap vs. Punch	0.003	[-3038...-836]	0.002	[10...34]	0.258	[-1579...481]	0.037	[-1723...-68]
Flap vs. Direct	0.114	[-132...1006]	0.775	[-11...14]	0.86	[-577...493]	0.128	[-633...96]
Punch vs. Direct	0.045	[39...2641]	0.008	[-36...-7]	0.361	[-464...1134]	0.032	[128...2167]

Figure 1: Schematic drawing of the histomorphometric parameters.

For Peer Review

Figure 2

Light micrograph showing the bone as well as gingival tissues around an implant installed using the flapped approach. No crestal bone resorption is present and the bone is in direct contact with the implant surface. (A: original magnification obj. 5x, bar = 1000µm; B: original magnification obj. 10x, bar = 100µm). R = remodelling lacuna, JE = junctional epithelium

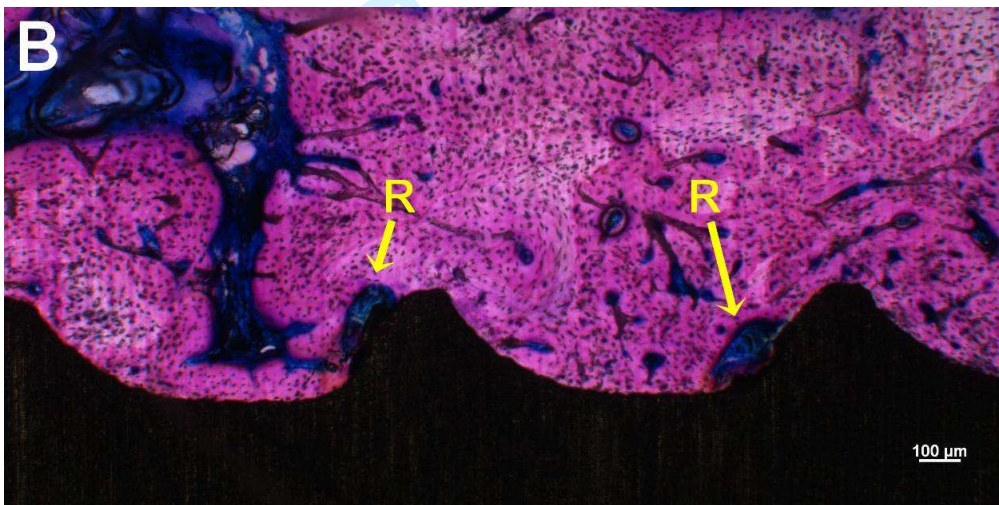
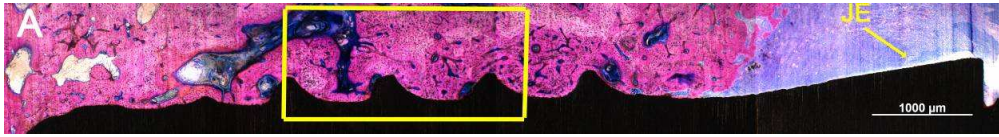
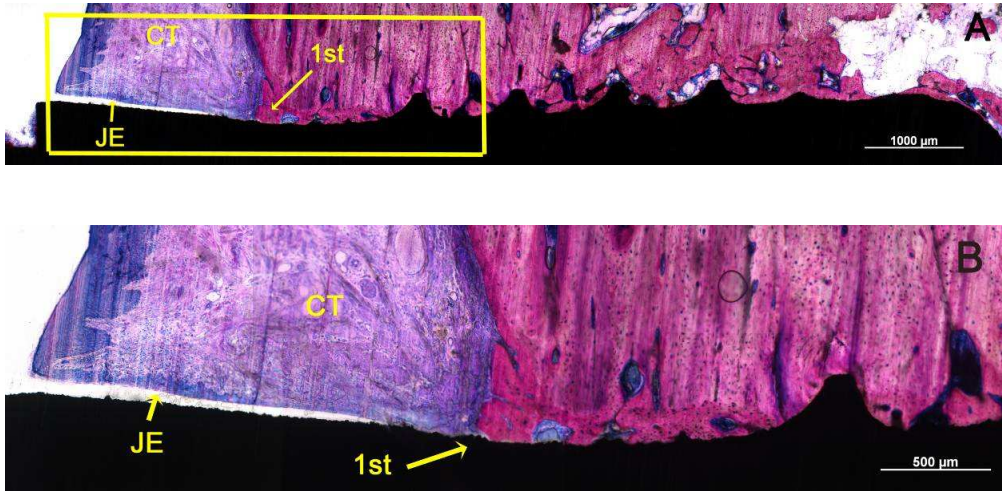


Figure 3

Light micrograph of an implant installed using a direct approach. The bone is in close contact with the implant surface. The first implant-bone contact (1st) occurred coronal of the first screw thread. The junctional epithelium (JE) contacts the implant surface and the subepithelial connective tissue (CT) layer is slightly inflamed (B) (A: original magnification obj. 5x, bar = 1000µm; B: original magnification obj. 10x, bar = 500µm).

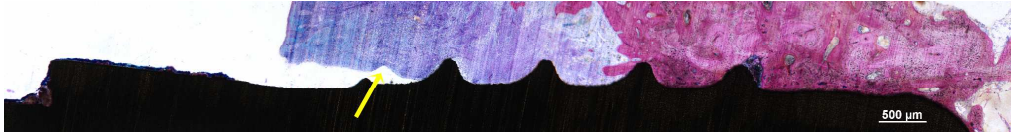


1
2
3
4
5
6
7
8
9
10
11
12
13
14
15
16
17
18
19
20
21
22
23
24
25
26
27
28
29
30
31
32
33
34
35
36
37
38
39
40
41
42
43
44
45
46
47
48
49
50
51
52
53
54
55
56
57
58
59
60

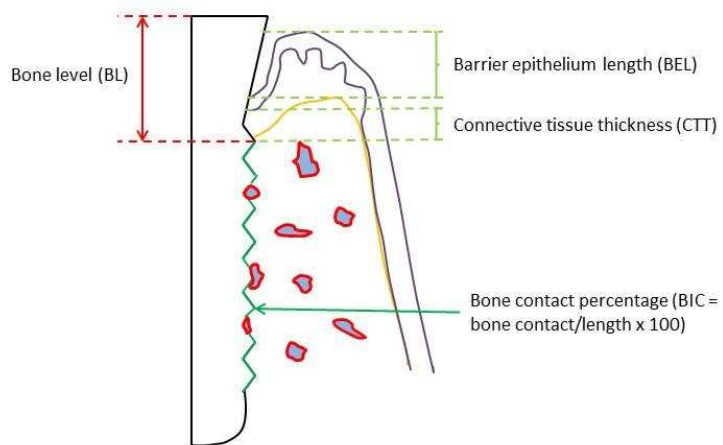
Figure 4

Deleted: ¶
-----Page Break-----

Histological section of an implant installed with the punch approach. Significant crestal bone resorption did occur resulting in exposure of the first three coronal screw-threads. The gingival tissue was loosely adhering to the implant surface and detachment (arrow) occurred during retrieval of the implant (original magnification obj. 5x, bar = 500µm).

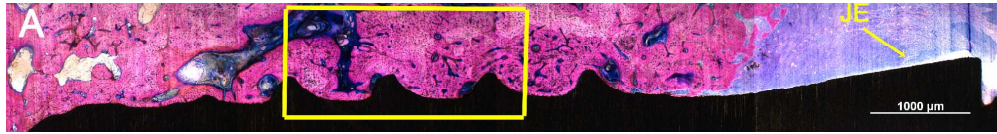


For Peer Review



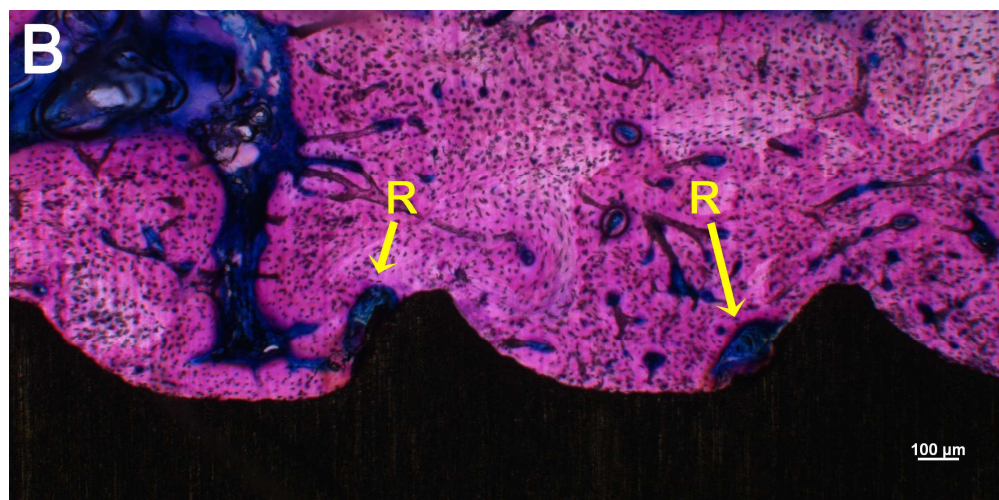
Schematic drawing of the histomorphometric parameters
254x190mm (96 x 96 DPI)

Review

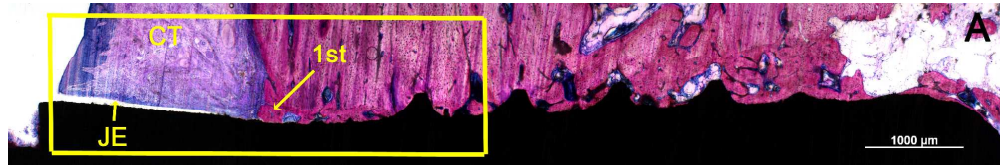


Light micrograph showing the bone as well as gingival tissues around an implant installed using the flapped approach. No crestal bone resorption is present and the bone is in direct contact with the implant surface. (A: original magnification obj. 5x, bar = 1000μm; B: original magnification obj. 10x, bar = 100μm). R = remodelling lacuna, JE = junctional epithelium
686x88mm (150 x 150 DPI)

For Peer Review

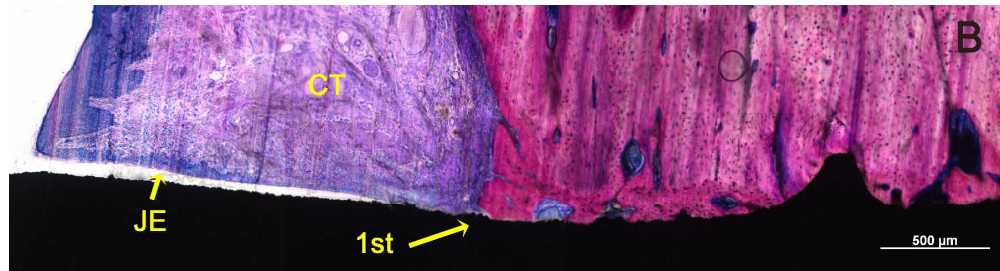


Light micrograph showing the bone as well as gingival tissues around an implant installed using the flapped approach. No crestal bone resorption is present and the bone is in direct contact with the implant surface. (A: original magnification obj. 5x, bar = 1000 μ m; B: original magnification obj. 10x, bar = 100 μ m). R = remodelling lacuna, JE = junctional epithelium
386x191mm (150 x 150 DPI)



Light micrograph of an implant installed using a direct approach. The bone is in close contact with the implant surface (A and C). The first implant-bone contact (1st) occurred coronal of the first screw thread (A). The junctional epithelium (JE) contacts the implant surface and the subepithelial connective tissue (CT) layer is slightly inflamed (B) (A: original magnification obj. 5x, bar = 1000 μ m; B: original magnification obj. 10x, bar = 500 μ m; C: original magnification obj. 5x, bar = 200 μ m).

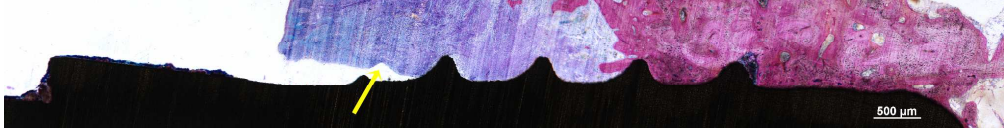
681x109mm (150 x 150 DPI)



Light micrograph of an implant installed using a direct approach. The bone is in close contact with the implant surface (A and C). The first implant-bone contact (1st) occurred coronal of the first screw thread (A). The junctional epithelium (JE) contacts the implant surface and the subepithelial connective tissue (CT) layer is slightly inflamed (B) (A: original magnification obj. 5x, bar = 1000 μ m; B: original magnification obj. 10x, bar = 500 μ m; C: original magnification obj. 5x, bar = 200 μ m).

612x162mm (150 x 150 DPI)

1
2
3
4
5
6
7
8
9
10
11
12
13
14
15
16
17
18
19
20
21
22
23
24
25
26
27
28
29
30
31
32
33
34
35
36
37
38
39
40
41
42
43
44
45
46
47
48
49
50
51
52
53
54
55
56
57
58
59
60



Histological section of an implant installed with the punch approach. Significant crestal bone resorption did occur resulting in exposure of the first three coronal screw-threads. The gingival tissue was loosely adhering to the implant surface and detachment (arrow) occurred during retrieval of the implant (original magnification obj. 5x, bar = 500μm).
691x89mm (150 x 150 DPI)

For Peer Review