



HAL
open science

Pancreatic Splenosis demonstrated by Contrast Enhanced Ultrasonography

Patrick James Rogers, M.P. Williams, Rashika Fernando, Simon Freeman

► **To cite this version:**

Patrick James Rogers, M.P. Williams, Rashika Fernando, Simon Freeman. Pancreatic Splenosis demonstrated by Contrast Enhanced Ultrasonography. *Journal of Clinical Ultrasound*, 2011, 39 (6), pp.348. 10.1002/jcu.20823 . hal-00638142

HAL Id: hal-00638142

<https://hal.science/hal-00638142>

Submitted on 4 Nov 2011

HAL is a multi-disciplinary open access archive for the deposit and dissemination of scientific research documents, whether they are published or not. The documents may come from teaching and research institutions in France or abroad, or from public or private research centers.

L'archive ouverte pluridisciplinaire **HAL**, est destinée au dépôt et à la diffusion de documents scientifiques de niveau recherche, publiés ou non, émanant des établissements d'enseignement et de recherche français ou étrangers, des laboratoires publics ou privés.



**Pancreatic Splenosis demonstrated by Contrast Enhanced
Ultrasonography**

Journal:	<i>Journal of Clinical Ultrasound</i>
Manuscript ID:	JCU-10-256.R1
Wiley - Manuscript type:	Case Report
Keywords:	Splenosis, contrast agents, Contrast enhanced, Ultrasound, pancreas

SCHOLARONE™
Manuscripts

Review

Pancreatic Splenosis demonstrated by Contrast Enhanced Ultrasonography

1
2
3
4
5
6
7
8
9
10
11
12
13
14
15
16
17
18
19
20
21
22
23
24
25
26
27
28
29
30
31
32
33
34
35
36
37
38
39
40
41
42
43
44
45
46
47
48
49
50
51
52
53
54
55
56
57
58
59
60

Title: Pancreatic Splenosis demonstrated by Contrast Enhanced Ultrasonography

For Peer Review

Abstract

Pancreatic splenosis is a very rare condition whose features on contrast-enhanced ultrasound (CEUS) have not, to our knowledge, been previously reported. We present the imaging findings in a case of pancreatic splenosis where a confident diagnosis was achieved with the use of CEUS and confirmed by a labeled heat denatured red cell scan. Accumulation of ultrasound contrast microbubbles in splenic tissue can be readily visualized on late-phase CEUS and this technique has already been used to confirm the nature of intrapancreatic accessory spleens. This case shows that it can also confirm the diagnosis of splenosis.

Case Report

A 64 year old male was referred to an urologist with an elevated serum prostatic specific antigen (PSA) level of 5.5 ng/mL as well as lower urinary tract symptoms. The patient had undergone a splenectomy for trauma after being involved in a road traffic accident as a pedestrian 47 years previously. There was no other significant past medical history. Transrectal ultrasound guided biopsy of the prostate diagnosed a Gleason grade 3+4 carcinoma of the prostate. MRI staging was performed (Phillips Intera 1.5T MRI) which included a T2 weighted axial sequence of the abdomen. This sequence showed a 4 cm mass arising from the lower pole of the left kidney with features consistent with a renal cell carcinoma and additionally a 5cm mass arising from the tail of the pancreas which was thought likely to represent a pancreatic tumour (Figure 1). Two nodules, were seen in the splenic bed and assumed to represent splenunculi. Further evaluation by contrast medium enhanced CT (GE High definition Lightspeed VCT scanner before and after intravenous contrast medium administration: 90mls Omipaque 300¹) confirmed a 5cm diameter mass in the pancreatic tail showing a little peripheral calcification. This mass was noted to show

Pancreatic Splenosis demonstrated by Contrast Enhanced Ultrasonography

1
2 non-uniform enhancement in the arterial phase and uniform enhancement in the portal
3
4 venous phase with enhancement characteristics identical to the two adjacent nodules in
5
6 the splenic bed (Figures 2 A-B-C). A CEUS study was undertaken (Toshiba Aplio XG
7
8 ultrasound system, 3.5 MHz abdominal transducer) using a contrast specific preset, with a
9
10 low mechanical index of 0.03, following an injection of 2.4mls of SonoVue ultrasound
11
12 contrast medium (Bracco Imaging). The lesion in the pancreatic tail was only visible via a
13
14 left flank approach (Figure 3). The pancreatic tail mass demonstrated inhomogeneous
15
16 enhancement in the early phase followed by uniform intense enhancement in the late
17
18 phase, with the mass remaining strongly enhanced at 7 minutes post injection, well
19
20 beyond blood-pool microbubble clearance (Figure 4). These features are consistent with
21
22 splenic tissue. A subsequent heat denatured red blood cell study and SPECT CT study
23
24 showed an intense uptake of red cells within the pancreatic lesion and also within the
25
26 accessory spleens (Figure 5).
27
28
29
30
31
32
33
34

35 Discussion

36
37 Splenosis is an acquired condition defined as autotransplantation of viable splenic tissue
38
39 throughout different anatomic compartments of the body. It occurs after traumatic or
40
41 iatrogenic rupture of the spleen² and can occur at many sites in the abdomen and
42
43 occasionally in the thorax³. These splenic masses are usually asymptomatic but may be
44
45 seen on a variety of imaging studies and cause diagnostic difficulty, particularly if the
46
47 history of splenic injury has not been appreciated. Pelvic splenosis in particular can be
48
49 misdiagnosed as pathological masses or tumour recurrence on ultrasound studies³ and
50
51 the true nature of the abnormality is frequently not established until surgery has been
52
53 undertaken.
54
55
56

57
58 Pancreatic splenosis is very uncommon; a report of a single case in the literature made the
59
60 diagnosis only after laparoscopic resection⁵. Intrapancreatic accessory spleens have been

Pancreatic Splenosis demonstrated by Contrast Enhanced Ultrasonography 4

more frequently reported but are usually less than 2cm in size⁶ and CEUS has been used to identify this condition⁷. Awareness of both of these conditions is important in the differential diagnosis of pancreatic tail lesions as other diagnostic possibilities (adenocarcinoma, islet cell tumour, metastasis)^{7,8,9,10} will frequently require surgical intervention which is unnecessary in the case of pancreatic splenosis or accessory spleen. Normal splenic tissue accumulates ultrasound contrast microbubbles similar to, but more pronounced than, their accumulation in normal liver parenchyma. The site of microbubble accumulation is thought to be within the splenic sinusoids or reticular endothelial system¹¹. This property can be used to differentiate splenic tissue from other soft-tissue masses which will show washout of microbubbles in the late phase. In this respect CEUS acts much like a heat denatured red cell scan but is a much simpler test to perform without any associated radiation burden.

Recent literature has highlighted the use of CEUS in the investigation of accessory spleens⁷, however there are distinct differences in accessory spleens compared to splenosis. An accessory spleen has normal splenic histology with its blood supply usually arising from a branch of the splenic artery, this can frequently be visualized with Doppler or contrast enhanced ultrasound. Blood supply in splenosis, in contrast, is derived from the surrounding tissues and vessels, without any association with the splenic artery^{3,2}. A further difference is that the tissue in splenosis usually reveals distorted architecture with no hilum, a poorly formed capsule and the tissue may be of any shape or size, whereas accessory spleens have a more uniform hilar architecture, and are generally rounded or oval.

Conclusion

Pancreatic Splenosis demonstrated by Contrast Enhanced Ultrasonography

In conclusion this is a rare case of pancreatic splenosis, diagnosed by CEUS, without the need for surgical intervention. This condition should be suspected when asymptomatic masses are identified in patients with a history of splenic injury or surgery. We suggest that CEUS may be able to replace nuclear medicine imaging in the diagnosis of this condition, which is in keeping with other recent literature¹².

References:

1. GE Healthcare, Inc., 101 Carnegie Center, Princeton, NJ 08540-9998.
2. Fremont RD, Rice TW. Splenosis: A Review; *South Med J.* 2007 Jun;100(6):589-93.
3. Thourani VH, Sharma J, Duarte IG, et al. Intrathoracic Splenosis; *Ann Thorac Surg.* 2005 Nov;80(5):1934-6.
4. Tasci Y, Kayikcioglu F, Cavusoglu D, et al. Splenosis mimicking pelvic mass. *Obstet Gynecol.*; 2005 Nov;106(5 Pt 2):1167-9.
5. Fiamingo P, Veroux M, Da Rold A, et al. A rare diagnosis for a pancreatic mass: splenosis. *J Gastrointest Surg.*; 2004;8:915–916.
6. Mortelé, KJ., Mortelé B, Silverman SG. CT Features of the Accessory Spleen; *Am J Roentgenol.* 2004 Dec;183(6):1653-7.
7. Kim SH, Lee JM, Lee JY, et al. Contrast-Enhanced Sonography of Intrapancreatic Accessory Spleen in Six Patients; *Am. J. Roentgenol.*, 2007 Feb;188(2):422-8.
8. Fleming CR, Dickson ER, Harrison EG Jr. Splenosis auto-transplantation of splenic tissue. *Am J Med*; 1976;61:414-419.
9. Ardengh JC, de Paulo GA, Ferrari AP. EUS-guided FNA in the diagnosis of pancreatic neuroendocrine tumors before surgery; *Gastrointest Endosc.* 2004 Sep;60(3):378-84.
10. Sica GT, Reed MF. Case 27: Intrapancreatic accessory spleen; *Radiology.* 2000 ;217(1):134-7.
11. Stewart VR, Sidhu PS; New directions in ultrasound: microbubble contrast; *Br J Radiol.* 2006;79(939):188-94.
12. Bertolotto M, Quaia E, Zappetti R, et al . Differential diagnosis between splenic nodules and peritoneal metastases with contrast-enhanced ultrasound based on signal-intensity characteristics during the late phase, *Radiol Med.* 2009 Feb;114(1):42-51.

Pancreatic Splenosis demonstrated by Contrast Enhanced Ultrasonography

6

1
2
3
4
5
6
7
8 Figures:

9
10 Figure 1

11 MRI

12
13
14 Axial T2 weighted spin echo sequence of the upper abdomen demonstrating a mass (arrow) in the
15
16 pancreatic tail with signal intensity similar to the renal parenchyma.
17

18
19
20 Figure 2A

21 CT without contrast.

22
23 Axial non-contrast enhanced CT section through the upper abdomen demonstrating flecks of calcification
24
25 (arrow) in the periphery of the mass.
26
27

28
29
30 Figure 2B

31 CT with arterial phase contrast medium enhancement

32
33 This shows heterogenous "stripes" through the lesion, typical of splenic parenchymal arterial enhancement
34
35 (arrow)
36
37

38
39
40 Figure 2C

41 CT with portal venous phase contrast medium enhancement.

42
43 Portal-venous phase contrast showing uniform enhancement through the lesion in the pancreas (arrow).
44
45
46

47
48 Figure 3

49 Ultrasonography

50
51 This image shows a hypoechoic 2.5cm lesion (arrow) within the pancreas.
52
53
54

55
56 Figure 4

57 Ultrasonography with contrast.
58
59
60

6

Pancreatic Splenosis demonstrated by Contrast Enhanced Ultrasonography

Split screen ultrasound image: contrast specific preset shown to the readers right. The pancreatic tail mass remains strongly enhanced at 7:09 minutes post injection (arrow), well beyond blood-pool microbubble clearance.

Figure 5

Heat denatured red blood cell study and SPECT CT.

There is intense uptake of red blood cells within the partially calcified largest lesion closely related to the tail of the pancreas. Arrow shows splenosis nodule.

For Peer Review

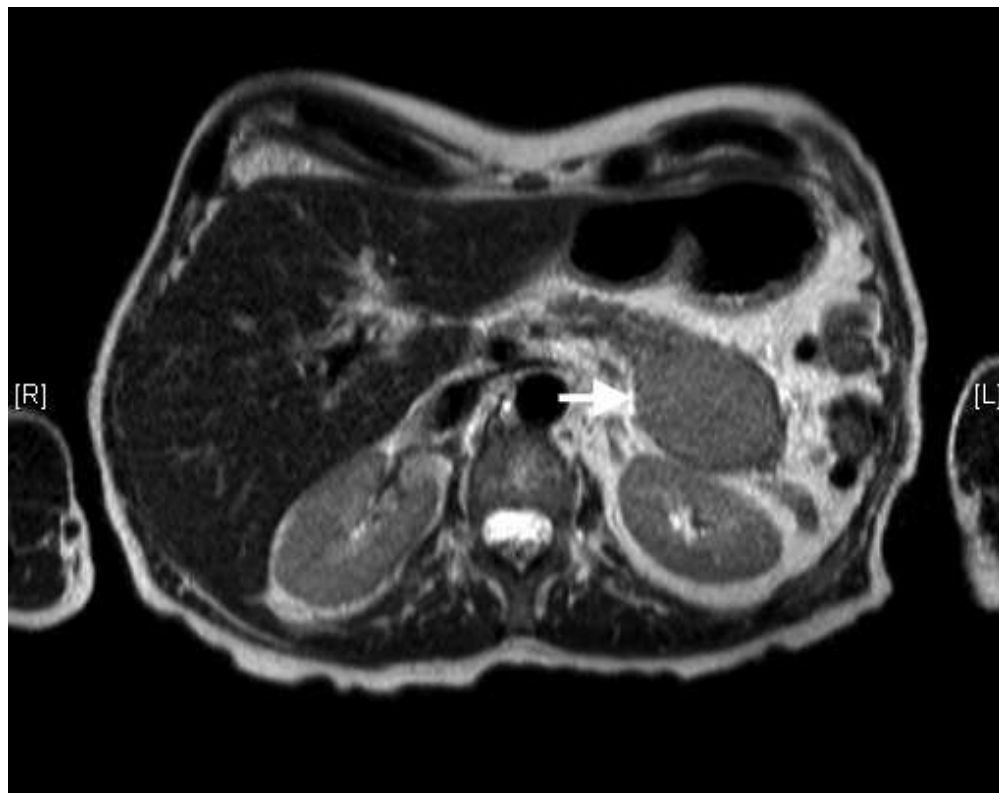


Figure 1
MRI
Axial T2 weighted spin echo sequence of the upper abdomen demonstrating a mass (arrow) in the pancreatic tail with signal intensity similar to the renal parenchyma.

95x75mm (136 x 136 DPI)

1
2
3
4
5
6
7
8
9
10
11
12
13
14
15
16
17
18
19
20
21
22
23
24
25
26
27
28
29
30
31
32
33
34
35
36
37
38
39
40
41
42
43
44
45
46
47
48
49
50
51
52
53
54
55
56
57
58
59
60

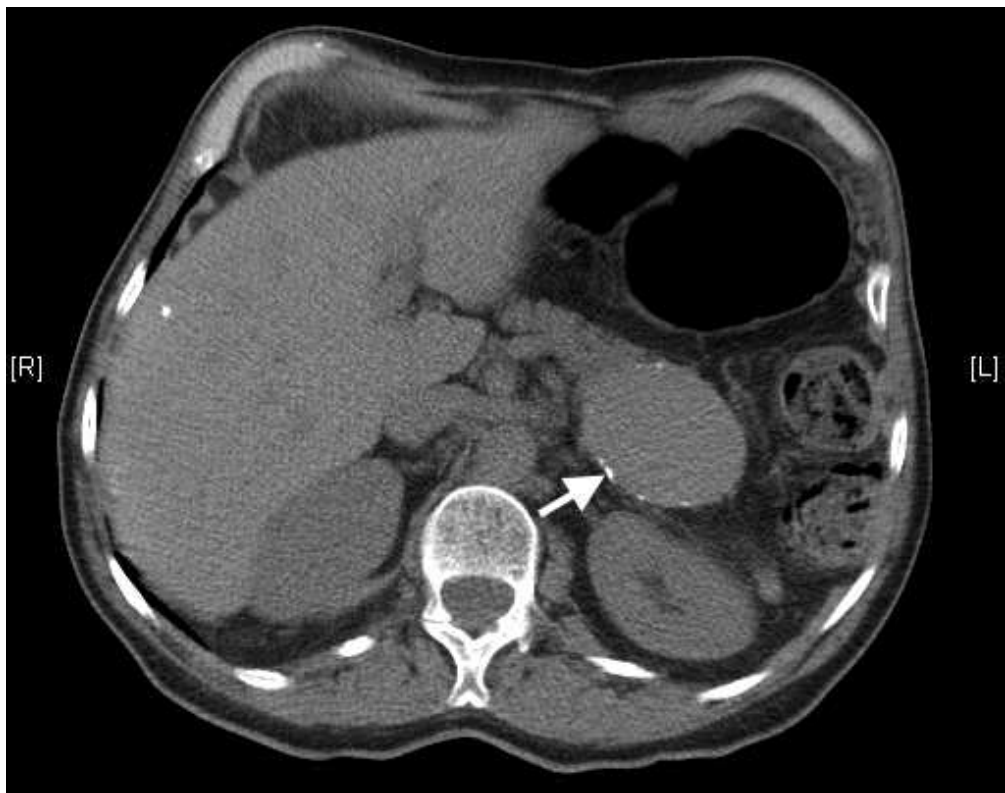

Figure 2A
CT without contrast.
Axial non-contrast enhanced CT section through the upper abdomen demonstrating flecks of calcification (arrow) in the periphery of the mass.

95x75mm (136 x 136 DPI)

1
2
3
4
5
6
7
8
9
10
11
12
13
14
15
16
17
18
19
20
21
22
23
24
25
26
27
28
29
30
31
32
33
34
35
36
37
38
39
40
41
42
43
44
45
46
47
48
49
50
51
52
53
54
55
56
57
58
59
60

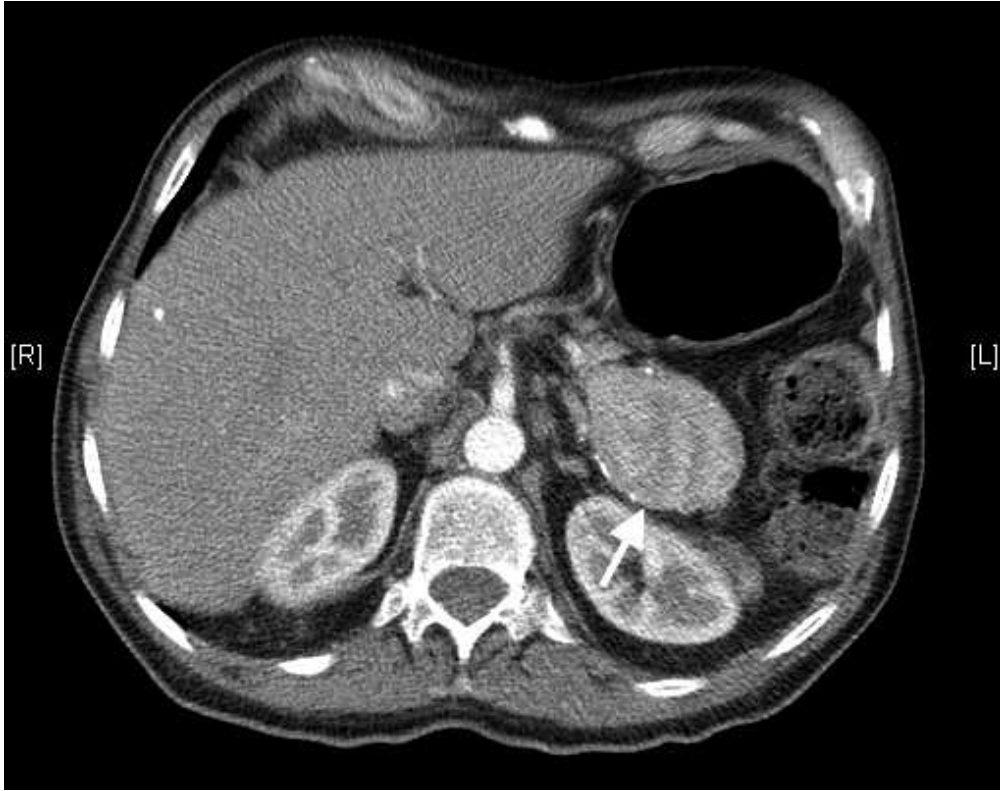

Figure 2B
CT with arterial phase contrast medium enhancement
This shows heterogenous "stripes" through the lesion, typical of splenic parenchymal arterial enhancement (arrow)

95x75mm (136 x 136 DPI)

ew

1
2
3
4
5
6
7
8
9
10
11
12
13
14
15
16
17
18
19
20
21
22
23
24
25
26
27
28
29
30
31
32
33
34
35
36
37
38
39
40
41
42
43
44
45
46
47
48
49
50
51
52
53
54
55
56
57
58
59
60

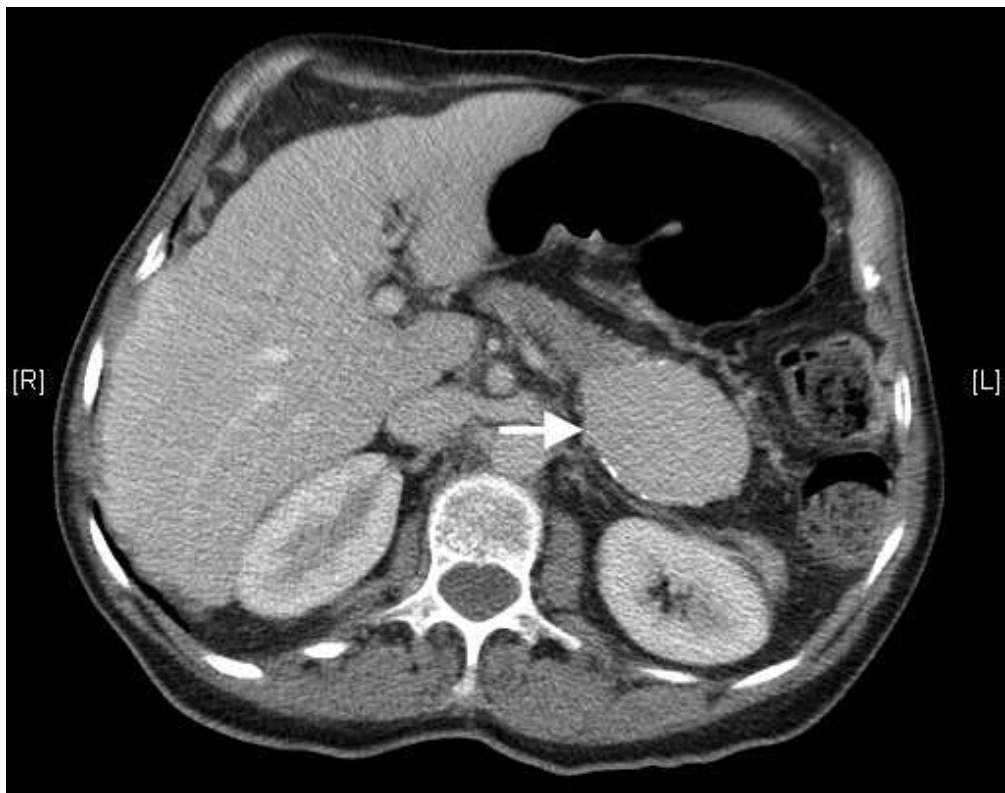

Figure 2C
CT with portal venous phase contrast medium enhancement.
Portal-venous phase contrast showing uniform enhancement through the lesion in the pancreas
(arrow).

95x75mm (136 x 136 DPI)

ew

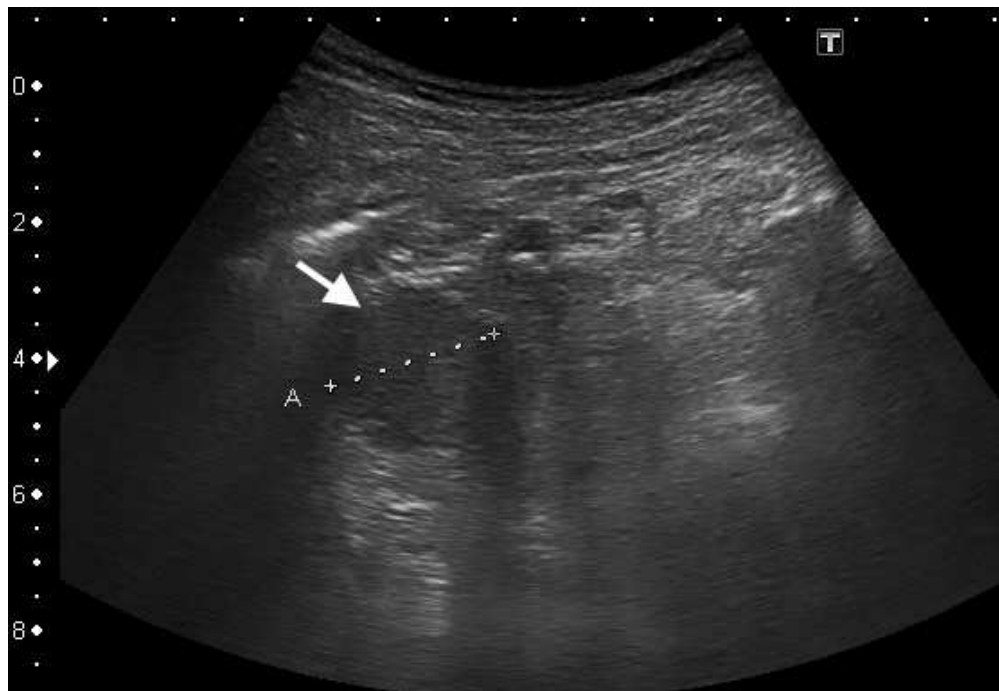

Figure 3
Ultrasonography
This image shows a hypoechoic 2.5cm lesion (arrow) within the pancreas.

94x65mm (149 x 149 DPI)

Review

1
2
3
4
5
6
7
8
9
10
11
12
13
14
15
16
17
18
19
20
21
22
23
24
25
26
27
28
29
30
31
32
33
34
35
36
37
38
39
40
41
42
43
44
45
46
47
48
49
50
51
52
53
54
55
56
57
58
59
60

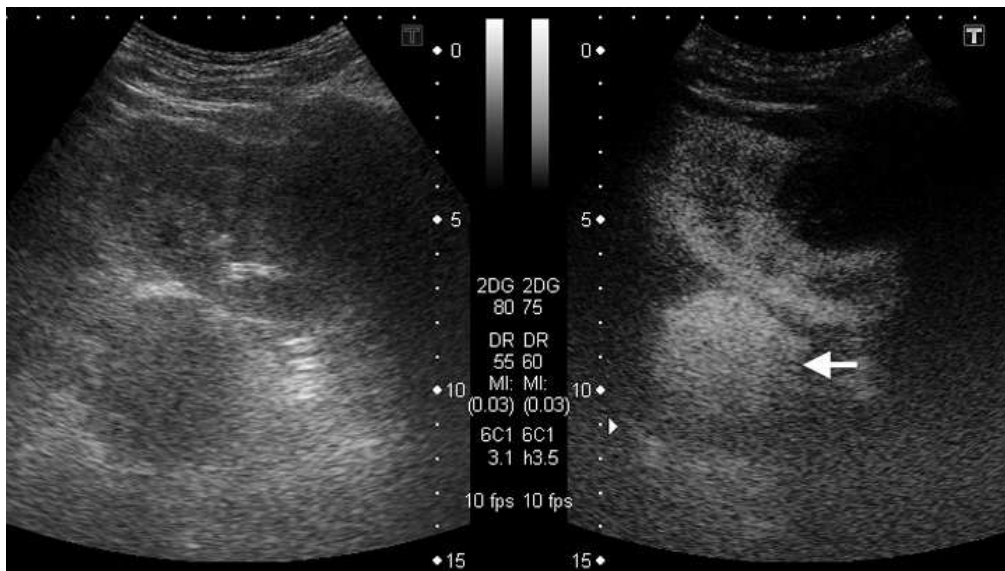


Figure 4
 Ultrasonography with contrast.
 Split screen ultrasound image: contrast specific preset shown to the readers right. The pancreatic tail mass remains strongly enhanced at 7:09 minutes post injection (arrow), well beyond blood-pool microbubble clearance.

95x53mm (191 x 191 DPI)

Review

1
2
3
4
5
6
7
8
9
10
11
12
13
14
15
16
17
18
19
20
21
22
23
24
25
26
27
28
29
30
31
32
33
34
35
36
37
38
39
40
41
42
43
44
45
46
47
48
49
50
51
52
53
54
55
56
57
58
59
60

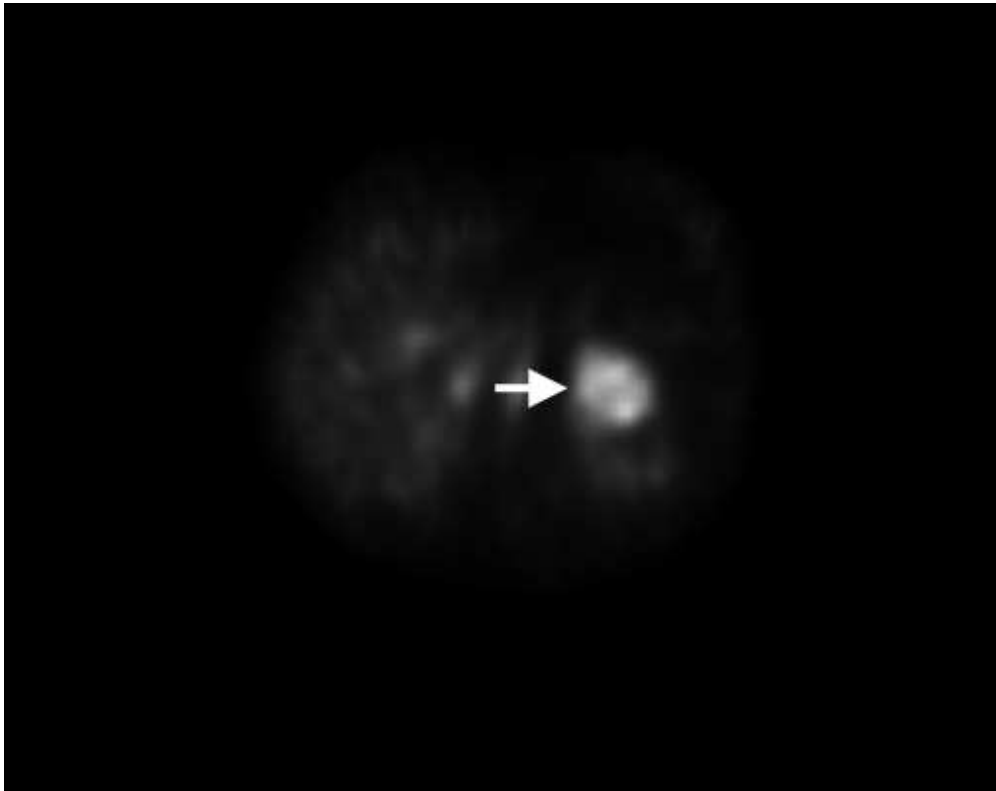


Figure 5
Heat denatured red blood cell study and SPECT CT.
There is intense uptake of red blood cells within the partially calcified largest lesion closely related to the tail of the pancreas. Arrow shows splenosis nodule.

95x75mm (136 x 136 DPI)

Pancreatic Splenosis demonstrated by Contrast Enhanced Ultrasonography

1
2
3
4
5
6
7
8
9
10
11
12
13
14
15
16
17
18
19
20
21
22
23
24
25
26
27
28
29
30
31
32
33
34
35
36
37
38
39
40
41
42
43
44
45
46
47
48
49
50
51
52
53
54
55
56
57
58
59
60

Title: Pancreatic Splenosis demonstrated by Contrast Enhanced Ultrasonography

For Peer Review

Introduction

Abstract

Pancreatic splenosis is a very rare condition whose features on contrast-enhanced ultrasound (CEUS) have not, to our knowledge, been previously reported. We present the imaging findings in a case of pancreatic splenosis where a confident diagnosis was achieved with the use of CEUS and confirmed by a labeled heat denatured red cell scan. Accumulation of ultrasound contrast microbubbles in splenic tissue can be readily visualized on late-phase CEUS and this technique has already been used to confirm the nature of intrapancreatic accessory spleens. This case shows that it can also confirm the diagnosis of splenosis.

Case Report

A 64 year old male was referred to an urologist with an elevated serum [prostatic specific antigen \(PSA\) level](#) of 5.5 ng/mL as well as lower urinary tract symptoms. The patient had undergone a splenectomy for trauma after being involved in a road traffic accident as a pedestrian 47 years previously. There was no other significant past medical history. Transrectal ultrasound guided biopsy of the prostate diagnosed a Gleason grade 3+4 carcinoma of the prostate. MRI staging was performed (Phillips Intera 1.5T MRI) which included a T2 weighted axial sequence of the abdomen. This sequence showed a 4 cm mass arising from the lower pole of the left kidney with features consistent with a renal cell carcinoma and additionally a 5cm mass arising from the tail of the pancreas which was thought likely to represent a pancreatic tumour (Figure 1). Two nodules, were seen in the splenic bed and assumed to represent splenunculi. Further evaluation by contrast medium enhanced CT (GE High definition [CT Lightspeed VCT scanner with before and after intravenous contrast medium administration](#): 90mls Omipaque 300¹) confirmed a 5cm

Pancreatic Splenosis demonstrated by Contrast Enhanced Ultrasonography

1
2
3
4 diameter mass in the pancreatic tail showing a little peripheral calcification. This mass was
5
6 noted to show non-uniform enhancement in the arterial phase and uniform enhancement
7
8 in the portal venous phase with enhancement characteristics identical to the two adjacent
9
10 nodules in the splenic bed (Figures 2 A-B-C). A CEUS study was undertaken (Toshiba
11
12 Aplio XG ultrasound system, 3.5 MHz abdominal transducer) using a ~~low acoustic~~
13
14 ~~pressure~~-contrast specific preset, with a low mechanical index of 0.03, following an
15
16 injection of 2.4mls of SonoVue ultrasound contrast medium (Bracco Imaging). The lesion
17
18 in the pancreatic tail was only visible via a left flank approach (Figure 3). The pancreatic
19
20 tail mass demonstrated inhomogeneous enhancement in the early phase followed by
21
22 uniform intense enhancement in the late phase, the mass remaining strongly enhanced at
23
24 7 minutes post injection, well beyond blood-pool microbubble clearance (Figure 4). These
25
26 features are consistent with splenic tissue. A subsequent heat denatured red
27
28 blood cell study and SPECT CT study showed an intense uptake of red cells within the
29
30 pancreatic lesion and also within the accessory spleens (Figure 5).
31
32
33
34
35
36
37
38

39 Discussion

40
41 Splenosis is an acquired condition defined as autotransplantation of viable splenic tissue
42
43 throughout different anatomic compartments of the body. It occurs after traumatic or
44
45 iatrogenic rupture of the spleen² and can occur at many sites in the abdomen and
46
47 occasionally in the thorax³. These splenic masses are usually asymptomatic but may be
48
49 seen on a variety of imaging studies and cause diagnostic difficulty, particularly if the
50
51 history of splenic injury has not been appreciated. Pelvic splenosis in particular can be
52
53 misdiagnosed as pathological masses or tumour recurrence on ultrasound studies³ and
54
55 the true nature of the abnormality is frequently not established until surgery has been
56
57 undertaken.
58
59
60

Pancreatic Splenosis demonstrated by Contrast Enhanced Ultrasonography

4

1
2
3
4
5
6
7
8
9
10
11
12
13
14
15
16
17
18
19
20
21
22
23
24
25
26
27
28
29
30
31
32
33
34
35
36
37
38
39
40
41
42
43
44
45
46
47
48
49
50
51
52
53
54
55
56
57
58
59
60

Pancreatic splenosis is very uncommon; a report of a single case in the literature made the diagnosis only after laparoscopic resection⁵. Intrapancreatic accessory spleens have been more frequently reported but are usually less than 2cm in size⁶ and CEUS has been used to identify this condition⁷. Awareness of both of these conditions is important in the differential diagnosis of pancreatic tail lesions as other diagnostic possibilities (adenocarcinoma, islet cell tumour, metastasis)^{7,8,9,10} will frequently require surgical intervention which is unnecessary in the case of pancreatic splenosis or accessory spleen. Normal splenic tissue accumulates ultrasound contrast microbubbles similar to, but more pronounced than, their accumulation in normal liver parenchyma. The site of microbubble accumulation is thought to be within the splenic sinusoids or reticular endothelial system¹¹. This property can be used to differentiate splenic tissue from other soft-tissue masses which will show washout of microbubbles in the late phase. In this respect CEUS acts much like a heat denatured red cell scan but is a much simpler test to perform without any associated radiation burden.

Recent literature has highlighted the use of CEUS in the investigation of accessory spleens⁷, however there are distinct differences in accessory spleens compared to splenosis. An accessory spleen has normal splenic histology with its blood supply usually arising from a branch of the splenic artery, this can frequently be visualized with Doppler or contrast enhanced ultrasound. Blood supply in splenosis, in contrast, is derived from the surrounding tissues and vessels, without any association with the splenic artery^{2,3}. A further difference is that the tissue in splenosis usually reveals distorted architecture with no hilum, a poorly formed capsule and the tissue may be of any shape or size, whereas accessory spleens have a more uniform hilar architecture, and are generally rounded or oval.

Pancreatic Splenosis demonstrated by Contrast Enhanced Ultrasonography

Conclusion

In conclusion this is a rare case of pancreatic splenosis, diagnosed by CEUS, without the need for surgical intervention. This condition should be suspected when asymptomatic masses are identified in patients with a history of splenic injury or surgery. We suggest that CEUS may be able to replace nuclear medicine imaging in the diagnosis of this condition, [which is in keeping with other recent literature¹²](#).

References:

1. GE Healthcare, Inc., 101 Carnegie Center, Princeton, NJ 08540-9998.
2. Fremont RD, Rice TW. Splenosis: A Review; South Med J. 2007 Jun;100(6):589-93.
3. Thourani VH, Sharma J, Duarte IG, et al. Intrathoracic Splenosis; Ann Thorac Surg. 2005 Nov;80(5):1934-
4. Tasci Y, Kayikcioglu F, Cavusoglu D, et al. Splenosis mimicking pelvic mass. Obstet Gynecol.; 2005 Nov;106(5 Pt 2):1167-9.
5. Fiamingo P, Veroux M, Da Rold A, et al. A rare diagnosis for a pancreatic mass: splenosis. J Gastrointest Surg.; 2004;8:915-916.
6. Mortelé, KJ., Mortelé B, Silverman SG. CT Features of the Accessory Spleen; Am J Roentgenol. 2004 Dec;183(6):1653-7.
7. Kim SH, Lee JM, Lee JY, et al. Contrast-Enhanced Sonography of Intrapancreatic Accessory Spleen in Six Patients; Am. J. Roentgenol., 2007 Feb;188(2):422-8.
8. Fleming CR, Dickson ER, Harrison EG Jr. Splenosis auto-transplantation of splenic tissue. Am J Med; 1976;61:414-419.
9. Ardengh JC, de Paulo GA, Ferrari AP. EUS-guided FNA in the diagnosis of pancreatic neuroendocrine tumors before surgery; Gastrointest Endosc. 2004 Sep;60(3):378-84.
10. Sica GT, Reed MF. Case 27: Intrapancreatic accessory spleen; Radiology. 2000 ;217(1):134-7.
11. Stewart VR, Sidhu PS; New directions in ultrasound: microbubble contrast; Br J Radiol. 2006;79(939):188-94.

[12. Bertolotto M, Quaia E, Zappetti R, et al . Differential diagnosis between splenic nodules and peritoneal metastases with contrast-enhanced ultrasound based on signal-intensity characteristics during the late phase, Radiol Med. 2009 Feb;114\(1\):42-51.](#)

1
2
3
4
5
6
7
8
9
10
11
12
13 Figures:

14 Figure 1

15
16
17 MRI

18 Axial T2 weighted spin echo sequence of the upper abdomen demonstrating a mass (arrow) in the
19 pancreatic tail with signal intensity similar to the renal parenchyma.
20
21

22
23
24
25 Figure 2A

26 CT without contrast.

27
28 Axial non-contrast enhanced CT section through the upper abdomen demonstrating flecks of calcification
29 (arrow) in the periphery of the mass.
30
31

32
33
34
35 Figure 2B

36 CT with arterial phase contrast medium enhancement

37
38 This shows heterogenous "stripes" through the lesion, typical of splenic parenchymal arterial enhancement
39 (arrow)
40
41

42
43
44 Figure 2C

45 CT with portal venous phase contrast medium enhancement.

46
47 Portal-venous phase contrast showing uniform enhancement through the lesion in the pancreas (arrow).
48
49

50
51
52 Figure 3

53 Ultrasonography

54
55 This image shows a hypoechoic 2.5cm lesion (arrow) within the pancreas.
56
57

58
59 Figure 4

60 Ultrasonography with contrast.

Pancreatic Splenosis demonstrated by Contrast Enhanced Ultrasonography

7

1
2
3
4
5
6
7
8
9
10
11
12
13
14
15
16
17
18
19
20
21
22
23
24
25
26
27
28
29
30
31
32
33
34
35
36
37
38
39
40
41
42
43
44
45
46
47
48
49
50
51
52
53
54
55
56
57
58
59
60

Split screen ultrasound image: contrast specific preset shown to the reader's right. The pancreatic tail mass remains strongly enhanced at 7:09 minutes post injection (arrow), well beyond blood-pool microbubble clearance.

Figure 5

Heat denatured red blood cell study and SPECT CT.

There is intense uptake of red blood cells within the partially calcified largest lesion closely related to the tail of the pancreas. Arrow shows splenosis nodule.

1
2
3
4
5
6 Response to reviewers:
7

8 **Title: Pancreatic Splenosis demonstrated by Contrast Enhanced Ultrasonography**

9
10 **JCU 10-256**
11
12
13
14
15
16
17
18
19

20 Dear Bruno D. Fornage, M.D.
21
22

23
24
25 Many thanks for your decision letter which kindly gives us the opportunity to make necessary
26
27 revisions to our submission.
28
29

30
31
32 We have welcomed your comments and have hopefully made all the changes that yourself, and
33
34 the reviewer, suggested. A point-by-point reply to your comments is below.
35
36
37

38
39 Many thanks for your response once again,
40

41
42 We look forward to hearing from you.
43
44
45

46 Yours sincerely,
47

48
49 Dr. Patrick Rogers MBChB BA
50
51
52
53
54
55
56
57
58
59
60

1
2
3
4
5
6
7
8
9
10
11
12
13
14
15
16
17
18
19
20
21
22
23
24
25
26
27
28
29
30
31
32
33
34
35
36
37
38
39
40
41
42
43
44
45
46
47
48
49
50
51
52
53
54
55
56
57
58
59
60

1. We have now included another ultrasonographis image of the splenosis which we feel is of value. Unfortunately the pancreas was only visualised with a left flank approach - we have now explained this in the text.

2. We had included the abstract in the online submission process. I assumed that this would be combined with the draft for your review, but this was not the case. I have now put it in the document.

3. The figures are now called in the text.

4. As above.

5. Completed

6. Completed

7. Completed

8. Completed

8. Completed

9. Completed

10. Yes, this is what we meant – we have changed this to “mechanical index”, and given a value.

11. We have complied wherever possible with the reference guidelines.

12. We now believe these to be accurate.

13. Completed

14. Completed

15. As we have included another image the figure numbering is not quite as you suggested, but the CT images are now named together (2 A-B-C). We have included another ultrasound image of the splenosis (fig 3), which we feel will interest your readership. The other images follow as previous.

16. This we have done. If you prefer the original way round, then we could use the original image.

17. Completed

Many thanks.